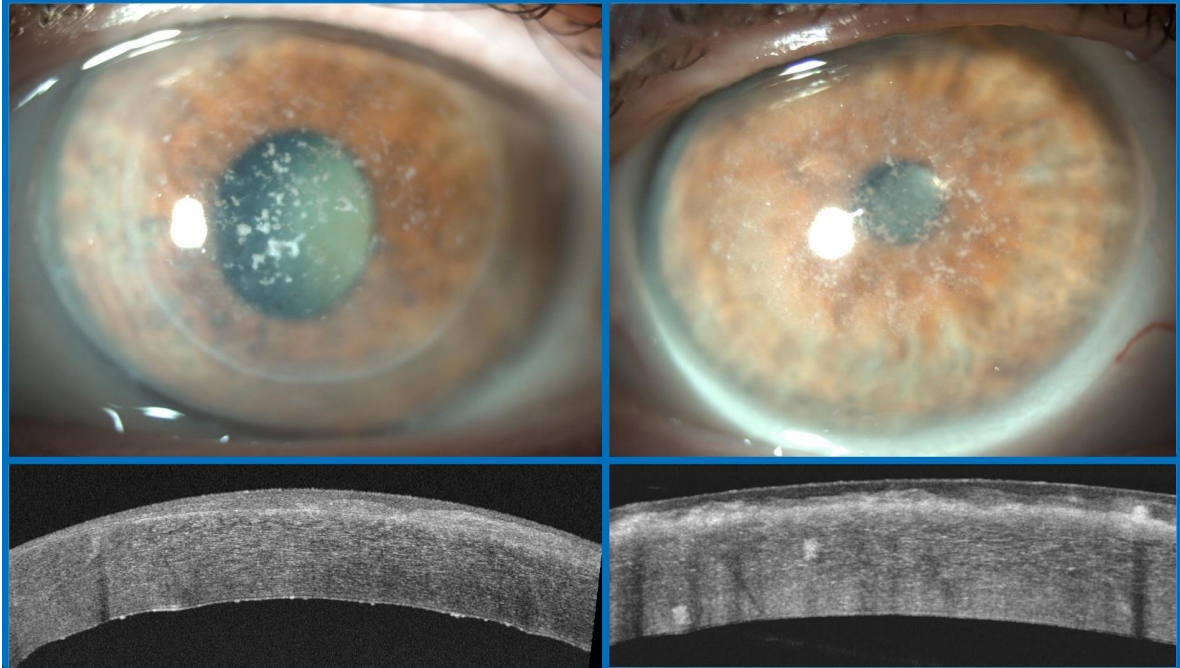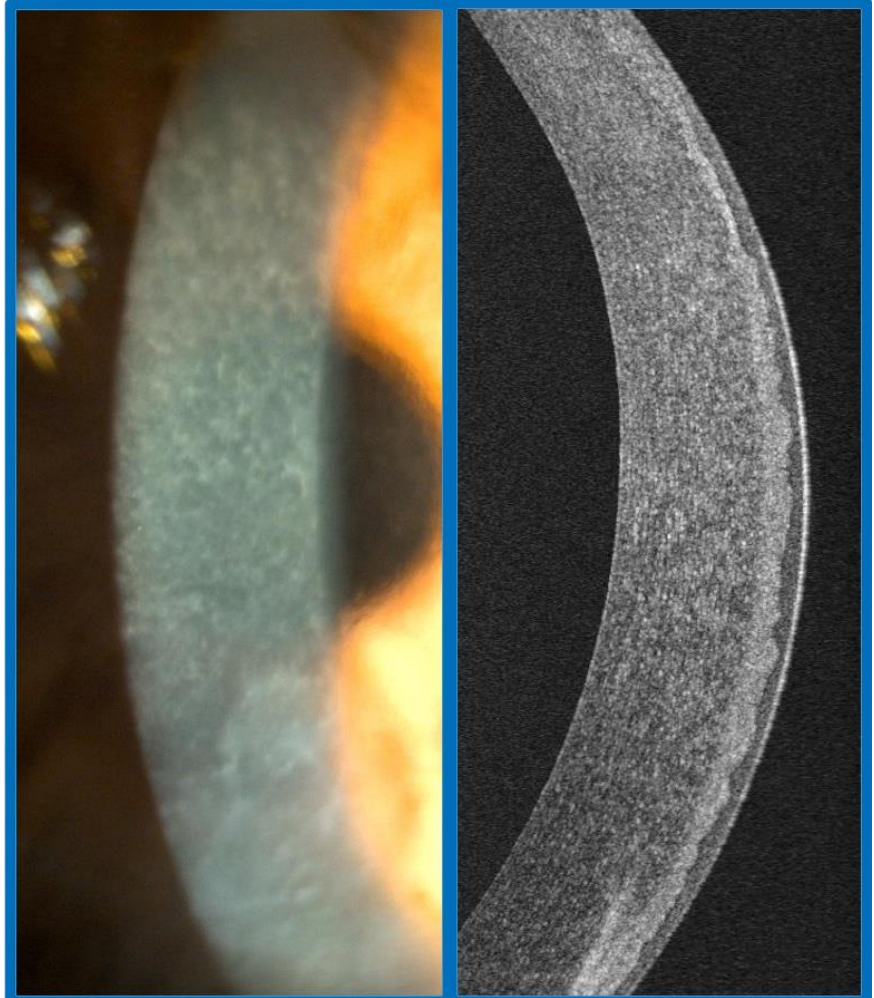


**Figure S1.** Anterior segment photo of RBCD (left) and OCT (right) showing irregular hyperreflective material at the Bowman layer.



**Figure S2.** Anterior segment photo of GCD of the right eye with old penetrating keratoplasty (top left) and left virgin cornea (top right), ASOCT of the right eye with recurrence of the disease and endothelial involvement (bottom left) and left eye with granular hyperreflective deposits in the stroma (bottom right).