Supplementary Material

1 Supplementary Tables

Supplementary Table S1. Primers used in this study.

Primer name	Sequence (5'-3')	Purpose
ORF38 L-F	GTGTTGGAGCTGACGG	Upstream homologous arm of ORF38 gene
ORF38 L-R	GCGAGCCGCCATTGA	
ORF38 R-F	ATCCCTCATACCGCCTC	Downstream homologous arm of ORF38 gene
ORF38 R-R	CCTGGAGATCCTGCTCA	
ORF37 R-F	GTGTTGGAGCTGACGG	Downstream homologous arm of ORF37/38 gene
ORF37 R-R	CTAAATCGACAAGGAG	
CMV-eGFP L-F	TAGTTATTAATAGTAATCAA	CMV-eGFP expression cassette
CMV-eGFP R-R	ATGCAGTGAAAAAAATGCT	
ΔORF38-F	TCTATACTTTCCTGAGC	Verification of ORF38 gene deletion
ΔORF38-R	AGACTCCACGGTTGC	
ΔeGFP-F	ATGGTGAGCAAGGGCGAG	Verification of eGFP gene deletion
ΔeGFP-R	ATCTAGATCCGGTGGATC	
ΔORF37-F	CTAGTACGATCTCACCGC	Verification of ORF37 gene deletion
ΔORF37-R	CACAACCGCTTCTATAAC	
eGFP-sgRNA-F	GCGAGGGCGATGCCACCTA	sgRNA targeting eGFP gene
eGFP-sgRNA-R	TAGGTGGCATCGCCCTCGC	
ORF37-sgRNA1-F	TATTCCGCCAAACGTGATA	sgRNA targeting ORF37 gene
ORF37-sgRNA1-R	TATCACGTTTGGCGGAATA	
ORF38-sgRNA2-F	CTCGGCGTTGAAGGTGCGCG	sgRNA targeting ORF38 gene
ORF38-sgRNA2-R	CGCGCACCTTCAACGCCGAG	

Supplementary Table S2. Virus strains and plasmids used in this study.

Strain Number	Genotype/Phenotype	Source
YM2019	Wild type EHV-1	China General Microbiological Culture Collection Center GenBank: MT063054
YM2019 ΔORF38	EHV-1 ORF38 gene-deleted virus	This study
YM2019 ΔORF37/38	EHV-1 ORF37/38 gene-deleted virus	This study
HDR-ORF38-E	pUC-19-ORF38 HDR-eGFP	This study
HDR-ORF38	pUC-19-ORF38 HDR	This study
HDR-ORF37/38-E	pUC-19-ORF37/38 HDR-eGFP	This study
HDR-ORF37/38	pUC-19-ORF37/38 HDR-eGFP	This study
ORF38-sgRNA1	pX330-ORF38-sgRNA1	This study
ORF37/38-sgRNA1	pX330-ORF37/38-sgRNA1	This study
CMV-eGFP-sgRNA	pX330-CMV-eGFP-sgRNA	This study

Supplementary Table S3. Histopathologic grading of lung and brain tissues in EHV-1

Histopathologic changes	**Histopathologic grading**			
Lung	**Normal**	**mild infection**	**moderate infection**	**fatal infection**
Interstitial pneumonia	0	1	2	3
Fibrosis	0	1	2	3
Inflammatory exudates	0	1	1	2
Neutrophilic inflammation	0	1	2	2
Hemorrhage	0	1	2	3
Brain	**Normal**	**mild infection**	**moderate infection**	**fatal infection**
Nonsuppurative encephalitis	0	1	2	3
Neuronal necrosis	0	1	2	3
Macrophage infiltration	0	1	2	2
Microglial activation	0	1	1	2
Gliosis	0	1	2	3

a score of < 3 indicates no typical pathological changes; 3 ⩽ score < 5 indicates mild pathological changes; 5 ⩽ score < 8 indicates moderate pathological changes; 8 ⩽ score < 10 indicates severe pathological damage.

Supplementary Table S4. Scoring system for clinical signs in EHV-1

Sign		Score
Mental State	Active and alert	0
	Depressed and standing still	1
	Lying still, moves after stimulation	2
	Lying still, no response after stimulation	3
Feeding and Weight	Immediate foraging and hoarding, normal weight gain	0
	Reduced feeding, slowed or no weight gain	1
	Does not actively forage but eats when fed separately, weight loss	2
	Completely stops eating, rapid weight loss	3
Discharges	No nasal discharge	0
	Small amount of watery nasal discharge	1
	Large amount of mucopurulent nasal discharge	2
	Excessive discharge from mouth, nose, and eyes	3
Neurological Signs	Has normal resistance reflexes	0
	Standing still with involuntary head and forelimb tremors	1
	Supine convulsions	2
	Complete paralysis	3
Respiratory Rate	Normal respiration (< 80/min)	0
	Slightly increased rate (81~120/min)	1
	Severely increased rate (> 121/min)	2
	Respiratory distress, exhibiting oral breathing	3
Death/ Total		**15**

a score of < 3 indicates no clinical signs; 3 ⩽ score < 5 indicates mild clinical signs; 5 ⩽ score < 8 indicates moderate clinical signs; 8 ⩽ score < 10 indicates severe clinical signs; a score of > 10 indicates fatal signs.

2 Supplementary Figures

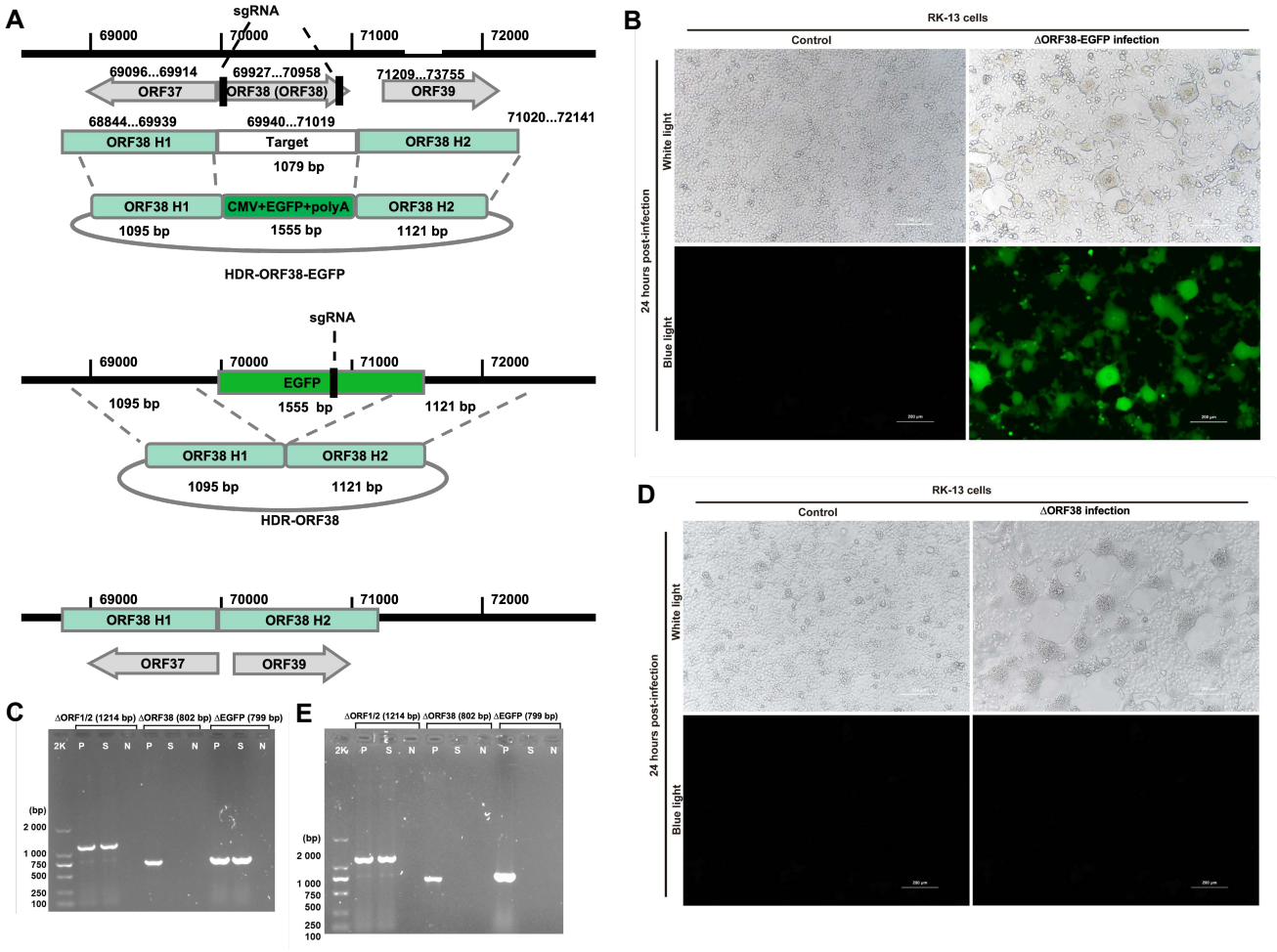

Supplementary Figure S1. Construction and identification of a ORF38 gene deletion mutant virus (EHV-1 ΔORF38). (A) The eGFP cassette was inserted using the Cas9 system based on the parental strain, and the ORF38 gene was replaced with the eGFP cassette to create the ΔORF38-eGFP mutant. (B) The CPE and green fluorescence were observed under a fluorescence microscope. (C) The deletion of the ORF38 gene and insertion of the eGFP gene were confirmed through PCR. (D) Under a fluorescence microscope, a CPE and no green fluorescence was observed. (E) PCR confirmed the deletion of the ORF38 and eGFP genes.

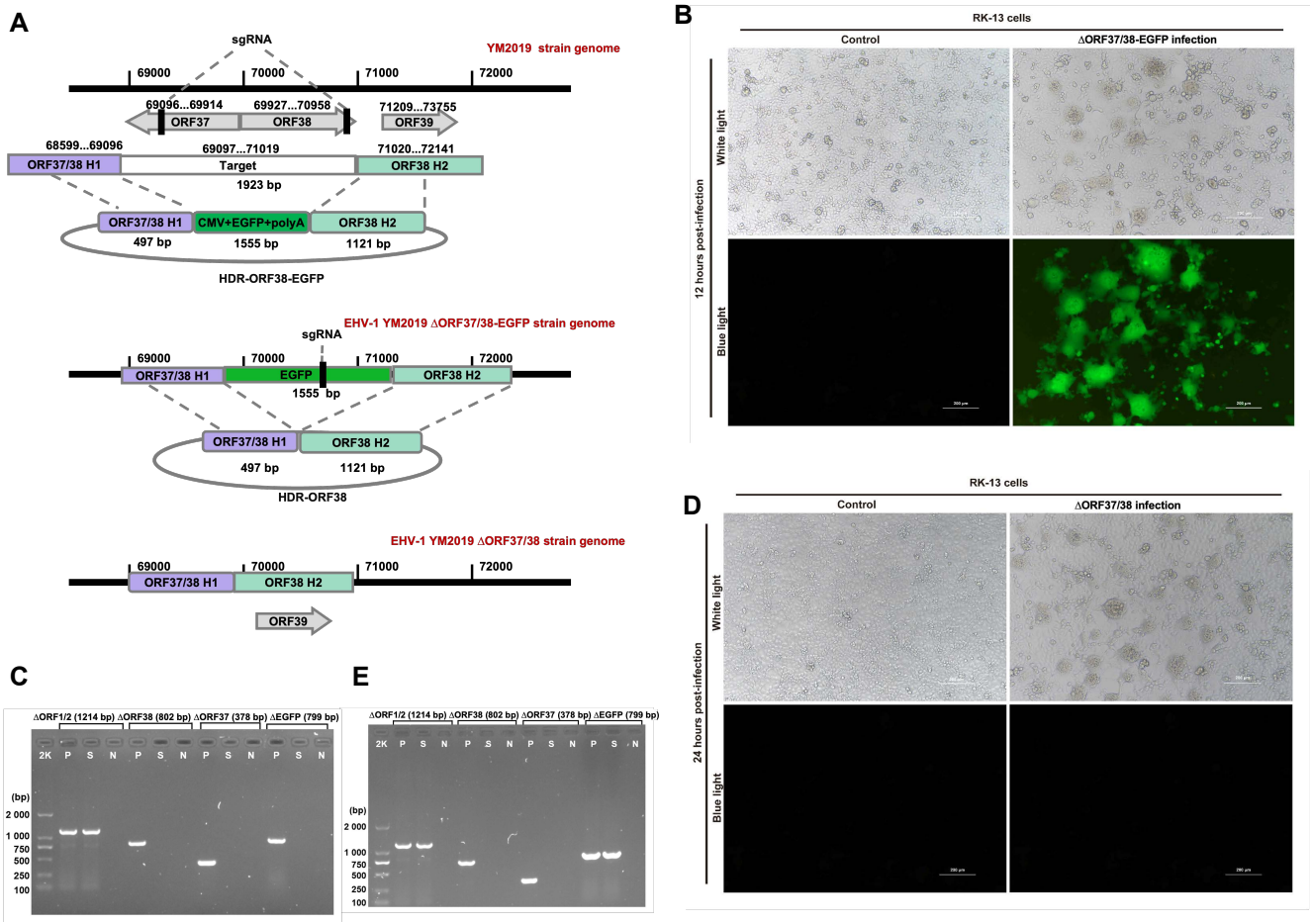

Supplementary Figure S2. Construction and identification of ORF37/38 genes deletion mutant virus (EHV-1 ΔORF37/38). (A) The eGFP cassette was inserted using the Cas9 system based on the Δgp2 mutant virus, and the ORF37/38 genes was replaced with the eGFP cassette to create the ΔORF37/38-eGFP mutant. (B) The CPE and green fluorescence were observed under a fluorescence microscope. (C) The deletion of the ΔORF37and ORF38 genes and insertion of the eGFP gene were confirmed through PCR. (D) Under a fluorescence microscope, a CPE and no green fluorescence was observed. (E) PCR confirmed the deletion of the ΔORF37, ORF38, and eGFP genes.

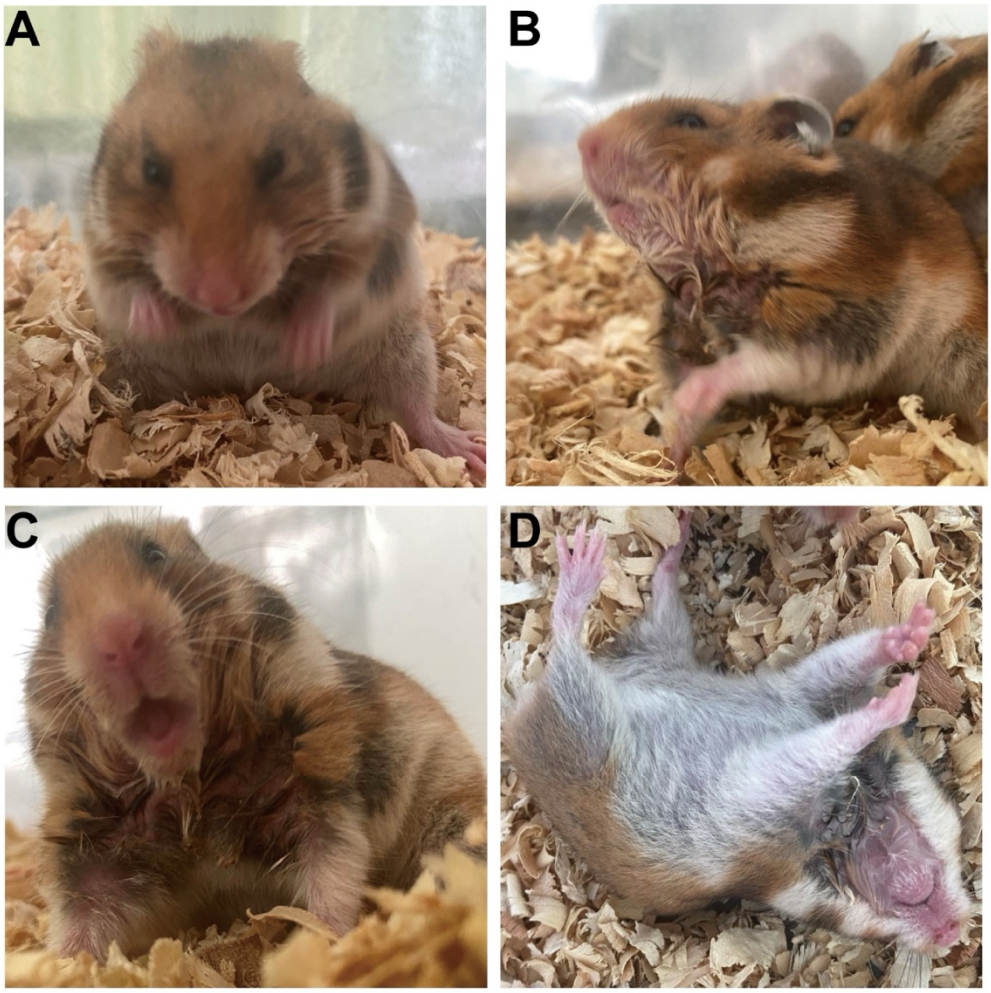

Supplementary Figure S3. Clinical signs of Syrian hamsters infected with EHV-1 YM2019 strain. (**A**) Mental depression and no appetite for food. (**B**) Salivation, (**C**) Breathing difficulties and choking, (**D**) Paralysis. For humanitarian reasons, all animals were euthanised at the end of clinical follow-up.

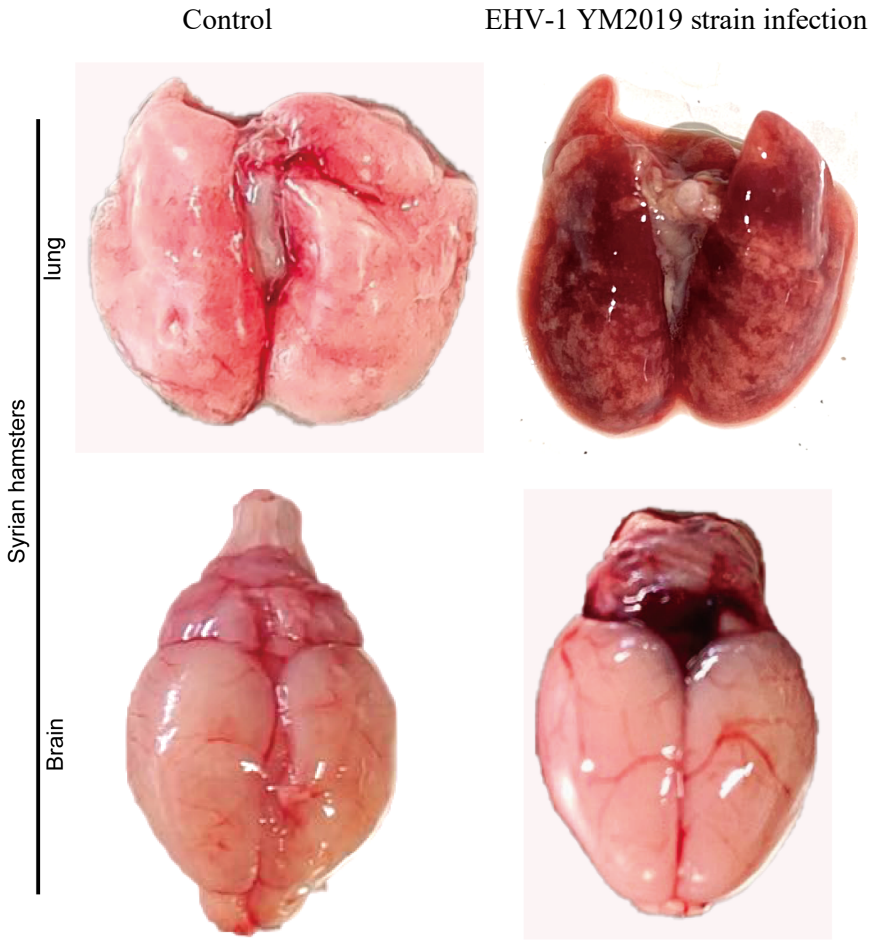

Supplementary Figure S4. Gross pathology of lung and brain of Syrian hamsters infected with EHV-1 YM2019 strain. Gross pathological observations of the lungs in hamsters infected with the EHV-1 YM2019 strain included pulmonary congestion and edema, with a mottled appearance on the surface, accompanied by exudation of fibrin and red blood cells. Gross pathological lesions in the brains of hamsters infected with the EHV-1 YM2019 strain presented as mild congestion and edema.