technologies

MDPI

Supplementary Material

Demonstration of the Proposed Methods in Action

The input data for demonstrating the proposed methods consists of ECG images used in clinical trials. An example of such a signal is shown in Figure S1.



Figure S1. Example of ECG images obtained from real patient case histories for use in clinical trials. This figure illustrates raw ECG recordings before any preprocessing steps, visually representing actual patient data.

To extract the ECG signal from these images (see example ECG in Figure S1), a preliminary image-processing stage was conducted, including:

- Removing all textual information from the input image.
- Splitting the input image into distinct fragments, each representing the ECG from a separate channel (Figure S2).

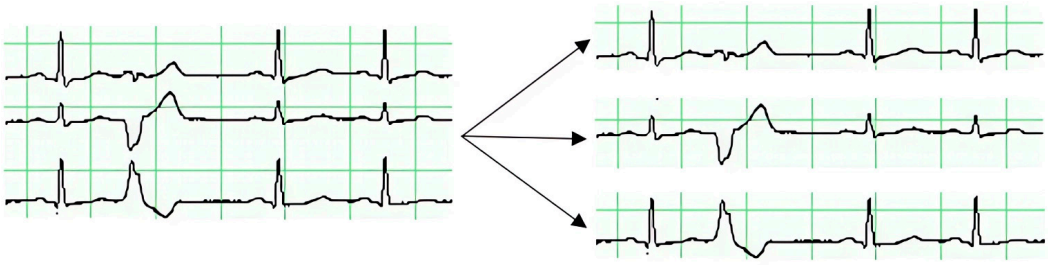

Figure S2. Example of dividing the ECG image into isolated channel-specific images. This figure highlights how each channel's waveform is separated for individual analysis, aiding in more precise signal processing.

The process of extracting the ECG from the images begins by converting the image to a grayscale. Next, using OpenCV v4.9.0 (free and open-source software under Apache 2 License), the image is transformed into a binary format, where every pixel is either black or white. This simplifies detecting the ECG waveform since black pixels are now represented on a white background. The vertical coordinates of the black pixels are gathered to reconstruct the signal line. These coordinates are then converted into a 1D array that reflects the amplitude of the ECG signal. Consequently, the proposed methods transform the ECG image into a digital format for further processing and classification. An example of the resulting 1D representation of the ECG is shown in Figure S3.

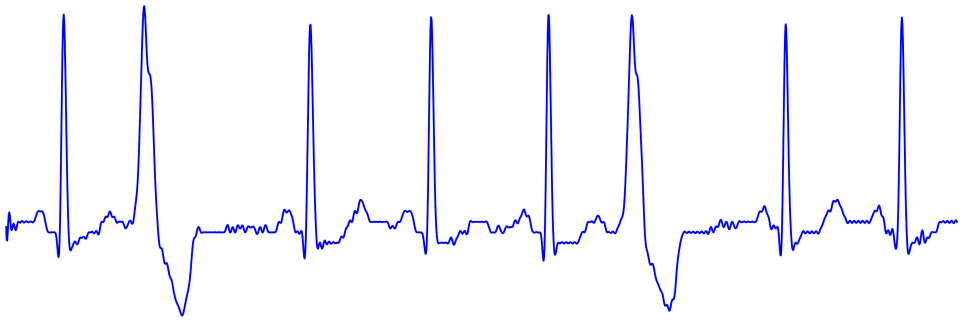

Figure S3. Visualization of the resulting 1D ECG. This figure demonstrates how the pixel-based ECG waveform, extracted from the original image, is converted into a one-dimensional array suitable for subsequent analysis.

The newly created 1D array representation of the ECG signal allows for applying the proposed methods.

The first processing method employed is the proposed method for identifying R peaks in ECG (see subsection 3.1 in the main text). In accordance with the steps of this method, domain knowledge of the reference ECG is integrated into the real-world ECG input. Figure S4 shows how these knowledge overlays are visualized on top of the ECG.

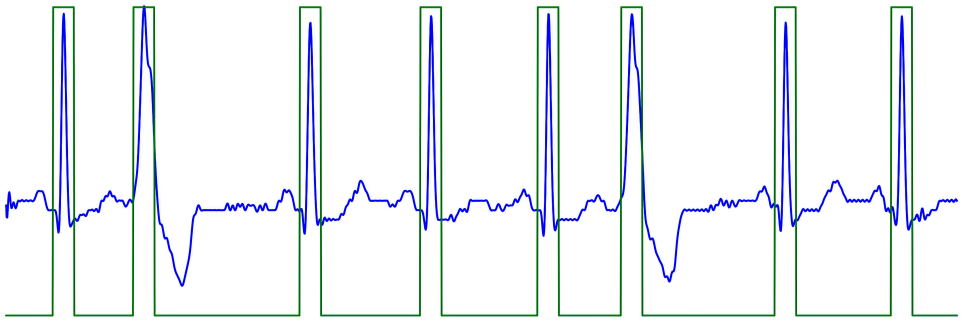

Figure S4. Visualization of the knowledge overlay applied to the input ECG. This figure shows how domain knowledge of the reference ECG (zones highlighted in green) is merged with the real ECG recording to facilitate more accurate R peak detection.

Both the ECG and the integrated knowledge are then fed into an encoder-decoder neural network to determine the indices of the R peaks. After processing the input data, the neural network returns probabilities transformed into R peak indices. In Figure S5, the detected R peaks for the input ECG are marked with red circles.

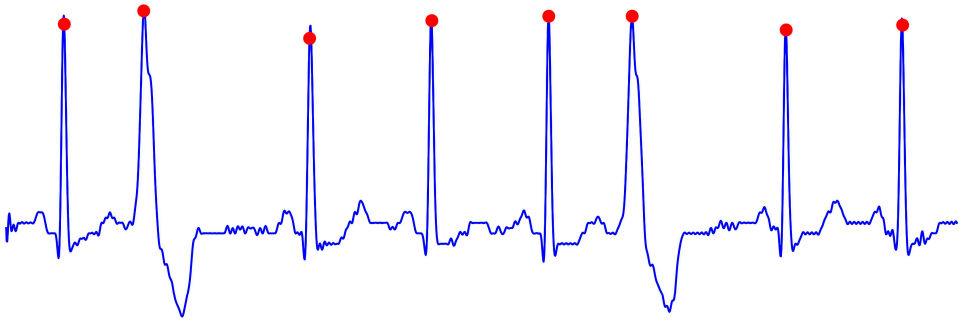

Figure S5. Visualization of the detected R peaks. Here, red circles indicate the positions of R peaks identified by the encoder-decoder neural network on the processed ECG.

Next, the ECG signals and the indices of the detected R peaks are processed using the introduced method for classifying arrhythmia based on ECG (see subsection 3.2 in the main text). Based on the detected R peak indices, segments of the ECG are generated for classification by the developed CNN model. An example of the segmented fragments is shown in Figure S6.

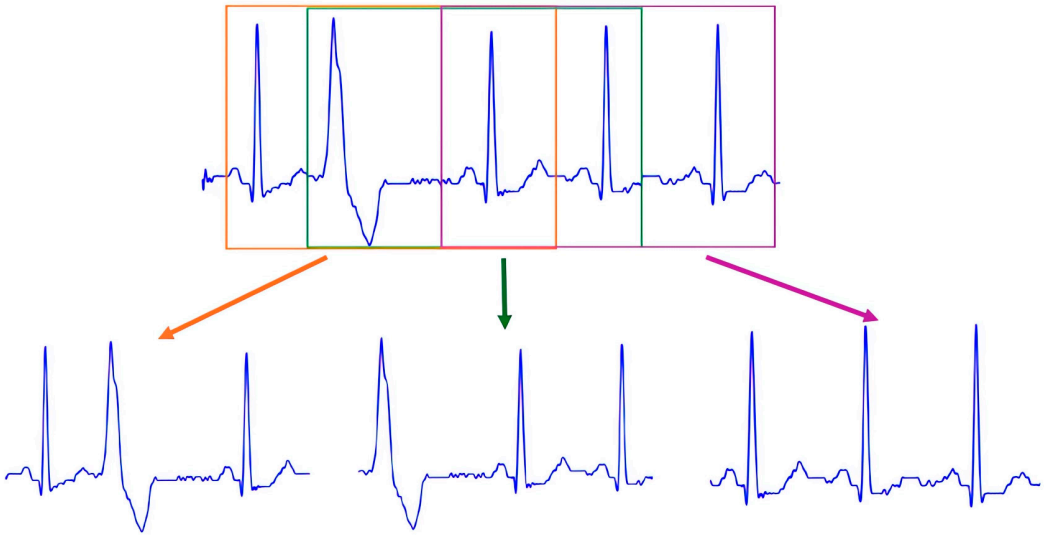

Figure S6. Visualization of segmented ECG fragments for classification. Each fragment, centered around an R peak, is prepared for input into the CNN model to identify potential heart arrhythmia. Each colored rectangle (orange, green, and purple) represents one of the cardio cycles derived from the input ECG by splitting it into three cardio cycles.

These segmented fragments are fed into the CNN model to classify detected pathology. Under the proposed method, the ECG can be classified into nine classes, including one "normal" class. The output of the CNN model is a predicted class for each fragment of the ECG signal. The classes determined for all fragments are combined into a single list representing the entire ECG input. Figure S7 illustrates the ECG signal with identified classes at the level of each cardio cycle. In this example, the label "N" corresponds to "Normal," while the label "V" represents "Ventricular Extrasystole."

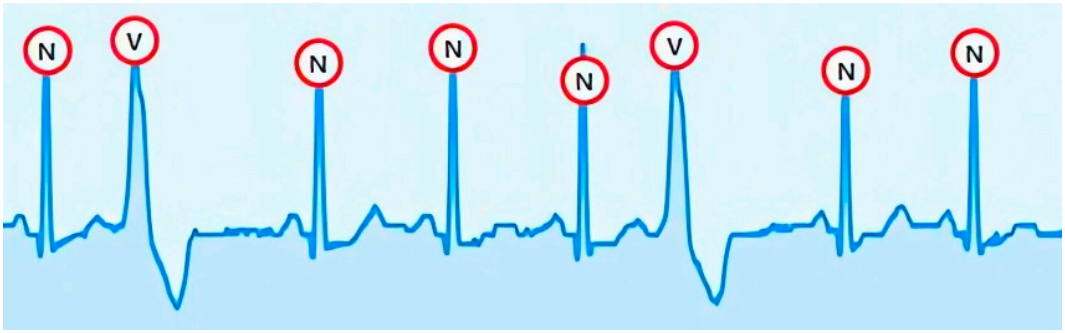

Figure S7. Visualization of each cardio cycle's class within the input ECG signal. In this figure, "N" indicates a normal cycle, and "V" indicates a ventricular extrasystole. The classification allows clinicians to identify arrhythmic events with a quick visual reference.

The final stage of ECG processing is the interpretation of the classification results, which is performed based on the proposed method for interpreting classification results (see subsection 3.3 in the main text). The interpretation method is demonstrated here for the "Ventricular Extrasystole" pathology, identified in the middle cardio cycle shown in Figure S8a.

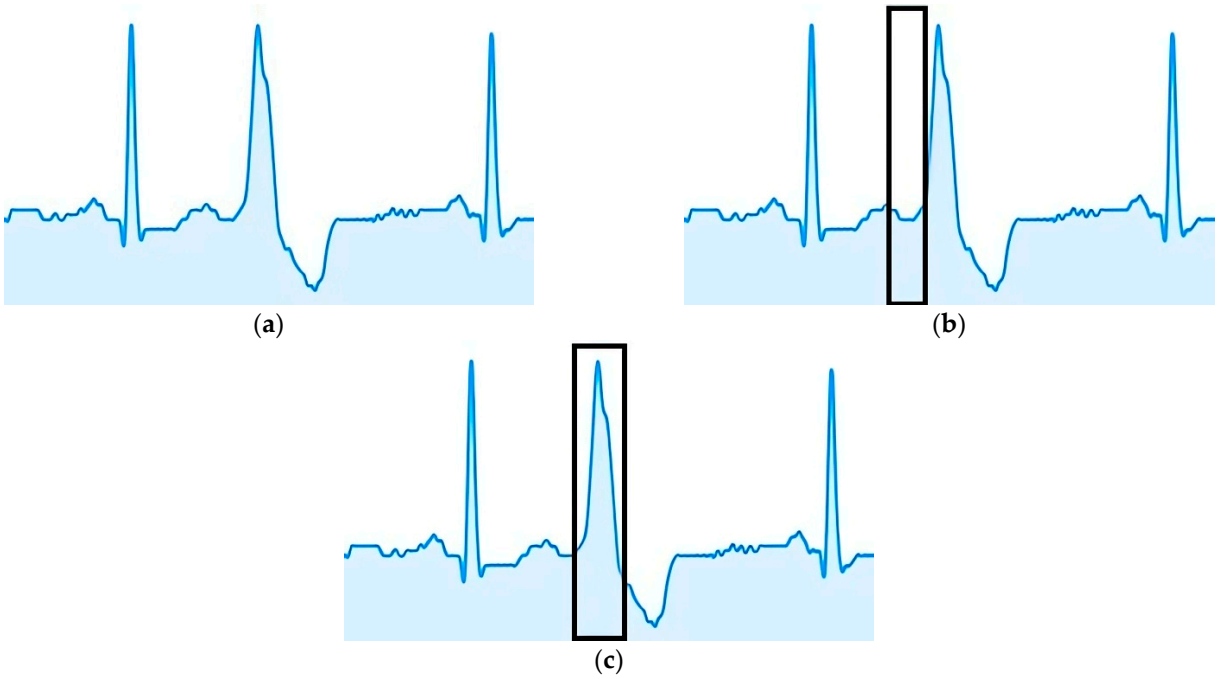

Figure S8. Illustration of (**a**) a cardio cycle with a "Ventricular Extrasystole," (**b**) the attention zone for the "Absent P wave" feature marked in black, and (**c**) the attention zone for the "Extended and deformed QRS complex" feature highlighted in black. These annotated views help explain the characteristic regions of interest for diagnosing a "Ventricular Extrasystole."

This pathology is characterized by the following features:

- Absent P wave.
- Extended and deformed QRS complex.
- Presence of a compensatory pause.

Consider the "Absent P wave" feature. According to clinical standards, when the P wave preceding the QRS complex is missing, it indicates a "Ventricular Extrasystole." Under the proposed interpretation method, an attention zone is determined for this feature. Visualization of the identified feature is shown in Figure S8b.

The next step involves selecting an approach to confirm or refute the presence of this feature. The conclusion about the given feature is reached with the help of the Neurokit2 v0.2.7 package (free and open-source software under MIT License), which can detect peaks in the ECG signal, including the P wave.

Next, the feature "Extended and deformed QRS complex" is considered. Similar to the previous feature, the portion of the signal corresponding to the current pathology's attention zone is identified (Figure S8c).

To explain this feature, applying a straightforward formula or statistical indicators is impossible. Therefore, according to the steps of the proposed interpretation method, a comparison is made between the cardio cycle of the identified pathology and that of a normal cycle. The comparison result is shown in Figure S9, where the analyzed ECG is displayed in green.

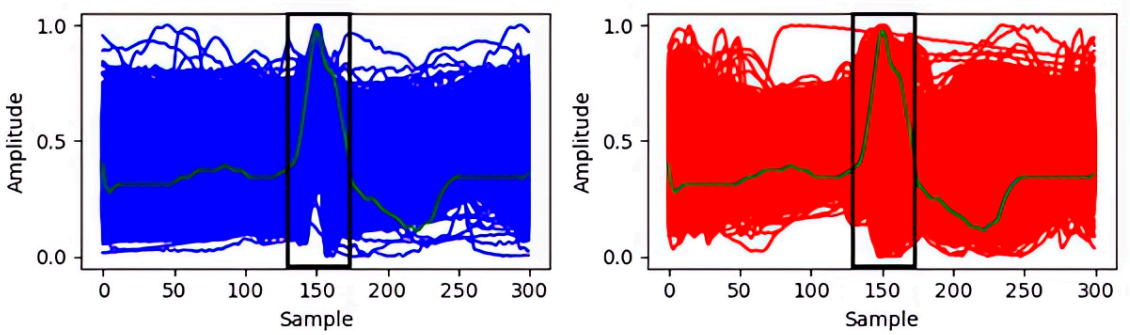

(**a**) (**b**)

Figure S9. Visual comparison of the ECG signal with (**a**) "Normal" class signals and (**b**) signals of the "Ventricular Extrasystole" class. The cardiac cycle, highlighted in green, is overlaid with a black rectangle to emphasize the zone of interest and represent the relevant signal fragment.

As shown in Figure S9, the ECG signal in the attention zone does not exhibit distinct separation. Hence, the next step involves a visual analytics procedure that uses ECG data obtained from the attention zone (see subsection 3.3.2 in the main text). The outcome of applying visual analytics to the ECG is illustrated in Figure S10.

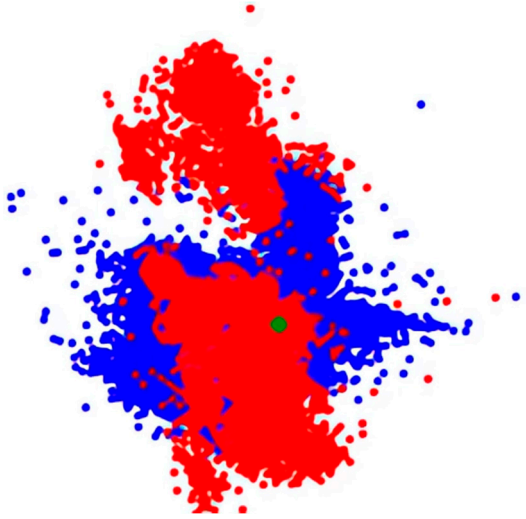

Figure S10. Application of visual analytics to the ECG signal. Red and blue clusters represent two distinct classes, highlighting areas of overlap and separation; the green dot represents the target ECG. This figure demonstrates how advanced visualization techniques (such as dimensionality reduction) help identify potential clusters or overlaps within the chosen signal segments.

From the results of this visual analytics step (see Figure S10), one can confirm that certain groupings exist in the ECG data obtained from the attention zone; however, no clear boundary differentiates these groupings. In such a situation, using deep learning methods to verify the presence of a feature is more effective than relying on traditional machine-learning approaches. Therefore, the portion of the signal taken from the attention zone is fed into a CNN model for binary classification, confirming or refuting the feature's presence or absence.

For the "Presence of a Compensatory Pause" feature, the attention zone is shown in Figure 11.

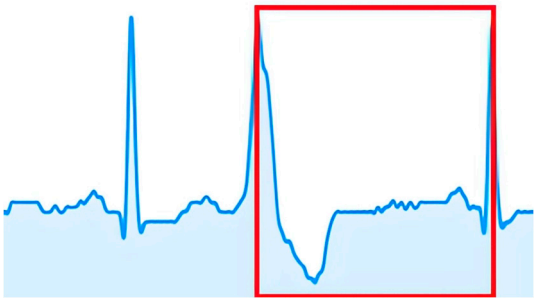

Figure S11. Illustration of a cardio cycle with the attention zone for the "Presence of a Compensatory Pause" feature (marked in red rectangle). This scheme highlights the segment immediately following a "Ventricular Extrasystole," crucial for detecting whether a pause matches clinical definitions.

Finally, it should be noted that the compensatory pause after a "Ventricular Extrasystole" is defined by the criterion in which the sum of the RR intervals before and after the extrasystole is equal to twice the normal RR interval. Hence, to confirm the presence of a compensatory pause, the following formula is used:

$$RR_{prev} + RR_{next} \approx 2 \times RR_n,$$

where RR_{prev} is the RR interval before the extrasystole, RR_{next} is the RR interval immediately after the extrasystole, and RR_n is the normal RR interval.