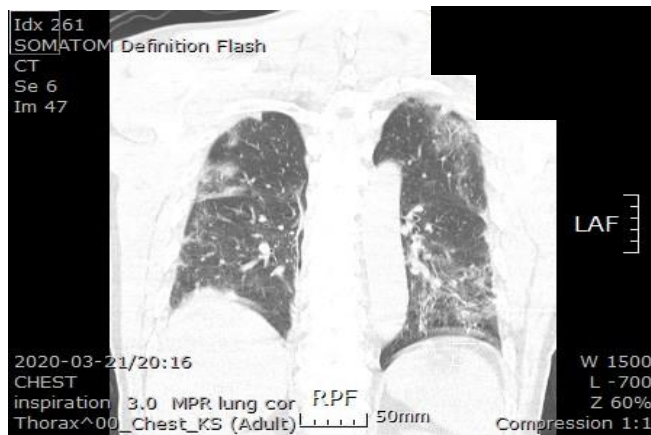
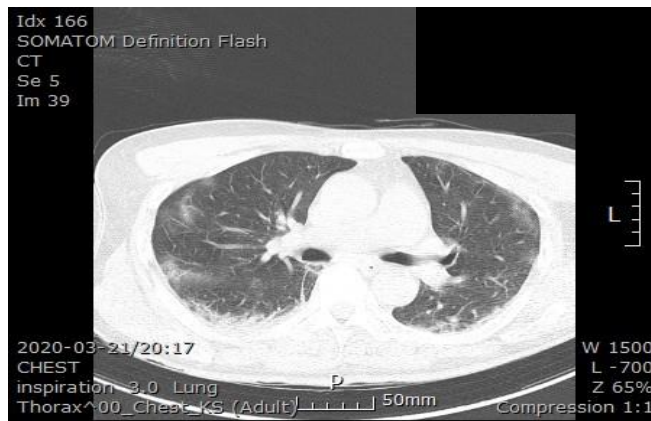
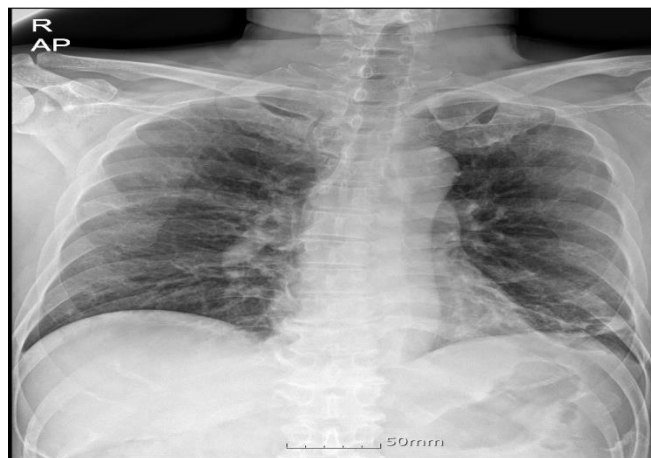

Case 1  
58/ M



Case 2  
59/ F

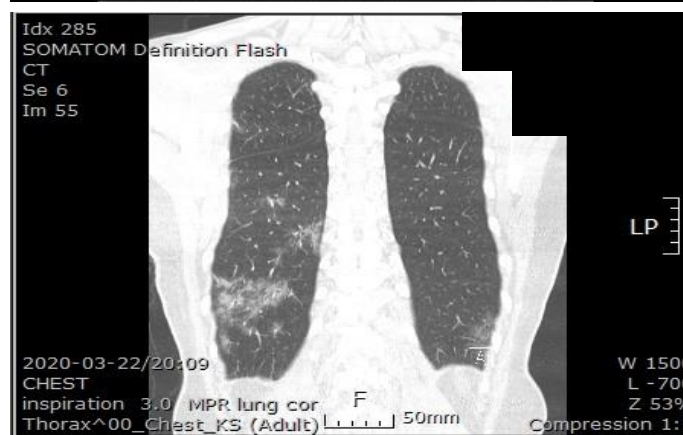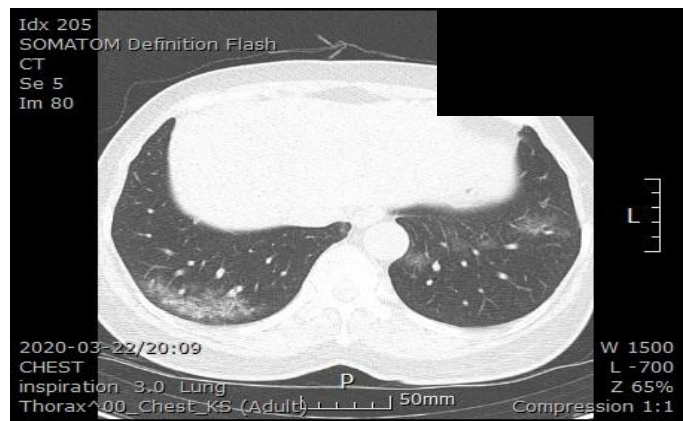

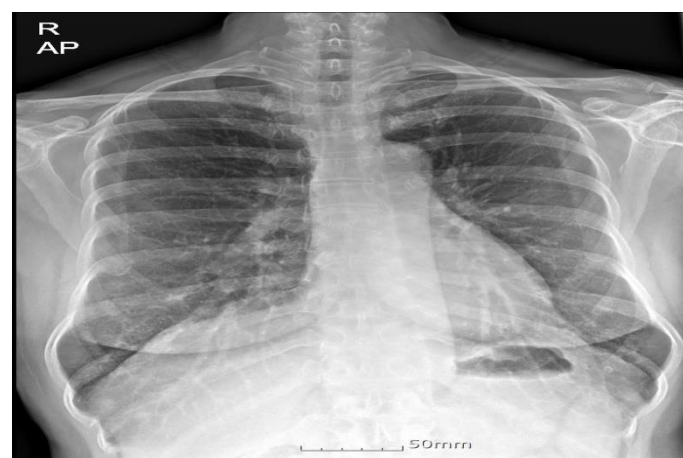
Figure S1. Plain chest radiograph and CT scan images of SARS-CoV2 office cleaner patients