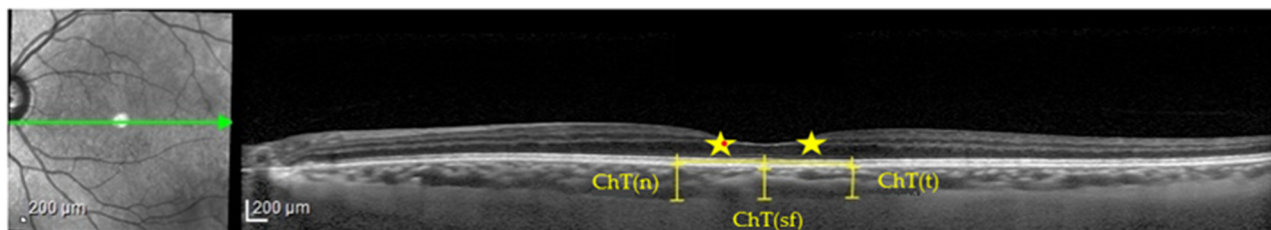


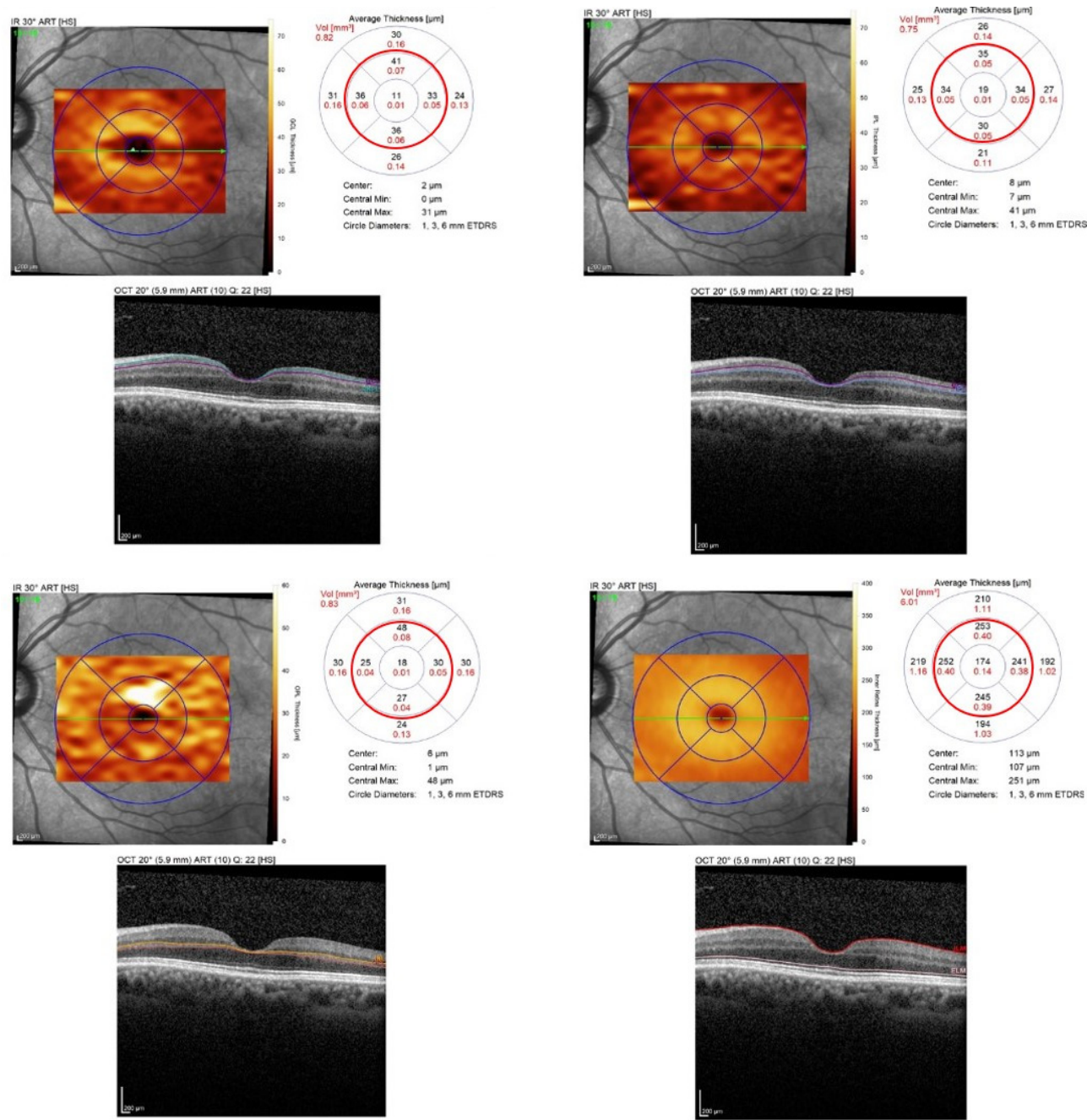
## Supplementary Materials:

**Figure S1.** Choroidal thickness (ChT) measurement in a healthy control (HC).



Legend: ChT(n), nasal choroidal thickness; ChT(sf), subfoveal choroidal thickness; ChT(t), temporal choroidal thickness; ★, 750 microns of horizontal distance from fovea.

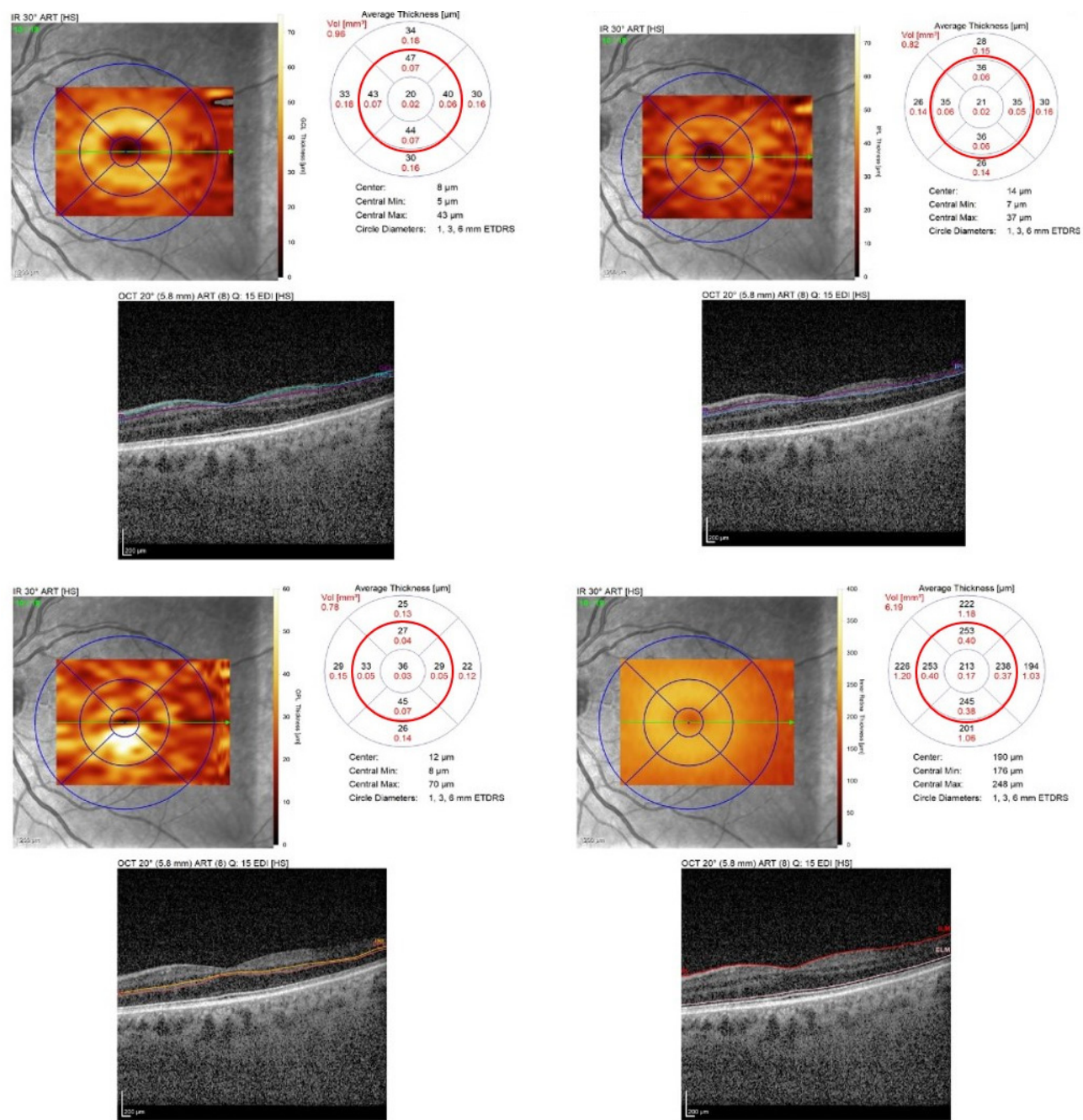
**Figure S2.** Retinal layer's (GCL, IPL, OPL, IRL respectively) thickness measurement in 5 central macular regions: a PSP patient.



Legend: red circle, 5 central macular regions.

Abbreviations: GCL, ganglion cell layer; IPL, inner plexiform layer; OPL, outer plexiform layer; IRL, inner retinal layers.

**Figure S3.** Retinal layer's (GCL, IPL, OPL, IRL respectively) thickness measurement in 5 central macular regions: a HC patient.



Legend: red circle, 5 central macular regions.

Abbreviations: GCL, ganglion cell layer; IPL, inner plexiform layer; OPL, outer plexiform layer; IRL, inner retinal layers.