



Figure S1. A receiver operating characteristic (ROC) curve analysis was used to evaluate the predictive value of the presence of 5.5–6.0 mm tags located on the posterior aspect of Right Upper Pulmonary Vein (RUPV) for a postablation AF recurrence among paroxysmal AF subgroup.

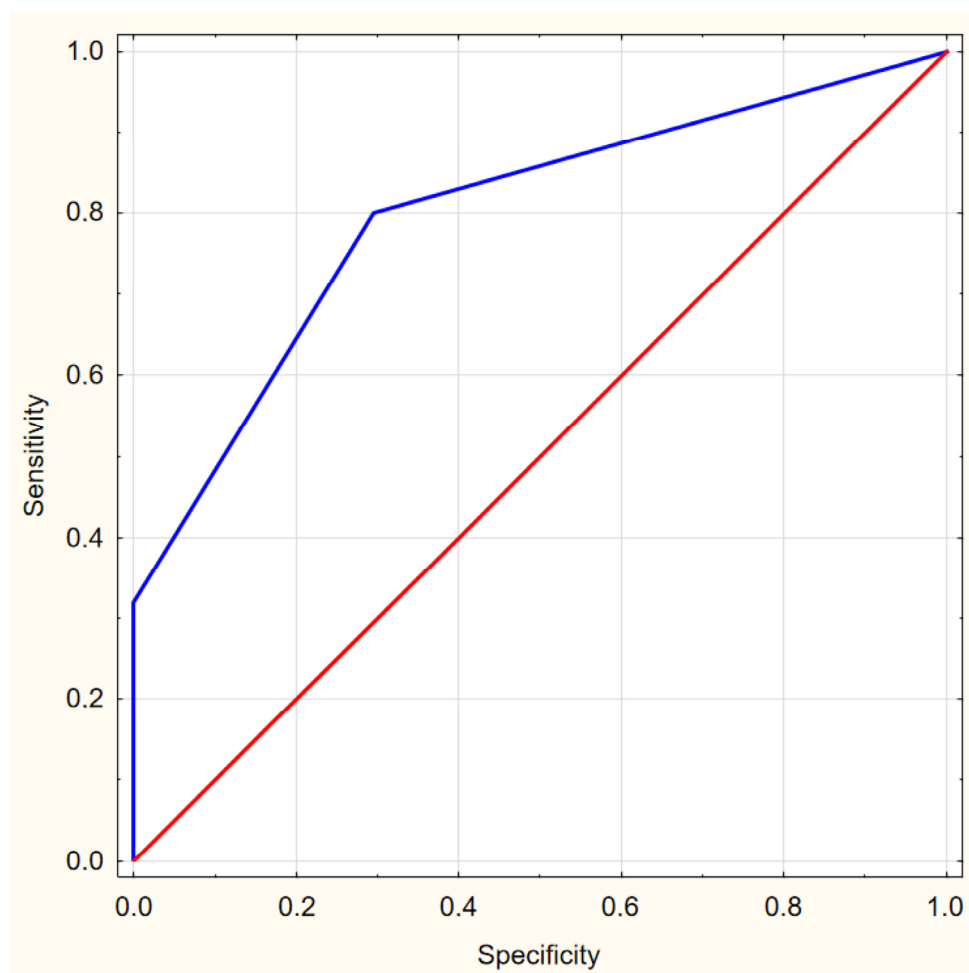


Figure S2. A receiver operating characteristic (ROC) curve analysis was used to evaluate the predictive value of the presence of 5.5–6.0 mm tags located on the posterior aspect of Right Upper Pulmonary Vein (RUPV) for a postablation AF recurrence among persistent AF subgroup.

