Supplementary Table S1 – Search strategy

Ovid MEDLINE (ALL – 1946 to present)
Searched on November 16, 2022
No language, article type, or publication date restrictions

Line #	Search
1	Neurilemmoma/ and Heart Neoplasms/
2	((cardiac or atrial or artery or arteries or heart or aorta or aortic or pericardial or pericardium) adj3 (schwannoma* or schwann cell* or neurilemmoma* or neurilemoma* or neurinoma* or neurolemmoma or nerve sheath tumor* or nerve sheath tumour*)).tw.
3	1 or 2

Ovid Embase (1974 to present)
Searched on November 16, 2022
No language, article type, or publication date restrictions

Line #	Search
1	neurilemoma/ and heart tumor/
2	((cardiac or atrial or artery or arteries or heart or aorta or aortic or pericardial or pericardium) adj3 (schwannoma* or schwann cell* or neurilemmoma* or neurilemoma* or neurinoma* or neurolemmoma or nerve sheath tumor* or nerve sheath tumour*)).tw.
3	1 or 2

Cochrane Library (Wiley)
Searched on November 16, 2022
No language, article type, or publication date restrictions

ID	Search
#1	((cardiac or atrial or artery or arteries or heart or aorta or aortic or pericardial or pericardium) NEAR/3 (schwannoma or "schwann cell" or neurilemmoma or neurilemoma or neurinoma or neurolemmoma or "nerve sheath tumor" or "nerve sheath tumour")):ti,ab

Web of Science – Core Collection (Clarivate)
Searched on November 16, 2022
No language, article type, or publication date restrictions

ID	Search
#1	TS=((cardiac or atrial or artery or arteries or heart or aorta or aortic or pericardial or pericardium) NEAR/3 (schwannoma or "schwann cell" or neurilemmoma or neurilemoma or neurinoma or neurolemmoma or "nerve sheath tumor" or "nerve sheath tumour"))

Supplementary Table S2 – Overview of the included studies

Author - Year	Journal	Country	Brief case description
Anderson 2011	Journal of Cardiac Surgery	USA	Presented with exertional dyspnea, syncope, sever aortic stenosis. Aortic valve replacement and mass resection was performed.
Arava 2015	Indian Journal of Pathology and Microbiology	India	Presented with rest dyspnea, palpitations, chest pain, low-grade fever, weight loss, severe tricuspid regurgitation, severe pulmonary hypertension, and mitral valve obstruction. Mass resection was performed.
Betancourt 1979	Chest	Puerto Rico	Presented with rest dyspnea, chest pain, and right ventricular outflow tract obstruction. Mass resection was performed.
Bizzarri 2001	Journal of Cardiovascular Surgery	Italy	History of renal adenocarcinoma. Presented with dyspnea and chest pain. Mass resection was performed.
Brandao 2020	Canadian Journal of Cardiology	Brazil	Previous parathyroidectomy due to a malignant tumor. Presented with palpitations and moderate dyspnea. Surgery not possible for dimension and multiple metastases. Chemotherapy was performed.
Cho 2012	Journal of Cardiac Surgery	South Korea	Presented with chest discomfort. Metastasis to lung. Mass resection and lung wedge resection were performed.
Dammert 1955	American Heart Journal	Finland	Presented with rest dyspnea, chest pain, cyanosis. Metastatic to mediastinum. Patient died before diagnosis.
Early 2007	Journal of Cardiothoracic Surgery	Ireland	Presented with hematemesis. Mass resection was performed.

Eekhoudt 2019	Canadian Journal of Cardiology	Canada	Presented with dyspnea, generalized malaise, headache, and night sweats. Surgery not possible for dimension and metastases to lung and brain. Chemo-radiotherapy was performed.
Eindhoven 2018	International Journal of Cardiovascular Imaging	The Netherlands	Presented with palpitations, dyspnea and abdominal pain. Partial debulking was performed.
Factor 1976	Cancer	USA	History of ovary papillary serous crystadenocarcinoma with liver metastases. Asymptomatic at presentation. Surgery not performed as terminally ill.
Fan 2012	American Journal of Clinical Pathology	USA	Presented with generalized swelling. Mass resection was performed.
Forbes 1994	Annals of Thoracic Surgery	USA	Presented with atrial fibrillation and chest pain. Mass resection was performed.
Gelfand 1977	Journal of Thoracic and Cardiovascular Surgery	Canada	Presented with dyspnea, cyanotic, nausea, epigastric pain, syncope, and tricuspid valve obstruction. Mass resection with chemo-radiotherapy was performed.
Gleason 1972	New York State Journal of Medicine	USA	Asymptomatic at presentation. Mass resection was performed.
Guo 2002	Chinese Journal of Internal Medicine	China	Presented with dyspnea, chest pain, and mitral valve obstruction. Mass resection and mitral valve replacement was performed.
Gushmann 1996	Pathologe	Germany	History of non-hodgkin lymphoma. Presented with dyspnea, mitral and aortic valve insufficiency. Mass resection, mitral valve plasty, aortic valve replacement and chemotherapy were performed.
Hallman 1966	Journal of Cardiovascular Surgery	USA	Presented with exertional dyspnea, easy fatigability. Mass resection was performed.

Hashimoto 1998	Annals of Thoracic Surgery	Japan	Asymptomatic at presentation. Mass resection was performed.
Huang 2021	Chinese Journal of Pathology	China	Presented with cough, exertional dyspnea, and hemoptysis. Mass resection was performed.
Hwang 2014	Korean Journal of Thoracic and Cardiovascular Surgery	South Korea	Presented with dyspnea, and chest pain at rest. Mass resection was performed.
Ivanov 2019	Russian Journal of Transplantology and Artificial Organs	Russia	Presented with fatigue, and palpitations. Mass resection was performed.
Jassal 2003	Journal of Thoracic and Cardiovascular Surgery	Canada	Presented with pleuritic chest discomfort. Mass resection was performed.
Jung 2015	Korean Journal of Thoracic and Cardiovascular Surgery	South Korea	History of sigmoid colon cancer. Asymptomatic at presentation. Mass resection was performed.
Kodama 1995	Circulation	Japan	Presented with exertional dyspnea and orthopnea. Mass resection was performed.
Koujanian 2017	Human Pathology: Case Reports	Canada	History of ovarian cancer. Presented with chest pain, exertional dyspnea, palpitations, and coronary artery disease. Mass resection and coronary artery bypass were performed.
La Francesca 2007	Annals of Thoracic Surgery	USA	Asymptomatic at presentation with coronary artery disease. Mass resection and coronary artery bypass were performed.
Li J 2021	Journal of Chest Surgery	China	Presented with dyspnea, cough, and upper left back pain. Mass resection was performed.
Li S 2019	Medicine	China	Presented with expiratory dyspnea, and edema of face for a month. Surgery aborted as deemed unresectable. Chemo-radiotherapy was performed.

Li X 2019	International Journal of Cardiovascular Imaging	China	Presented with cough, expectoration, and dyspnea. Mass resection was performed.
Machado 2016	International Journal of Surgical Pathology	Spain	Presented with exertional syncope. Mass resection and radiotherapy were performed.
Moldovan 2022	Medicina	Romania	Asymptomatic at presentation. Mass resection was performed.
Monroe 1984	Archives of Pathology & Laboratory Medicine	USA	History of metastatic lung adenocarcinoma. Presented with weight loss, exertional chest pain, nail clubbing, and atrial fibrillation. Lung metastasis found inside neurilemmoma. Patient died before diagnosis.
Morishita 1988	Clinical Cardiology	Japan	Presented with exertional dyspnea, general fatigue, and fever. Only biopsy was performed.
Nakamura 2003	European Journal of Cardio-thoracic Surgery	Japan	Presented with cough and sputum. Mass resection was performed.
Pauwels 1999	Histopathology	The Netherlands	History of breast cancer. Presented with severe tricuspid valve regurgitation and right ventricular outflow tract obstruction. Partial debulking was performed.
Prifti 2014	Annals of Thoracic Surgery	Albania	Presented with dyspnea, facial swelling, cyanosis, fatigue, tricuspid valve obstruction and superior vena cava compression. Mass resection and chemo-radiotherapy were performed.
Rausche 2006	Clinical Research in Cardiology	Germany	Presented with cough, and subfebrile. Mass resection was performed.
Salem 2011	European Journal of Internal Medicine	UK	Presented with Exertional shortness of breath, fatigue, worsening exercise tolerance, and mitral valve obstruction. Mass resection and radiotherapy were performed.

Sevimli 2007	Echocardiography: A Journal of Cardiovascular Ultrasound and Allied Techniques	Turkey	Presented with palpitations. Partial debulking was performed.
Sirlak 2003	Cardiovascular Pathology	Turkey	Presented with dyspnea. Mass resection was performed.
Son 2015	Yonsei Medical Journal	South Korea	Presented with palpitations. Mass resection was performed.
Stepien-Walek 2018	Kardiologia Polska	Poland	Presented with dyspnea, weakness, significant reduction of exercise tolerance, and mitral valve obstruction. Mass resection was performed.
Stolf 2006	Clinics	Brazil	Asymptomatic at presentation. Mass resection was performed.
Sun 2014	Cardiovascular Pathology	USA	Presented with generalized swelling, and mitral valve obstruction. Mass resection was performed.
Ursell 1982	Human Pathology	USA	Presented with shortness of breath, easy fatigability, ankle edema, increased abdominal girth, and right ventricular outflow tract obstruction. Mass resection was performed.
Valeviciene 2011	Gazzetta Medica Italiana	Lithuania	Presented with dyspnea, chest pain, general malaise, and atrial fibrillation. Mass resection and radiotherapy were performed.
Voluckiene 2012	Central European Journal of Medicine	Lithuania	Presented with atrial fibrillation. Mass resection and chemo-radiotherapy were performed.
Wang 2021	Cardiovascular Pathology	China	Asymptomatic at presentation. Mass resection was performed.
Wang 2022	BMC Cardiovascular Disorders	China	History of lung adenocarcinoma. Presented with syncope. Mass resection was performed

Xiao 2018	Cardiovascular Flashlight	China	Presented with palpitations, dyspnea, cough, and facial and lower limb oedema. Metastatic at lymph-nodes. Resection not performed as during operation deemed not resectable.
Yokoyama 2021	Surgical Case Reports	Japan	History of schwannomatosis. Asymptomatic at presentation. Mass resection was performed.
Zhu 2019	Journal of Cardiac Surgery	China	Presented with syncope, chest distress, shortness of breath, accompanied by palpitation, fever, weight loss, and mitral valve obstruction. Partial mass resection, mitral valve replacement, and chemo-radiotherapy were performed.

Supplementary Table S3 – Joanna Briggs Institute Critical Appraisal tool

Paper	Q1	Q2	Q3	Q4	Q5	Q6	Q7	Q8
Anderson 2011	Yes	Yes	Yes	Yes	Yes	Yes	Yes	No
Arava 2015	Yes	Yes	Yes	Yes	Yes	No	Yes	Yes
Betancourt 1979	Yes	Yes	Yes	Yes	Yes	No	Yes	No
Bizzarri 2001	Yes	Yes	Yes	Yes	Yes	No	Yes	No
Brandao 2020	Yes	Yes	Yes	Yes	Yes	Yes	Yes	Yes
Cho 2012	Yes	Yes	Yes	Yes	Yes	Yes	Yes	No
Dammert 1955	Yes	Yes	Yes	Yes	Yes	Yes	Yes	Yes
Early 2007	Yes	Yes	Yes	Yes	Yes	No	Yes	Yes
Eekhoudt 2019	Yes	Yes	Yes	Yes	Yes	No	Yes	No
Eindhoven 2018	Yes	Yes	Yes	Yes	Yes	No	Yes	No
Factor 1976	Yes	Yes	Yes	Yes	Yes	Yes	Yes	Yes
Fan 2012	Yes	Yes	Yes	Yes	Yes	No	Yes	No
Forbes 1994	Yes	Yes	Yes	Yes	Yes	Yes	Yes	Yes
Gelfand 1977	Yes	Yes	Yes	Yes	Yes	Yes	Yes	No
Gleason 1972	Yes	Yes	Yes	Yes	Yes	No	Yes	Yes
Guo 2002	Yes	Yes	Yes	Yes	Yes	No	Yes	No
Gushmann 1996	Yes	Yes	Yes	Yes	Yes	Yes	Yes	Yes
Hallman 1966	Yes	Yes	Yes	Yes	Yes	No	Yes	Yes
Hashimoto 1998	Yes	Yes	Yes	Yes	Yes	No	Yes	Yes
Huang 2021	Yes	Yes	Yes	Yes	Yes	No	Yes	No
Hwang 2014	Yes	Yes	Yes	Yes	Yes	Yes	Yes	Yes
Ivanov 2019	Yes	Yes	Yes	Yes	Yes	Yes	Yes	Yes
Jassal 2003	Yes	Yes	Yes	Yes	Yes	No	Yes	Yes
Jung 2015	Yes	Yes	Yes	Yes	Yes	Yes	Yes	Yes
Kodama 1995	Yes	Yes	Yes	Yes	Yes	No	Yes	No
Koujanian 2017	Yes	Yes	Yes	Yes	Yes	No	Yes	Yes
La Francesca 2007	Yes	Yes	Yes	Yes	Yes	Yes	Yes	Yes
Li J 2021	Yes	Yes	Yes	Yes	Yes	No	Yes	Yes
Li S 2019	Yes	Yes	Yes	Yes	Yes	No	Yes	Yes
Li X 2019	Yes	Yes	Yes	Yes	Yes	No	Yes	Yes
Machado 2016	Yes	Yes	Yes	Yes	Yes	No	Yes	Yes
Moldovan 2022	Yes	Yes	Yes	Yes	Yes	Yes	Yes	Yes
Monroe 1984	Yes	Yes	Yes	Yes	Yes	Yes	Yes	Yes
Morishita 1988	Yes	Yes	Yes	Yes	Yes	No	Yes	Yes
Nakamura 2003	Yes	Yes	Yes	Yes	Yes	No	Yes	Yes
Pauwels 1999	Yes	Yes	Yes	Yes	Yes	No	Yes	Yes
Prifti 2014	Yes	Yes	Yes	Yes	Yes	Yes	Yes	Yes
Rausche 2006	Yes	Yes	Yes	Yes	Yes	No	Yes	No
Salem 2011	Yes	Yes	Yes	Yes	Yes	Yes	Yes	Yes
Sevimli 2007	Yes	Yes	Yes	Yes	Yes	No	Yes	Yes
Sirlak 2003	Yes	Yes	Yes	Yes	Yes	No	Yes	Yes
Son 2015	Yes	Yes	Yes	Yes	Yes	No	Yes	Yes
Stepien-Walek 2018	Yes	Yes	Yes	Yes	Yes	Yes	Yes	No
Stolf 2006	Yes	Yes	Yes	Yes	Yes	No	Yes	Yes
Sun 2014	Yes	Yes	Yes	Yes	Yes	No	Yes	No
Ursell 1982	Yes	Yes	Yes	Yes	Yes	Yes	Yes	Yes
Valeviciene 2011	Yes	Yes	Yes	Yes	Yes	Yes	Yes	Yes

Voluckiene 2012	Yes	Yes	Yes	Yes	Yes	Yes	Yes	Yes
Wang 2021	Yes	Yes	Yes	Yes	Yes	No	Yes	Yes
Wang 2022	Yes	Yes	Yes	Yes	Yes	Yes	Yes	Yes
Xiao 2018	Yes	Yes	Yes	Yes	Yes	No	No	No
Yokoyama 2021	Yes	Yes	Yes	Yes	Yes	Yes	Yes	Yes
Zhu 2019	Yes	Yes	Yes	Yes	Yes	No	Yes	Yes

Supplementary Figure S1 – PRISMA flow diagram of the included studies

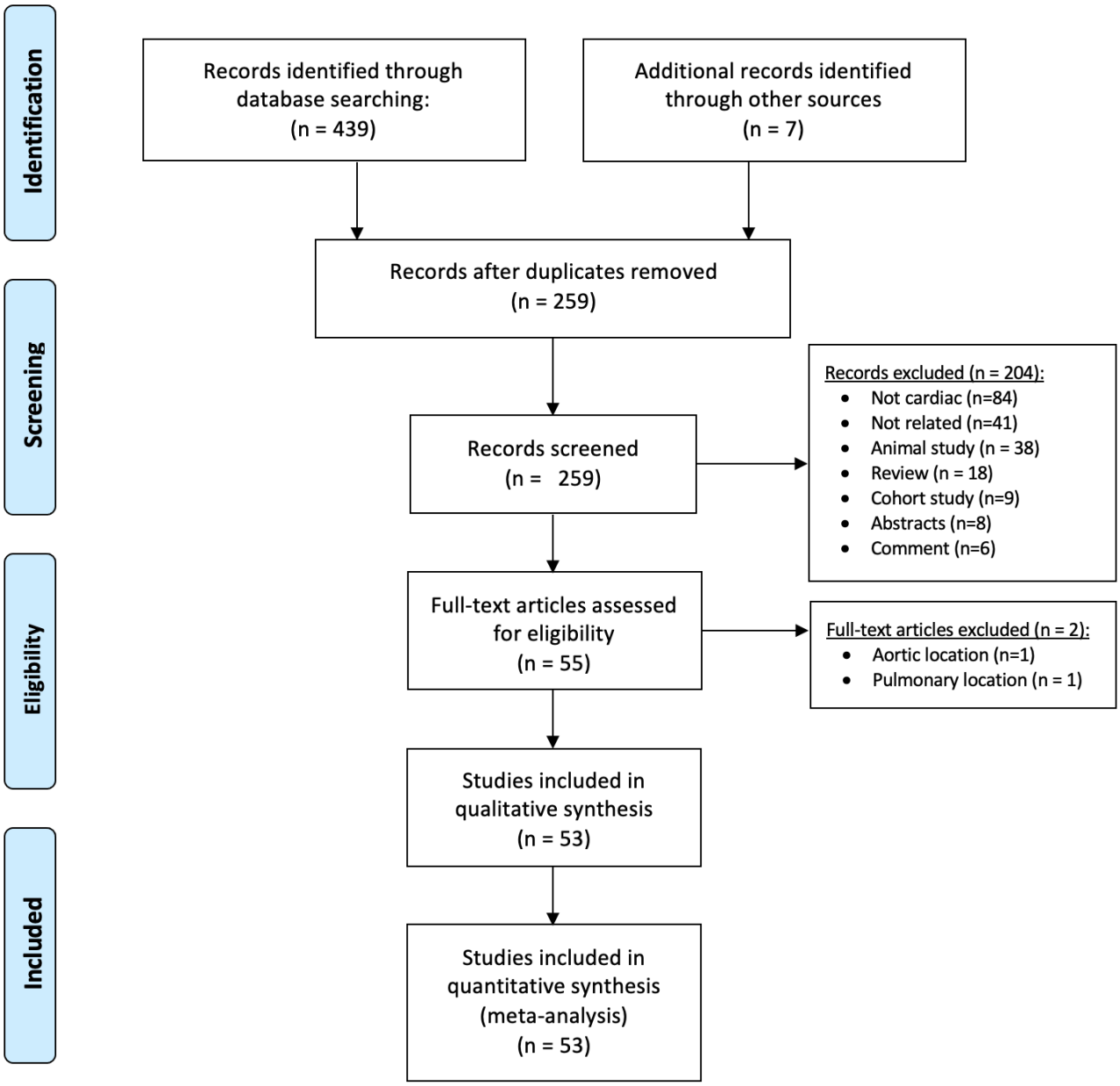

Supplementary Figure S2 – Number of cases per country

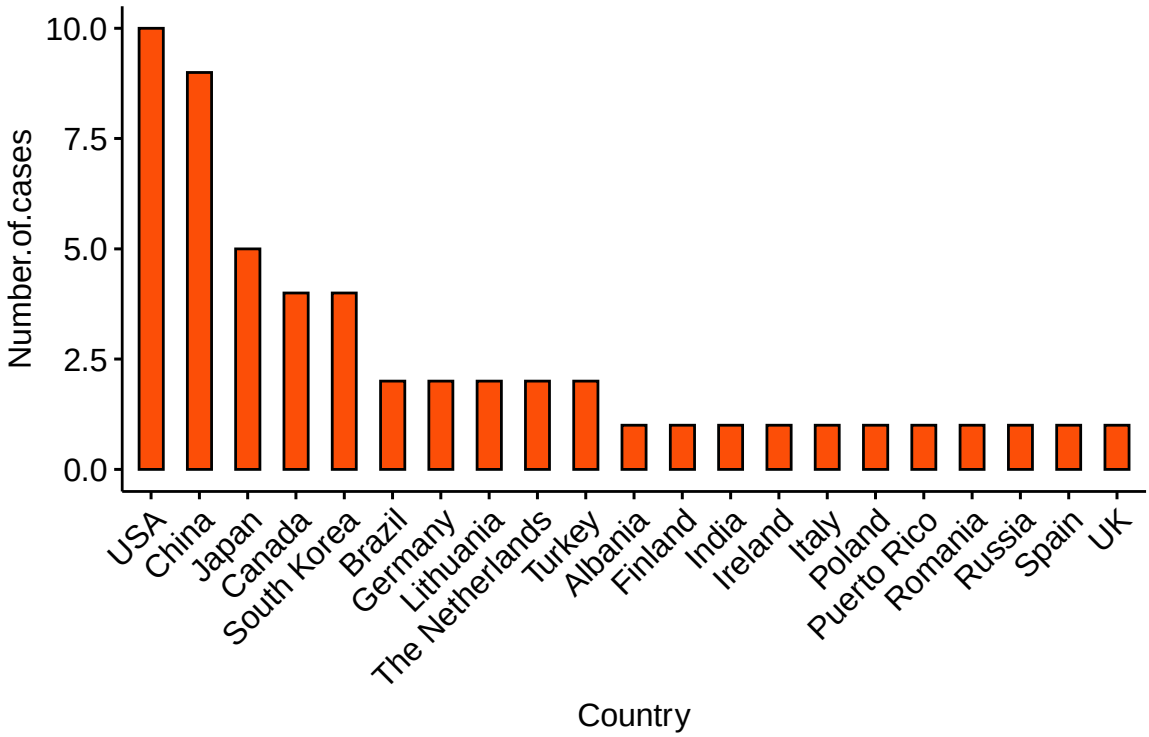

Supplementary Figure S3 – Kaplan-Meier curve showing the overall survival of the entire cohort

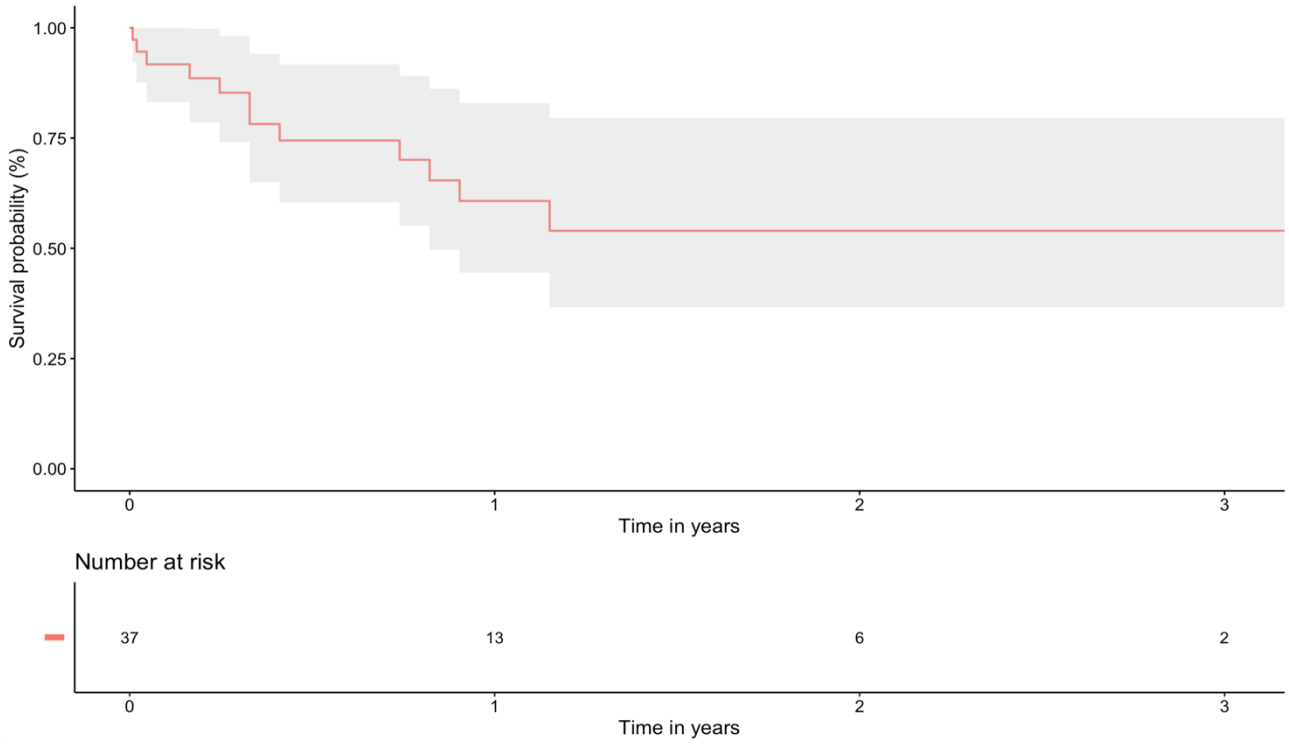

Supplementary Figure S4 – Kaplan Meier curve of overall survival comparing A) females vs males and B) left vs right side of the heart

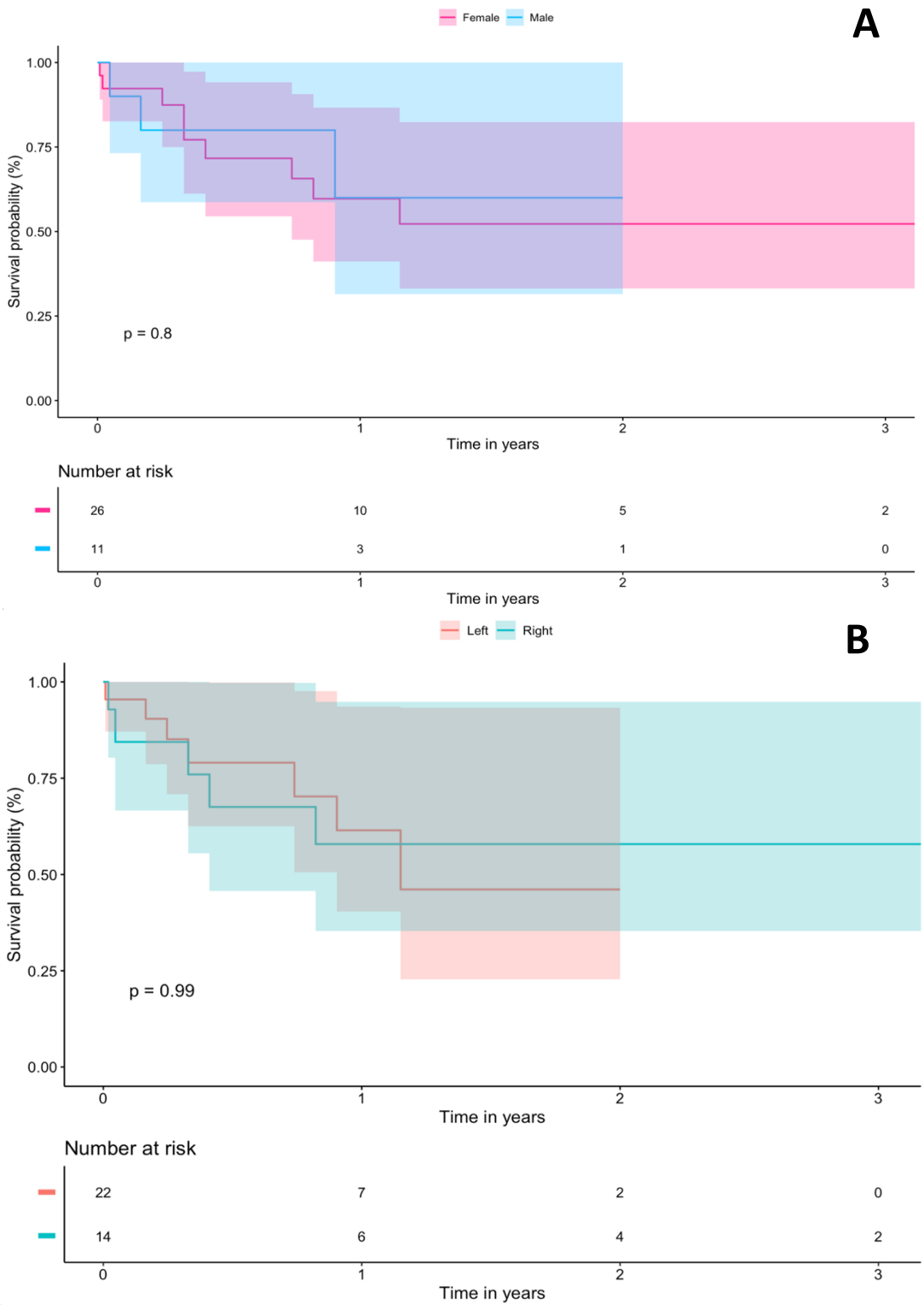

Supplementary Figure S5 - Subgroup analysis for late mortality after adjustment for sex

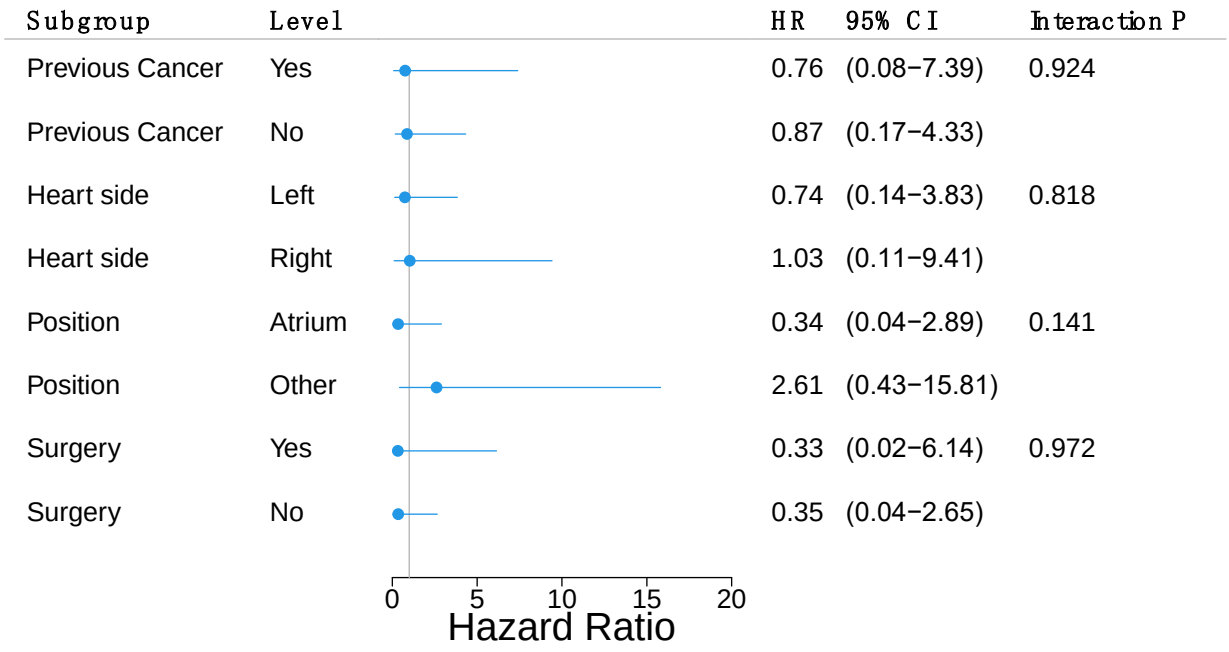

Supplementary Figure S6 - Subgroup analysis for late mortality after adjustment for cardiac location

