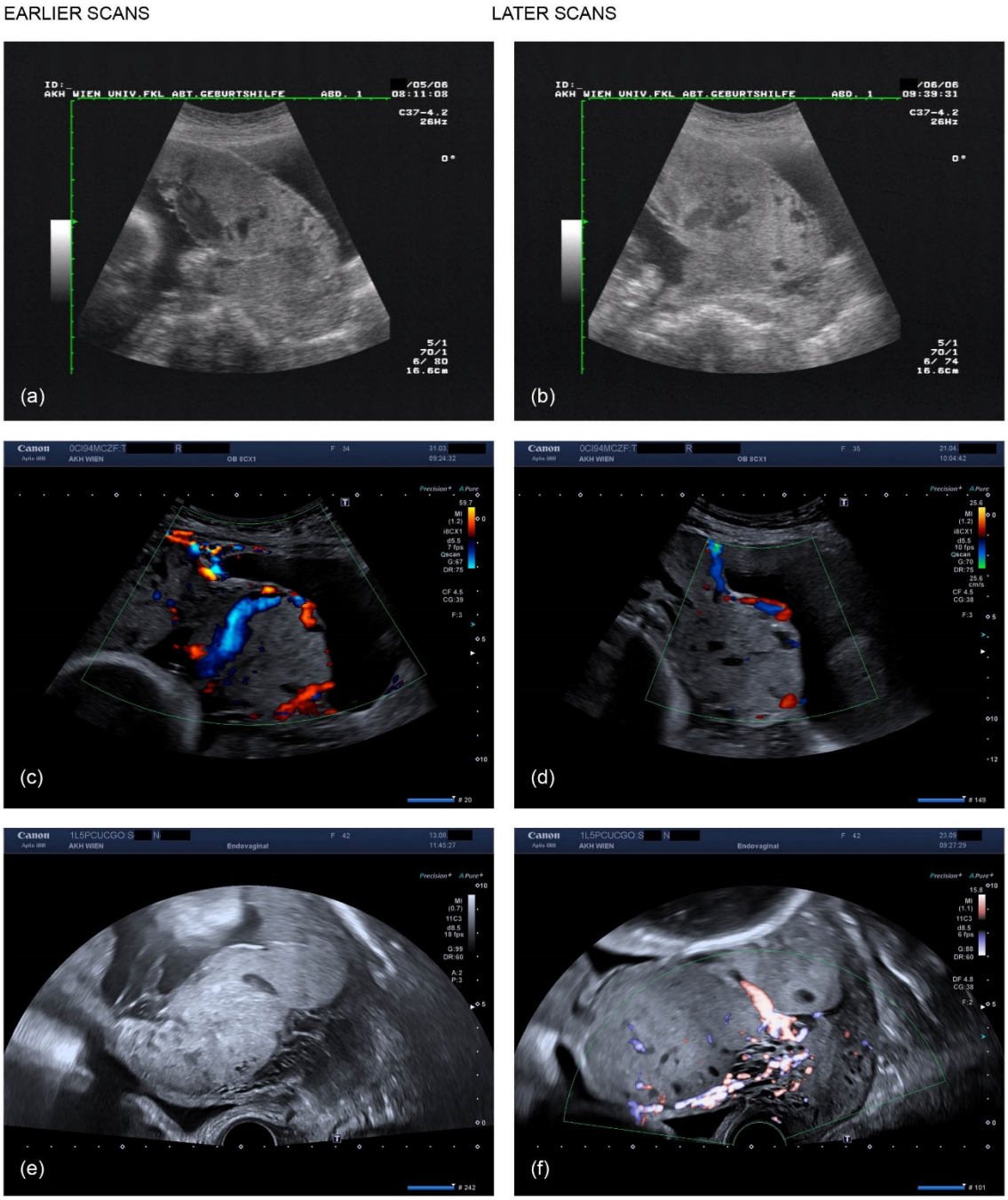

Figure S1. Example ultrasound pictures of 3 AIP cases, rows show the same patient, the earlier scans are depicted on the left, the later scans on the right; none of the later scans displays a diagnostic criterion for AIP, which is not visible on the earlier scans. (**a**,**b**) transabdominal (31 days between scans): visible myometrial thinning with partially absent myometrium + placental lacunae; (**c**,**d**) transabdominal (22 days between scans): pronounced placental bulge; (**e**,**f**) transvaginal (42 days between sans): precervically only serosa delineable, although this layer is also partially absent or interrupted by vascular convolutes indicating subplacental hypervascularity.