T0 **T1**

a

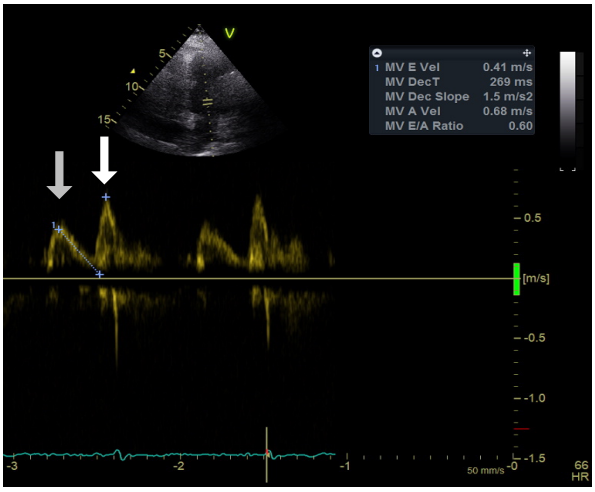

b

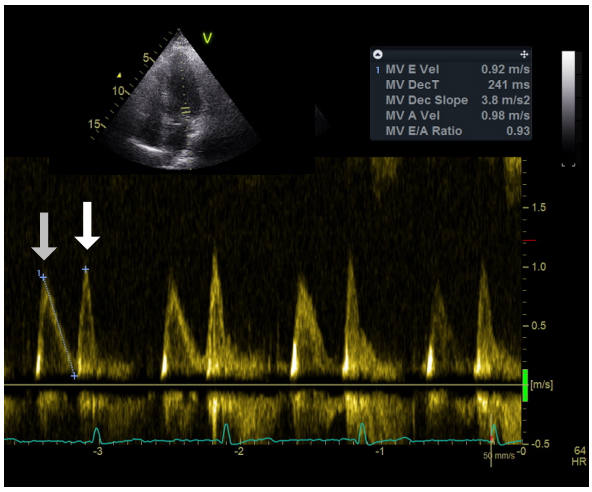

c

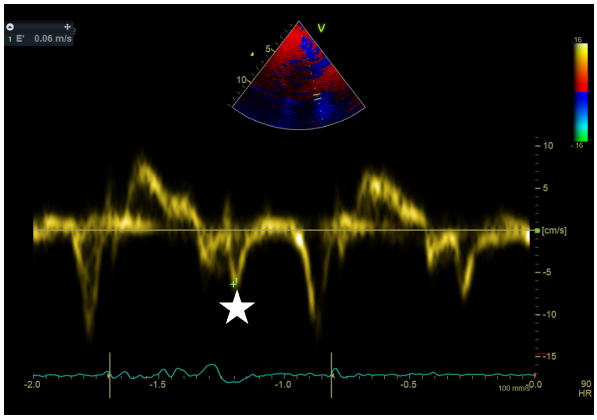

d

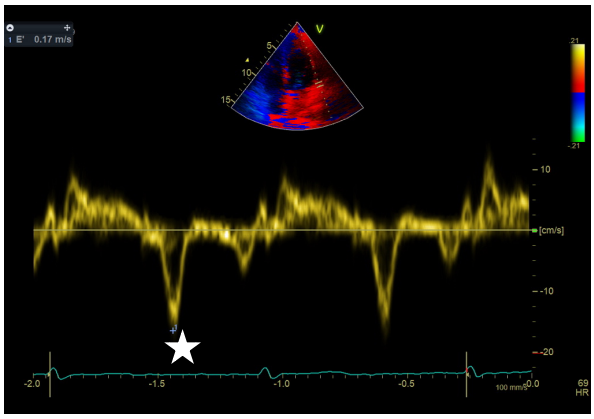

e

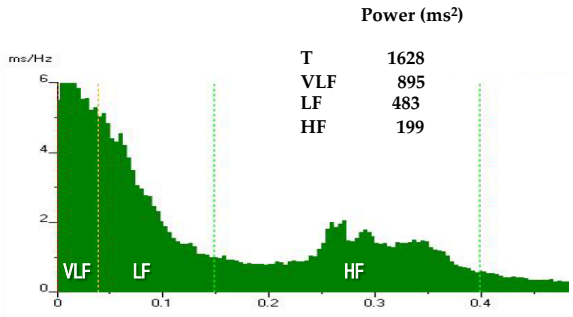

f

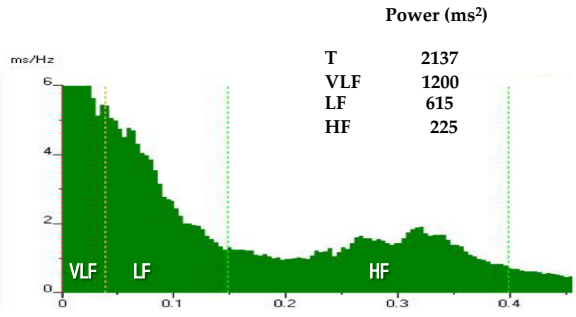

g

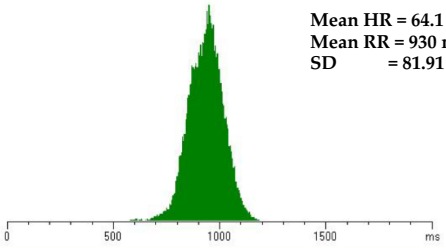

h

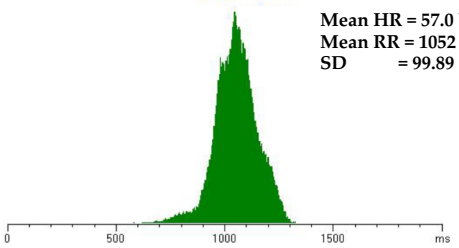

Figure S1. Changes in representative cardiovascular parameters. Left panel shows baseline (T0) evaluation. Right panel shows the same parameters after 3-month (T1). Black-background figures are echocardiographic parameters, white background 24-h derived parameters. A mitral early inflow (E wave, grey arrow) is reduced and broader compared to atrial inflow (A wave, white arrow) with an E/A peak velocity ratio of 0.7, sign of grade 1 diastolic dysfunction. C mitral annulus peak velocity by tissue doppler (E' wave, star) is 0.06 m/s (reduced). B and D after three months there is an improvement in E/A ratio to 0.93 and an increase of E' to 0.17 m/s (normalization of diastolic function). E HRV frequency bands divided in VLF, LF and HF (vertical dotted line). Total power sum of each frequency band. At T1 (F) there is an increase in total power, mainly due to increase in VLF and LF. G histogram of total beats is shown with mean HR of 64 bpm with a SD of total intervals of 81.9 ms. At T1 (H) the histogram is wider due to an increase in SD (99.8 ms) and shifted rightward (decrease of mean HR to 57 bpm). HRV heart rate variability, VLF very low frequency, LF low frequency, HF high frequency, SD standard deviation.