

## Supplementary material

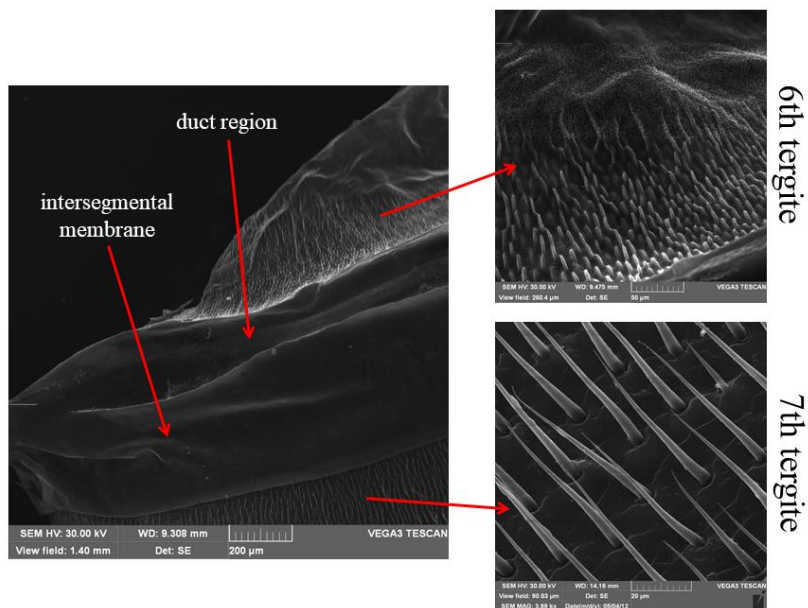


Figure S1. Nasonov gland in normal workers observed under SEM (according to Ptaszyńska et al.'s (2014; DOI: 10.3896/IBRA.1.53.5.02) method).