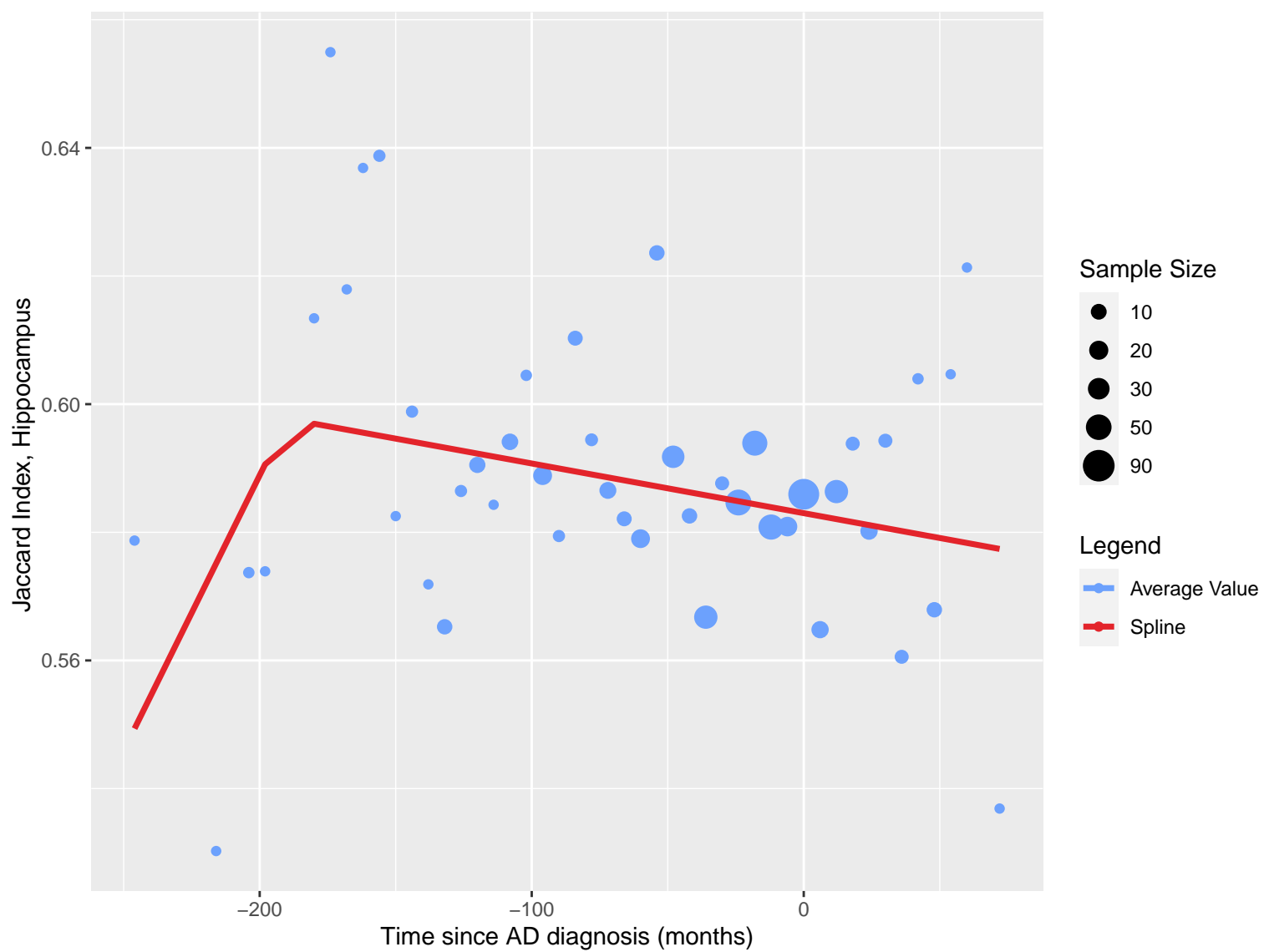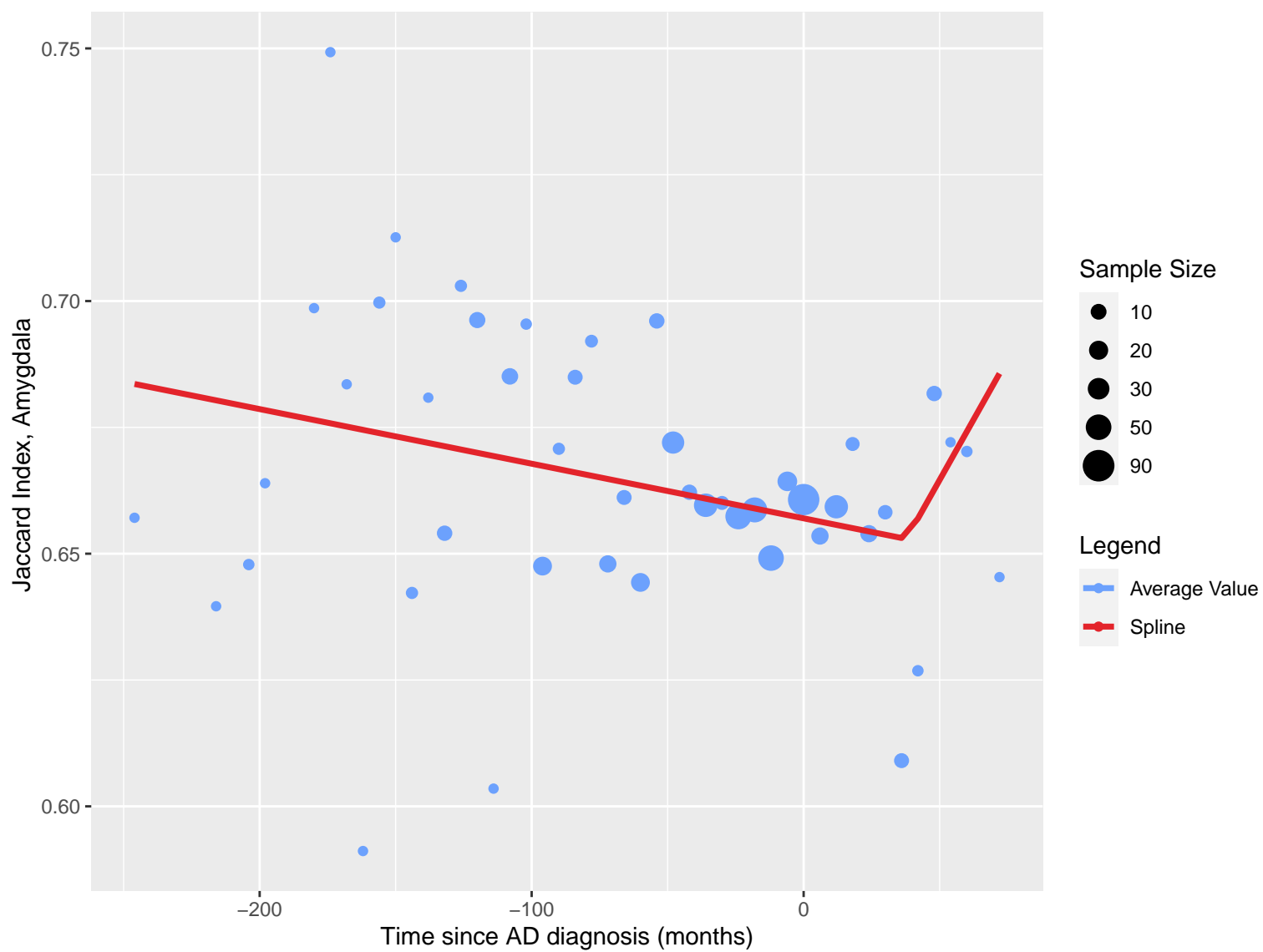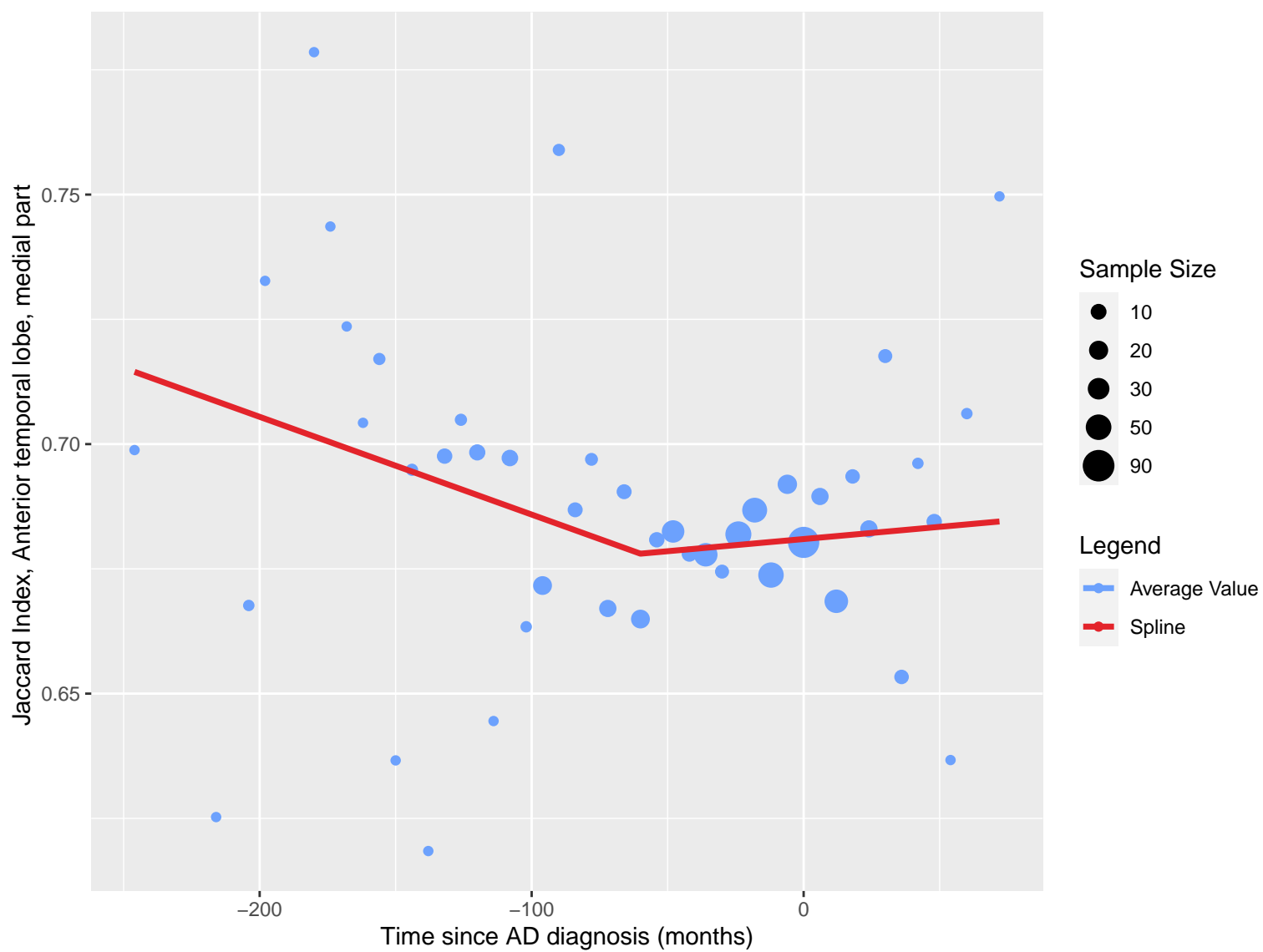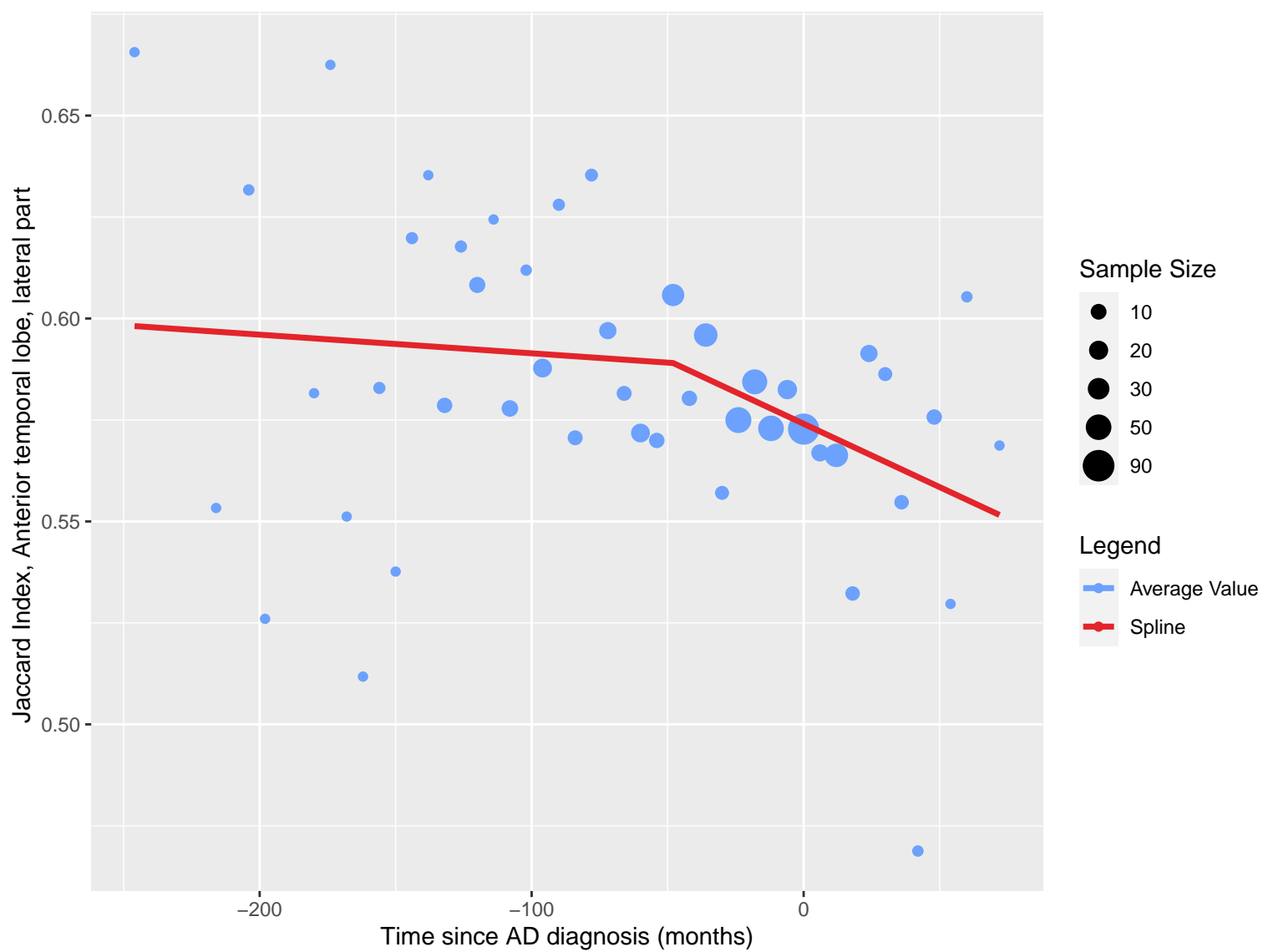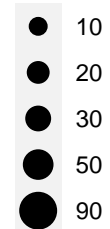


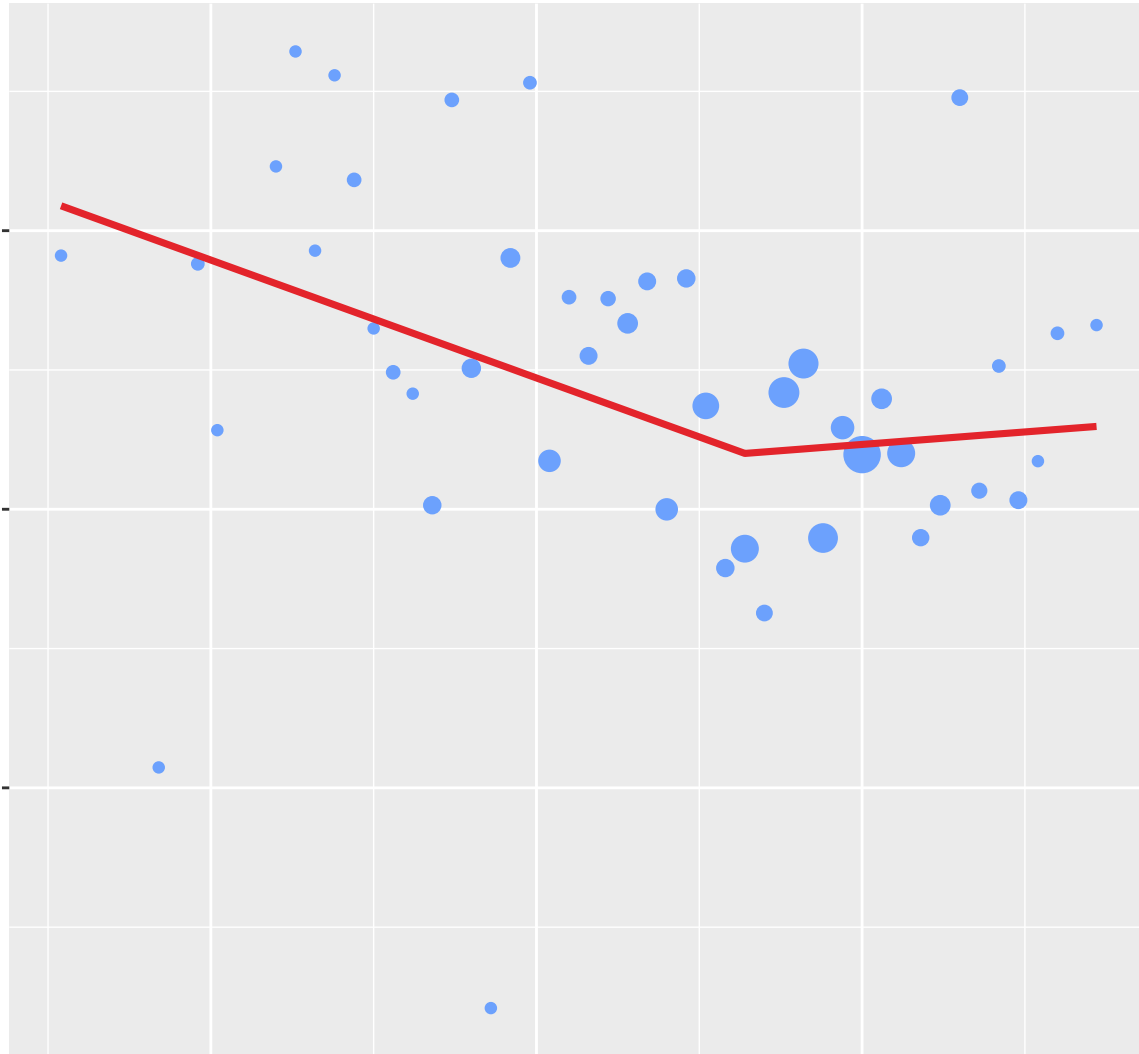
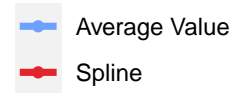
Jaccard Index, Gyri parahippocampalis et ambiens

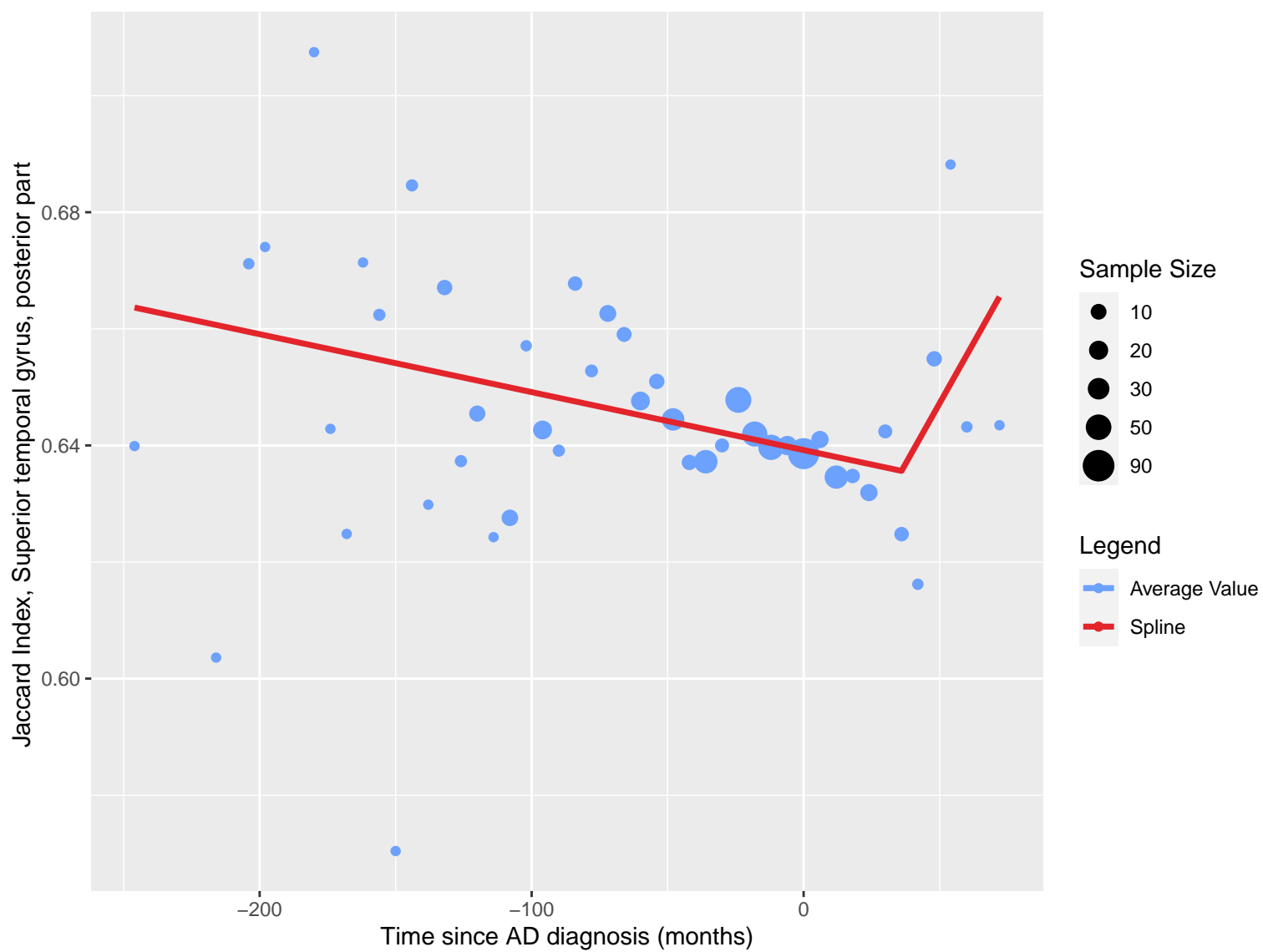
Time since AD diagnosis (months)

Sample Size

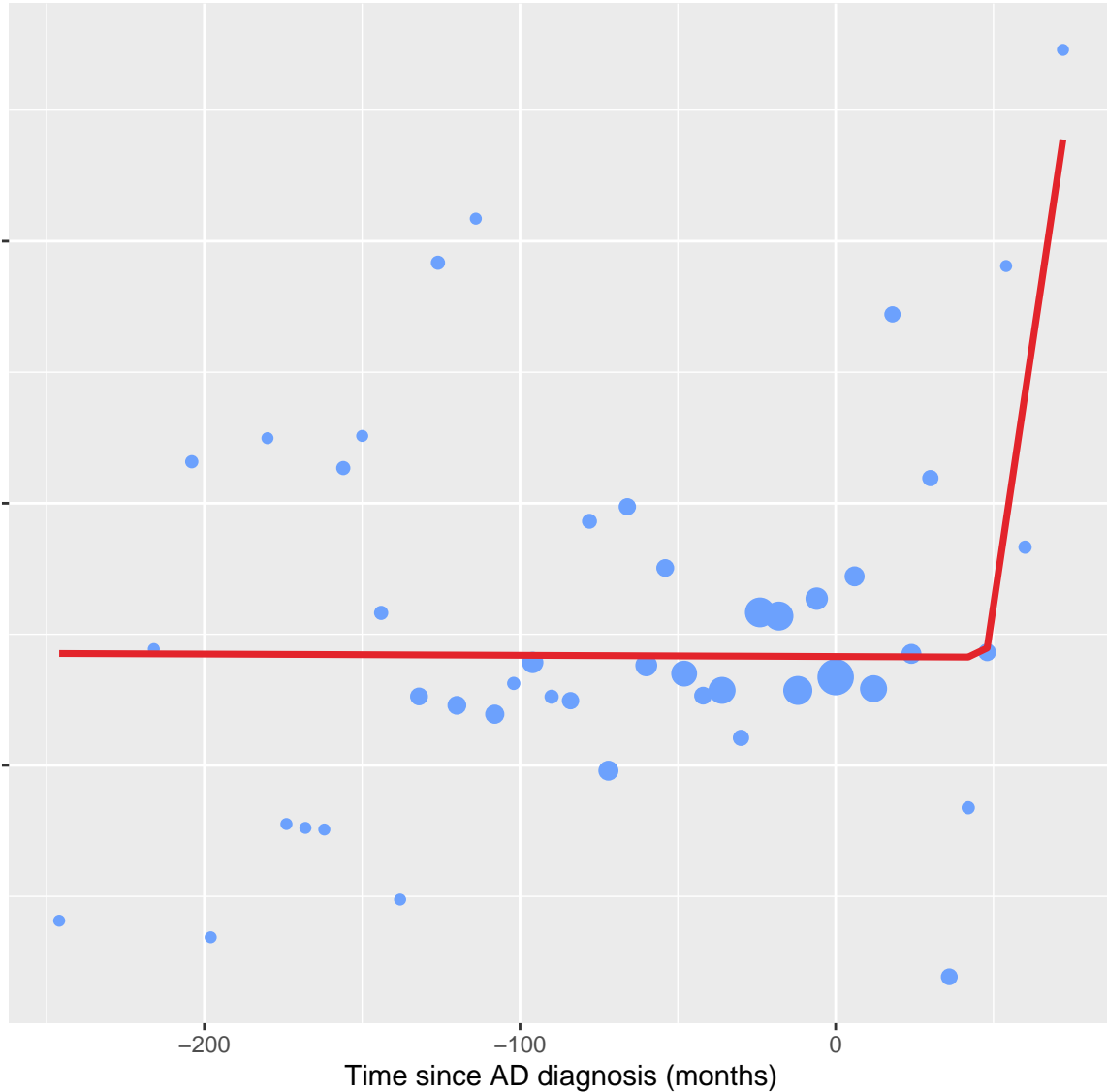


Legend

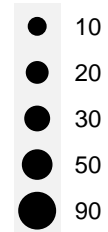




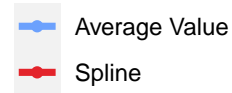
Jaccard Index, Lateral occipitotemporal gyrus, gyrus fusiformis

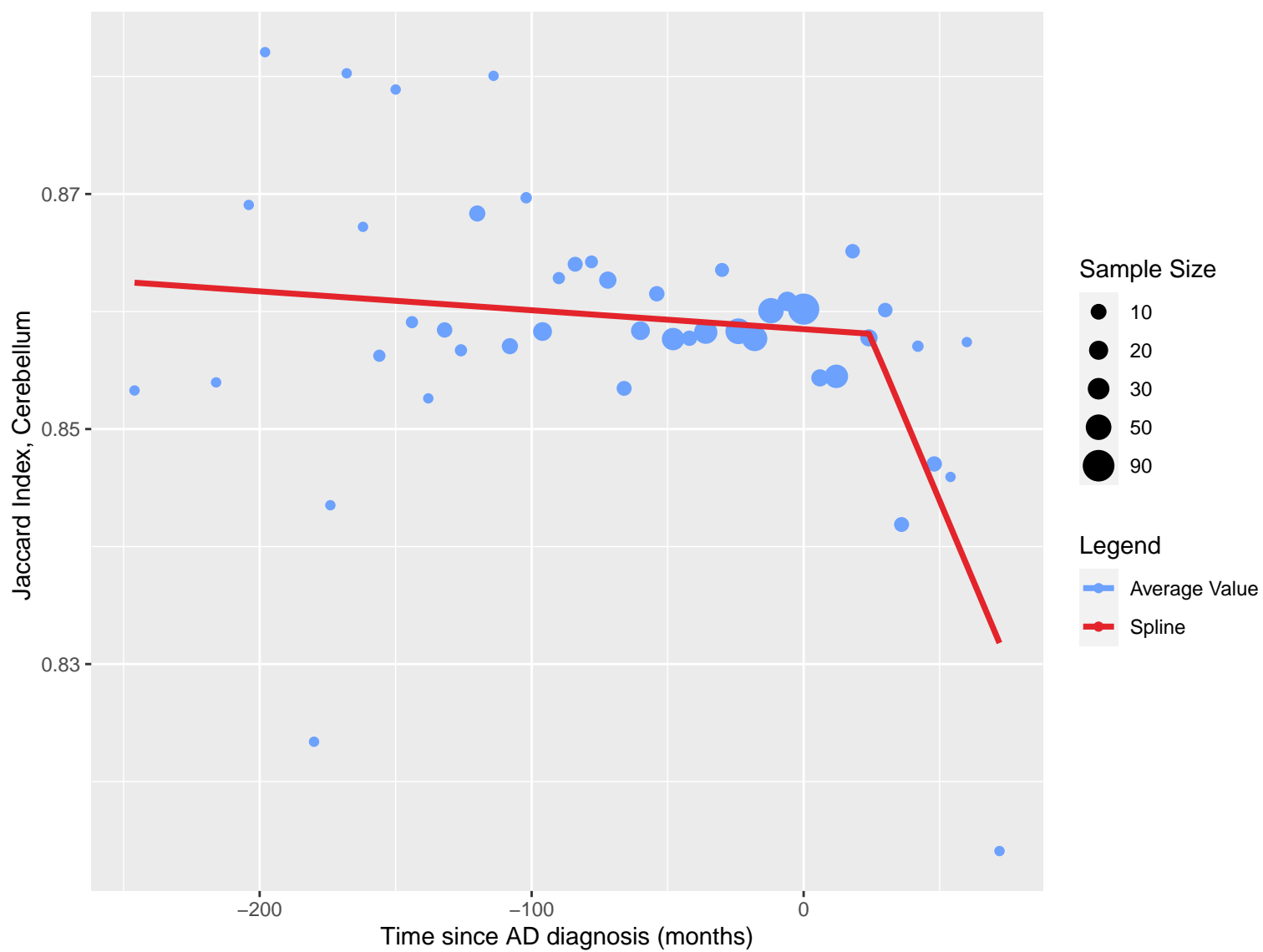


Sample Size

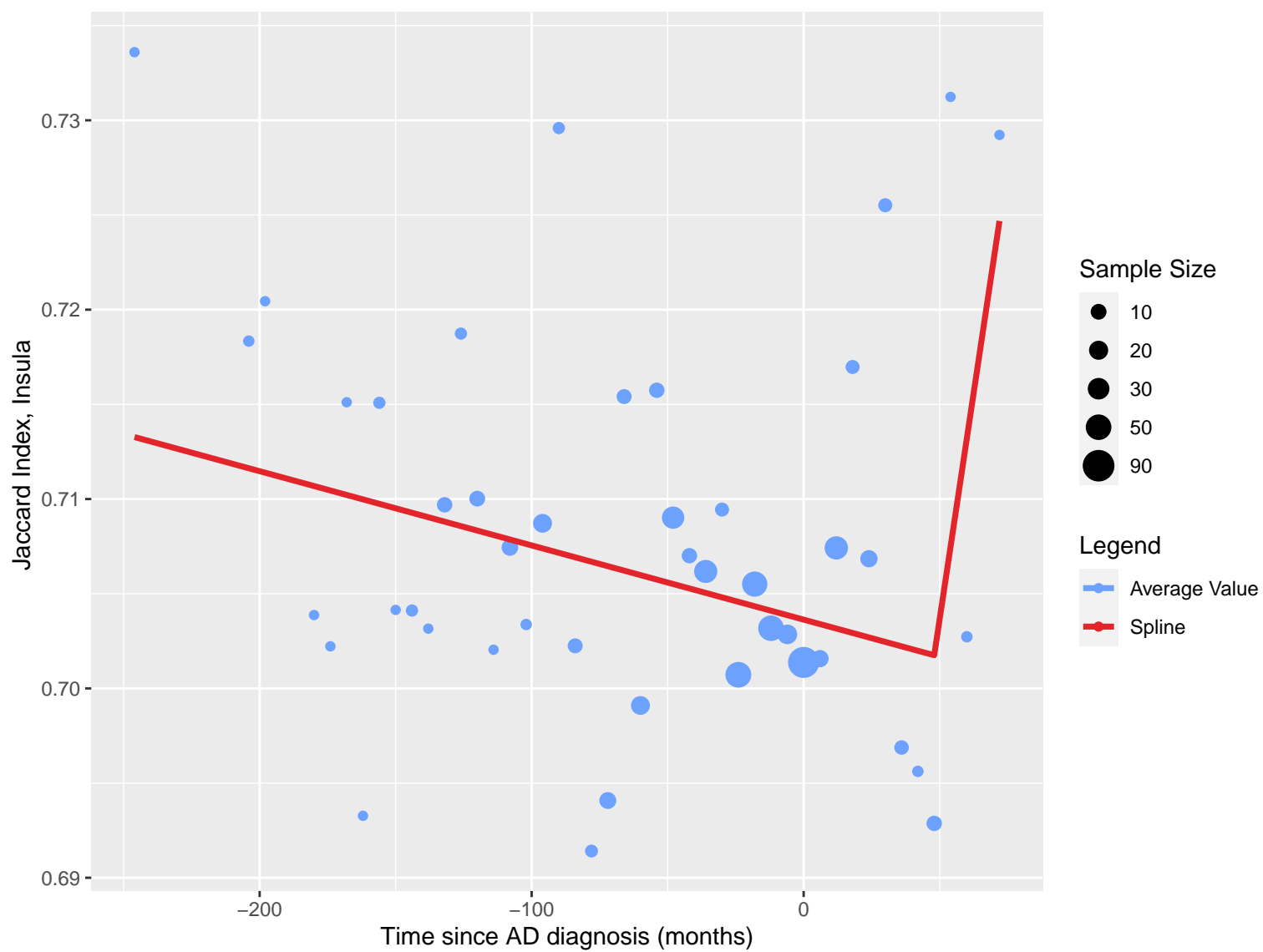


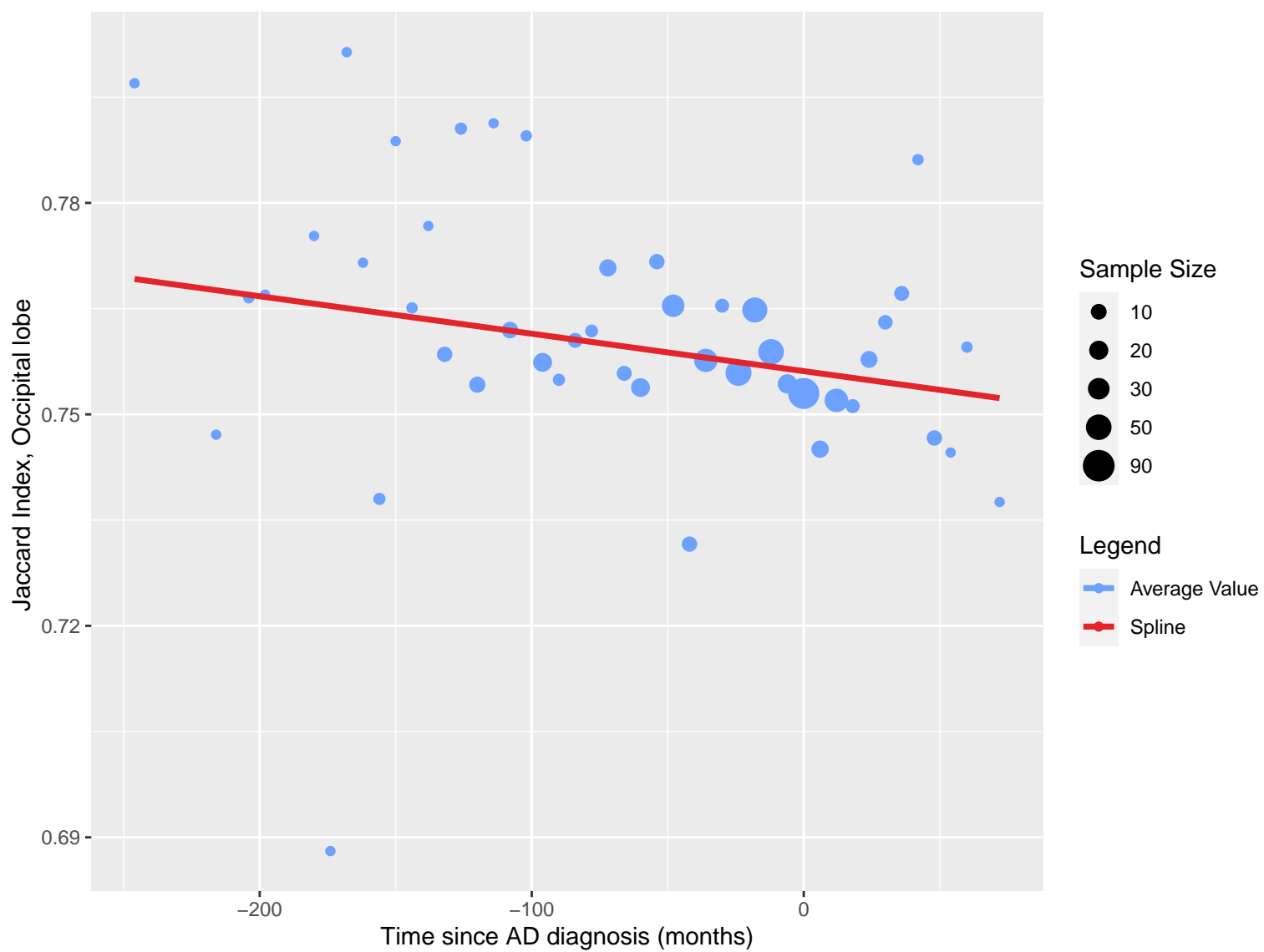
Legend

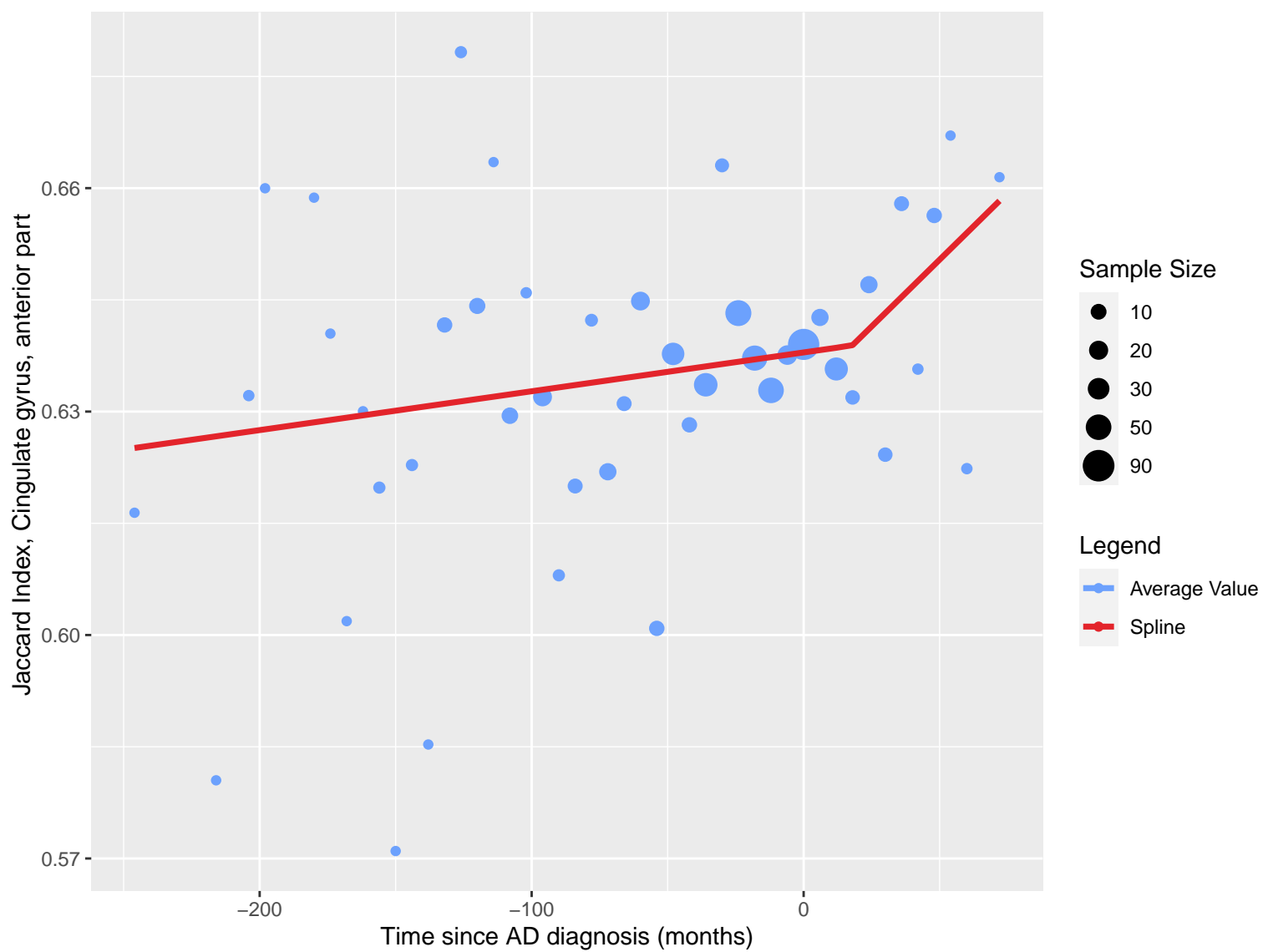




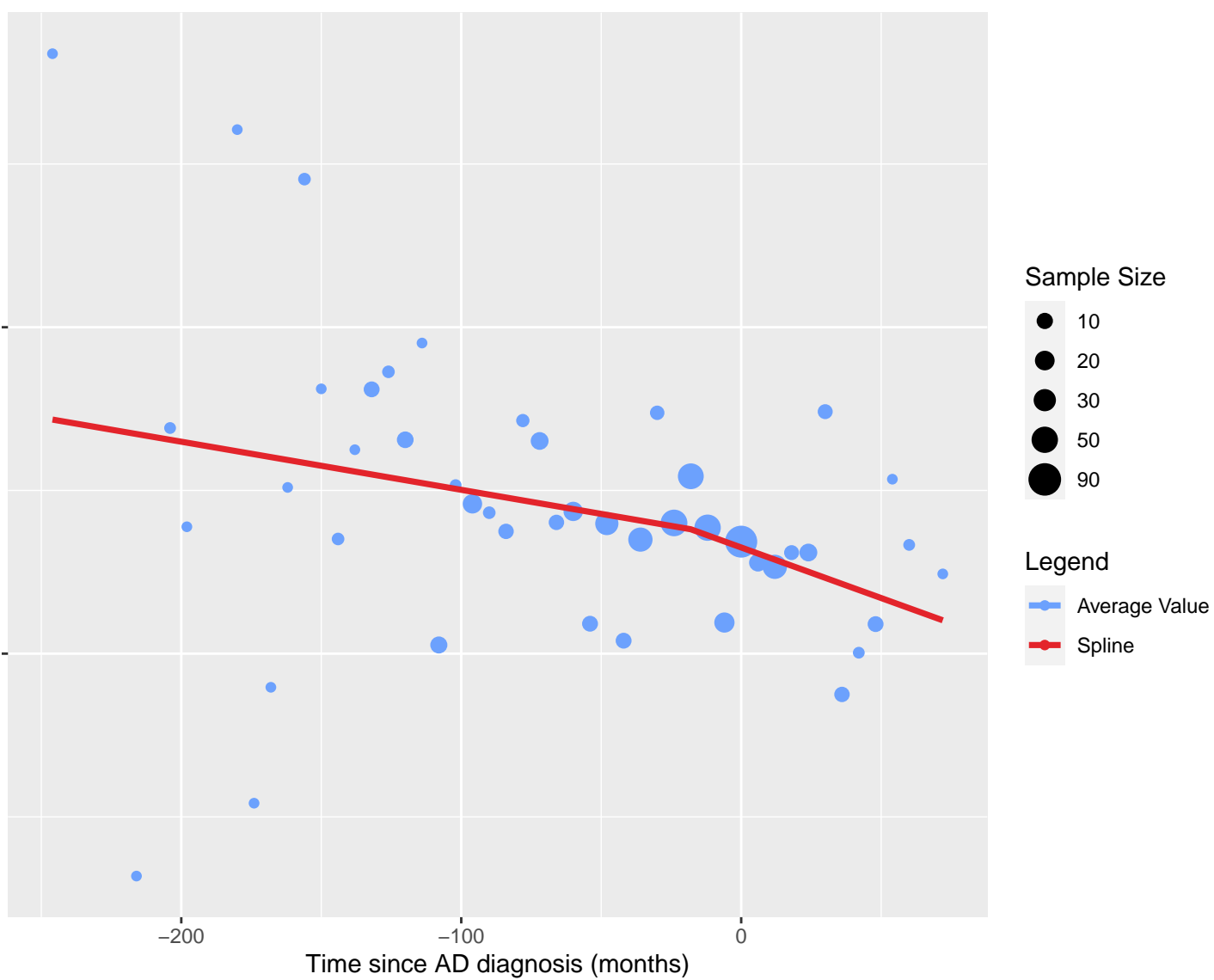


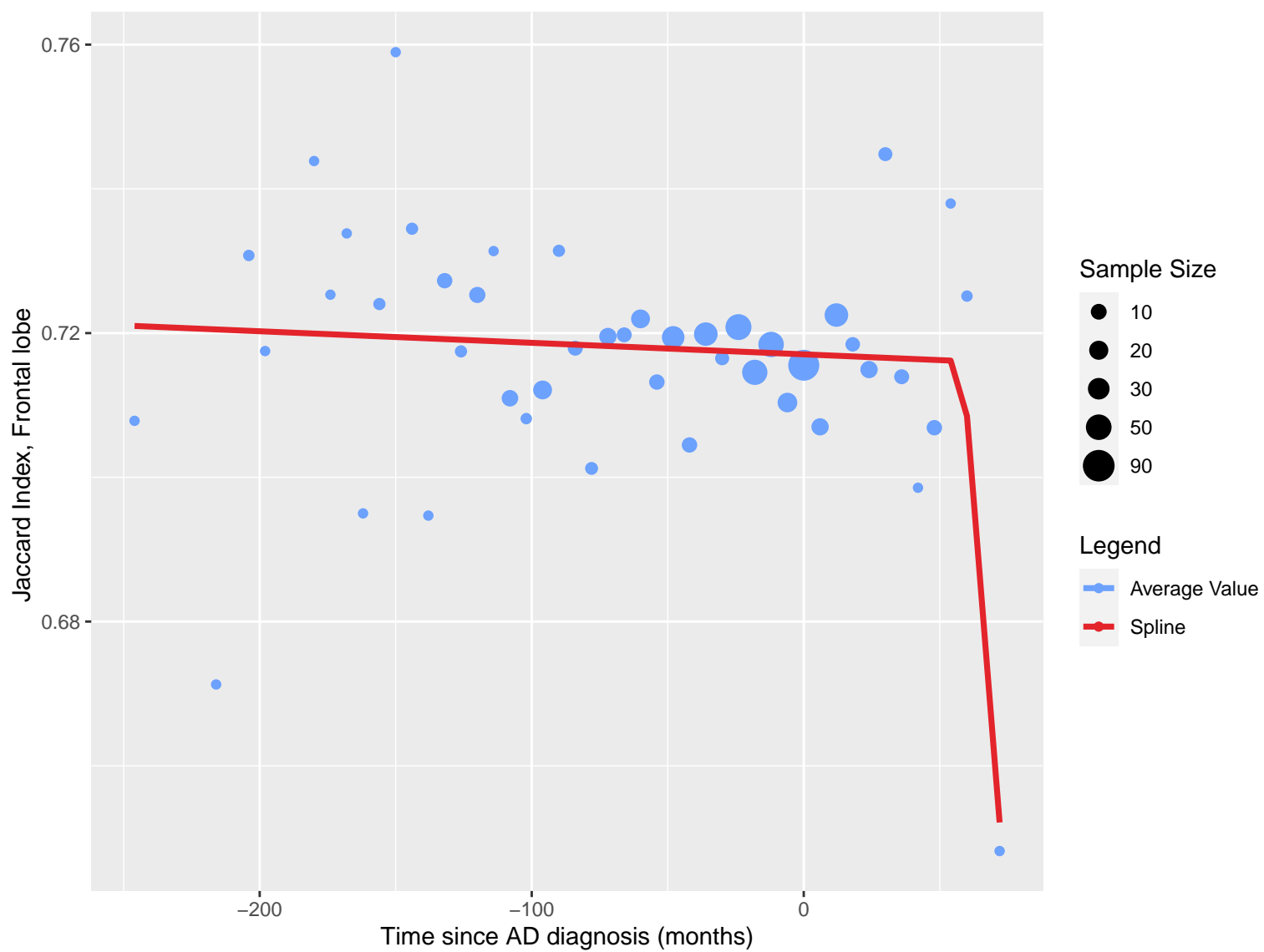


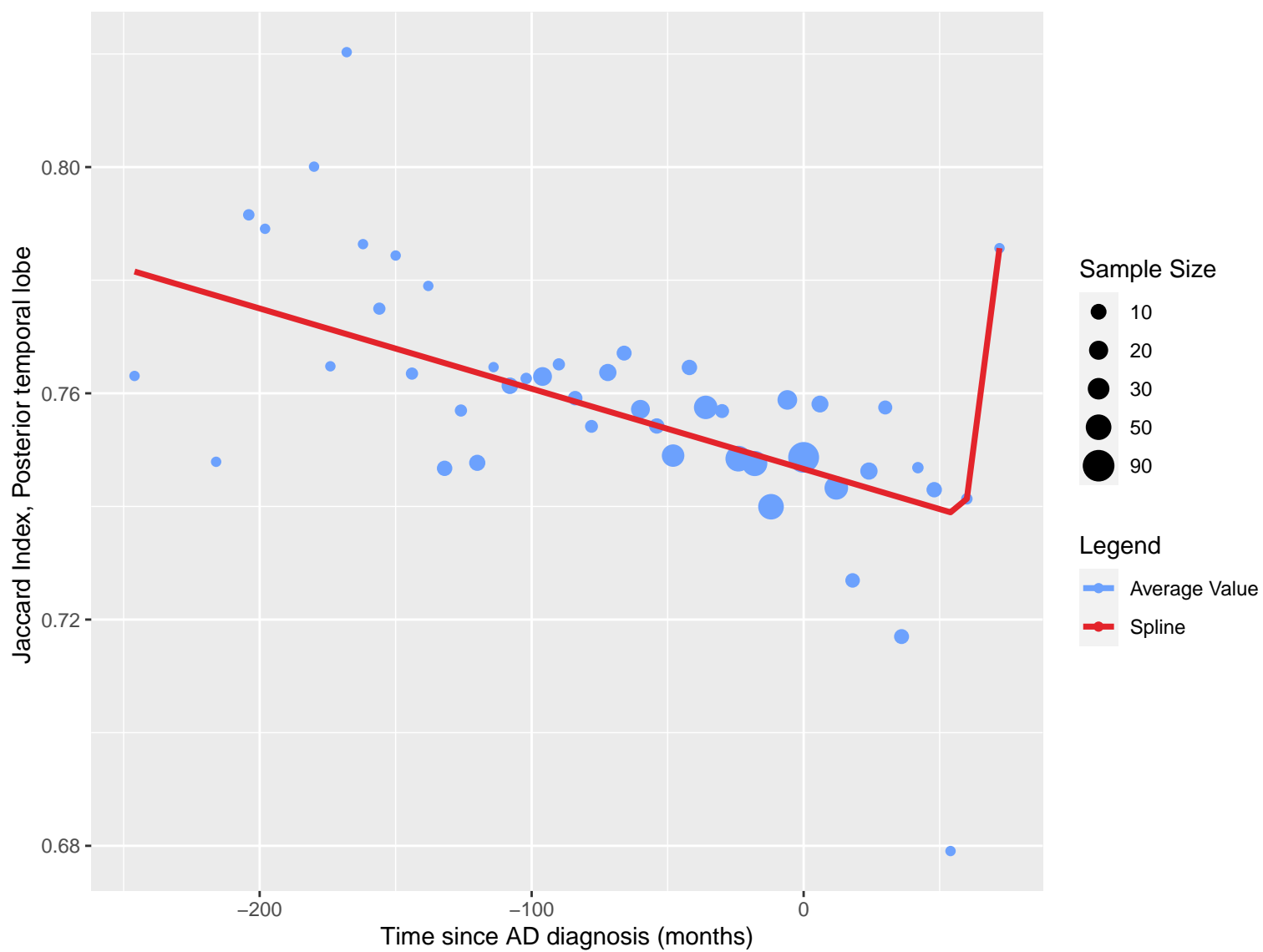


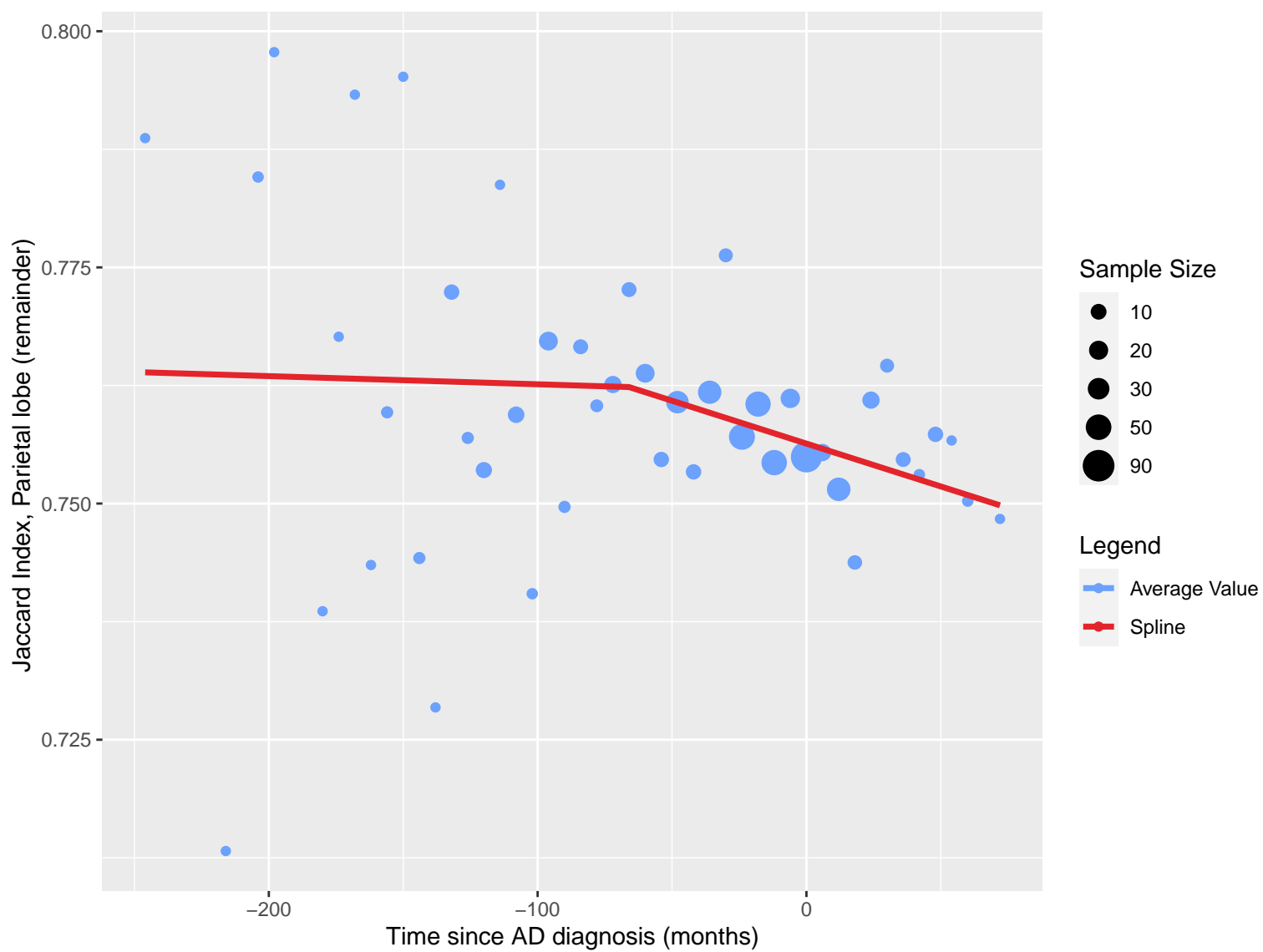


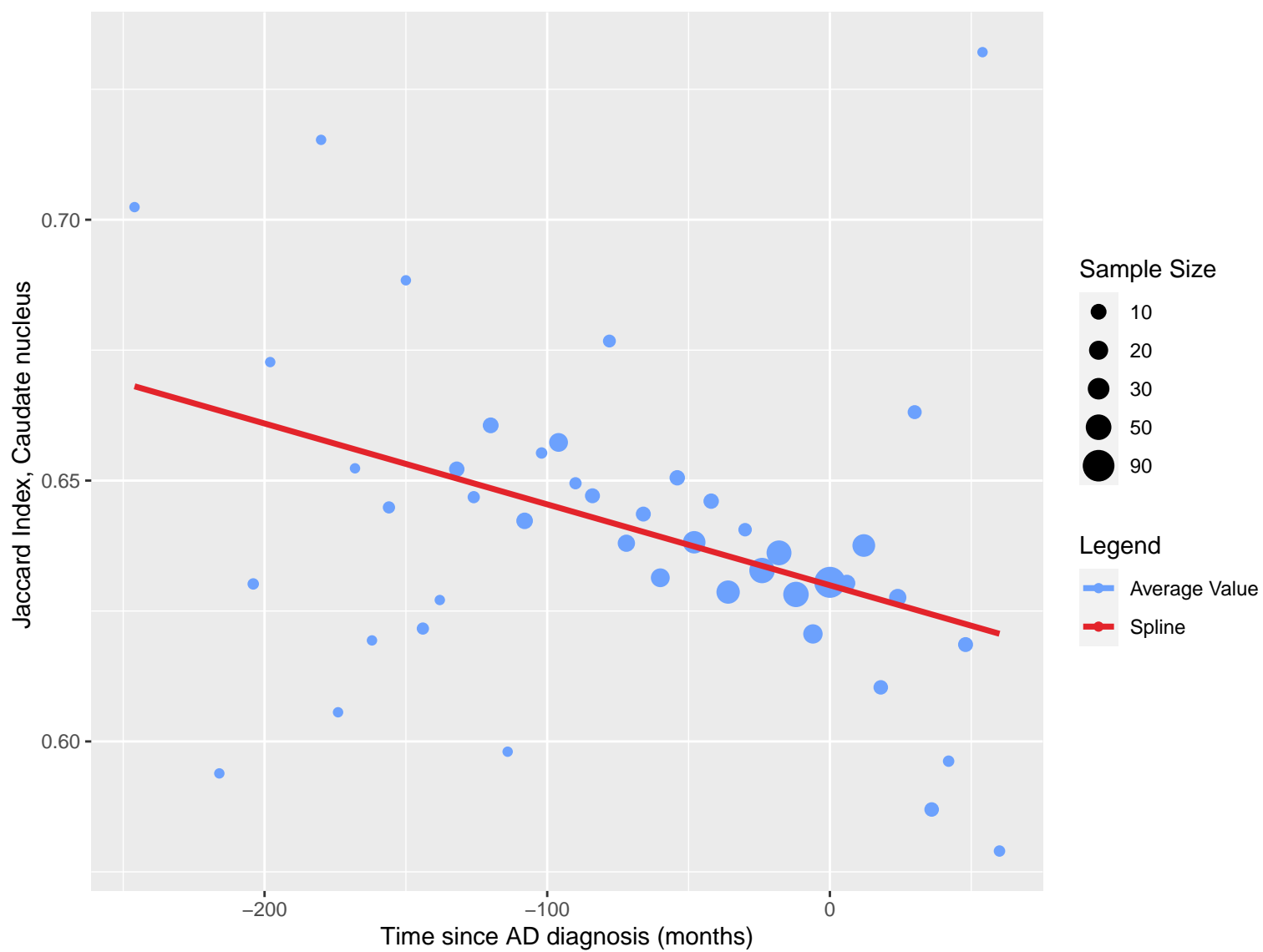
Jaccard Index, Cingulate gyrus, posterior part



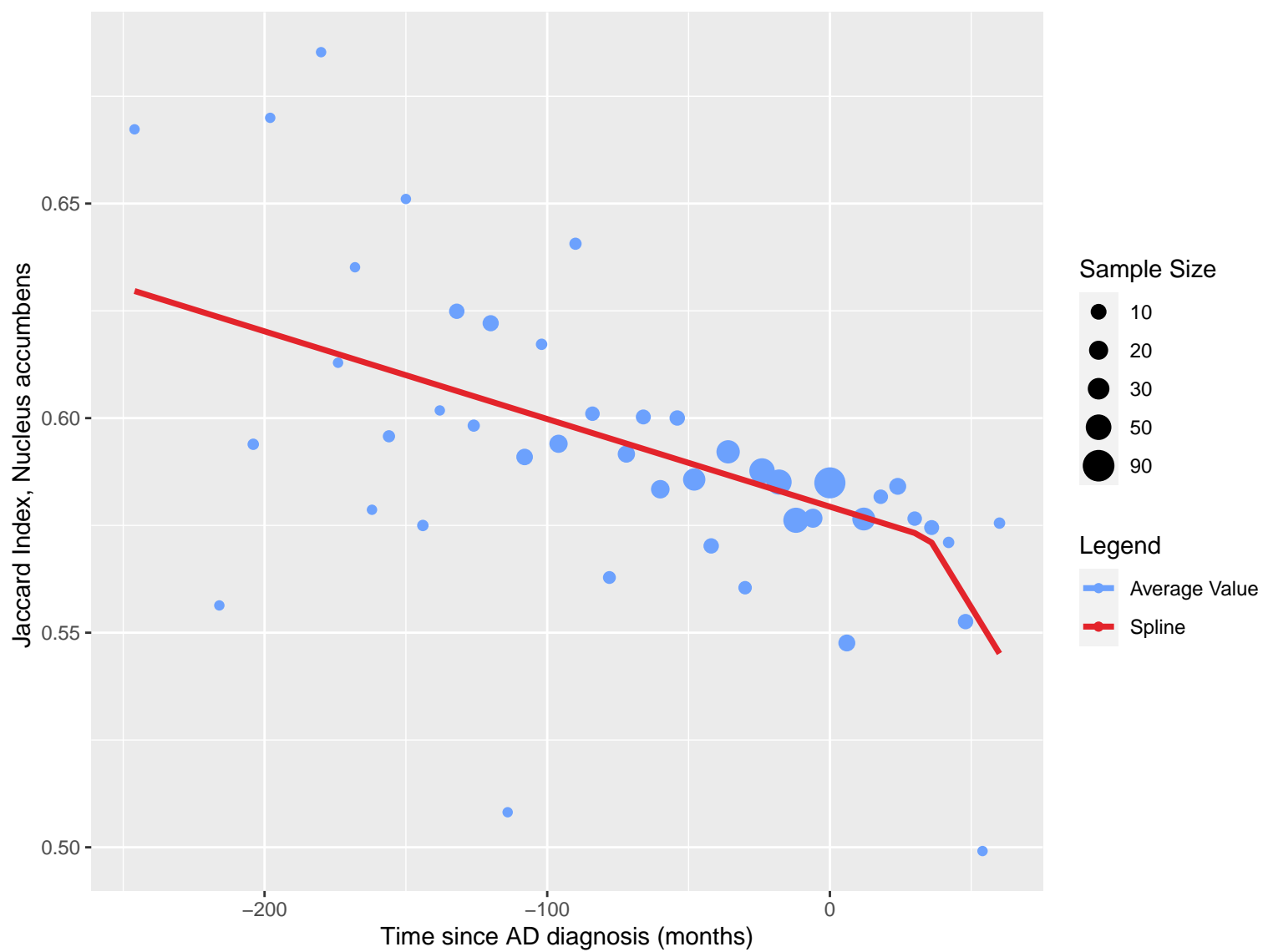


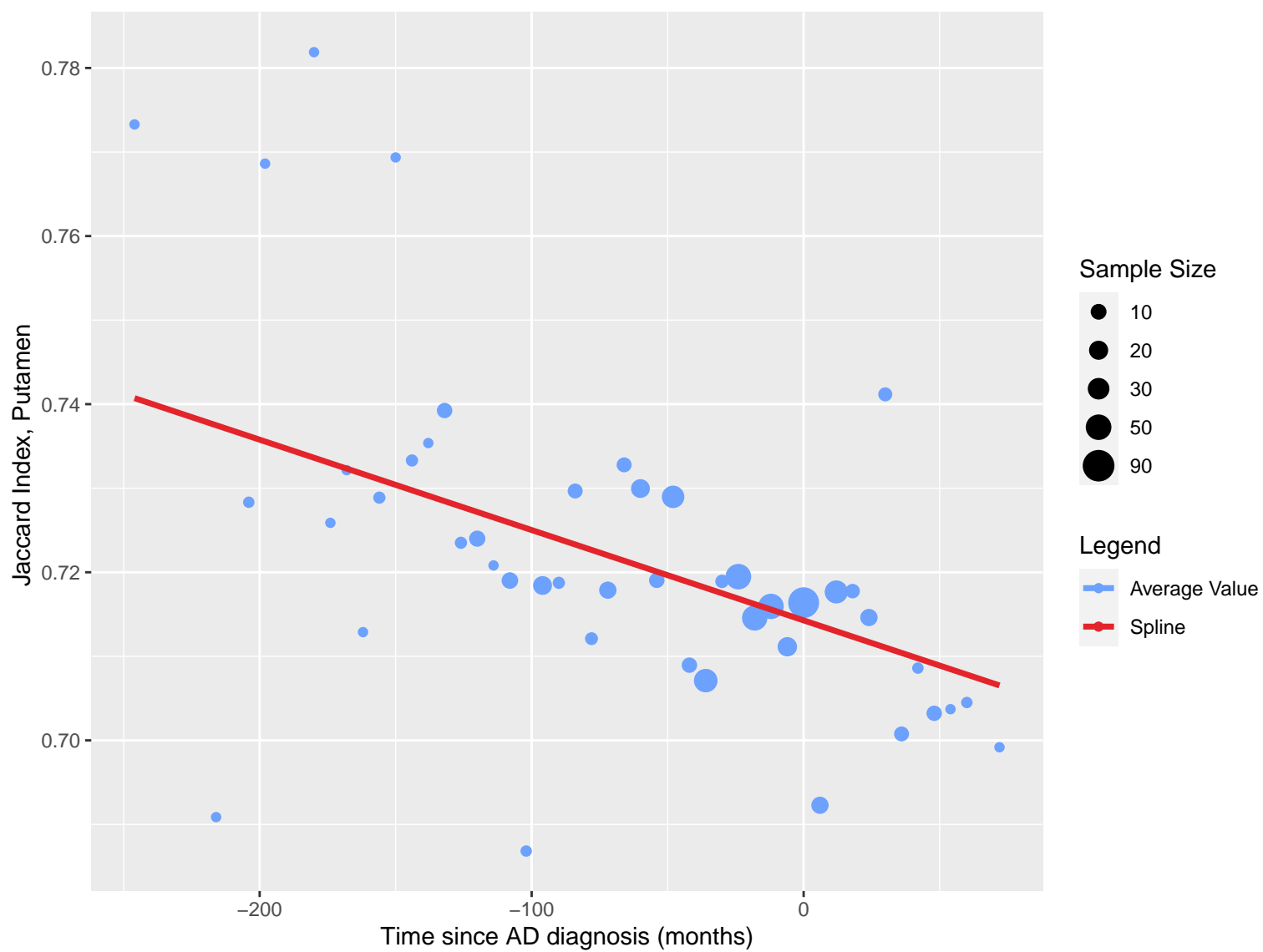


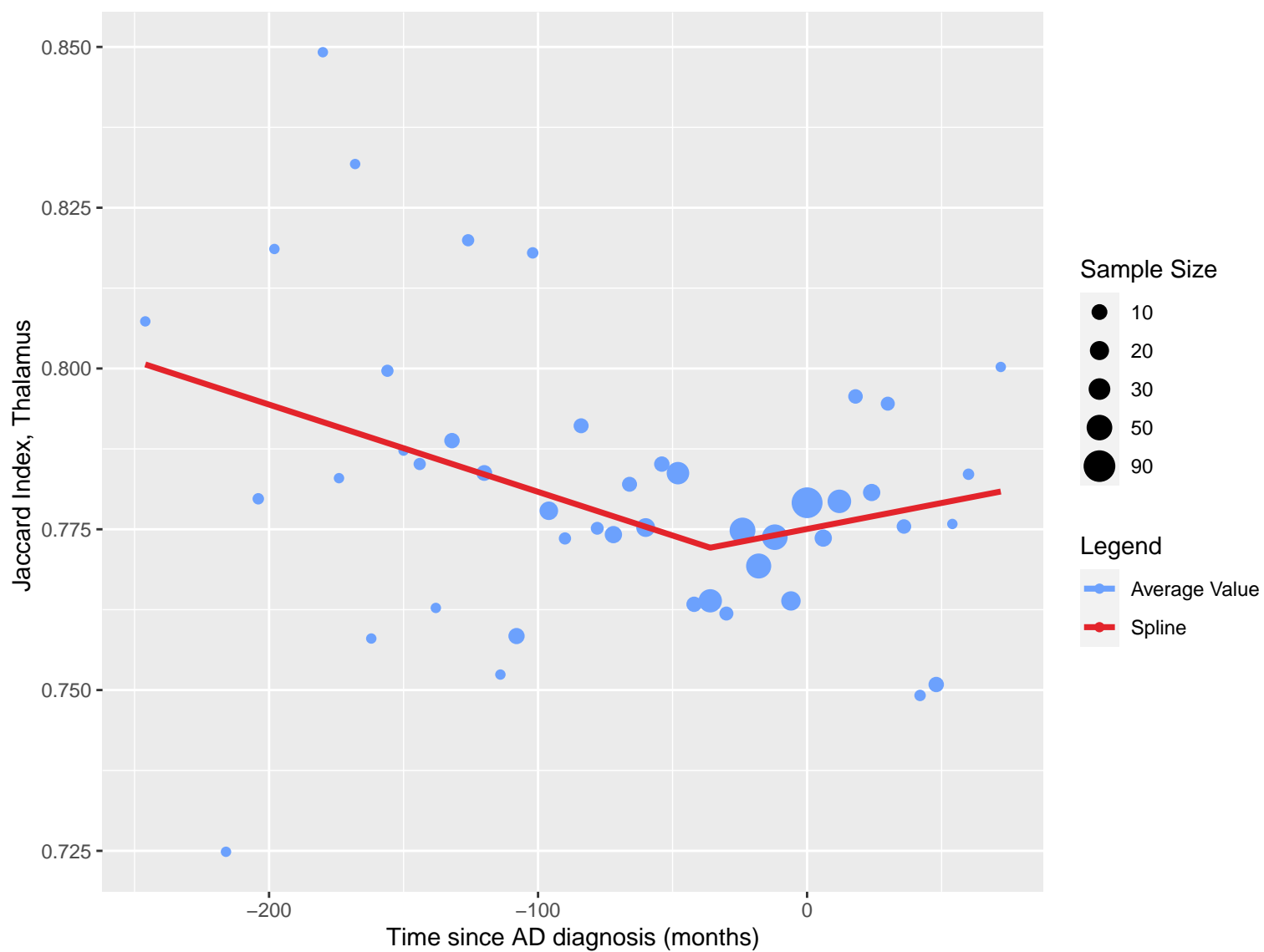


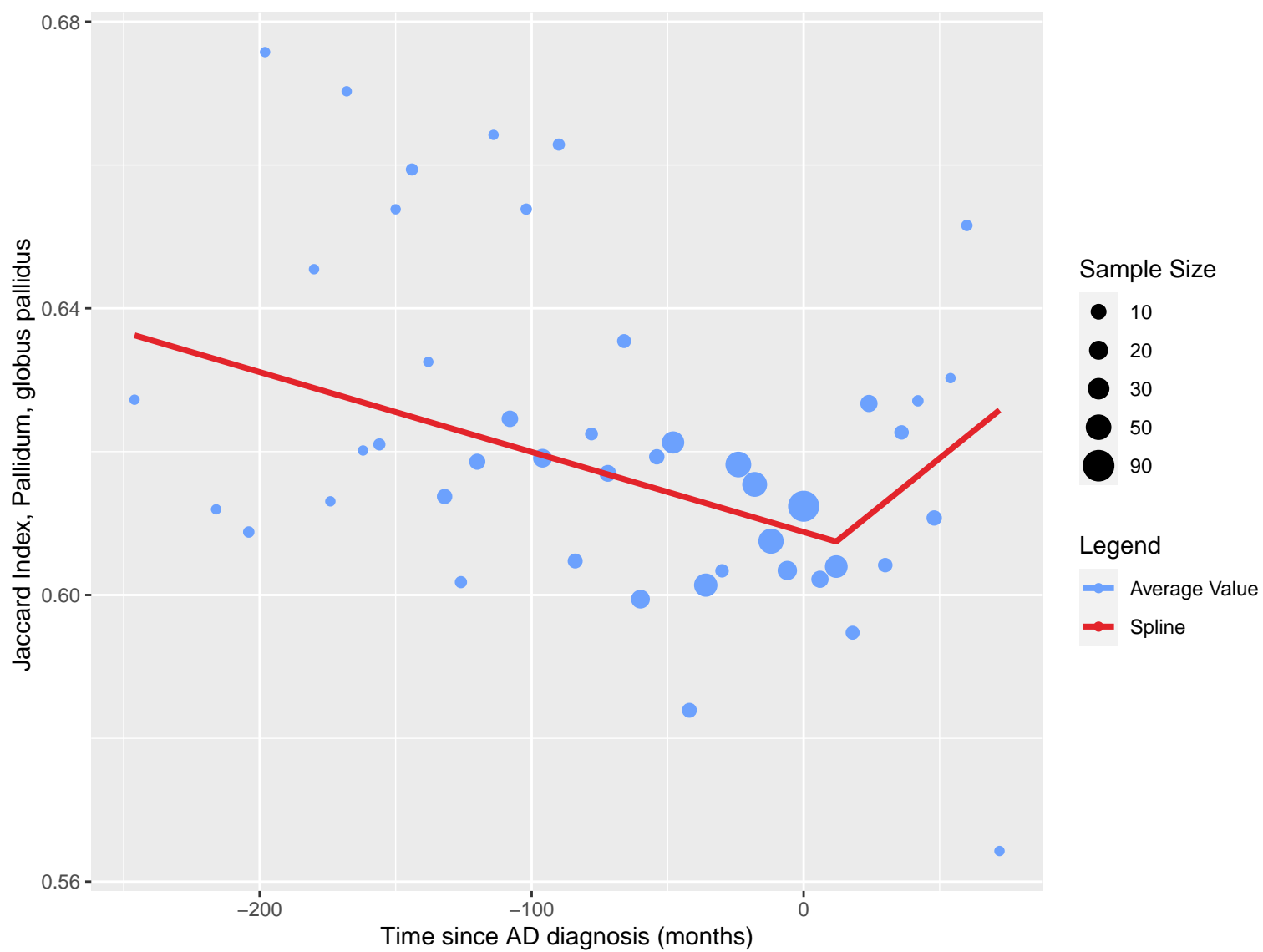


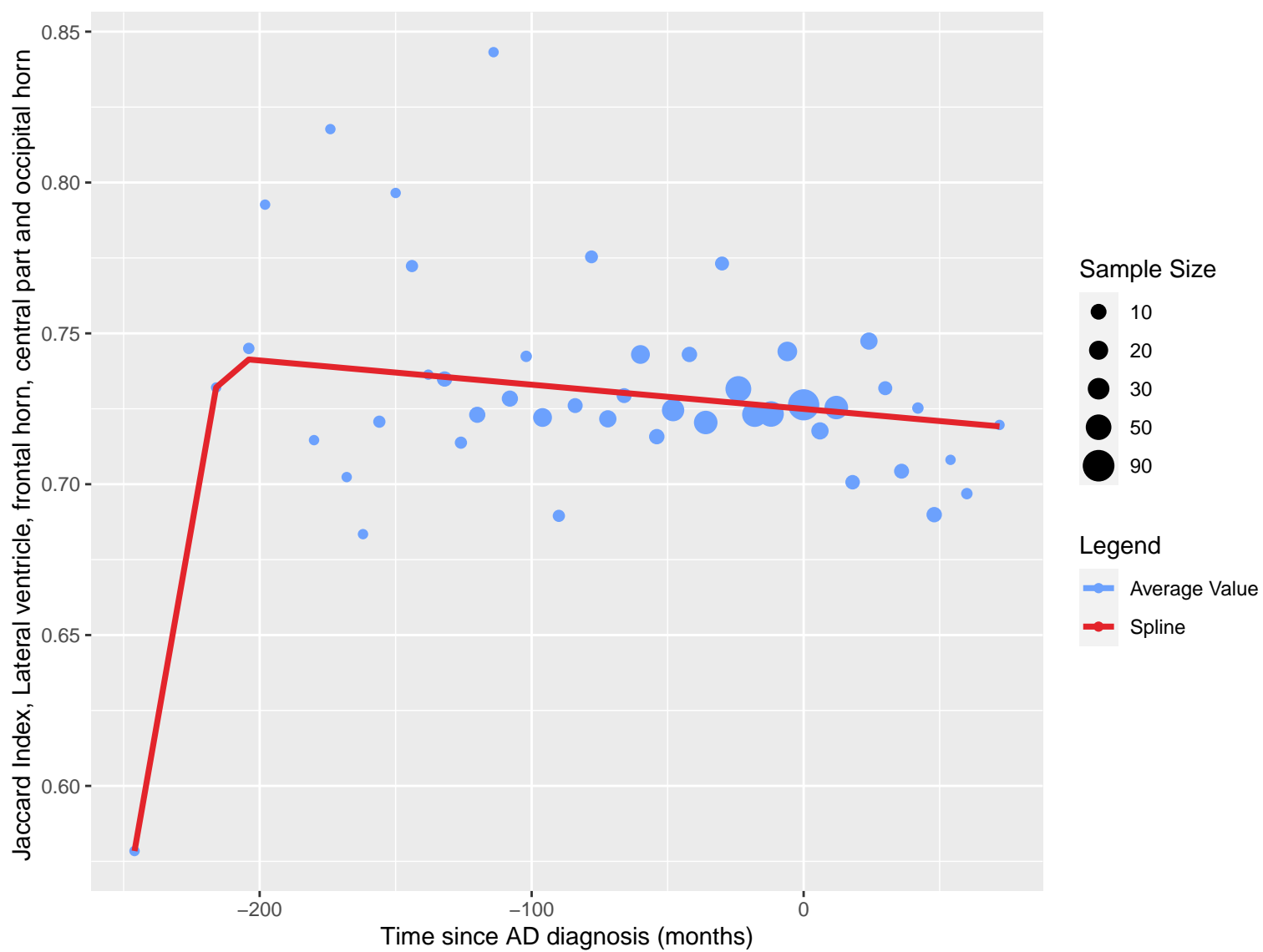


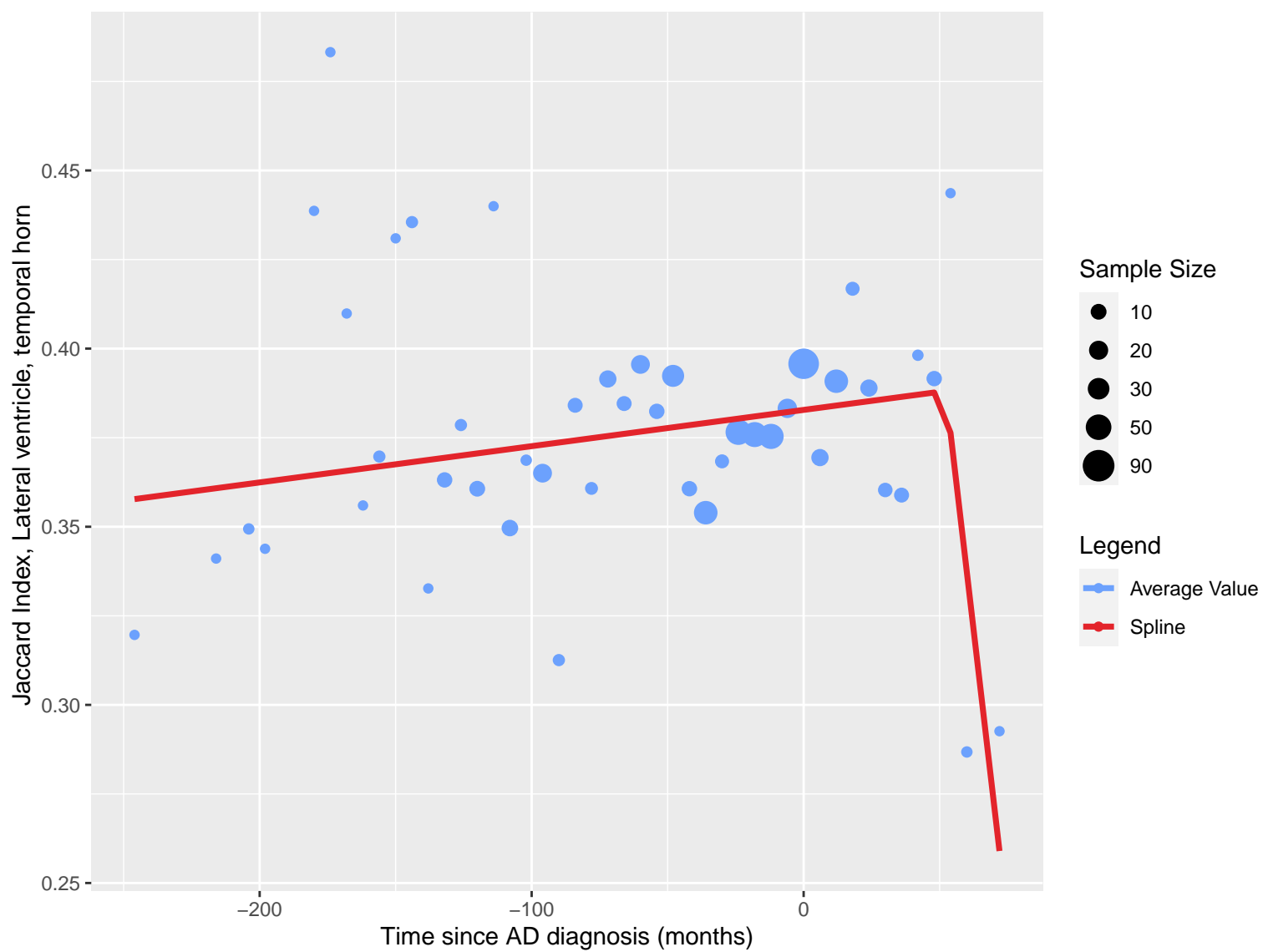


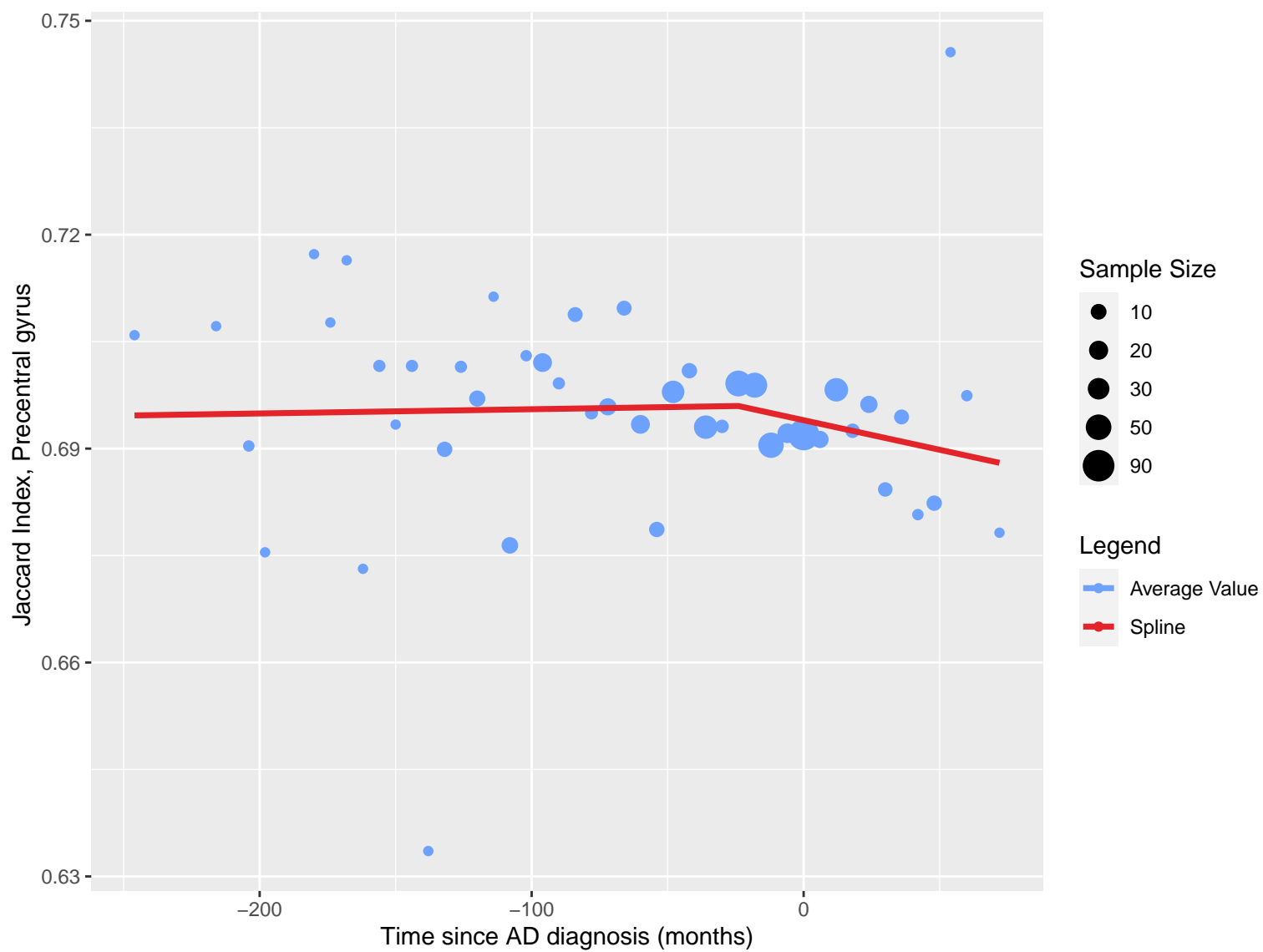


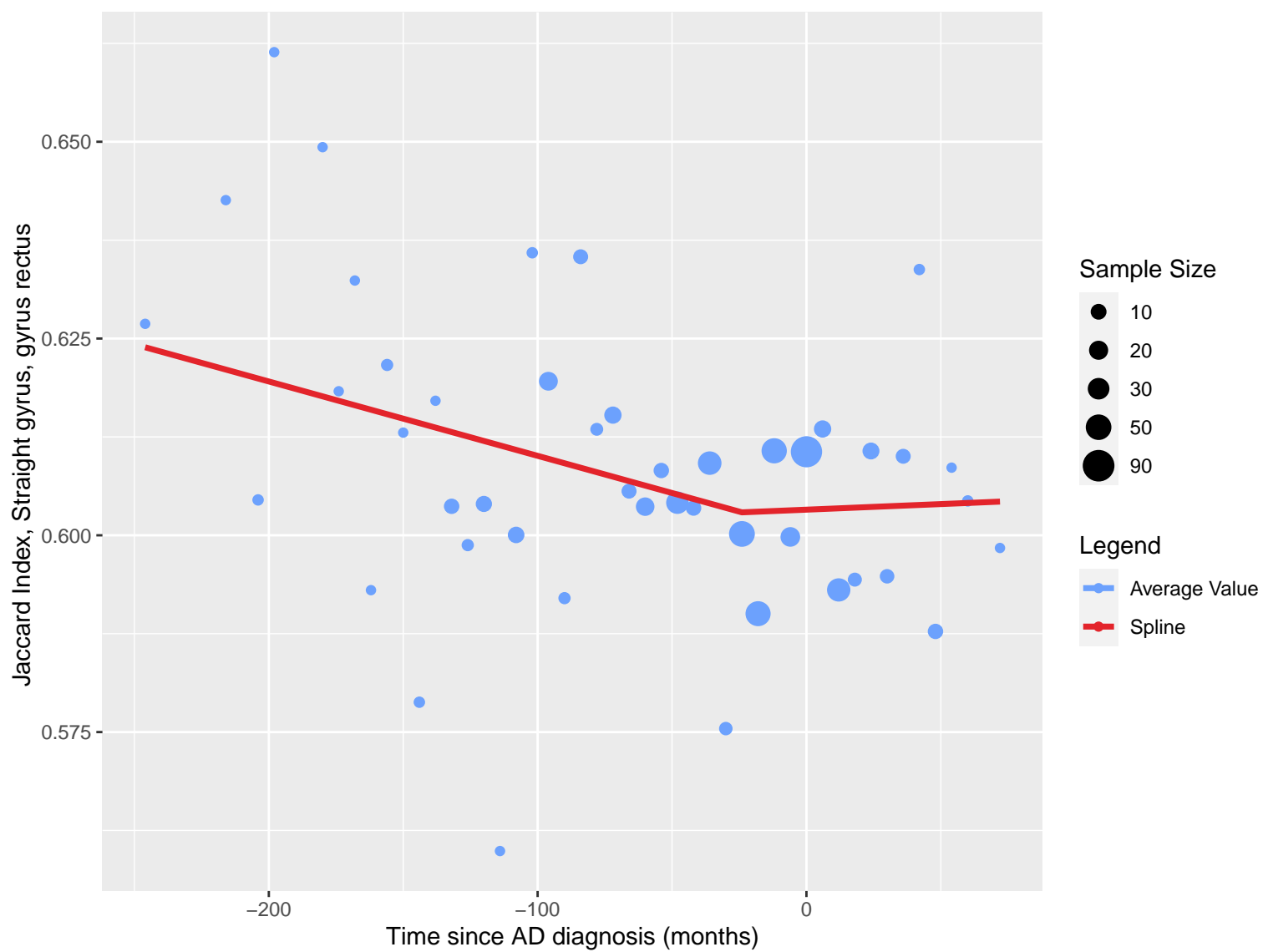




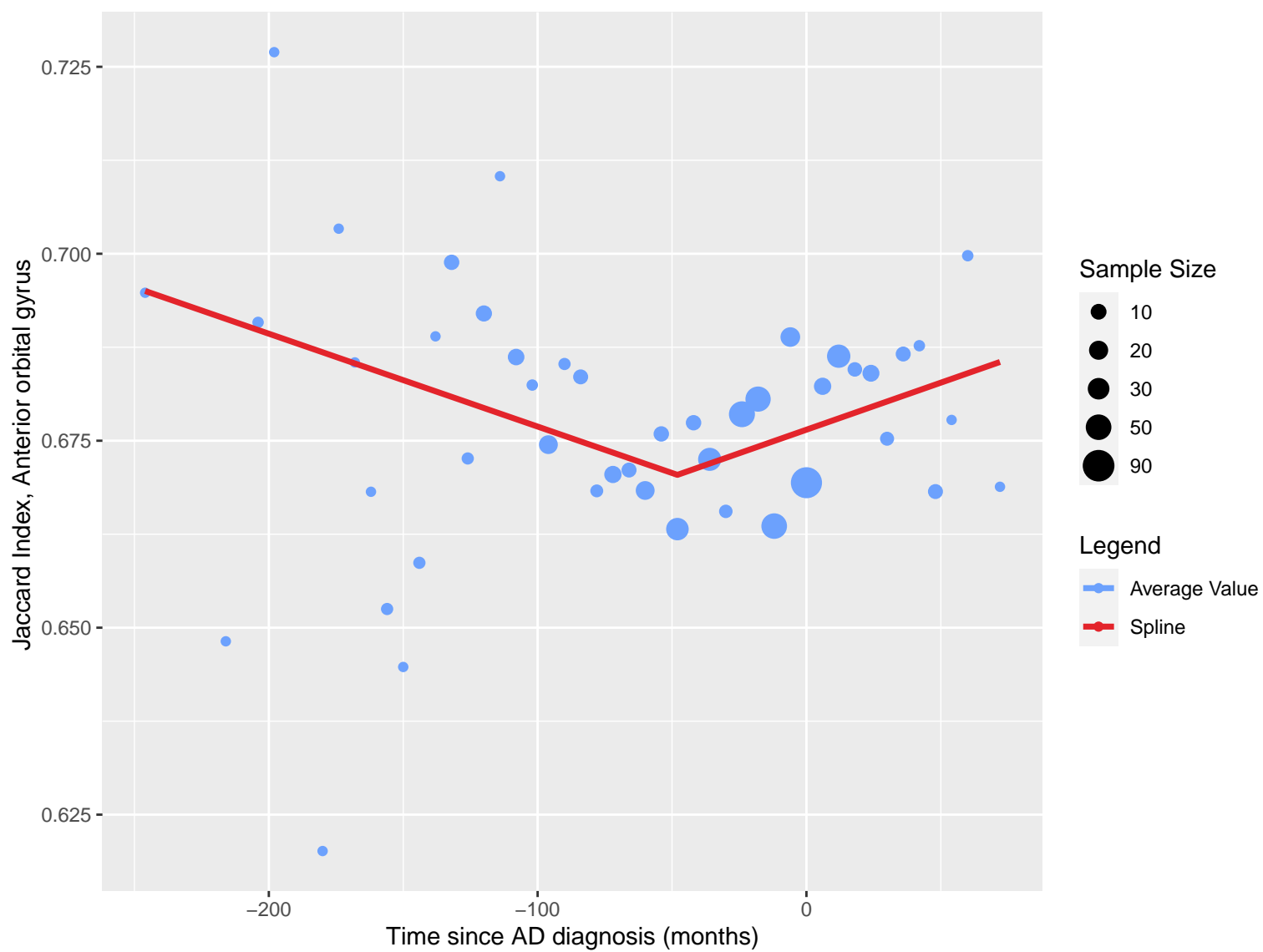


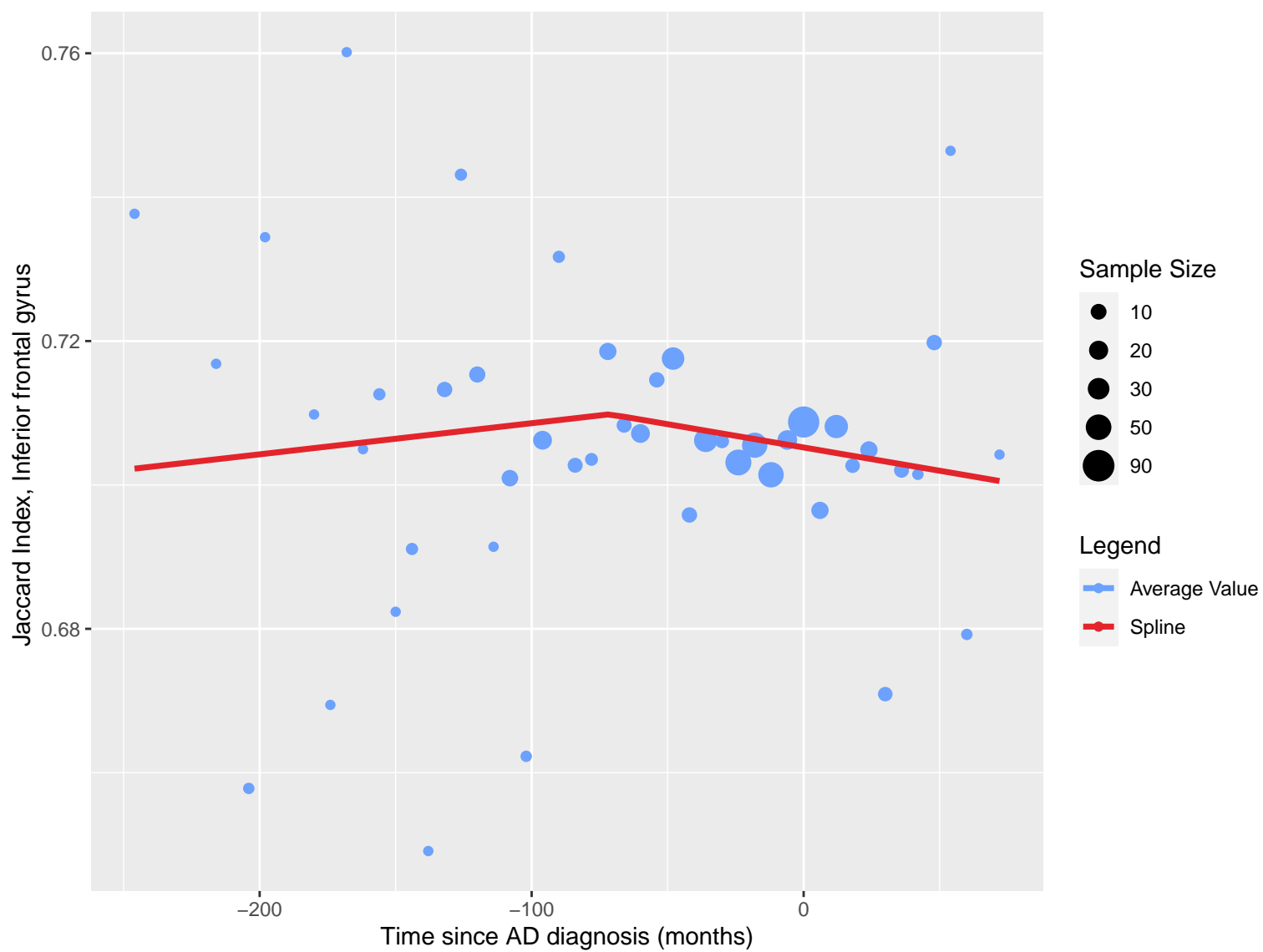


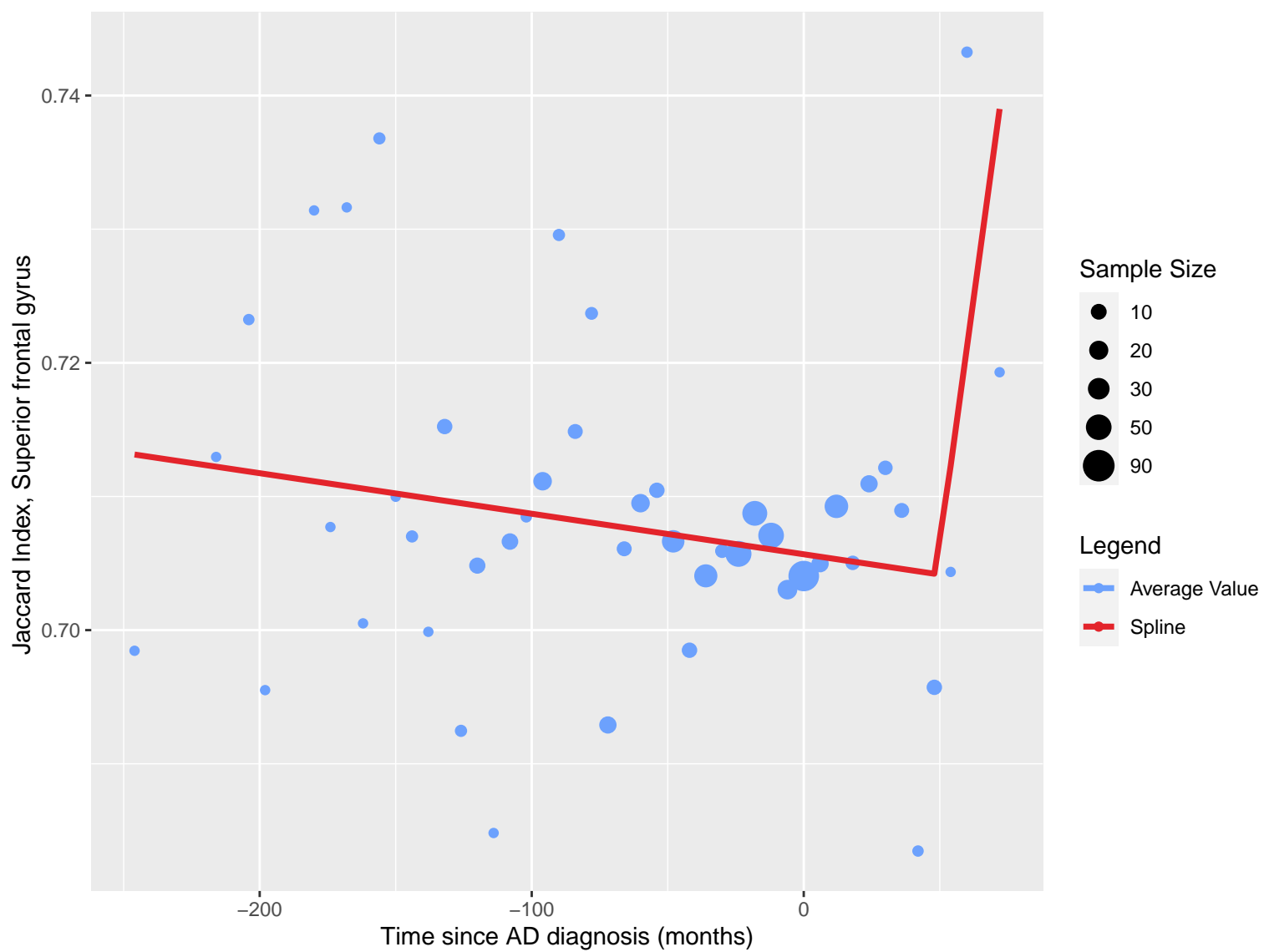


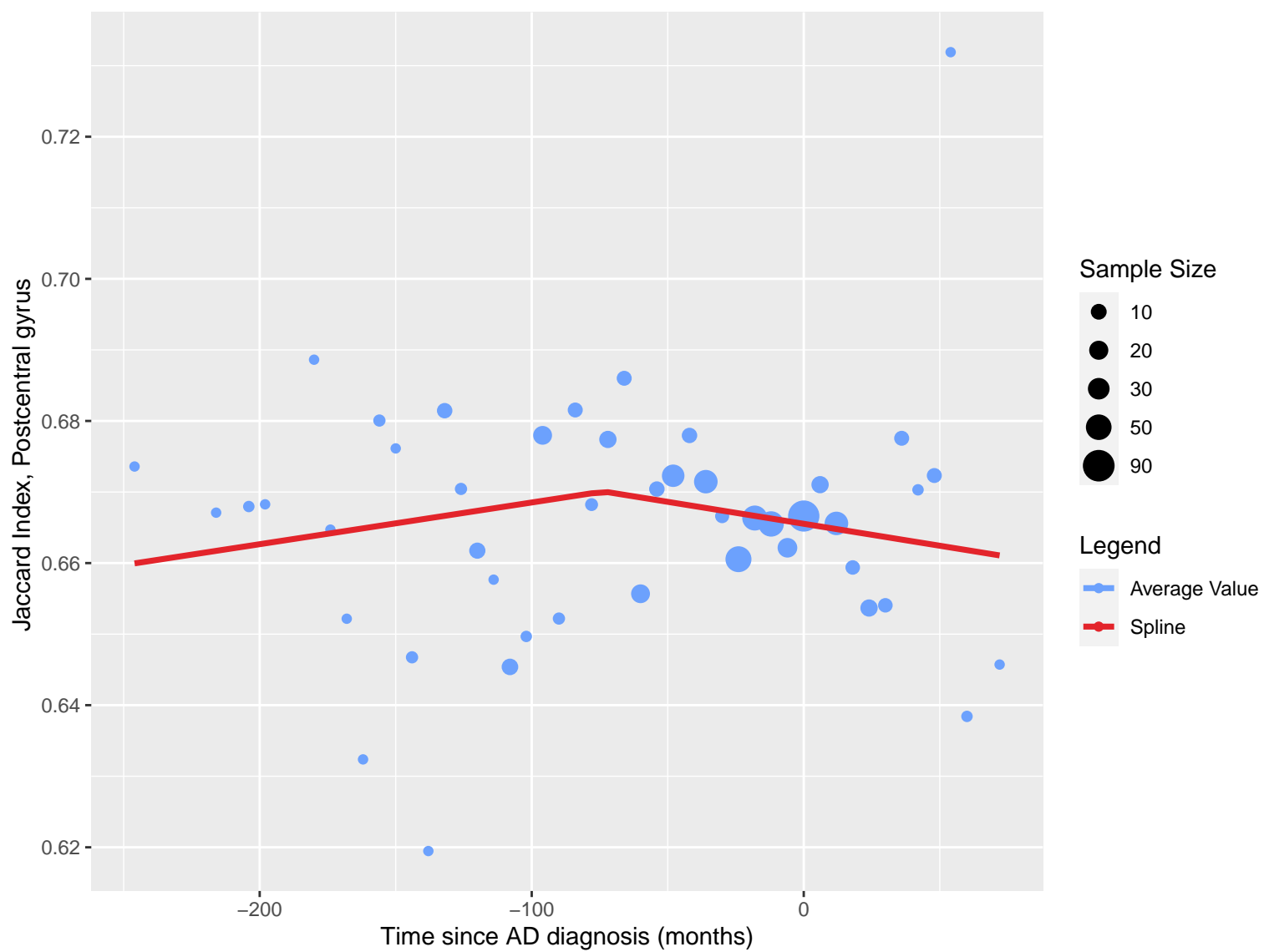


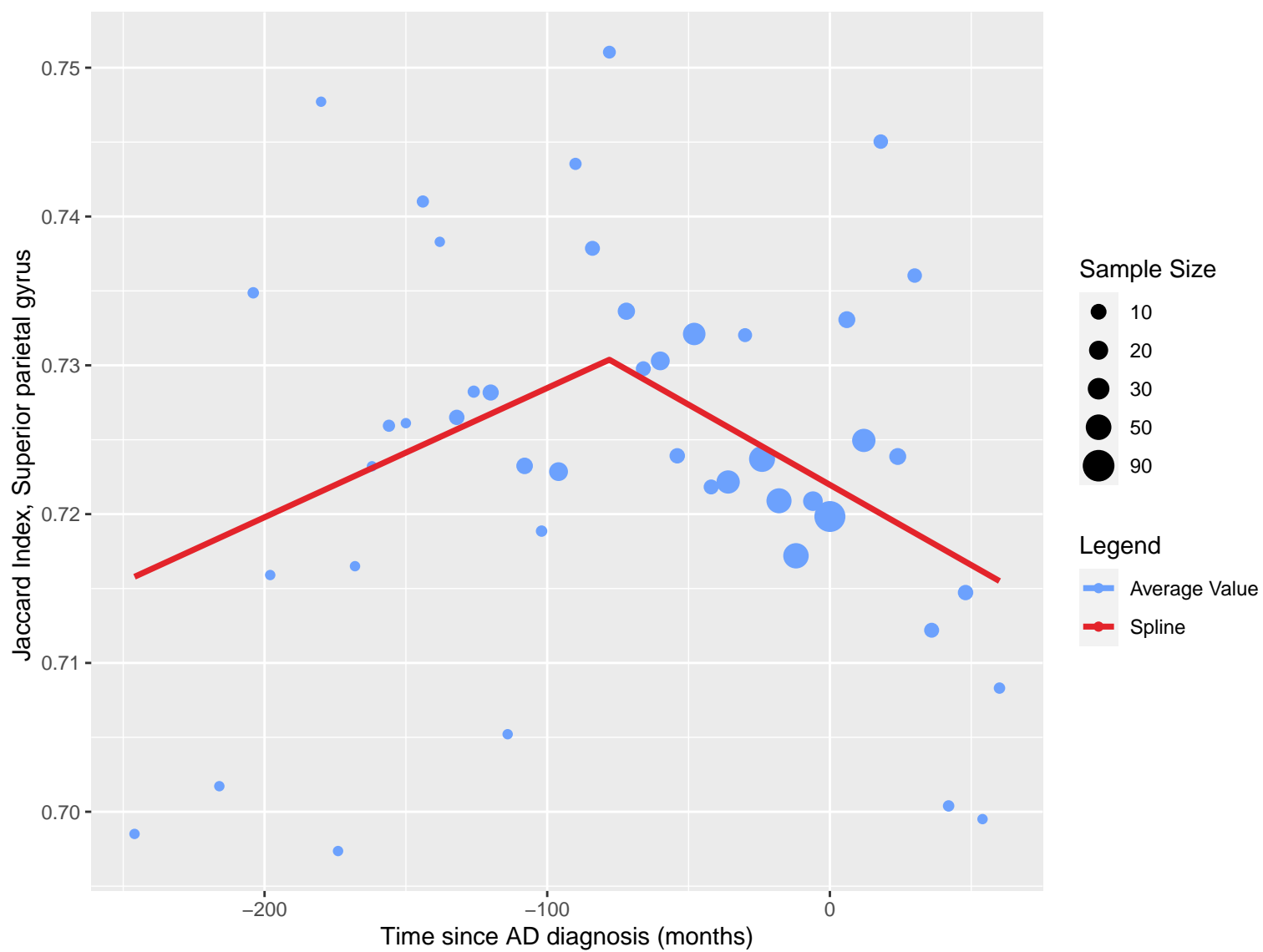


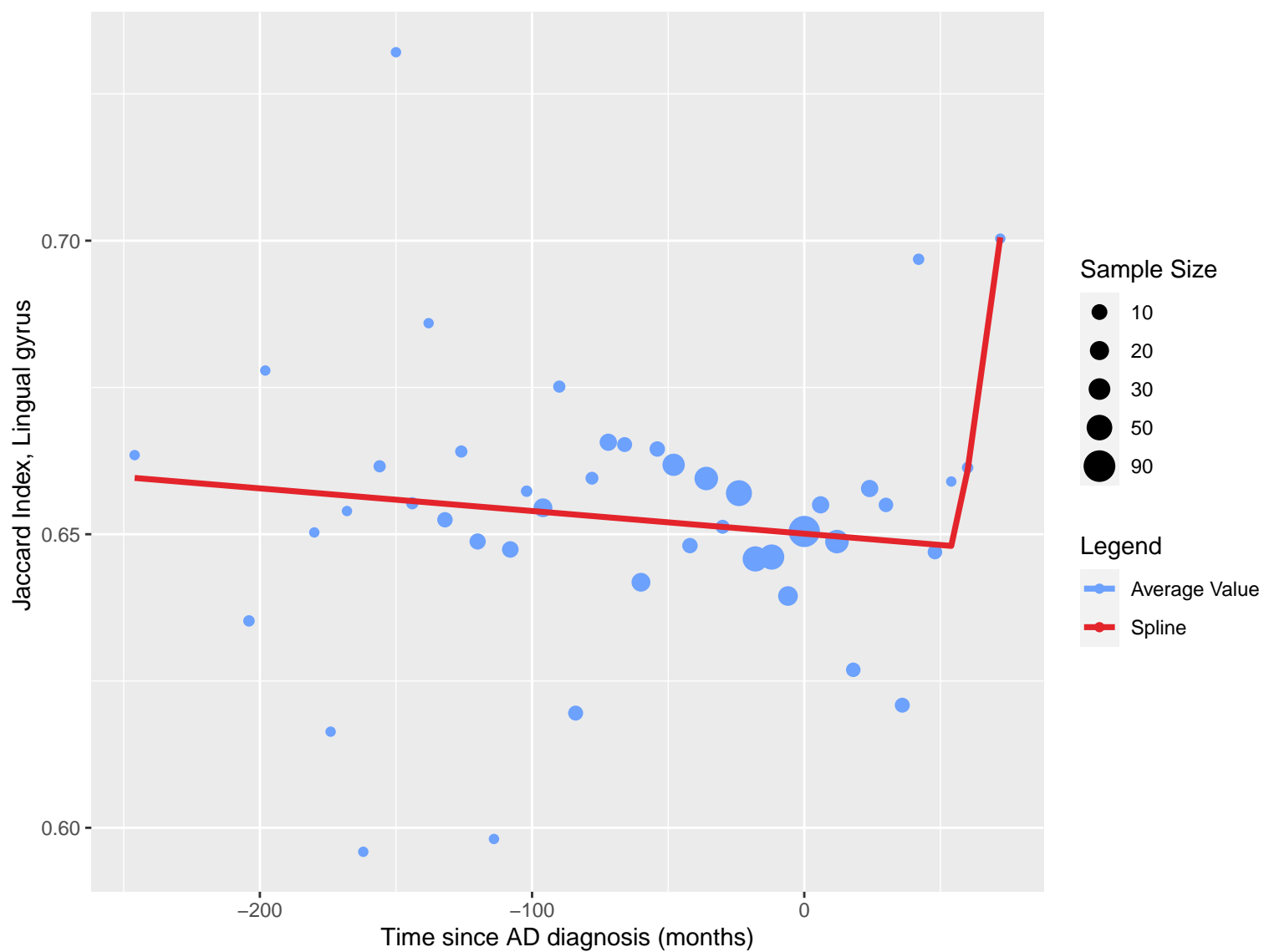


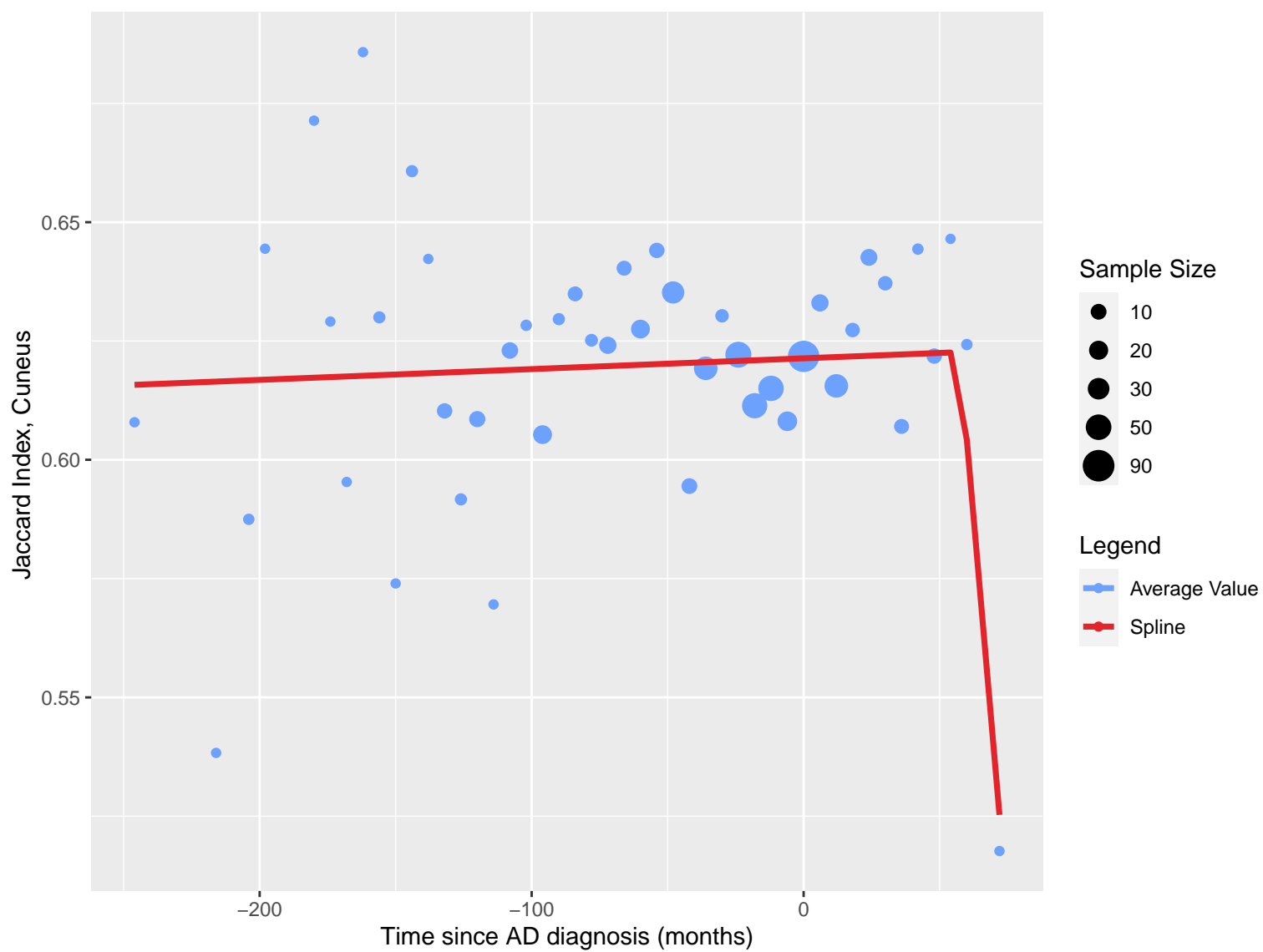


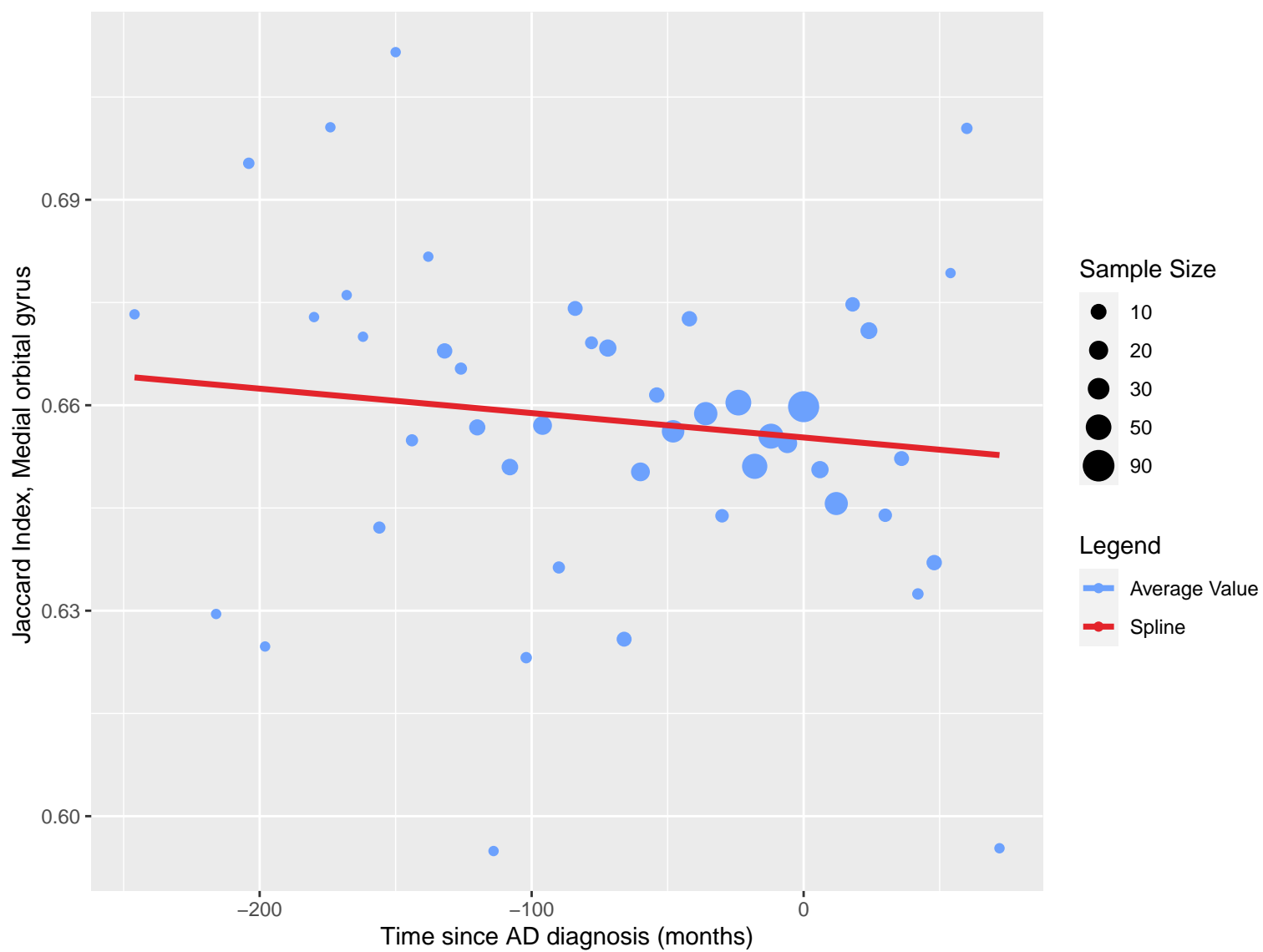




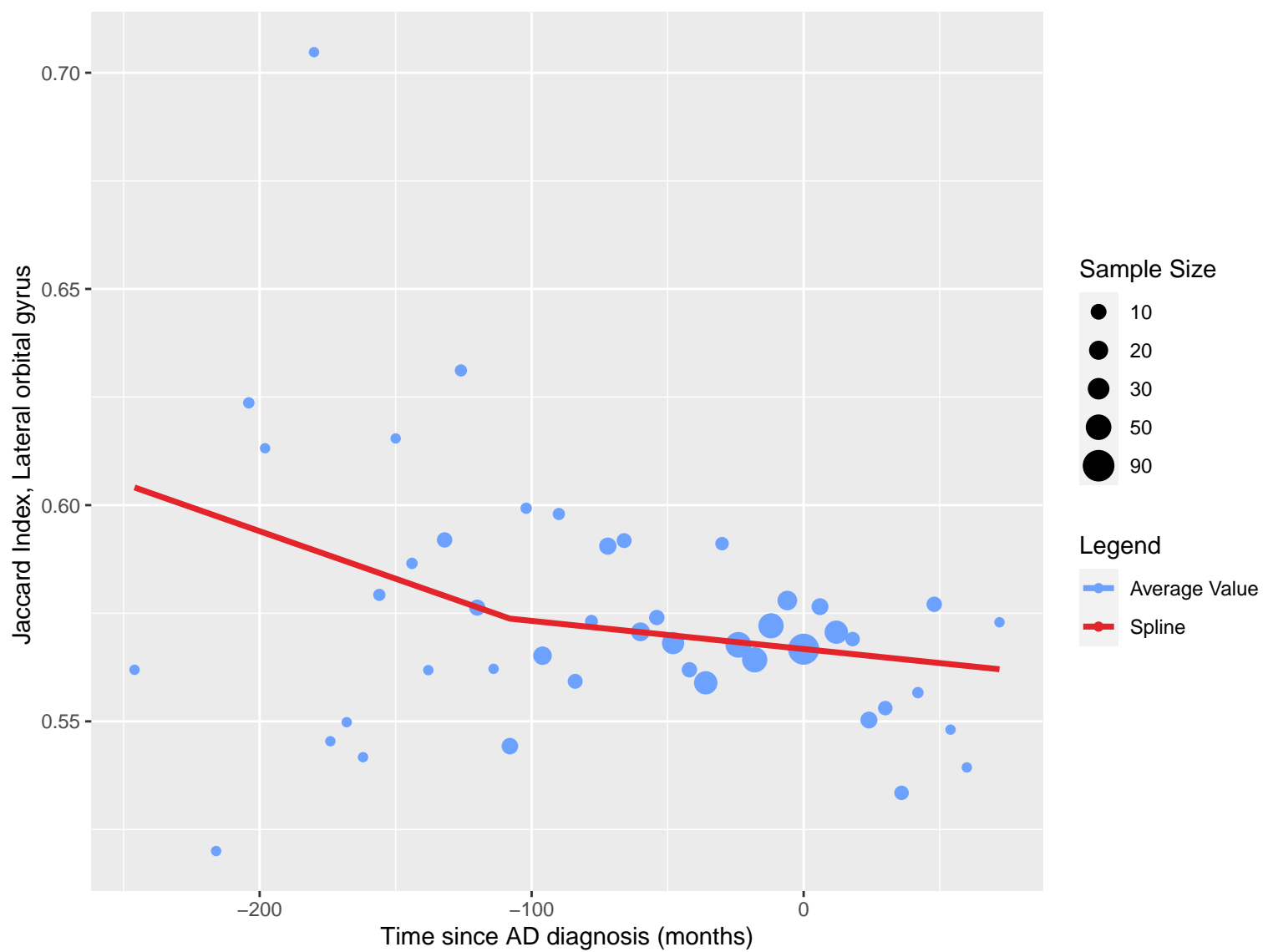


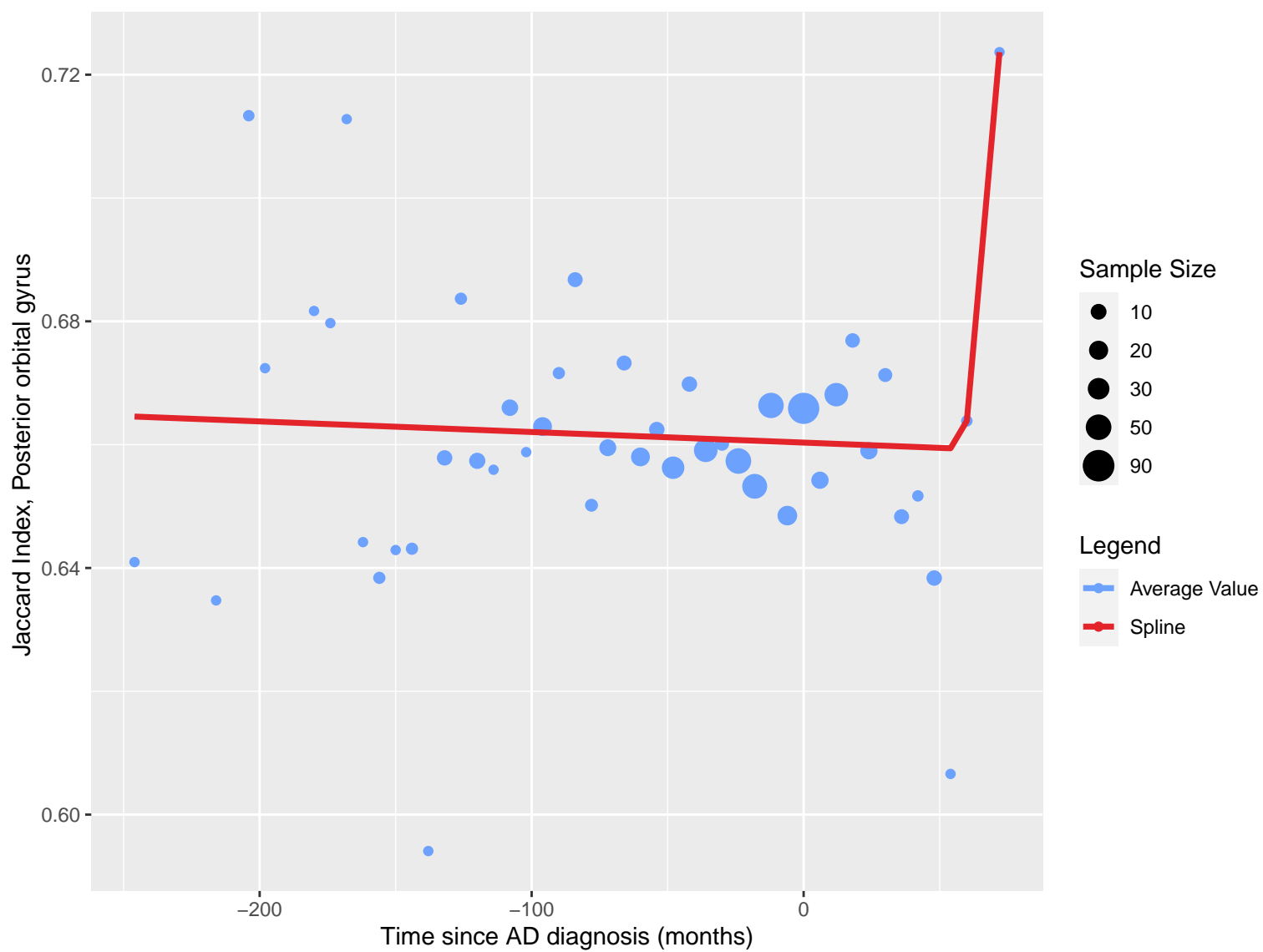


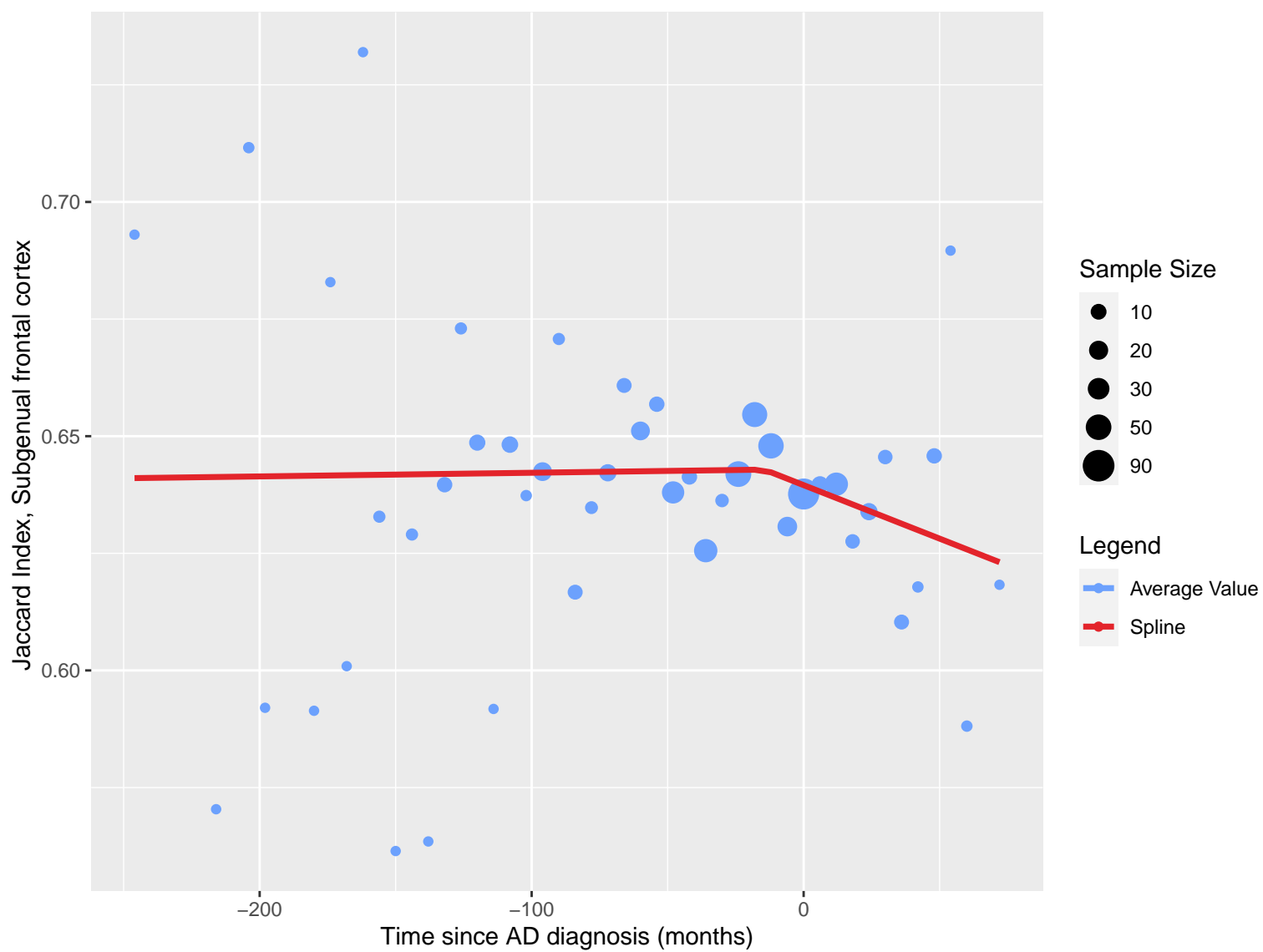


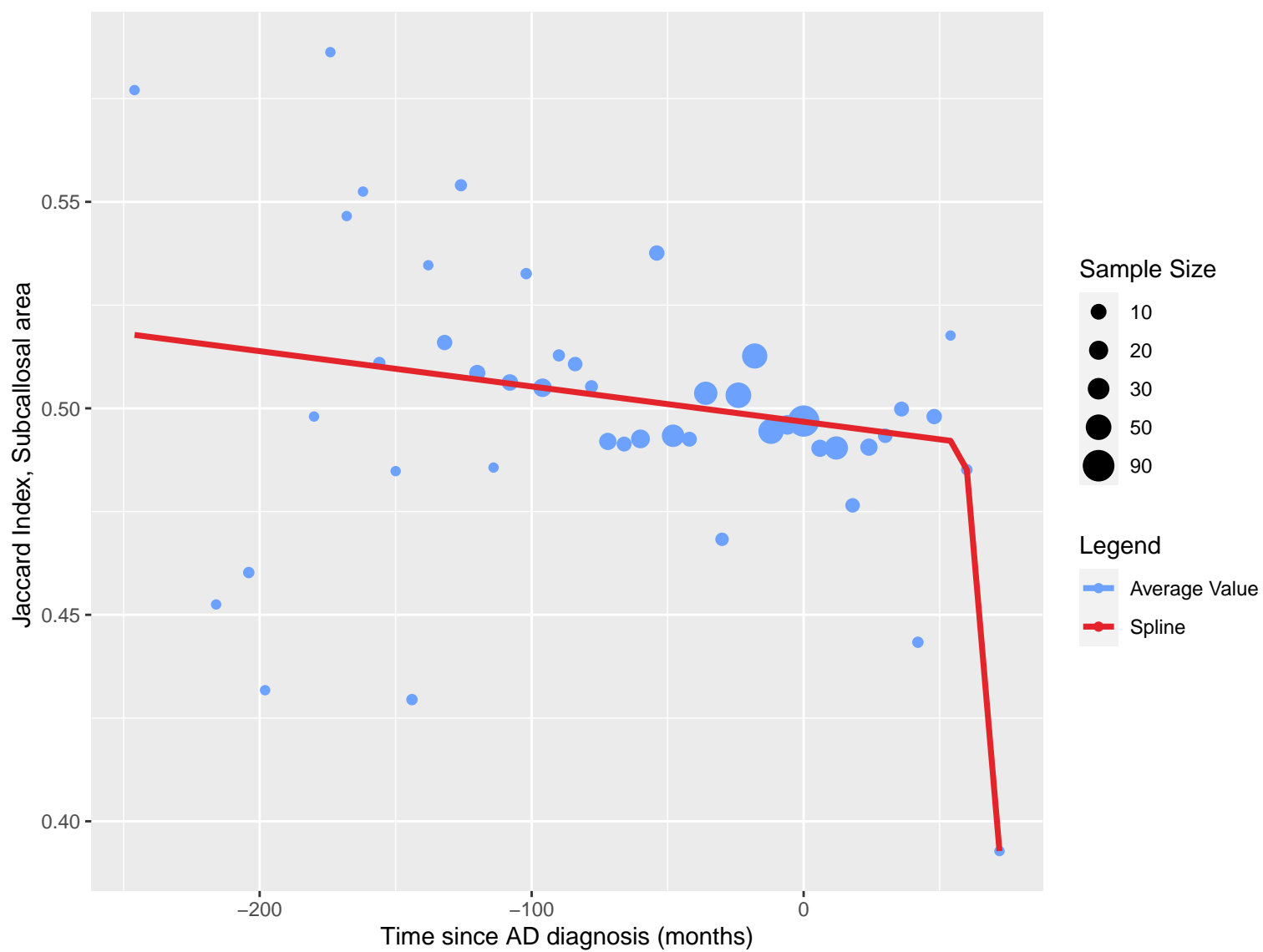


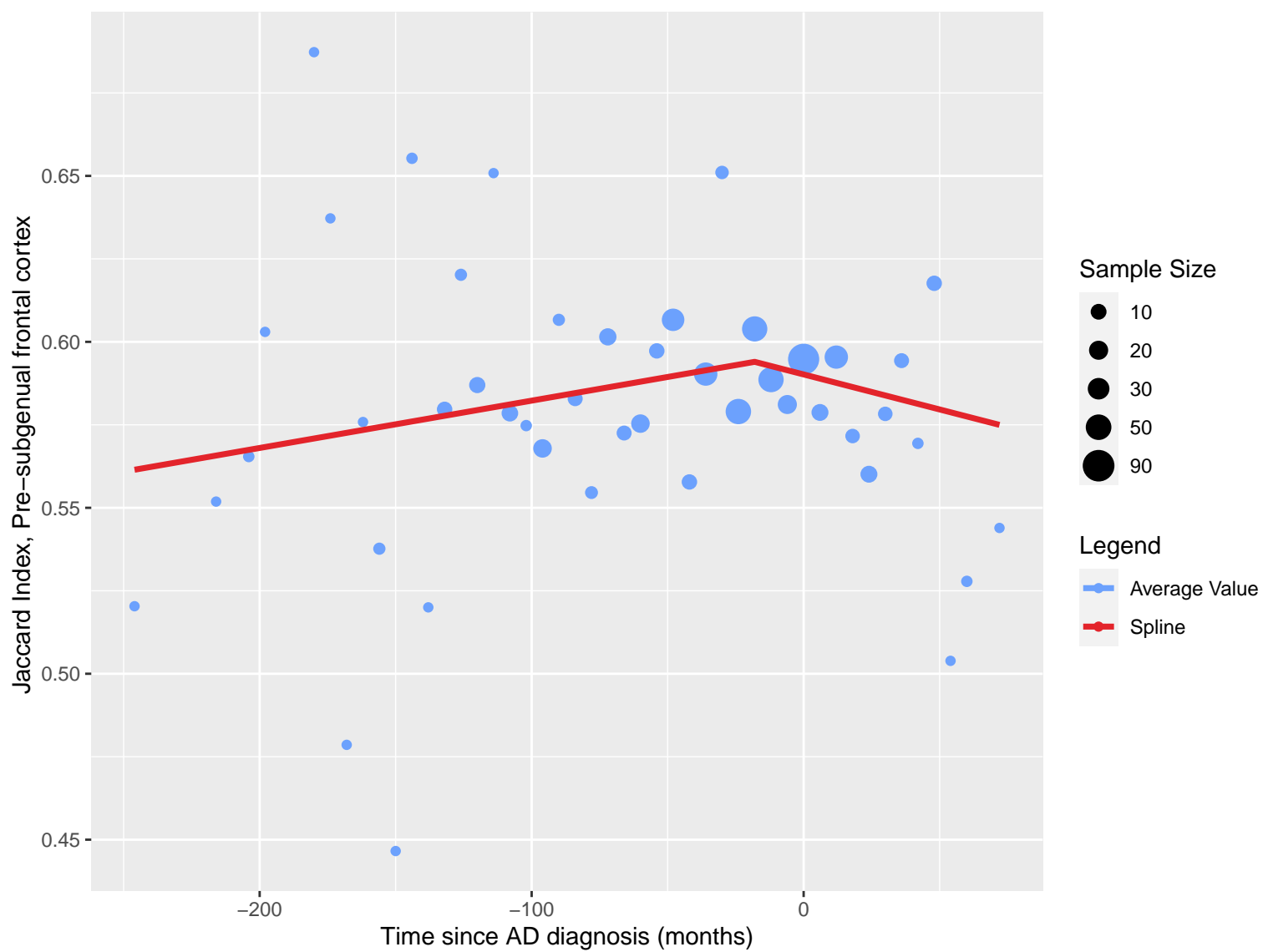


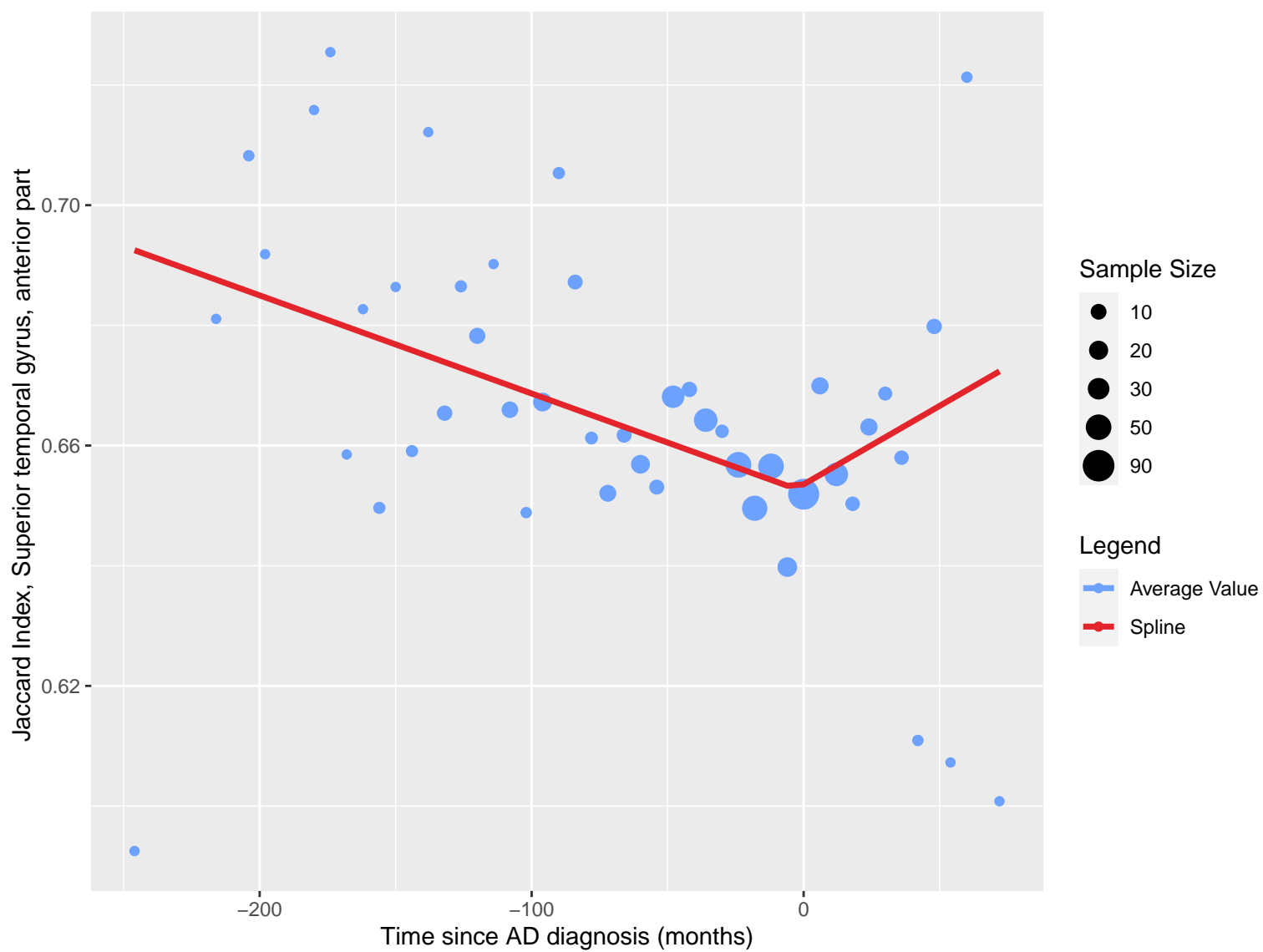


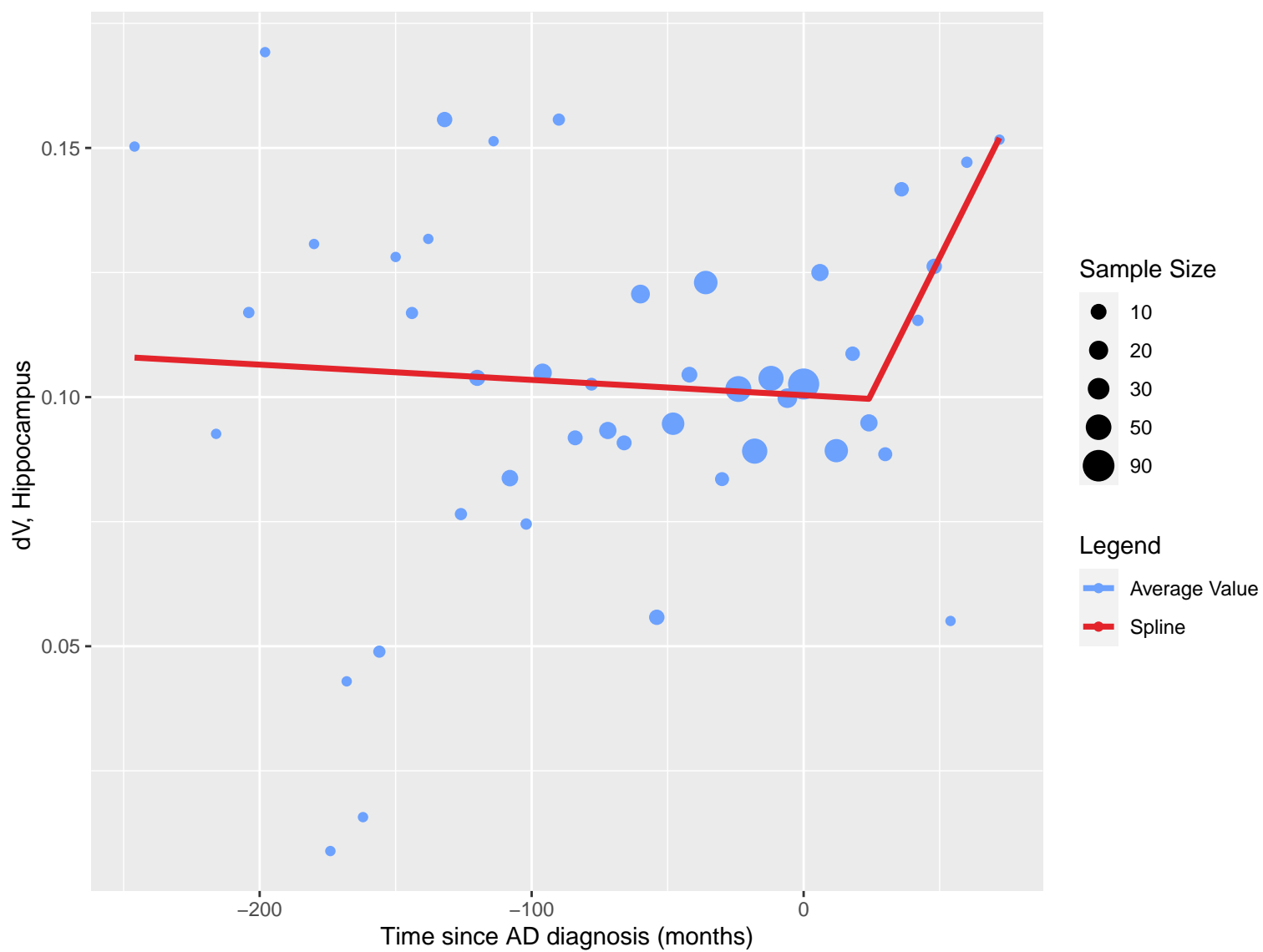


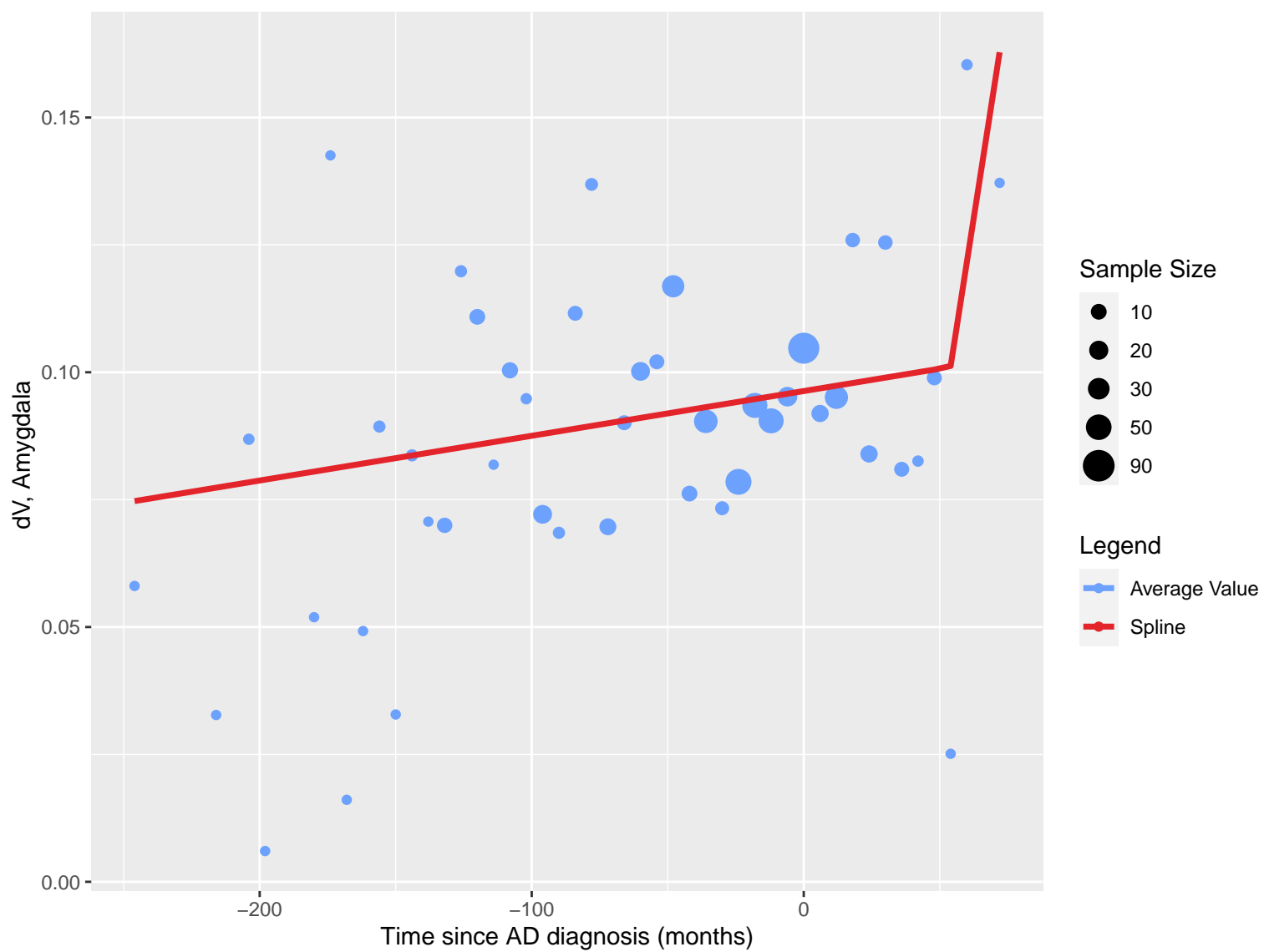














dV, Anterior temporal lobe, medial part

0.20

0.15

0.10

0.05

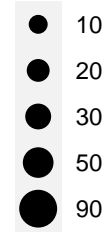
-200

-100

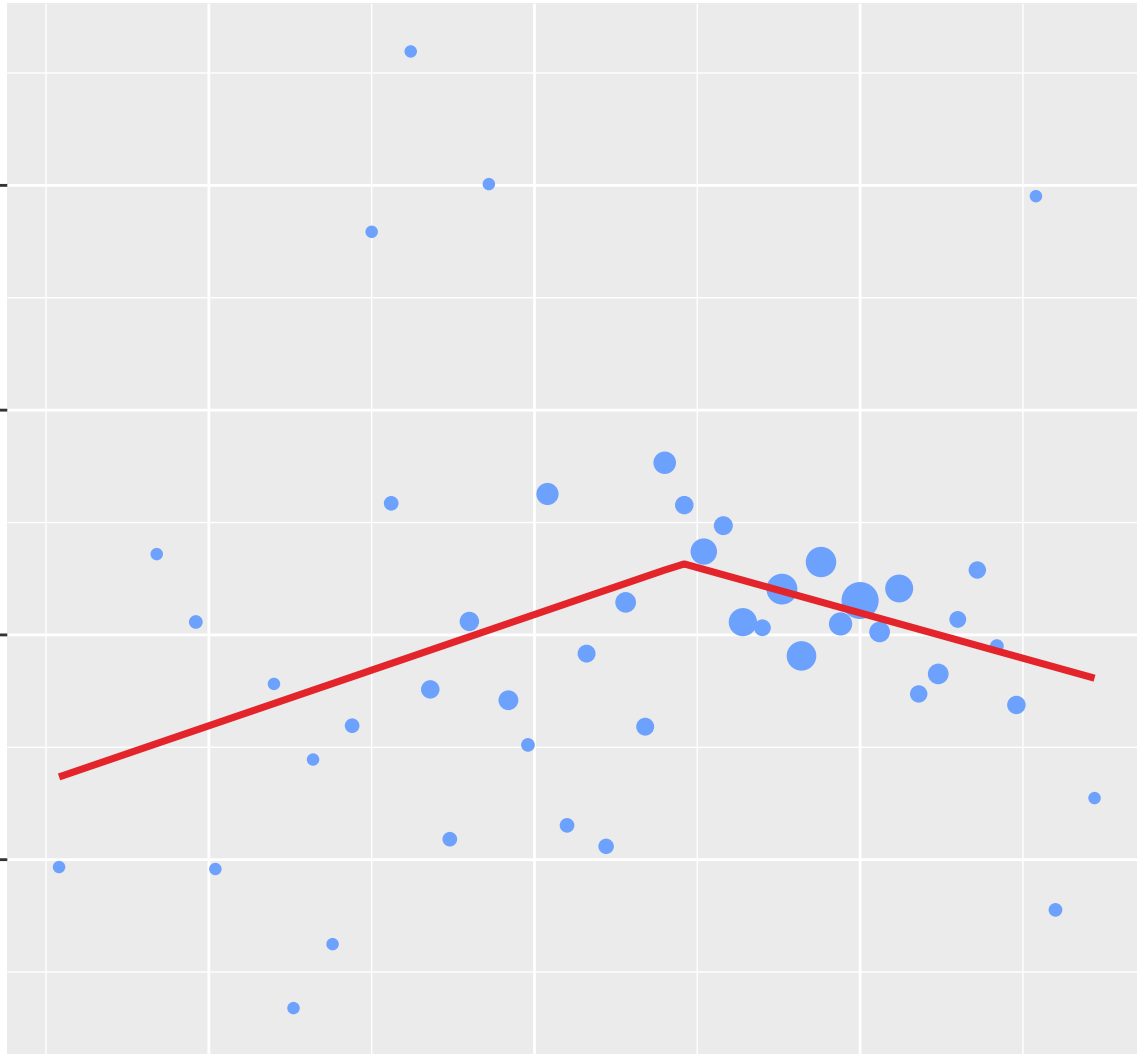
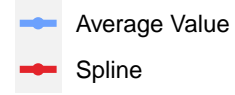
0

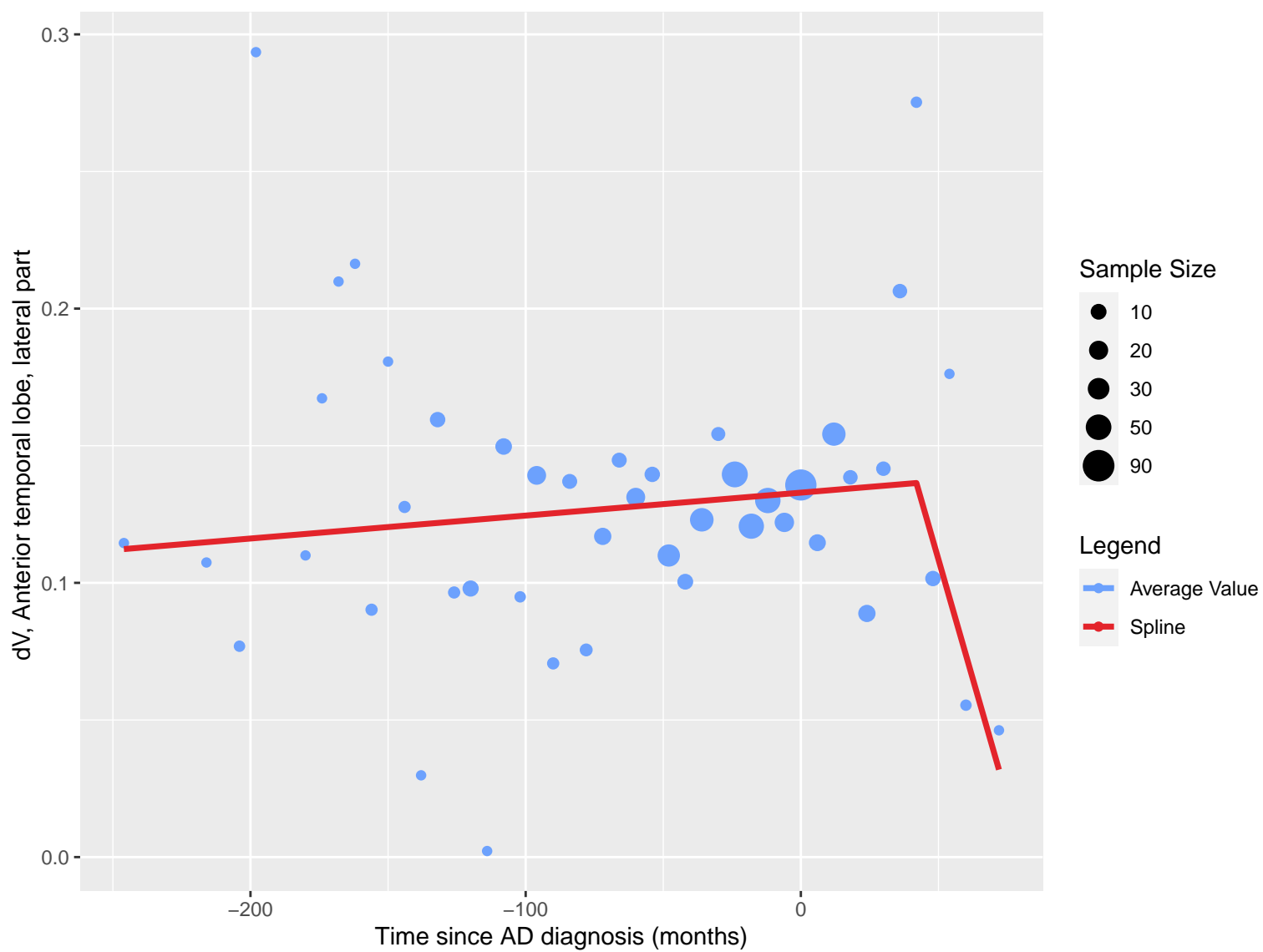
Time since AD diagnosis (months)

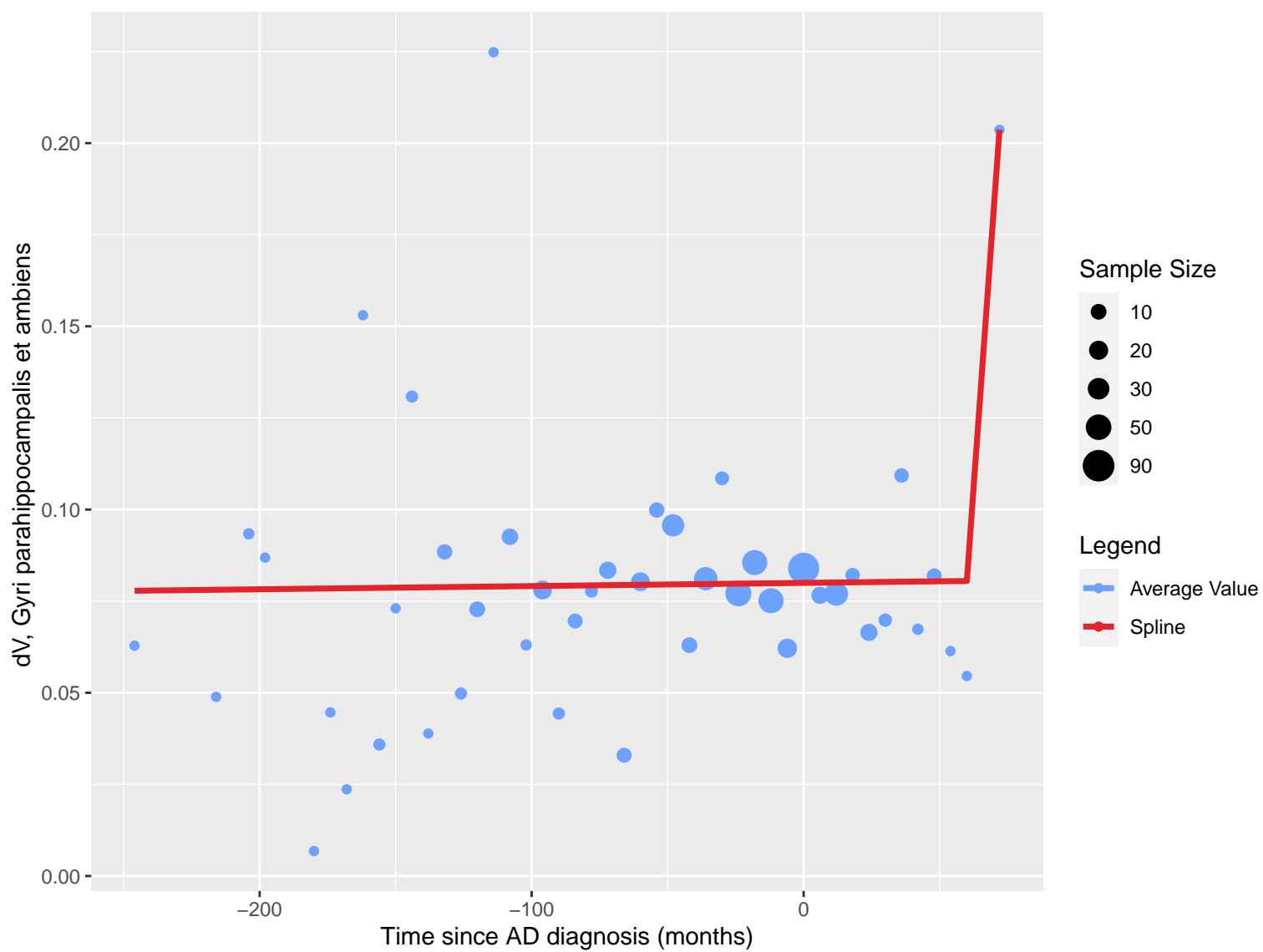
Sample Size

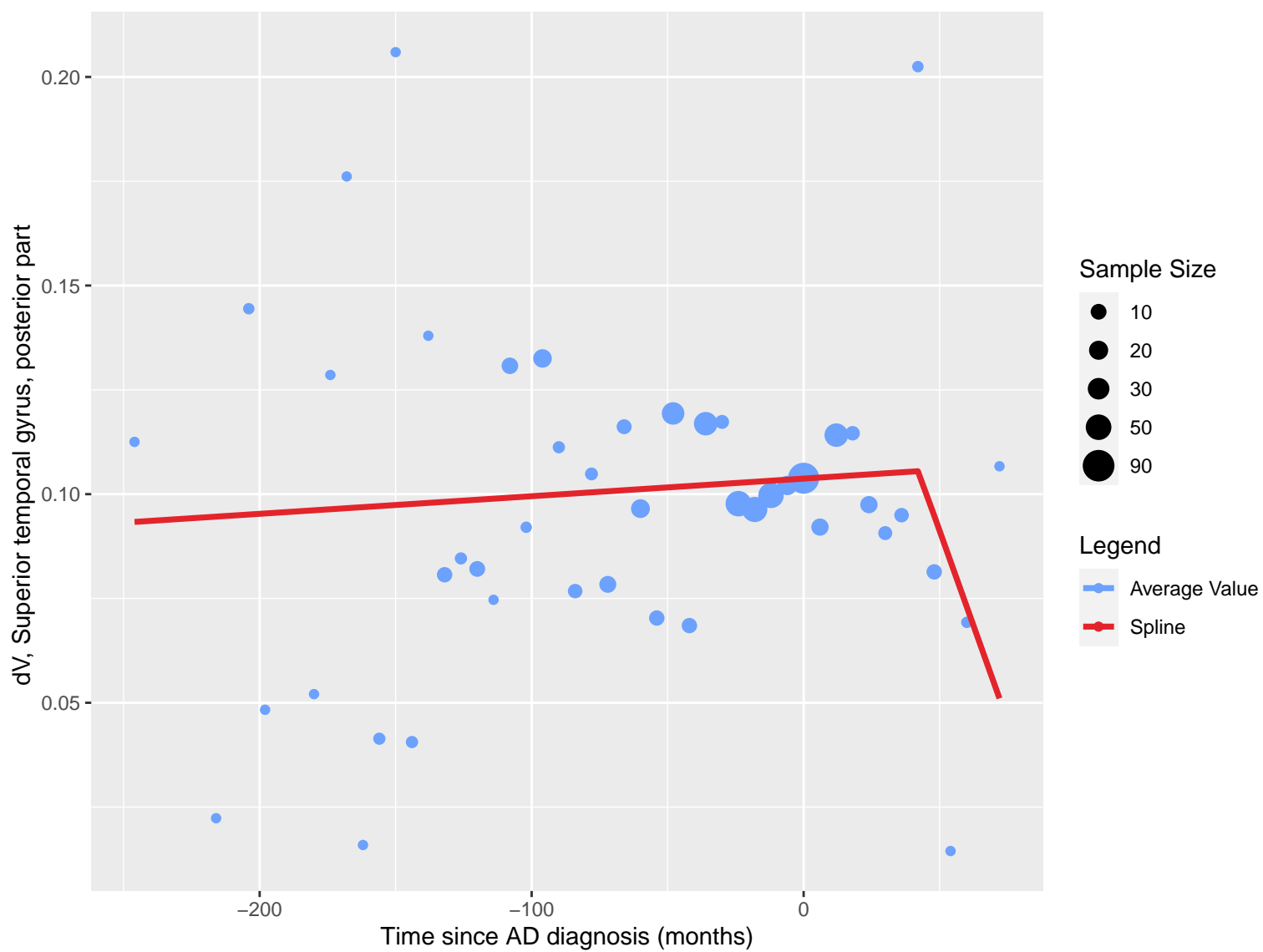


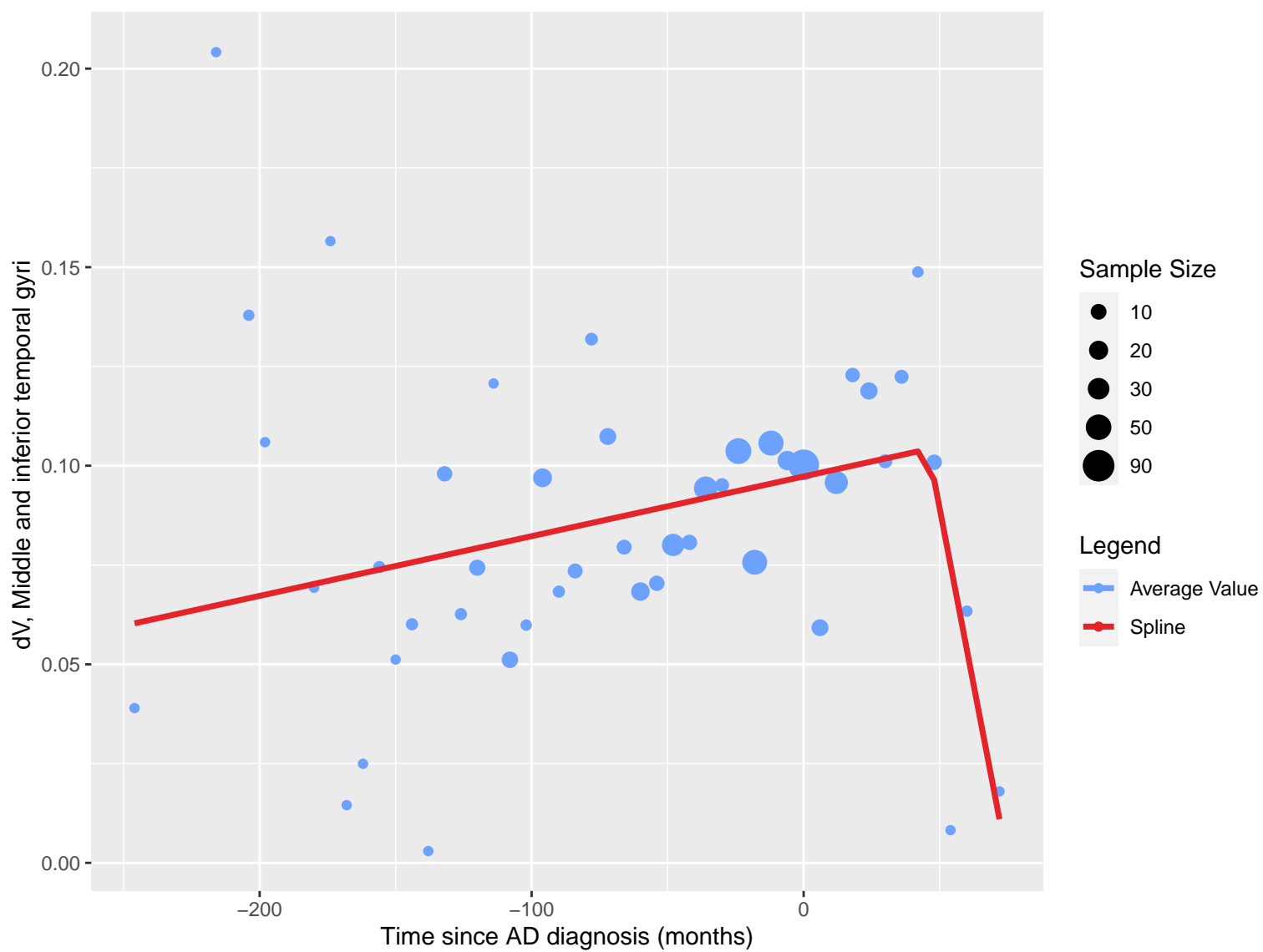
Legend

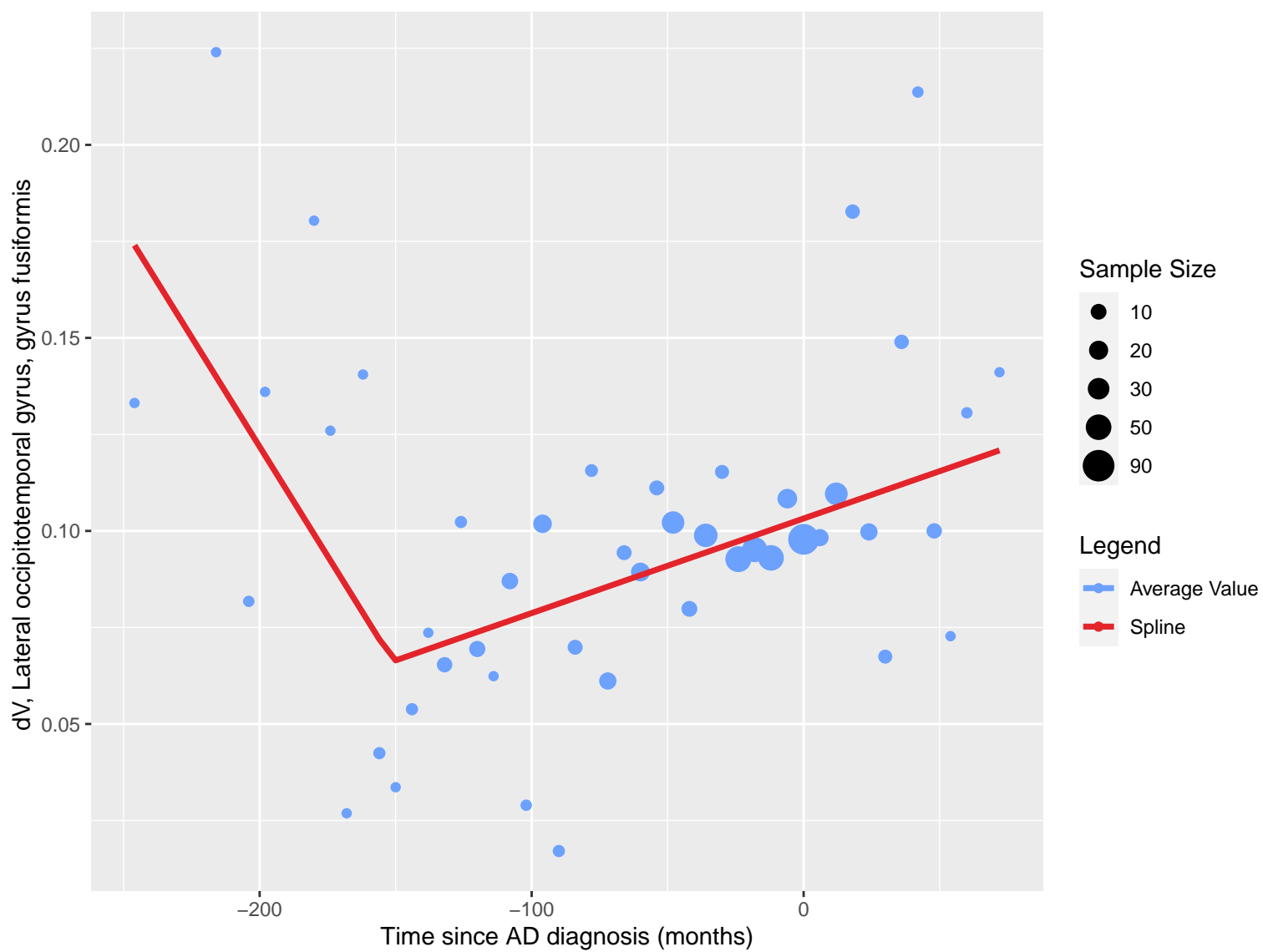


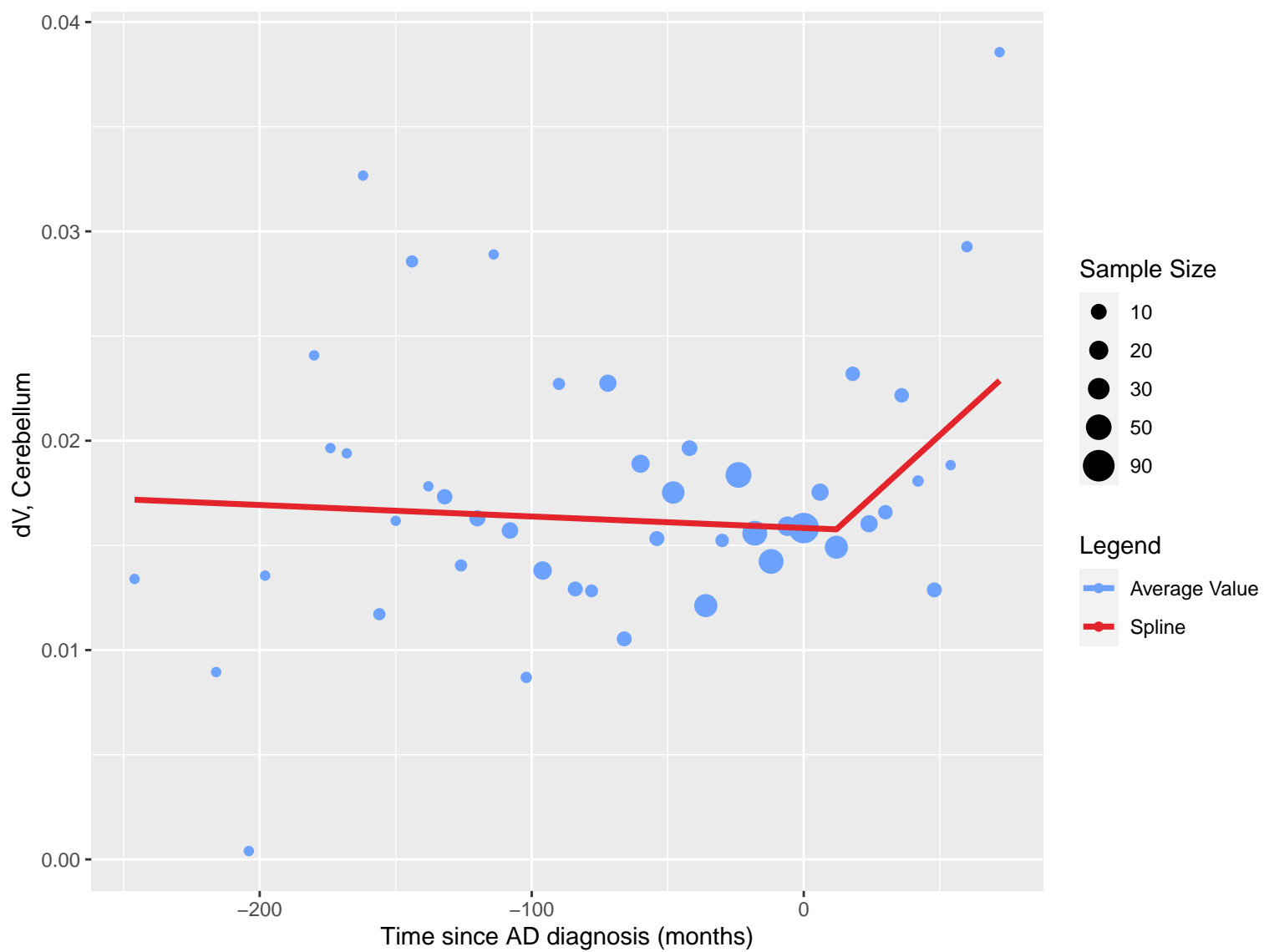


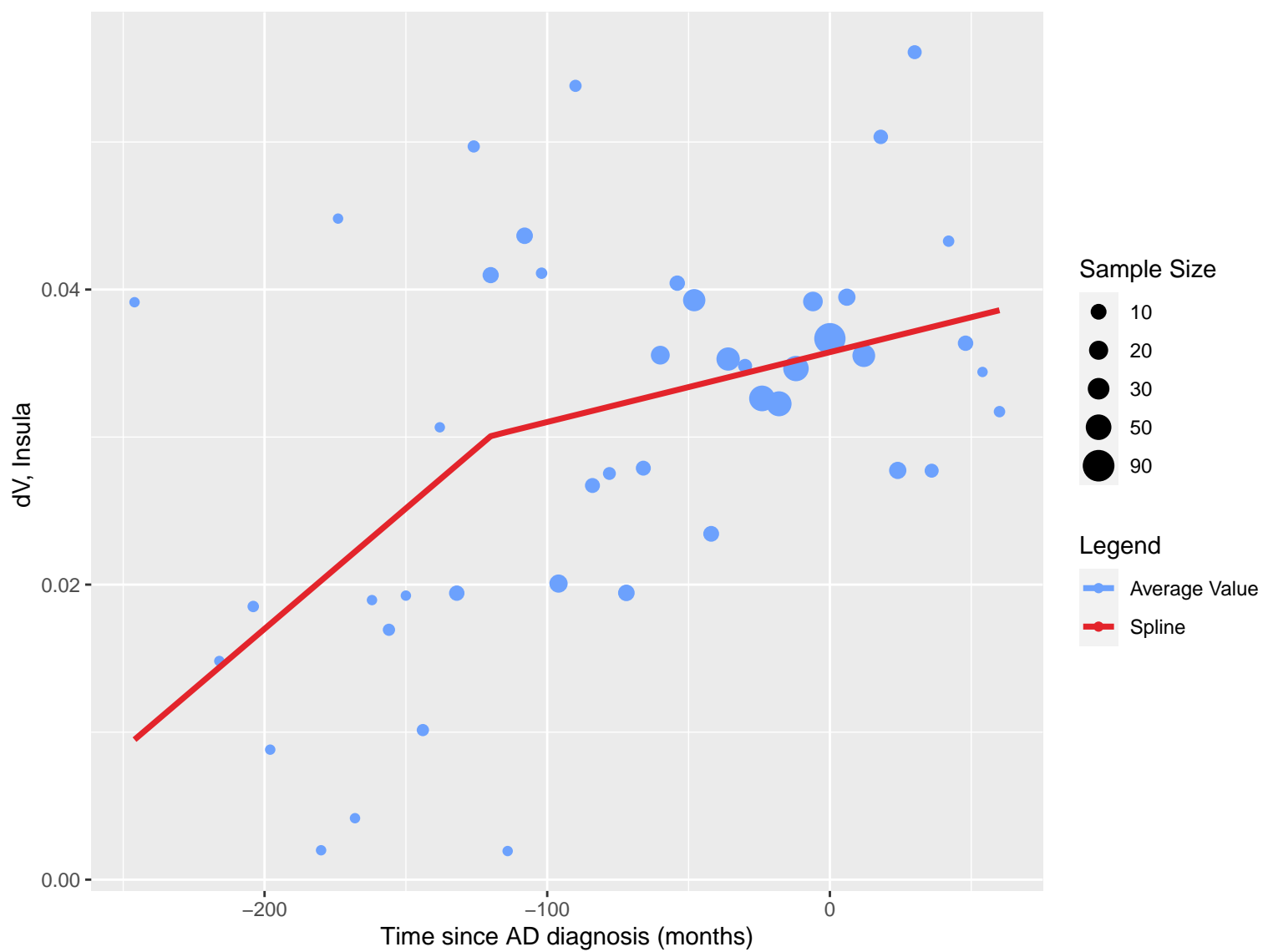




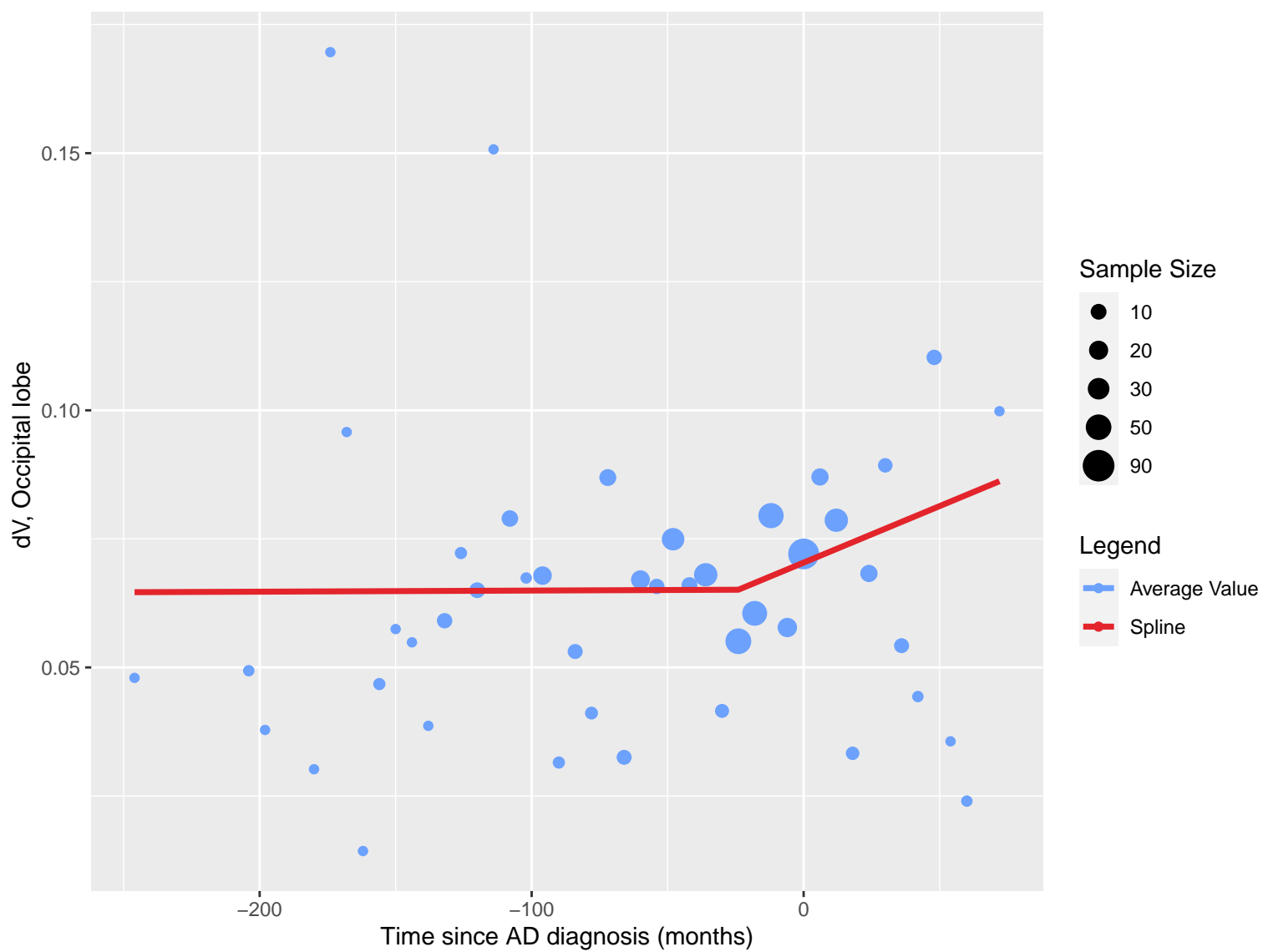


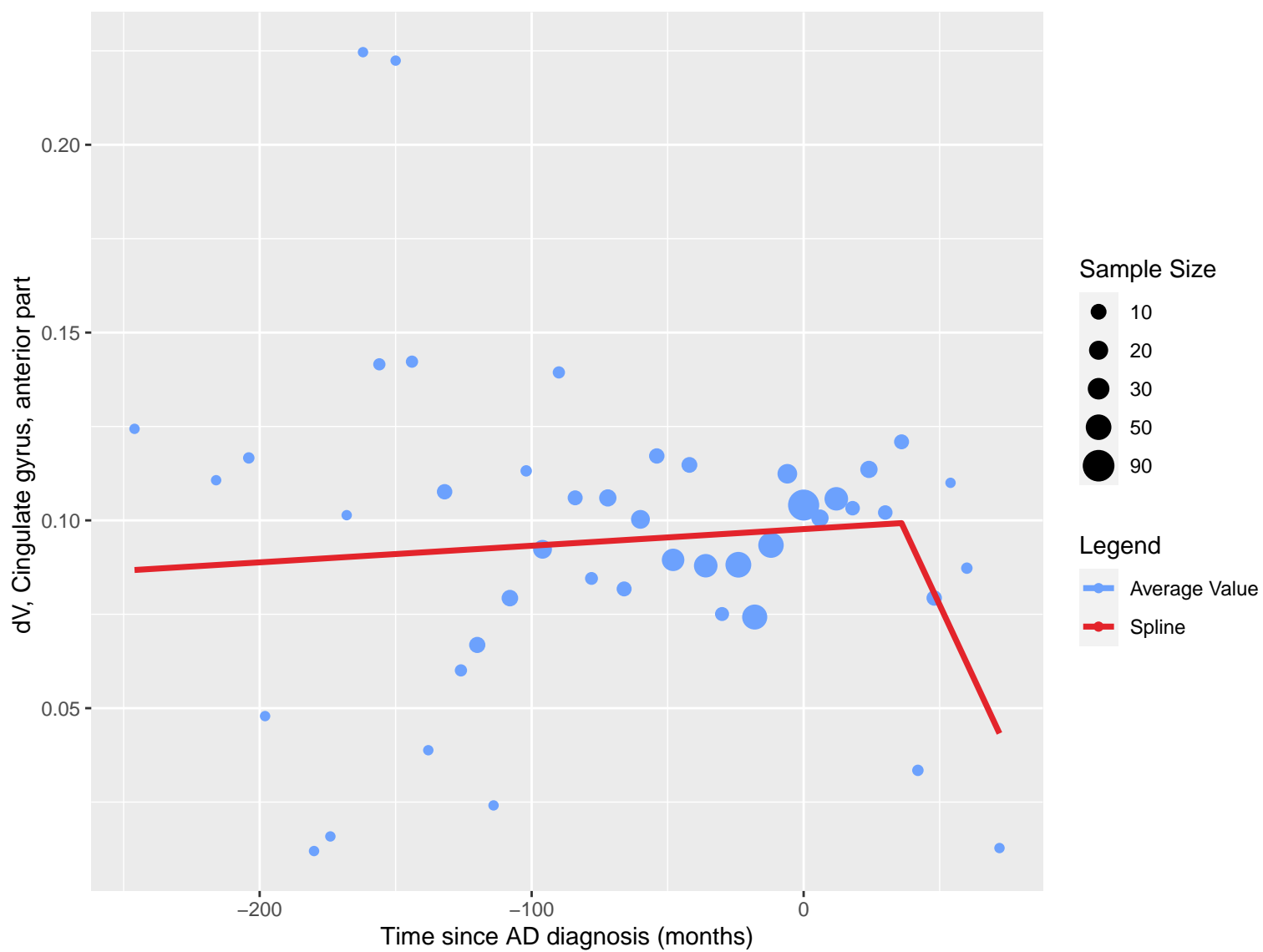


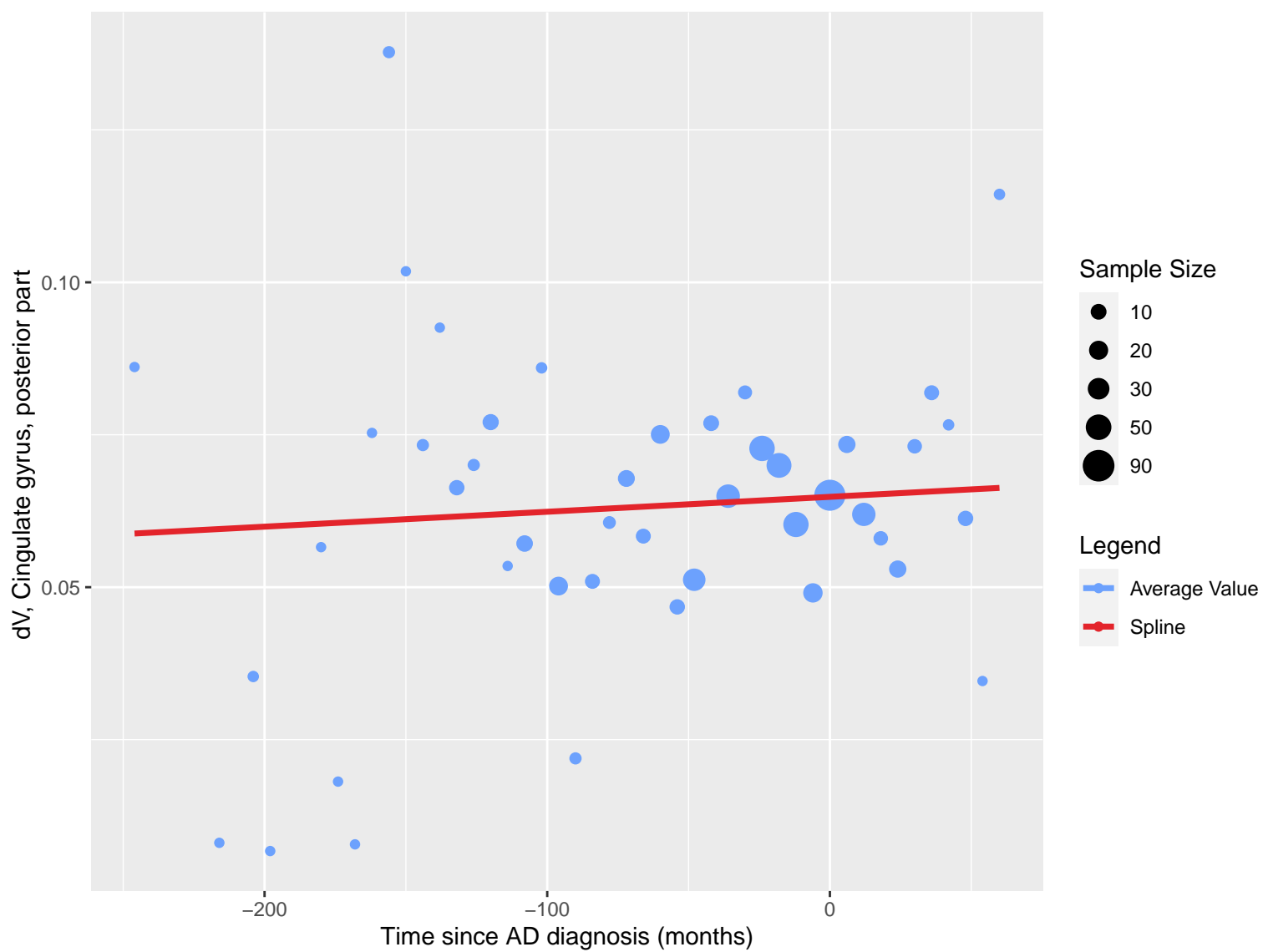


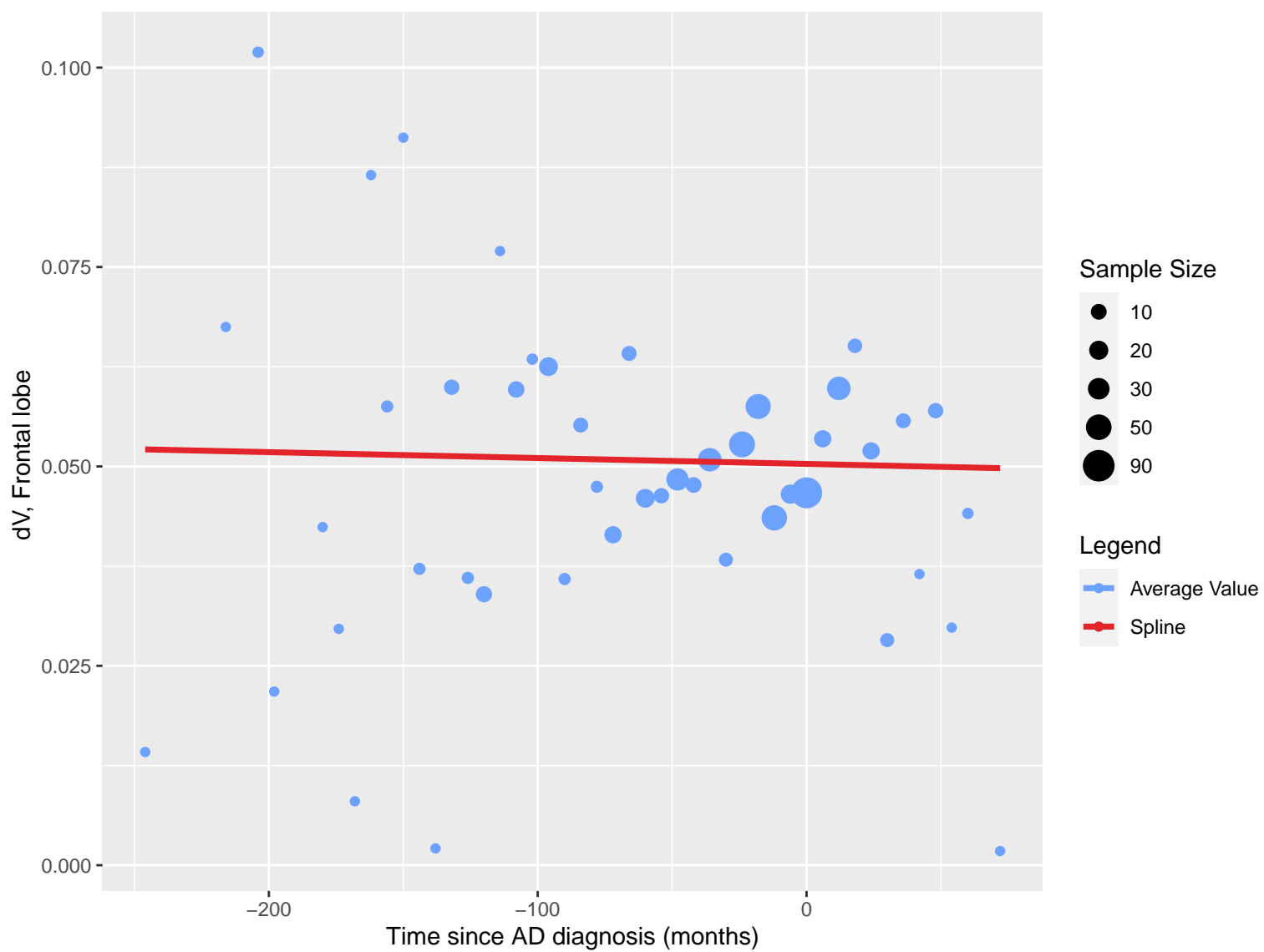


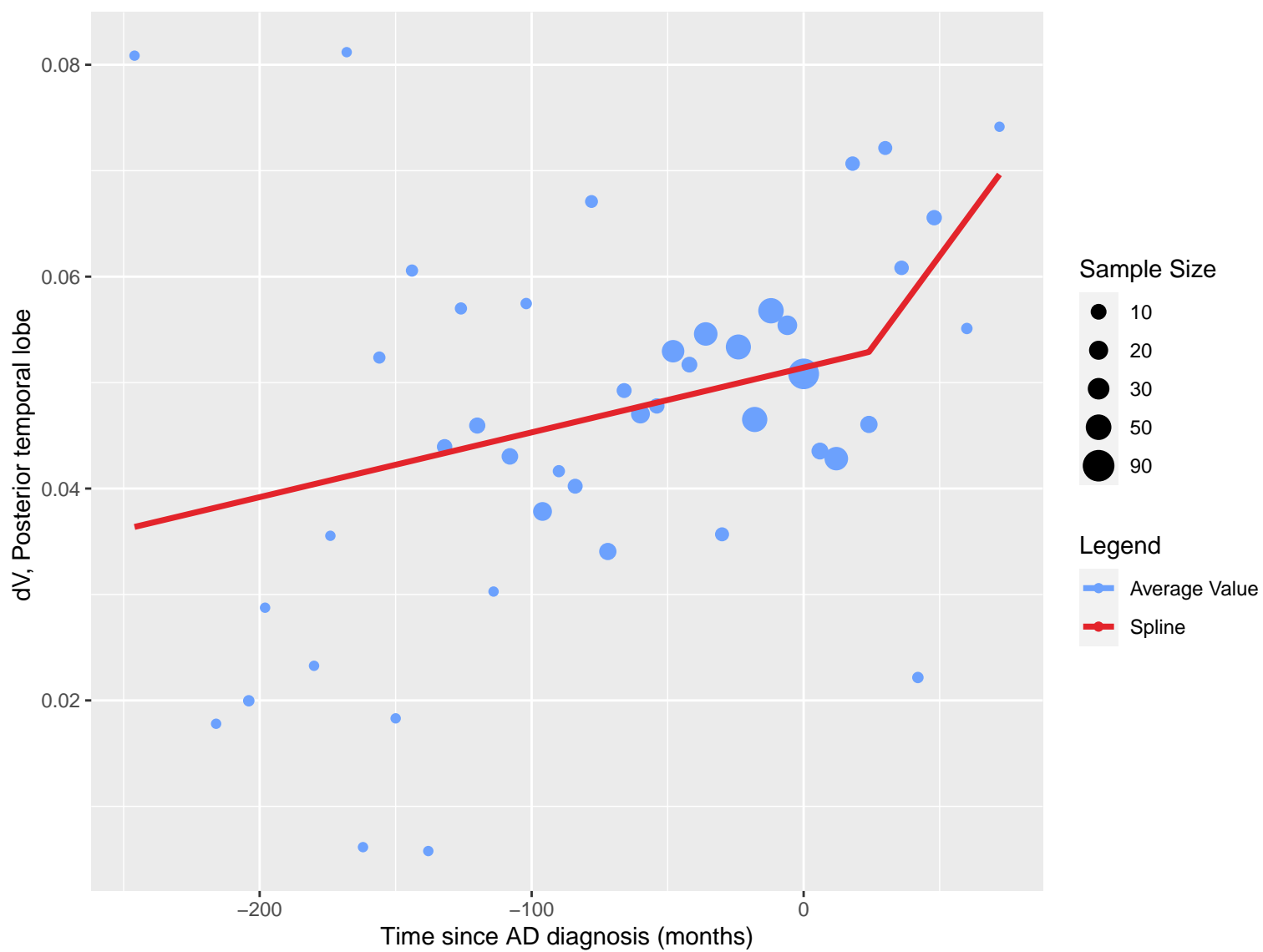


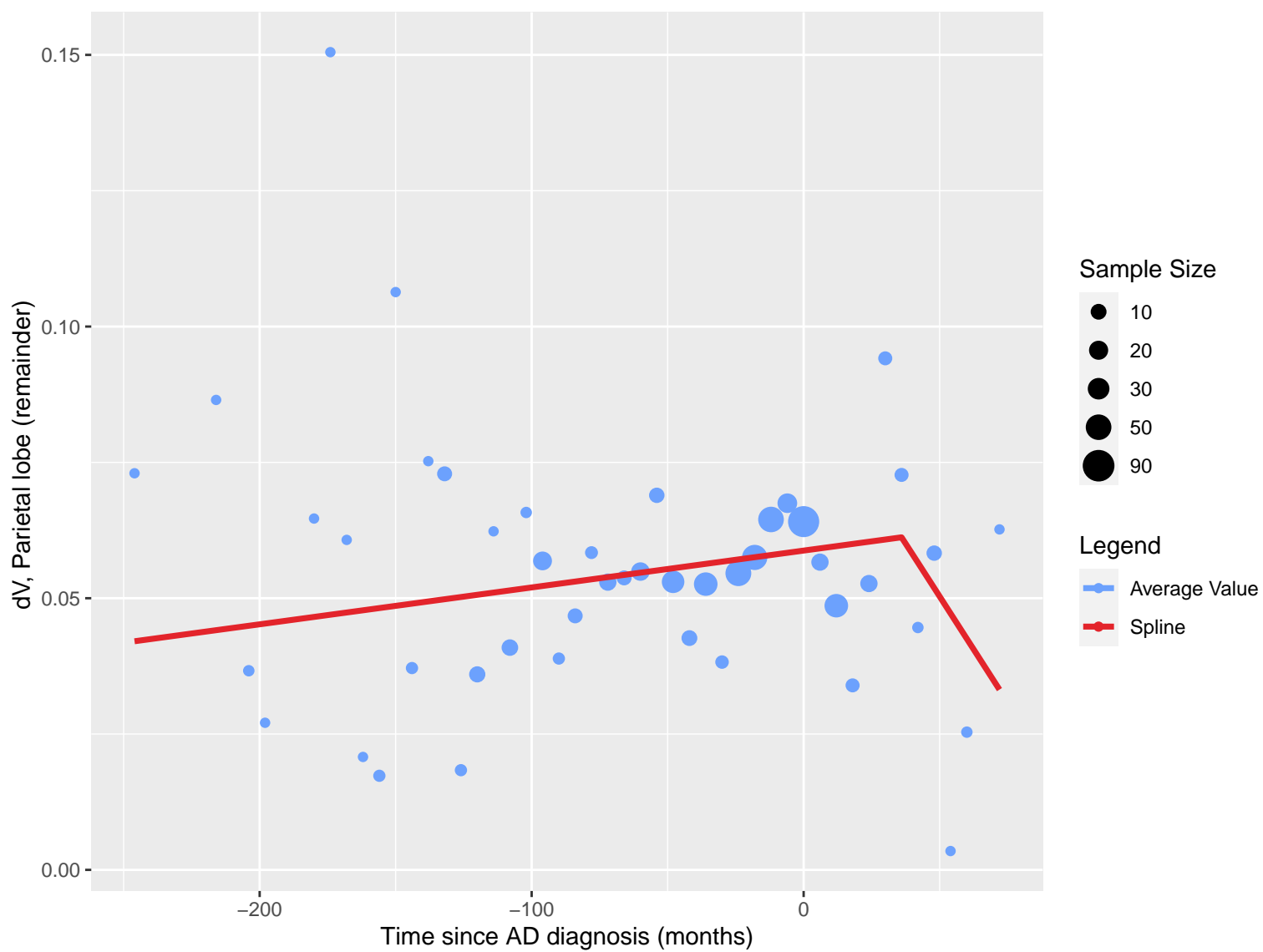


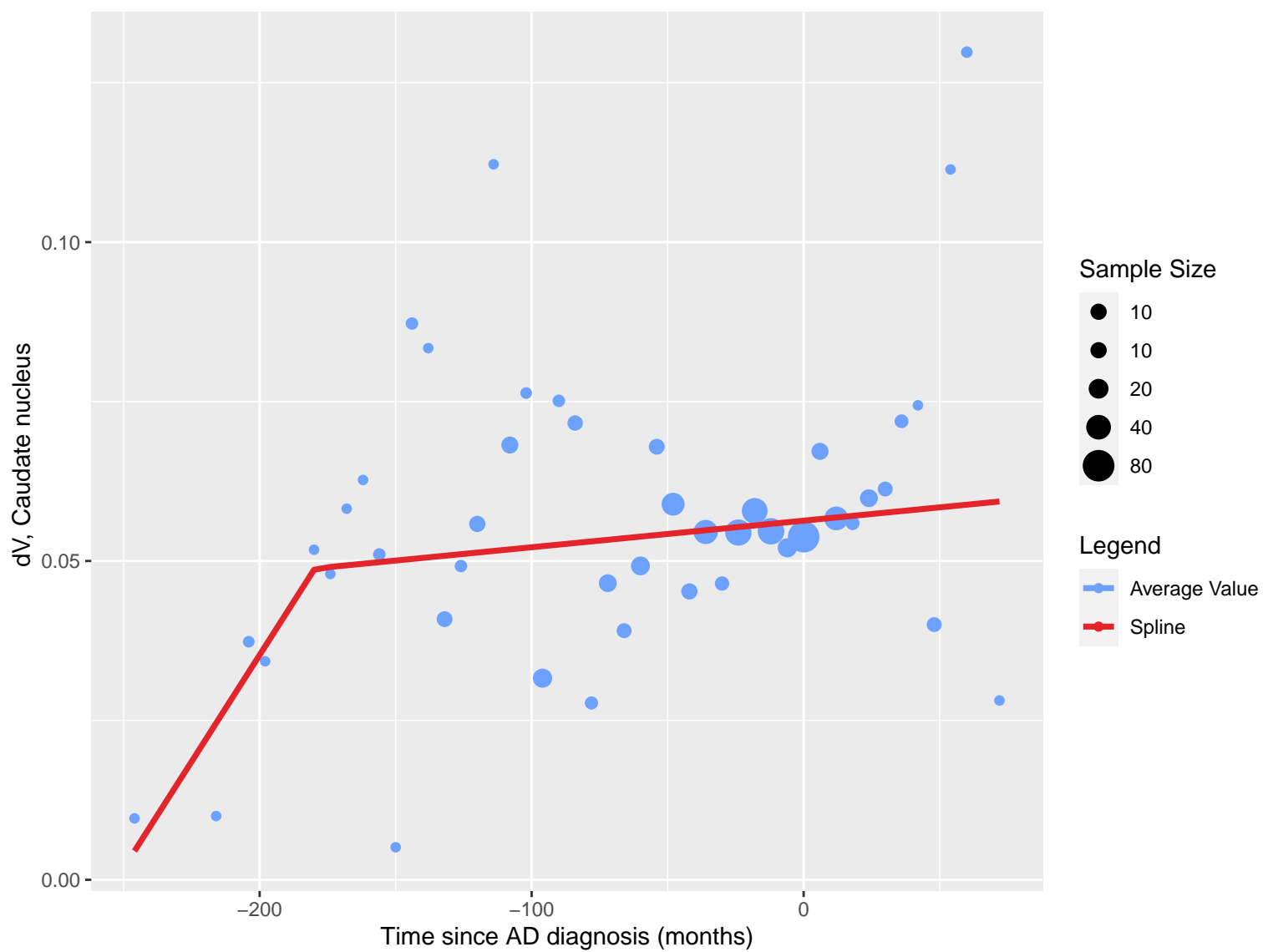


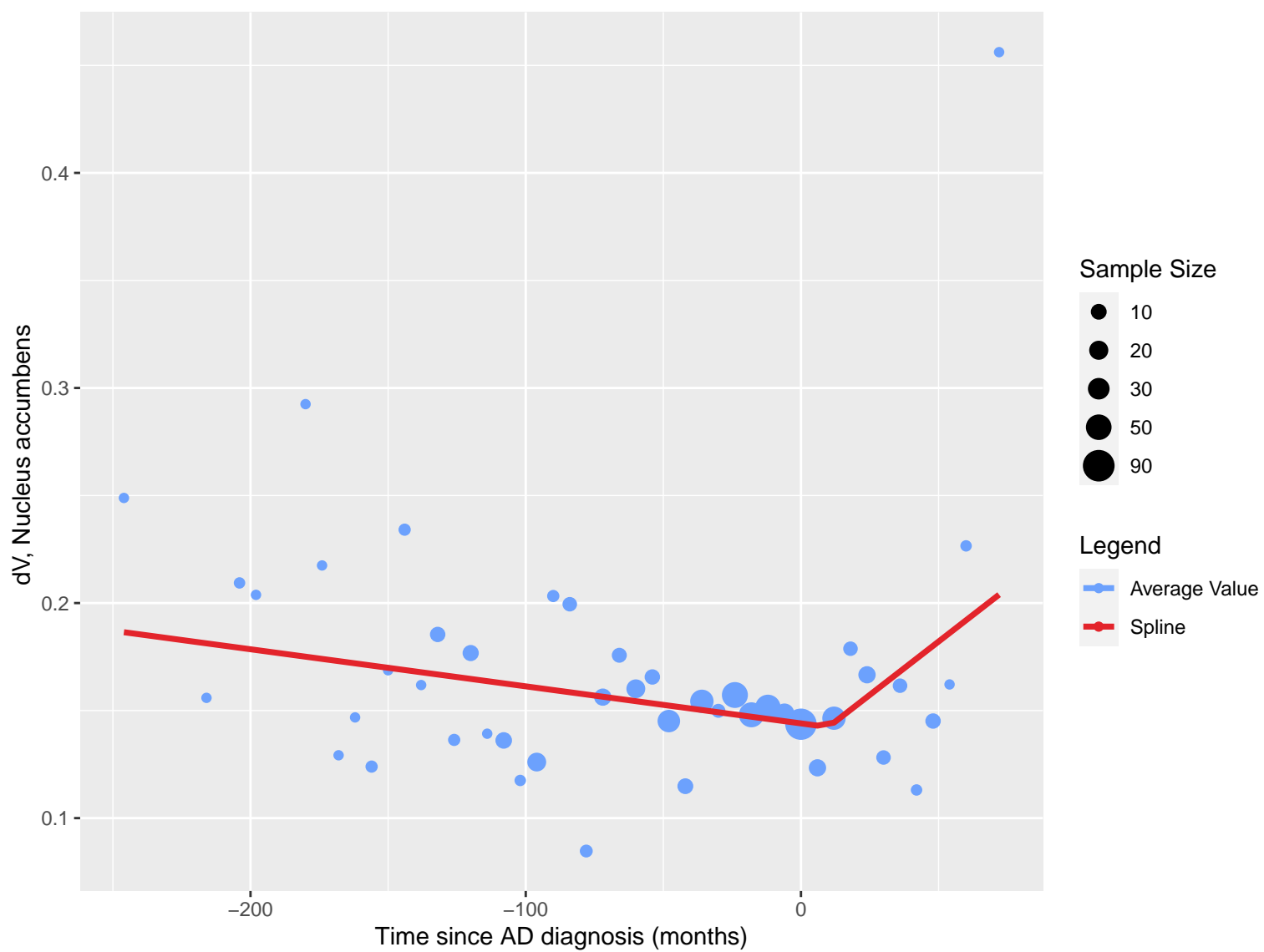




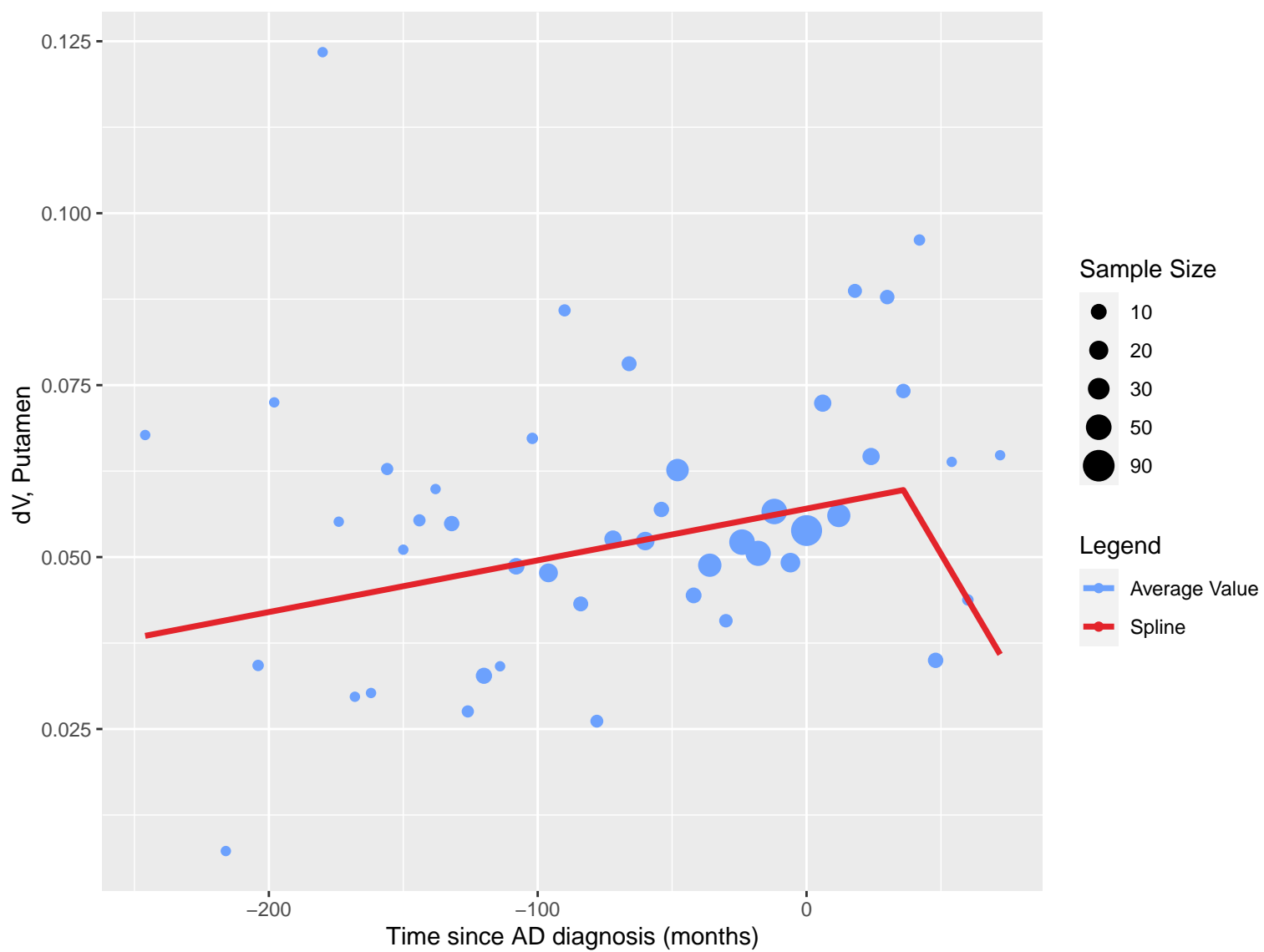


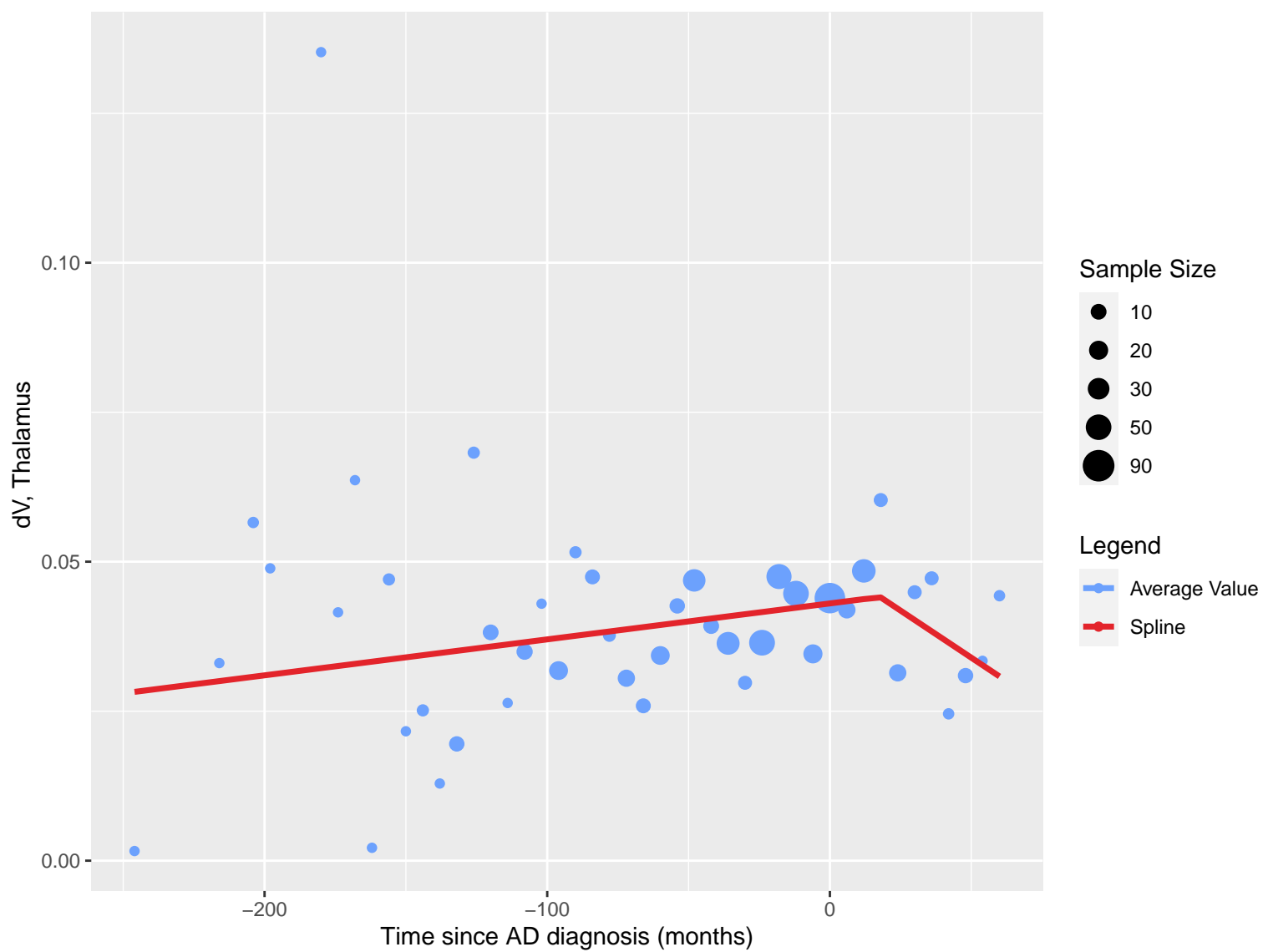


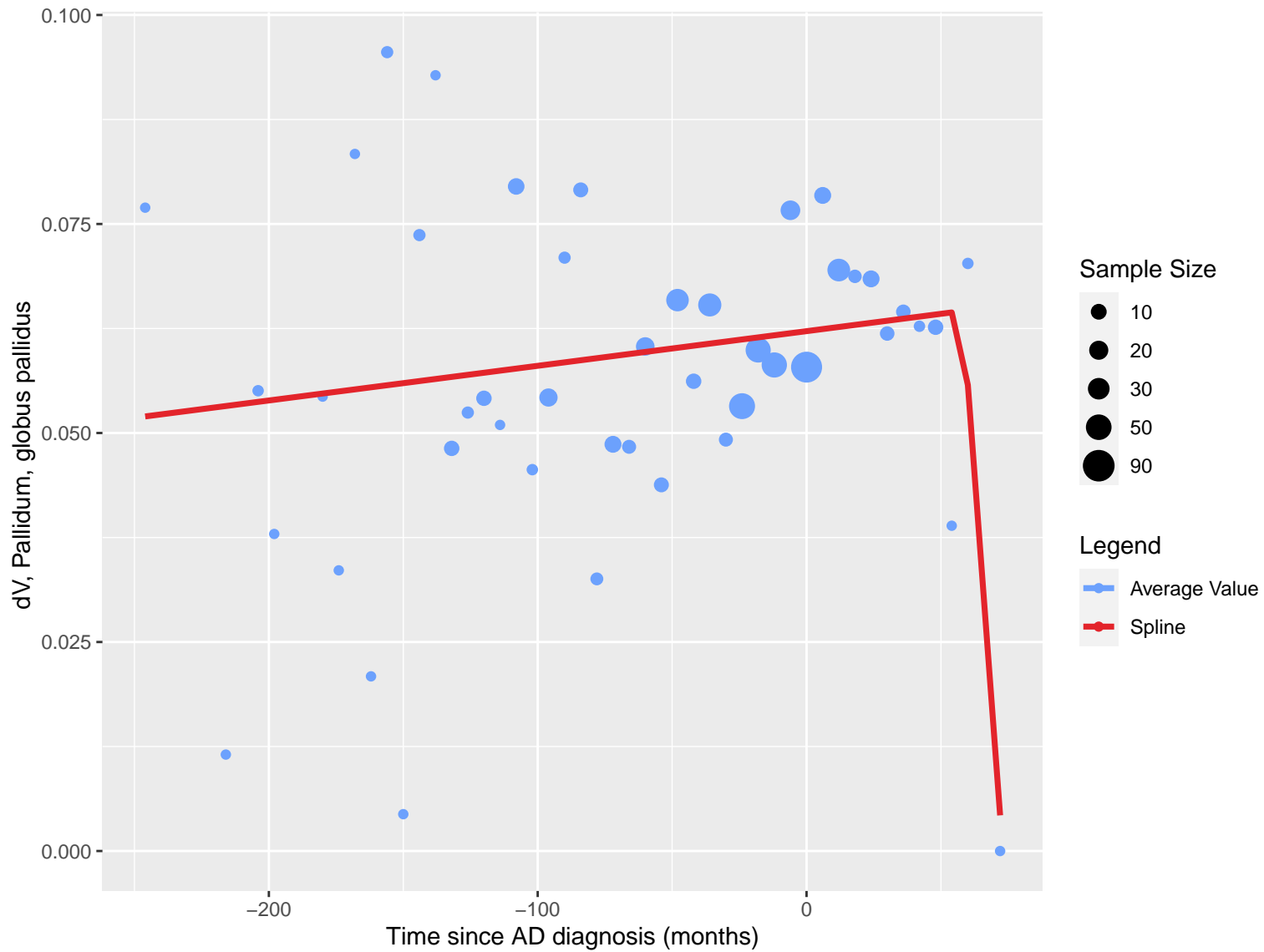


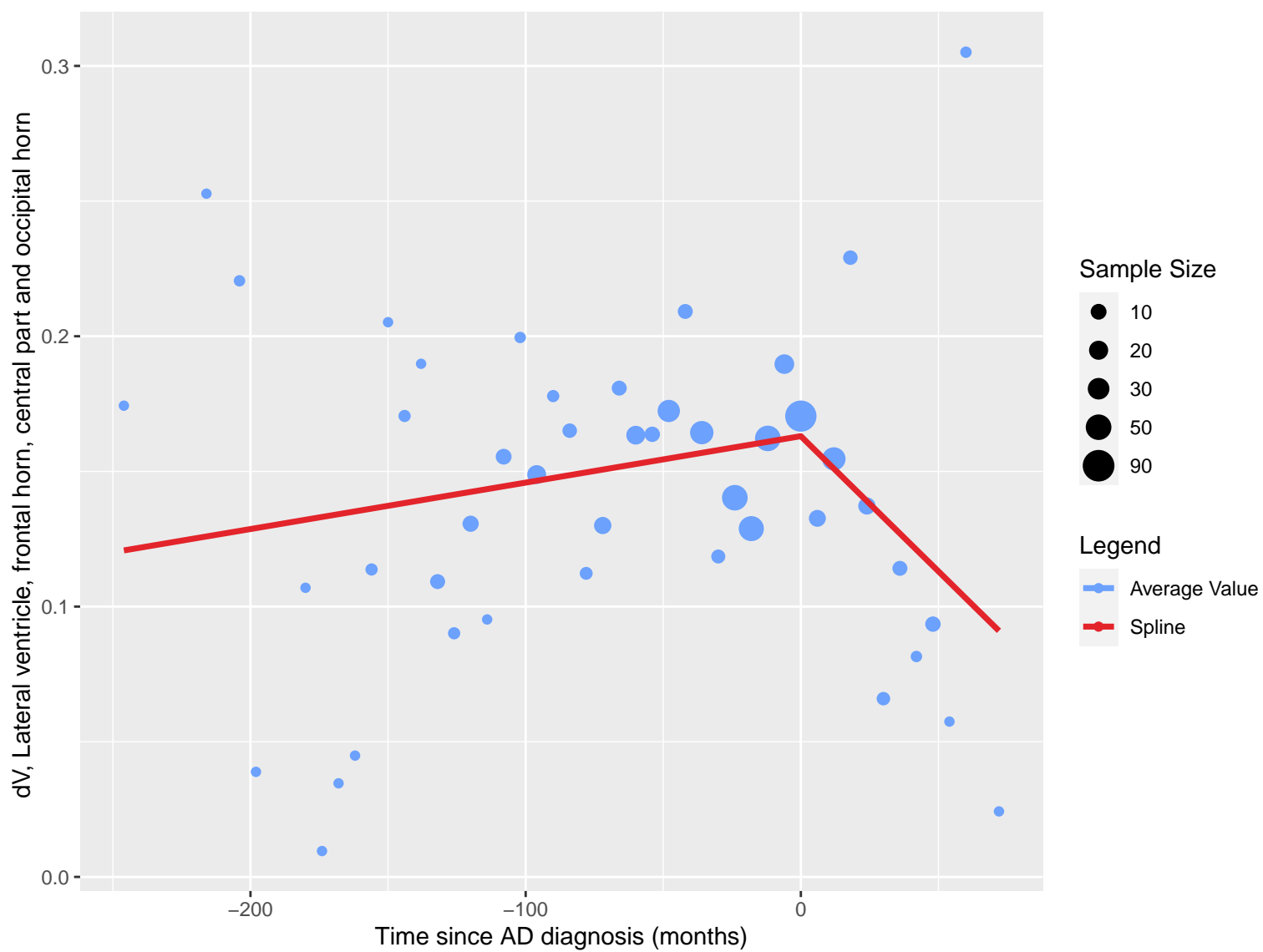


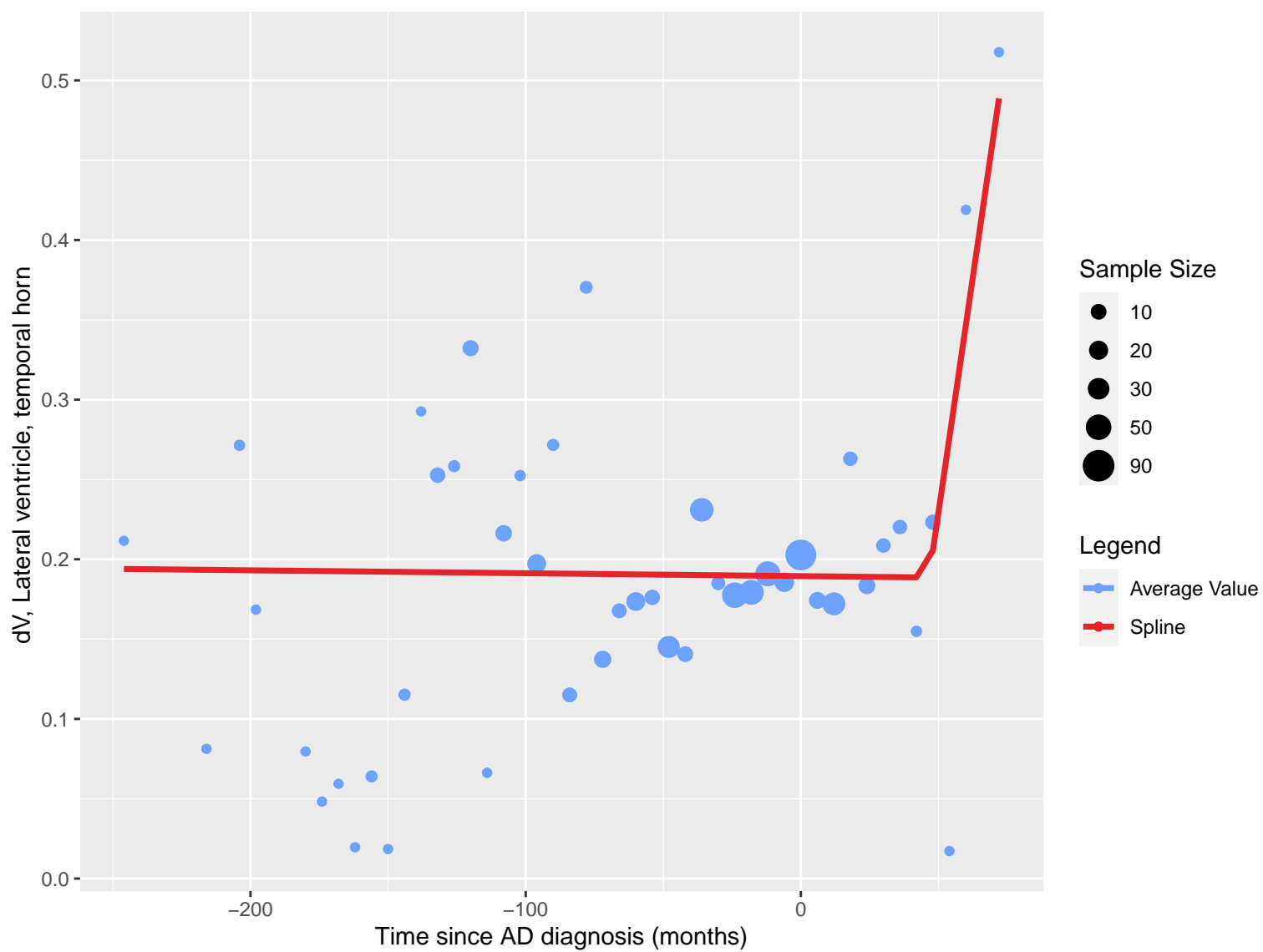


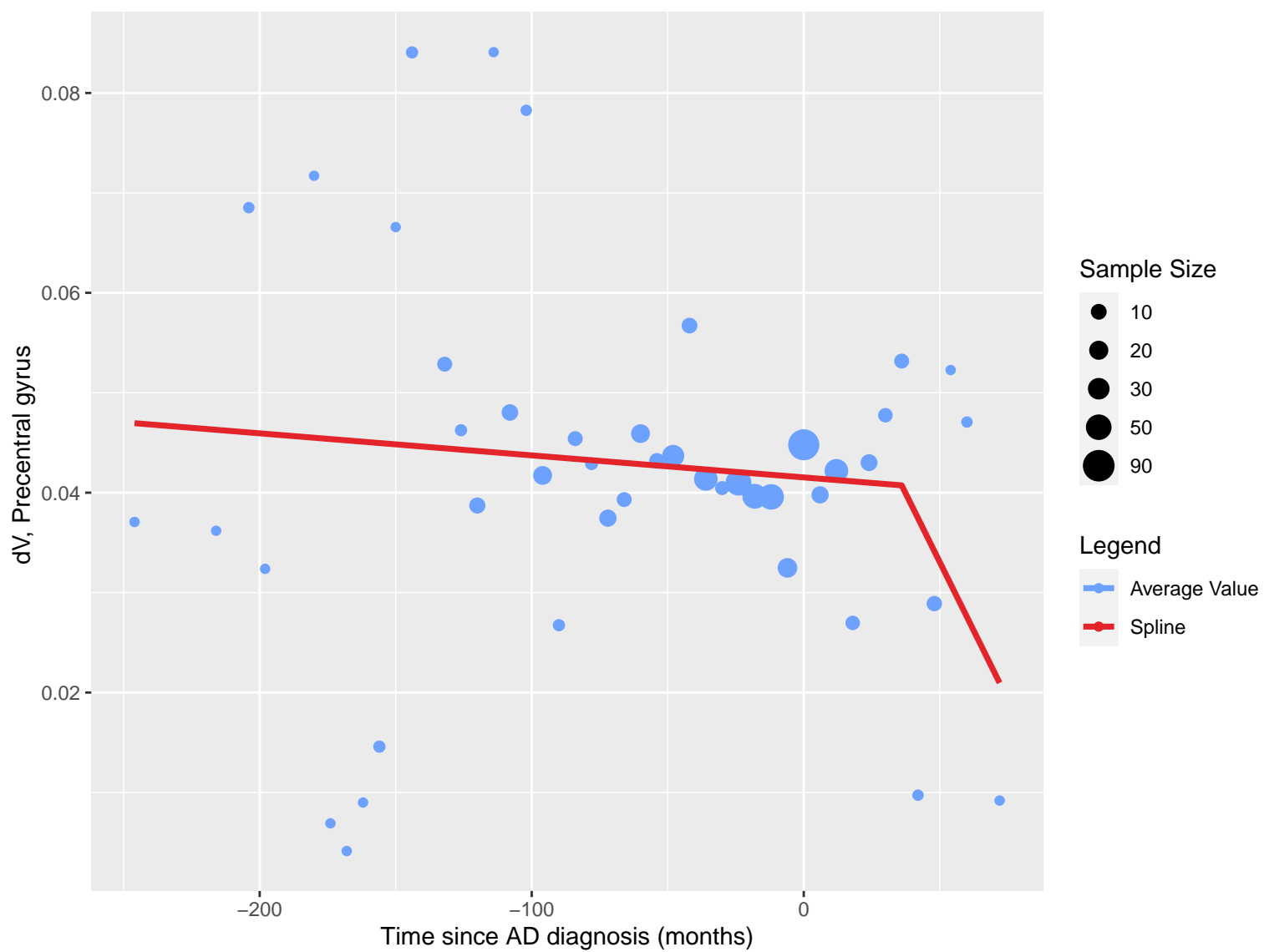


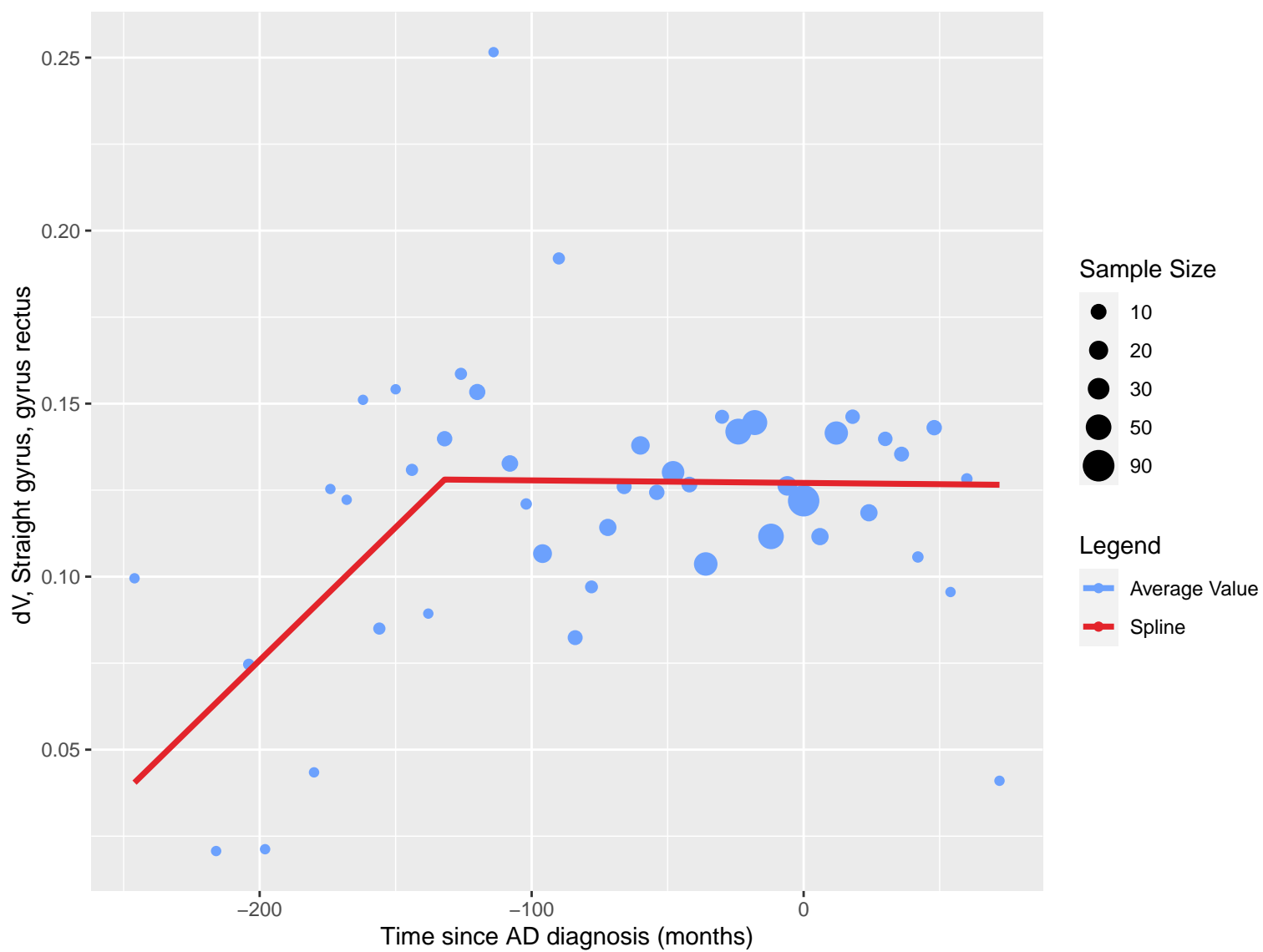


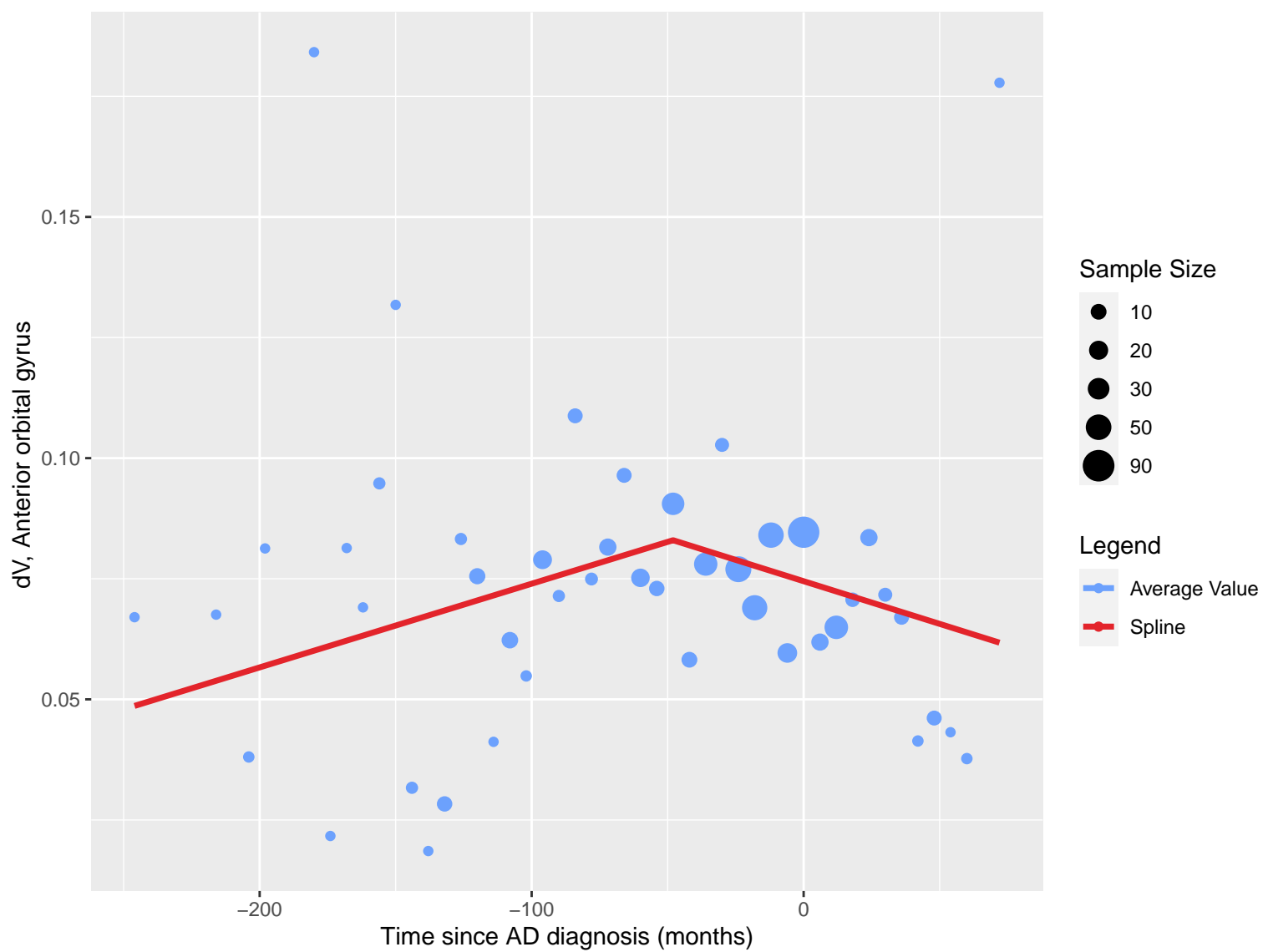




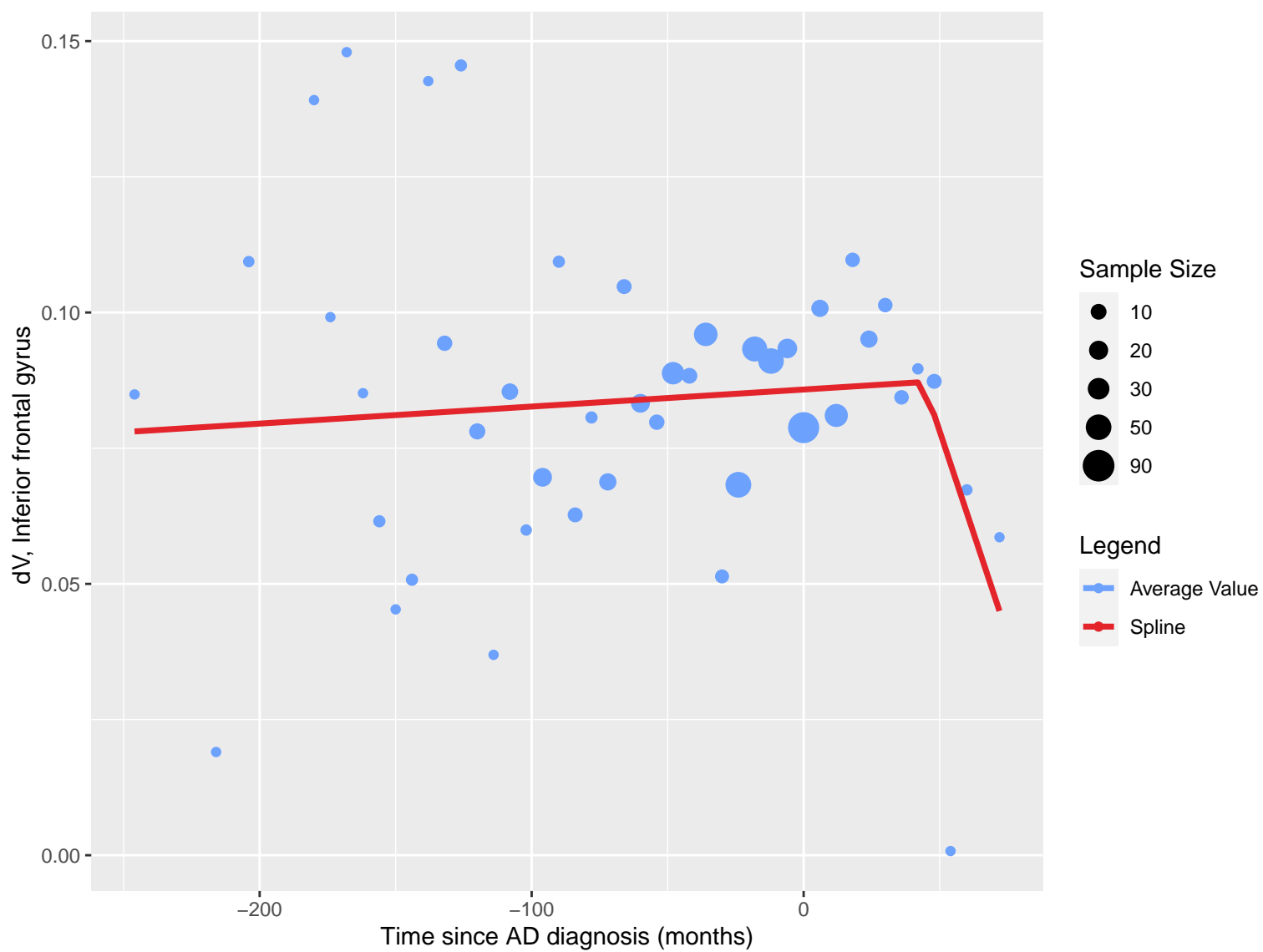


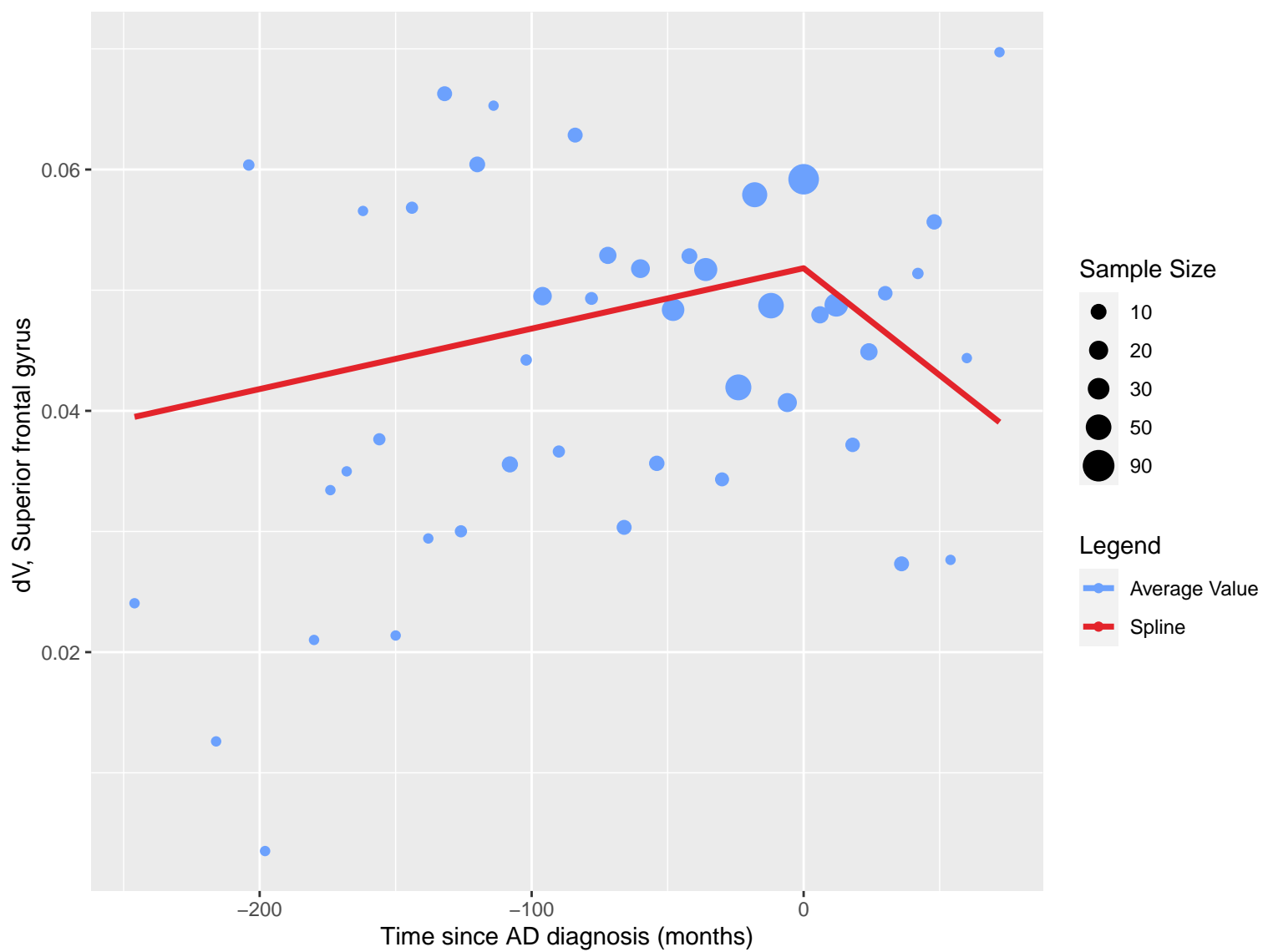


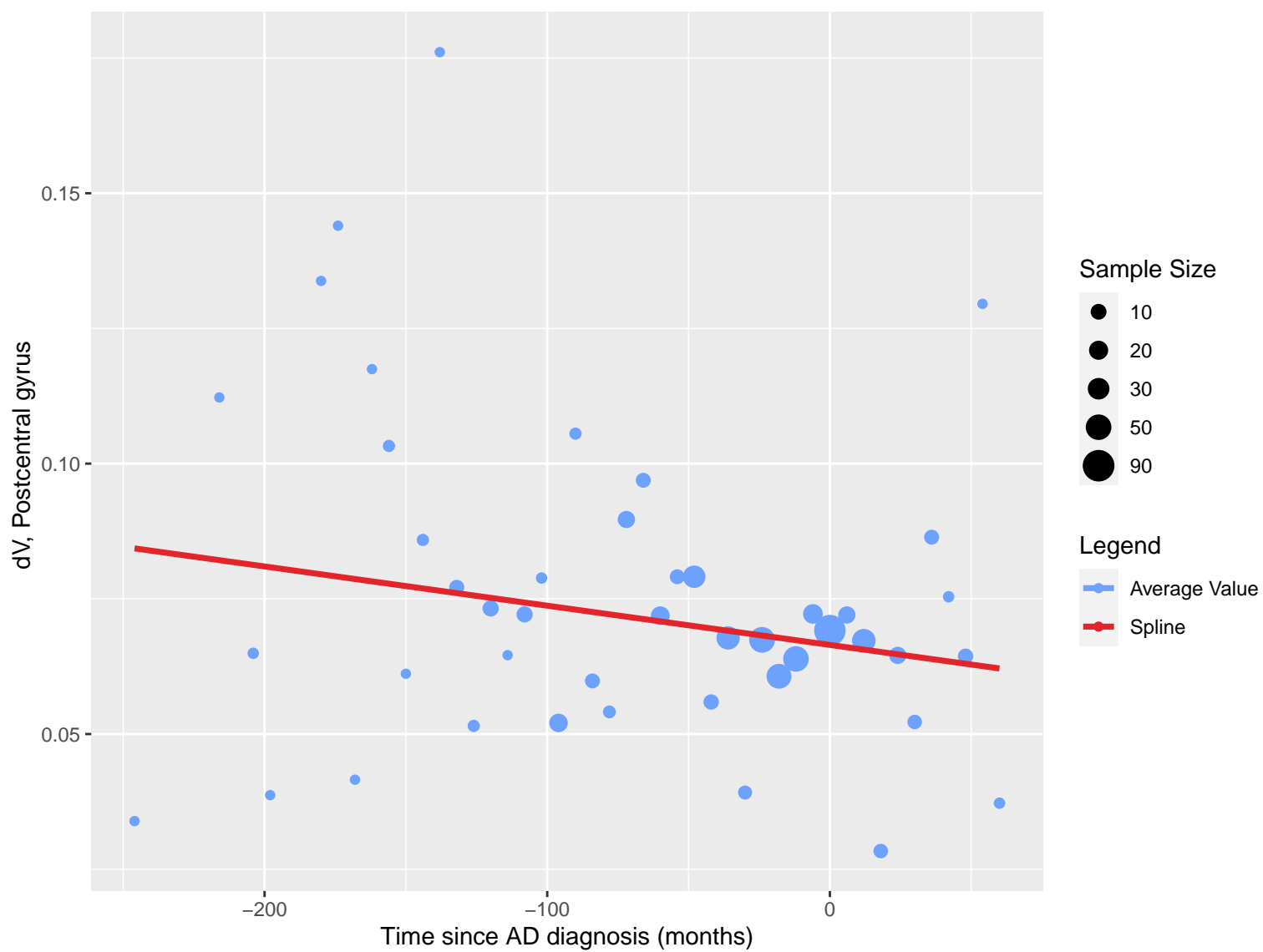


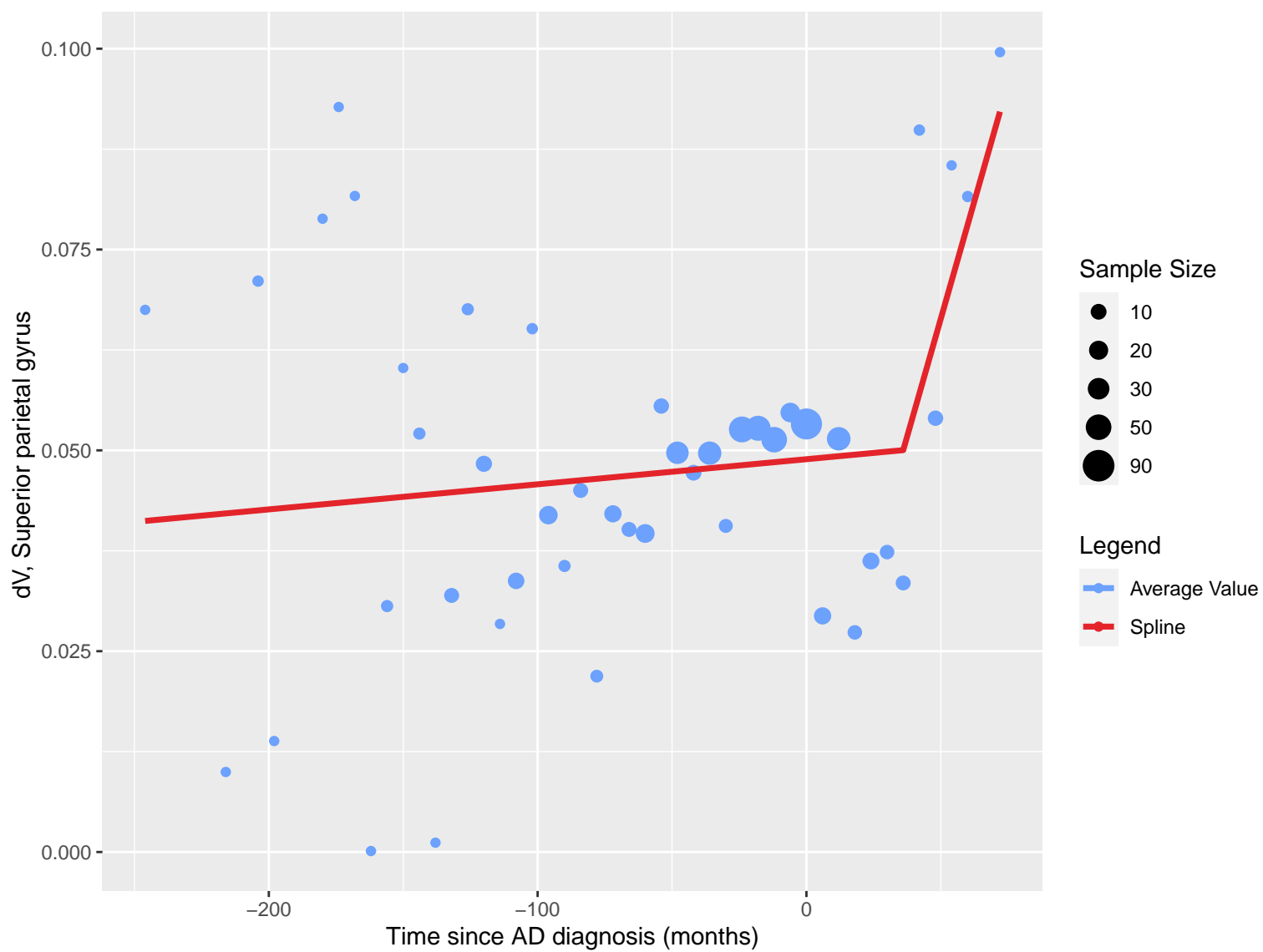


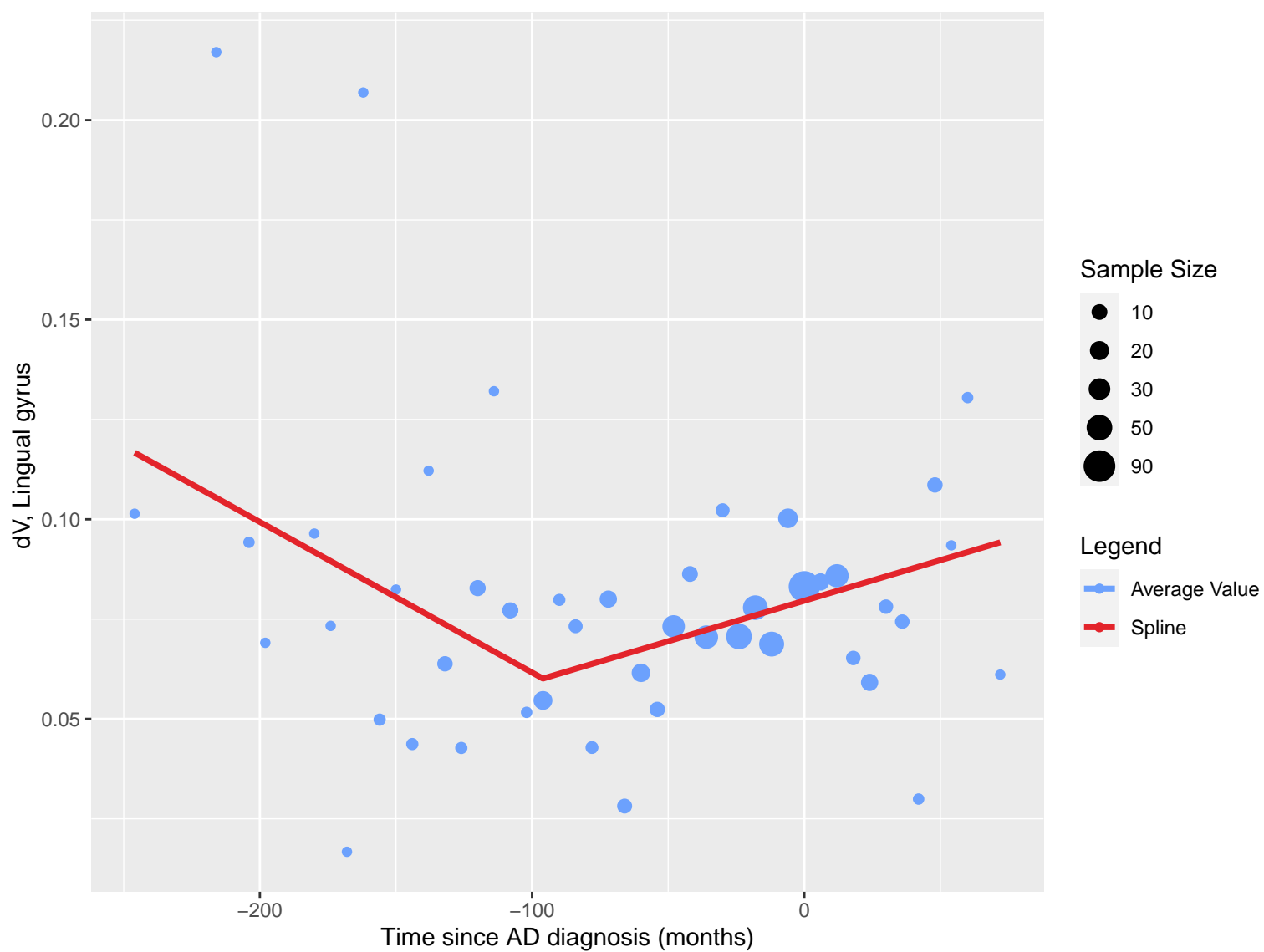


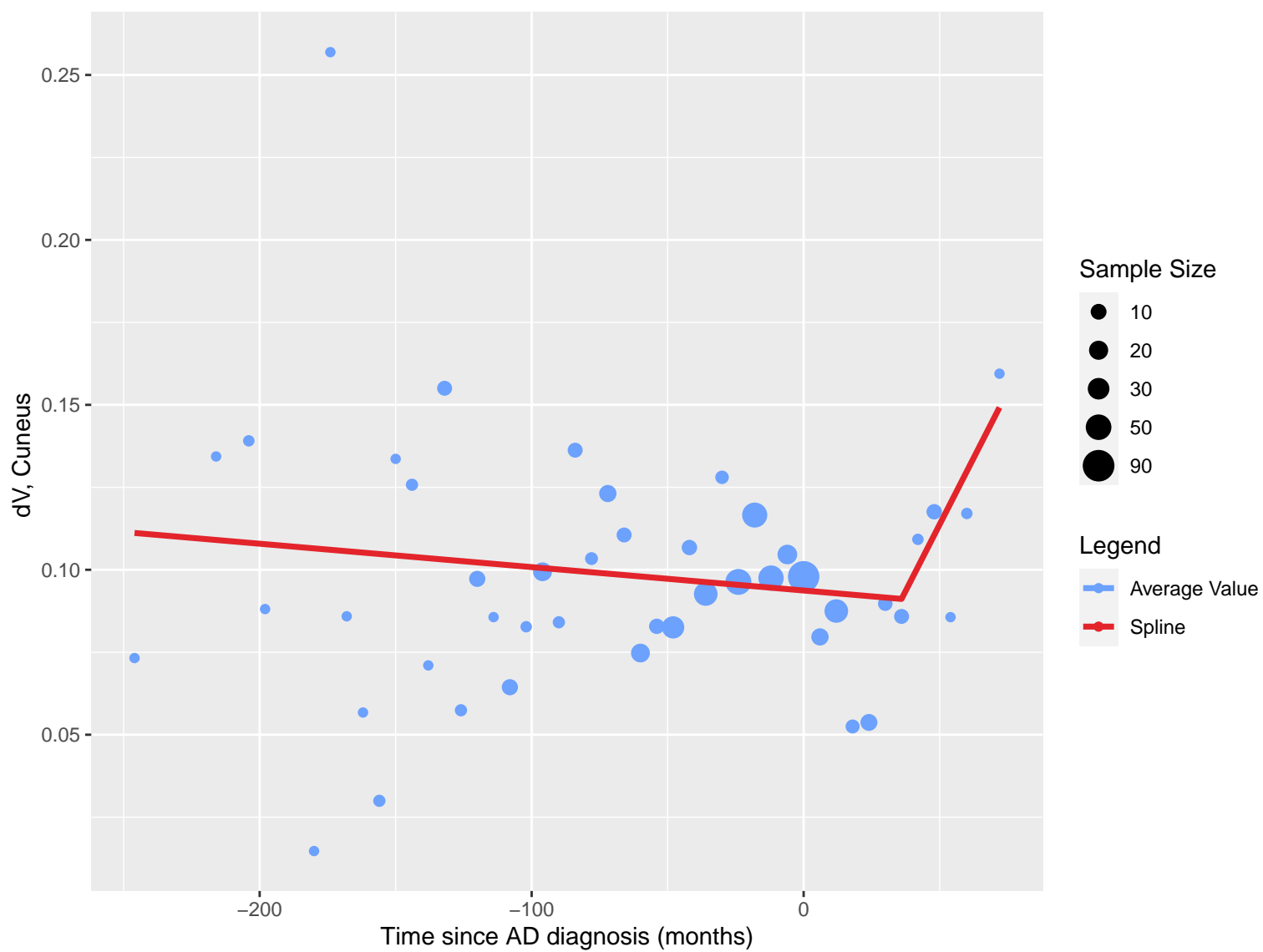


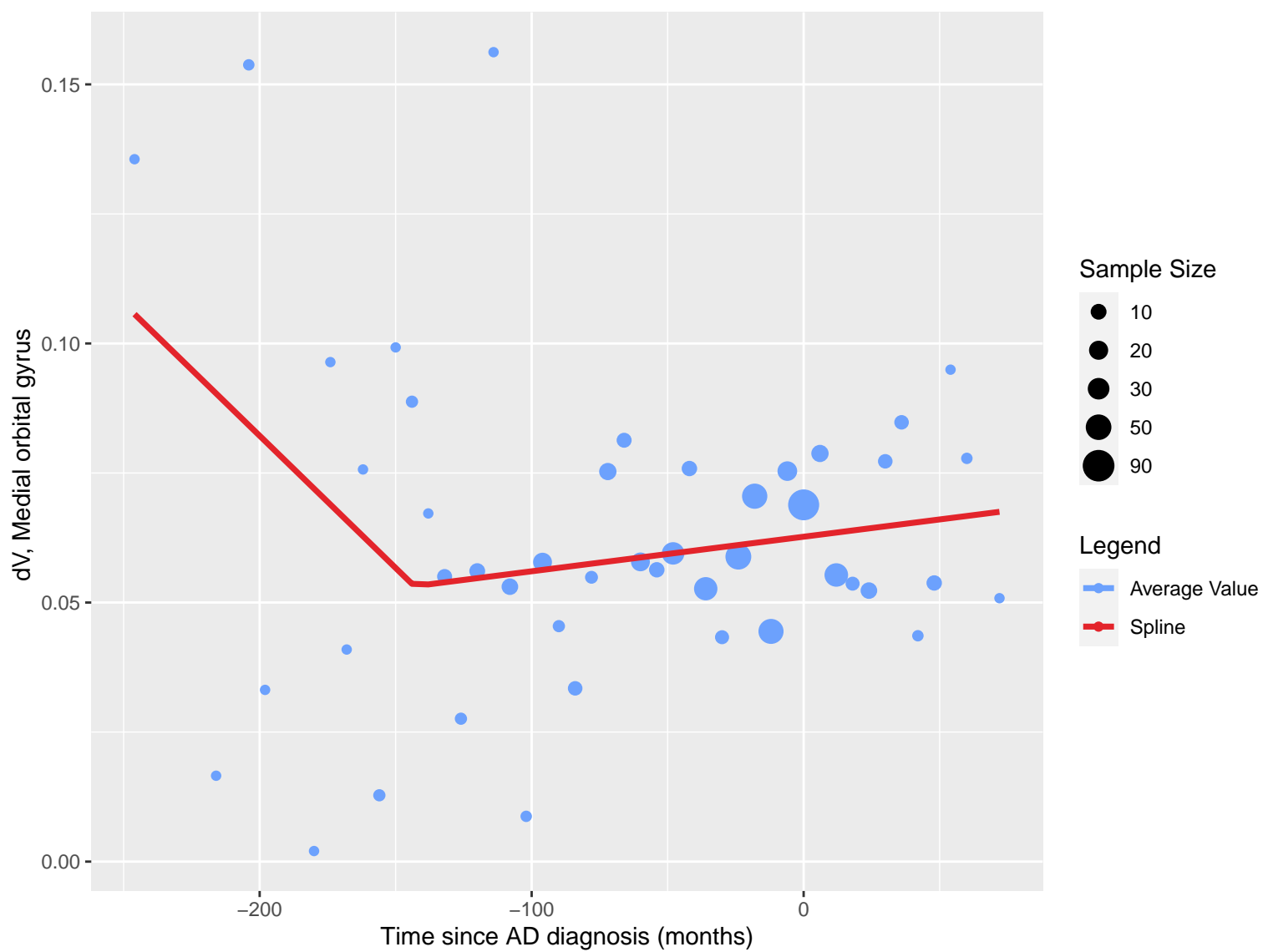


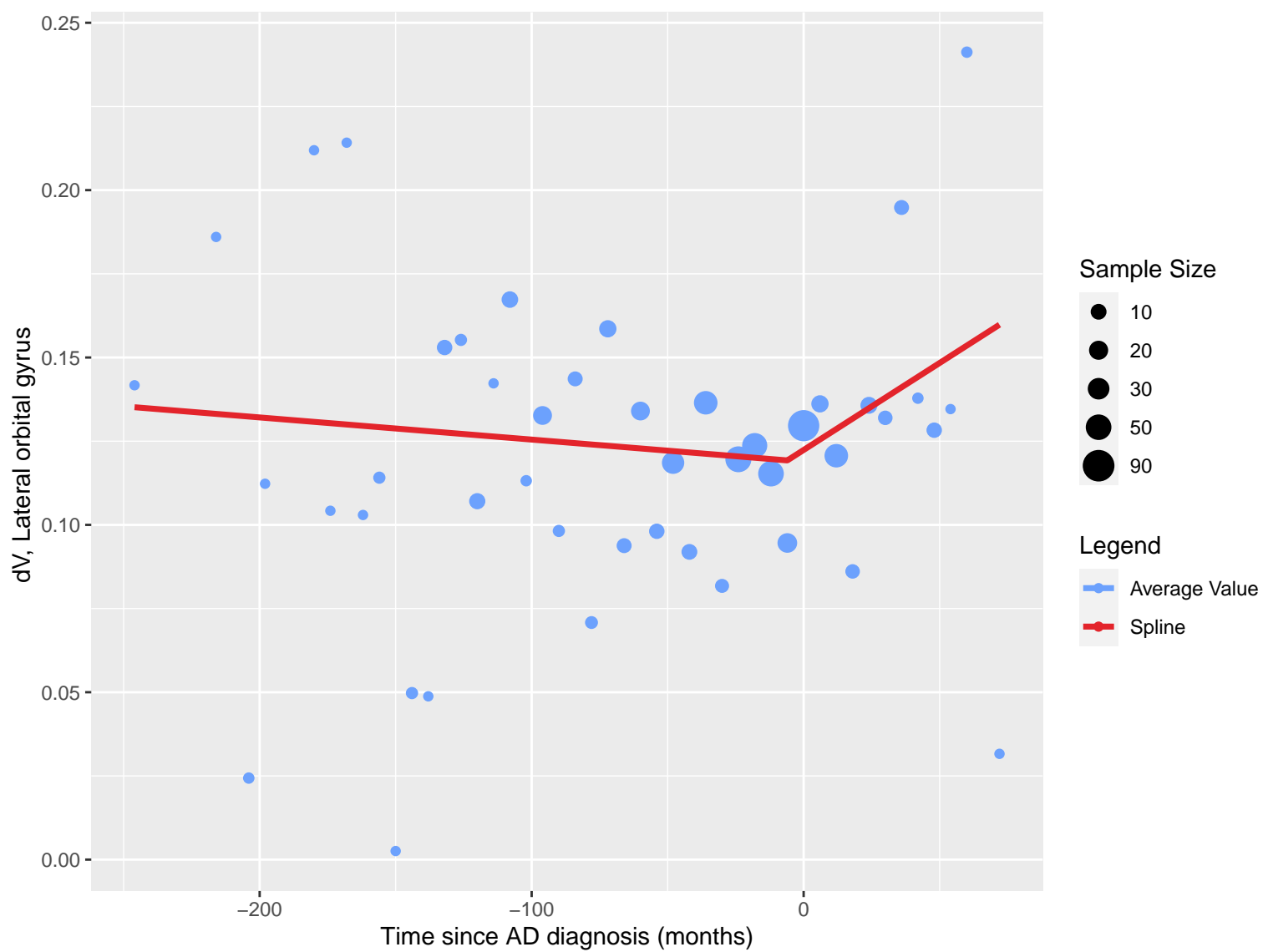




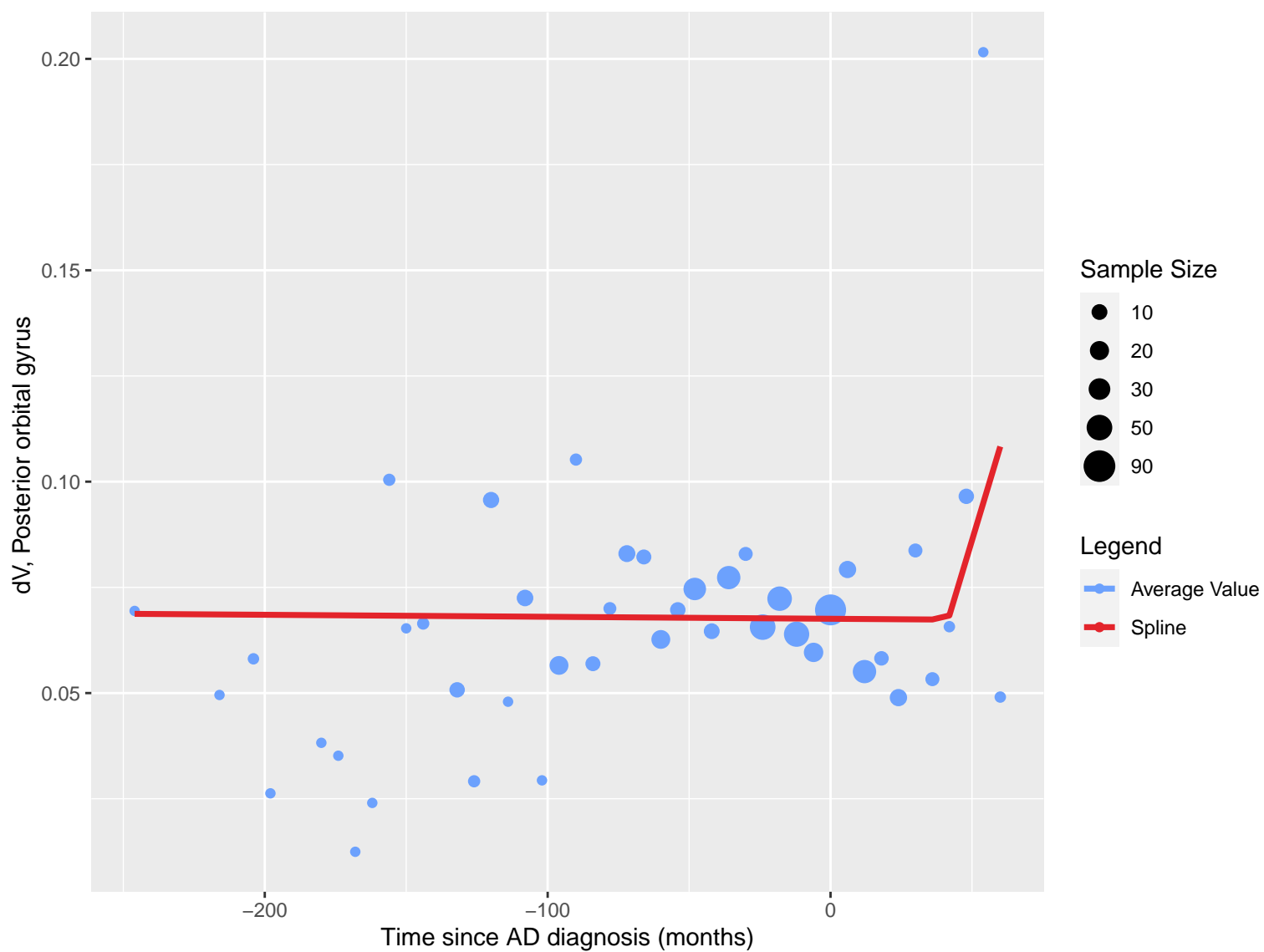


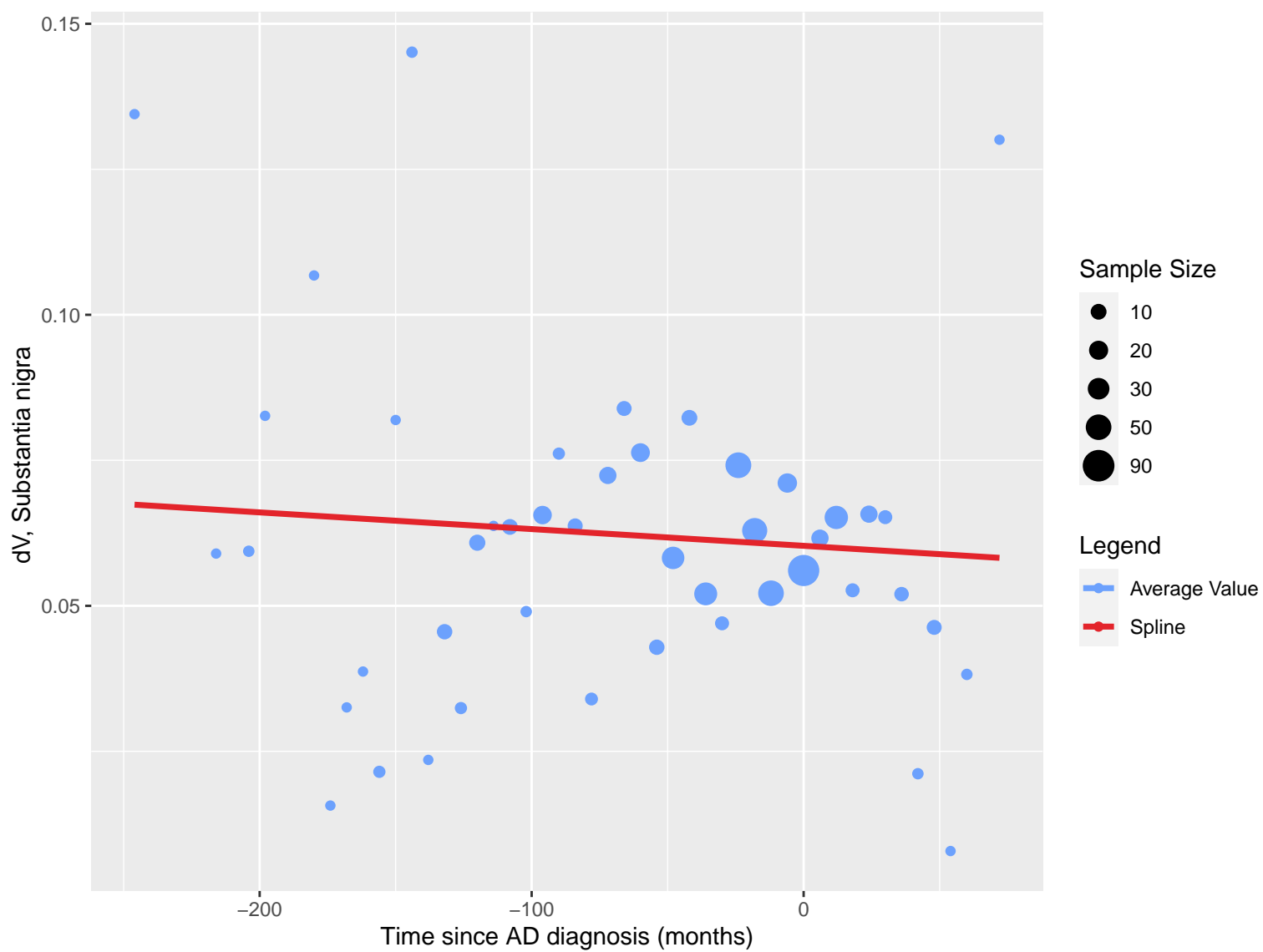


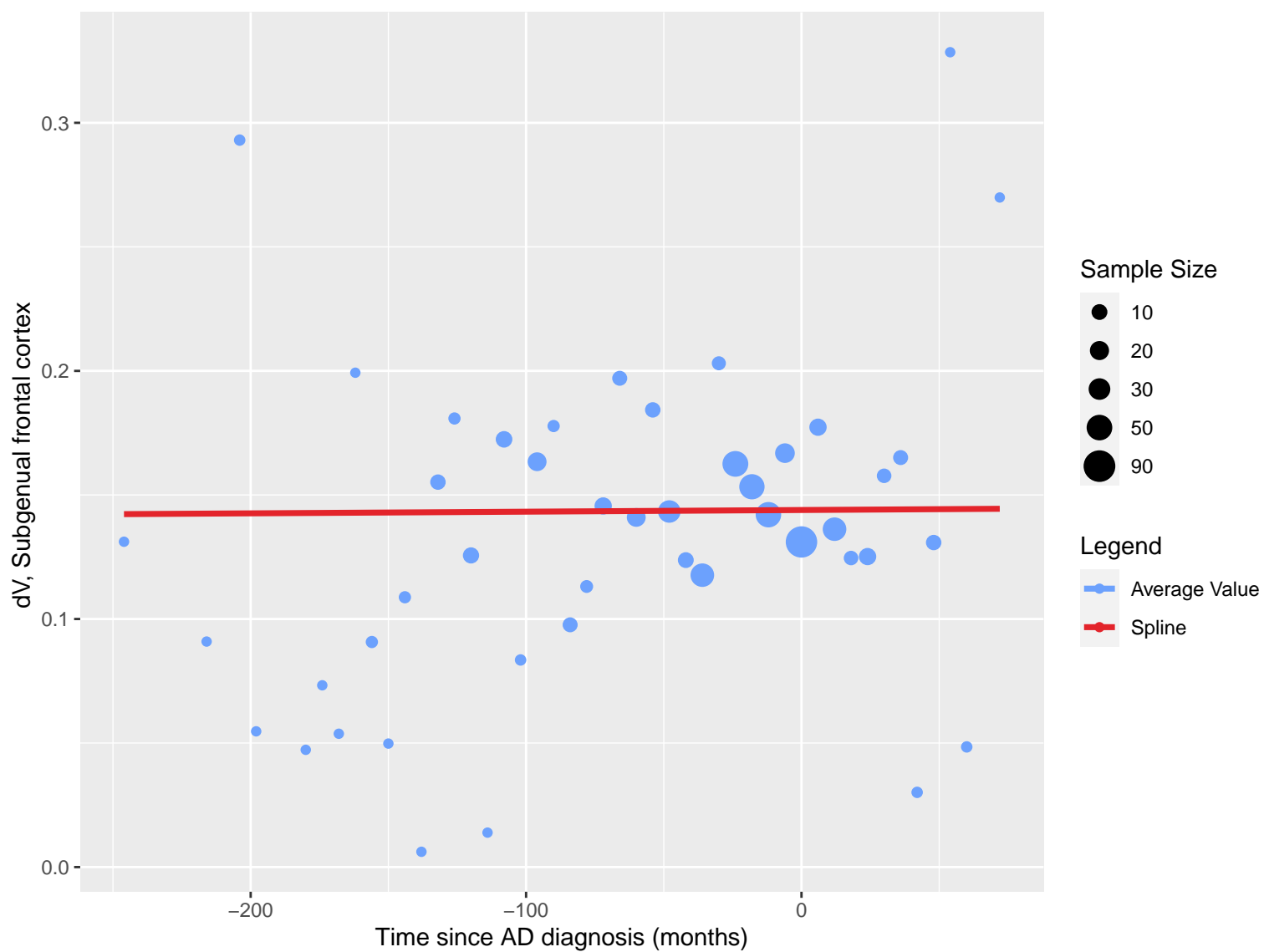


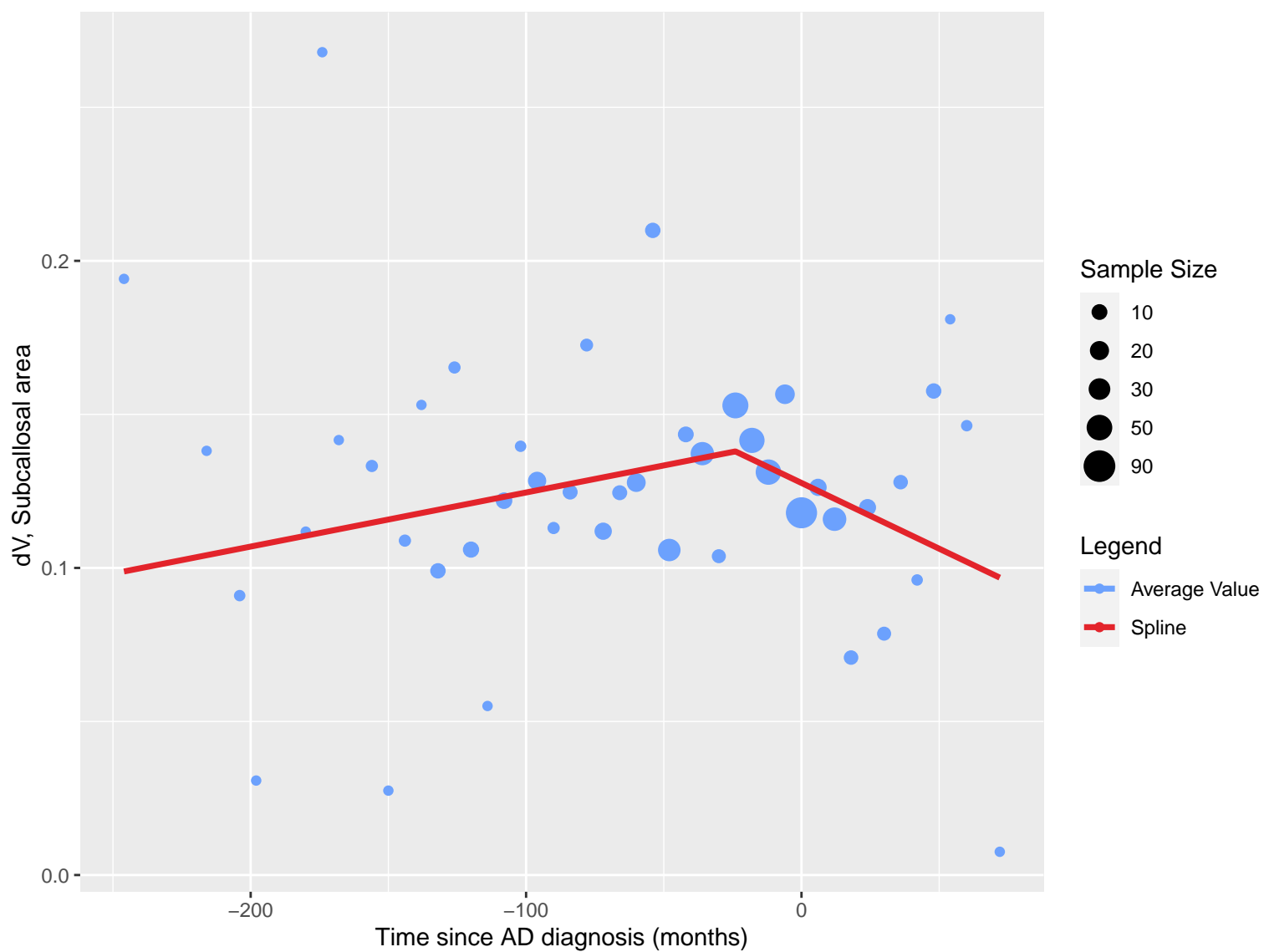


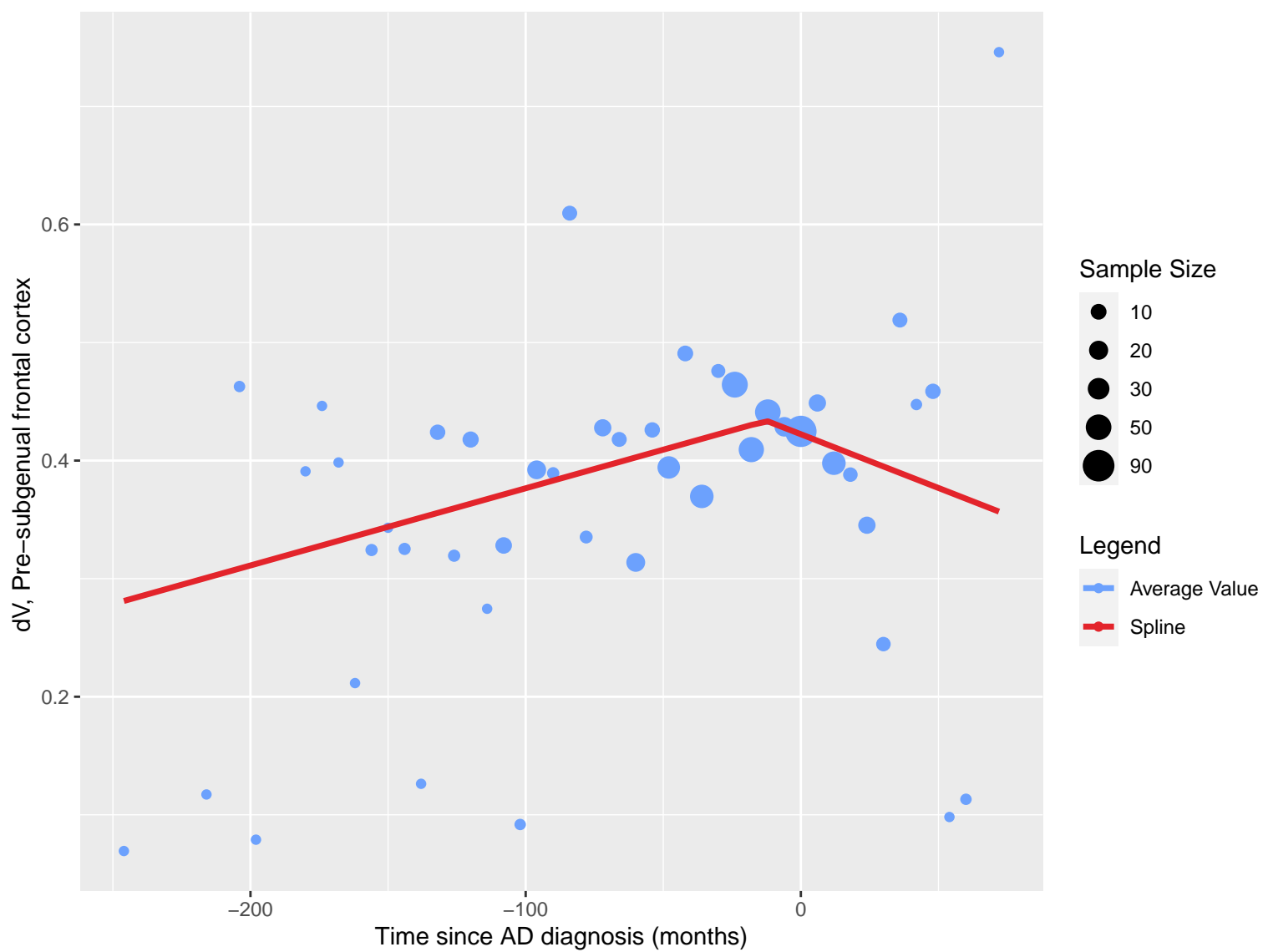


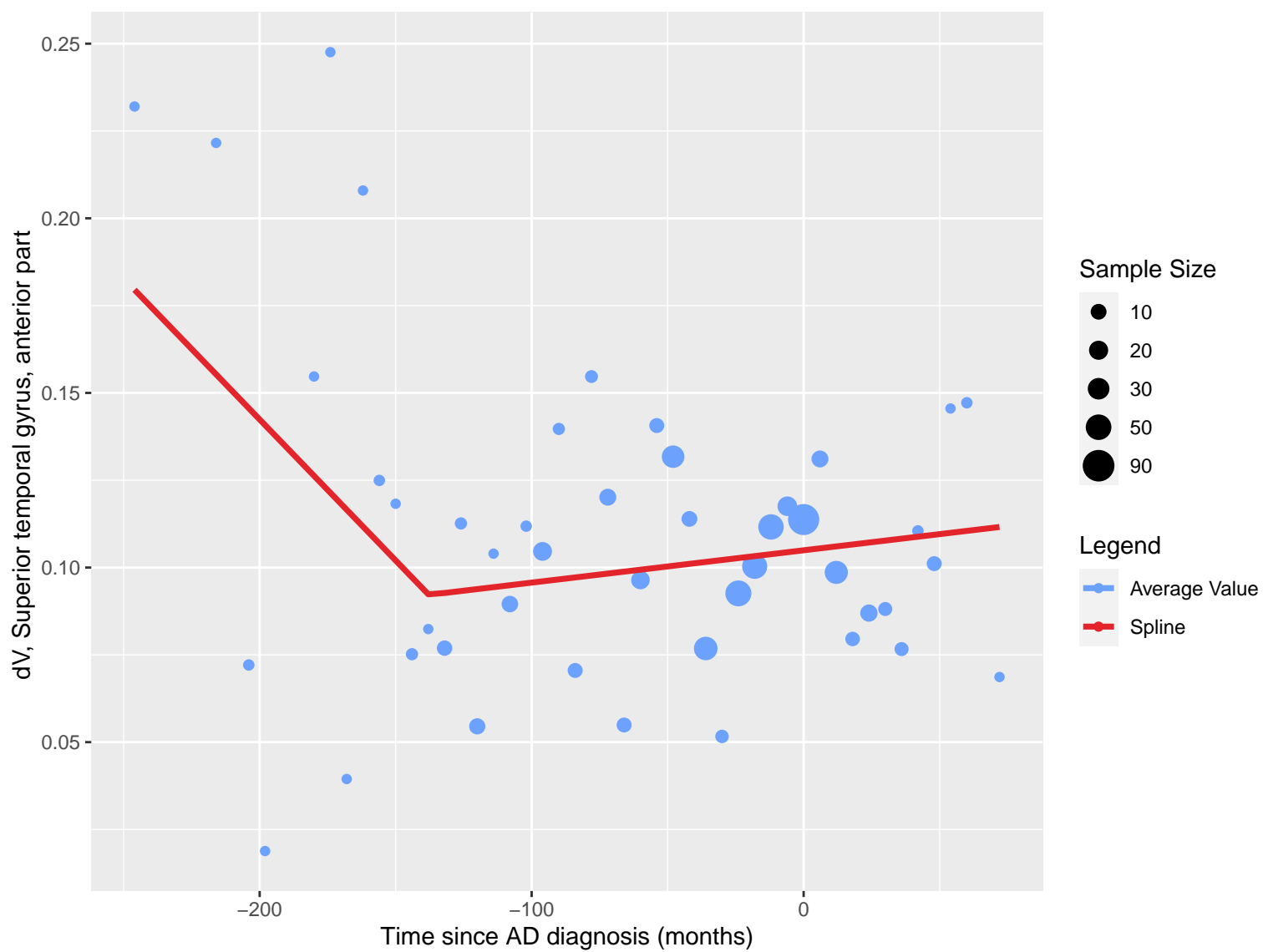


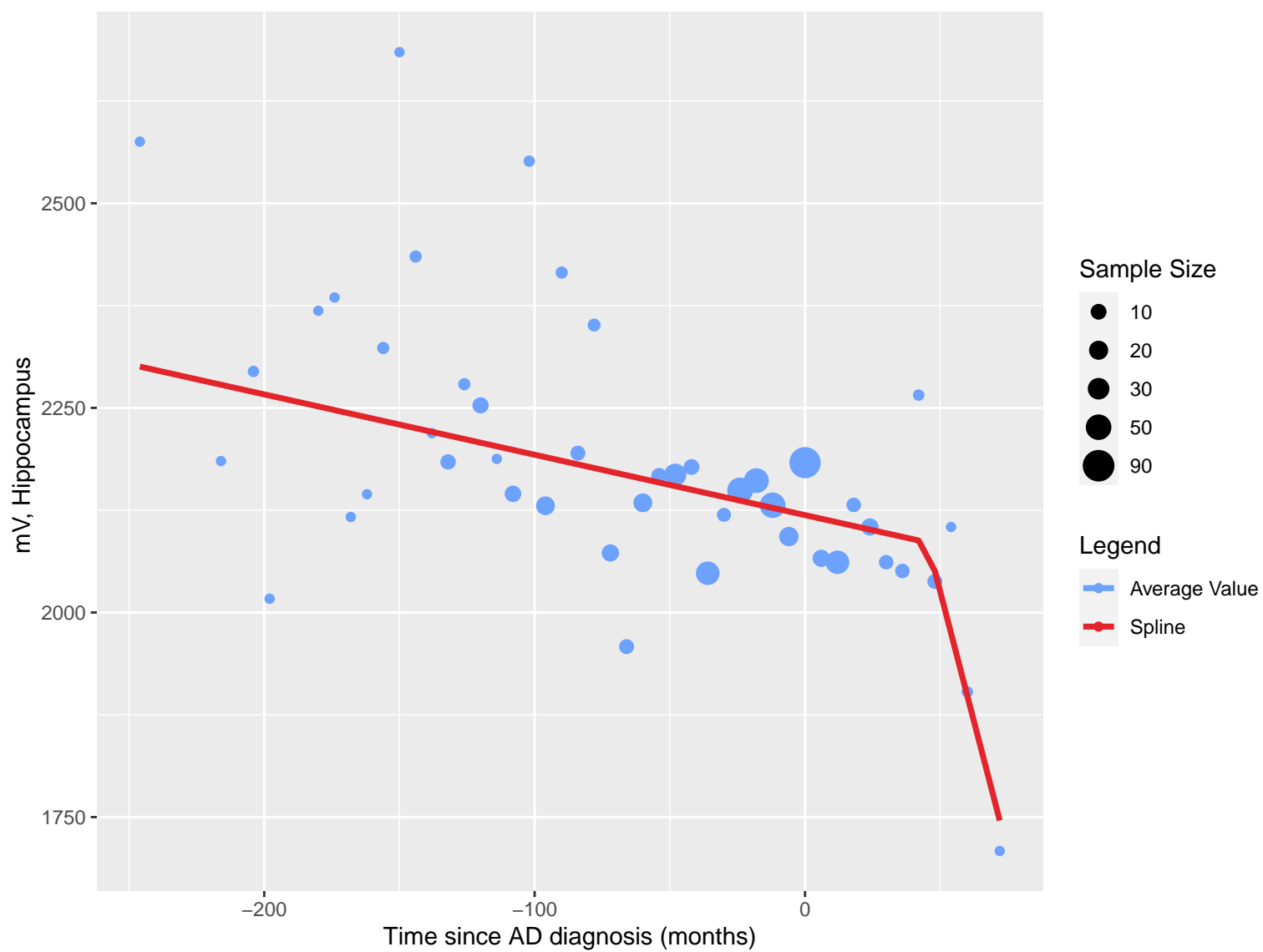


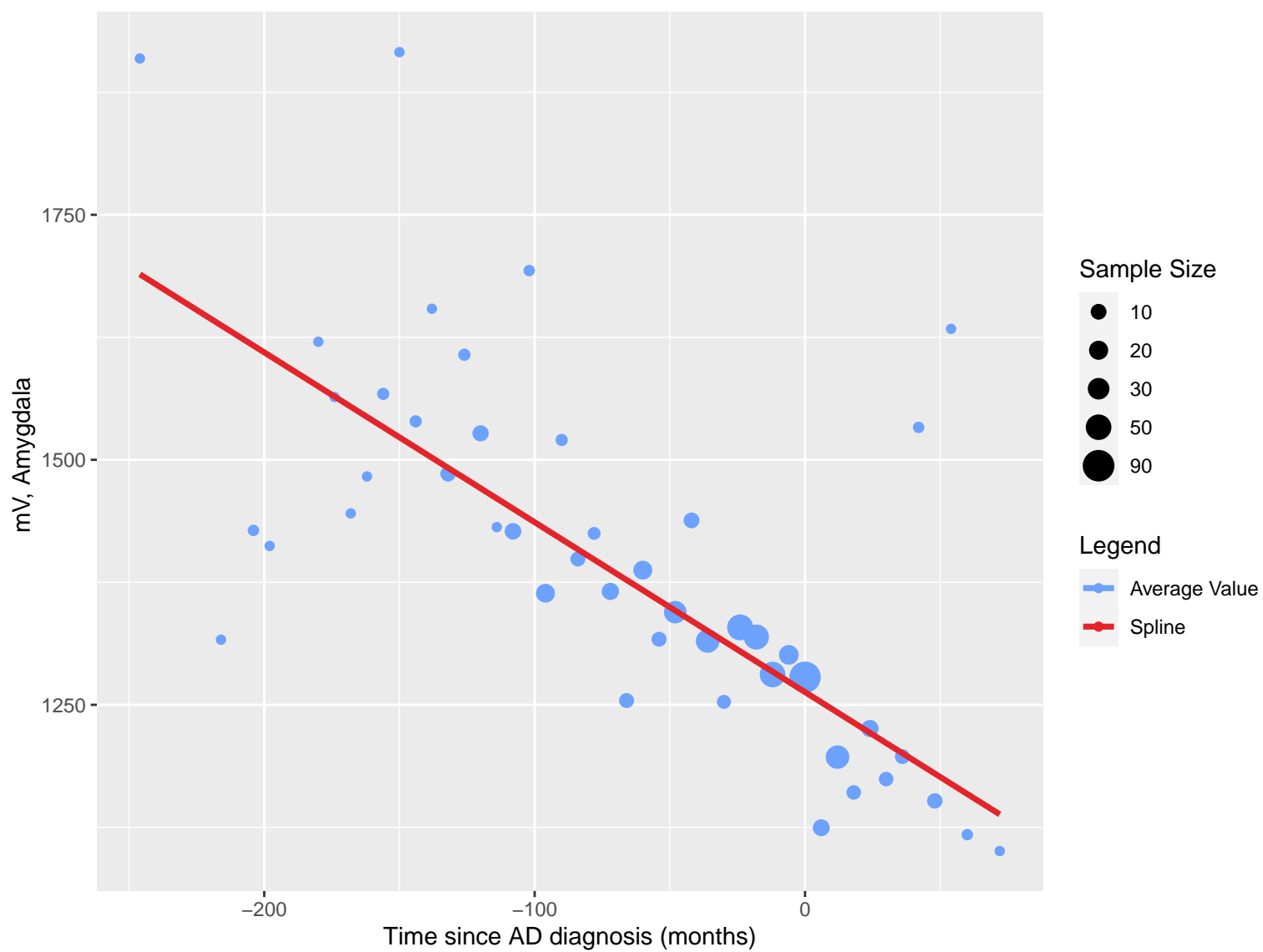






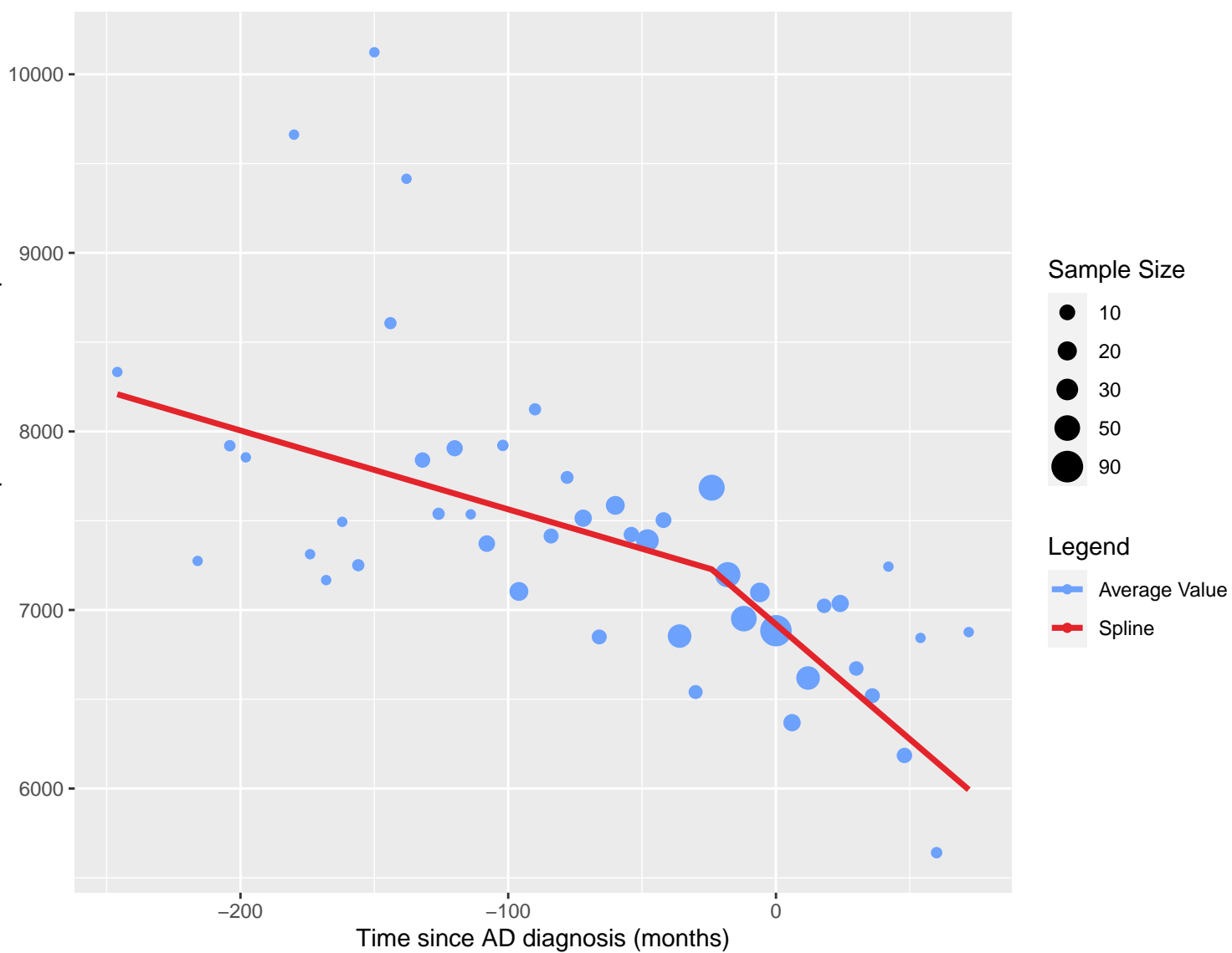


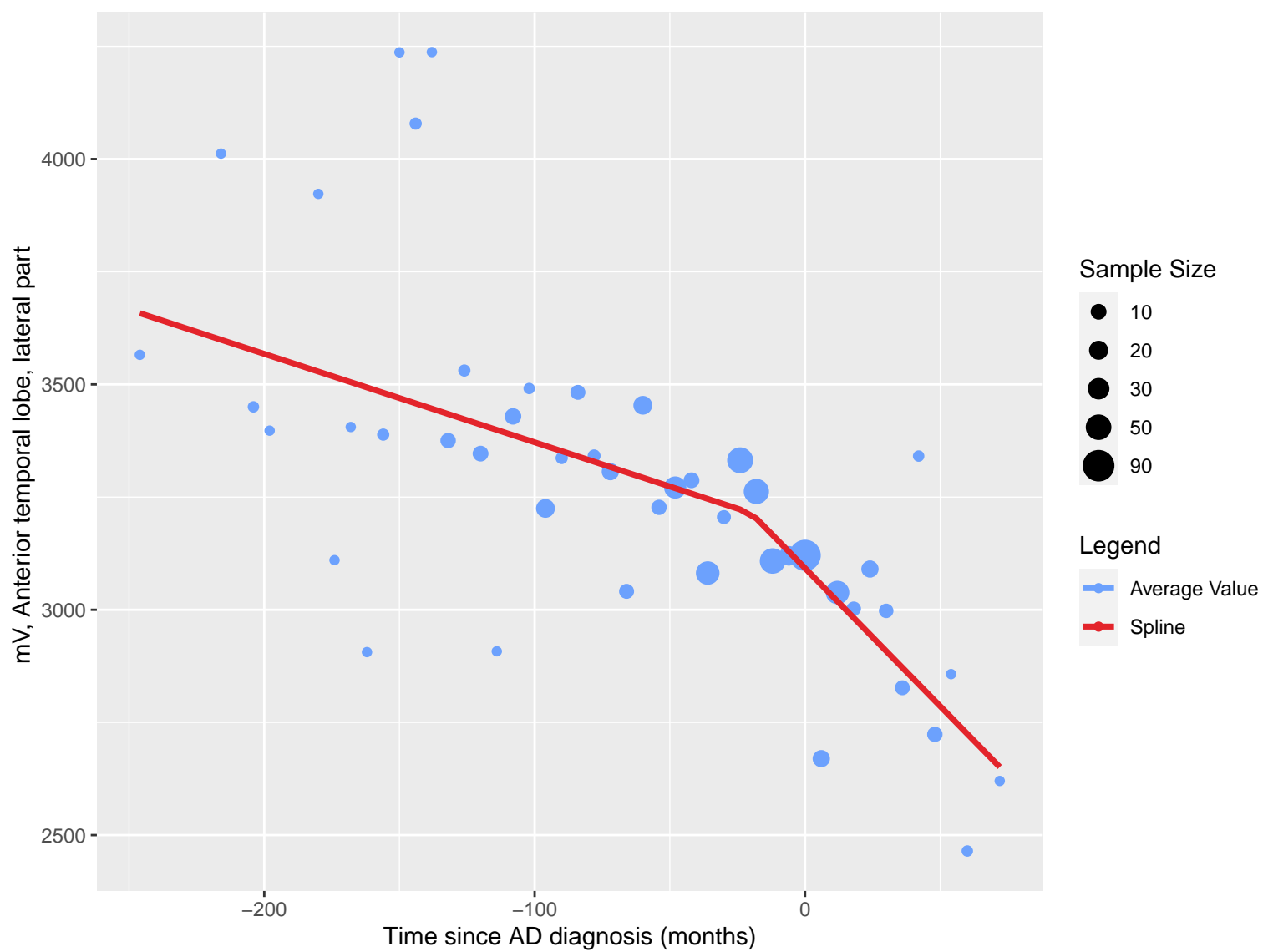


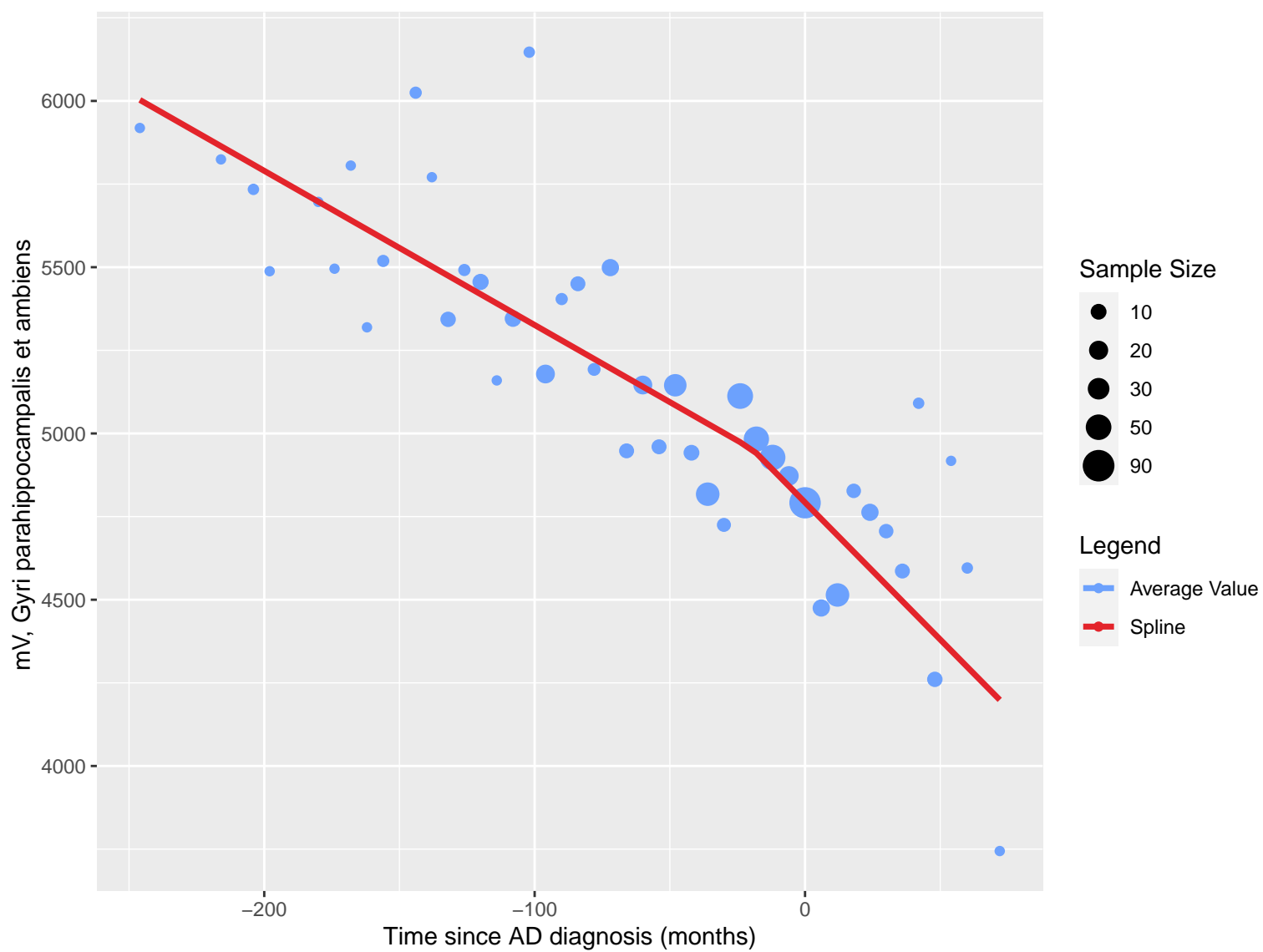


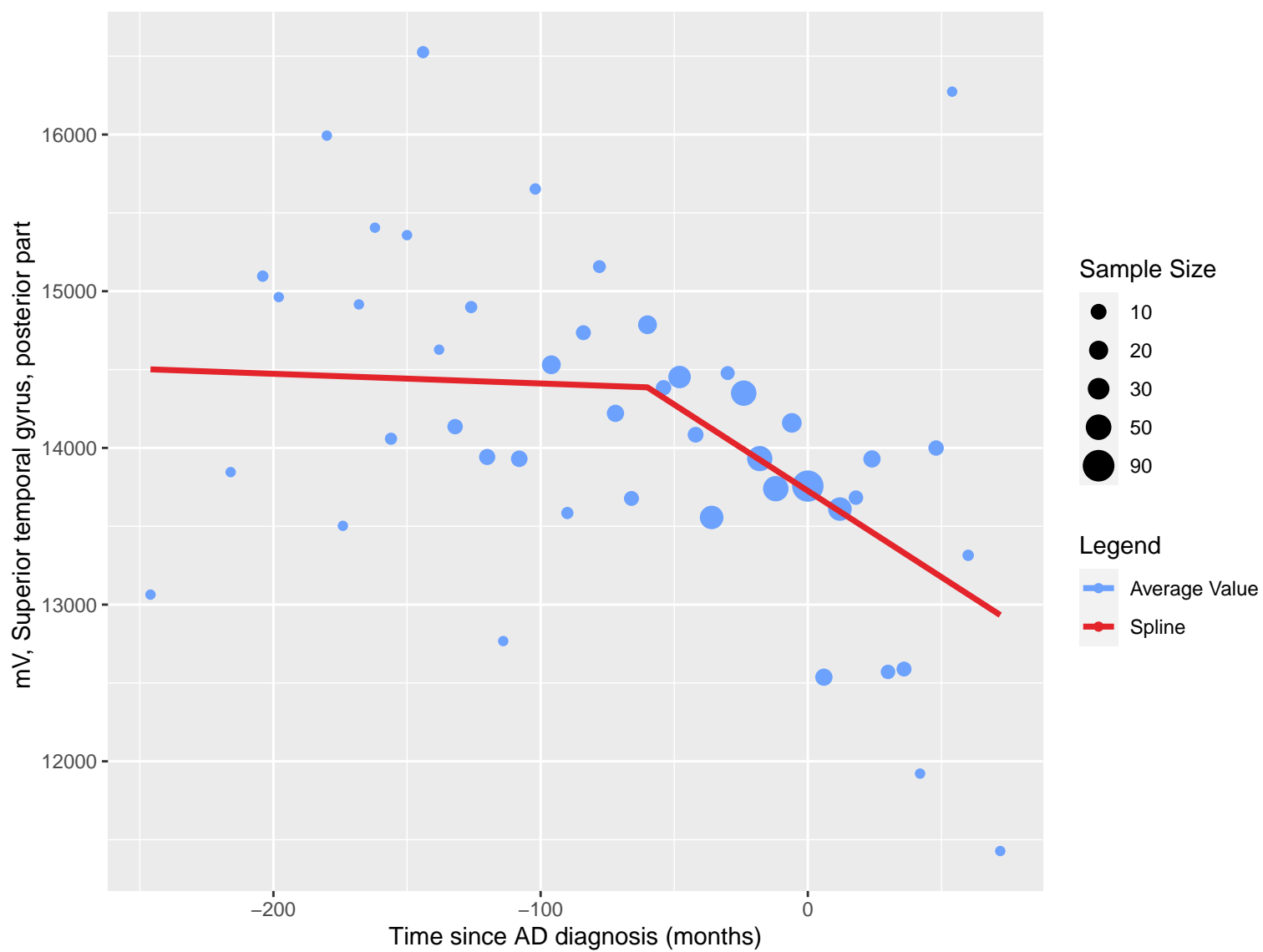


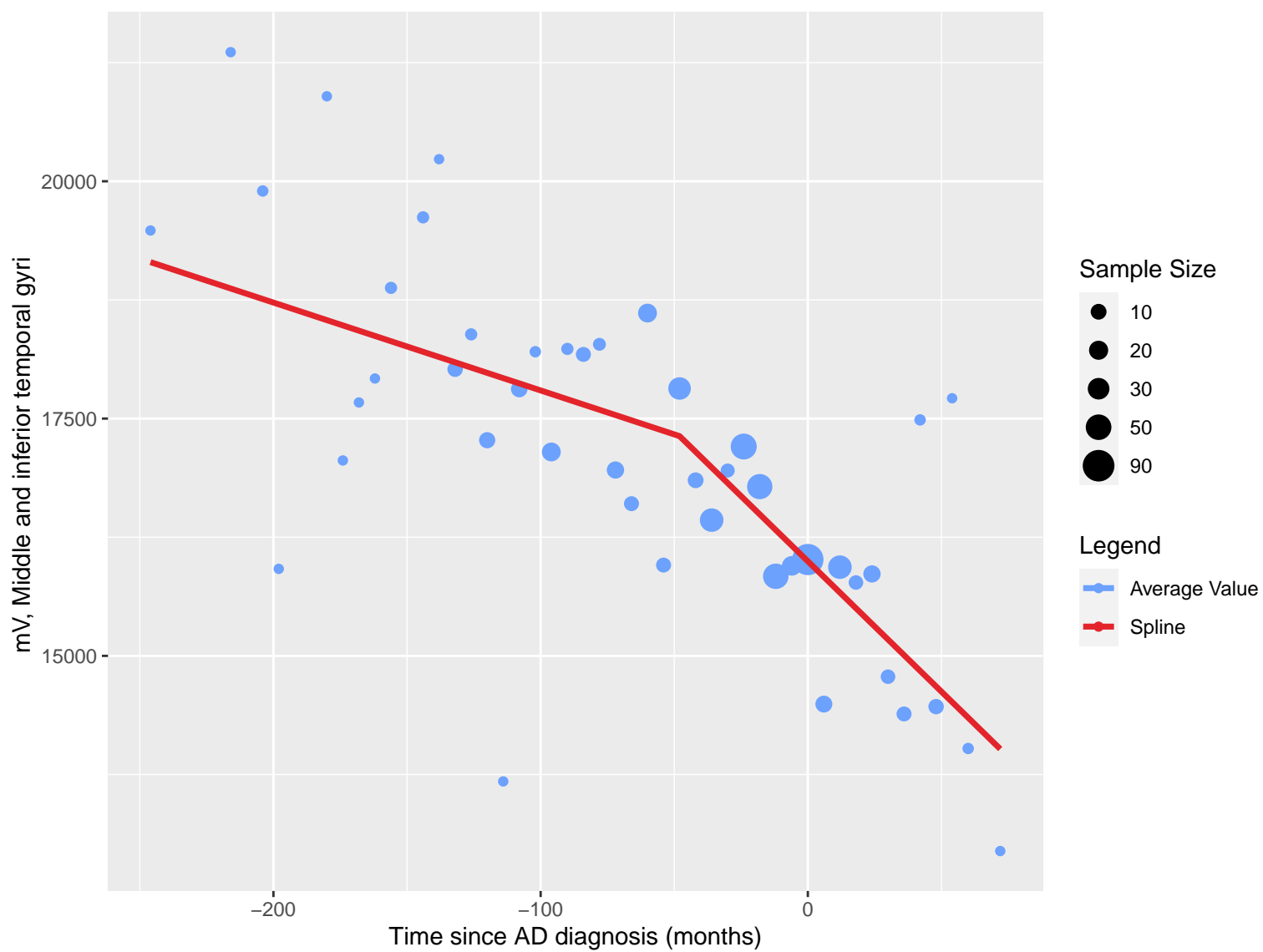
mV, Anterior temporal lobe, medial part

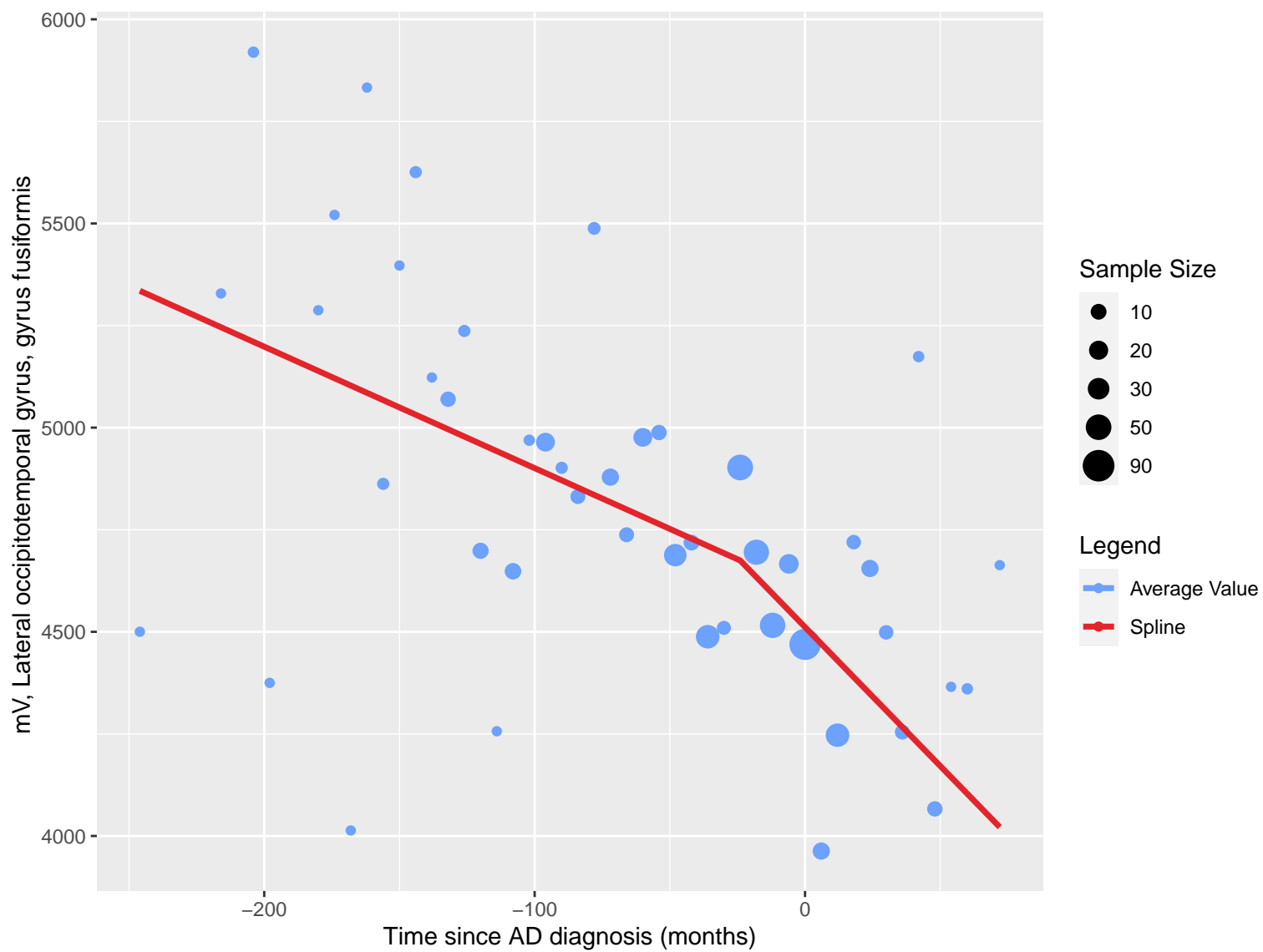


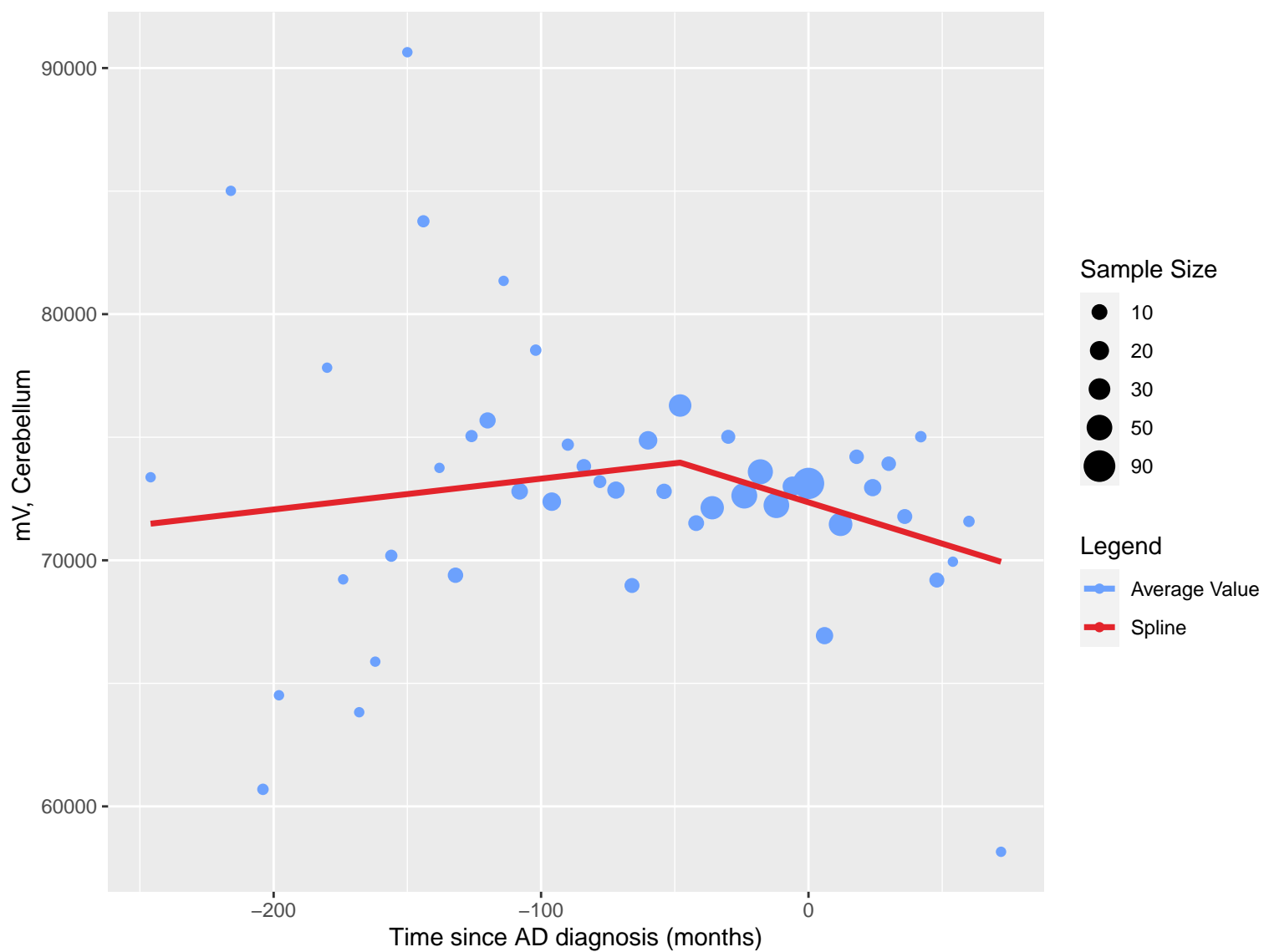


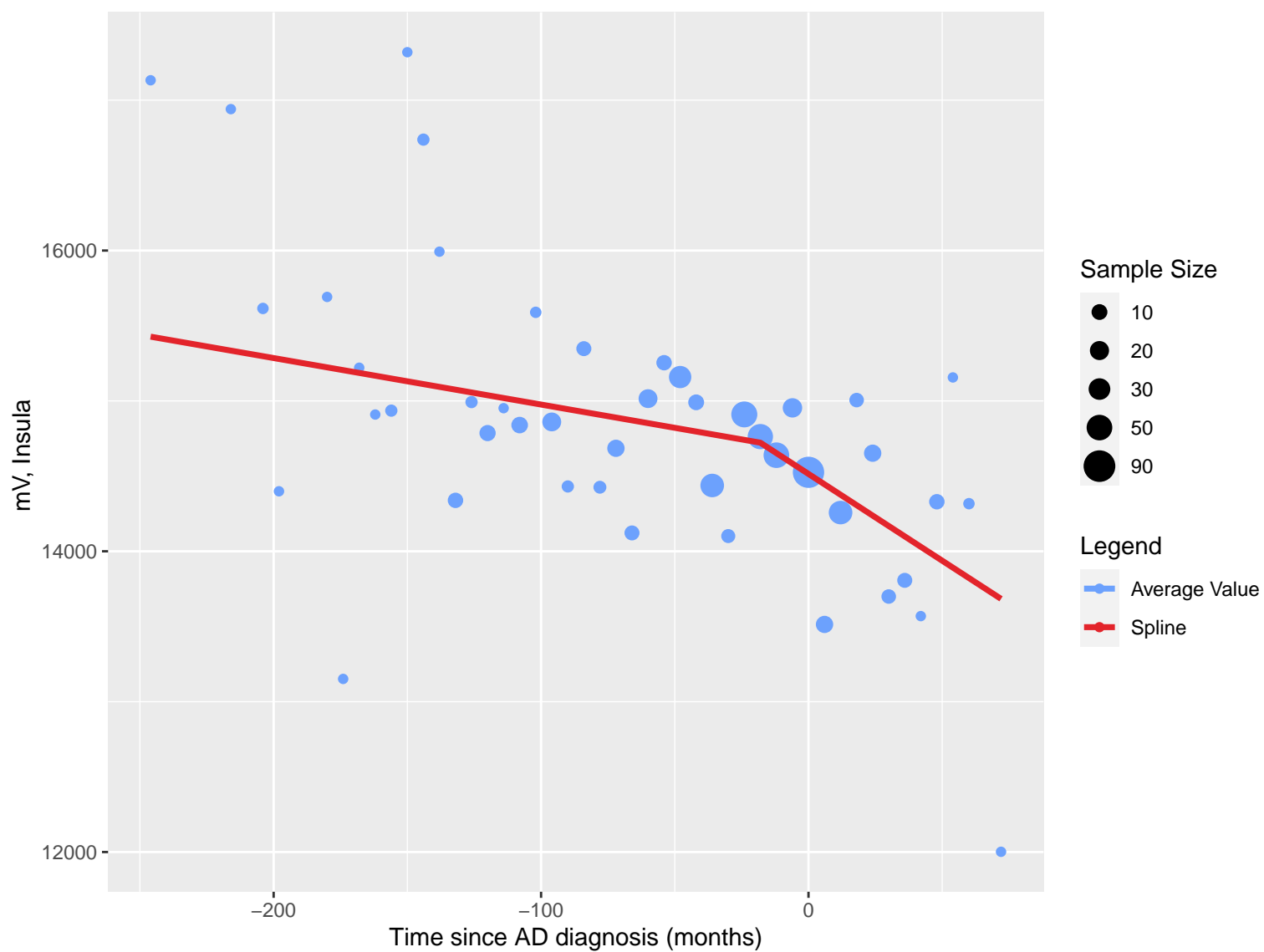




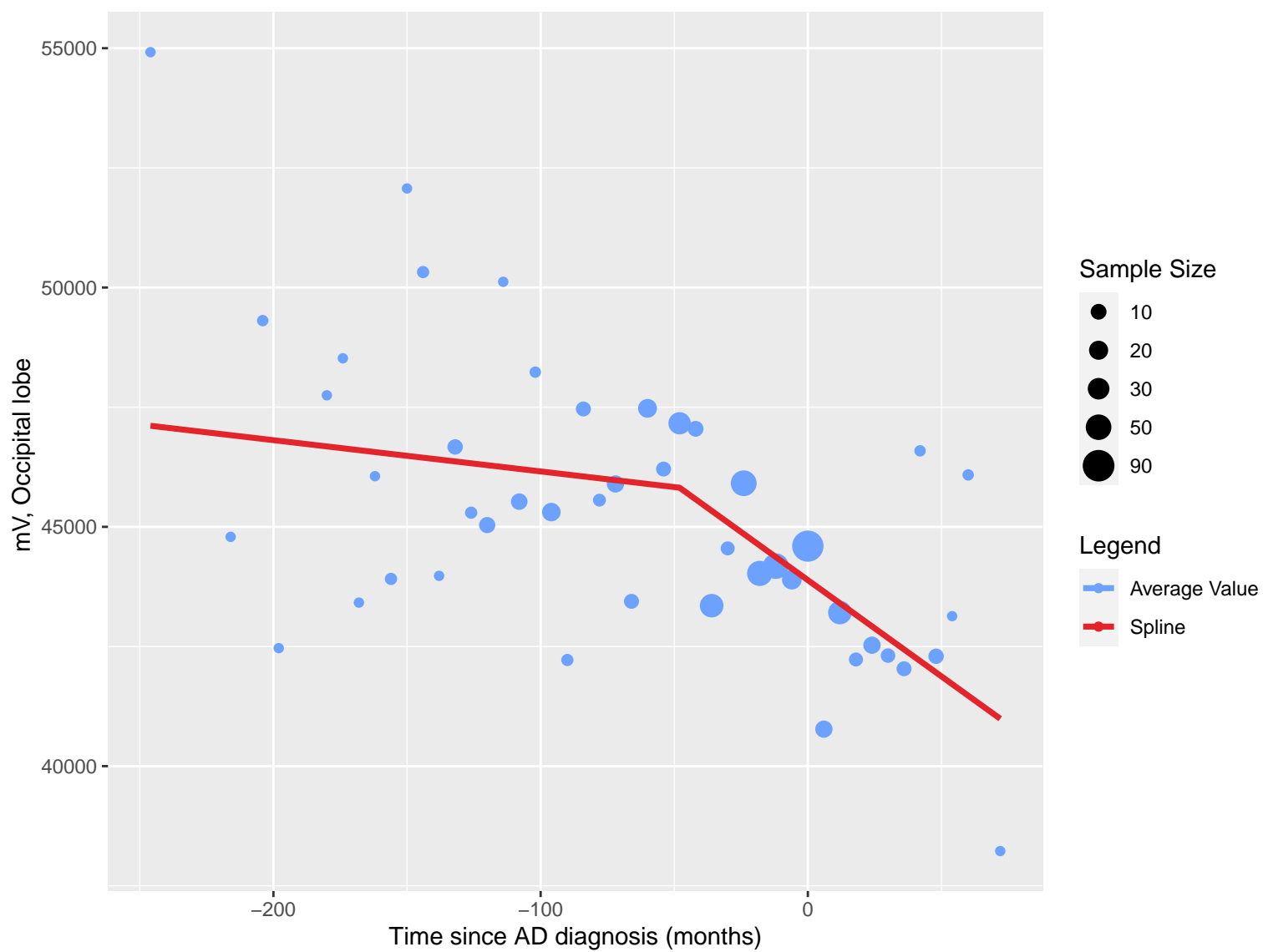


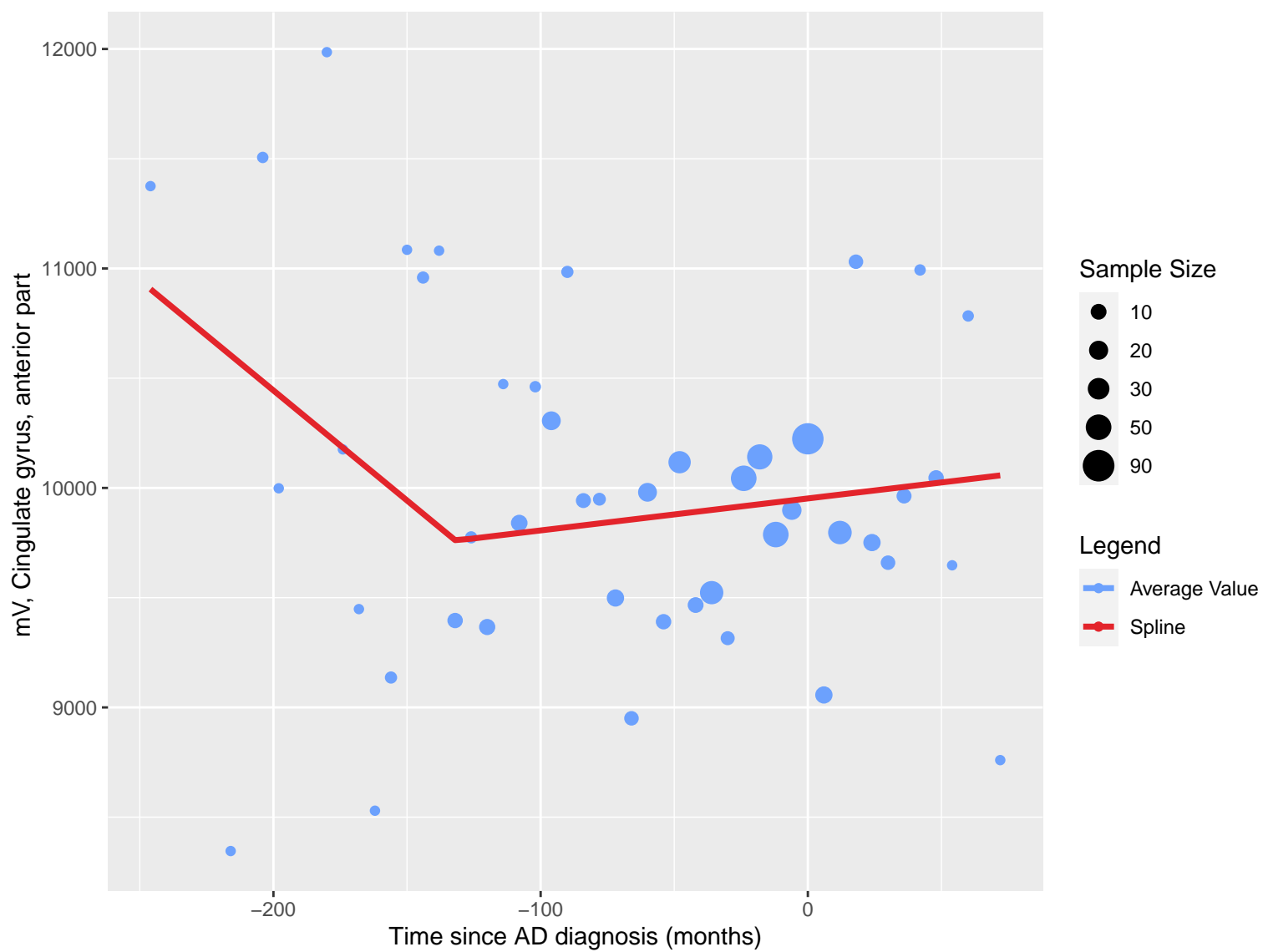


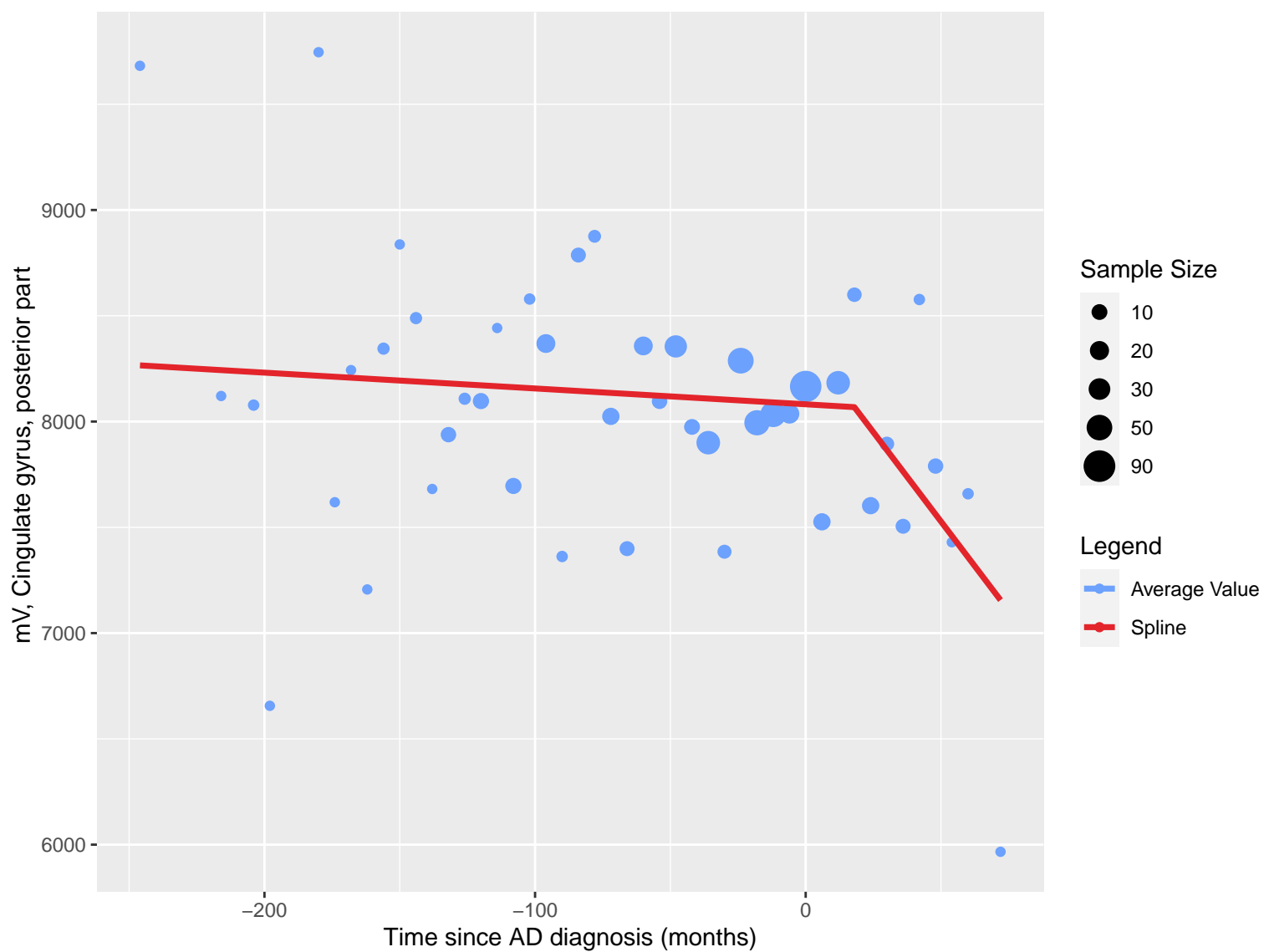


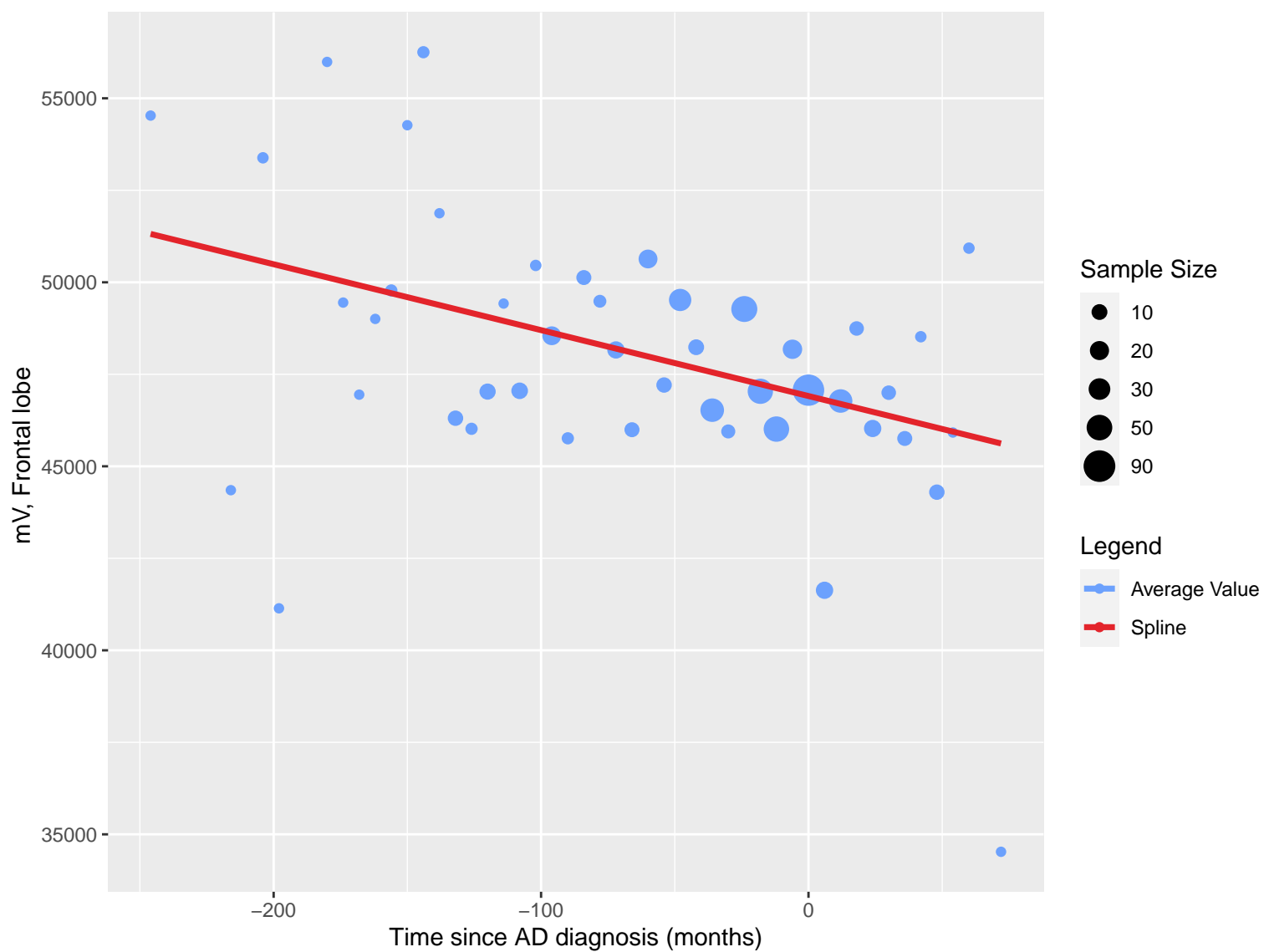


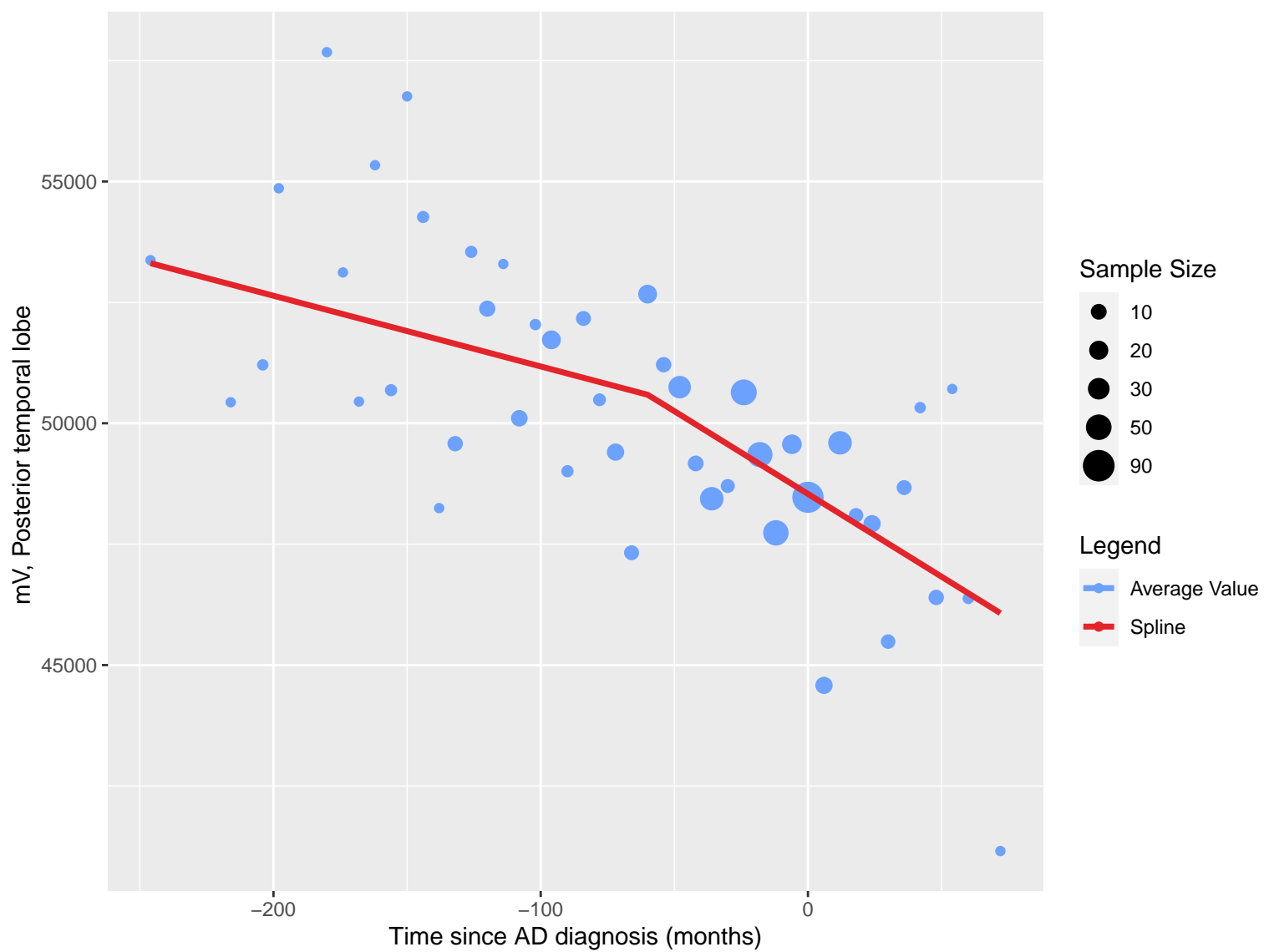


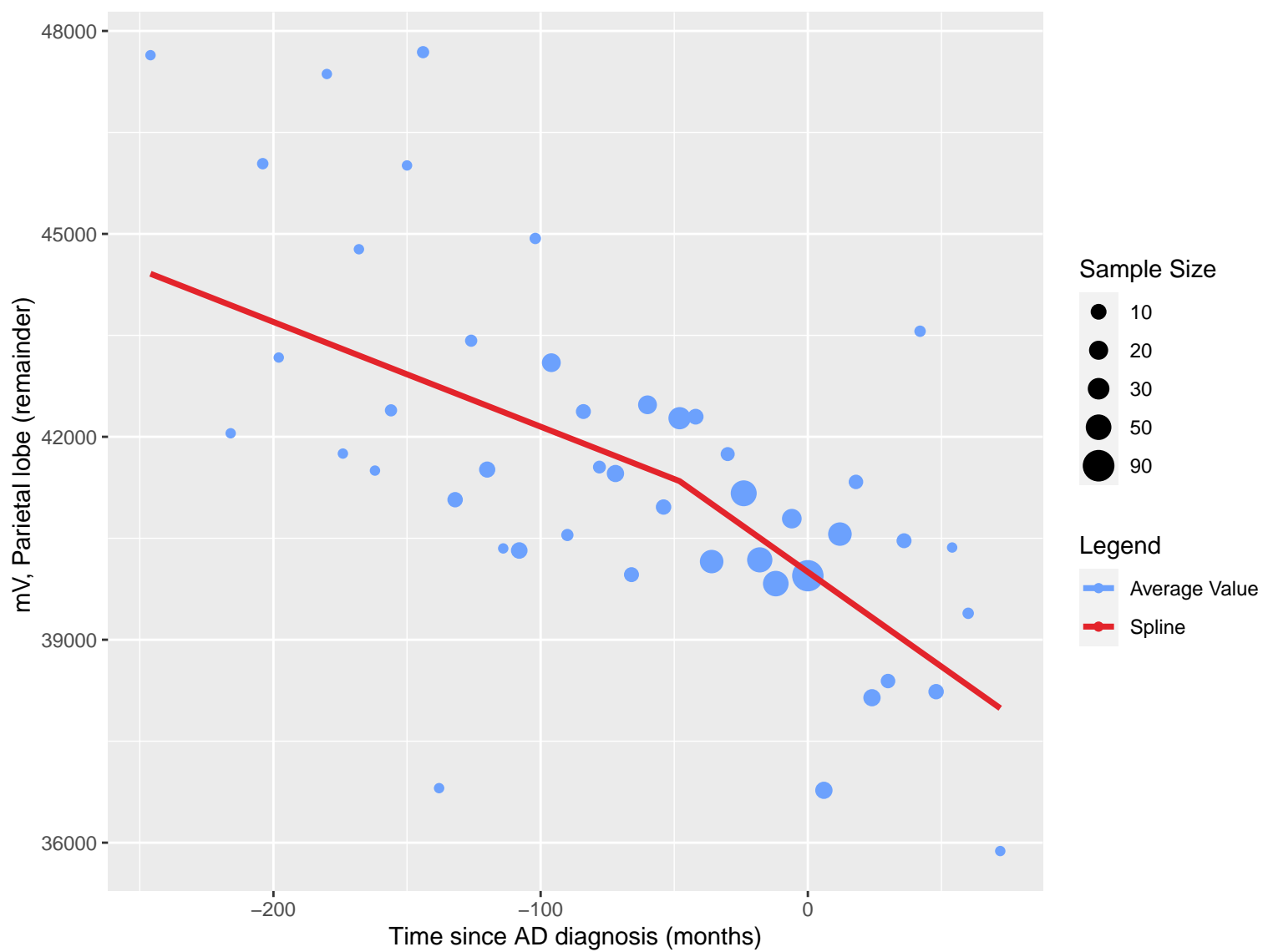


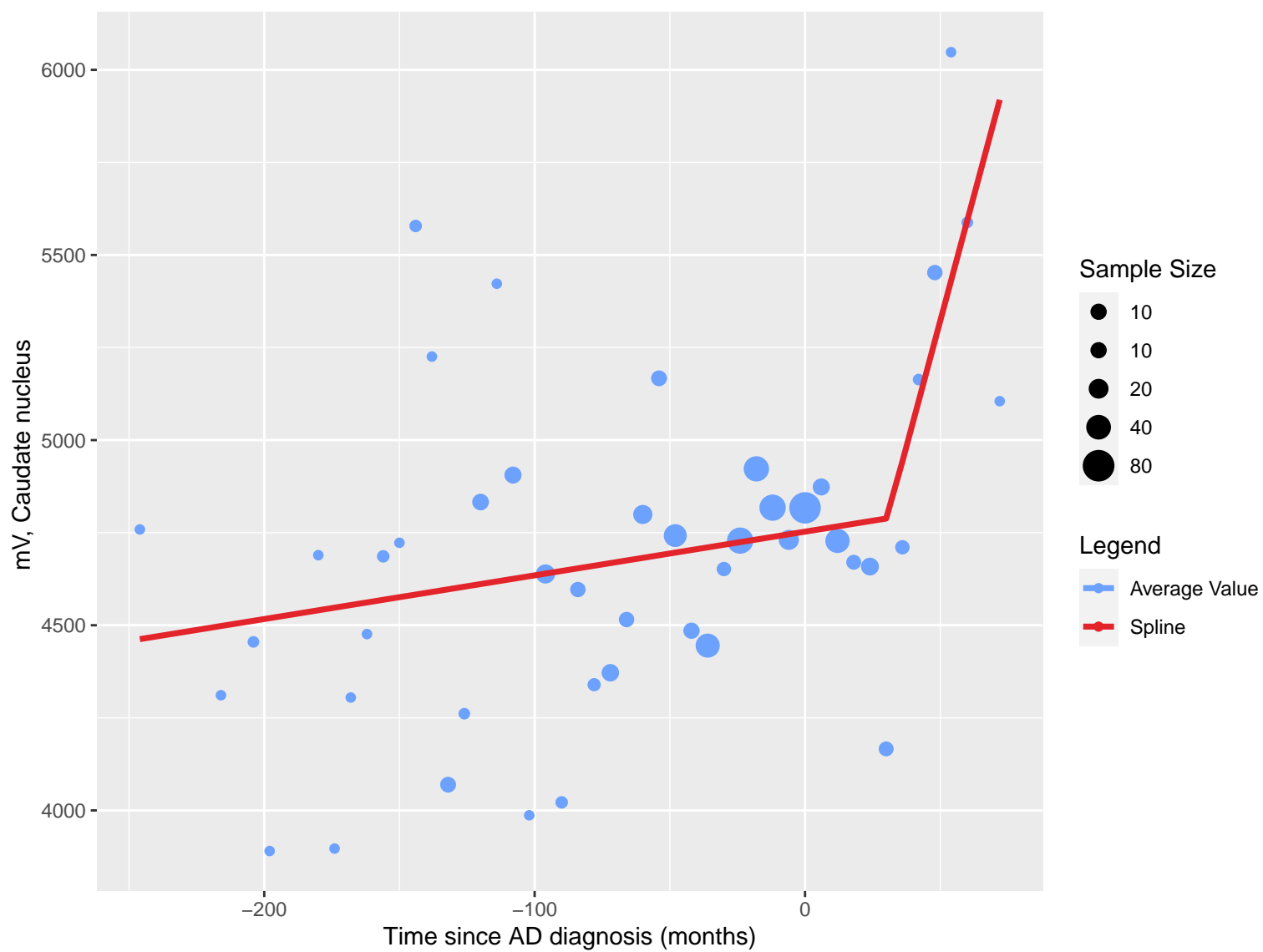


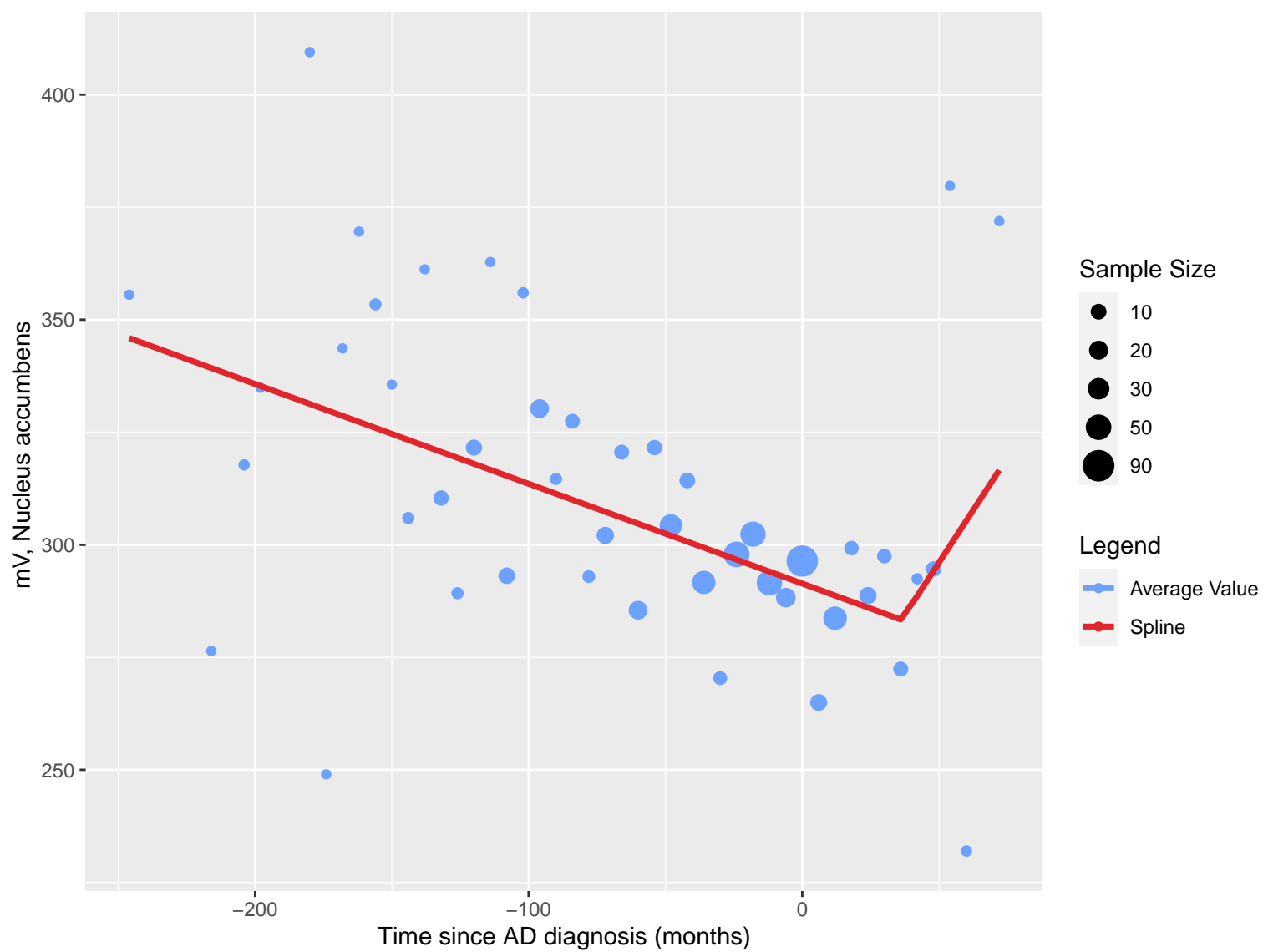




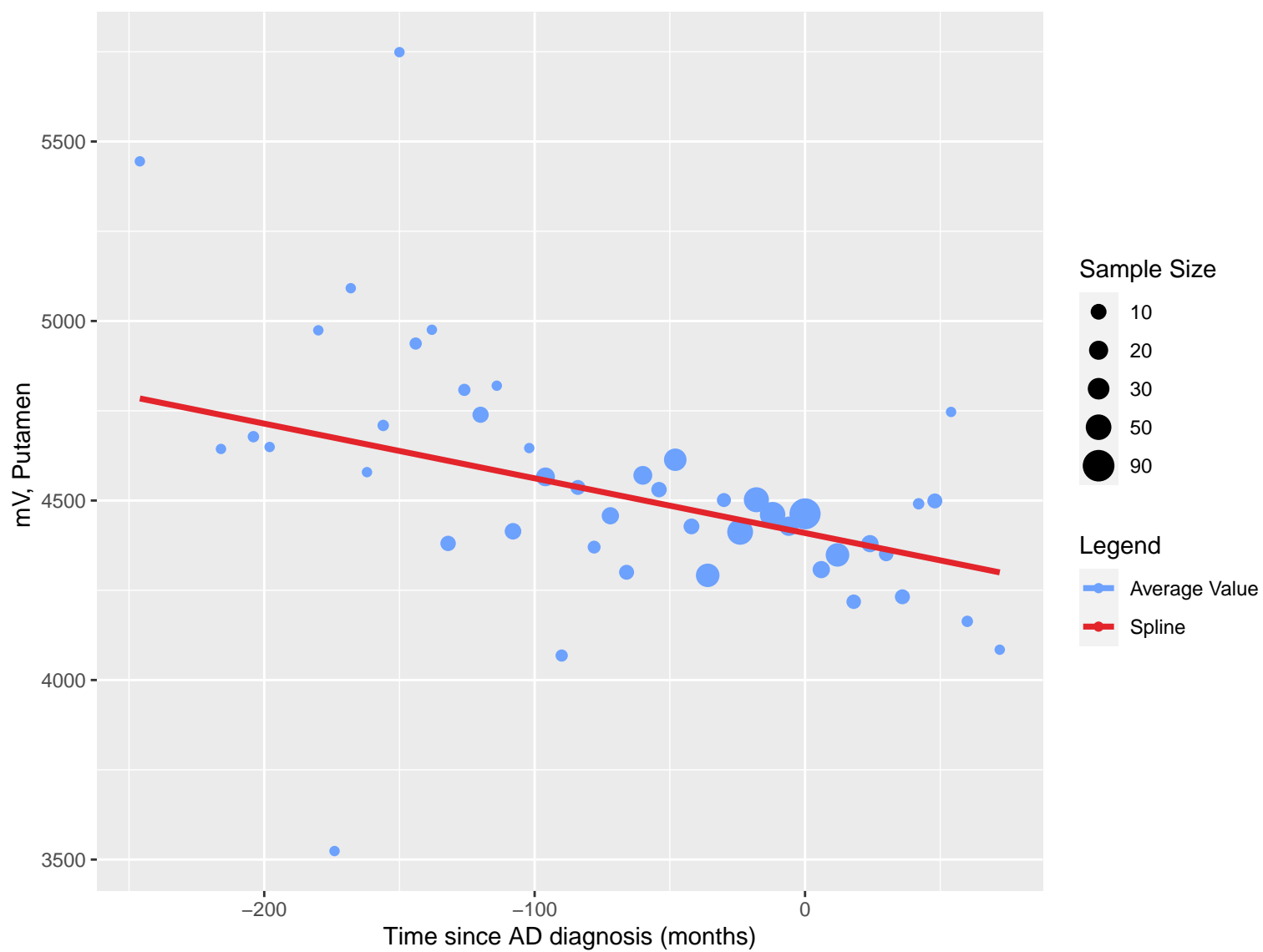


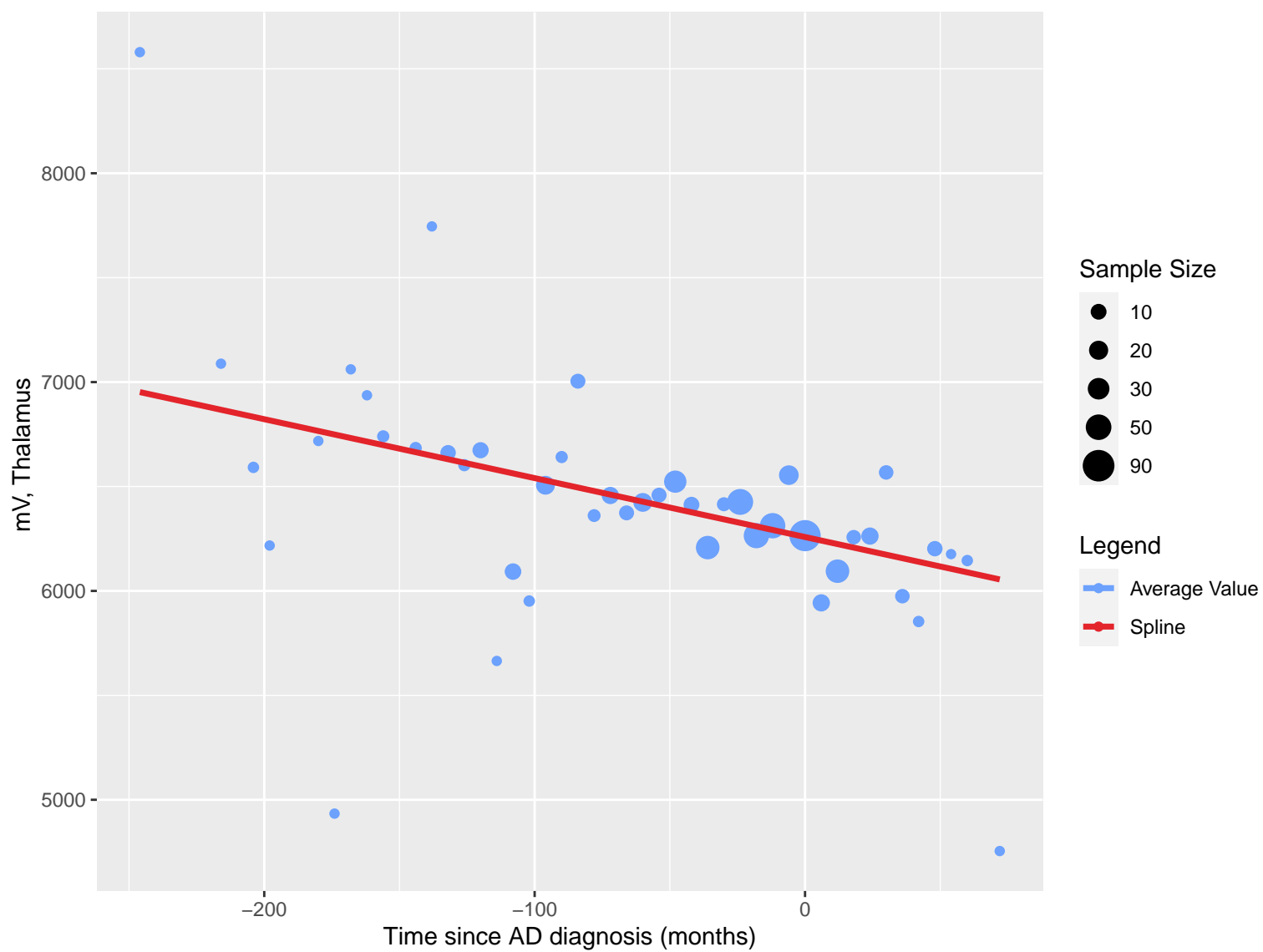


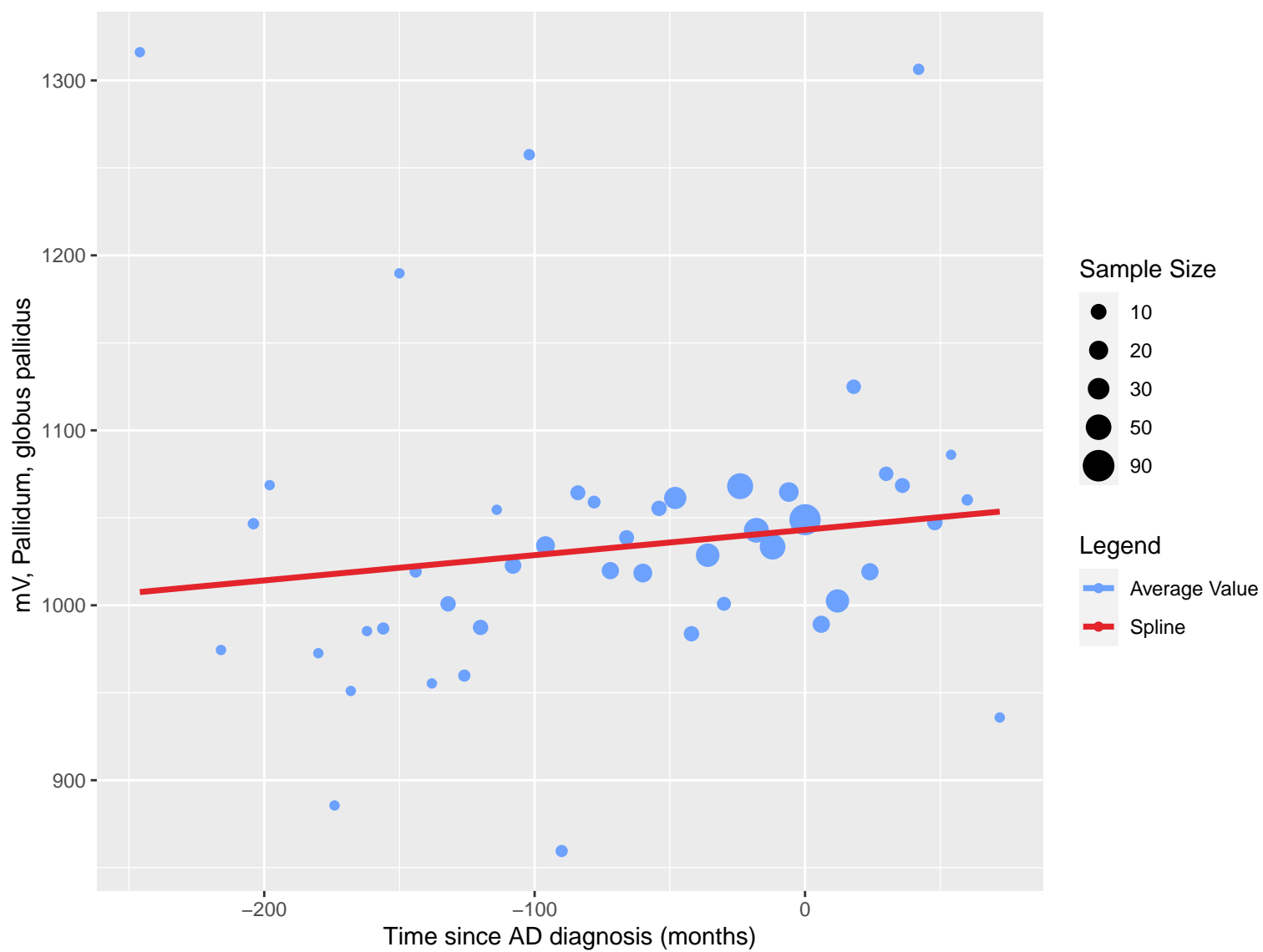




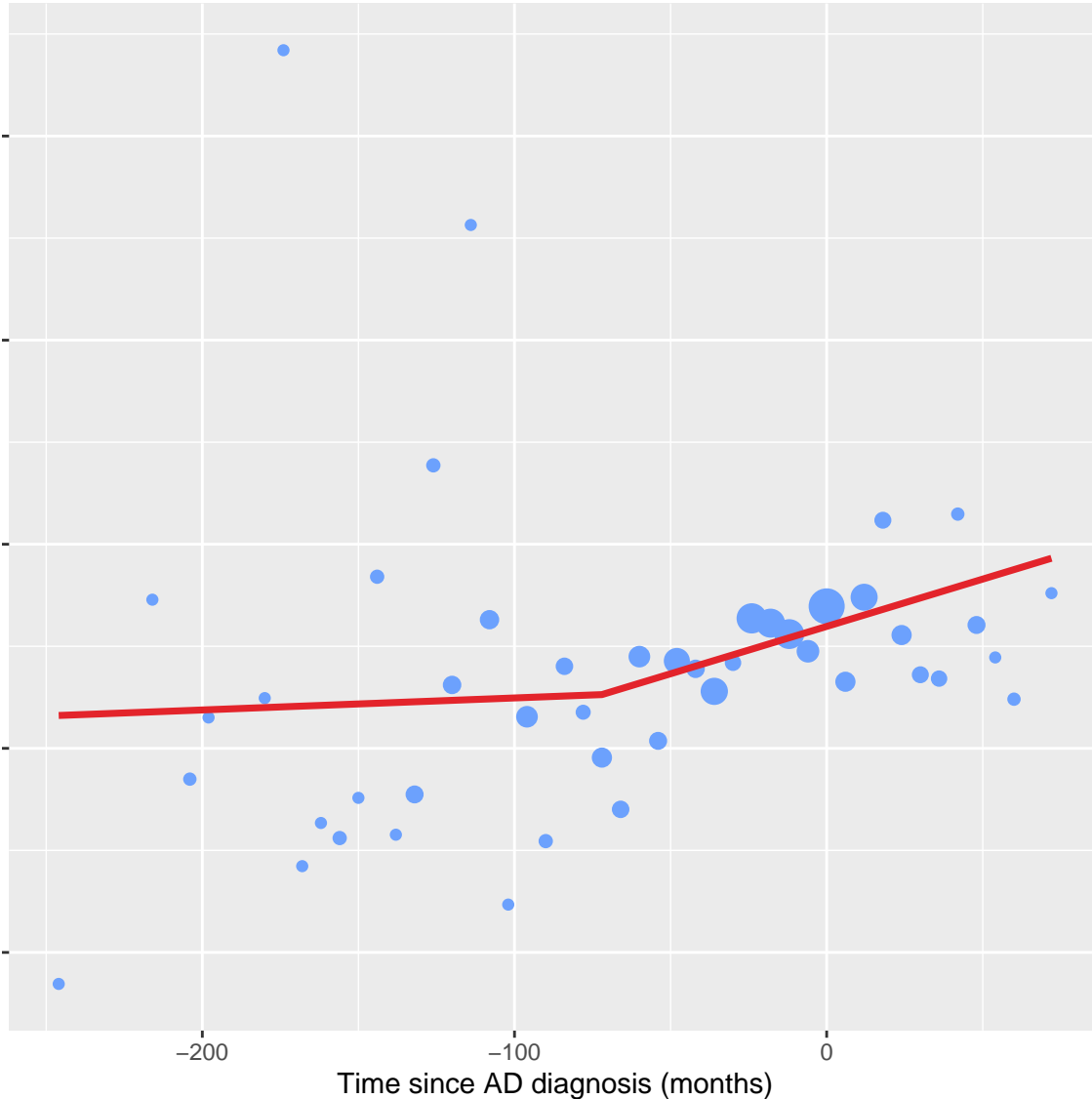


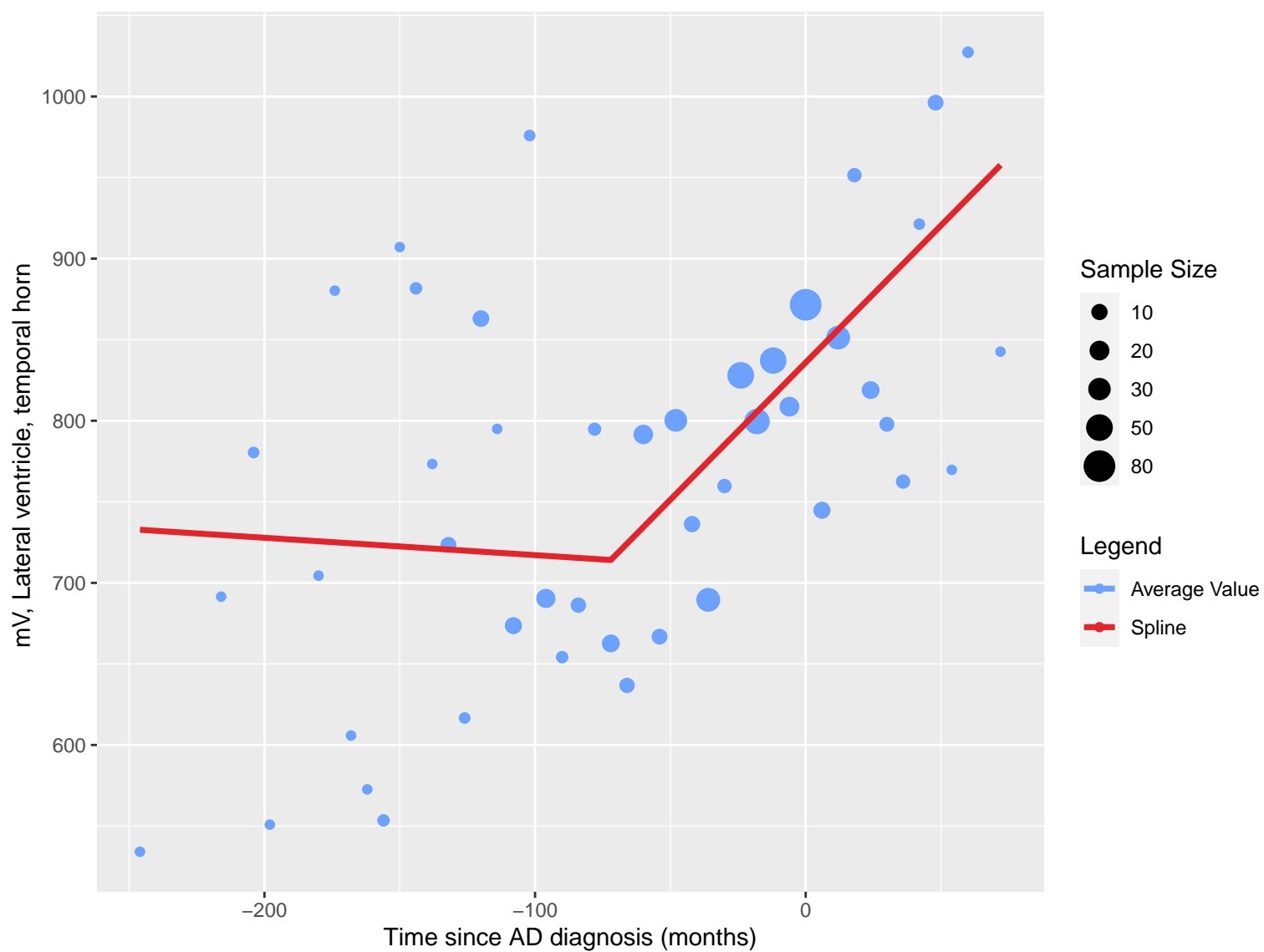


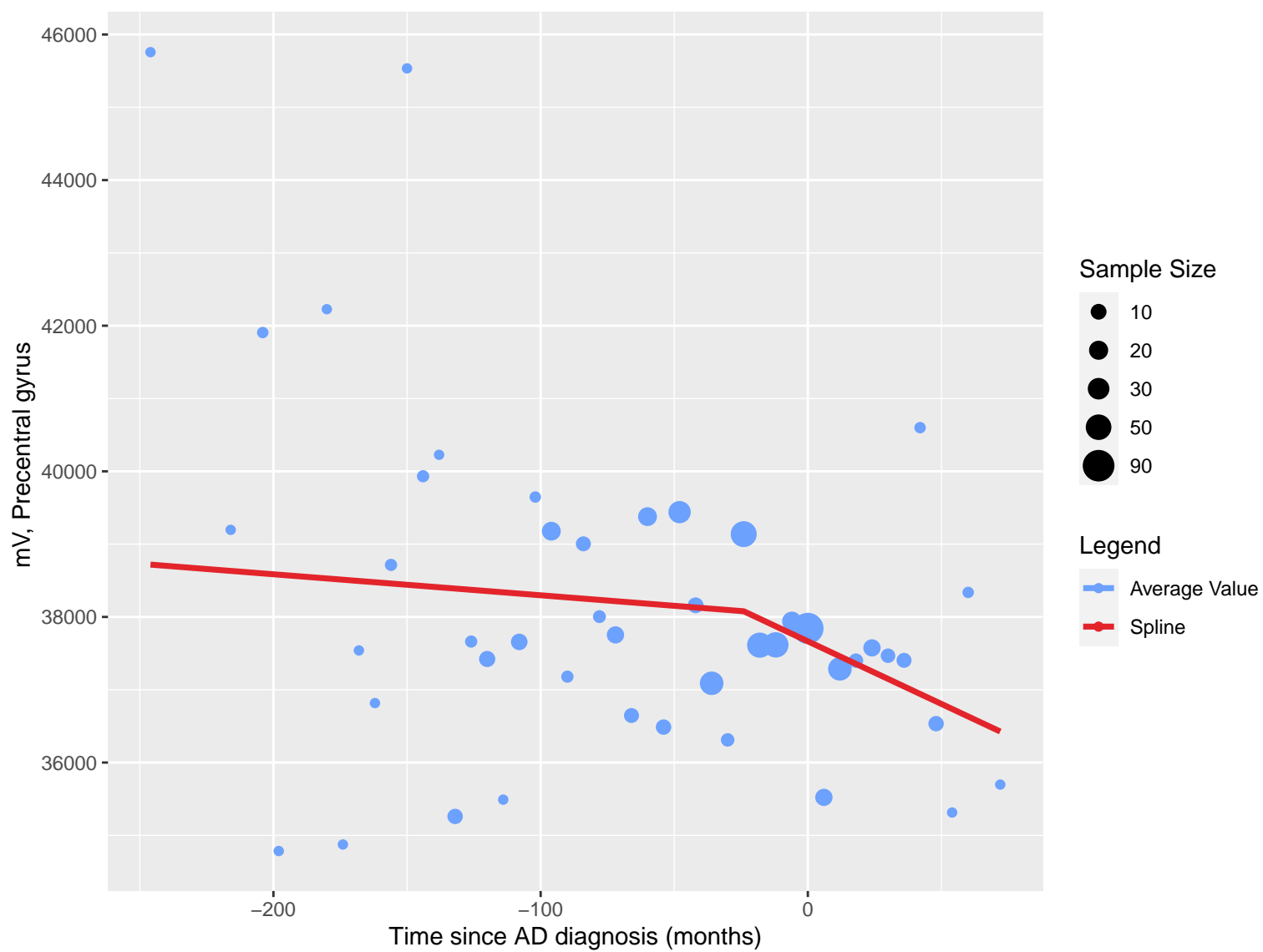


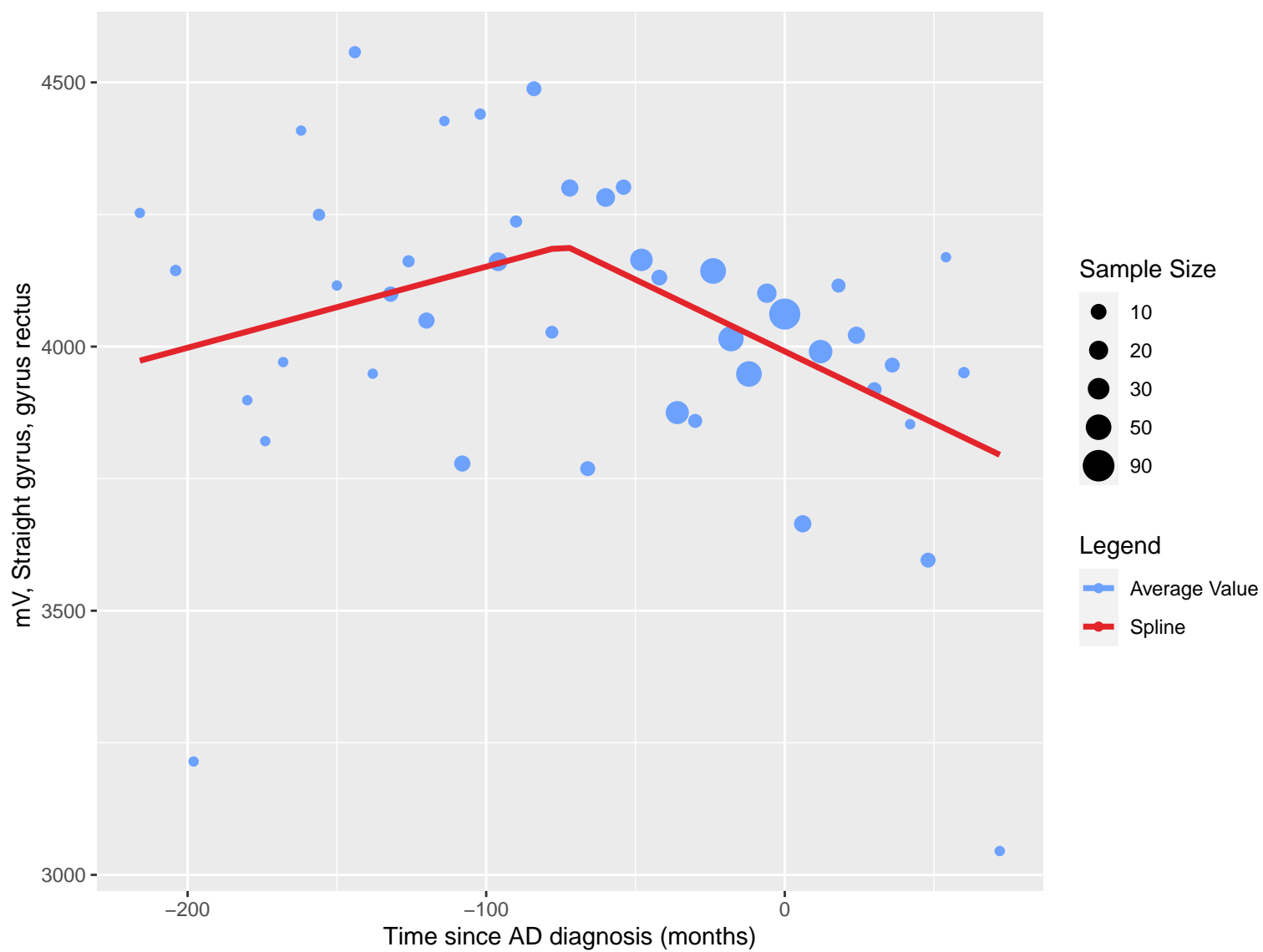


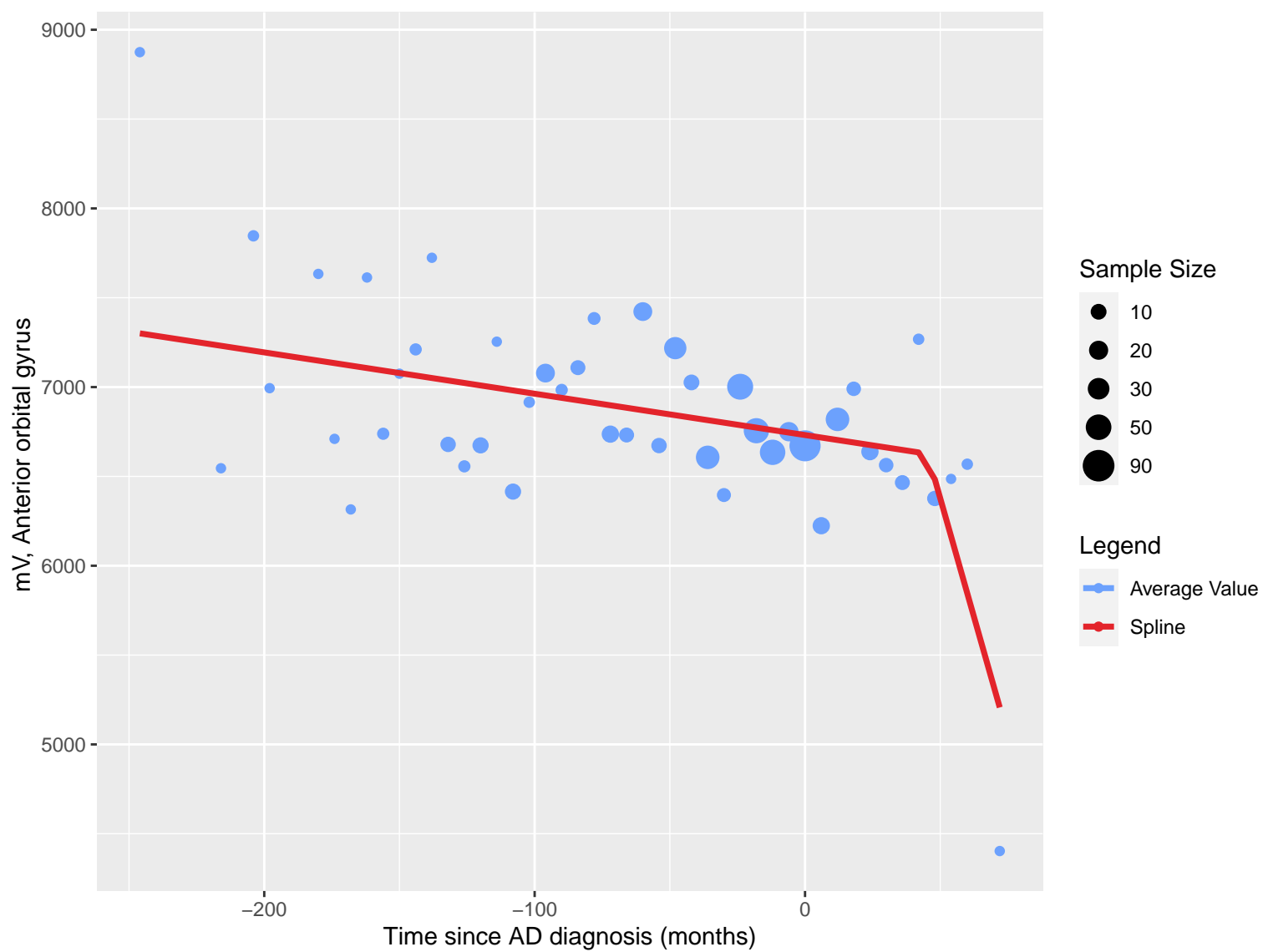
mV, Lateral ventricle, frontal horn, central part and occipital horn



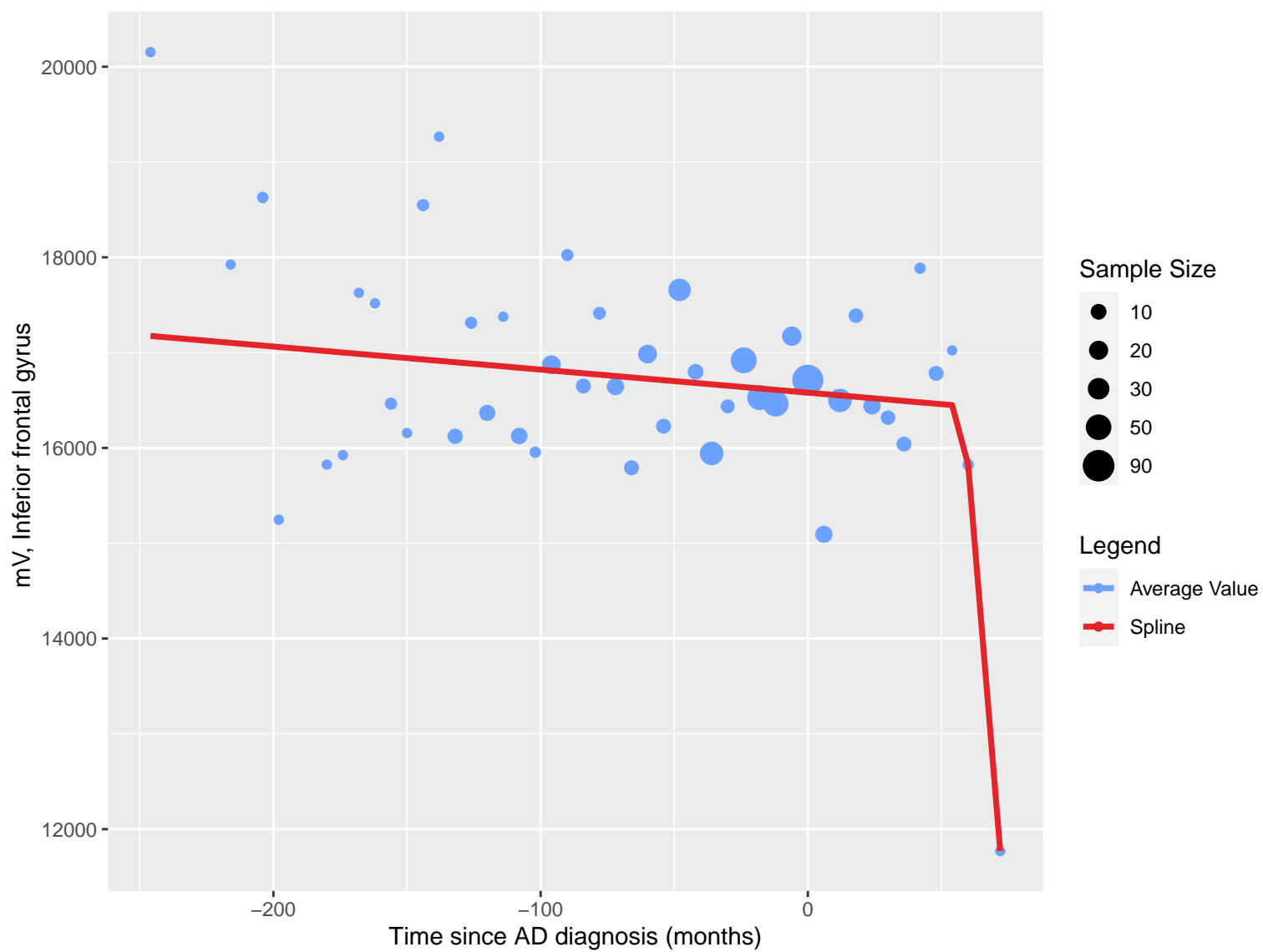


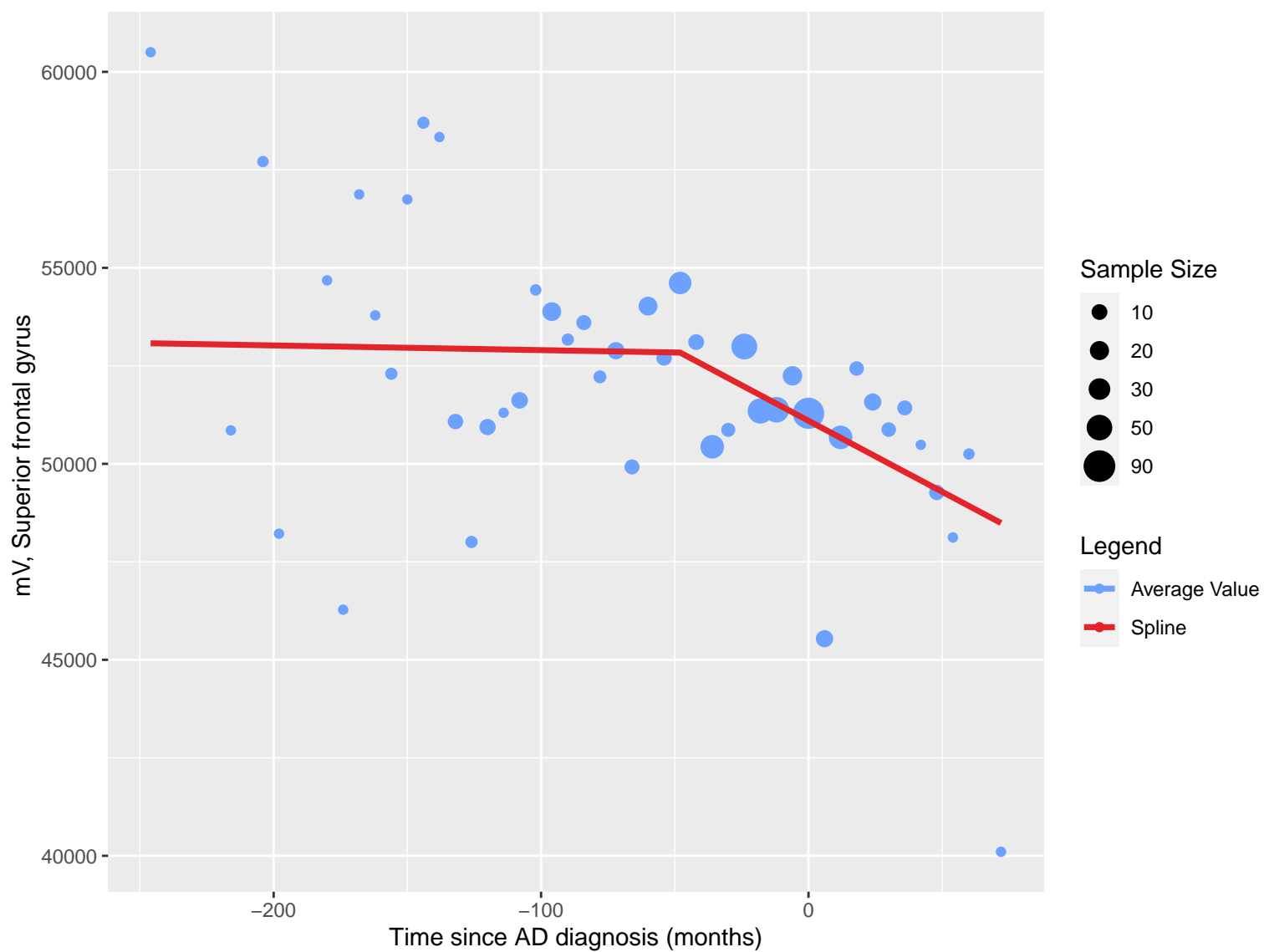


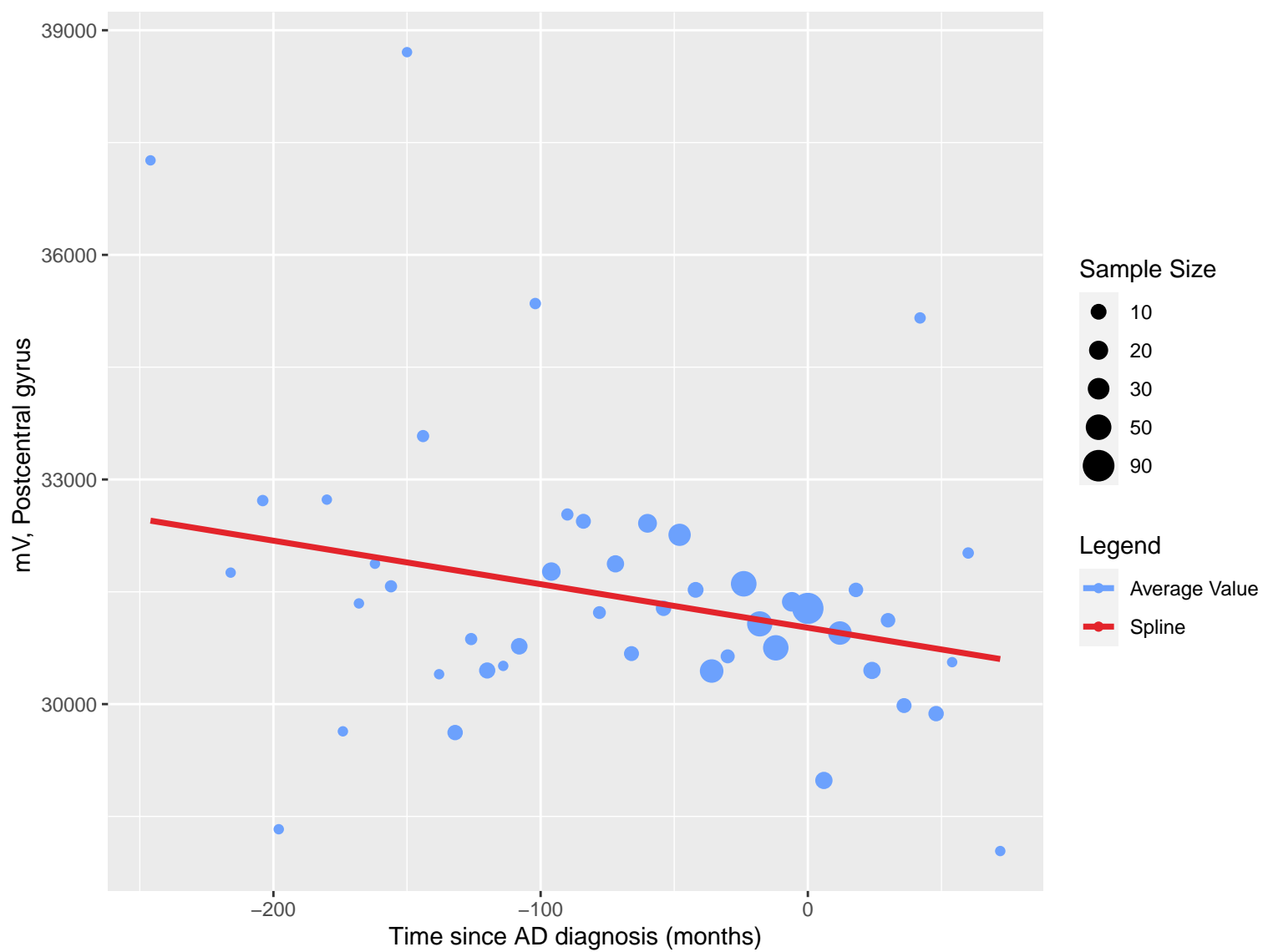


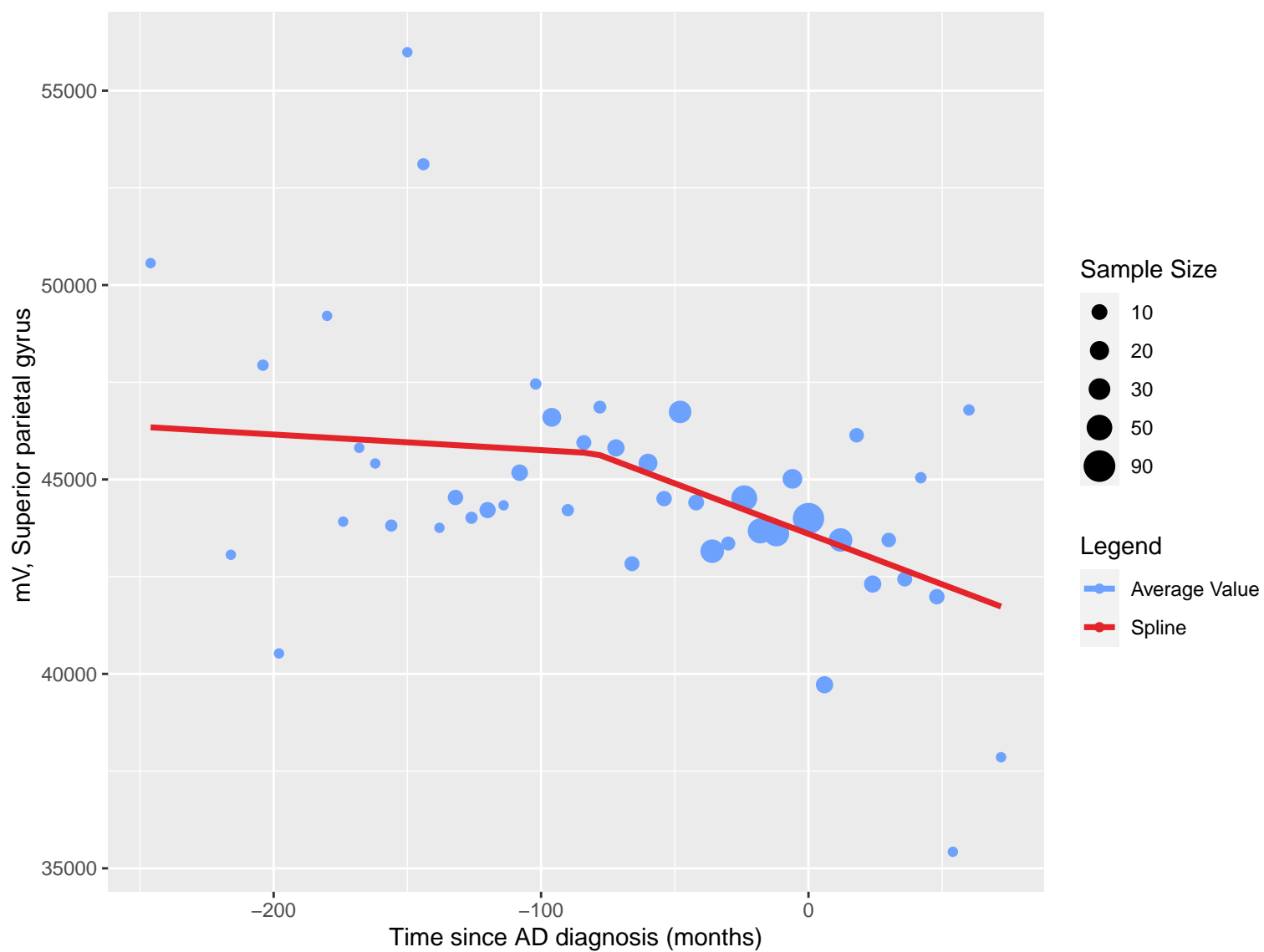


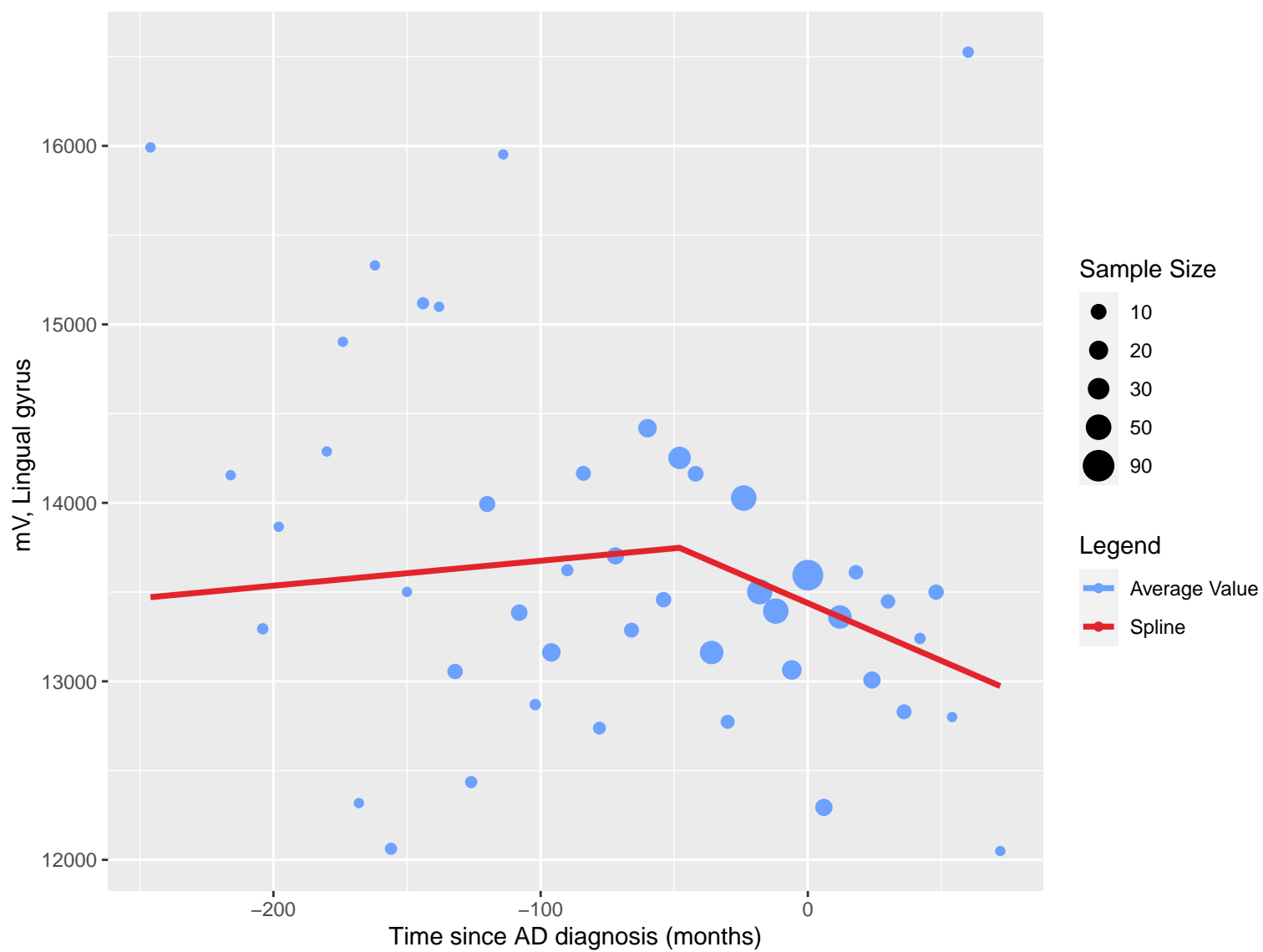


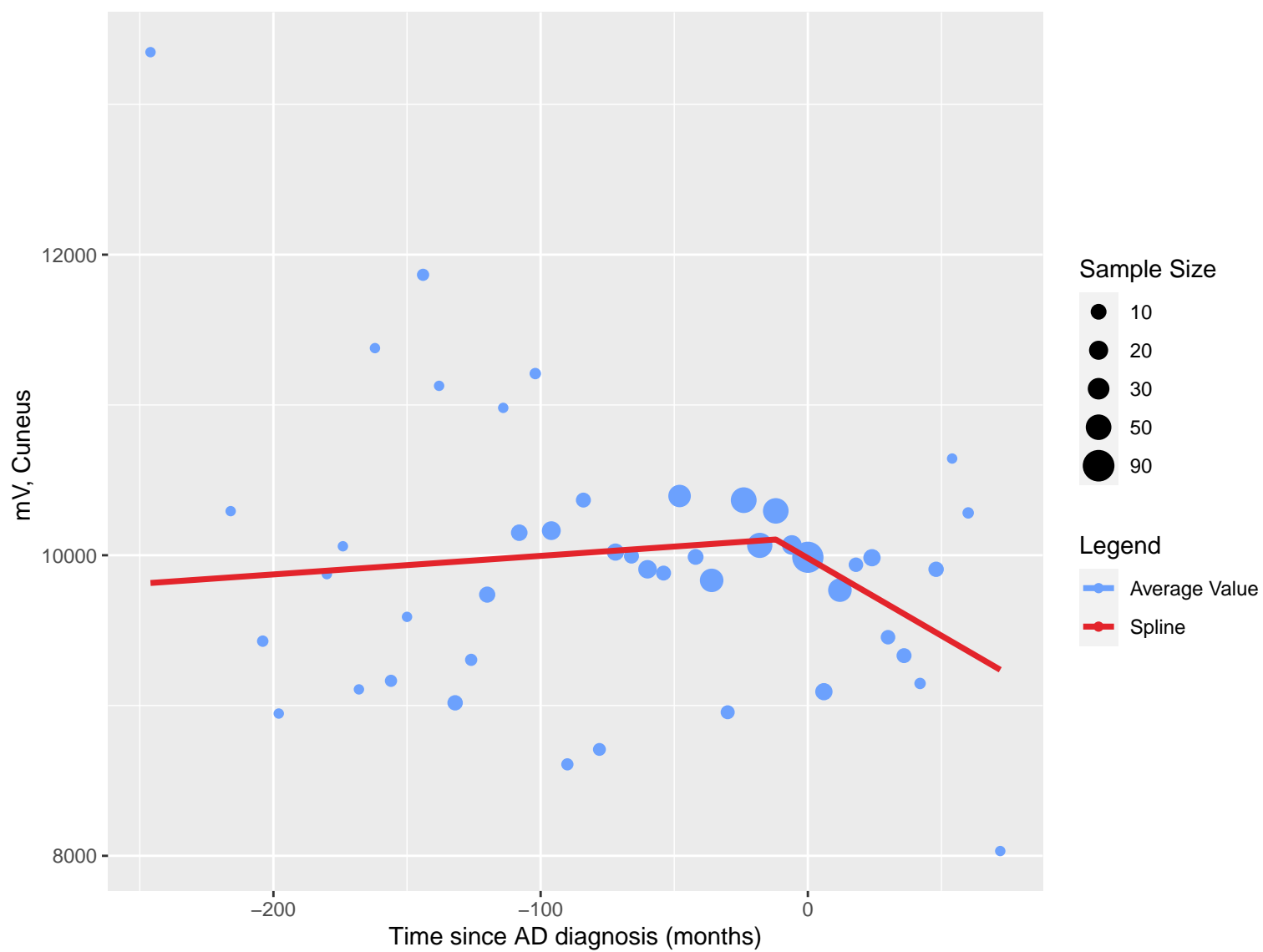


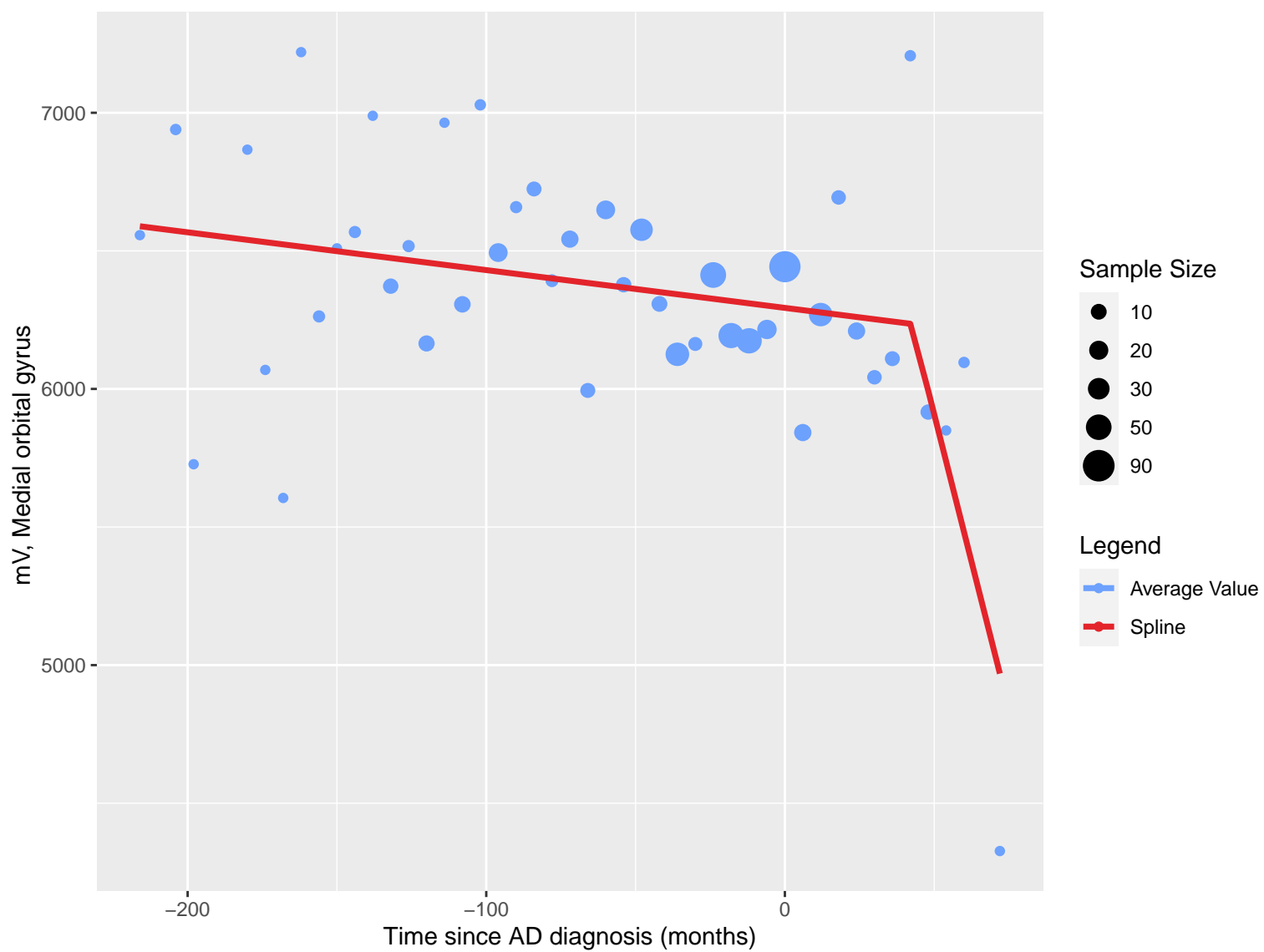


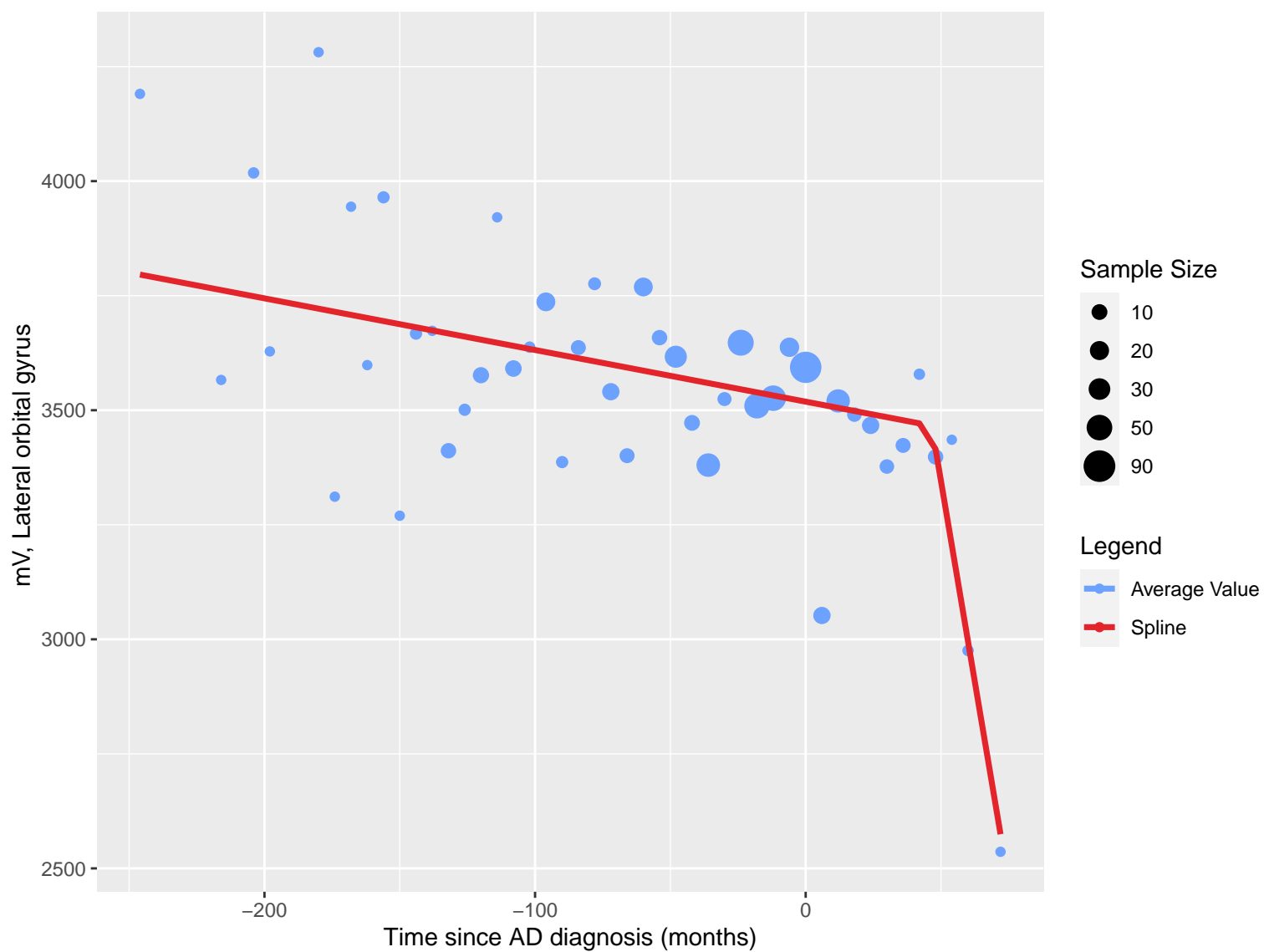




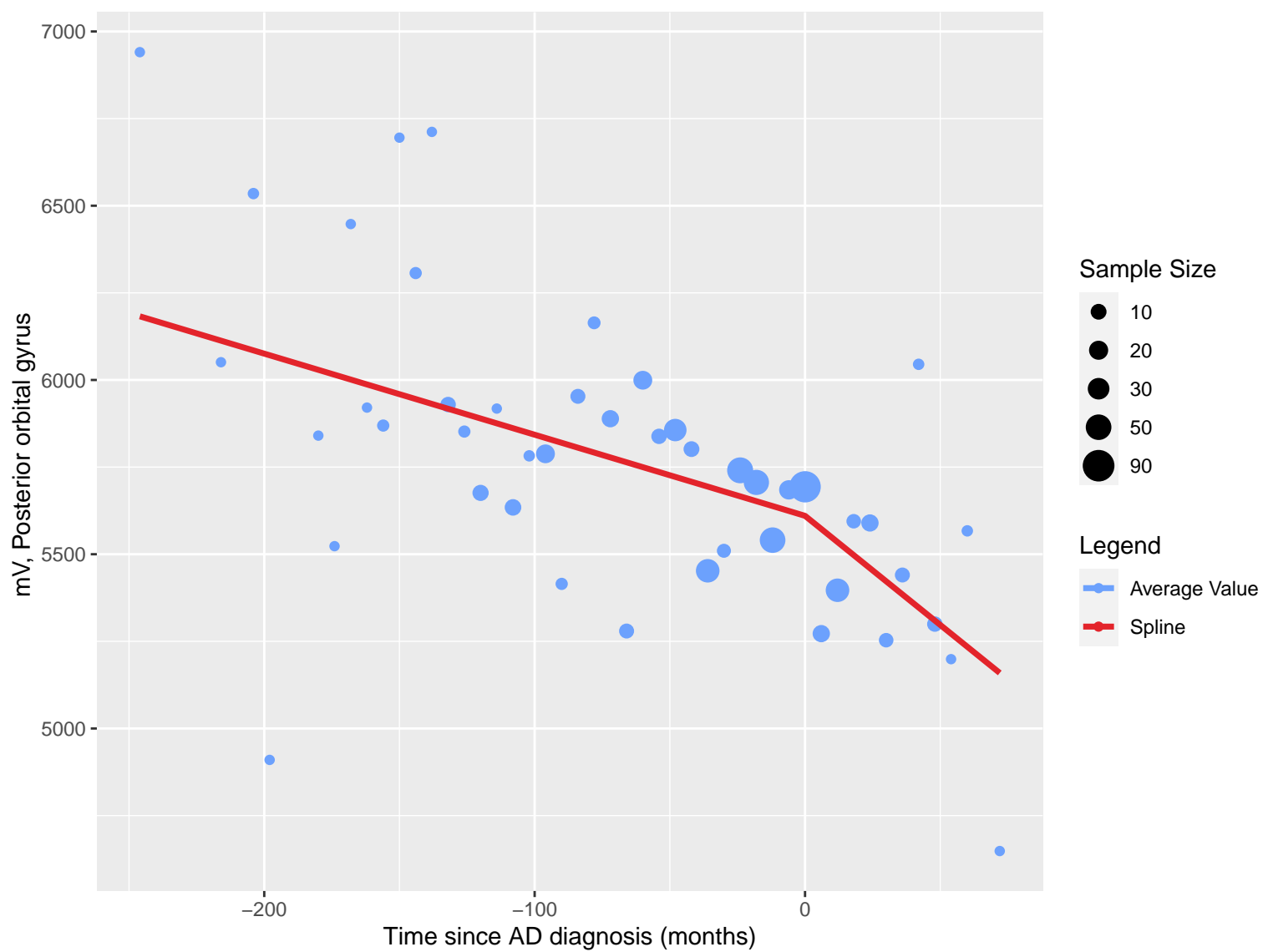


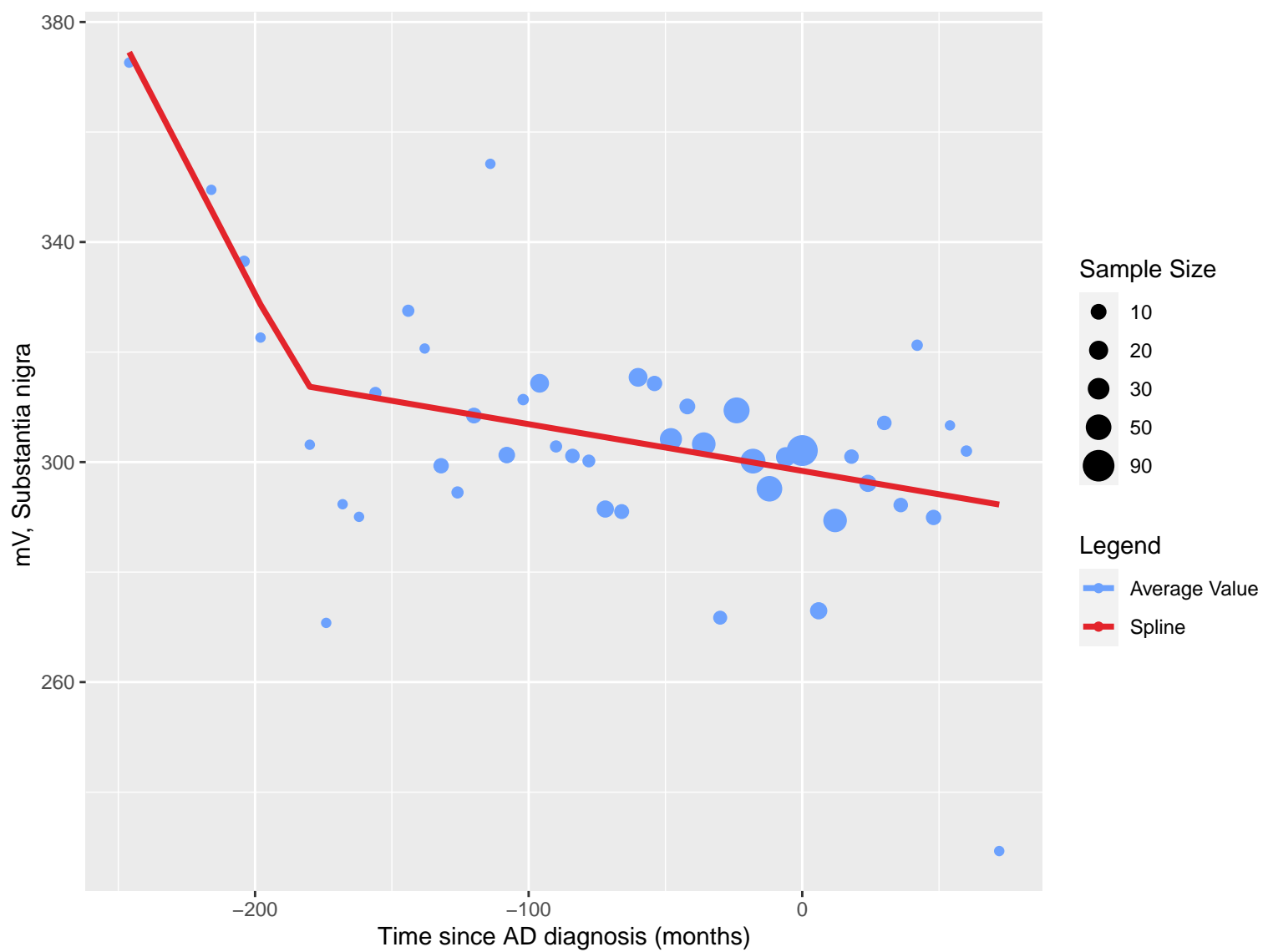


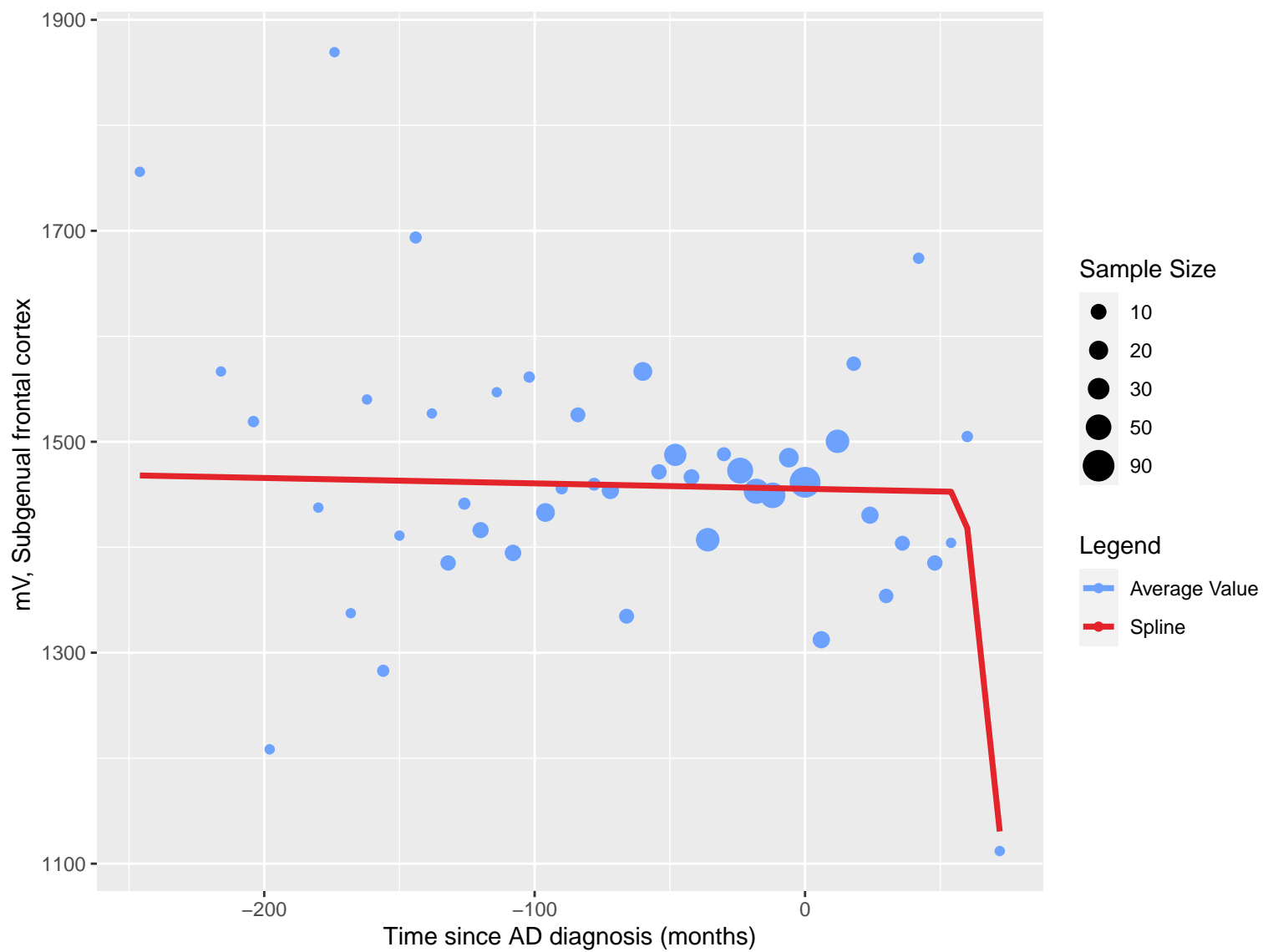


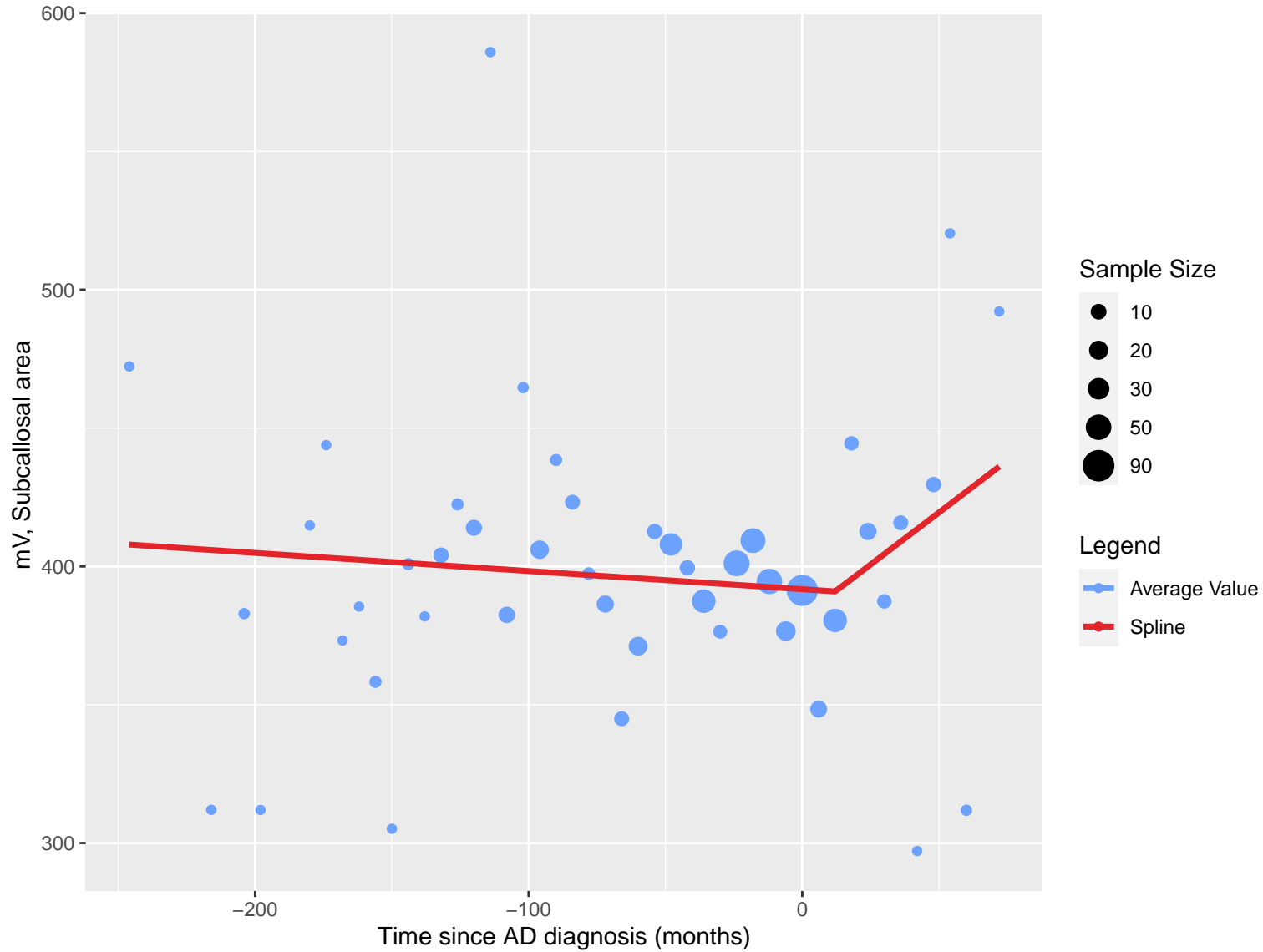


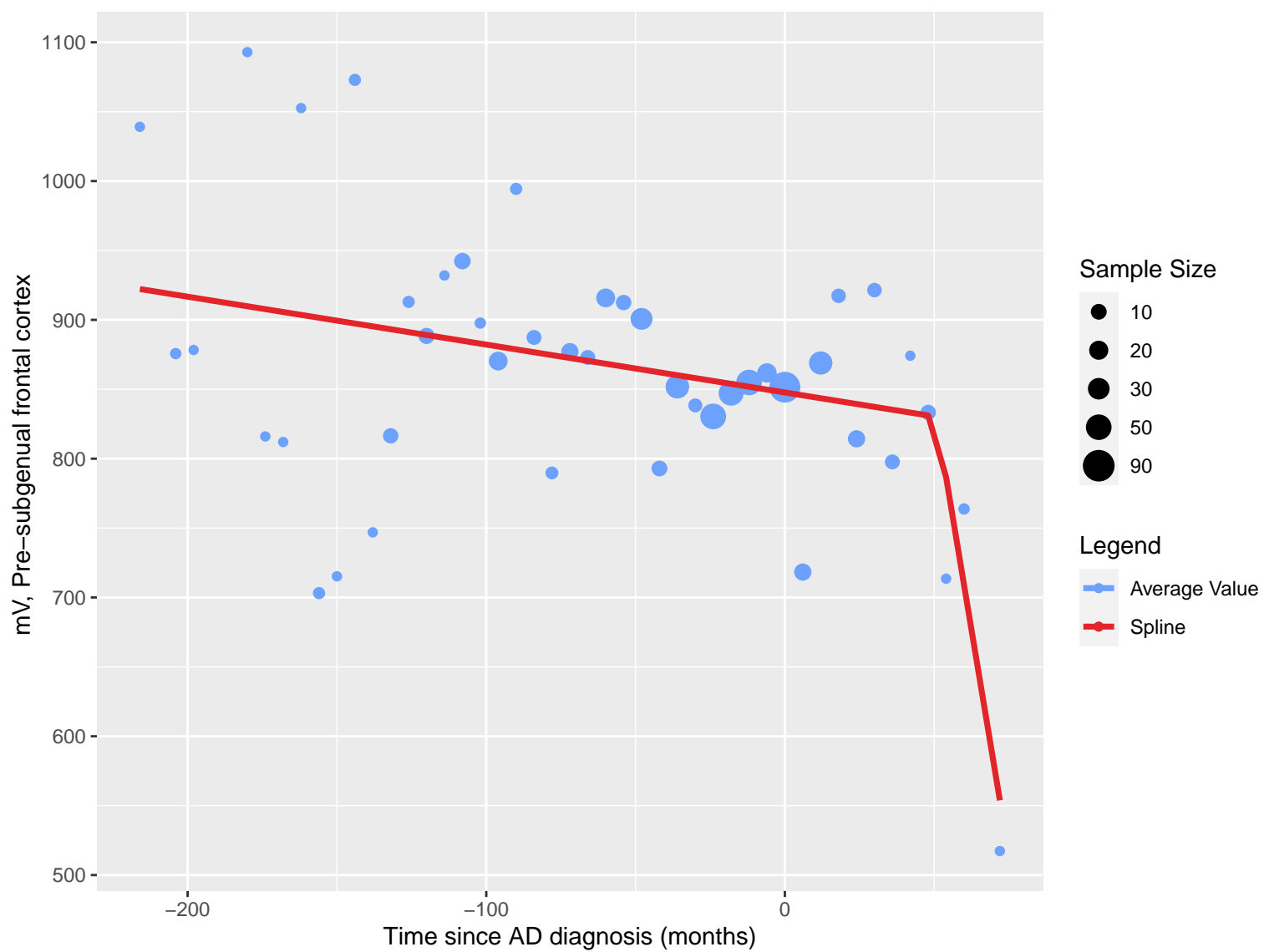


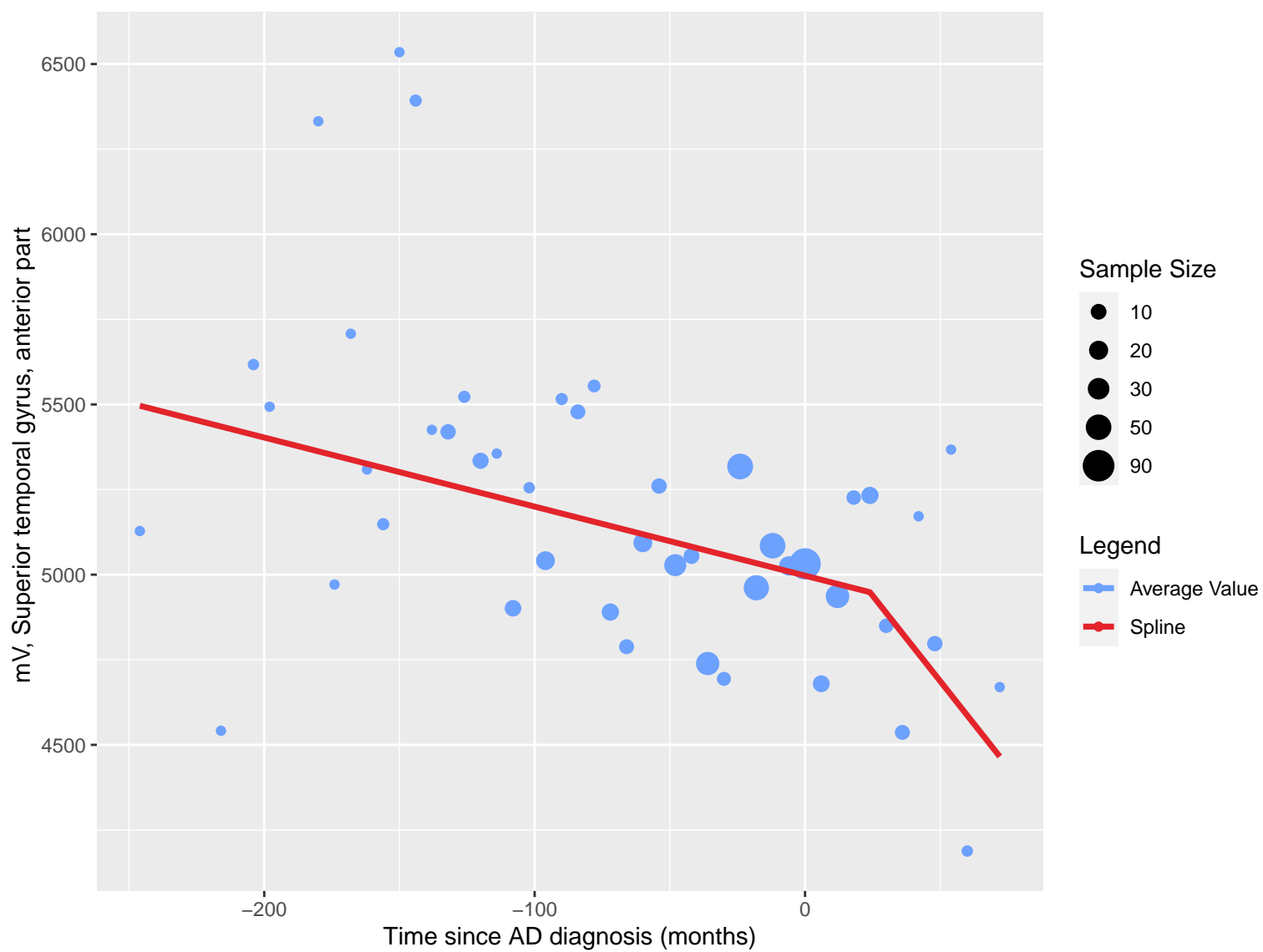


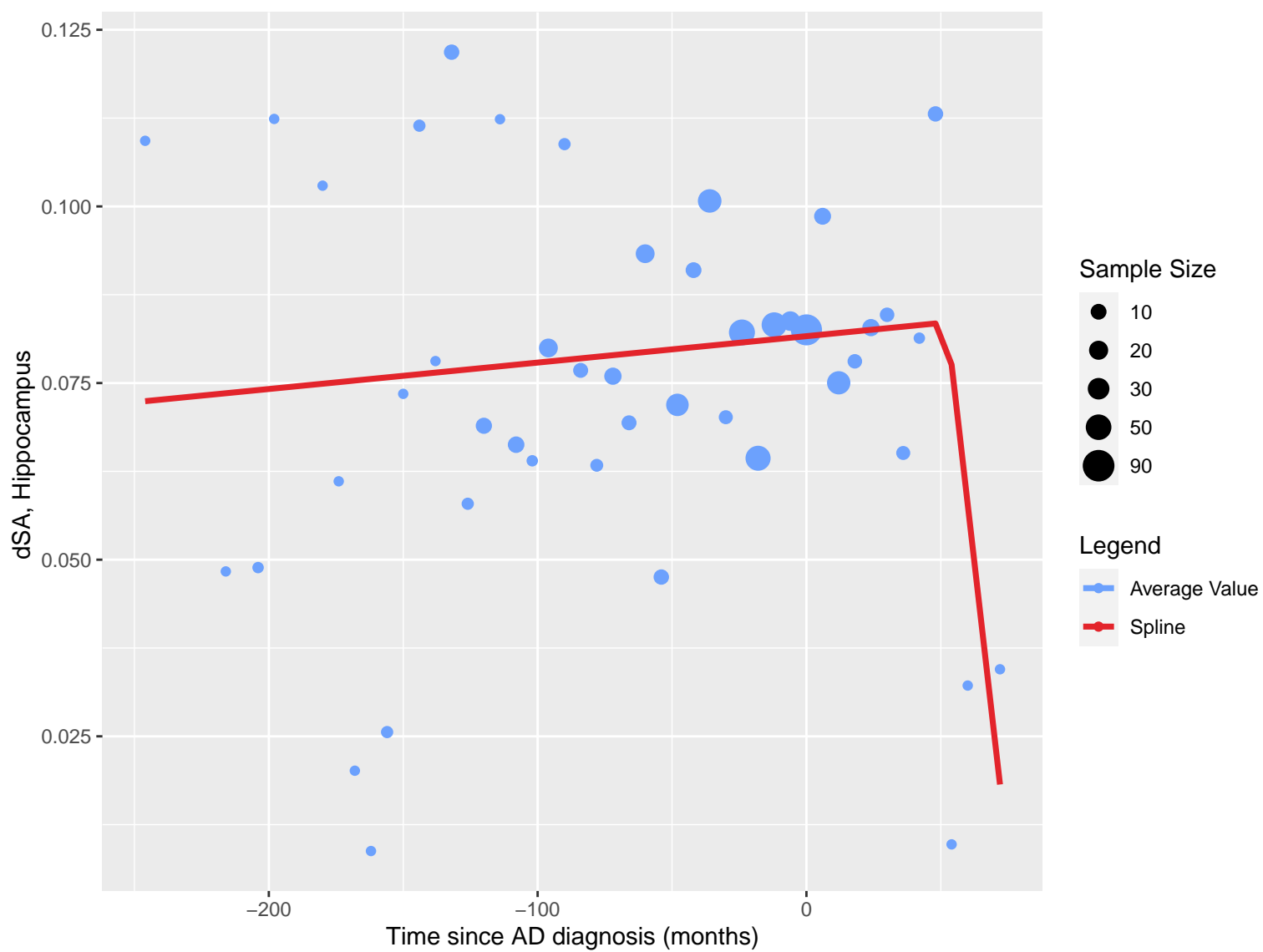


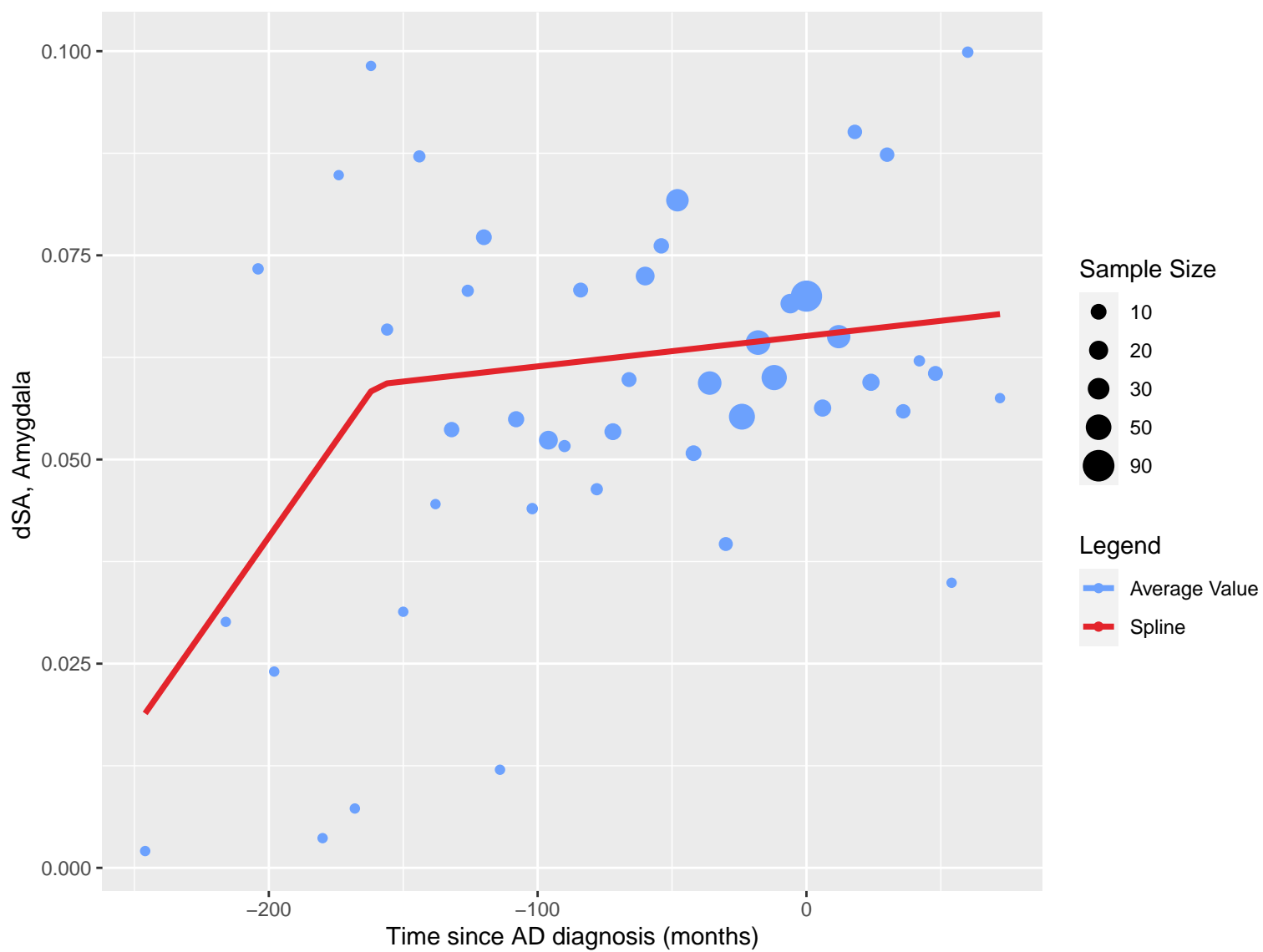




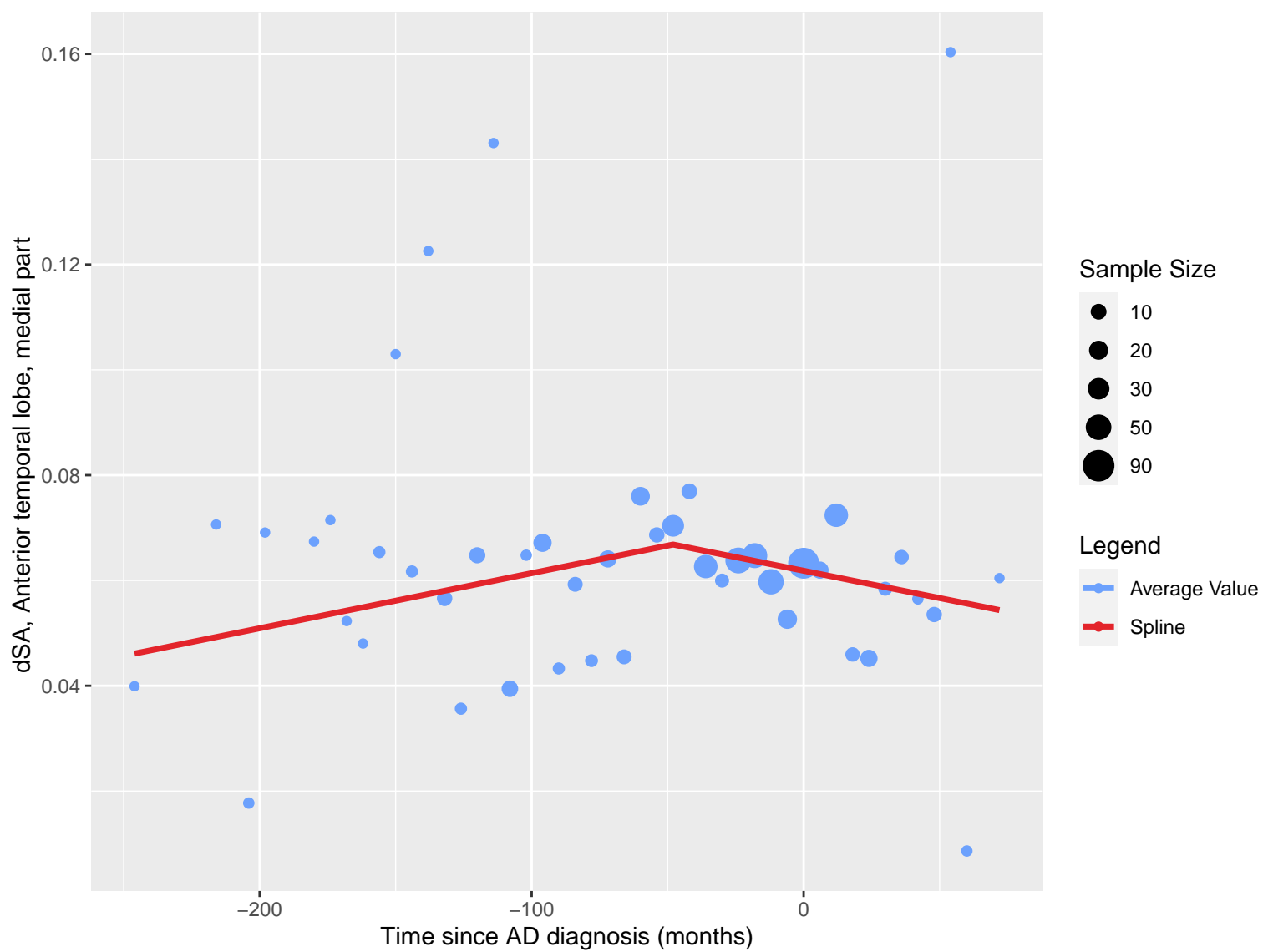


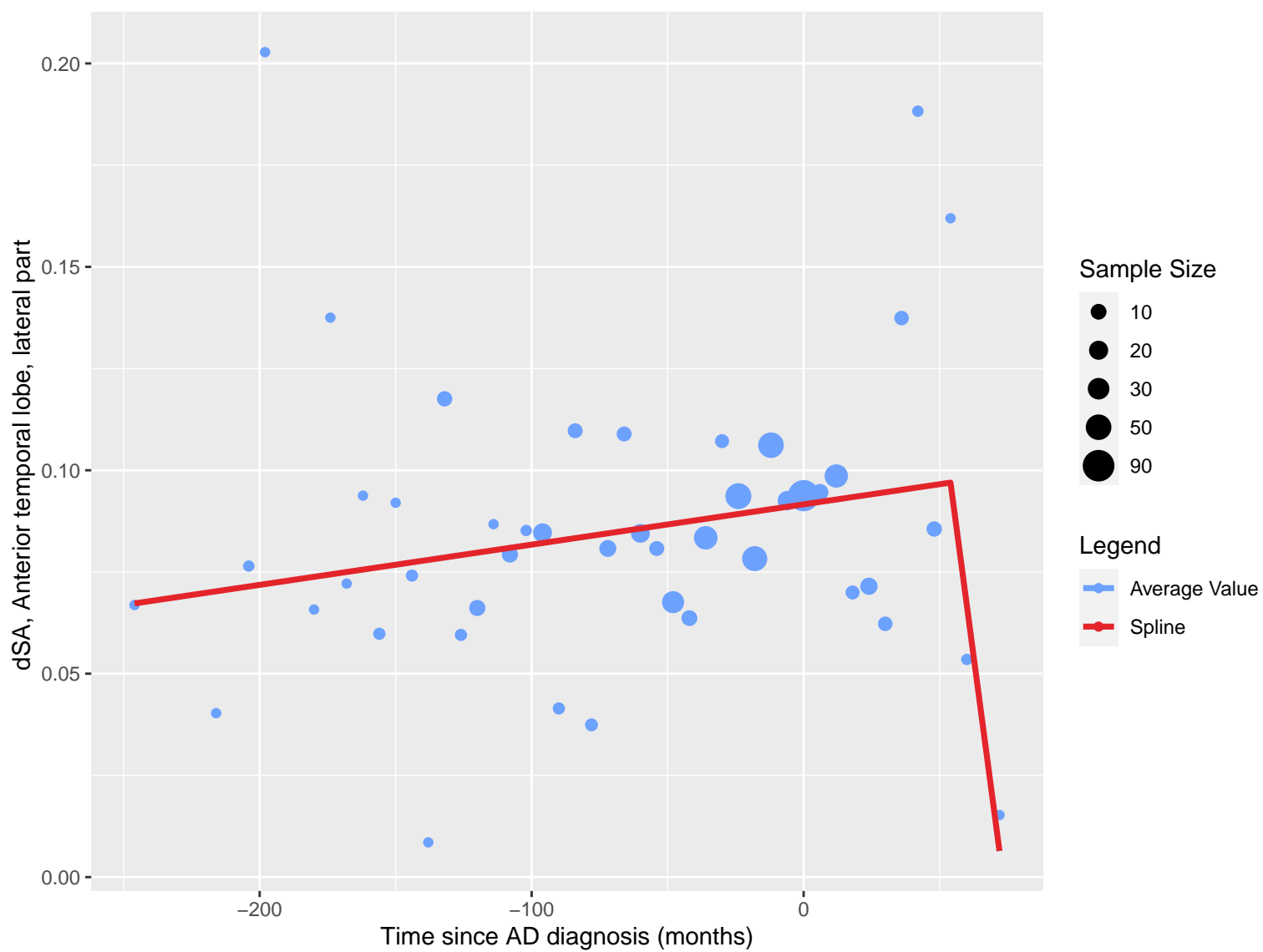












dSA, Gyri parahippocampalis et ambiens

0.100

0.075

0.050

0.025

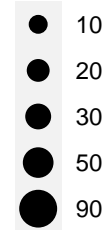
-200

-100

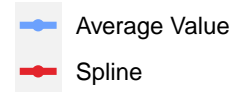
0

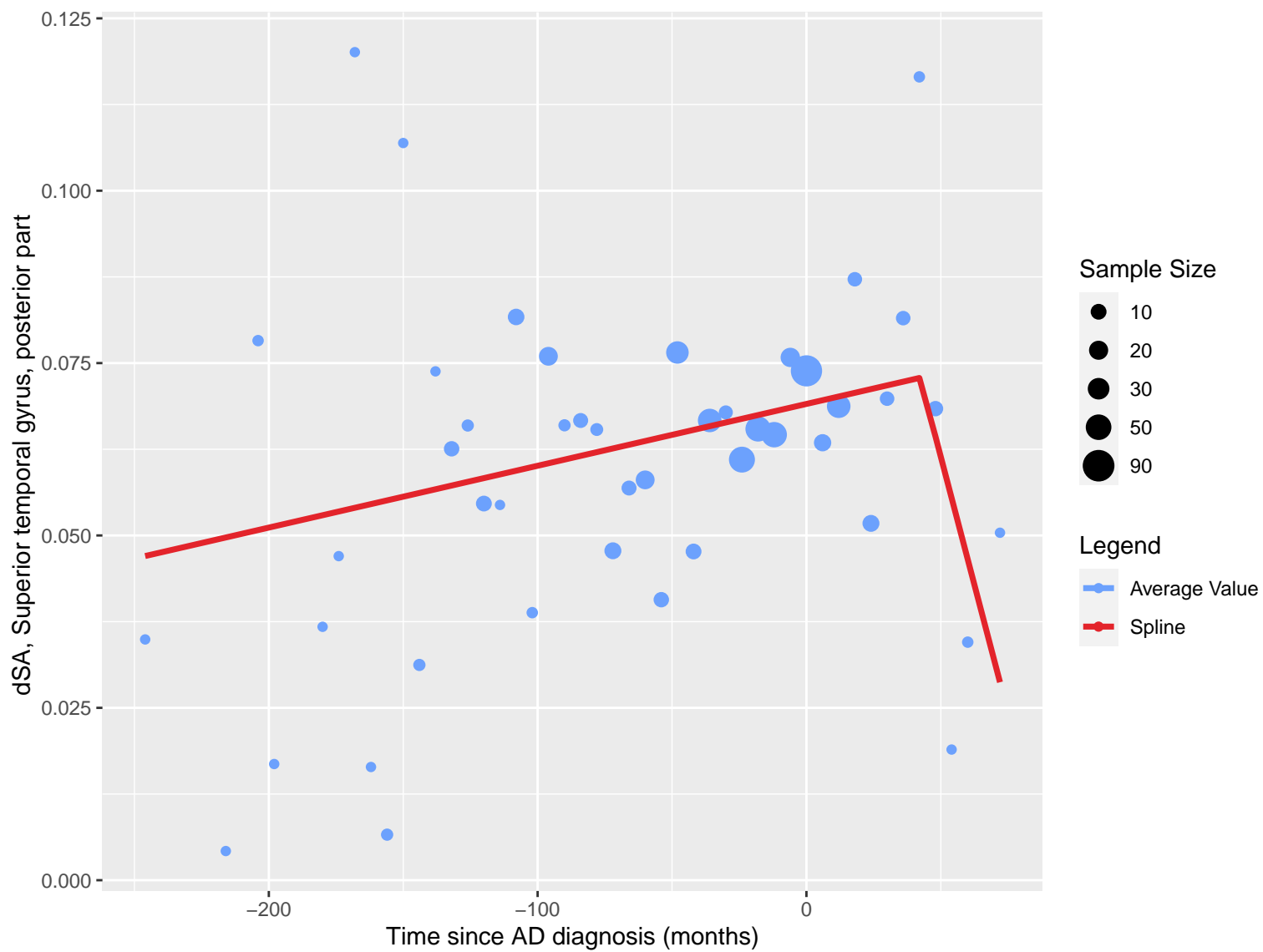
Time since AD diagnosis (months)

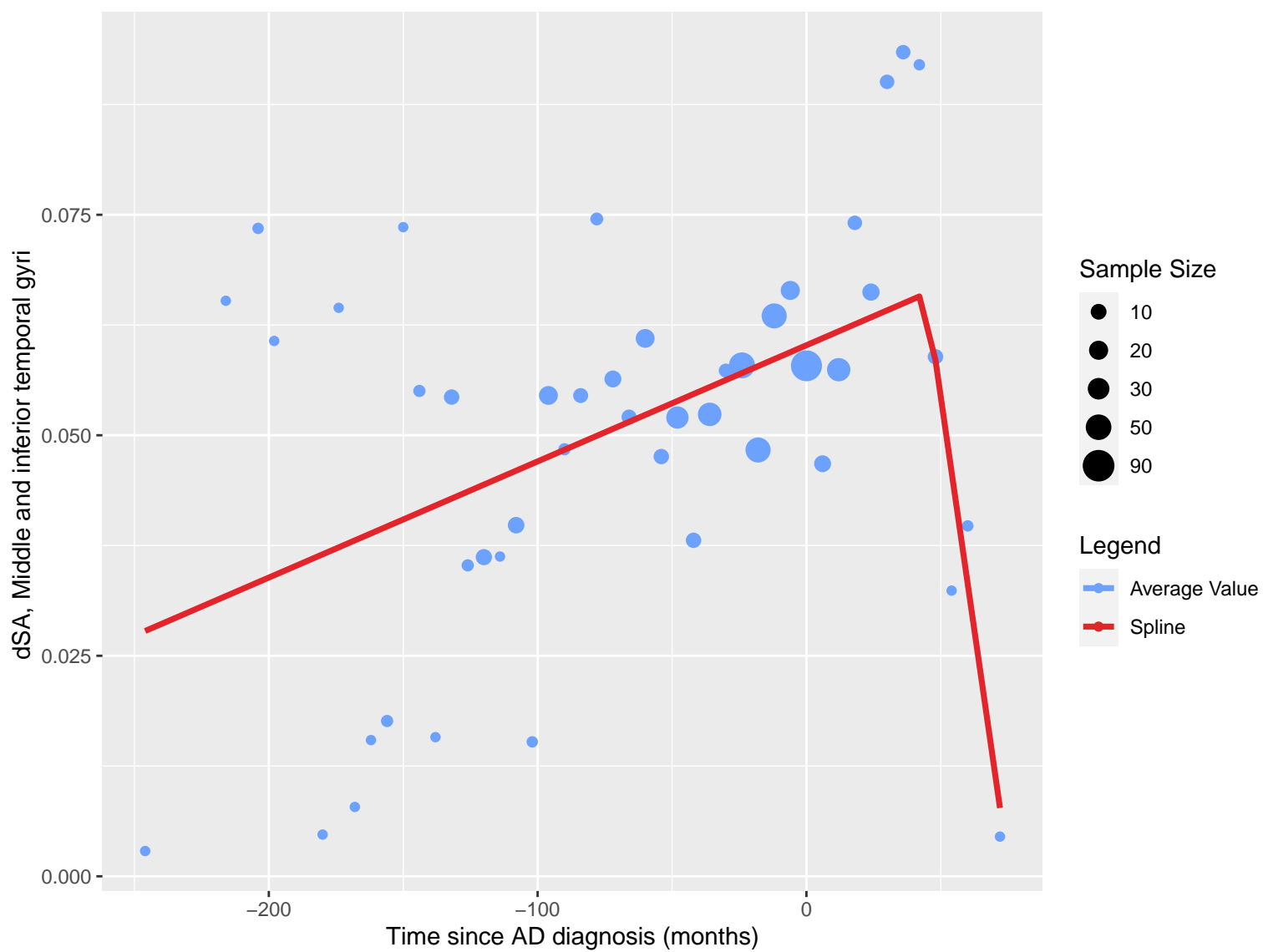
Sample Size

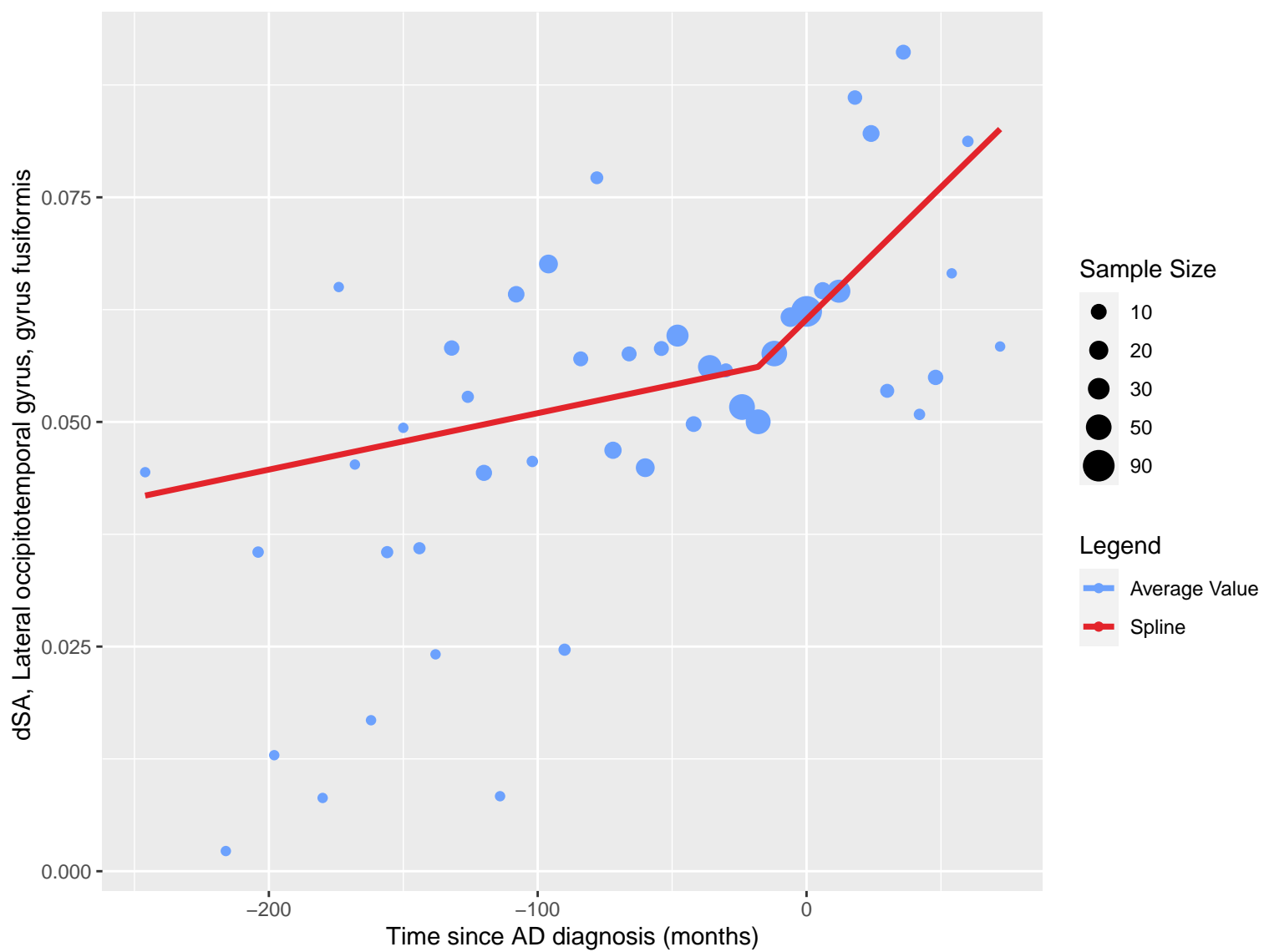


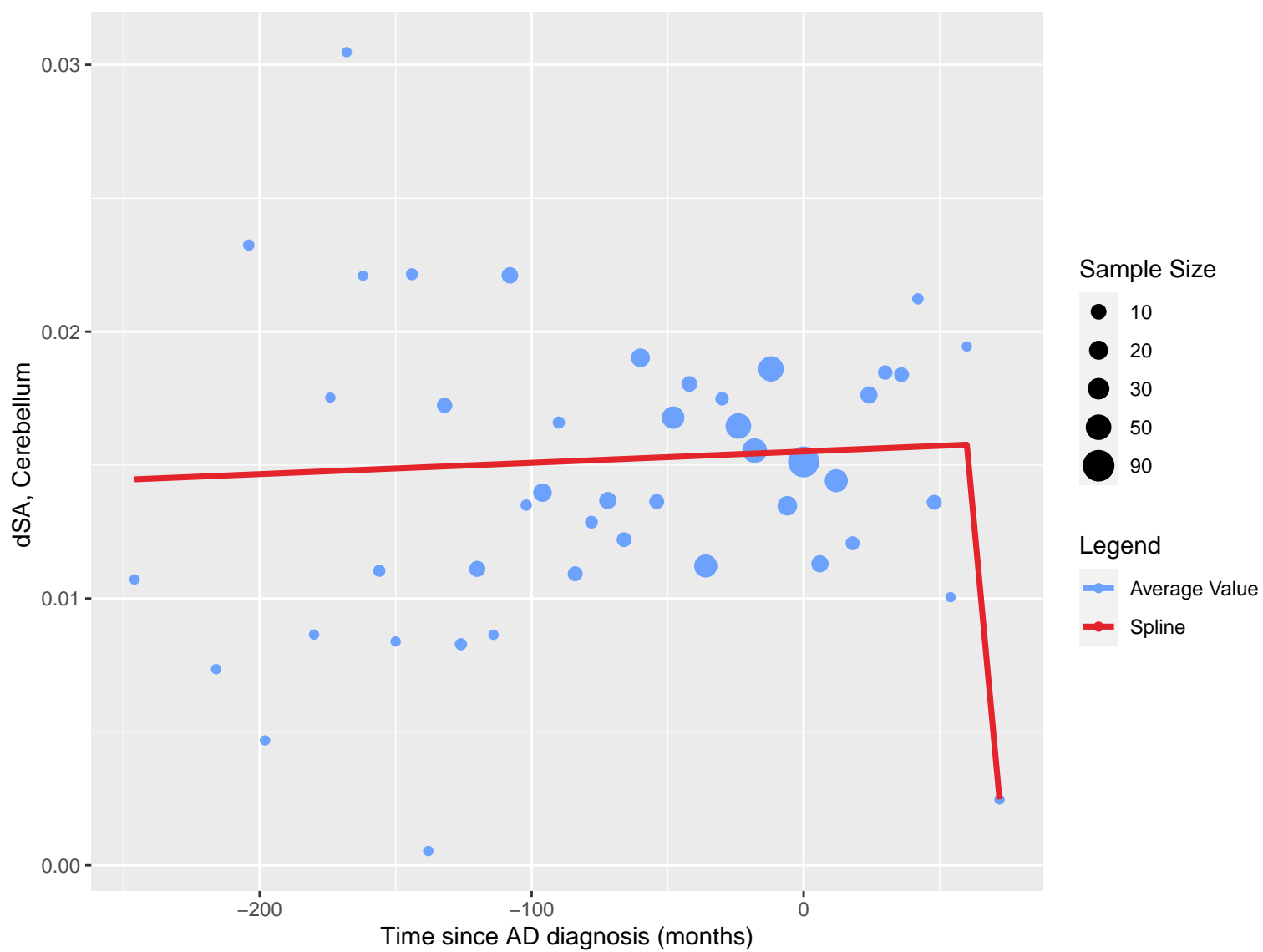
Legend

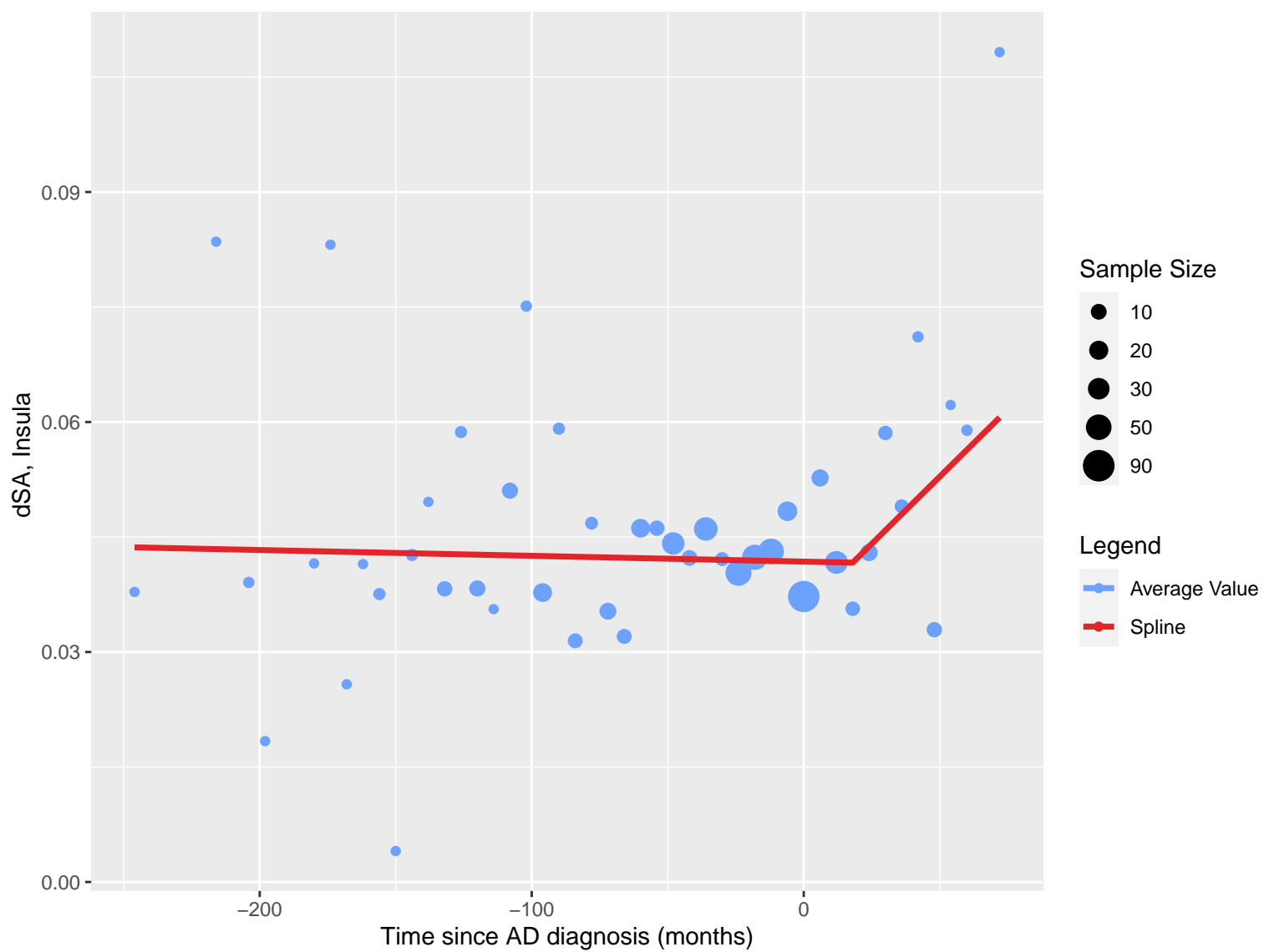




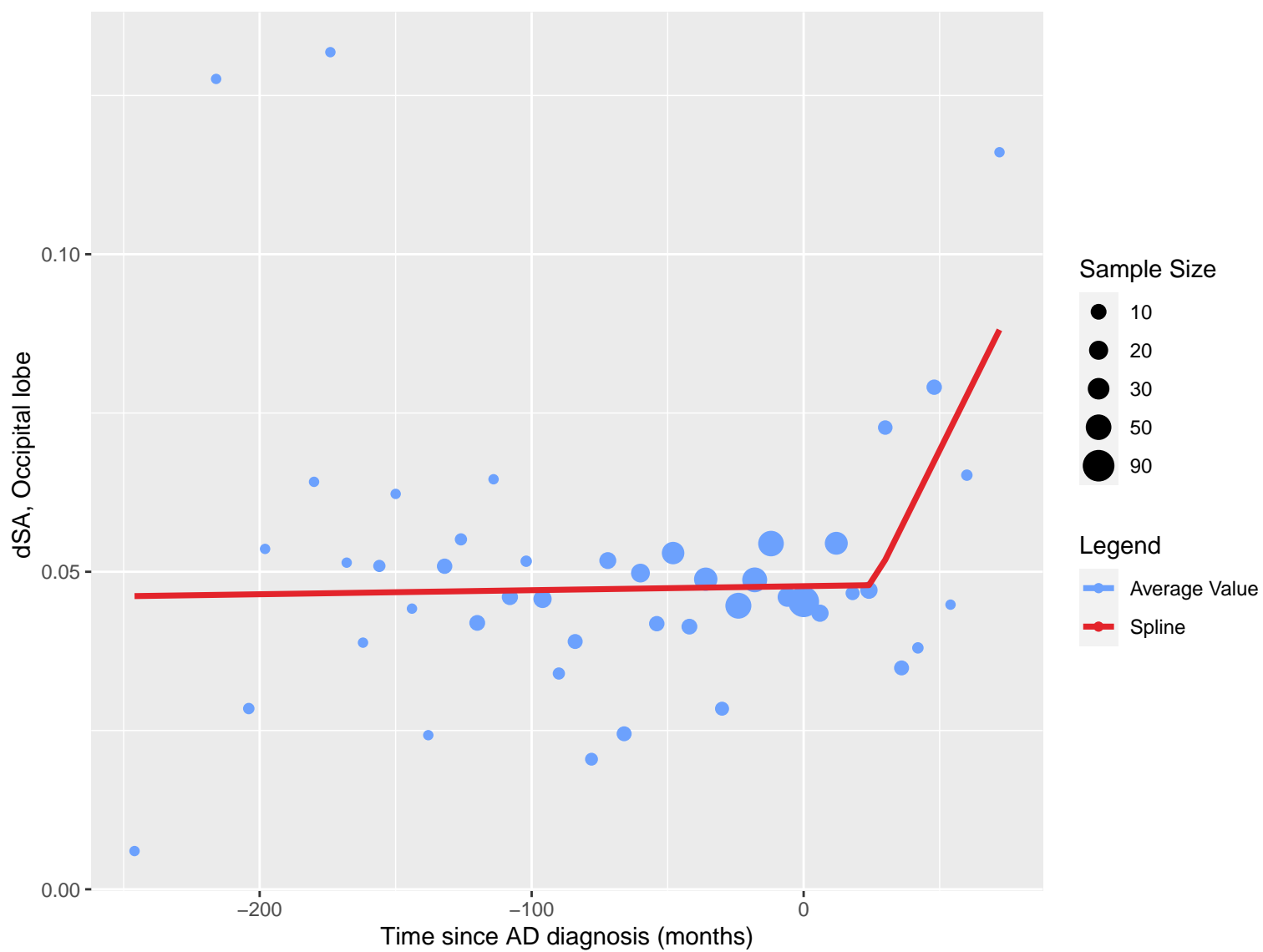


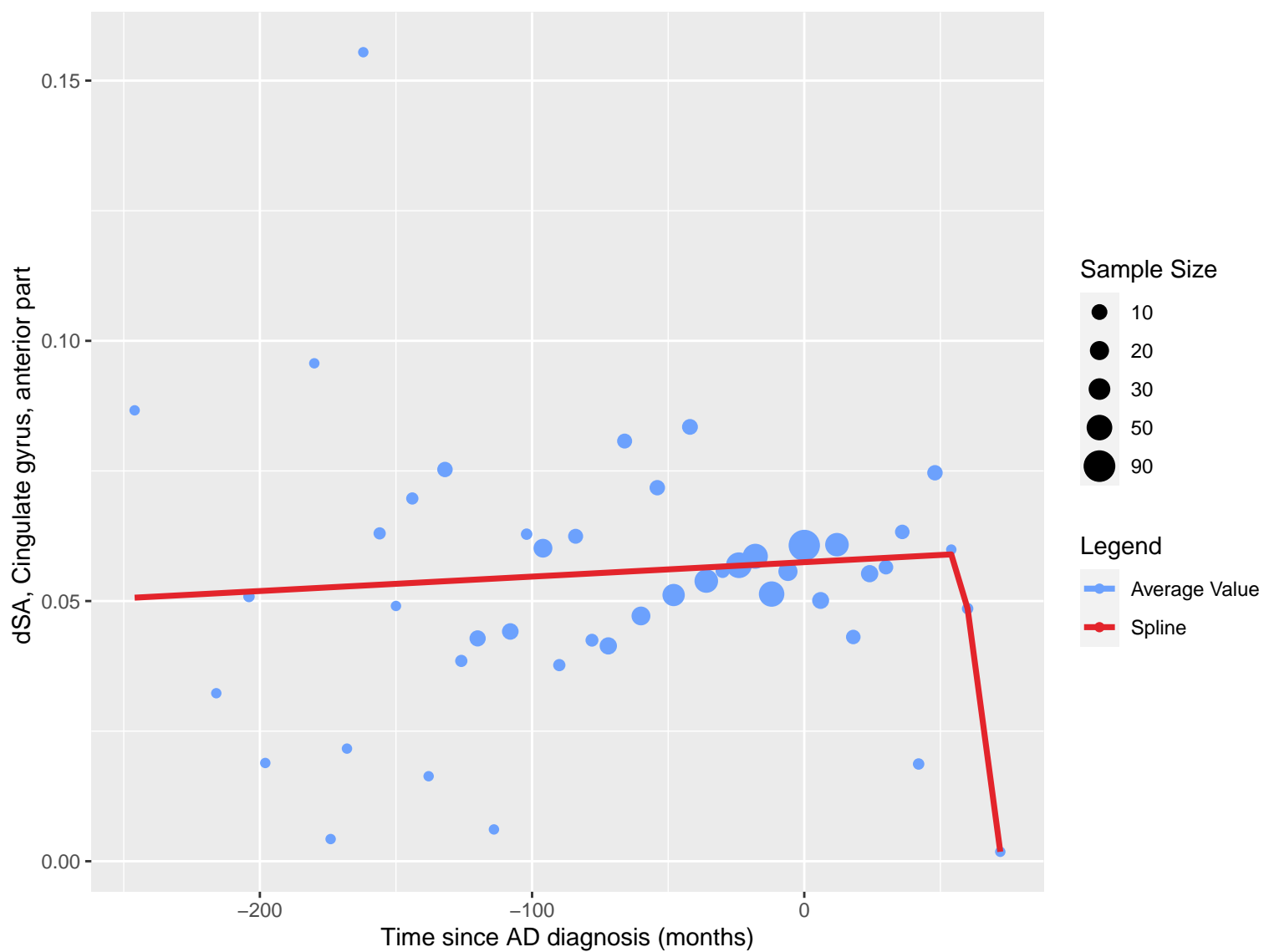












dSA, Cingulate gyrus, posterior part

0.08

0.06

0.04

0.02

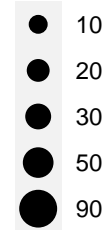
-200

-100

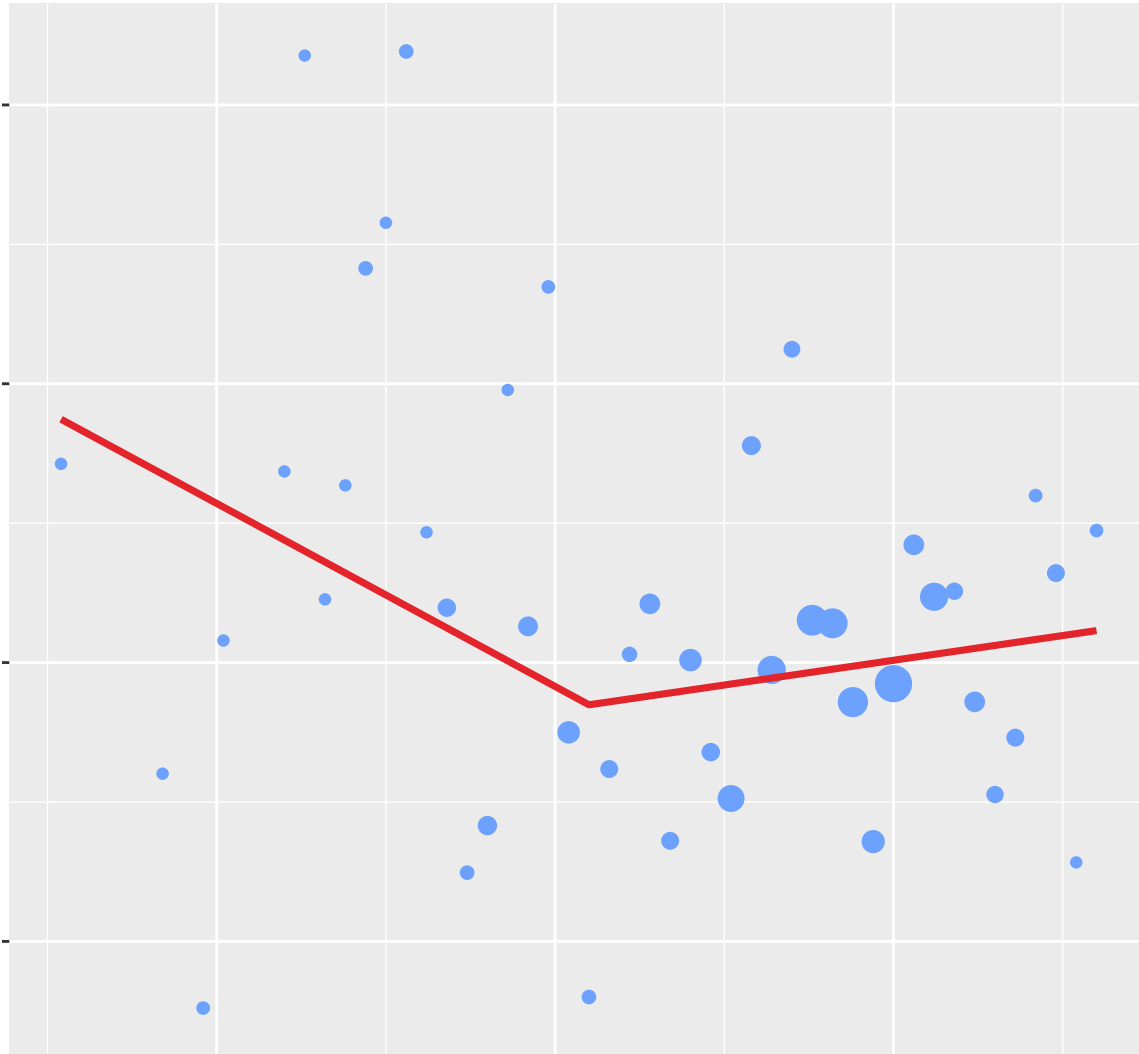
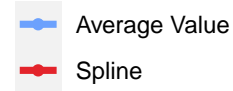
0

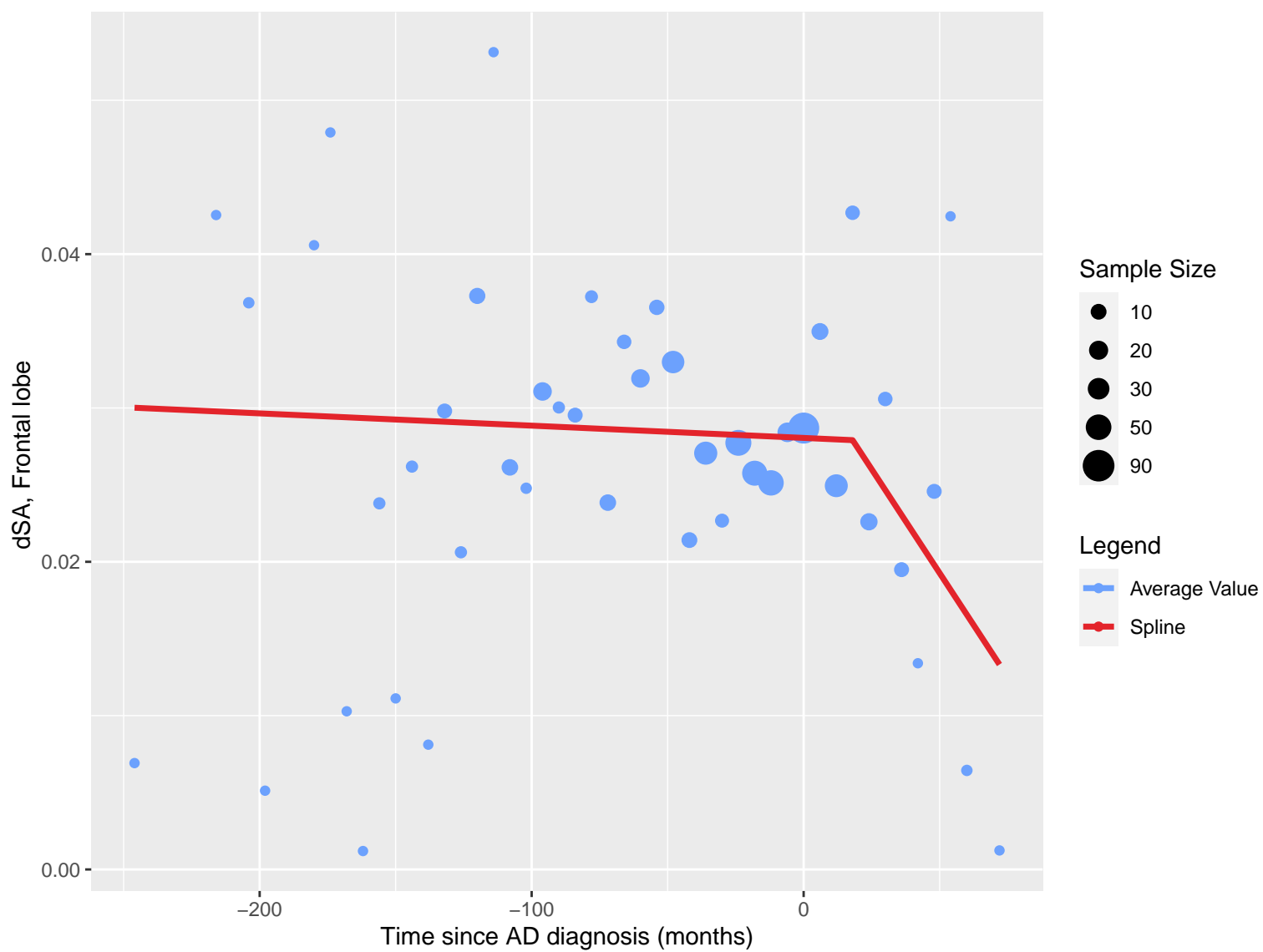
Time since AD diagnosis (months)

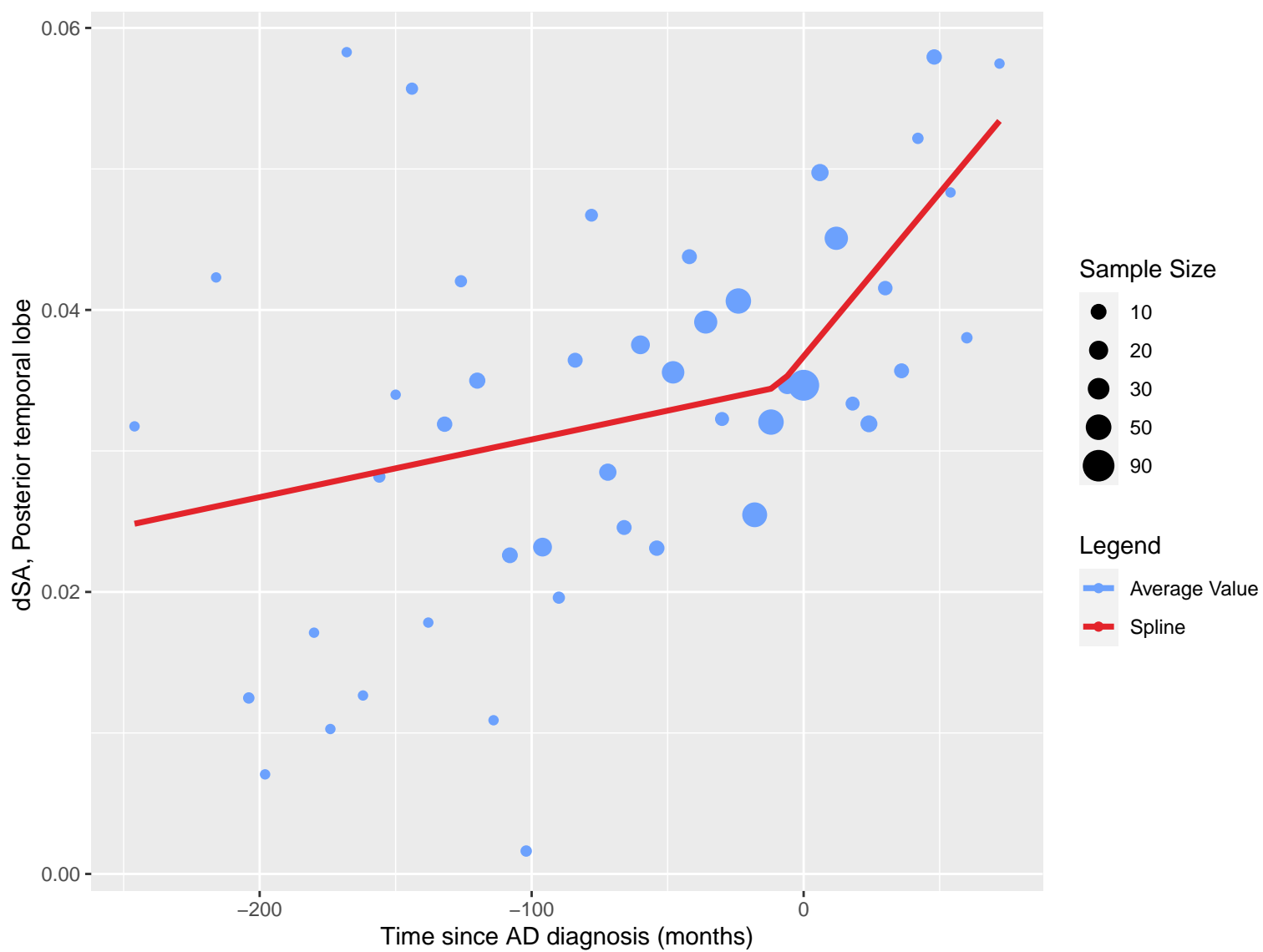
Sample Size

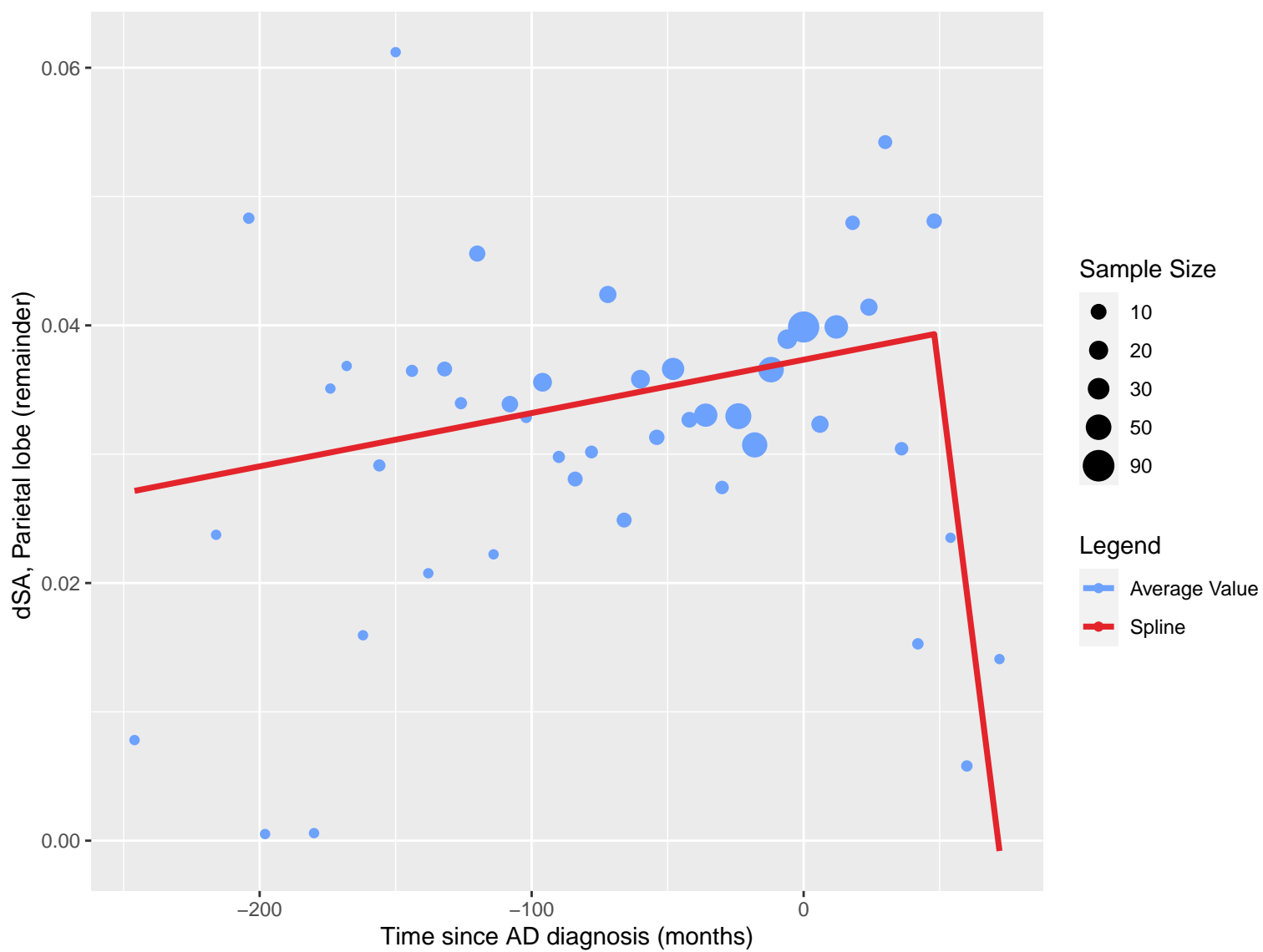


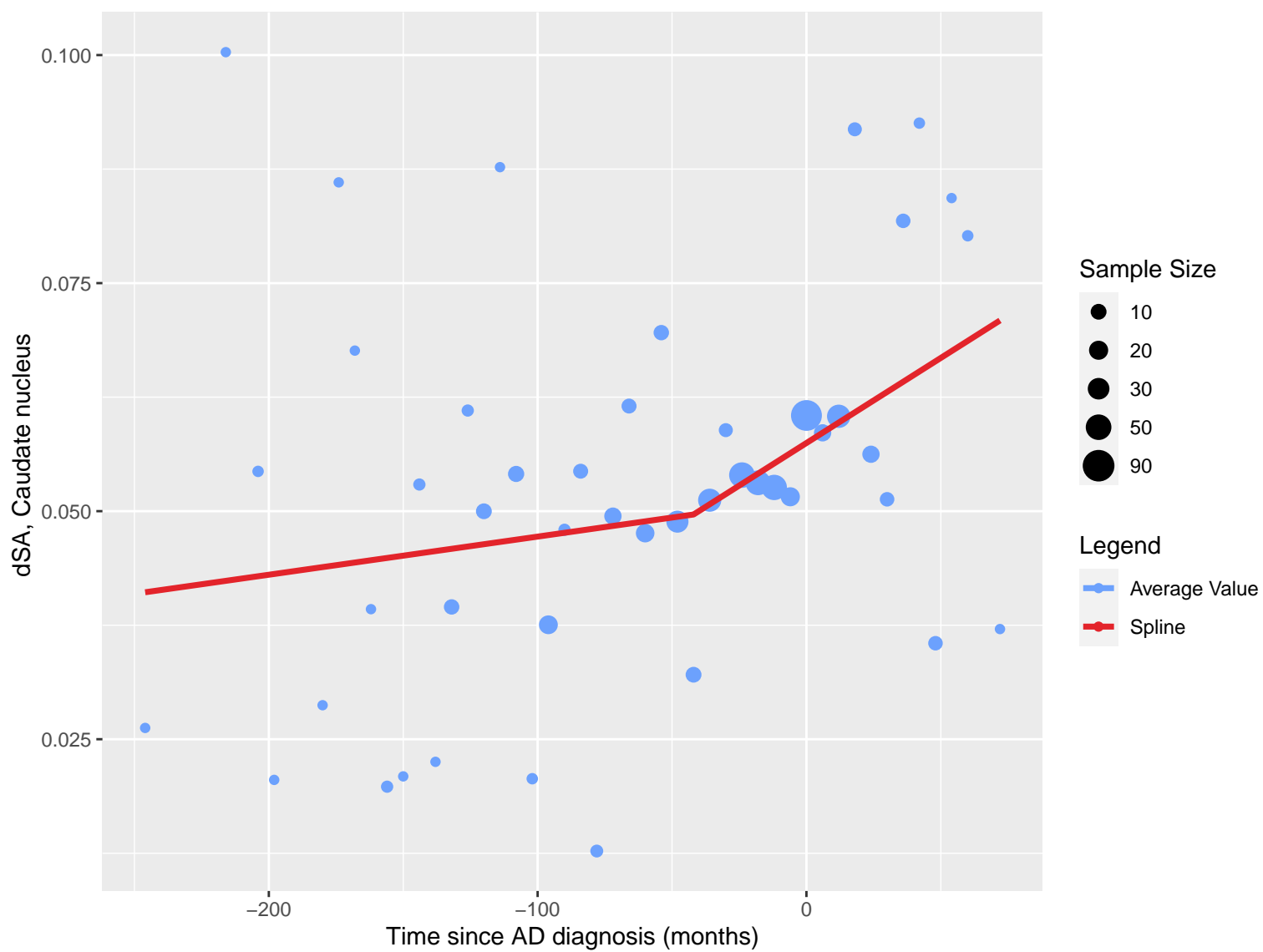
Legend

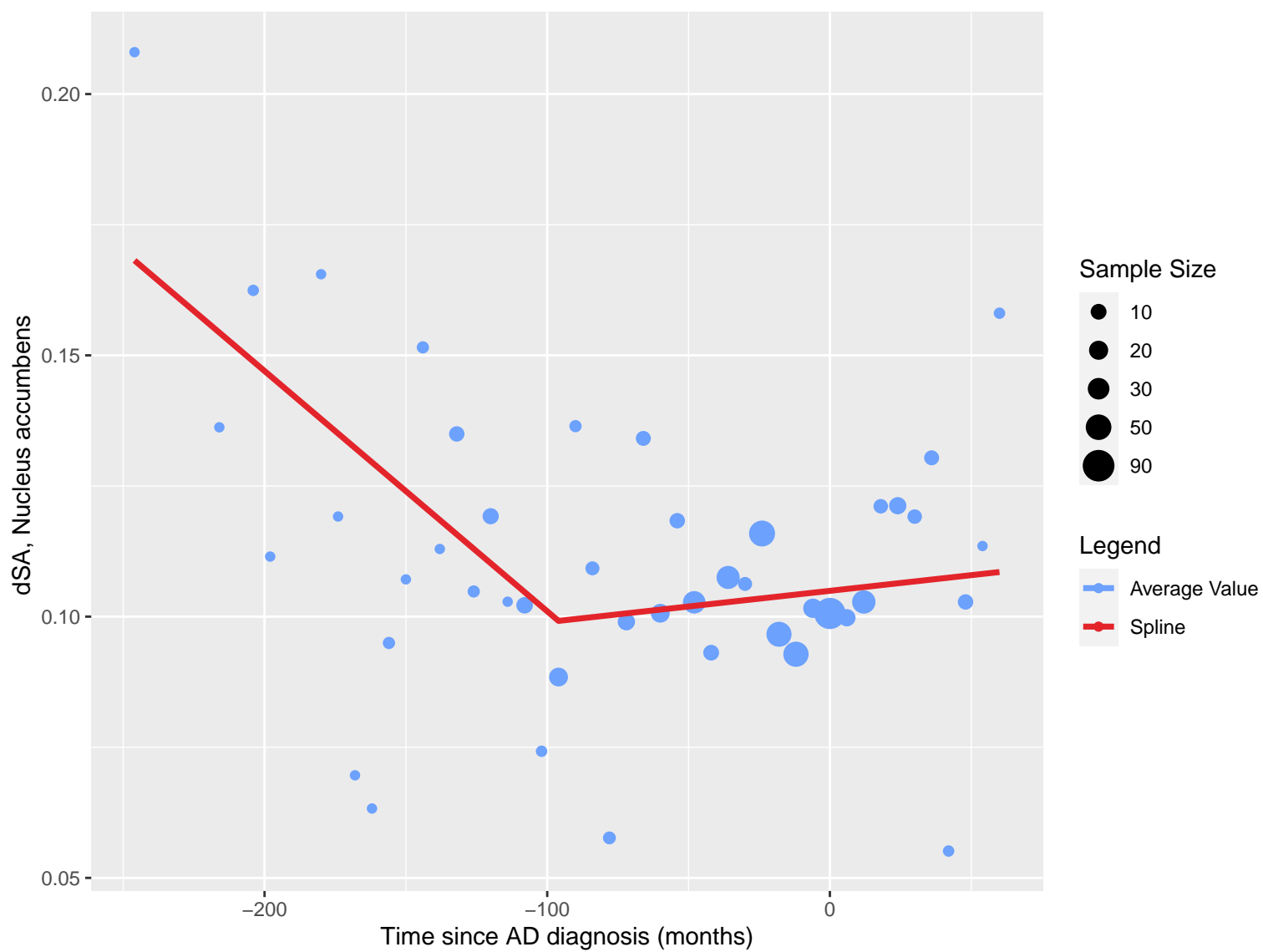




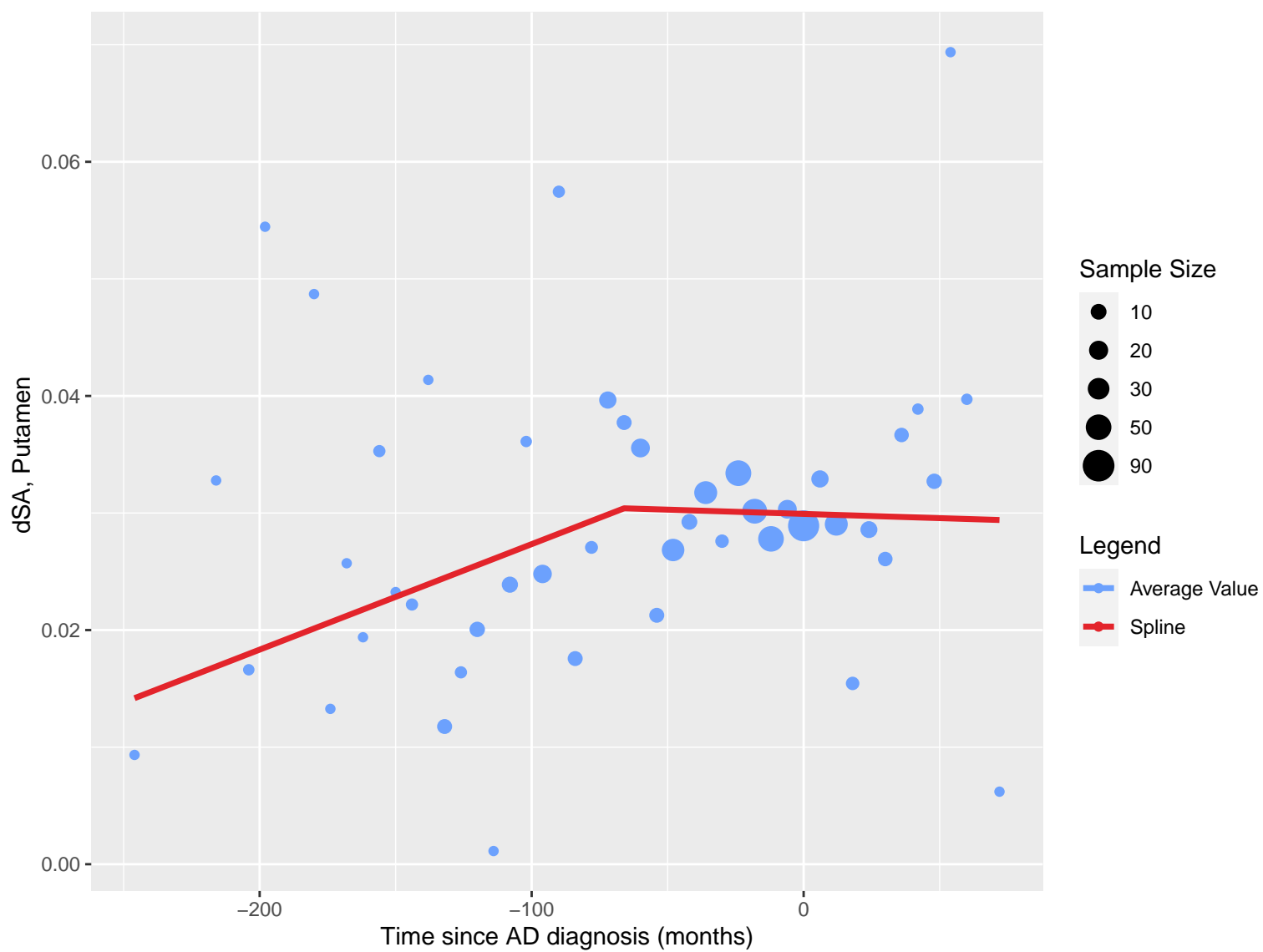


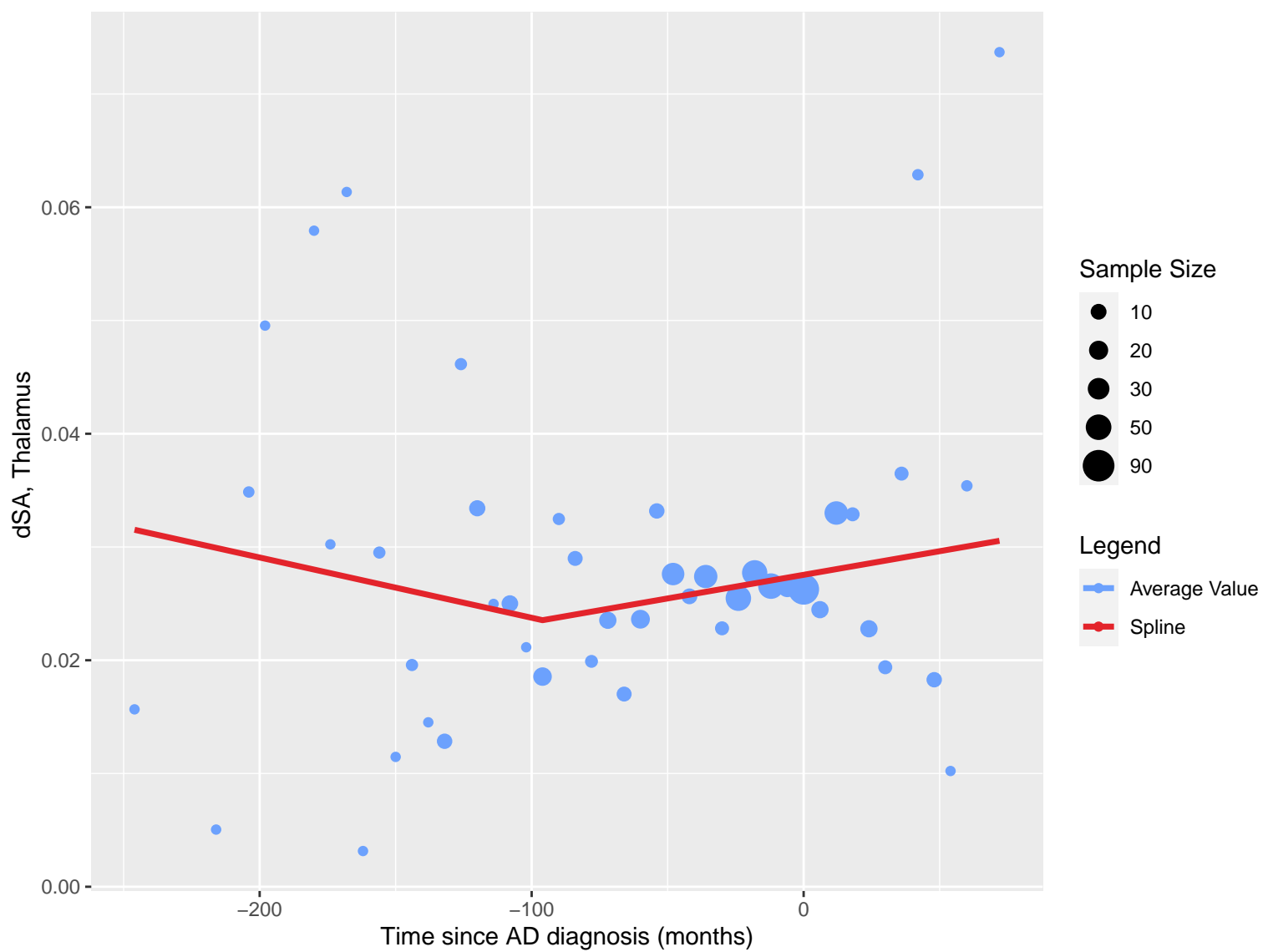


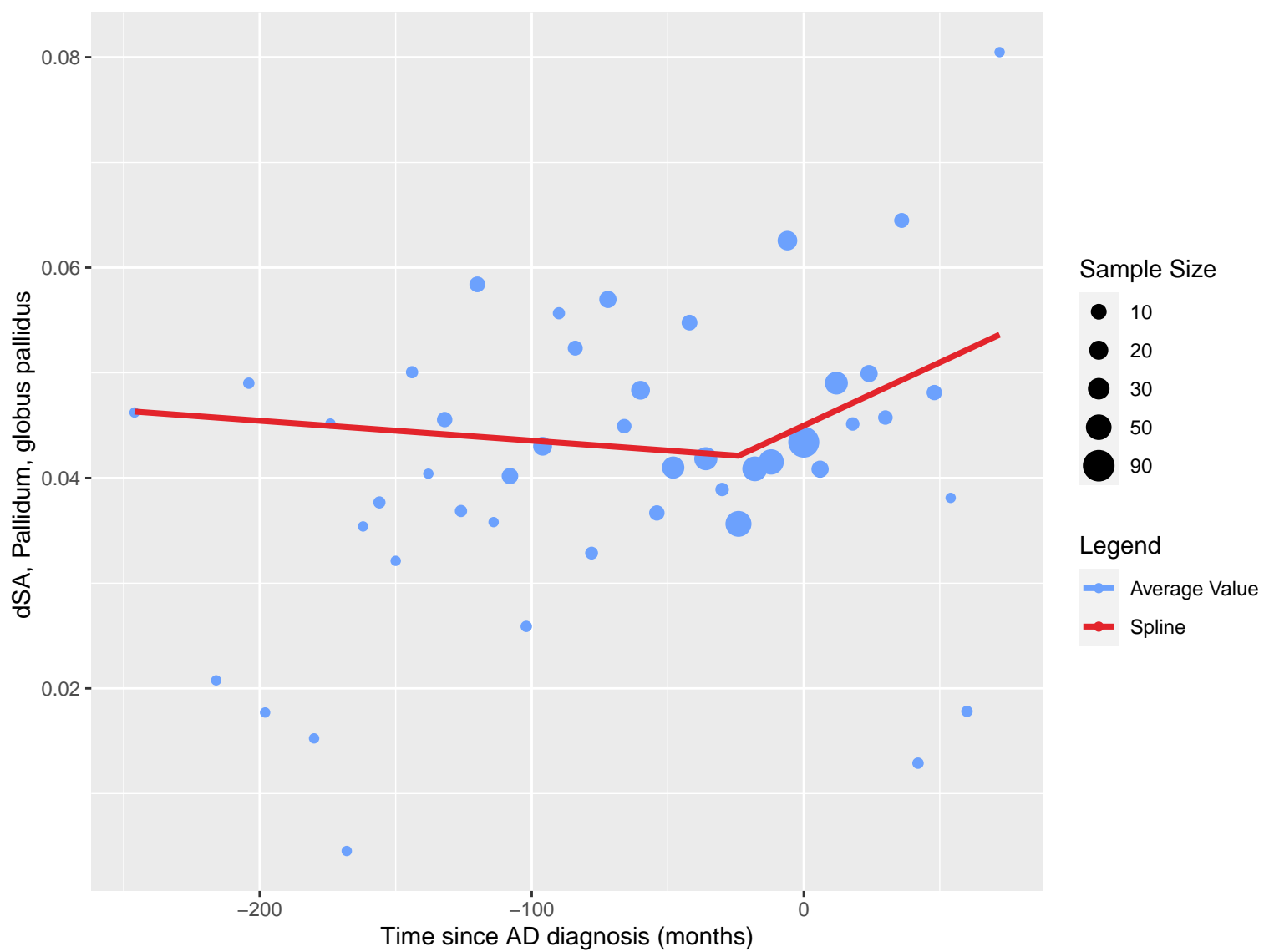


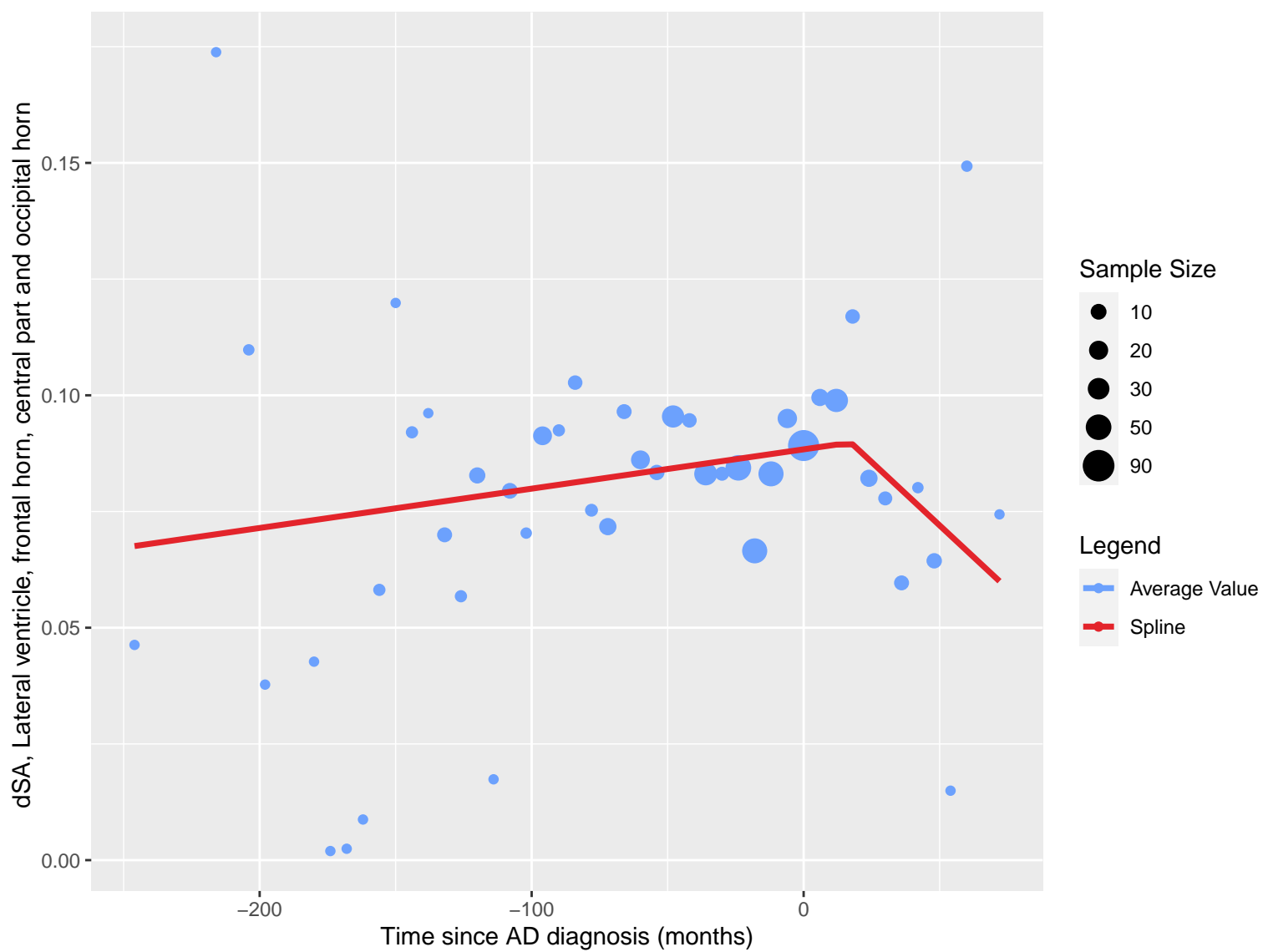


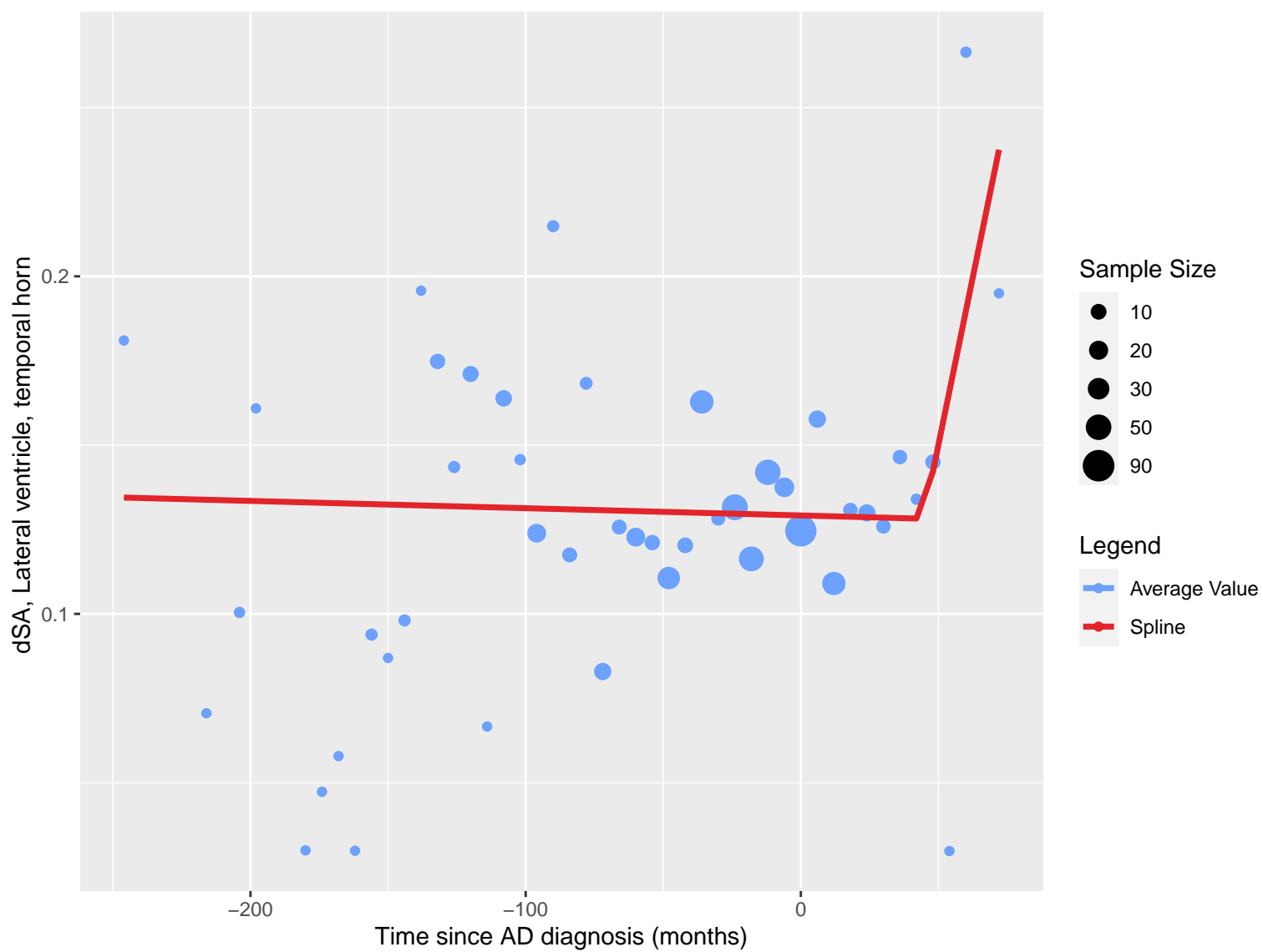


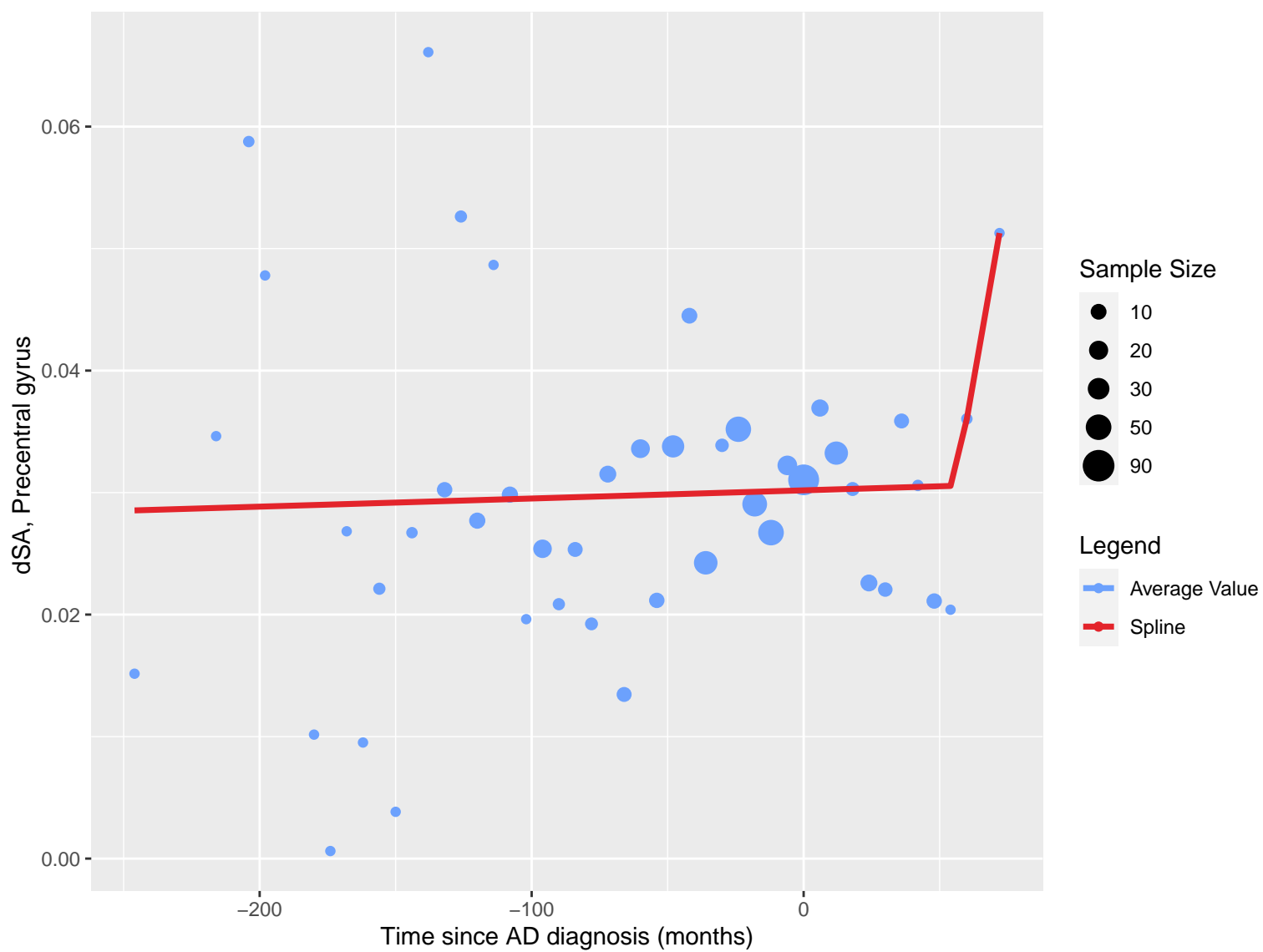


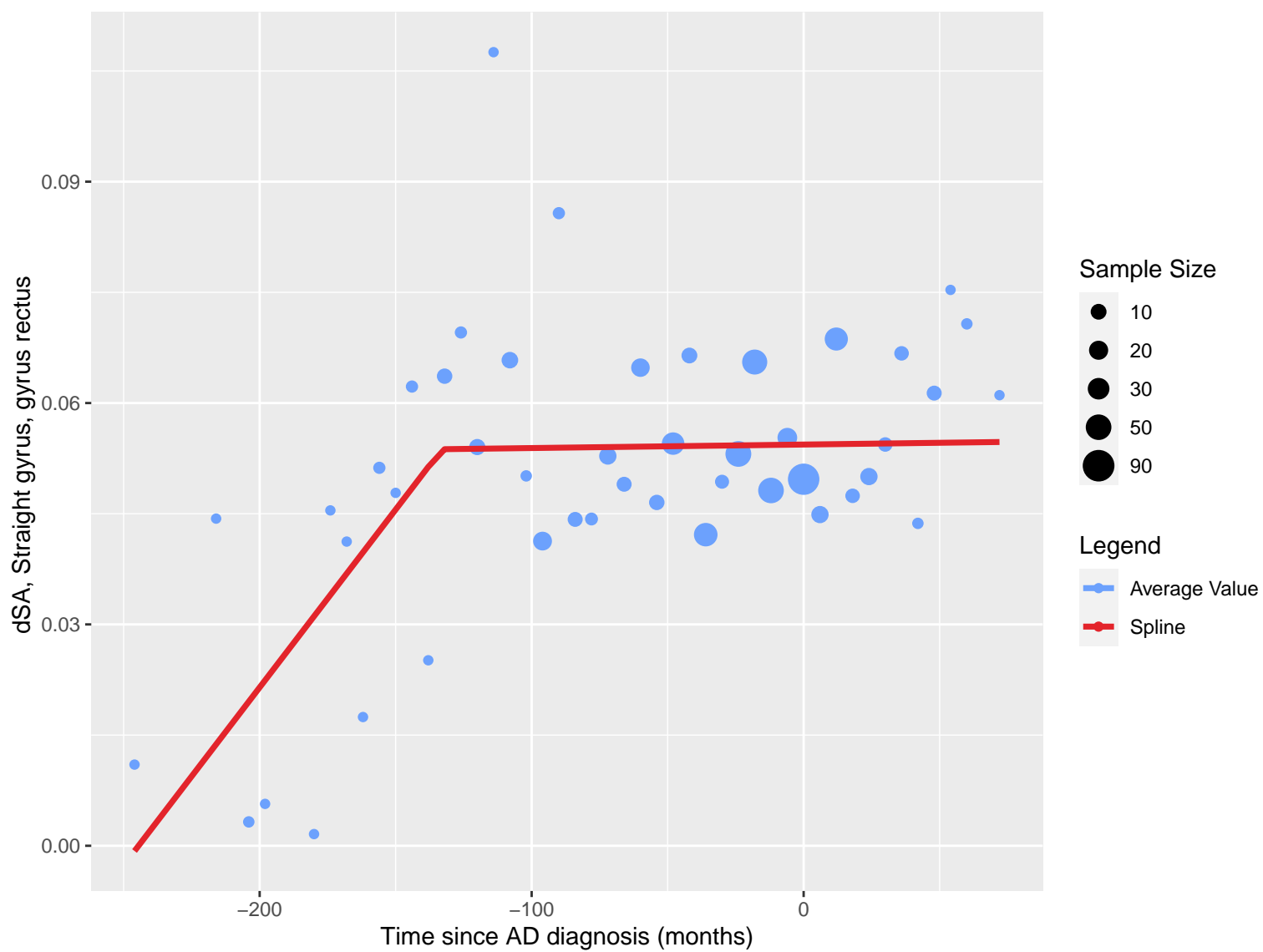


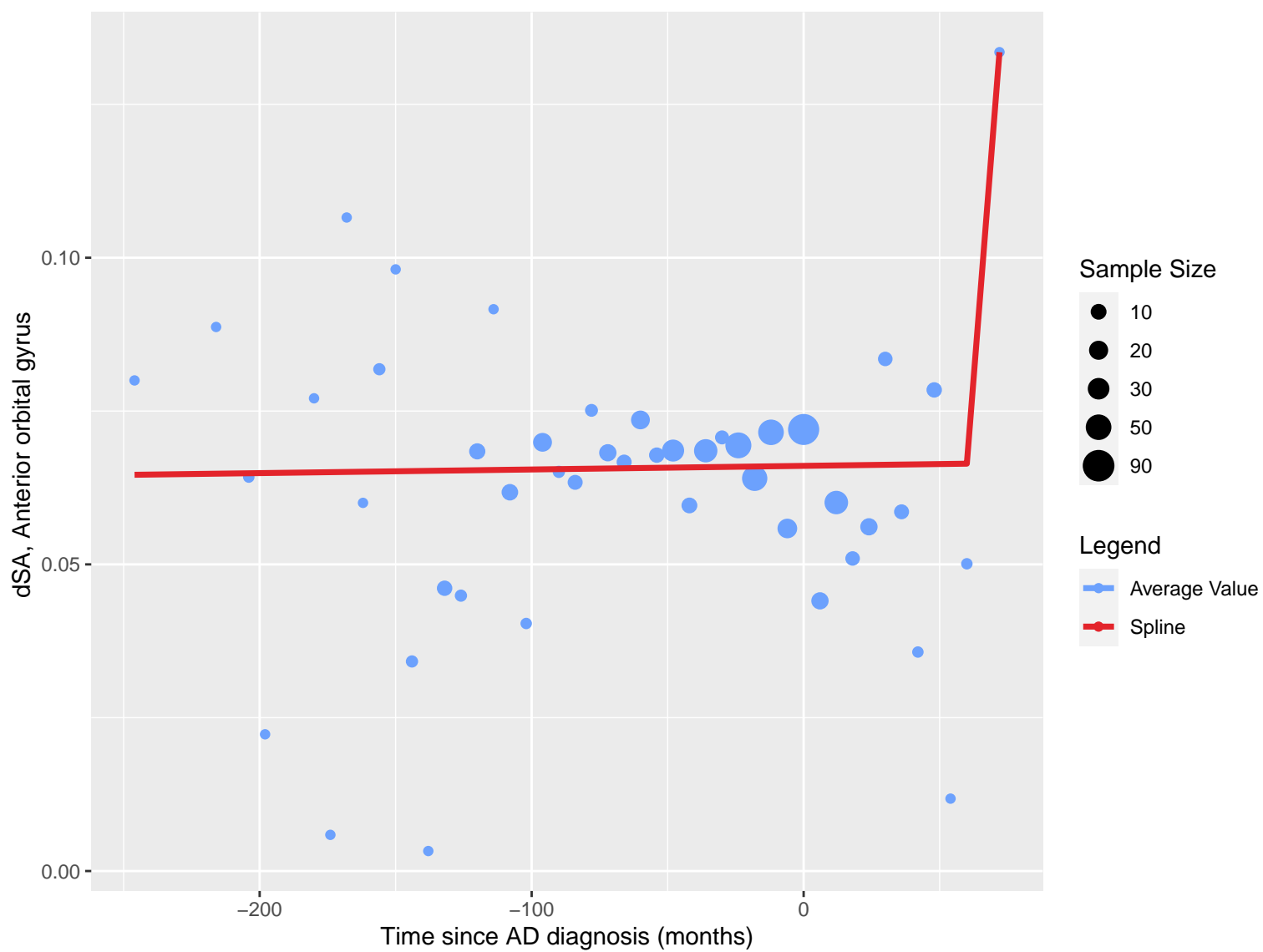




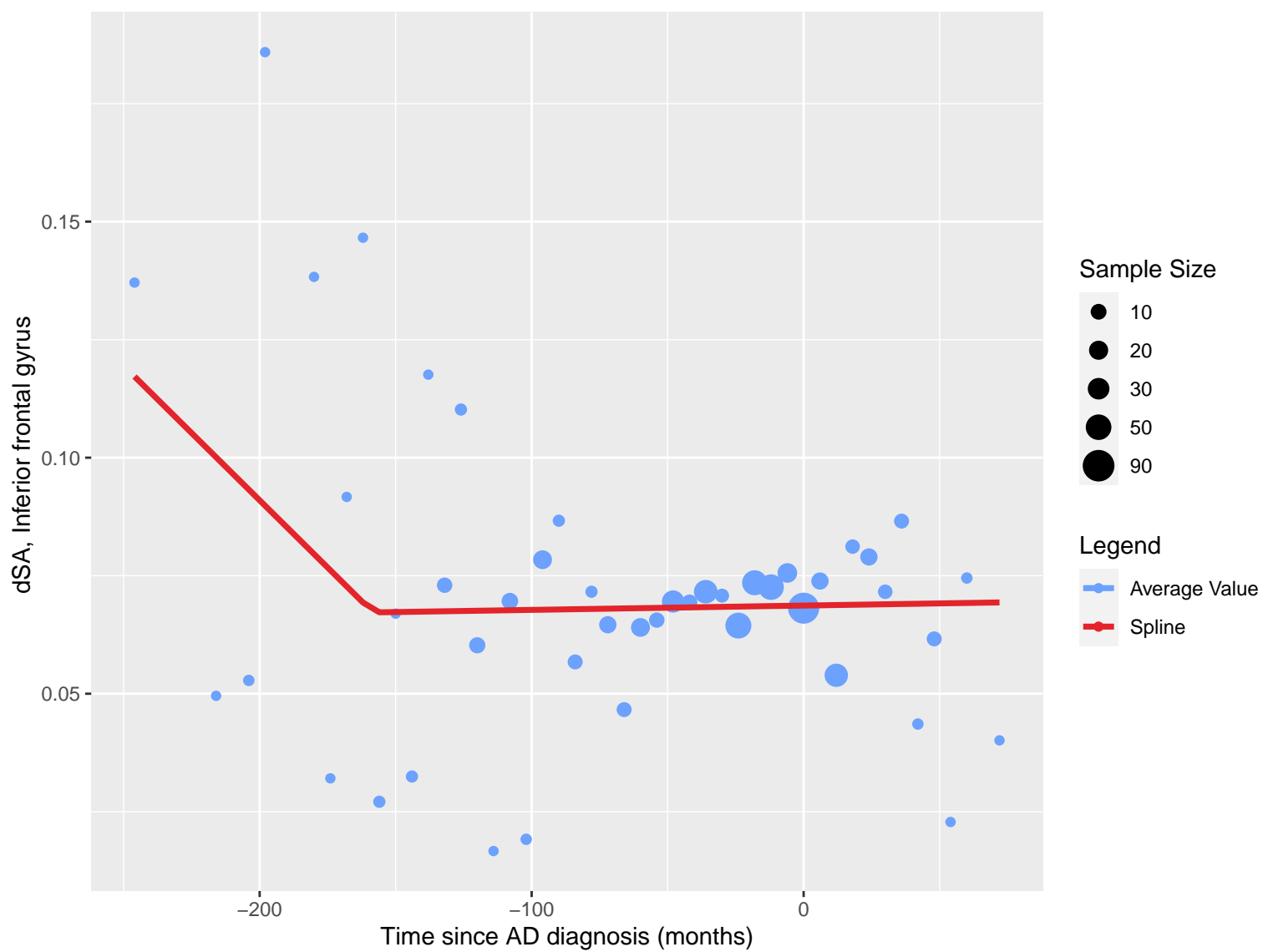


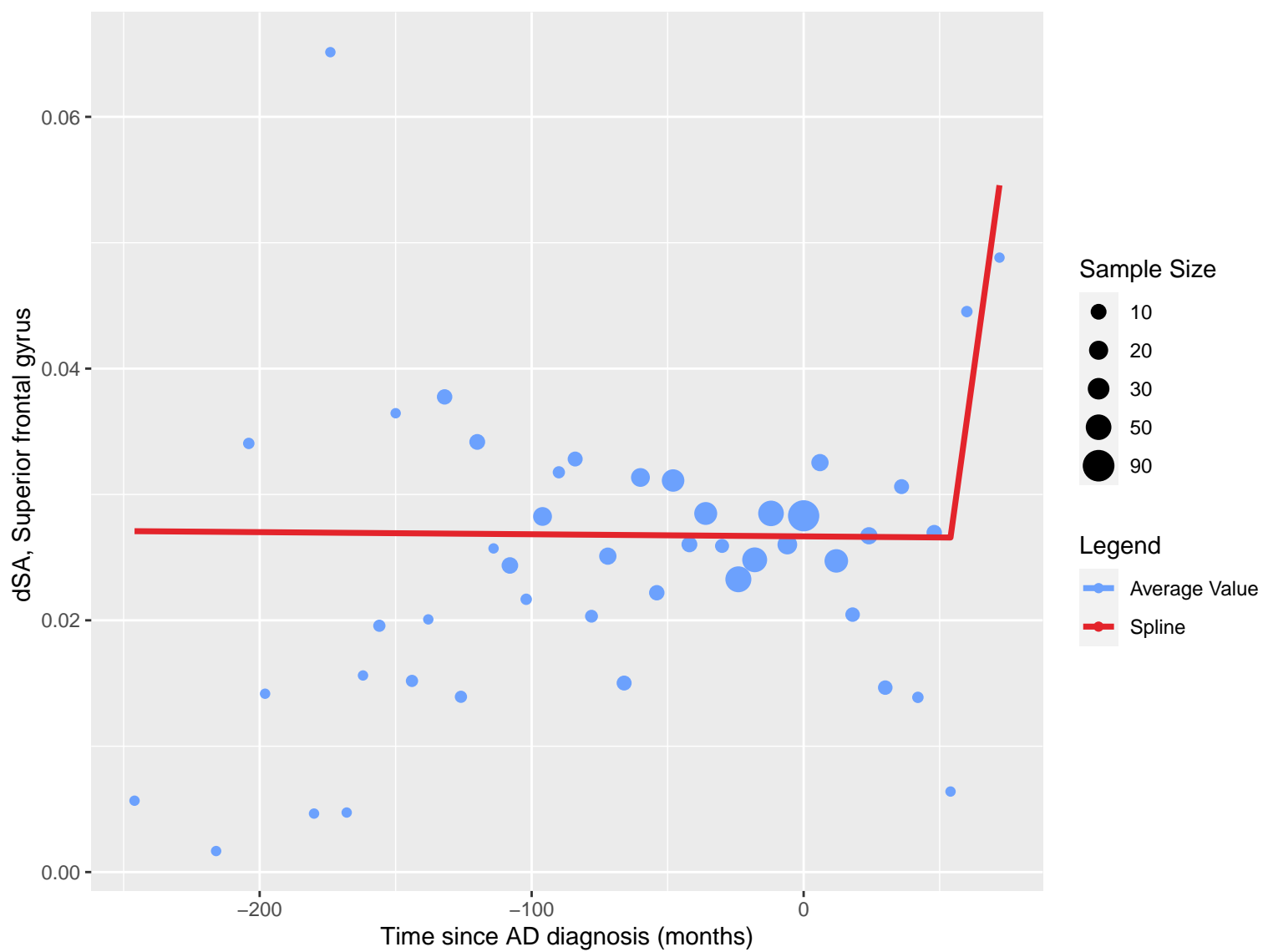


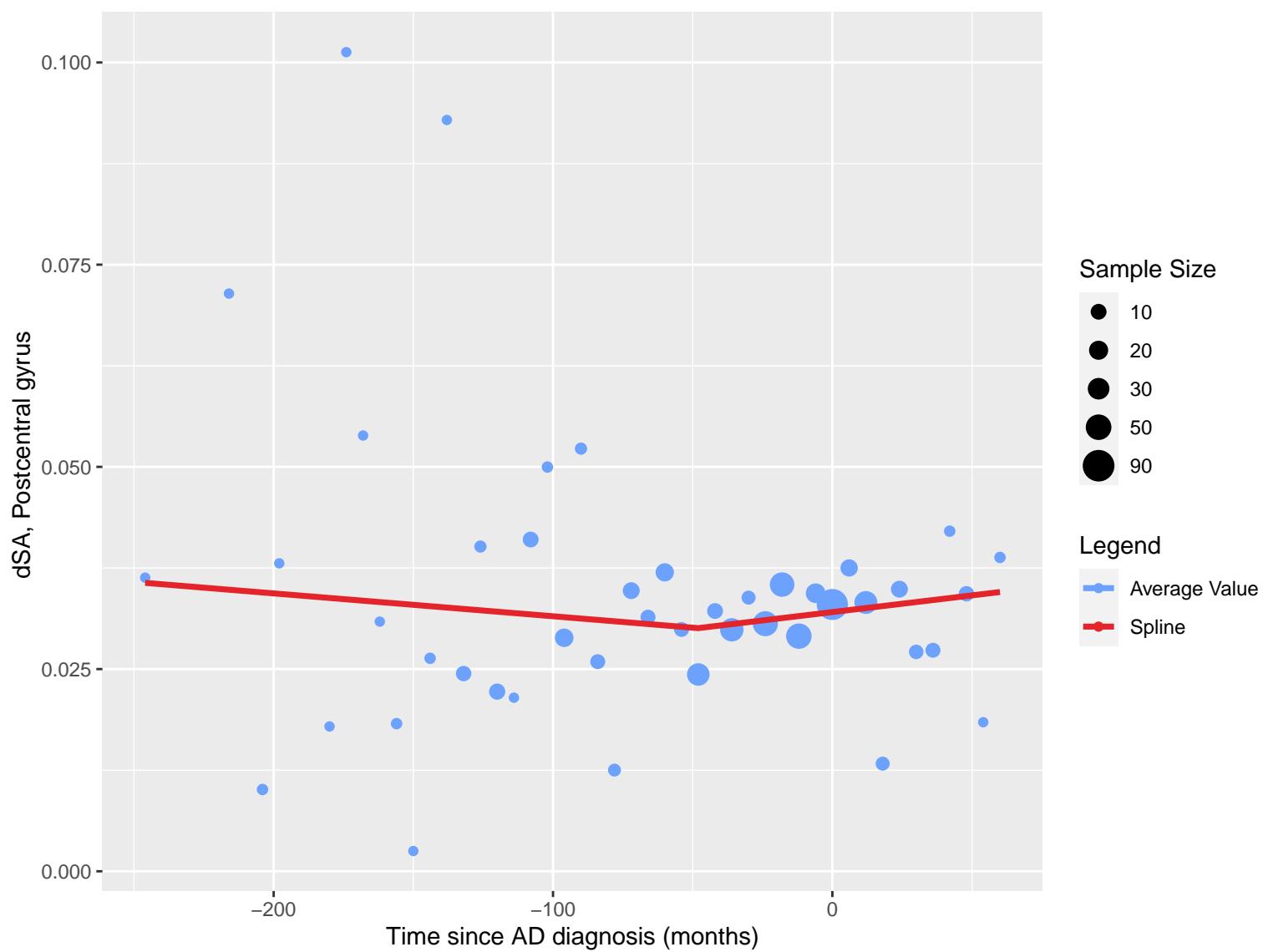


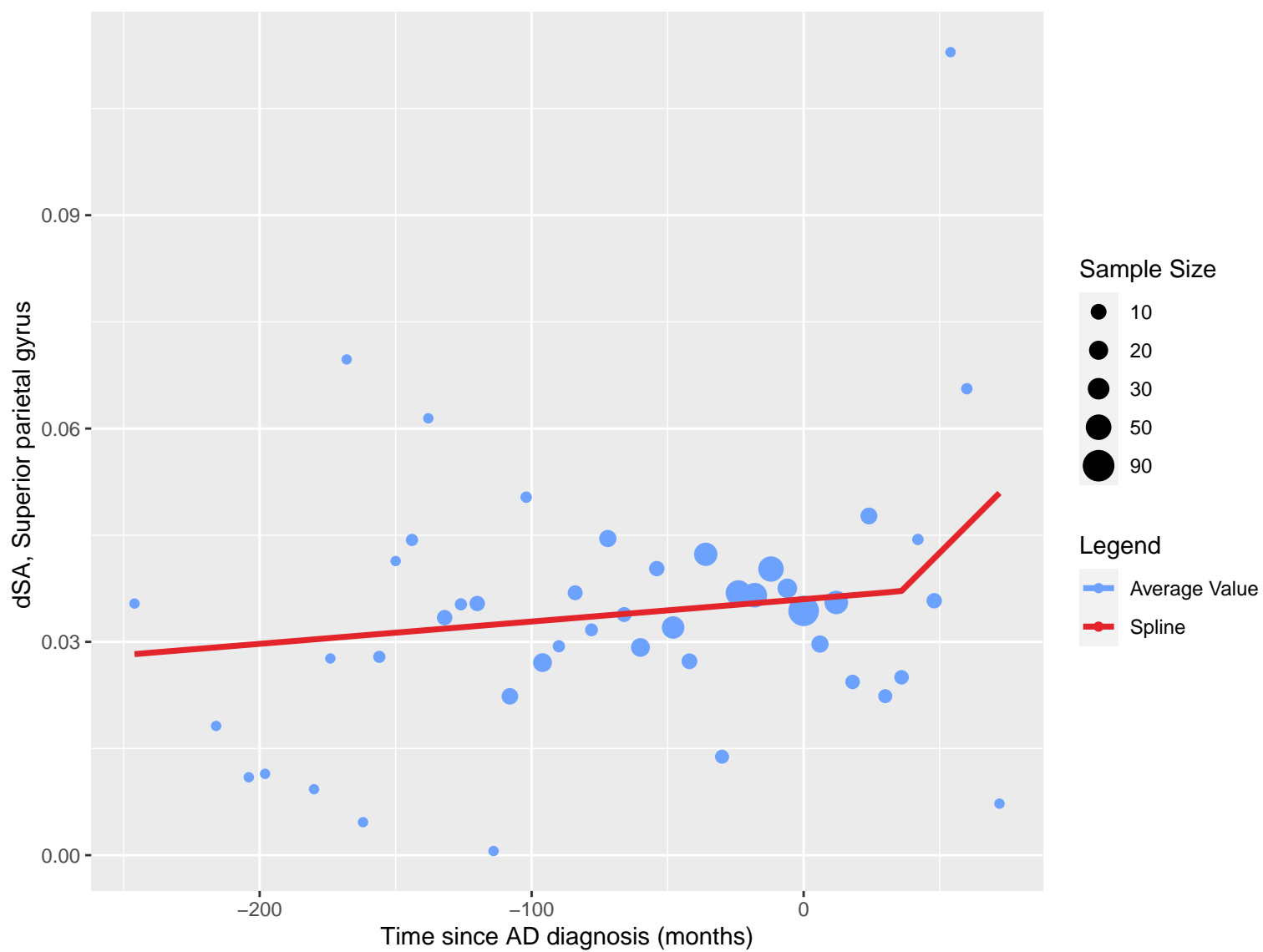


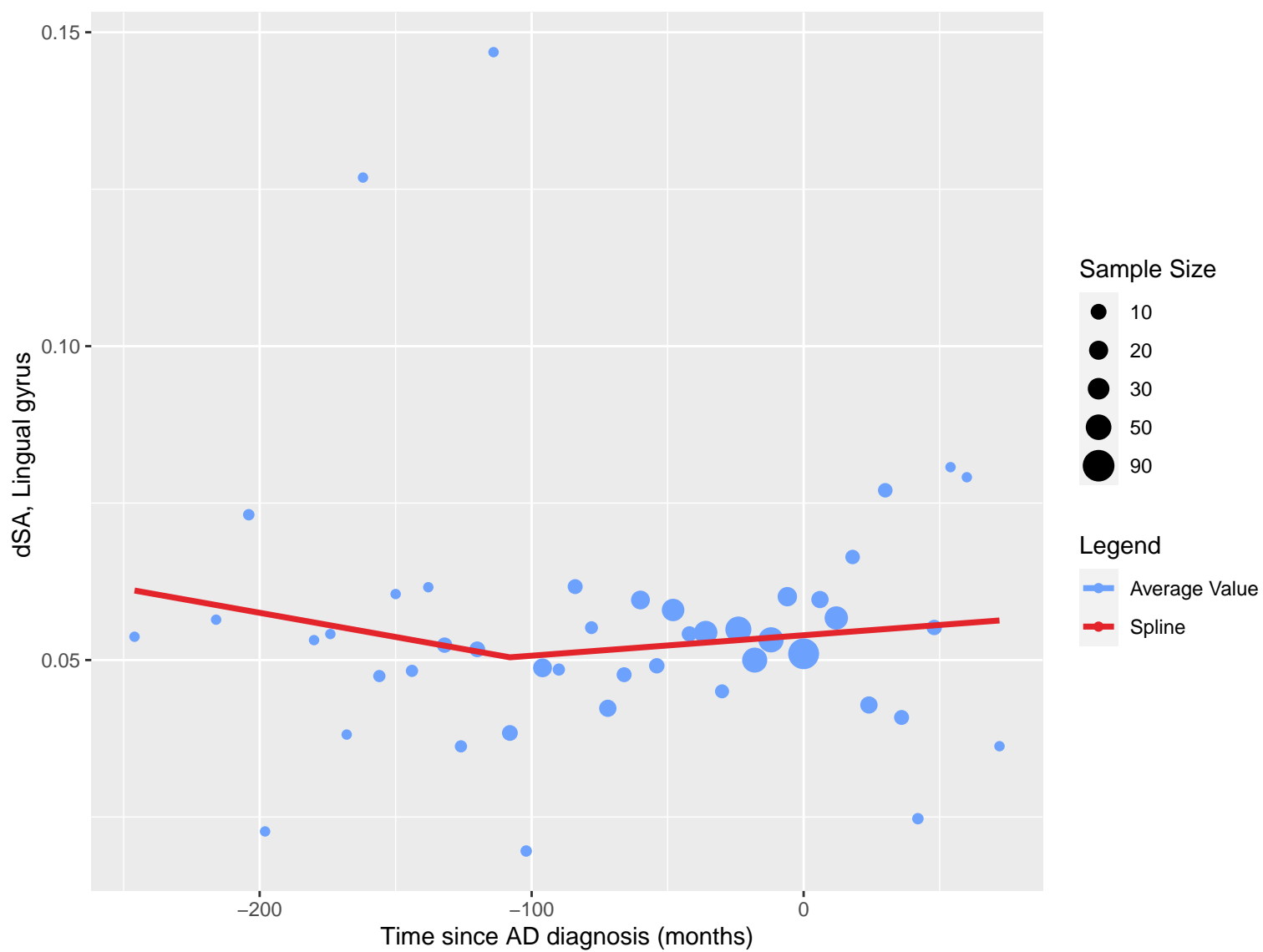


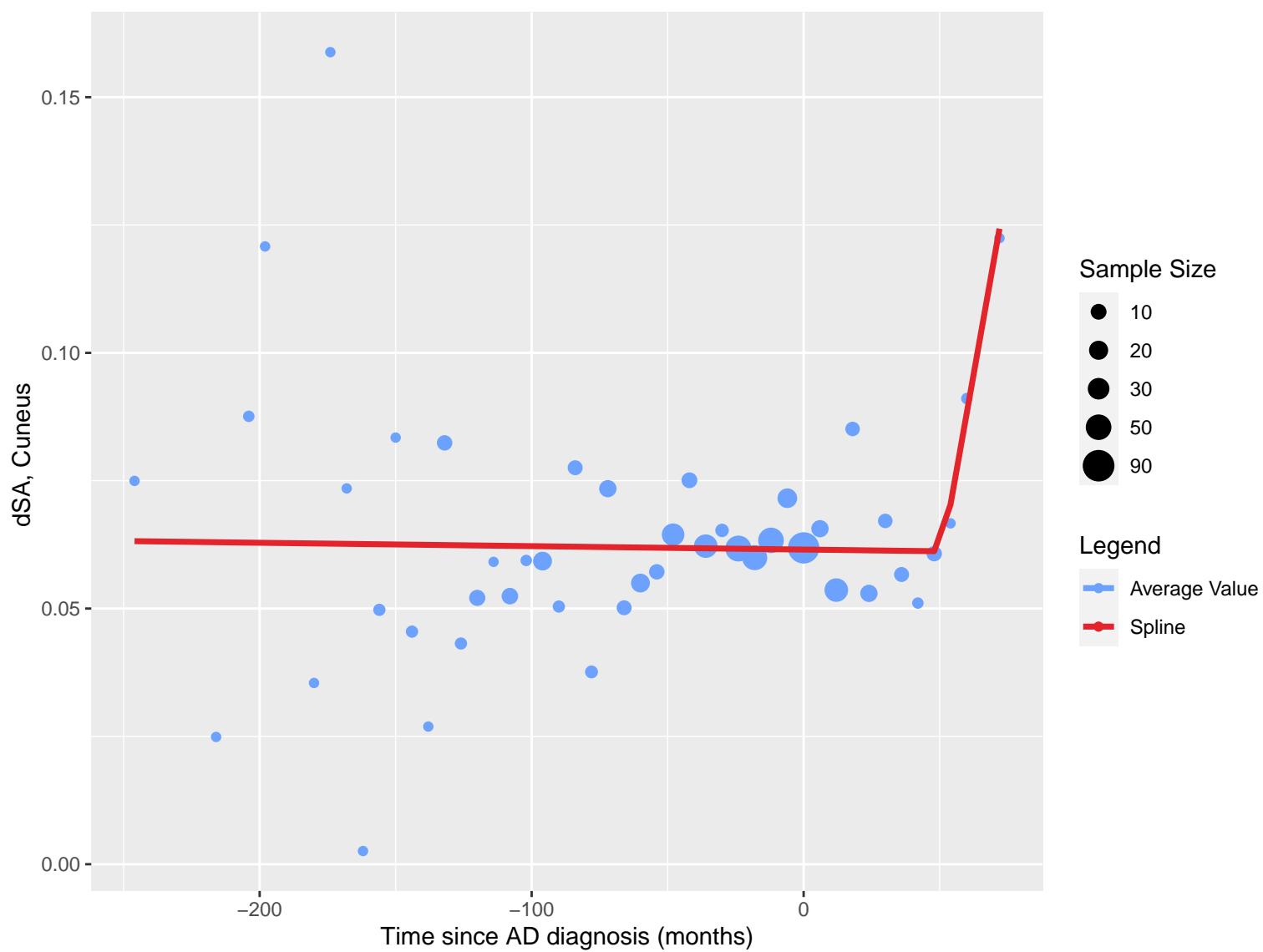


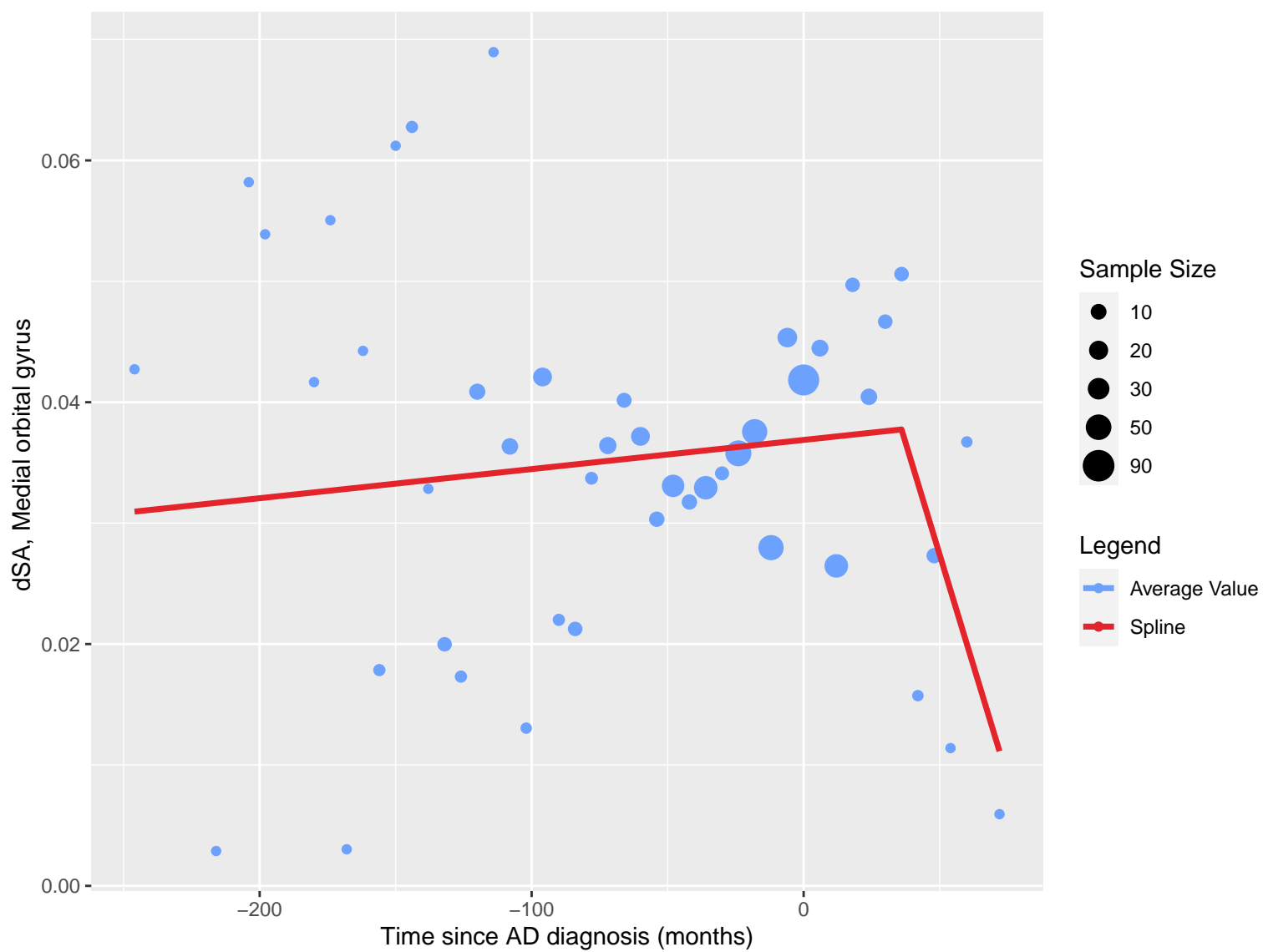


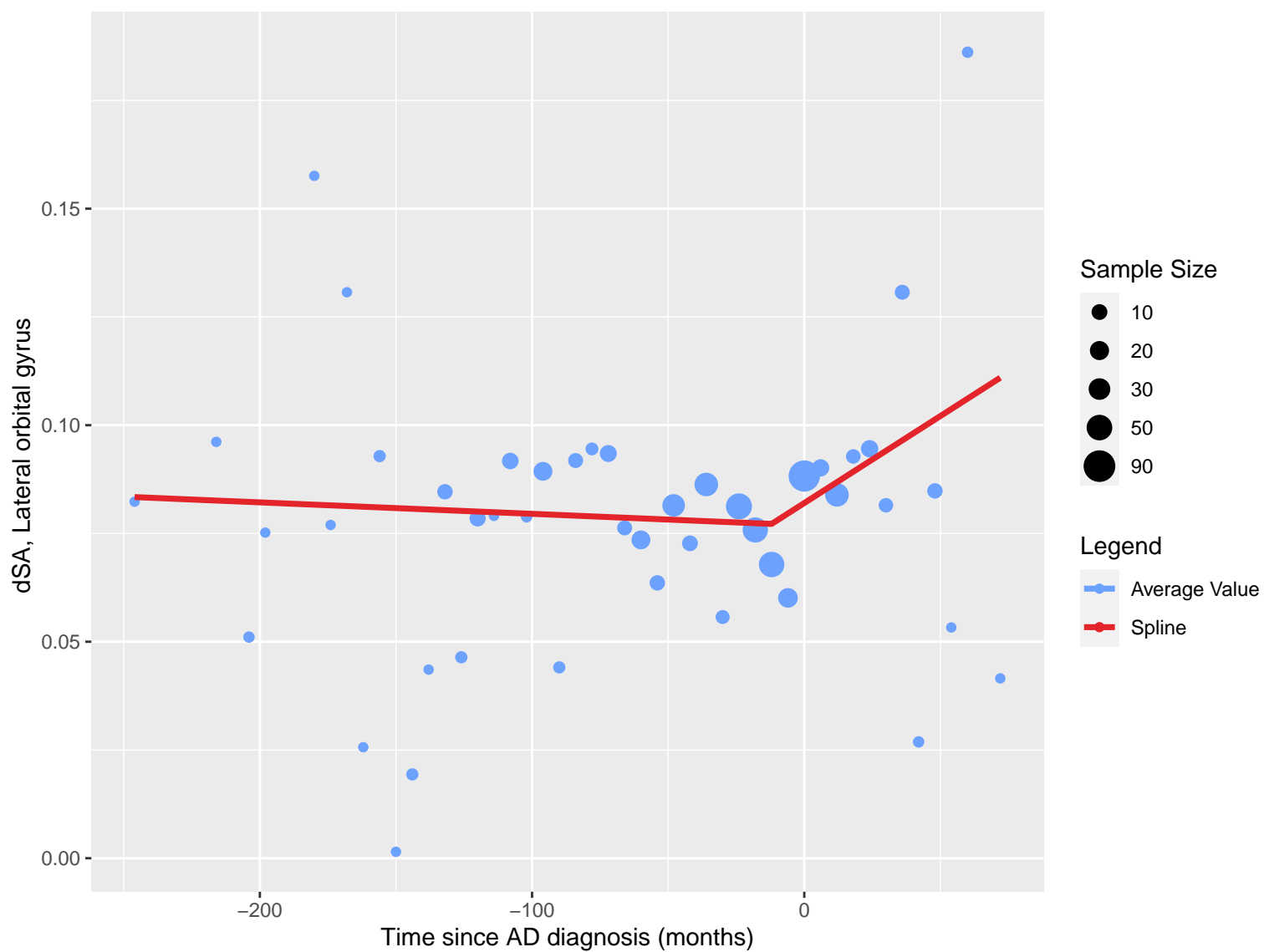




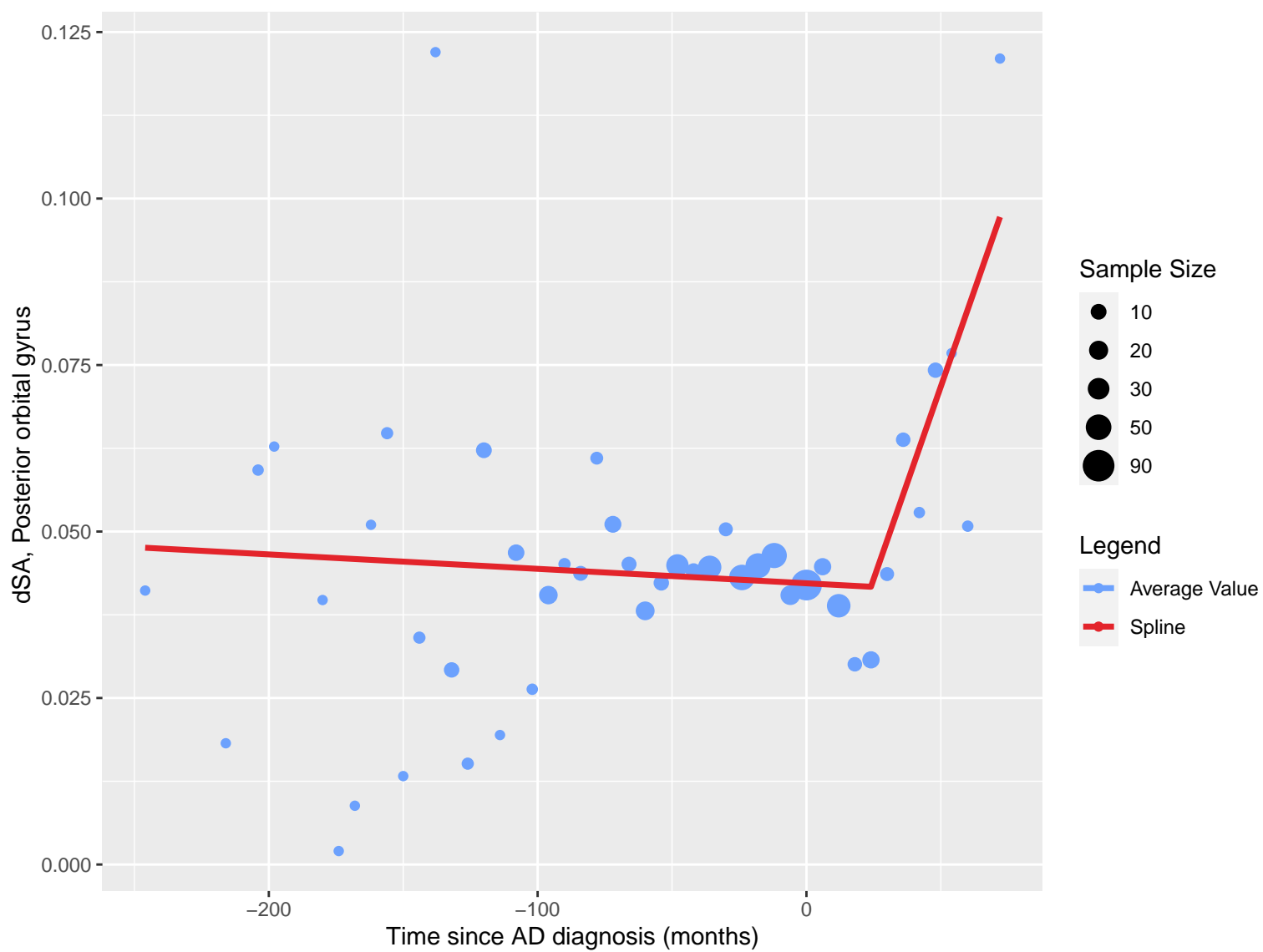


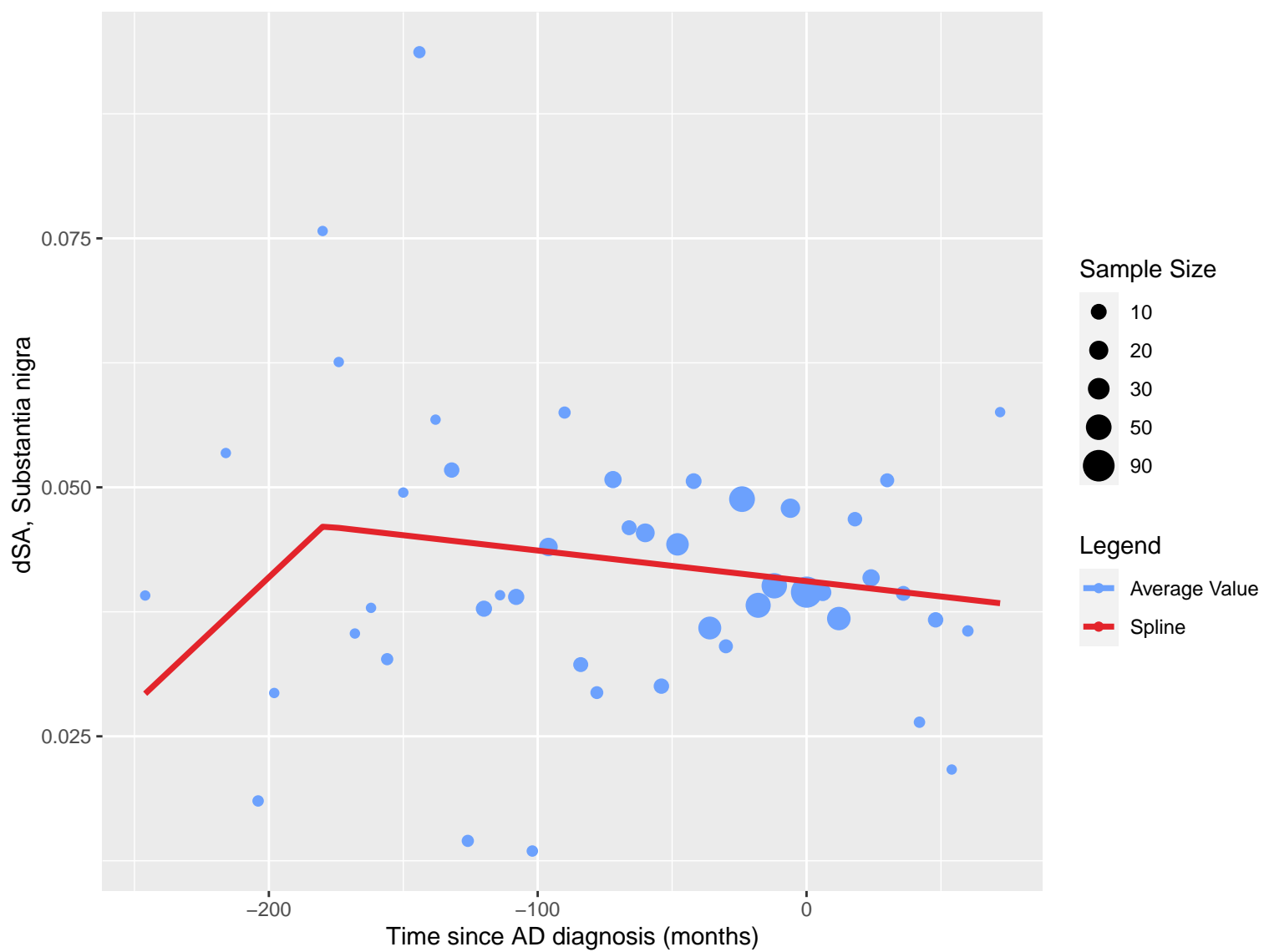


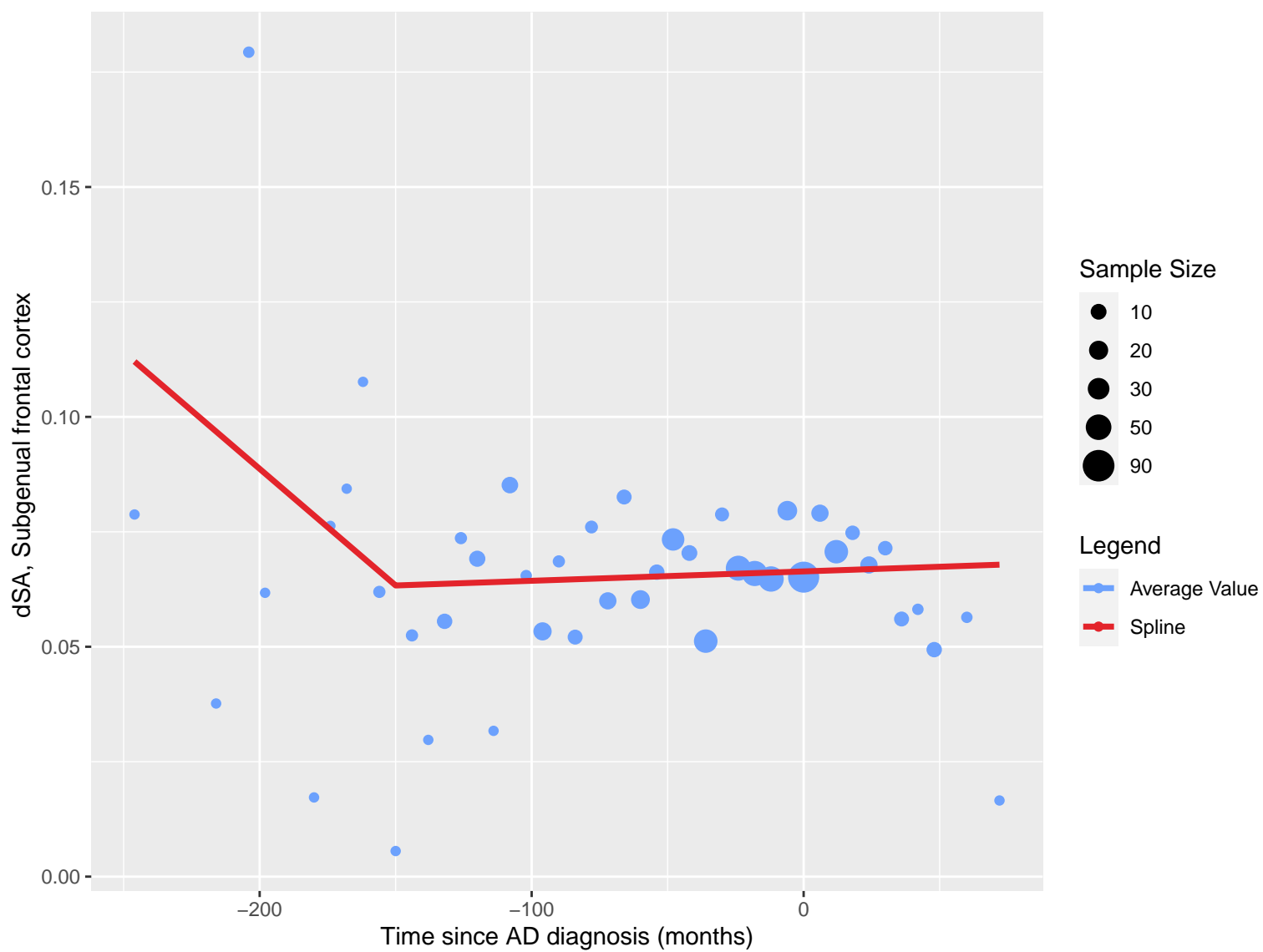


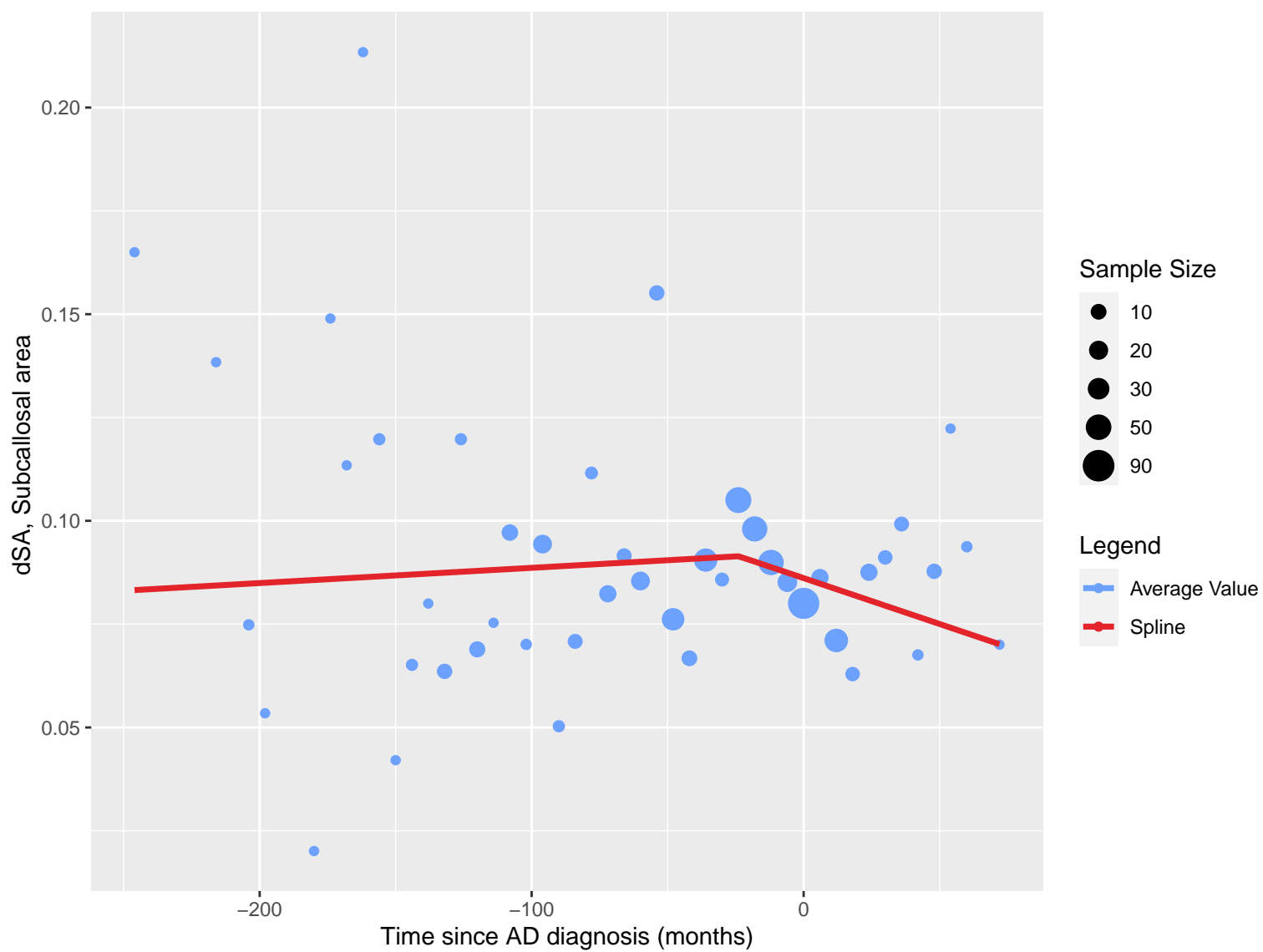


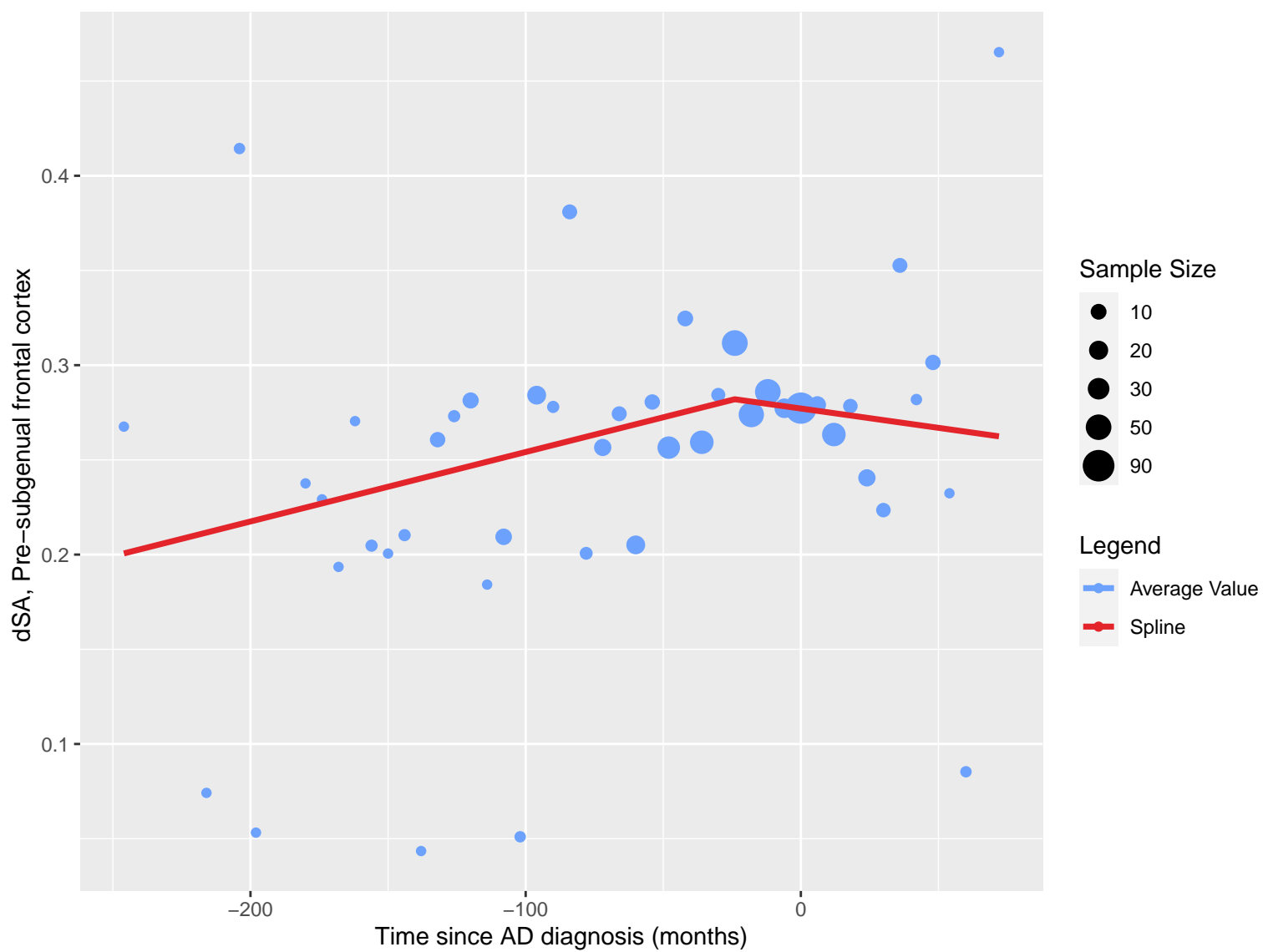












dSA, Superior temporal gyrus, anterior part

0.20

0.15

0.10

0.05

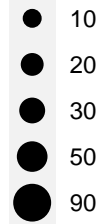
-200

-100

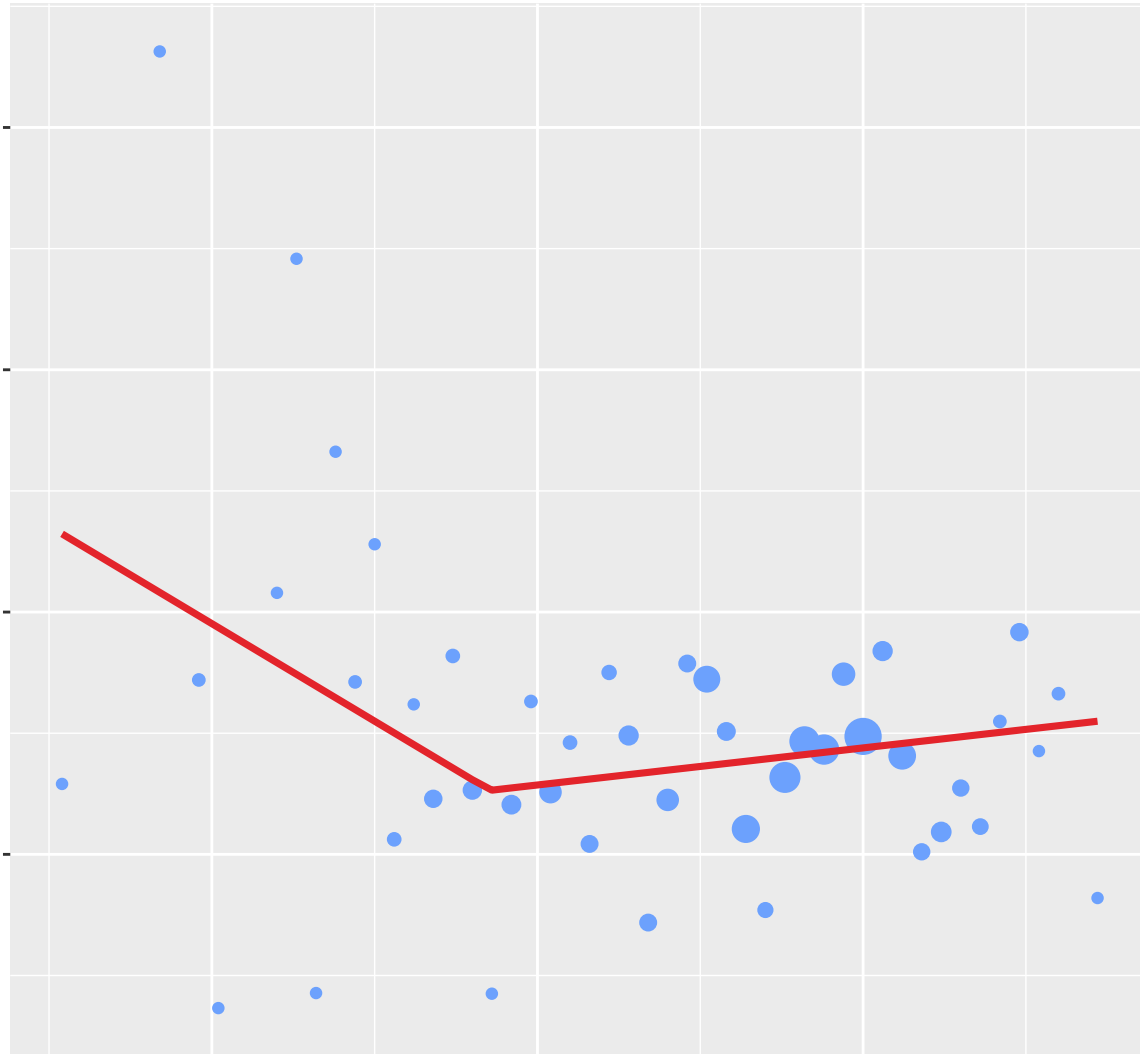
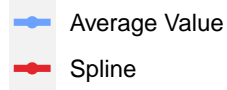
0

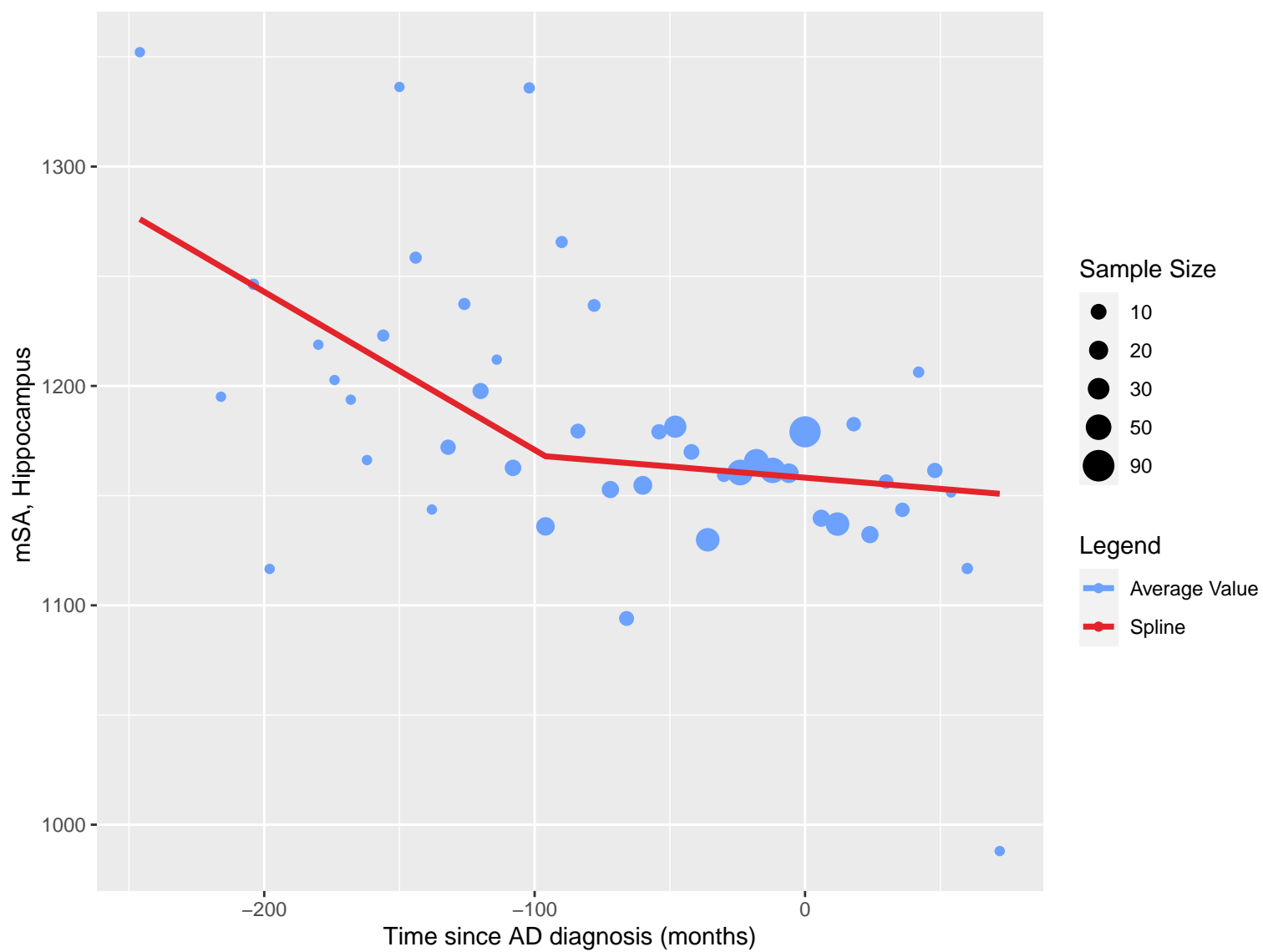
Time since AD diagnosis (months)

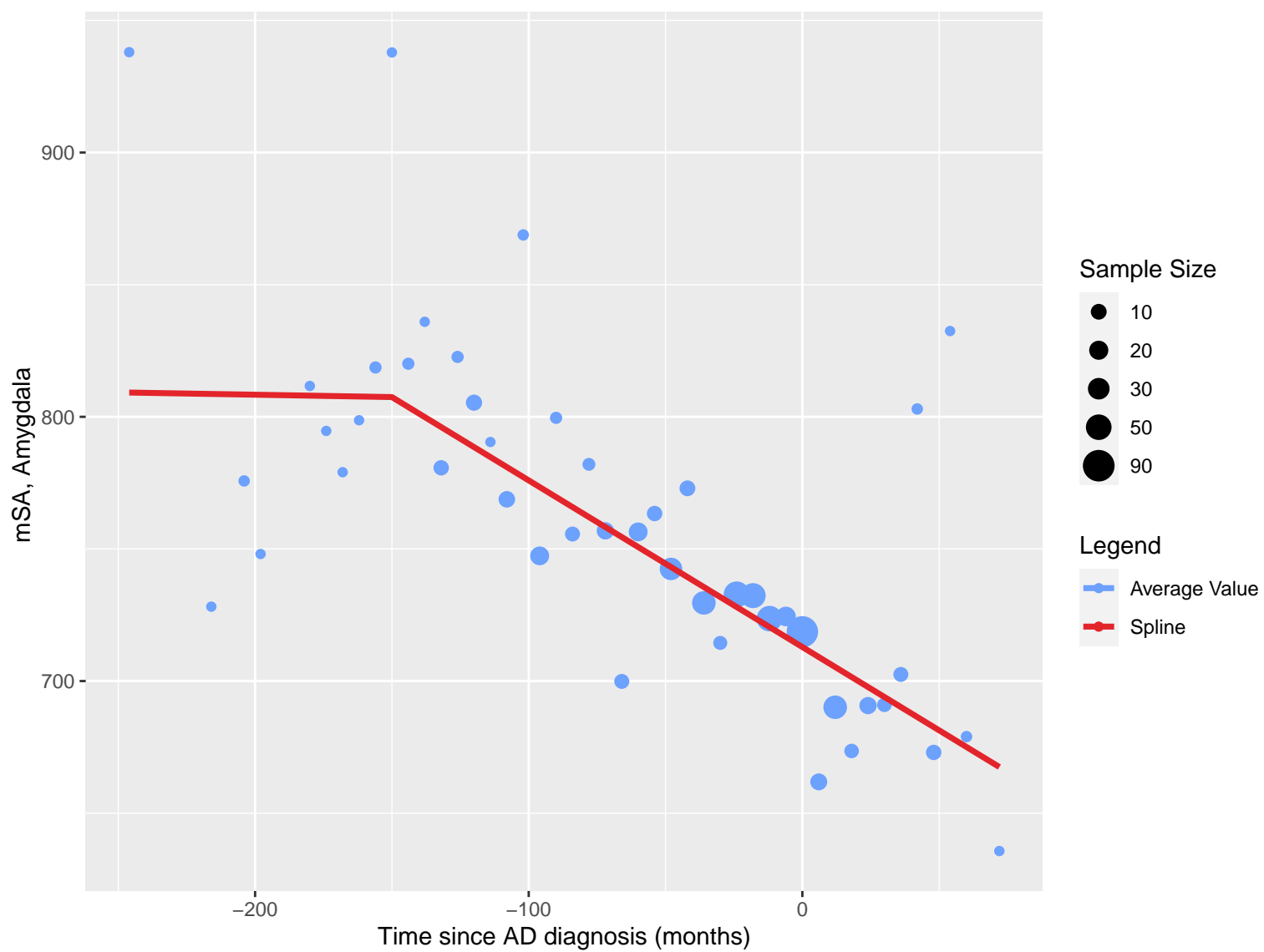
Sample Size



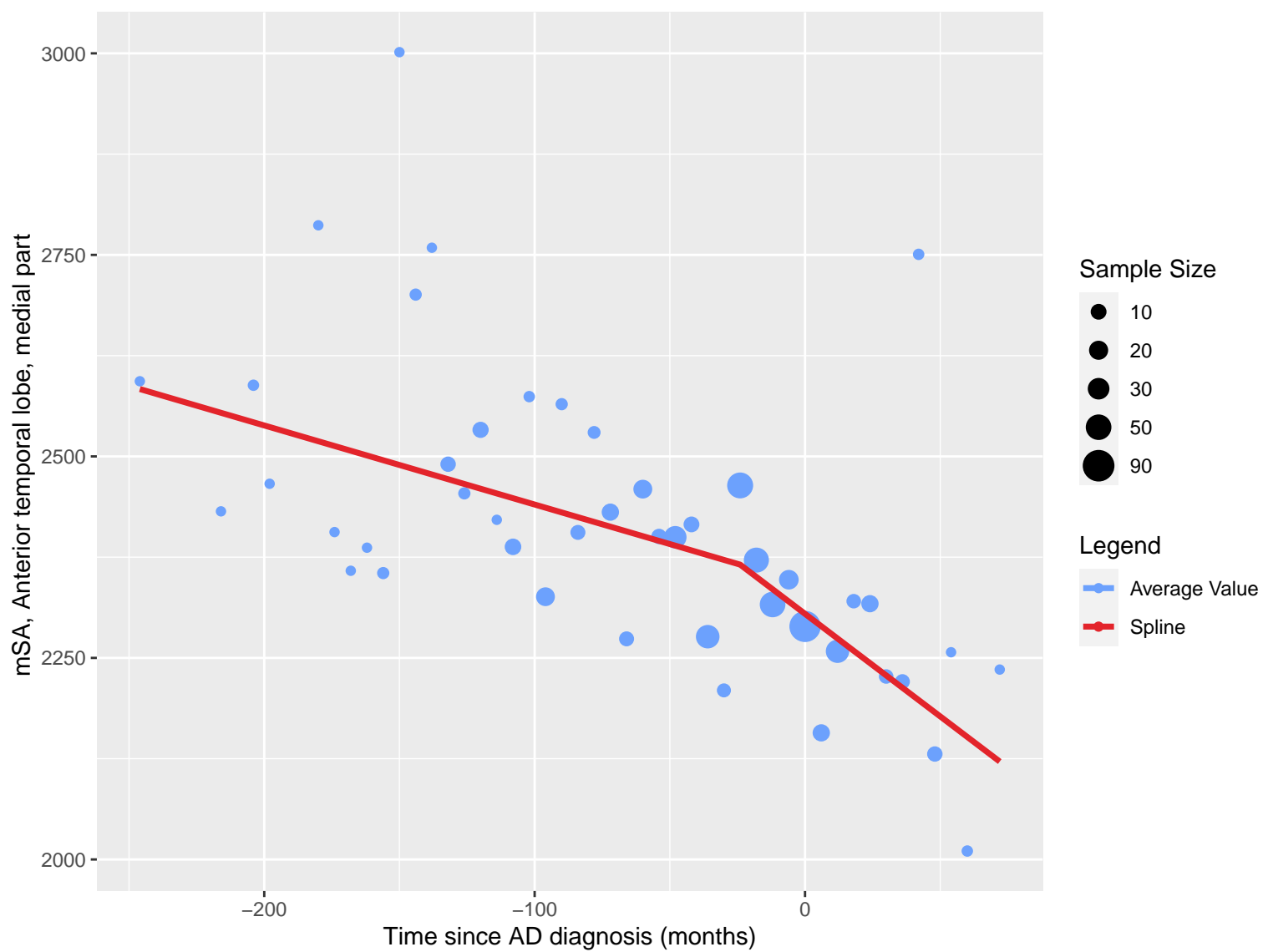
Legend

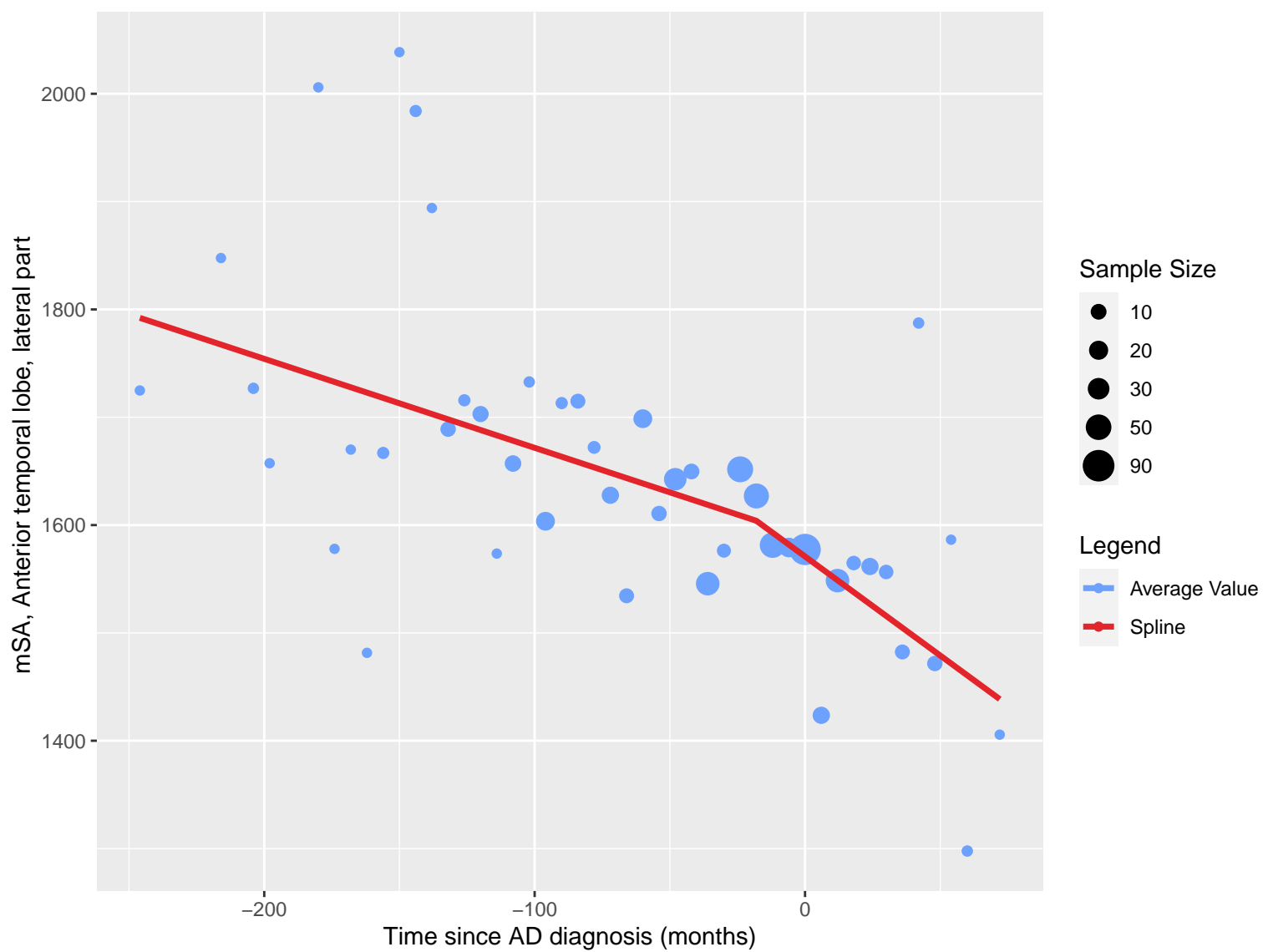


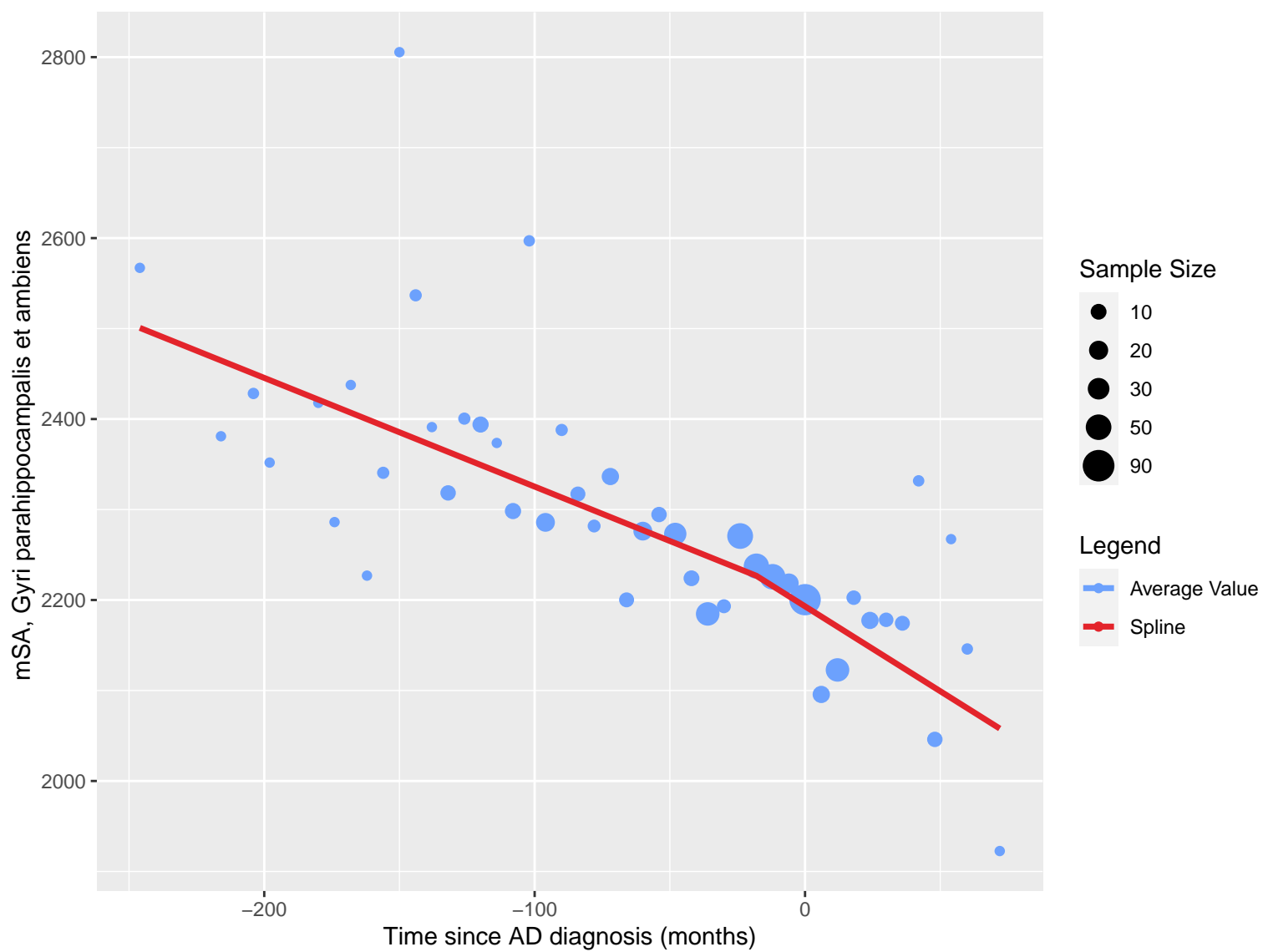


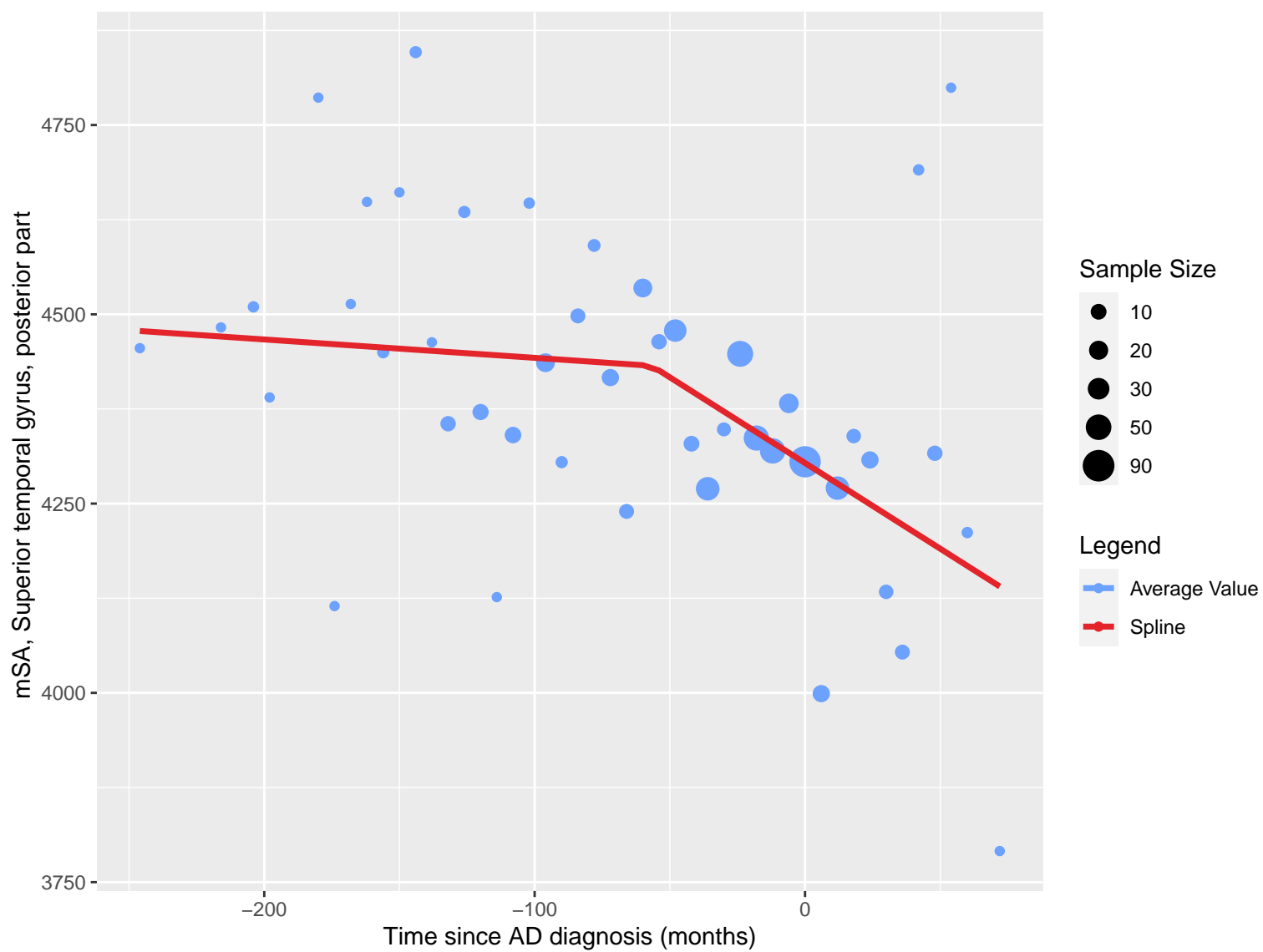


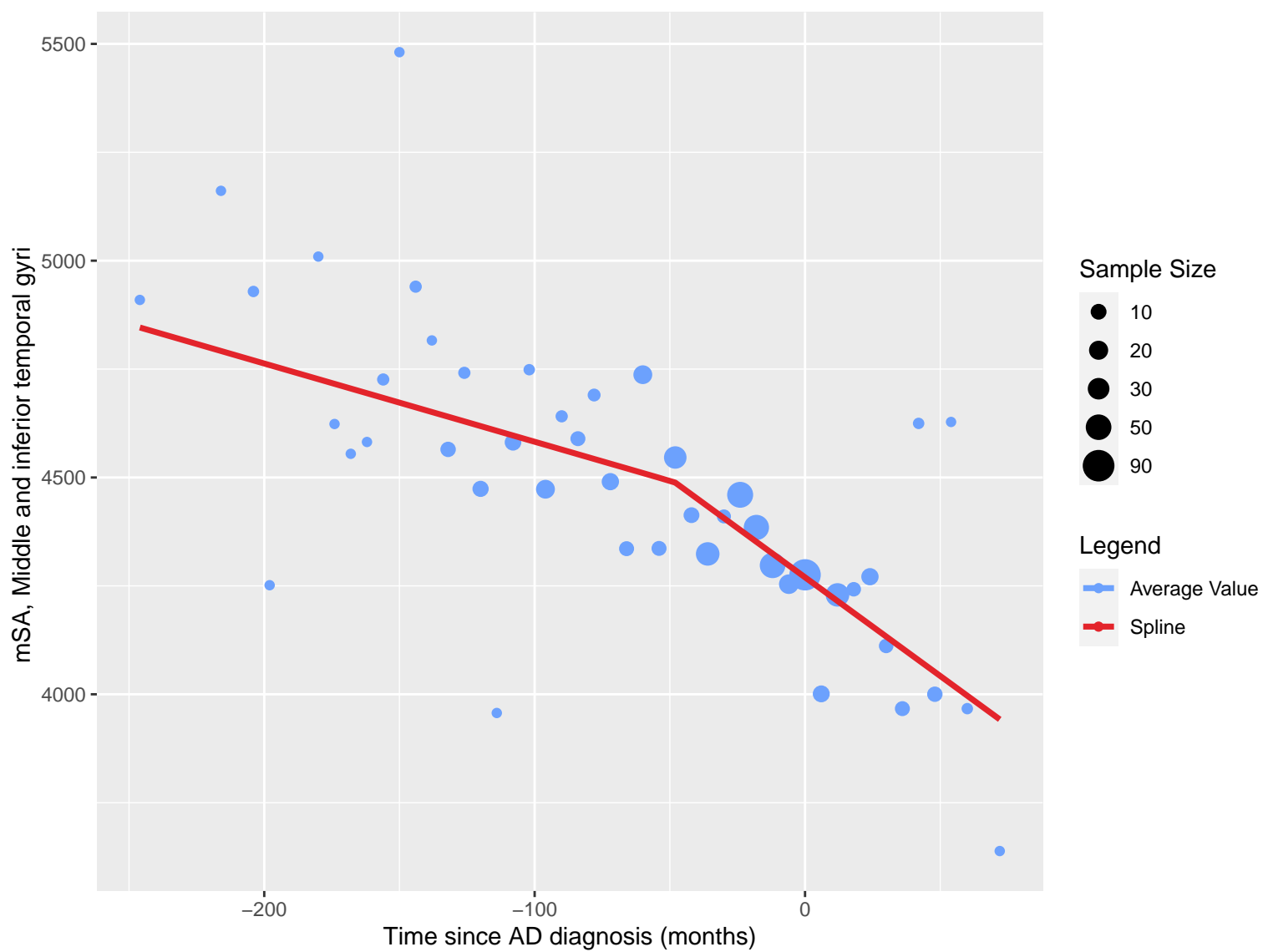


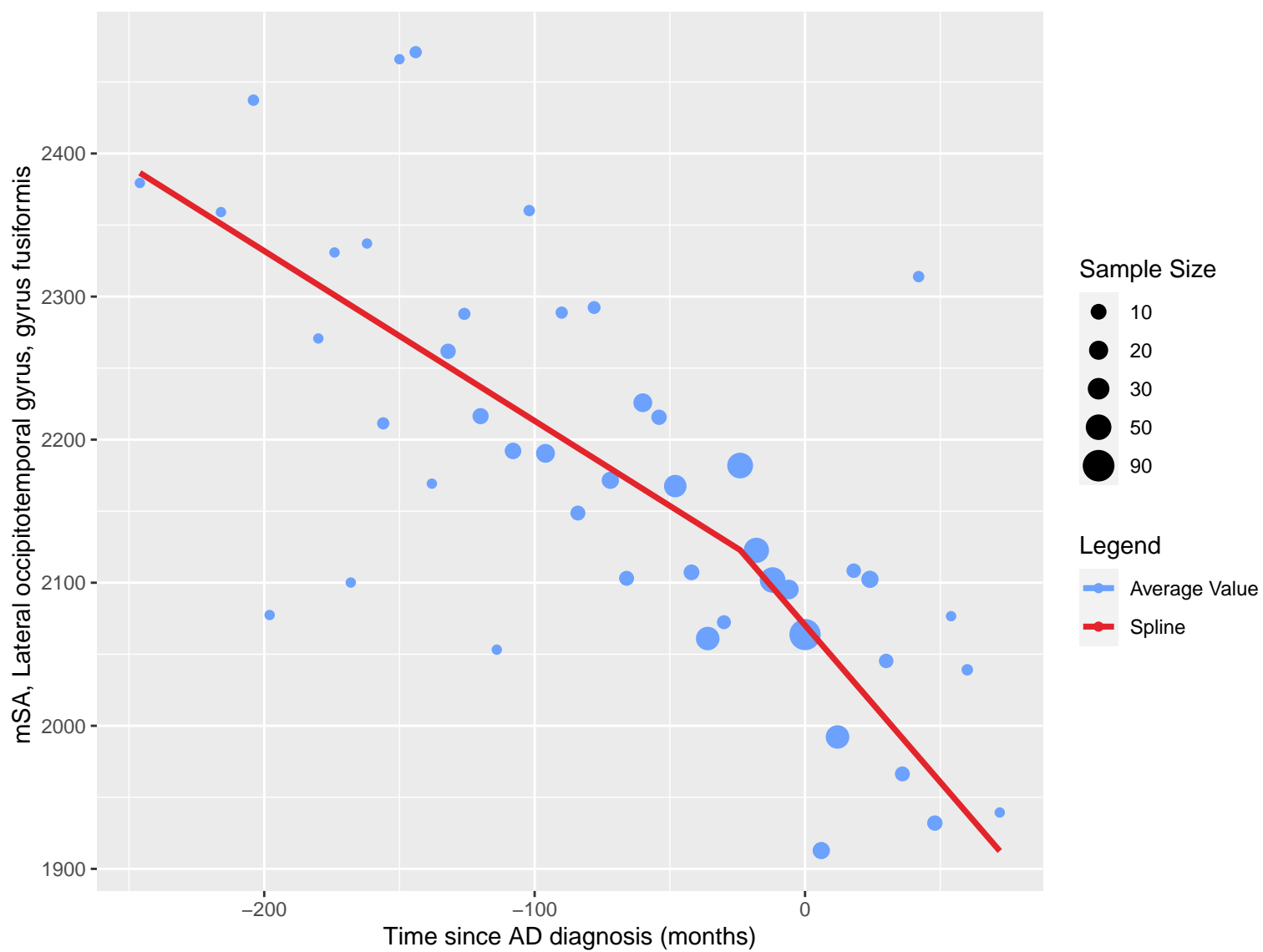


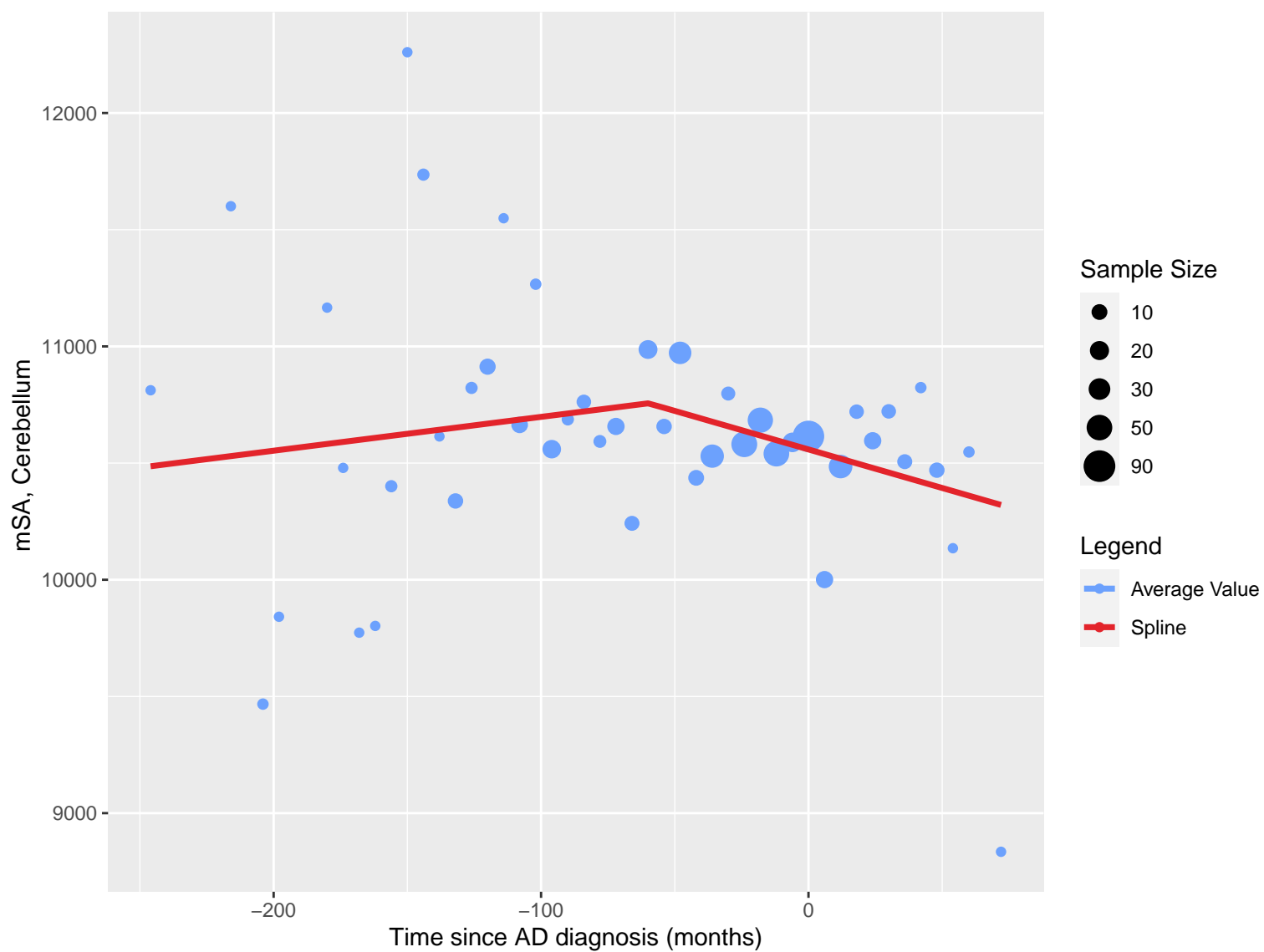


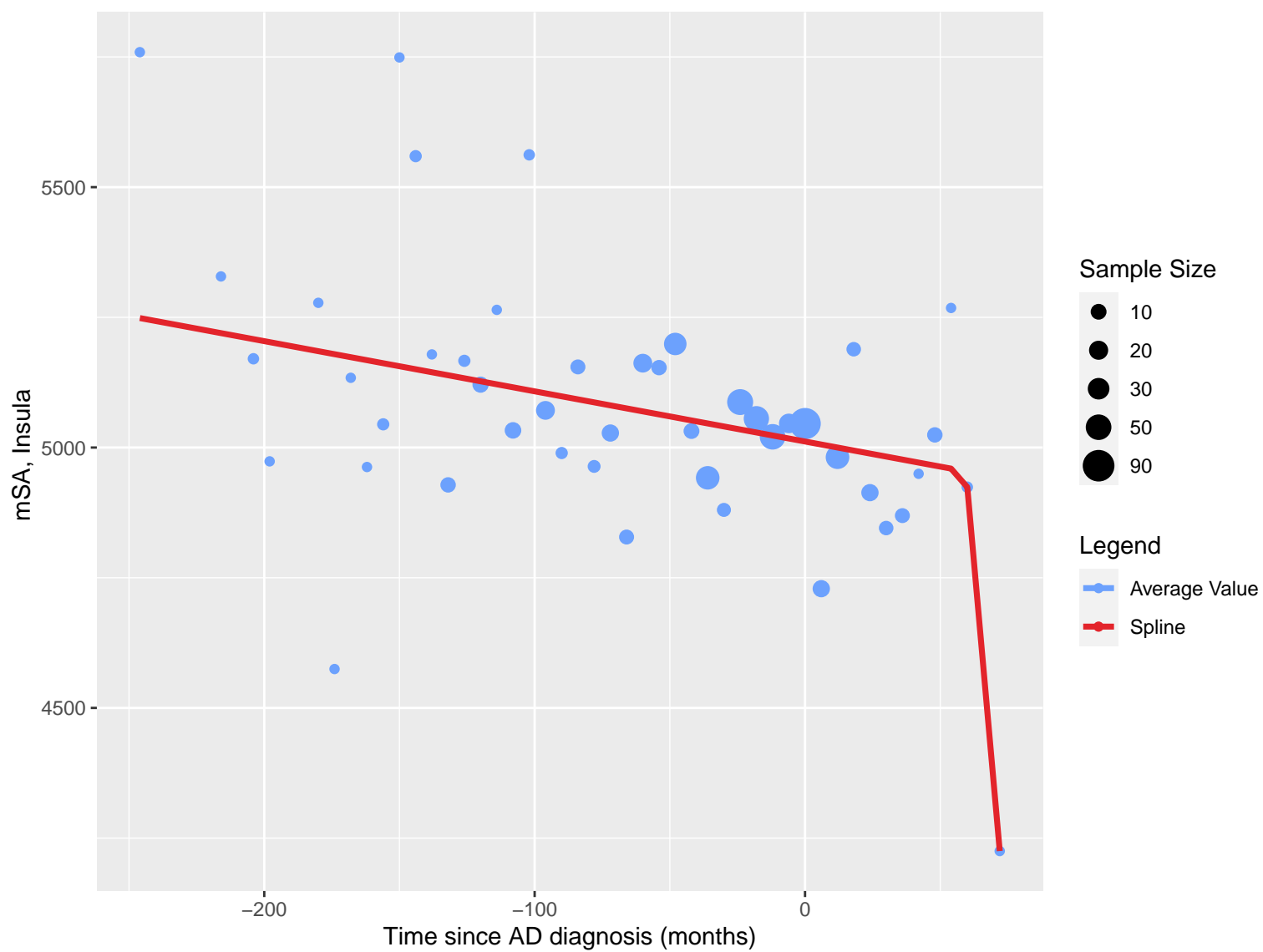




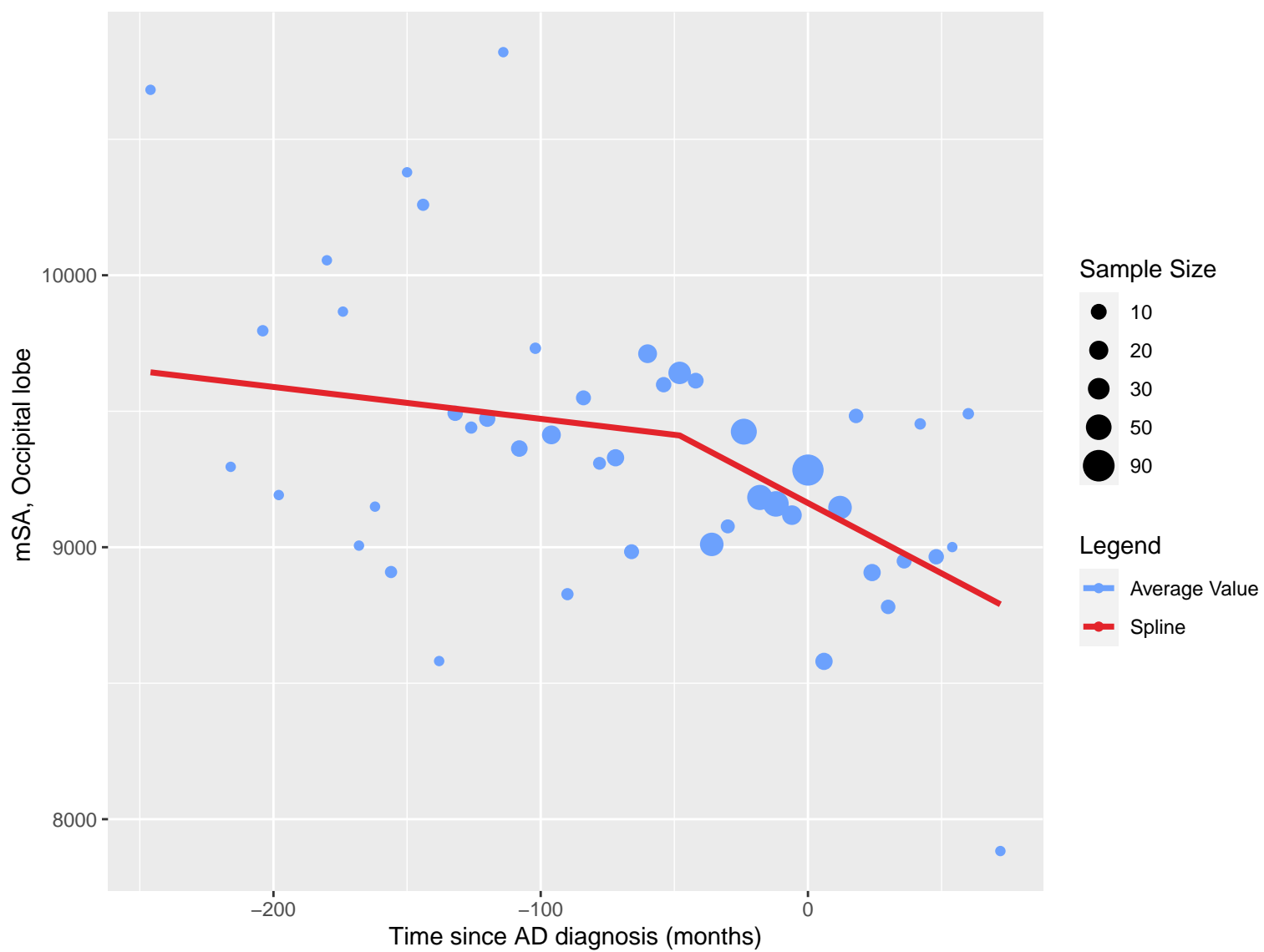


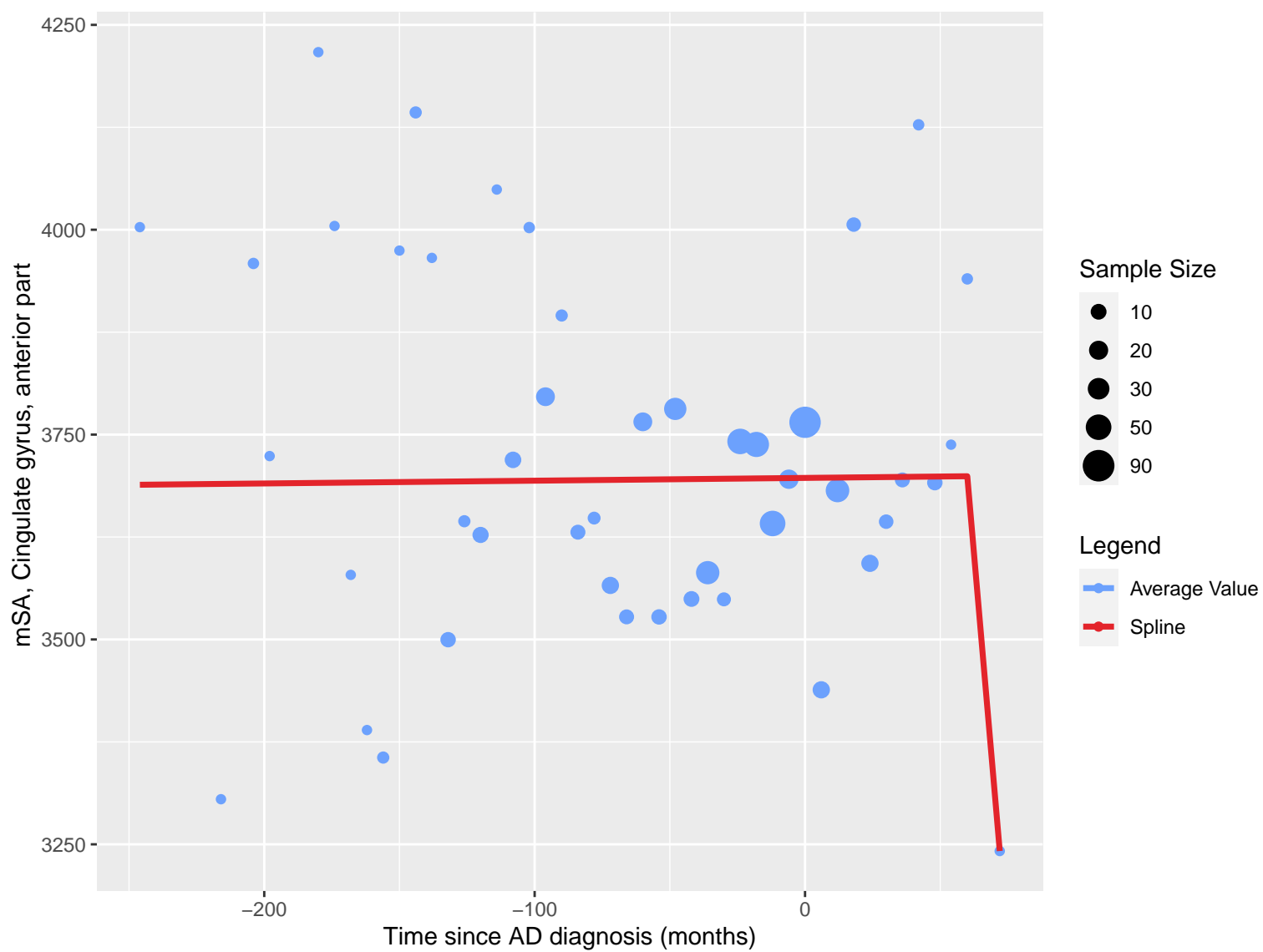


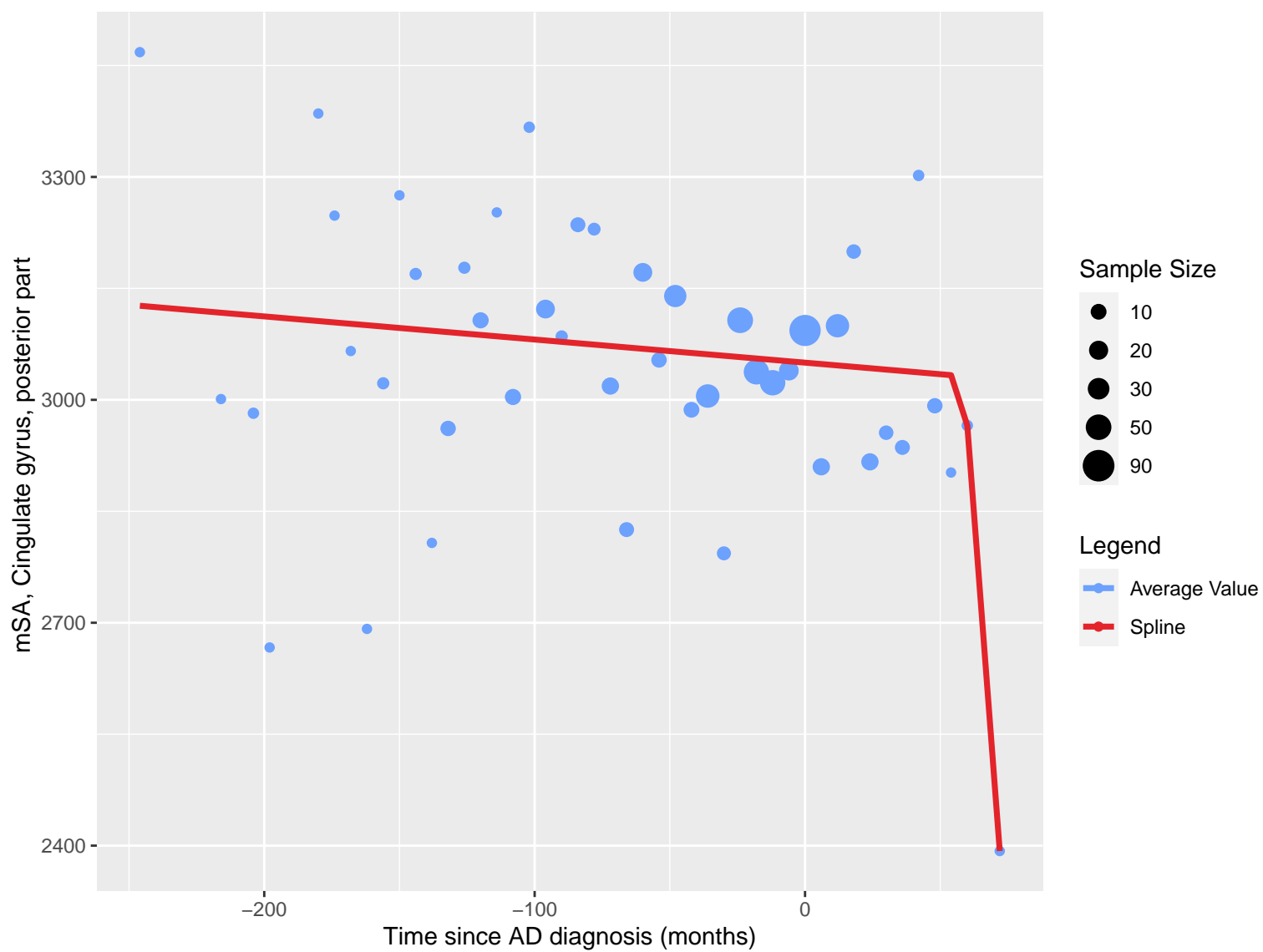


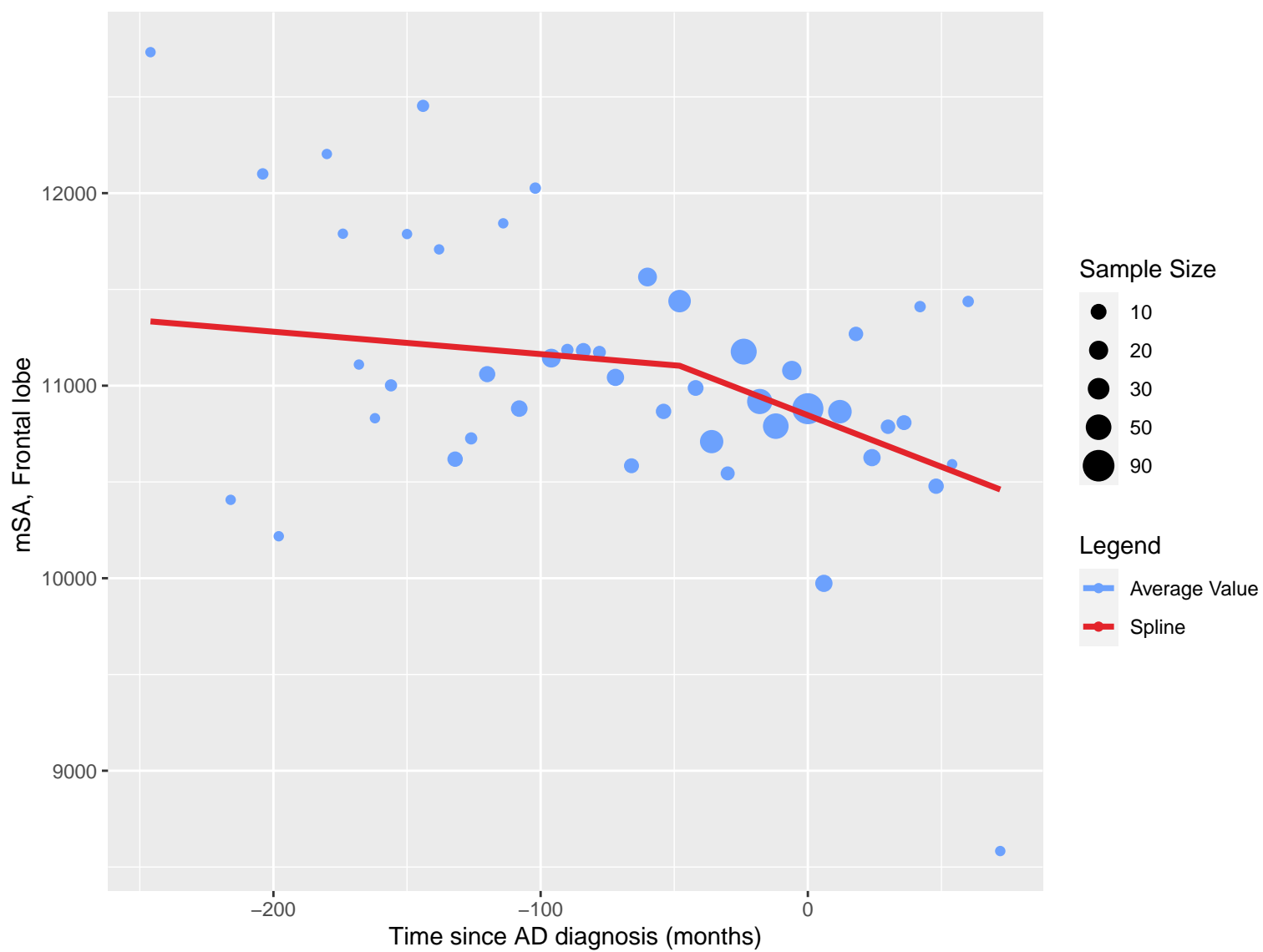


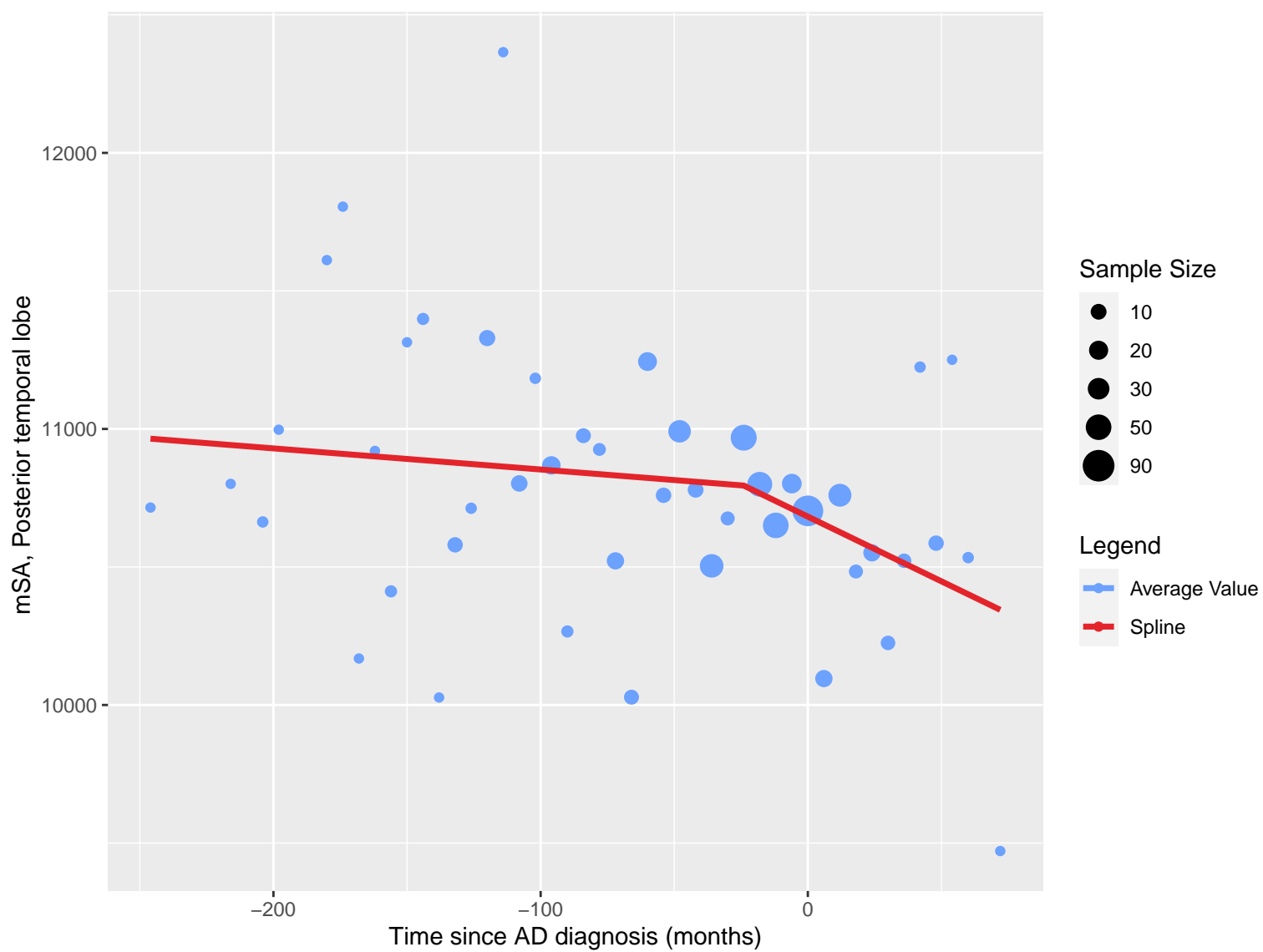


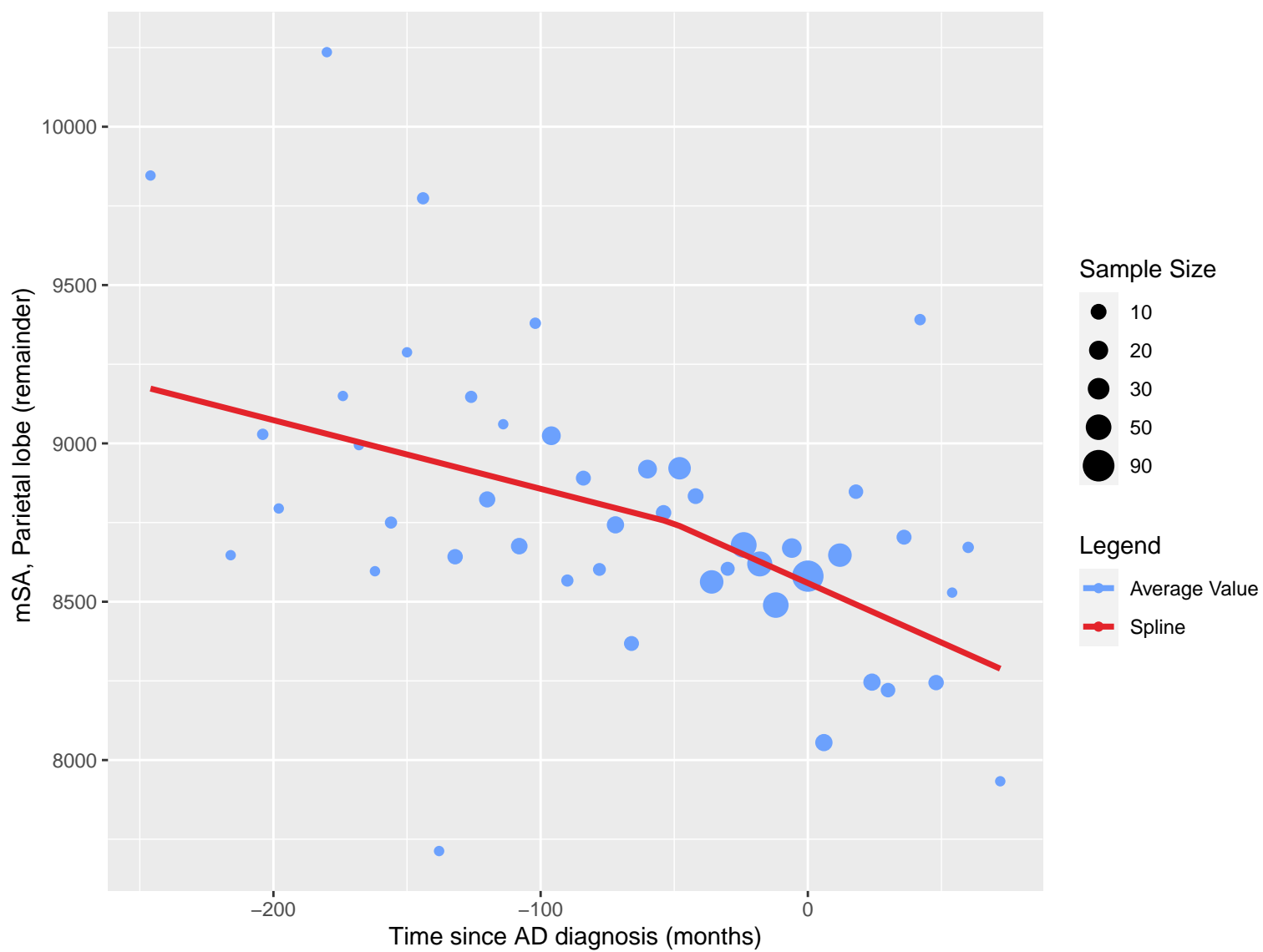


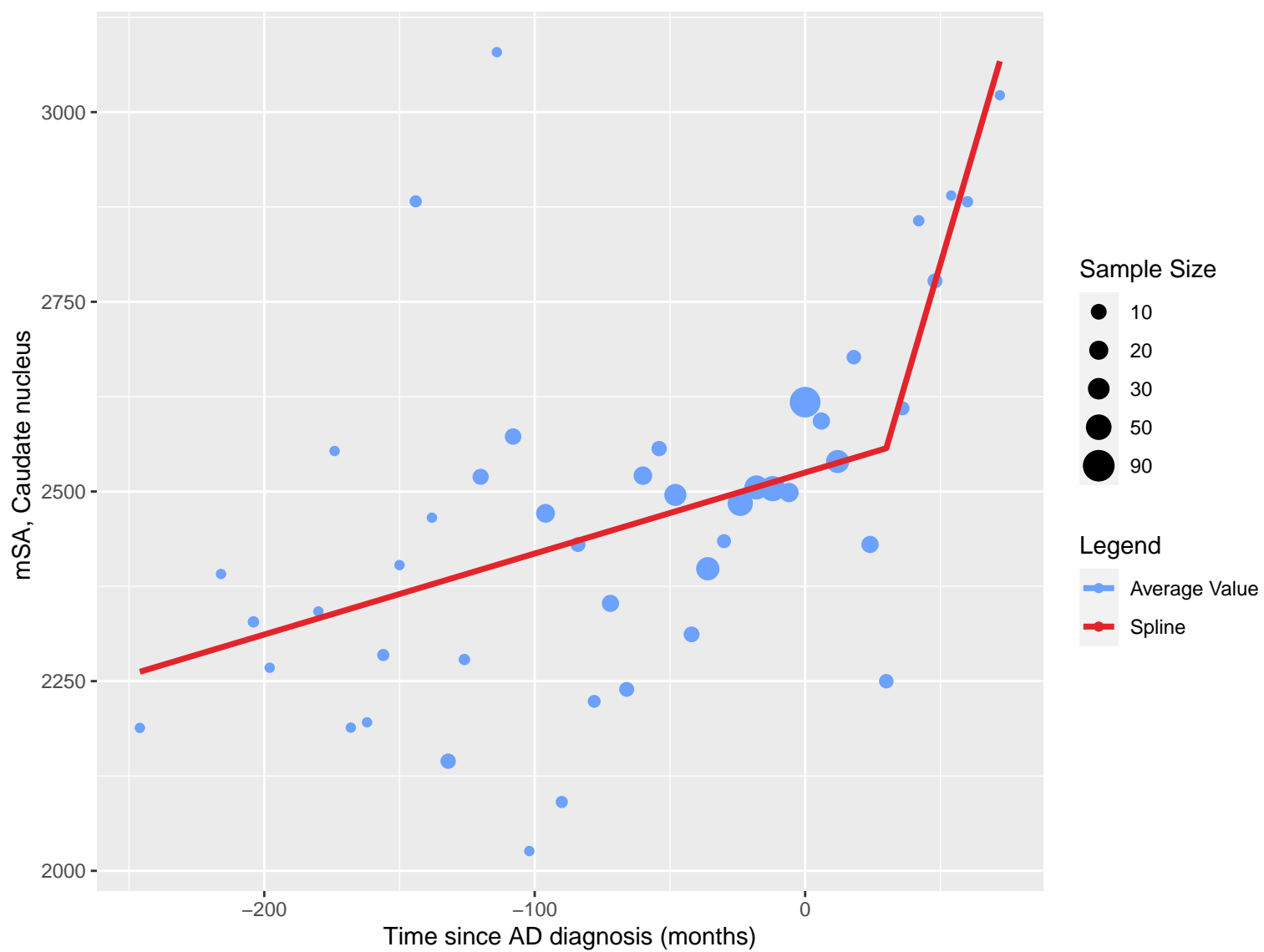


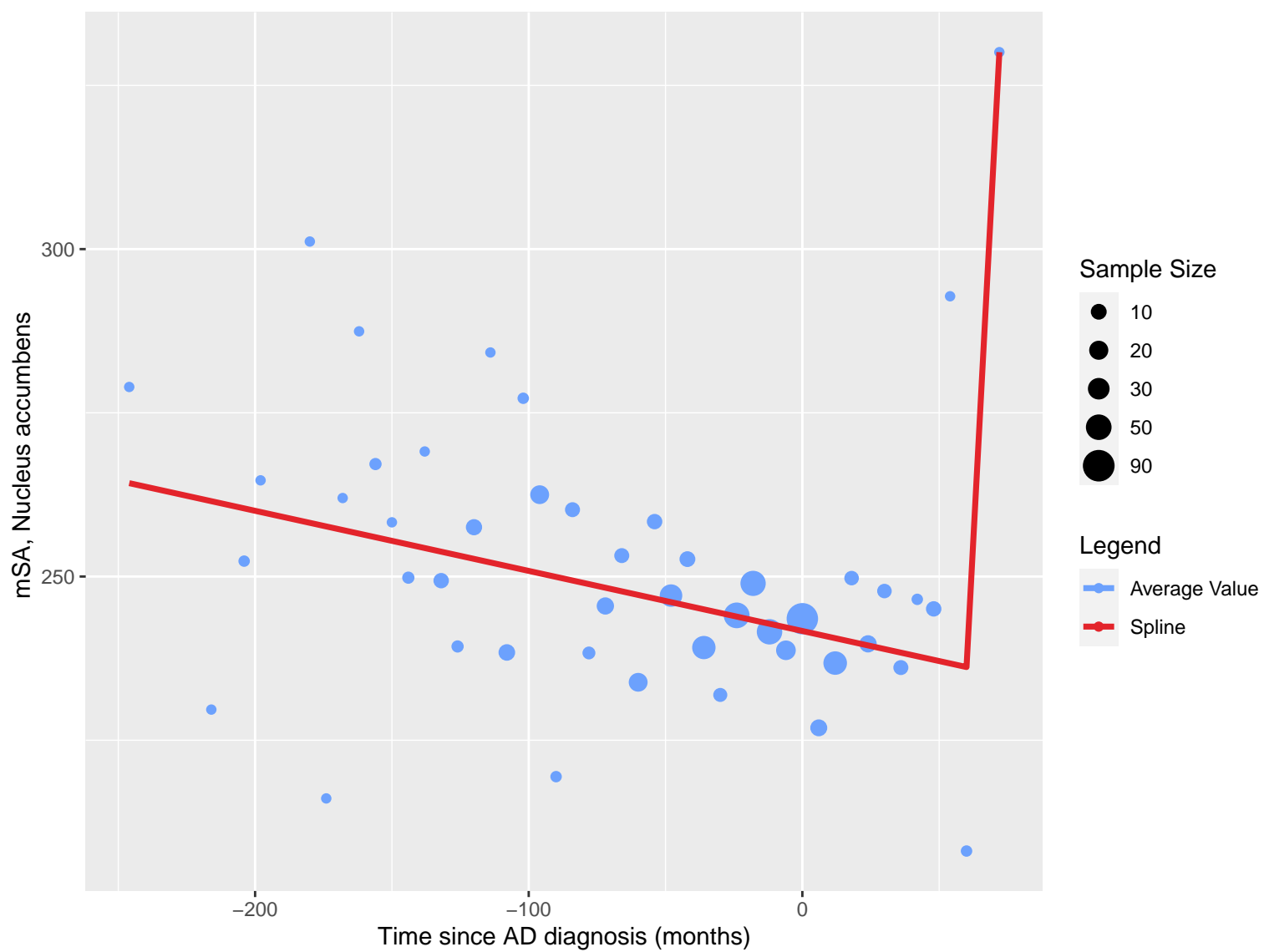




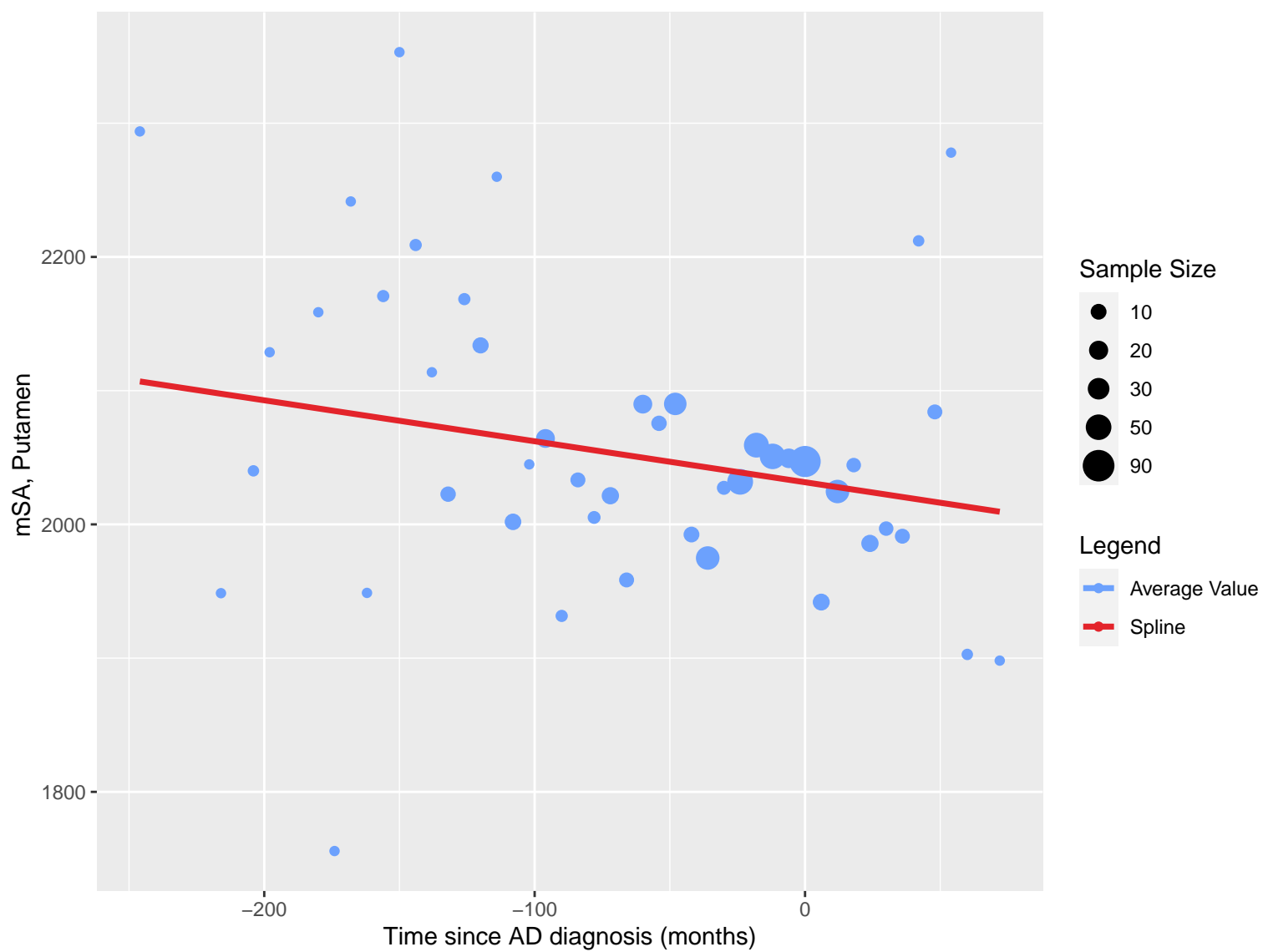


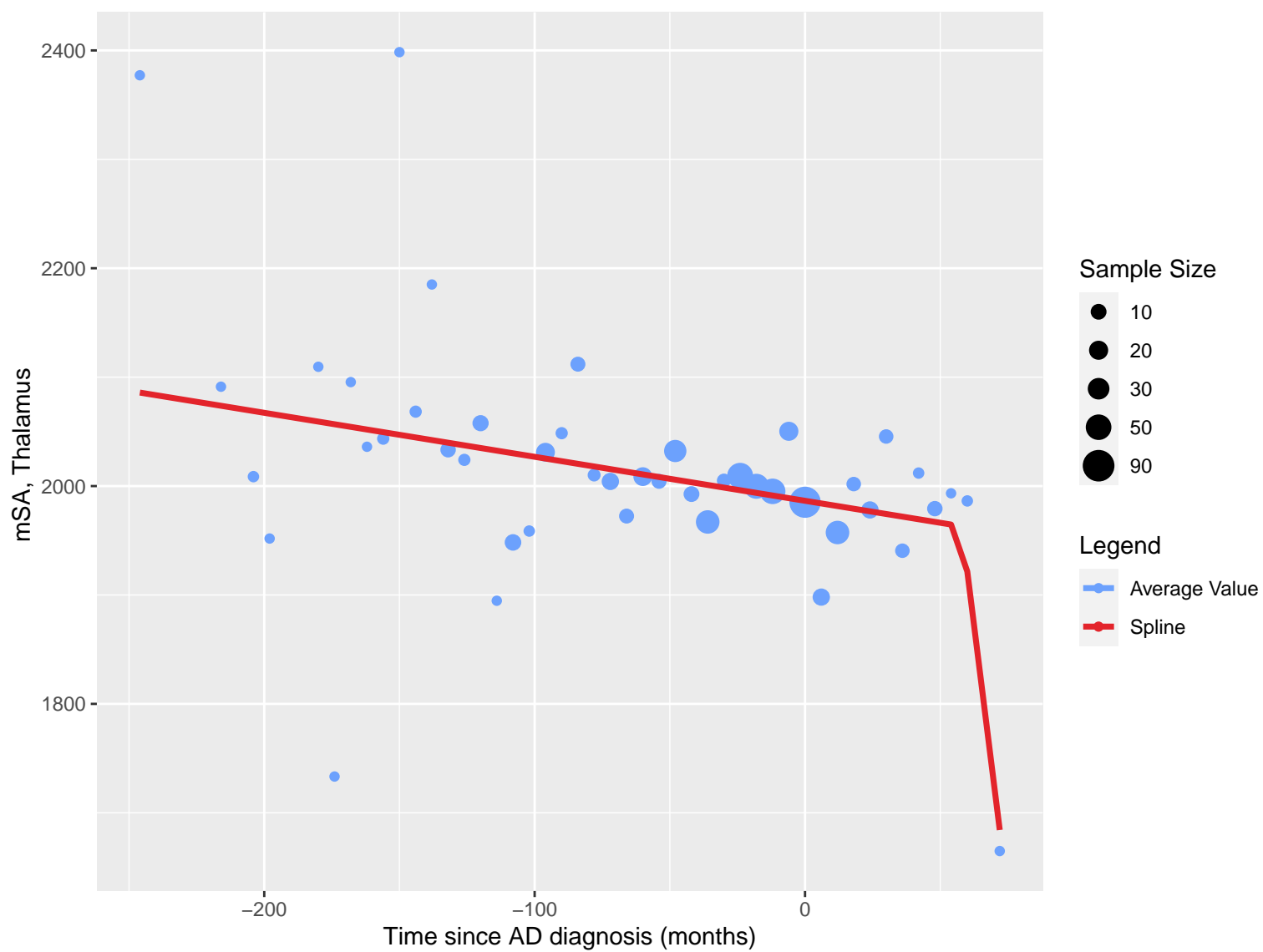


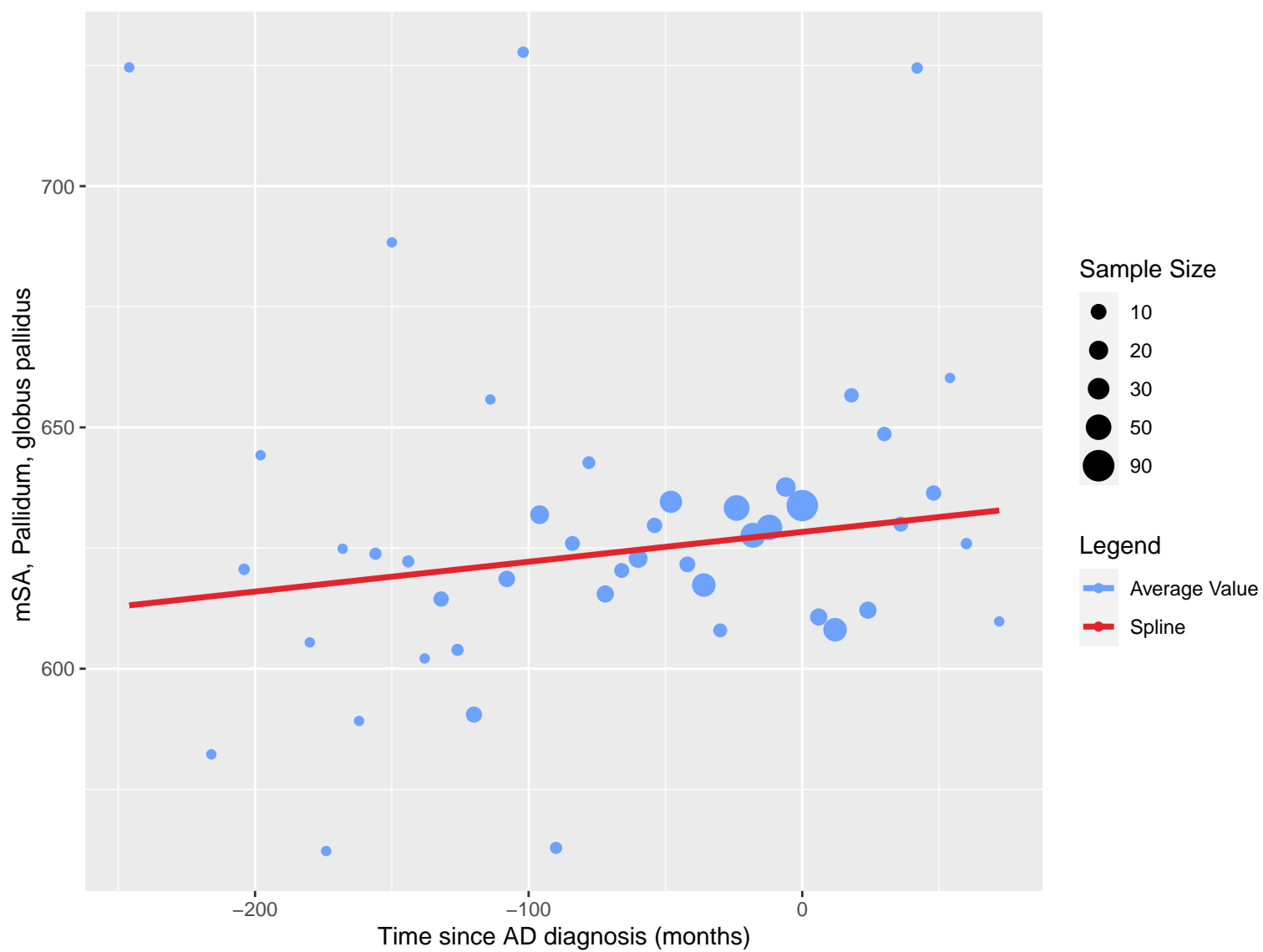








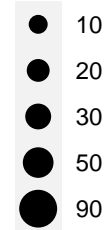




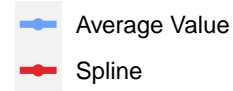
mSA, Lateral ventricle, frontal horn, central part and occipital horn

Time since AD diagnosis (months)

Sample Size



Legend



10000

8000

6000

-200

-100

0

mSA, Lateral ventricle, temporal horn

1000

900

800

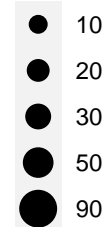
-200

-100

0

Time since AD diagnosis (months)

Sample Size



Legend

