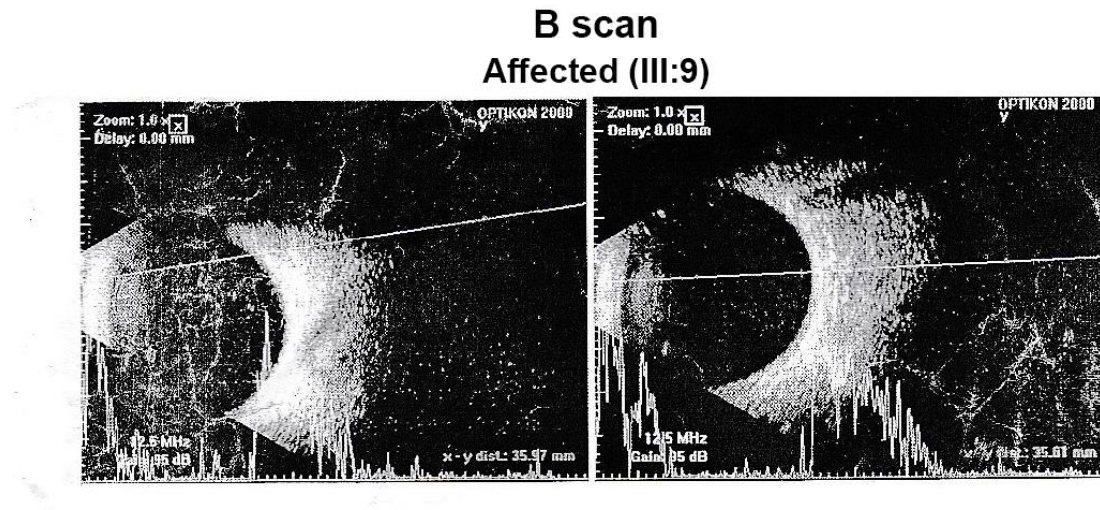


Delineating the Molecular and Phenotypic Spectrum of the *CNGA3*-Related Cone Photoreceptor Disorder in Pakistani Families

Sairah Yousaf ¹, Nabeela Tariq ², Zureesha Sajid ³, Shakeel A. Sheikh ⁴, Tasleem Kausar ⁵, Yar M. Waryah ⁶, Rehan S. Shaikh ^{3,7}, Ali M. Waryah ⁴, Saumil Sethna ^{1,†}, Saima Riazuddin ^{1,8} and Zubair M. Ahmed ^{1,8,9,*}



Axial scan of right eye shows intact posterior capsule region. In transverse and longitudinal scan right eye shows multiple low intensity echoes in vitreous cavity. Retina is in situ. Choroid, Optic nerve head, extra-ocular muscles and retro-ocular fat are within normal limits. No evidence of IOFB is seen.

IMPRESSION: R.E vitreous opacities

Figure S1: Axial B-scan of right eye of affected individual (III:9) of PKED06.