

Clinically Relevant Prenatal Ultrasound Diagnosis of Umbilical Cord Pathology

Roxana Elena Bohîlțea ^{1,2,*}, Vlad Dima ^{2,*}, Ioniță Ducu ³, Ana Maria Iordache ^{4,*}, Bianca Margareta Mihai ², Octavian Munteanu ⁵, Corina Grigoriu ^{1,3,*}, Alina Veduță ², Dimitrie Pelinescu-Onciul ¹ and Radu Vlădăreanu ¹

¹ Department of Obstetrics and Gynecology, “Carol Davila” University of Medicine and Pharmacy Bucharest, 37 Dionisie Lupu, 020021 Bucharest, Romania; dimitriepelinescu@yahoo.com (D.P.-O.); vladareanu@gmail.com (R.V.)

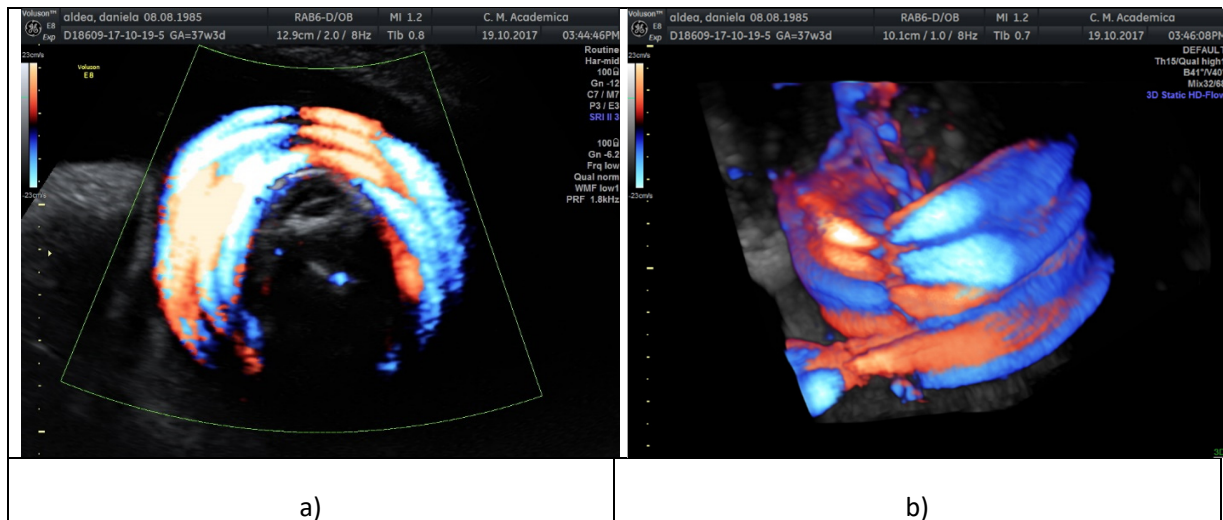
² Department of Obstetrics, Gynecology and Neonatology, Filantropia Hospital, 11–13 Ion Mihalache Blv., Sector 1, 011171 Bucharest, Romania; bmmihai@gmail.com (B.M.M.); alina.veduta@gmail.com (A.V.)

³ Department of Obstetrics and Gynecology, University Emergency Hospital, 169 Splaiul Independentei Bld., sector 5, 050098 Bucharest, Romania; ionitaducu@gmail.com

⁴ Optospintronics Department, National Institute for Research and Development in Optoelectronics-INOE 2000, 409 Atomistilor, 077125 Magurele, Romania

⁵ Department of Anatomy, “Carol Davila” University of Medicine and Pharmacy Bucharest, 37 Dionisie Lupu, 020021 Bucharest, Romania; octav_munteanu@yahoo.com

* Correspondence: r.bohiltea@yahoo.com (R.E.B.); dima.vlad@yahoo.com (V.D.); ana.iordache@inoe.ro (A.M.I.); corigri@gmail.com (C.G.)



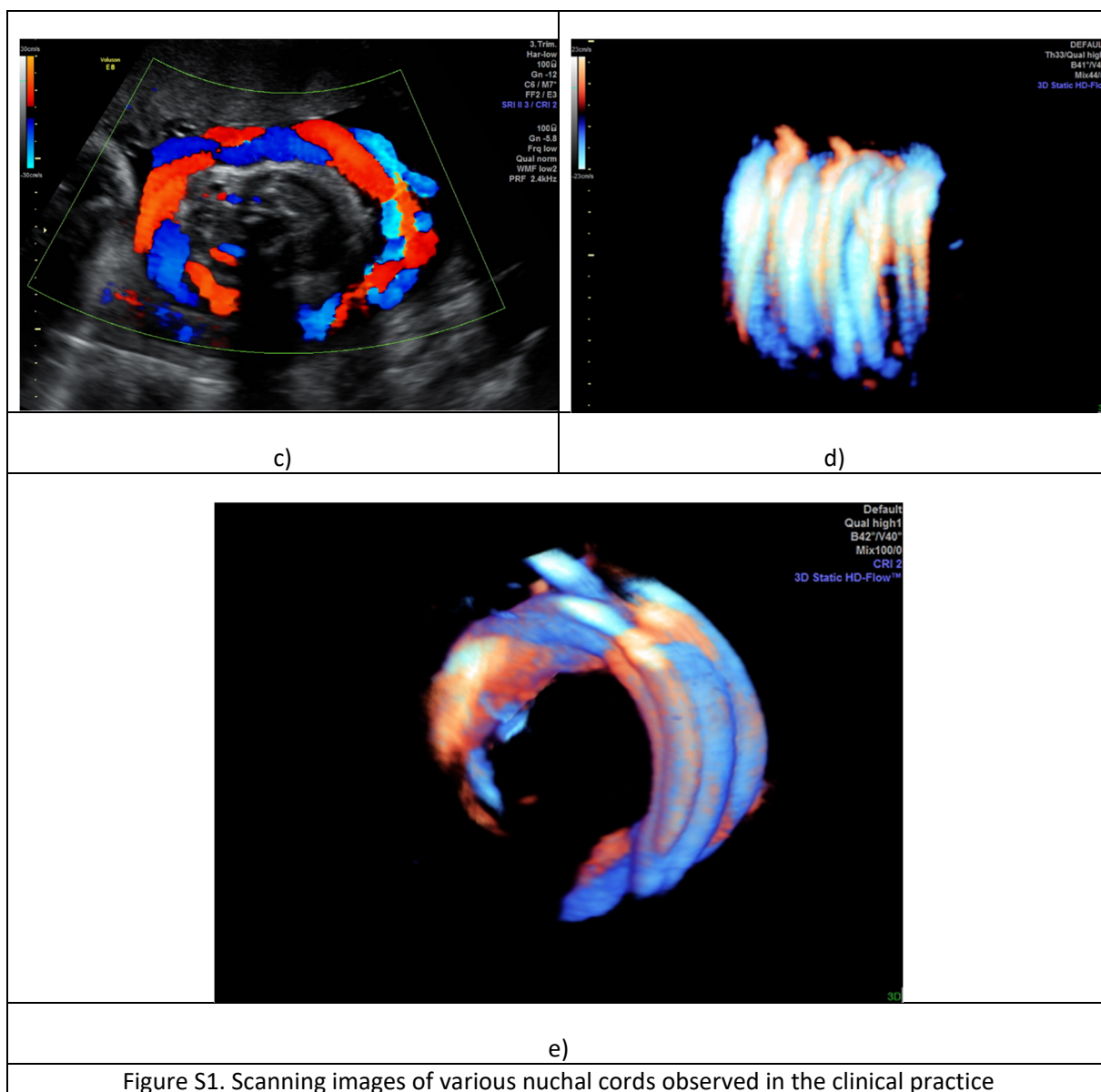


Figure S1. Scanning images of various nuchal cords observed in the clinical practice

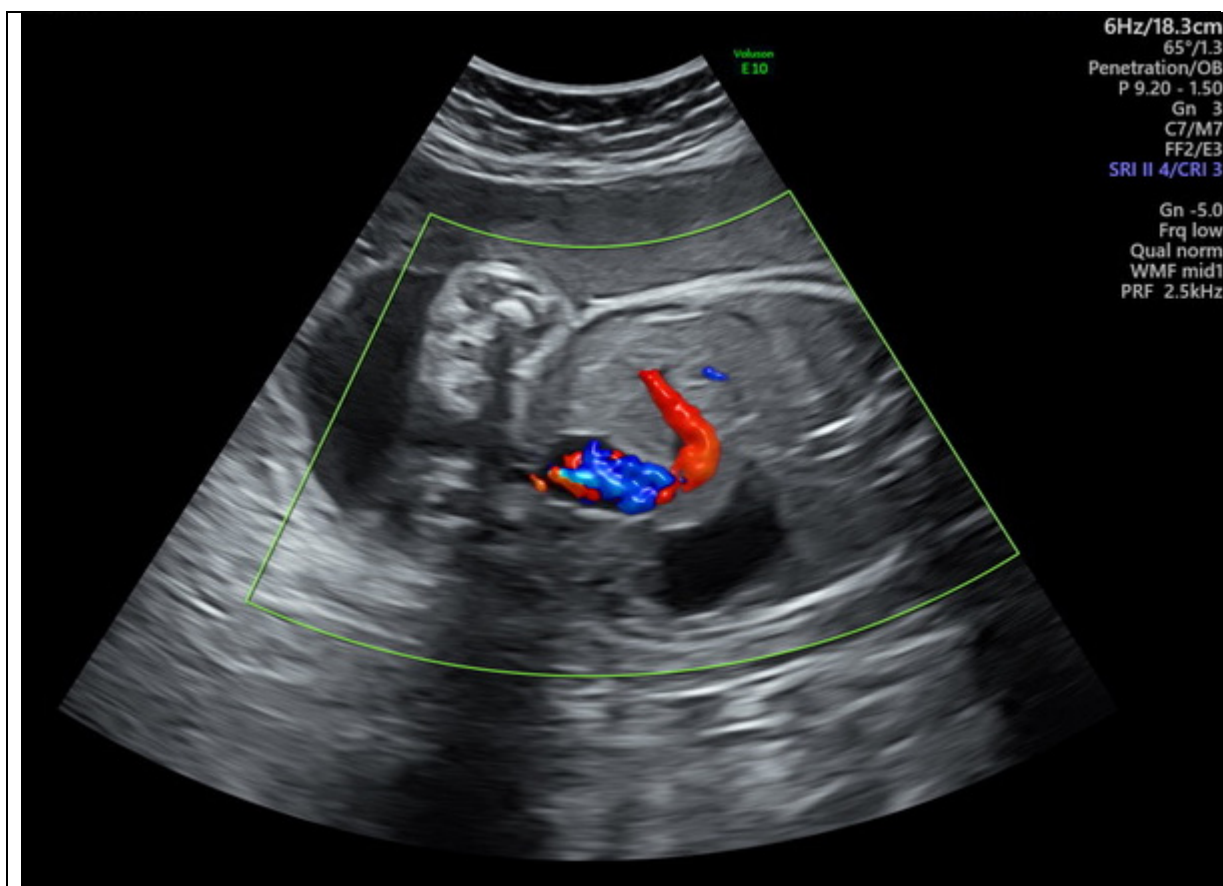


Figure S2. 3D imaging of varix cords

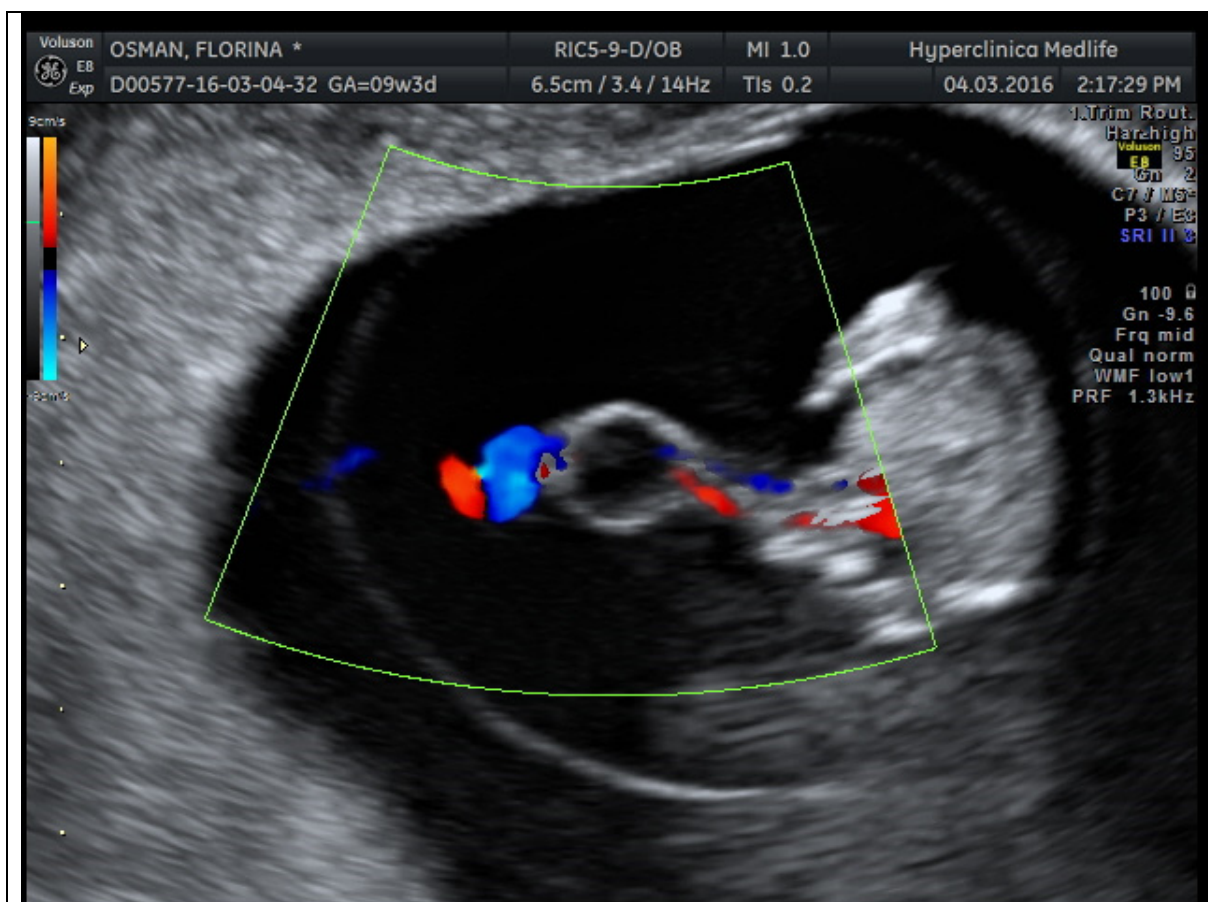


Figure S3. Cystic abnormalities

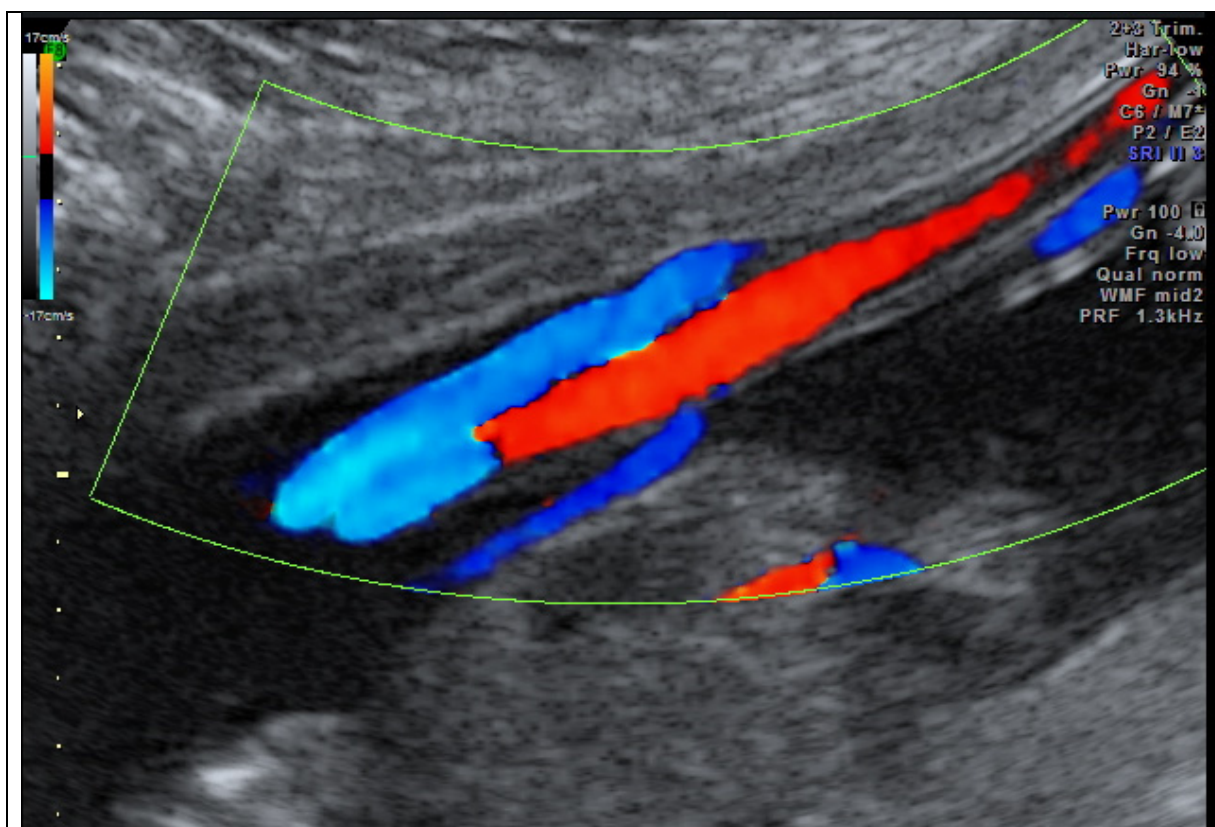


Figure S4. Coiling pathologies: lax cord