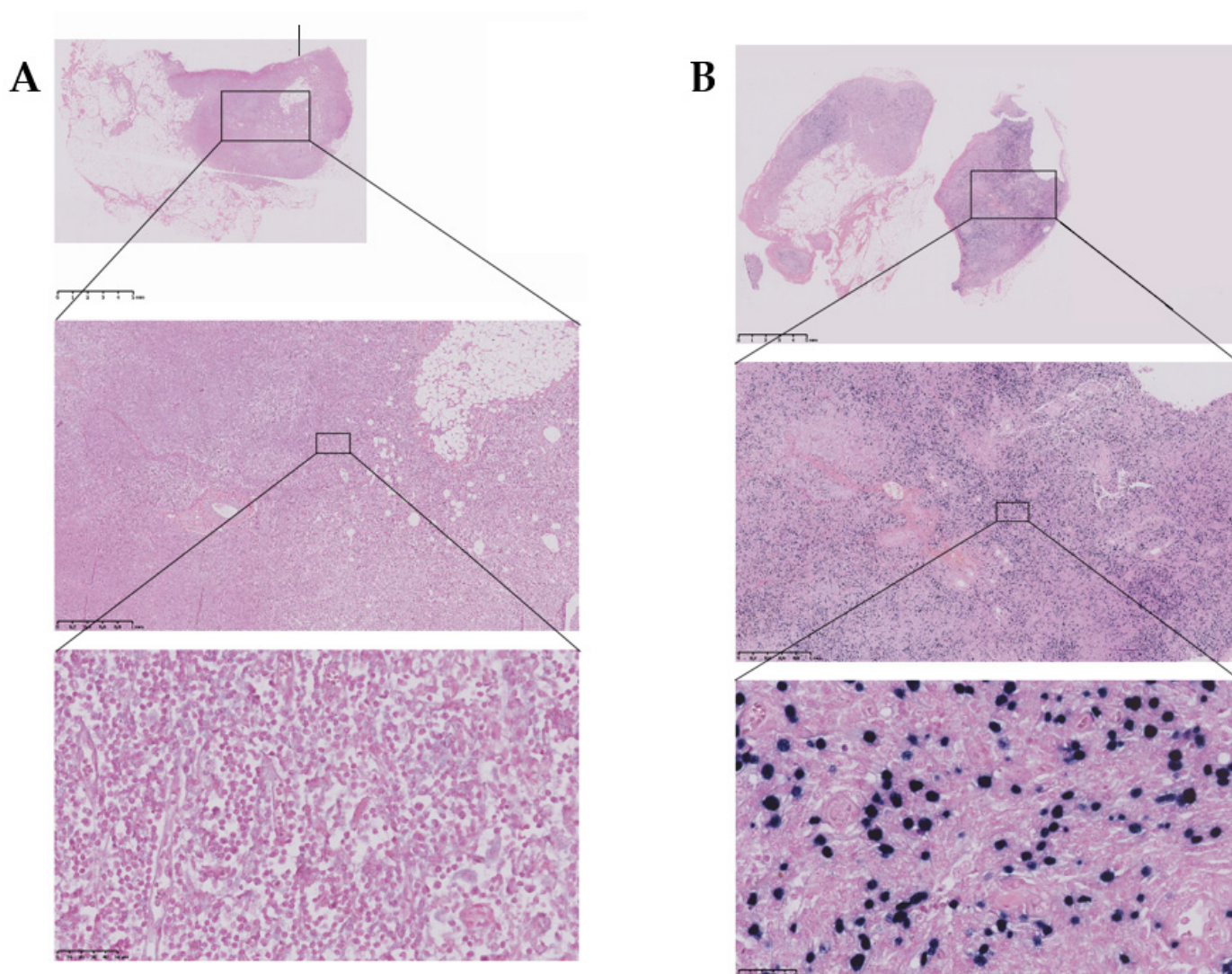


*Supplementary Material*

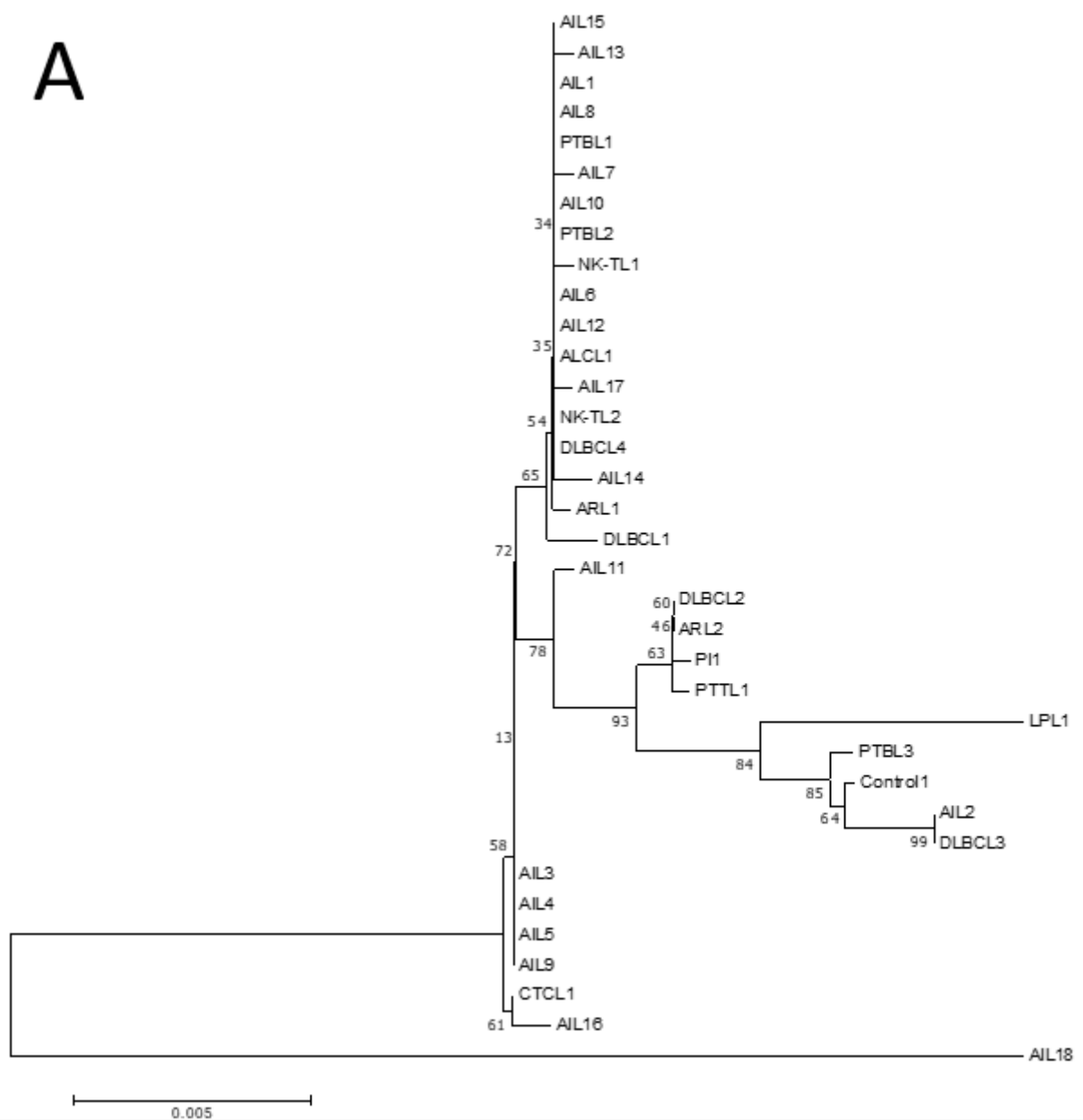
# Epstein-Barr Virus (EBV) Is Mostly Latent and Clonal in Angioimmunoblastic T Cell Lymphoma (AITL)

Racha Bahri, François Boyer, Mohamad Adnan Halabi, Alain Chaunavel, Jean Feuillard, Arnaud Jaccard and Sylvie Ranger-Rogez \*

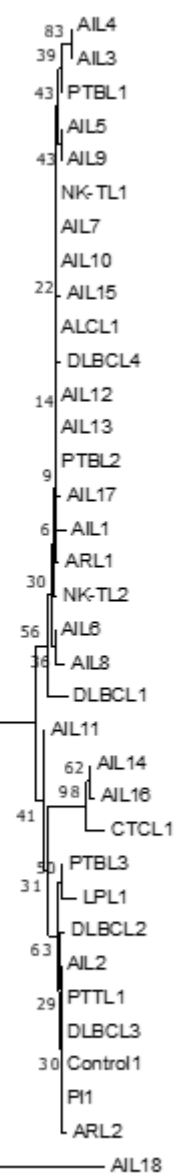


**Figure S1.** Results obtained for EBER ISH staining. (A) Negative staining for control 1 (B) Positive staining for AIL8 patient for example.

A



B



0.02

