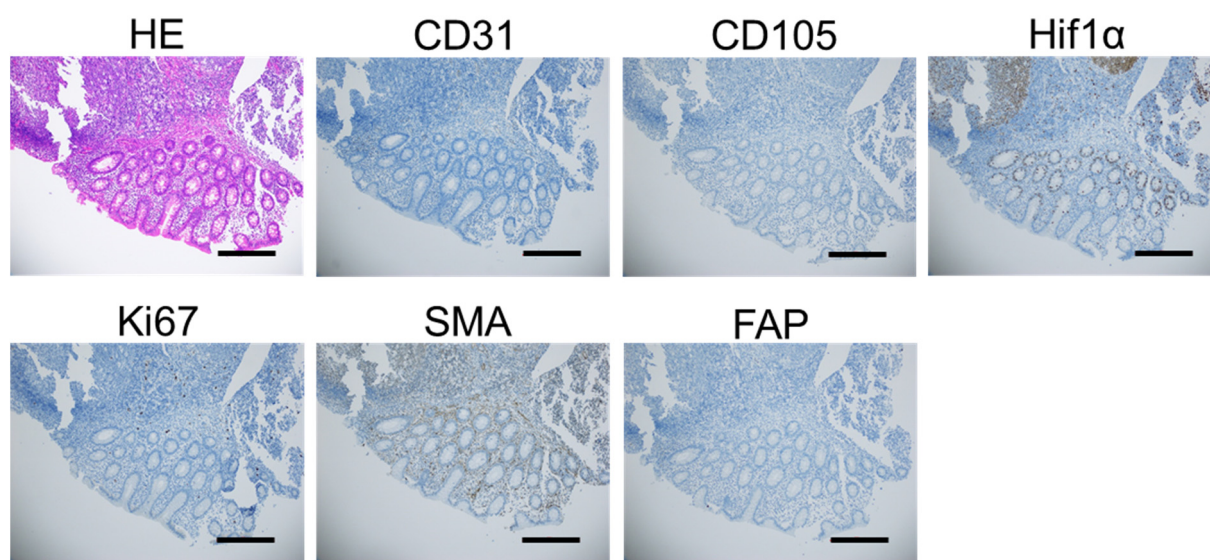


# Anti-Angiogenic Treatment in Pseudomyxoma Peritonei—Still a Strong Preclinical Rationale

Yvonne Andersson, Karianne G. Fleten, Torveig W. Abrahamsen, Wenche Reed, Ben Davidson and Kjersti Flatmark



**Figure S1.** Immunohistochemical images showing HE, CD31, CD105, Hif1 $\alpha$ , Ki67, SMA and FAP staining in normal appendix as a control to stainings shown in Figure 1. Scale bar indicate 300  $\mu$ M.

**Table S1.** Properties of the PDX models used in experiments: Patient characteristics; immunohistochemistry (IHC); mutation analysis by targeted next-generation sequencing. The number of immunoreactive tumor cells was semi-quantitatively evaluated: 0 (no positive cells); 1 = 1% to 5%; 2 = 6% to 25%; 3 = 26% to 75%; and 4 = 75% to 100%. The data was previously published in [1–3].

Patient Characteristics	PMP-2	PMCA-1	PMCA-3
Age	56	68	62
Gender	F	F	M
<b>IHC parameters</b>			
CK20	4	0	4
CK7	4	4	1
CEA	4	4	4
Vimentin	0	0	0
Ki67	2	3	3
VEGF	0	0	0
<b>Mutations</b>			
KRAS	G12V	G12A	WT
GNAS	R201C	WT	R201C
BRAF	WT	WT	V600E

## References

- Flatmark, K.; Davidson, B.; Kristian, A.; Stavnes, H.T.; Førsund, M.; Reed, W. Exploring the peritoneal surface malignancy phenotype—a pilot immunohistochemical study of human pseudomyxoma peritonei and derived animal models. *Human Pathology* **2010**, *41*, 1109–1119.

2. Flatmark, K.; Reed, W.; Halvorsen, T.; Sorensen, O.; Wiig, J.N.; Larsen, S.G.; Fodstad, O.; Giercksky, K.E. Pseudomyxoma peritonei--two novel orthotopic mouse models portray the PMCA-I histopathologic subtype. *BMC Cancer* **2007**, *7*, 116, doi:10.1186/1471-2407-7-116.
3. Fleten, K.G.; Lund-Andersen, C.; Waagene, S.; Abrahamsen, T.W.; Mørch, Y.; Boye, K.; Torgunrud, A.; Flatmark, K. Experimental Treatment of Mucinous Peritoneal Metastases Using Patient-Derived Xenograft Models. *Translational oncology* **2020**, *13*, 100793.