

# Management of Acute Radiodermatitis in Non-Melanoma Skin Cancer Patients Using Electrospun Nanofibrous Patches Loaded with *Pinus halepensis* Bark Extract

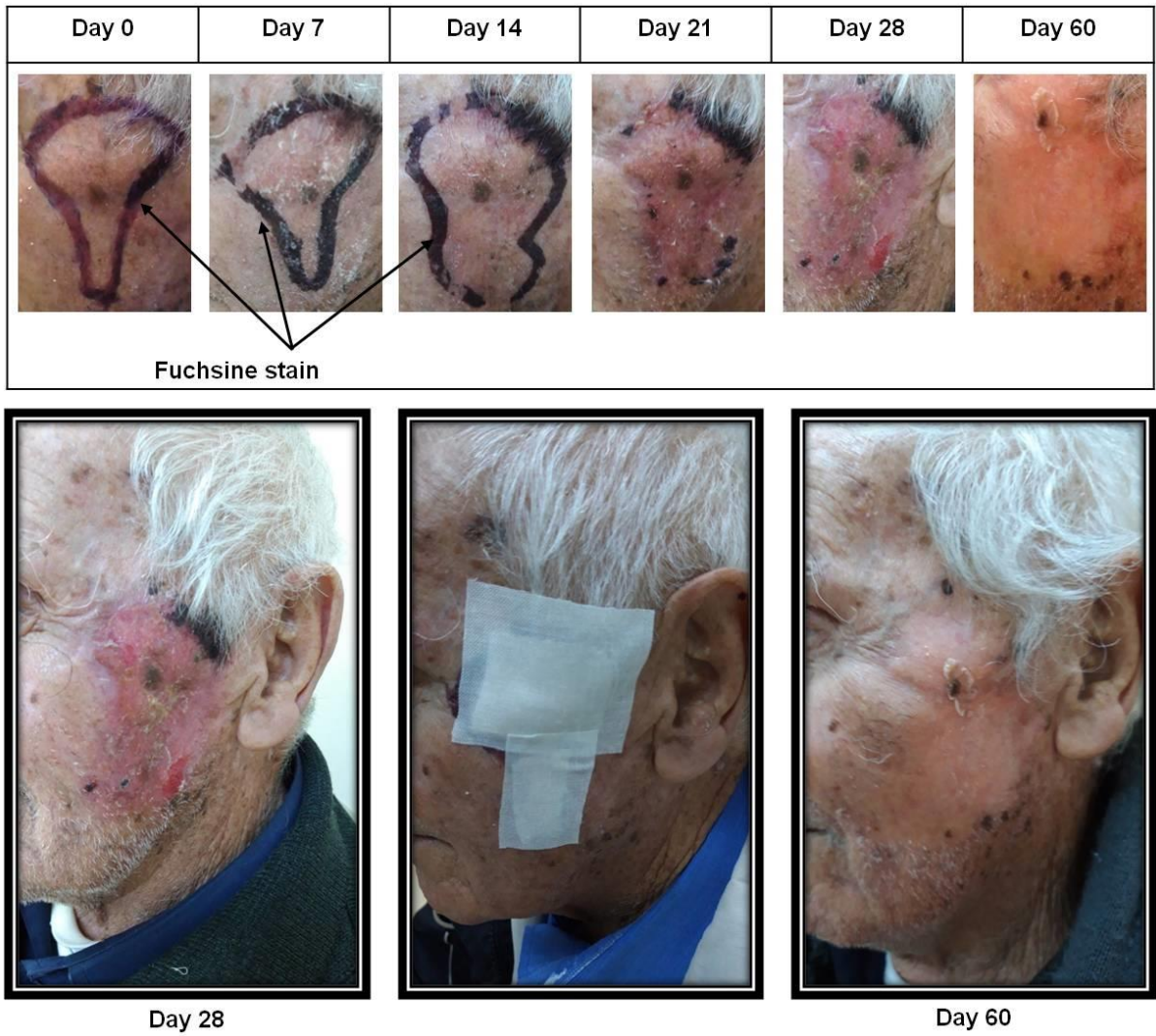
Aikaterini Kyritsi <sup>1</sup>, Stefanos Kikionis <sup>2</sup>, Anna Tagka <sup>3</sup>, Nikolaos Koliarakis <sup>3</sup>, Antonia Evangelatou <sup>3</sup>, Panagiotis Papagiannis <sup>3</sup>, Alexandros Stratigos <sup>3</sup>, Vangelis Karalis <sup>1</sup>, Paraskevas Dallas <sup>1</sup>, Andreas Vitsos <sup>1</sup>, Efstathia Ioannou <sup>2</sup>, Vassilios Roussis <sup>2,\*</sup> and Michail Rallis <sup>1,\*</sup>

<sup>1</sup> Section of Pharmaceutical Technology, Department of Pharmacy, School of Health Sciences, National and Kapodistrian University of Athens, Panepistimiopolis Zografou, Athens 15784, Greece; katerinakyr18394@gmail.com (A.K.); vkaralis@pharm.uoa.gr (V.K.); dallas@pharm.uoa.gr (P.D.); avitsos@yahoo.gr (A.V.)

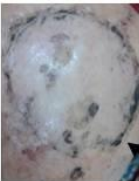
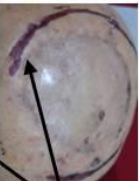







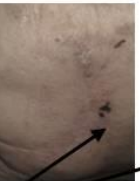















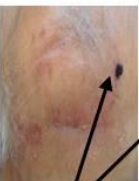







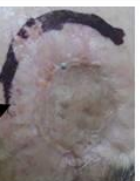


<sup>2</sup> Section of Pharmacognosy and Chemistry of Natural Products, Department of Pharmacy, School of Health Sciences, National and Kapodistrian University of Athens, Panepistimiopolis Zografou, Athens 15771, Greece; skikionis@pharm.uoa.gr (S.K.); eioannou@pharm.uoa.gr (E.I.)

<sup>3</sup> First Department of Dermatology-Venereology, National and Kapodistrian University of Athens, Andreas Syggros Hospital, 5 Ionos Dragoumi Str., Athens 11621, Greece; annatagka@gmail.com (A.T.); nkoliarakis@yahoo.gr (N.K.); antevagelatou@gmail.com (A.E.); PPaPagi@med.uoa.gr (P.P.); alstrat2@gmail.com (A.S.)






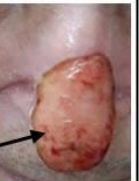


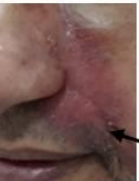















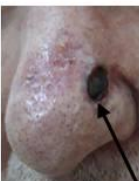
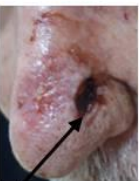
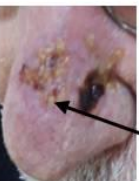


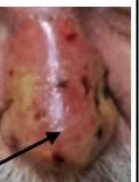






\* Correspondence: roussis@pharm.uoa.gr (V.R.); rallis@pharm.uoa.gr (M.R.); Tel.: +30-210-7274592 (V.R.); +30-210-7274699 (M.R.)



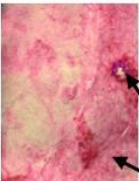
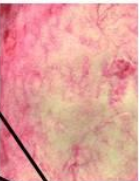
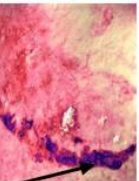

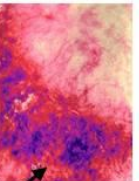
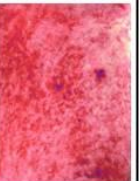


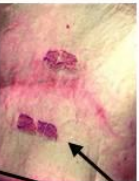




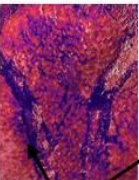
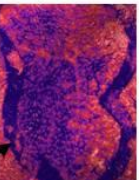

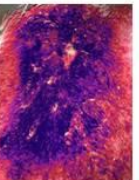
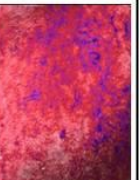
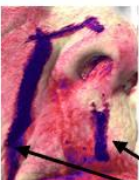




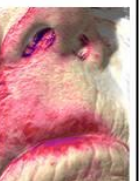

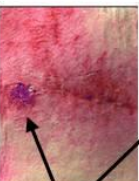
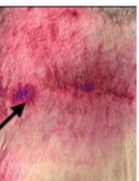

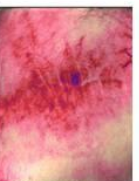

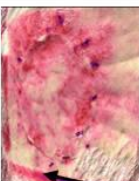
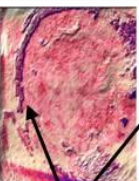
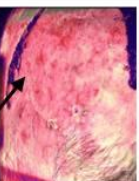
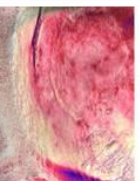

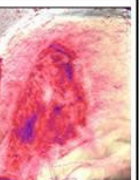
**Figure S1.** Application of the PHBE patch on a representative patient enrolled in the study.

Patient	Day 0	Day 7	Day 14	Day 21	Day 28	Day 60
(1)						
		Fuchsine stain		Irritant Contact Dermatitis		
(2)						
		Fuchsine stain				
(3)						
		Fuchsine stain				
(4)						
		Fuchsine stain				
(5)						
		Fuchsine stain				
(6)						
		Fuchsine stain				



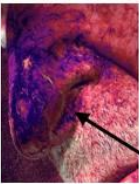
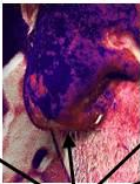
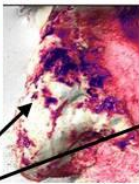
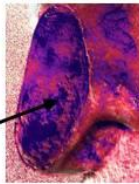


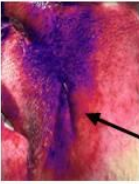
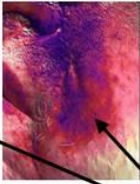

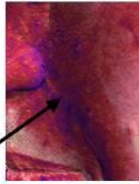
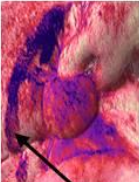

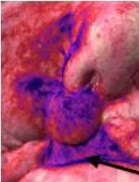
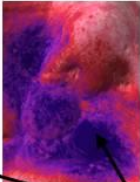
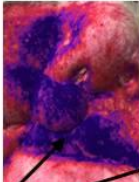
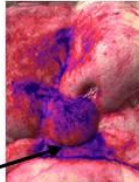
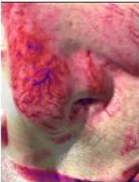
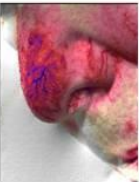
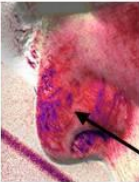

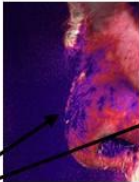
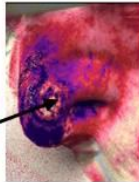
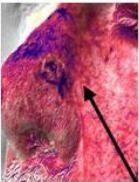
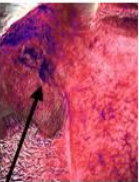
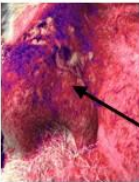
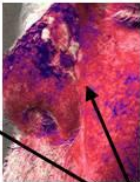
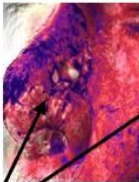
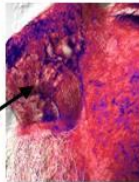




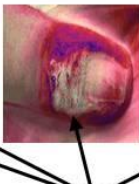
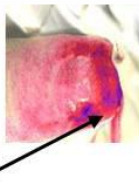
**Figure S2.** Images of all patients treated with PHBE patch, during days 7, 14, 21, and 28, and one month after RT (day 60).

Patient	Day 0	Day 7	Day 14	Day 21	Day 28	Day 60
(7)						
	Acute Radiodermatitis					
(8)						
	Fuchsine stain		Acute Radiodermatitis			
(9)						
	Fuchsine stain		Acute Radiodermatitis			
(10)						
	Acute Radiodermatitis					
(11)						
	Fuchsine stain		Acute Radiodermatitis			
(12)						
	Acute Radiodermatitis					

**Figure S3.** Images of all patients treated with the reference product, during days 7, 14, 21, and 28, and one month after RT (day 60).

Patient	Day 0	Day 7	Day 14	Day 21	Day 28	Day 60
(1)						
	Fuchsine stain		Irritant Contact Dermatitis			
(2)						
	Fuchsine stain					
(3)						
	Fuchsine stain					
(4)						
	Fuchsine stain					
(5)						
	Fuchsine stain					
(6)						
	Fuchsine stain					

**Figure S4.** Antera 3D images of all patients treated with PHBE patch, during days 7, 14, 21, and 28, and one month after RT (day 60).

Patient	Day 0	Day 7	Day 14	Day 21	Day 28	Day 60
(7)						
	Acute Radiodermatitis					
(8)						
	Acute Radiodermatitis					
(9)						
	Fuchsine stain	Acute Radiodermatitis				
(10)						
	Acute Radiodermatitis					
(11)						
	Fuchsine stain	Acute Radiodermatitis				
(12)						
	Acute Radiodermatitis					

**Figure S5.** Antera 3D images of all patients treated with the reference product, during days 7, 14, 21, and 28, and one month after RT (day 60).