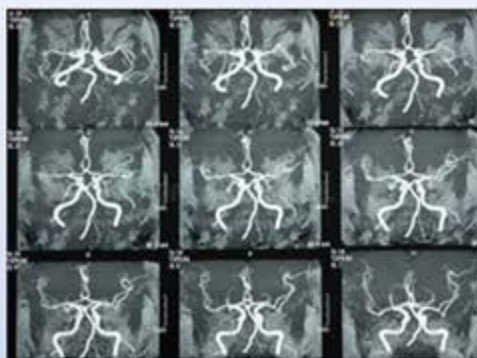
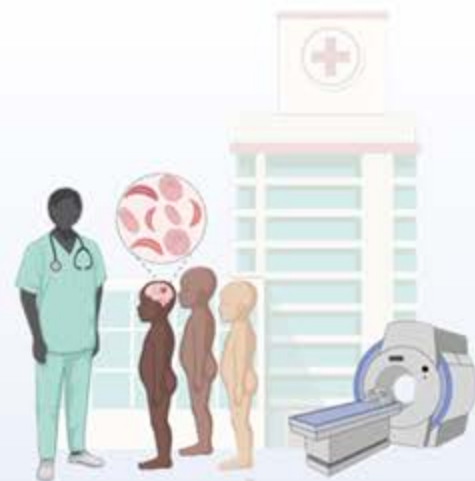


# Supplementary Figure S1

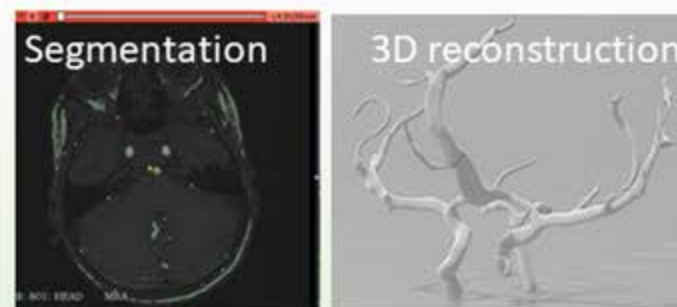
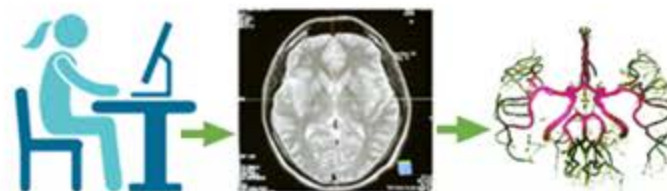## Step1: MRI imaging

Children ages 5-15 years with SCD

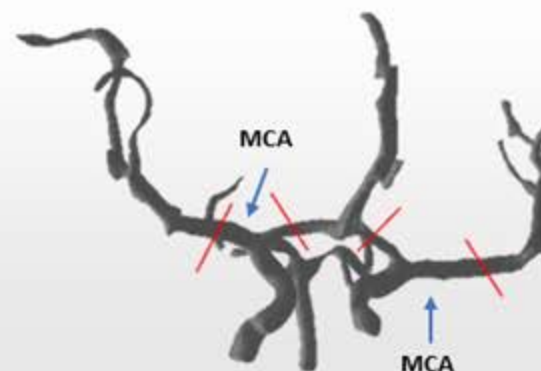


## Step2: Image processing

Feature extract



Isolation of left and right MCA



## Step3: CFD and Data analysis

Feature selection

