therapeutics

MDPI

Review

Multimodal Management of Spinal Cord Hemangioblastomas: A Comprehensive Review

Francisco Alfredo Call-Orellana [1,*], Juan Pablo Zuluaga-Garcia [1], Maria Alejandra Sierra [2,3], Mariana Zuluaga-Garcia [4], Esteban Ramirez-Ferrer [1] and Alejandro Bugarini [1]

[1] Department of Neurosurgery, The University of Texas M.D. Anderson Cancer Center, Houston, TX 77030, USA; jpzuluaga@mdanderson.org (J.P.Z.-G.); eramirez14@mdanderson.org (E.R.-F.); abugarini@mdanderson.org (A.B.)
[2] Faculty of Medicine, Universidad del Rosario, Bogota 110221, Colombia; mariaaleja.sierra@urosario.edu.co
[3] Department of Neurosurgery, Center of Research and Training in Neurosurgery, Bogota 110221, Colombia
[4] Faculty of Medicine, Universidad EIA, Medellin 050021, Colombia; mariana.zuluaga41@eia.edu.co
* Correspondence: facall@mdanderson.org

Abstract

Spinal cord hemangioblastomas are rare, benign, and highly vascular tumors that occur sporadically or in association with von Hippel–Lindau disease. Despite their histological benignity, they often cause significant morbidity due to progressive neurological deficits, syrinx formation, and recurrence in the von Hippel-Lindau population. We performed a comprehensive review of the literature by searching PubMed, EMBASE, and Scopus for studies published in English on spinal cord hemangioblastomas. Eligible studies included original research, case series, and case reports with explicit clinical outcomes or management strategies for pathologically or radiographically confirmed SCHb. Gross total resection is feasible in most cases, leading to durable tumor control and favorable neurological outcomes. Preoperative embolization has been employed selectively to reduce intraoperative bleeding. Radiotherapy, particularly stereotactic radiosurgery, has shown promising local control for surgically inaccessible or recurrent lesions, while conventional external beam approaches provide less consistent results. Anti-angiogenic agents have demonstrated anecdotal benefit, and the HIF-2α inhibitor belzutifan represents the first systemic therapy approved by the FDA for VHL-associated hemangioblastomas. The management of SCHb requires an individualized, multimodal strategy. Microsurgery remains the cornerstone of treatment; radiotherapy and pharmacotherapy are valuable adjuncts for specific clinical scenarios. Further prospective studies are needed to optimize patient selection and integration of these therapies.

Keywords: embolization; hemangioblastoma; intramedullary tumors; pharmacotherapy; radiotherapy; surgical management

Check for updates

Academic Editor: Nejat Düzgüneş

Received: 30 January 2026
Revised: 3 April 2026
Accepted: 23 April 2026
Published: 12 May 2026

Copyright: © 2026 by the authors. Licensee MDPI, Basel, Switzerland. This article is an open access article distributed under the terms and conditions of the Creative Commons Attribution (CC BY) license.

1. Introduction

Hemangioblastomas are rare, benign, and highly vascular tumors of the central nervous system (CNS), with an overall reported incidence of approximately 0.141 per 100,000 person-years on the Surveillance, Epidemiology, and End Results (SEER)-18 registry data encompassing 2062 cases in the United States [1]; this figure reflects all CNS hemangioblastomas and should be interpreted in the context of its registry-based, geographically limited derivation, as comparable population-level data from other world regions are lacking. Spinal cord hemangioblastomas specifically carry a considerably

lower incidence, estimated at 0.014 per 100,000 person-years based on the SEER data from 2000 to 2010 [2], with a modest male predominance and the highest rates reported among Caucasian individuals. These tumors most often arise in the cerebellum and brainstem, with up to 13–50% occurring in the dorsal spinal cord [3,4]. They may be sporadic or associated with von Hippel–Lindau (VHL) disease, where 60–80% of patients eventually develop CNS lesions [5]. Although histologically benign, spinal cord hemangioblastomas (SCHb) can cause significant morbidity due to mass effect, syrinx formation, and their high recurrence rate in VHL.

Microsurgical resection remains the mainstay of treatment—particularly for symptomatic patients and those with threatened neurologic function—and can achieve high rates of gross total resection (GTR) [6]. Selective preoperative embolization may, in theory, facilitate resection, but carries high risks, including spinal cord ischemia [7]. Radiotherapy, particularly stereotactic radiosurgery (SRS), offers an alternative for inoperable or recurrent lesions [8]. More recently, systemic therapy with HIF-2α inhibitors such as belzutifan has shown promise in VHL-associated hemangioblastomas [9].

While prior reviews have addressed hemangioblastomas broadly across cranial and spinal locations, none have provided a spinal cord-specific synthesis integrating all currently available treatment modalities within a single clinical framework. Recognizing the heterogeneity of interventions and the underlying evidence, this narrative review does not seek to provide a formal quantitative synthesis; rather, it addresses that gap by mapping the therapeutic landscape for spinal hemangioblastomas, including surgery, embolization, radiotherapy, and systemic pharmacotherapy, clarifying where each modality fits, the outcomes typically reported, key limitations, and identifying priorities for future investigation. This scope reflects the current state of the field and is intended to serve as a practical reference for clinicians managing these tumors across neurosurgery, neuro-oncology, and radiation oncology.

2. Materials and Methods

A comprehensive literature search was conducted in PubMed, EMBASE, and Scopus to find articles relevant to the multimodal management of spinal cord hemangioblastomas. The search was performed in September 2025 and covered publications since the database inception through August 2025. Search terms were used in combination via Boolean operators (AND, and OR) and included: "hemangioblastoma," "spinal cord hemangioblastoma," "spinal cord tumor," "von Hippel–Lindau," "VHL disease," "surgical resection," "gross total resection," "preoperative embolization," "stereotactic radiosurgery," "CyberKnife," "external beam radiotherapy," "belzutifan," "HIF-2α inhibitor," "bevacizumab," "anti-VEGF," and "multimodal management." Terms were applied as free text and, where available, as Medical Subject Headings (MeSH) in PubMed.

Inclusion criteria: (1) original research articles, case series, case reports, or systematic reviews reporting clinical outcomes, imaging characteristics, histopathological features, or management strategies for SCHb; (2) studies published in English; (3) studies reporting data on at least one patient with a pathologically confirmed or radiographically diagnosed spinal cord hemangioblastoma; and (4) studies addressing at least one of the review's primary domains: surgical management, preoperative embolization, radiotherapy, or systemic pharmacotherapy.

Exclusion criteria: (1) studies reporting exclusively on intracranial (cerebellar, brainstem, or supratentorial) hemangioblastomas without separately analyzable spinal cord data; (2) abstracts, editorials, letters, or conference proceedings without peer-reviewed full text available; (3) studies written in languages other than English without validated English translation; and (4) studies with no extractable clinical outcome data.

Study selection, data extraction, and synthesis were performed by two independent reviewers (F.C.-O. and J.Z.-G.), with discrepancies resolved by consensus. Given the predominantly retrospective and case series-level nature of available evidence, a formal meta-analysis was not performed; findings are reported as a narrative synthesis.

3. Results

3.1. Tumor Characteristics, Signs, and Symptoms

Hemangioblastomas are rare, benign (World Health Organization Grade I), and highly vascular tumors that can occur anywhere along the neural axis and can be sporadic or associated with VHL syndrome [10]. SCHb are generally sporadic (70–80% of cases) rather than associated with VHL, and they represent about 2% of the total primary spinal cord tumors, commonly arising from the thoracic or cervical cord and posterior to the dentate ligament [6,11]; they have been described as intradural intramedullary (most common), intramedullary + extramedullary, and intradural extramedullary (Figure 1) [12]. These lesions have a slight male predominance and can occur at any age, with those associated with VHL manifesting earlier [13,14].

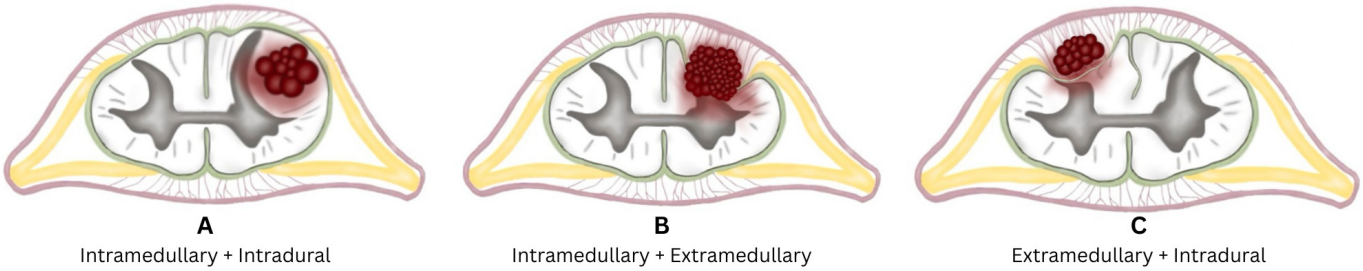

Figure 1. Schematic depicting the common relationship of SCHb with the spinal cord, dura mater, and epidural space. Illustration created by M.A.S.D. using Savage Interactive, Procreate (version 5.3).

Despite their benign nature, they are generally intraspinal lesions associated with high morbidity due to their associated peritumoral cysts and syrinx formation [6,8]. Symptoms include radiculopathy and myelopathy, and manifest as motor and sensory disturbances, gait ataxia, altered deep tendon reflexes, local pain, bowel or bladder dysfunction, and rarely, paralysis, all due to local mass effect and associated hemorrhage [15,16].

3.2. Diagnostic Workup

Diagnosis of SCHb should begin with a thorough review of medical, surgical, and family history to assess possible association with VHL disease [17]. When this lesion is suspected, imaging plays a pivotal role in diagnosing these tumors.

Magnetic resonance imaging is the preferred diagnostic method for CNS hemangioblastomas. Common radiographic features include a solid mural nodule accompanying a non-enhancing cyst, and perilesional syringomyelia secondary to fluid leaking from these lesions [13,18]. Characteristics of the tumor depend on the size and MRI sequence used; small lesions (<1 cm) appear isointense on T1-weighted imaging and hyperintense on T2, while large tumors have heterogeneous intensity on T2 (Figure 2A,B) and hypointense or mixed hypo-/isointense on T1 [11]. On gadolinium-enhanced T1-weighted MRI, SCHb demonstrate intense enhancement due to intense hypervascularity (Figure 2C,D) [19].

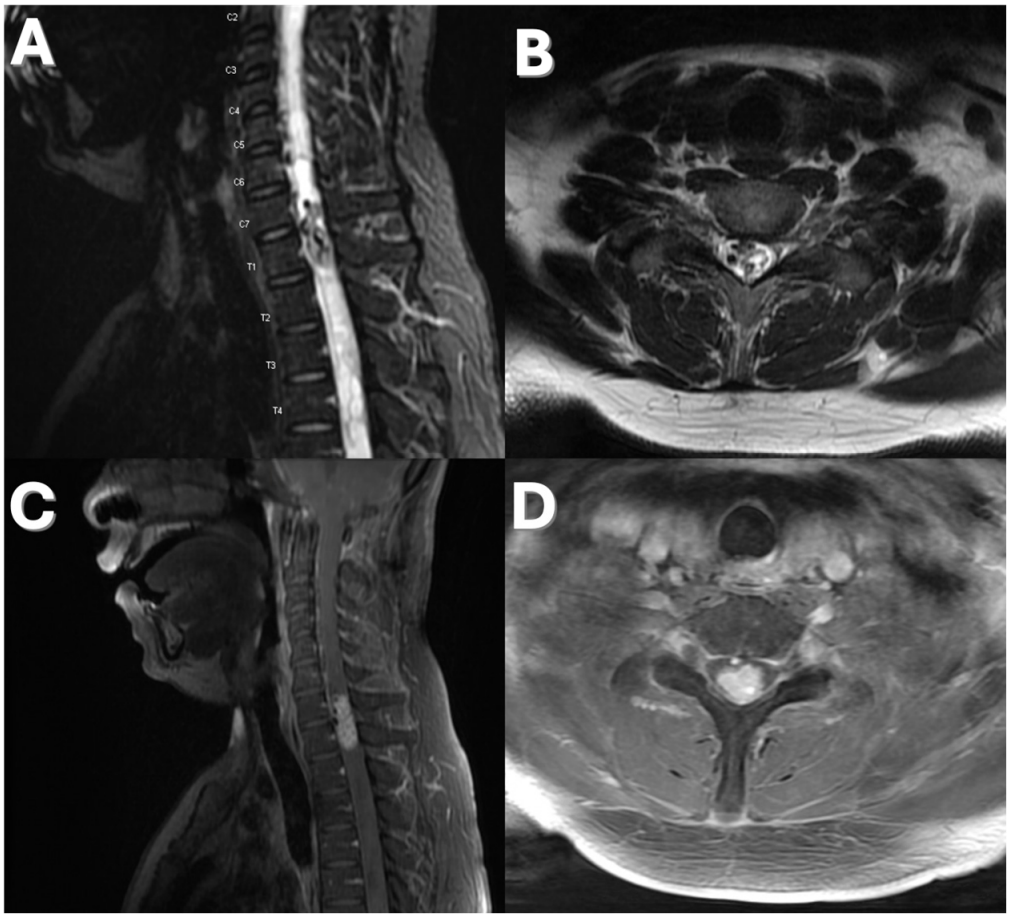

Figure 2. Case example of a large C7-T1 hemangioblastoma in sagittal (**A**) and axial (**B**) T2-weighted MRI sequences, and sagittal (**C**) and axial (**D**) post-contrast T1-weighted MRI. Written informed consent for publication was obtained from the patient. MRI = magnetic resonance imaging.

Conventional catheter-based angiography is recommended for large tumors and for those with an equivocal diagnosis. It is a technique that is both diagnostic and potentially therapeutic; it allows identification of feeding and draining vessels and allows for preoperative selective embolization if feasible and/or surgical planning for resection [14].

3.3. Histopathologic Features

Surgical specimens allow for definite diagnosis and help differentiate SCHb from morphologically similar lesions, particularly clear cell renal cell carcinoma. On light microscopy, hemangioblastomas display a characteristic biphasic composition of stromal cells (neoplastic component) in a rich network of thin-walled capillary or sinusoidal vascular channels lined by reactive endothelial cells [20,21]. Two recognized histological variants exist: the more common reticular variant, in which stromal cells are evenly distributed around and between the vascular channels, and the cellular variant, in which stromal cells aggregate into larger sheets or clusters that predominate over the vascular component [20].

Stromal cells are identified for being large, with indistinct cytoplasmic borders, vacuolated cytoplasm (lipid-rich), and mildly pleomorphic nuclei with small nucleoli [21]. The tumor in general is non-infiltrative with variable lobules defined by a reticulin network that separates the vascular and stromal components. Hemosiderin deposition is frequently seen and reflects chronic microhemorrhages [20].

Immunohistochemistry (IHC) is critical for diagnosis and differential diagnosis. Stromal cells in hemangioblastomas are positive for Inhibin A, Neuron Specific Enolase (NSE), Glial Fibrillary Acidic Protein (GFAP), S-100, CD56 (Neural Cell Adhesion Molecule

[NCAM]), vimentin, and carbonic anhydrase IX [22,23]. Importantly, stromal cells are negative for epithelial markers, including cytokeratin and epithelial membrane antigen (EMA). The endothelial component is positive for CD31, CD34, and Factor VIII-related antigen. This IHC profile is diagnostically decisive in distinguishing hemangioblastoma from metastatic clear cell renal cell carcinoma, which is PAX8-positive, EMA-positive, and inhibin-negative—a distinction with major therapeutic implications, particularly in patients with known VHL disease who are at elevated risk for both tumor types [22].

3.4. Surgical Management

The mainstay of treatment is surgical resection, and this decision is straightforward for patients with sporadic lesions, while for those with VHL, the decision is less clear, as multiple recurrences are common [24]. Despite these challenges, multiple authors have evaluated the degree of resection, reporting overall GTR rates greater than 80% [25].

Hemangioblastomas, in general, are known for having a thin capsule that can be ruptured during surgery, with an intraoperative hemorrhage risk in up to 40% of cases, particularly for intracranial lesions [26]. Preoperative embolization has therefore been proposed as an adjunct to reduce intraoperative blood loss and facilitate surgical dissection; however, its use in spinal cord hemangioblastomas remains selective and infrequent [7]. Proposed patient selection criteria for preoperative embolization include: (1) large tumor size (typically >2 cm or associated with significant vascularity on imaging), (2) clearly identifiable arterial feeders amenable to selective catheterization on diagnostic angiography, and (3) absence of radiculopial or radiculomedullary vessels supplying the lesion from the same pedicle, to minimize the risk of spinal cord ischemia [27]. Cases in which arterial feeders cannot be individually identified, where vessel tortuosity precludes safe catheter positioning, or where a single radiculomedullary artery (e.g., the artery of Adamkiewicz) supplies both the tumor and the cord, represent contraindications or high-risk scenarios for this approach [27].

Surgical resection alone has been demonstrated to be beneficial for patients with SCHb. Most articles include patients with and without VHL, and according to Na et al., no differences in outcomes have been appreciated between these two cohorts [6]. Siller et al. reported their outcomes in 24 patients without preoperative embolization: 17 sporadic cases and 7 associated with VHL. Patients with sporadic tumors achieved GTR after the first surgery; two of those with VHL required a second intervention [28]. These results are similar to those of Sun et al., as in their series of 14 patients with sporadic tumors and without preoperative embolization, confirmed GTR in all of them, with presumed recurrence in one case after 15 years [29].

Other case series report outcomes of patients with and without embolization prior to surgery. Mehta et al. included 108 patients with VHL, accounting for 156 interventions, from which only two had preoperative embolization. They did not report bleeding complications from the non-embolized patients and achieved a GTR rate > 95% with no recurrences at the end of their follow-up [30]. Butenschoen et al. reported outcomes of 60 patients (16 with VHL, 38 sporadic, and 6 with unknown status). They performed pre-operative embolization in six patients who had larger tumors. GTR was achieved in >90%, especially in those with associated syrinx. They note a recurrence rate of 7.8% among those with subtotal resection (p = 0.001) [27,31]. A similar conclusion was reported by Biondi et al. in a 4-patient series (3 sporadic, 1 associated with VHL), where the consulted surgeons concluded that preoperative embolization facilitates GTR [32].

Meanwhile, surgery can lead to neurologic stability or complete neurological recovery in the majority of symptomatic cases [24,31]. Reports of postoperative neurologic function decline, evidenced by new detectable or subjective deficits or worsening of those if

present at baseline, have been published. However, these deficits are transitory, with most patients recovering spontaneously in the following weeks, and a few of them requiring physical therapy [25,33].

Due to the dorsal anatomical basis of these lesions, most cases can be accomplished through a posterior open approach, requiring wide laminectomies and assistance of a microscope for tumor microdissection. There is a case report by Li et al., where the resection of a cervical hemangioblastoma was performed by a "mini open" approach by doing a 4 cm midline incision over the C3 lamina and accessing the spinal cord through a hemilaminectomy. The tumor was located beneath the dorsal root entry zone, and gross total en bloc resection was achieved. The authors reported regrowth of the C3 lamina and no recurrence after 1.5 years [34]. Regarding minimally invasive approaches, Kruger et al. reported the only known series to date of SCHb resection through a tubular retraction system in 18 patients. One of those patients had a tumor volume of 2457.2 mm^3 and prompted preoperative embolization. Most of their tumors were intramedullary but close to the surface of the cord (3/19) or were in a nerve root; two were deep and required myelotomy. GTR was confirmed with MRI scans 12 months after surgery [35].

3.5. Non-Surgical Management

3.5.1. Role of Radiotherapy

Data on external beam radiotherapy (EBRT) is scarce. Koh et al. published the hallmark study discussing this modality for the treatment of CNS hemangioblastomas; however, they do not separate outcomes for cranial and spinal hemangioblastomas. In their cohort of 18 patients (5 with VHL), eight of those had spinal cord tumors. In total, 17 of the patients had prior surgical interventions. Their overall local control rates at 5 and 10 years are 69% and 30%, respectively. No relevant toxicities were reported [36].

On the other hand, several series have demonstrated excellent local control and favorable safety profiles with SRS. One CyberKnife study included 46 spinal hemangioblastomas in 28 patients (14 sporadic and 14 with VHL), of which 20 had prior surgeries and 12 had prior radiotherapy. Radiation was delivered in one to five fractions for a total dose of 15–35 Gy. Their actuarial control rates were 96.1%, 92.3%, and 92.3% at 1, 3, and 5 years, respectively. Importantly, 81.2% of patients experienced symptomatic improvement, and no treatment-related complications were reported [37]. Similar findings were published by Moss et al., by treating 16 spinal cord hemangioblastomas (not specifying VHL status among these) with CyberKnife and a total dose of 20–25 Gy delivered in 1–5 fractions. They report a 5-year local control of 92%, with 15 lesions having decreased in size or remained stable, and one having progressed [16].

In another CyberKnife study, including 42 SCHb in 18 patients with (92.9%) and without VHL and prior radiotherapy or surgery, Yoo et al. found a local control rate of 97.4% at 5 years. The radiation was delivered in 1–5 fractions and achieved a total dose of 18–27 Gy. They report a higher local control rate for SCHb versus their cranial counterparts (87.8% at 5 years, $p < 0.05$). Clinical improvement was seen in 52.5% of these patients, and one event of radiation-induced edema was reported, which resolved with steroid treatment [38].

Specifically for VHL-related SCHb, Cvek et al. published their outcomes in 5 patients totaling 18 tumors, treated with a CyberKnife system in three or five fractions for a total dose of 24–26 Gy. None of their patients had received prior radiotherapy. Indications for radiosurgery included tumor progression (worsening symptoms or enlargement) regardless of prior surgery, patient refusal of surgical intervention, or lesions deemed inoperable by a neurosurgeon. They reported tumor volume regression and non-progression of baseline

symptoms but failed to demonstrate symptom improvement. One case of myelopathy occurred two years after treatment [39].

Regarding spinal cord toxicity, Daly et al. published a study focusing on cord tolerance to radiation. They treated 27 SCHb in 19 patients with stereotactic radiosurgery, delivering 18–30 Gy in a single fraction or 18–25 Gy in two or three fractions. They reported an actuarial local control rate of 86%. Acute toxicity was rare; one patient developed vomiting, and one patient with VHL, who had prior surgery and radiotherapy, developed footdrop after treatment of a T10 hemangioblastoma. Chronic toxicity was also rare, with two patients developing sensory deficits > 18 months after treatment. Anatomic association was only established for patients with foot drop, as MRI changes were evident. For the patients with sensory deficit, no lesion was observed [40].

3.5.2. Systemic Therapies

To understand the molecular targets for pharmacotherapy, it is necessary to briefly review the pathogenesis of the disease in the context of VHL disease. Mutations in the tumor suppression gene VHL lead to aberrant or underexpression of the product pVHL, and this deficiency leads to unregulated survival of HIF-2α and, as a consequence, increased VEGF, favoring cysts and vascular tumors formation (Figure 3) [41]. This pathogenesis led to the off label use of anti-VEGF monoclonal antibodies (bevacizumab) and multi-target VEGF receptor tyrosine kinase inhibitors (TKI) such as pazopanib, sunitinib, and anlotinib (Table 1).

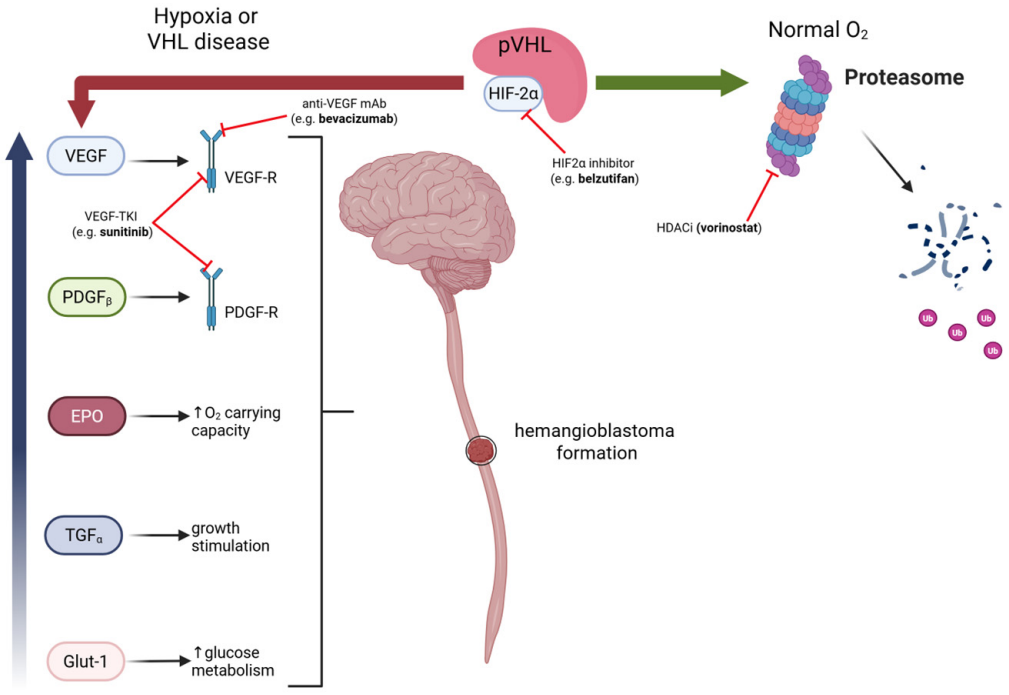

Figure 3. Graphical demonstration of the pathogenesis of SCHb and depicting the chemotherapy targets. Abbreviations: Glut-1 = glucose transporter 1; HDACi = histone deacetylase inhibitor; HIF-2α = hypoxia inducible factor-2 alpha; EPO = erythropoietin; mAb = monoclonal antibody; PDGF = platelet-derived growth factor; pVHL = von Hippel-Lindau protein; TGF = transforming growth factor; TK = tyrosine kinase; VEGF = vascular endothelial growth factor; VHL = von Hippel-Lindau. Created in Biorender. Francisco Alfredo Call-Orellana. (2025) https://app.biorender.com/illustrations/697246fd90aaf0c8926dca32?slideId=b09944c5-b761-427b-8b73-f38f1c139517 (accessed on 30 January 2026) and the license was provided by UT MD Anderson.

Table 1. Summary of systemic therapy used for SCHb.

Agent (Class)	Mechanism of Action	Evidence Level	Indication
Bevacizumab (anti-VEGF monoclonal antibody) [42,43]	VEGF neutralization with decreased angiogenesis	Case reports	Unresectable, recurrent, or symptomatic CNS HBs in VHL patients when surgery/radiation is not feasible
Pazopanib, Sunitinib, Anlotinib, Sorafenib (VEGF-TKIs) [44–47]	Multi-target inhibition of VEGFR with decreased angiogenesis	Case reports and early trials	VHL patients with multiple progressive CNS lesions or systemic disease; salvage treatment; surgery or radiation not possible
Belzutifan (HIF-2α inhibitor) [9,47,48]	Direct inhibition of HIF-2α leading to decreased VEGF and therefore decreased angiogenesis	Phase II trials and FDA approval	Adults with VHL requiring therapy for renal cell carcinoma, pancreatic neuroendocrine tumors, and CNS hemangioblastomas and who do not require emergent surgery.
Vorinostat (HDACi) [49]	Blocks proteasome degradation of pVHL, promoting clearance of HIF and other transcription factors.	Pilot study (NCT02108002)	Adults with known germline missense *VHL* gene mutation.

Abbreviations: CNS = central nervous system; FDA = Food and Drug Administration; HDACi = histone deacetylase inhibitor; HIF = hypox-ia-inducible factor; pVHL = von Hippel-Lindau protein; VEGF = vascular endothelial growth factor; VEGFR = VEGF-receptor.

Bevacizumab use was reported by Omar et al. and Mak et al., where, in their case reports, the drug led to tumor regression and symptomatic improvement in a cervical SCHb refractory to conventional treatment [42,43].

Regarding evidence for TKI, the use of pazopanib was reported by Kim et al., in a case report where a patient with cerebellar hemangioblastoma refractory to conventional treatment had clinical improvement without toxicity [44]. Also, an early phase II trial by Jonasch et al. assessed the use of pazopanib in patients with VHL; despite having a short follow-up period, they argued that some beneficial effect could be seen. However, they also highlight the risk of bleeding and toxicity when using this agent [45]. Anlotinib was first reported to be successful in causing radiographic regression in multiple lumbar and sacral SCHb, as stated by Jin et al. [46]. A retrospective study done by Ma et al. evaluating TKI for VHL lesions, including CNS hemangioblastomas, reported stability while using these drugs with an acceptable spectrum of side effects [47].

Another investigational therapy is the oral histone deacetylase inhibitor (HDACi) vorinostat, currently approved for cutaneous T-cell lymphoma. Prior reports suggested that proteostasis modulation could refunctionalize pVHL in patients with missense mutations, limiting tumorigenesis and growth [50,51]. A clinical trial by Chittiboina et al. provided evidence to support its use in patients with missense mutations in the VHL gene [49].

Current guideline-level therapy for VHL-associated hemangioblastomas includes belzutifan, the first orally bioavailable, selective HIF-2α inhibitor that directly suppresses the upstream transcriptional driver (HIF-2α) of VHL-associated tumorigenesis. The FDA approved belzutifan in 2021 for adults with VHL who require systemic therapy for associated renal cell carcinoma, CNS hemangioblastomas, or pancreatic neuroendocrine tumors, and do not require immediate surgery [9,48,52]. Clinical evidence for its use in CNS hemangioblastomas derives primarily from the LITESPARK-004 trial, a Phase 2, single-arm, multicenter study that enrolled 61 patients, of whom 50 had VHL-associated CNS hemangioblastomas. The objective response rate among those patients with solid

and cystic components in the tumor was 44% (95% CI = 30–59%, n = 22/50), and for those with solid lesions only 76% (95% CI = 55–91%, n = 19/25). Time to response was 5.4 (2.7–16.5) months for the first group and 3.1 (2.6–8.5) months for the second. For those with solid and cystic components, 72.2% (95% CI = 39.5–89.1) remained in response for at least 36 months, while 75% (95% CI = 12.8–96.1) remained in response for the same period. No median progression-free survival was reported by the authors. The safety profile was characterized by mostly Grades 1 and 2 adverse events, commonly anemia in 45 patients (90%), fatigue in 35 (70%), dizziness in 25 (50%), headache in 20 (40%), nausea in 19 (38%), and dyspnea in 15 (30%). Adverse events grade 4 (retinal vein occlusion and embolism) and 5 (suicide and fentanyl overdose) were deemed unrelated to therapy. These data support belzutifan as a durable systemic option for VHL-associated CNS hemangioblastomas not requiring emergent surgical intervention [9].

4. Discussion

Spinal cord hemangioblastomas (SCHb) represent a rare but clinically significant subset of primary spinal cord tumors. Although histologically benign, their intramedullary location and strong vascularity confer a disproportionate morbidity when compared to other low-grade lesions. The results of our review highlight the importance of a multimodal treatment paradigm that extends beyond surgery, incorporating endovascular, radiosurgical, and systemic approaches.

Surgical resection is reasonable for symptomatic patients, and it can achieve GTR in up to 80% of cases [24,25,29]. Despite having similar outcomes between sporadic and VHL-associated tumors, it is important to consider three things when planning surgical resection: recurrence is more frequent in the context of VHL [28]; sporadic disease typically presents as an isolated lesion, while VHL can manifest with multiple concurrent tumors [36]; and STR can be associated with higher rates of recurrence [30]. The presence of a syrinx can be associated with a more favorable plane of dissection, increasing the likelihood of GTR, and these tumors can be ideal candidates for MIS, together with those located below the dorsal root entry zone [27,35]. Nonetheless, resection is technically demanding due to the tumor's fragile capsule and hypervascularity, with intraoperative bleeding reported in up to 40% of cases [26].

Preoperative embolization has been proposed to mitigate intraoperative bleeding risk. Available series suggest that embolization may facilitate surgical dissection and reduce intraoperative blood loss, particularly for large tumors, though the supporting data are derived from small, heterogeneous series rather than controlled trials. Butenschoen et al. performed embolization in six patients with larger tumors and achieved GTR in >90% of the overall cohort [27,31]. Biondi et al., in a 4-patient series, similarly concluded that preoperative embolization facilitated GTR [32]. Complication rates specific to embolization in spinal hemangioblastomas are difficult to isolate from the broader literature, given the small number of embolized cases across all published series; however, the most serious reported complication is spinal cord ischemia secondary to inadvertent occlusion of radiculomedullary feeders [27]. Based on available evidence, preoperative embolization should be reserved for large, anatomically complex tumors in which discrete arterial feeders can be identified on diagnostic angiography and should be performed by experienced surgeons at high-volume centers.

Radiotherapy represents a valuable adjunct for unresectable, recurrent, or multifocal disease. Conventional EBRT has shown modest control rates—approximately 69% at 5 years—but with declining efficacy over longer follow-up [36]; however, it is difficult to draw conclusions from one paper evaluating the effects of this modality. One of the reasons for the scarcity of data on EBRT may be due to the amount of normal tissue irradiated

with this modality, worsening long-term neurological symptoms that are intrinsic to VHL disease in this population [16].

Therefore, SRS has emerged as the preferred radiation modality for SCHb, supported by several series demonstrating 5-year local control rates consistently exceeding 80% with minimal toxicity. In the largest available spine-specific CyberKnife series, Pan et al. reported actuarial control rates of 96.1%, 92.3%, and 92.3% at 1, 3, and 5 years, respectively, with improved symptoms in 81.2% of tumors, and no complications were observed [37]. Moss et al. reported 82% 5-year local control in 16 tumors [16]. Yoo et al. further demonstrated a 5-year local control rate of 97.4% among the SCHb (notably higher than cranial lesions [87.8%, $p < 0.05$]) and reported only one case (of 42 spinal cord lesions) of radiation-induced edema, which resolved with corticosteroids [38]. One study focusing on cord tolerance, conducted by Daly et al., observed acute toxicity and chronic sensory deficits in 2/27 SCHb when treated with 18–30 Gy in 1–3 fractions [40]. Collectively, this data from series having follow-up times of 2–5 years support the integration of radiosurgery into the therapeutic algorithm, particularly for surgically inaccessible, recurrent, or multifocal lesions. Unanswered questions include the optimal fractionation scheme (single-fraction versus hypofractionated), appropriate dose constraints for the spinal cord in retreatment settings, and whether upfront SRS can serve as a primary treatment alternative to surgery in carefully selected treatment-naïve patients.

Systemic therapy is an evolving frontier. VEGF-targeted agents have anecdotally demonstrated to have some symptomatic and radiological benefit; however, strong recommendations cannot be drawn from case reports, case series, or trials evaluating their benefit as a secondary outcome [42,44,46,47]. The most significant advancement in pharmacotherapy has been the approval of belzutifan for VHL-associated CNS hemangioblastomas. In the trial published by Iliopoulos et al., belzutifan yielded an objective response rate of 44% (n = 22/50) among those with lesions with solid and cystic components and 76% (n = 19/25) among those with solid lesions only. They also reported durable responses (above 70% in-response for those with CNS hemangioblastomas with solid only or solid and cystic components for more than 3 years) and manageable toxicity (mostly grades 1 and 2 adverse events) [9,52]. Although these agents remain investigational for sporadic SCHb, they open research doors for systemic management in multiple simultaneous lesions and where surgery or radiosurgery is not feasible.

5. Limitations

The evidence base for the management of spinal cord hemangioblastomas is subject to several important methodological limitations that must be considered when interpreting the findings of this review.

5.1. Retrospective and Non-Comparative Study Designs

Most available studies are retrospective case series or case reports, lacking control groups and subject to inherent selection bias. Treatment decisions are made at the clinician/author's and institutional level based on factors not always reported in publications (e.g., patient preference, comorbidity, VHL mutational status), precluding meaningful comparisons across modalities. Future prospective registries enrolling consecutive patients at high-volume centers could substantially reduce this bias.

5.2. Heterogeneous Patient Populations

Many series combine sporadic and VHL-associated SCHb, as well as spinal and intracranial hemangioblastomas, without providing separately analyzable subgroup data. This limits the ability to draw modality-specific conclusions for SCHb specifically, and

for sporadic versus VHL disease independently. Authors of future studies should stratify outcomes by tumor location (spinal vs. intracranial), etiology (sporadic vs. VHL-associated), and number of prior interventions. The development of multi-institutional or international registries for VHL disease would facilitate this stratification.

5.3. Small Cohort Sizes and Rare Disease

The rarity of SCHb fundamentally limits the power of any single-center study to detect differences between treatment arms or to establish robust predictors of outcome. Collaborative, multi-center prospective study designs represent the most feasible path toward higher-quality evidence.

5.4. Outcome Heterogeneity

Neurological outcome measures, radiographic response definitions, and recurrence criteria are inconsistently defined across studies, precluding direct pooled analysis. Adoption of standardized neurological outcome and consensus radiographic response criteria would improve comparability across future studies.

6. Conclusions

For spinal hemangioblastomas, microsurgical resection remains the cornerstone for function-threatening or progressive lesions, with angiographic adjuncts improving safety, as they allow for better surgical planning and the decision to embolize prior to surgery. Preoperative embolization can be useful and should be done by experienced physicians due to the potential risk of cord ischemia. Radiosurgery, particularly stereotactic modality, offers durable control with relatively low toxicity for lesions deemed inoperable or for recurrent targets. Belzutifan has introduced a systemic option for VHL-associated CNS HBs not requiring immediate surgery, while bevacizumab/TKIs remain case-based options for highly selected scenarios. Data on sporadic SCHb remains limited.

Future research directions warrant prospective investigation. First, the role of upfront SRS as a primary alternative to surgery for small, symptomatic SCHb remains undefined and would benefit from multicenter, registry-based comparative studies. Second, trials evaluating the sequencing of belzutifan and other systemic agents with surgery and radiotherapy in SCHb are needed to optimize multimodal treatment algorithms. Third, the genomic characterization of sporadic SCHb remains a fundamental gap; tumor banking and biomarker studies within surgical series could identify actionable targets and expand systemic options beyond VHL-associated disease.

Author Contributions: Conceptualization, F.A.C.-O., J.P.Z.-G., M.A.S., M.Z.-G., E.R.-F. and A.B.; methodology, F.A.C.-O., J.P.Z.-G., E.R.-F. and A.B.; formal analysis, F.A.C.-O.; investigation, F.A.C.-O., J.P.Z.-G., M.A.S. and M.Z.-G.; data curation, F.A.C.-O., J.P.Z.-G. and E.R.-F.; writing—original draft preparation, F.A.C.-O.; writing—review and editing, J.P.Z.-G., M.A.S., M.Z.-G., E.R.-F. and A.B.; visualization, M.A.S. and M.Z.-G.; supervision, A.B.; project administration, A.B. All authors have read and agreed to the published version of the manuscript.

Funding: This research received no external funding.

Institutional Review Board Statement: Not applicable.

Informed Consent Statement: Written informed consent has been obtained from the patient to publish this paper.

Data Availability Statement: No new data were created or analyzed in this study.

Conflicts of Interest: The authors declare no conflicts of interest.

Abbreviations

The following abbreviations are used in this manuscript:

CNS	Central Nervous System
EBRT	External Beam Radiotherapy
FDA	Food and Drug Administration
GFAP	Glial Fibrillary Acidic Protein
GTR	Gross Total Resection
HDACi	Histone Deacetylase Inhibitor
HIF-2α	Hypoxia-Inducible Factor-2α
MIS	Minimally Invasive Surgery
MRI	Magnetic Resonance Imaging
NCAM	Neural Cell Adhesion Molecule
NSE	Neuron Specific Enolase
pVHL	von Hippel–Lindau Protein
RCC	Renal Cell Carcinoma
SCHb	Spinal Cord Hemangioblastoma
SRS	Stereotactic Radiosurgery
STR	Subtotal Resection
TKI	Tyrosine Kinase Inhibitor
VEGF	Vascular Endothelial Growth Factor
VEGFR	Vascular Endothelial Growth Factor Receptor
VHL	von Hippel–Lindau

References

1. Khan, M.M.; Hall, W.A.; Belkhair, S. Hemangioblastoma. In *StatPearls*; StatPearls Publishing: Treasure Island, FL, USA, 2025.
2. Westwick, H.J.; Giguère, J.-F.; Shamji, M.F. Incidence and Prognosis of Spinal Hemangioblastoma: A Surveillance Epidemiology and End Results Study. *Neuroepidemiology* **2015**, *46*, 14–23. [CrossRef]
3. Kim, T.Y.; Yoon, D.H.; Shin, H.C.; Kim, K.N.; Yi, S.; Oh, J.K.; Ha, Y. Spinal Cord Hemangioblastomas in von Hippel-Lindau Disease: Management of Asymptomatic and Symptomatic Tumors. *Yonsei Med. J.* **2012**, *53*, 1073–1080. [CrossRef] [PubMed]
4. Kanno, H.; Yamamoto, I.; Nishikawa, R.; Matsutani, M.; Wakabayashi, T.; Yoshida, J.; Shitara, N.; Yamasaki, I.; Shuin, T. Spinal cord hemangioblastomas in von Hippel–Lindau disease. *Spinal Cord* **2009**, *47*, 447–452. [CrossRef] [PubMed]
5. Yoda, R.A.; Cimino, P.J. Neuropathologic features of central nervous system hemangioblastoma. *J. Pathol. Transl. Med.* **2022**, *56*, 115–125. [CrossRef]
6. Na, J.H.; Kim, H.S.; Eoh, W.; Kim, J.H.; Kim, J.S.; Kim, E.-S. Spinal cord hemangioblastoma: Diagnosis and clinical outcome after surgical treatment. *J. Korean Neurosurg. Soc.* **2007**, *42*, 436–440. [CrossRef]
7. Ampie, L.; Choy, W.; Khanna, R.; Smith, Z.A.; Dahdaleh, N.S.; Parsa, A.T.; Bloch, O. Role of preoperative embolization for intradural spinal hemangioblastomas. *J. Clin. Neurosci.* **2016**, *24*, 83–87. [CrossRef]
8. Kreatsoulas, D.C.; Lonser, R.R. Spinal cord hemangioblastomas in von Hippel-Lindau disease. *Neurooncol. Adv.* **2024**, *6*, iii66–iii72. [CrossRef] [PubMed]
9. Iliopoulos, O.; Iversen, A.B.; Narayan, V.; Maughan, B.L.; Beckermann, K.E.; Oudard, S.; Else, T.; Maranchie, J.K.; Goldberg, C.M.; Fu, W.; et al. Belzutifan for patients with von Hippel-Lindau disease-associated CNS haemangioblastomas (LITESPARK-004): A multicentre, single-arm, phase 2 study. *Lancet Oncol.* **2024**, *25*, 1325–1336. [CrossRef]
10. Conway, J.E.; Chou, D.; Clatterbuck, R.E.; Brem, H.; Long, D.M.; Rigamonti, D. Hemangioblastomas of the Central Nervous System in von Hippel-Lindau Syndrome and Sporadic Disease. *Neurosurgery* **2001**, *48*, 55.
11. Zhang, Z.; Low, S.W.; Sun, I.; Lim, S.L.; Tan, C.L.; Goh, C.P.; Zhang, Z.; Low, S.W.; Sun, I.; Lim, S.L.; et al. Spinal Hemangioblastoma: The Role of Imaging Characteristics in Preoperative Diagnosis and Surgical Planning. *Cureus* **2025**, *17*, e82740. [CrossRef]
12. Imagama, S.; Ito, Z.; Wakao, N.; Sakai, Y.; Kato, F.; Yukawa, Y.; Sato, K.; Ando, K.; Hirano, K.; Tauchi, R.; et al. Differentiation of localization of spinal hemangioblastomas based on imaging and pathological findings. *Eur. Spine J.* **2011**, *20*, 1377–1384. [CrossRef]
13. Ho, V.B.; Smirniotopoulos, J.G.; Murphy, F.M.; Rushing, E.J. Radiologic-pathologic correlation: Hemangioblastoma. *AJNR Am. J. Neuroradiol.* **1992**, *13*, 1343–1352.
14. Roonprapunt, C.; Silvera, V.M.; Setton, A.; Freed, D.; Epstein, F.J.; Jallo, G.I. Surgical Management of Isolated Hemangioblastomas of the Spinal Cord. *Neurosurgery* **2001**, *49*, 321.

15. Ganeshan, D.; Menias, C.O.; Pickhardt, P.J.; Sandrasegaran, K.; Lubner, M.G.; Ramalingam, P.; Bhalla, S. Tumors in von Hippel-Lindau Syndrome: From Head to Toe-Comprehensive State-of-the-Art Review. *Radiographics* **2018**, *38*, 849–866. [CrossRef]
16. Moss, J.M.; Choi, C.Y.H.; Adler, J.R.J.; Soltys, S.G.; Gibbs, I.C.; Chang, S.D. Stereotactic radiosurgical treatment of cranial and spinal hemangioblastomas. *Neurosurgery* **2009**, *65*, 79. [CrossRef]
17. Binderup, M.L.M.; Smerdel, M.; Borgwadt, L.; Nielsen, S.S.B.; Madsen, M.G.; Møller, H.U.; Kiilgaard, J.F.; Friis-Hansen, L.; Harbud, V.; Cortnum, S.; et al. von Hippel-Lindau disease: Updated guideline for diagnosis and surveillance. *Eur. J. Med. Genet.* **2022**, *65*, 104538. [CrossRef]
18. Shah, L.M.; Salzman, K.L. Conventional and Advanced Imaging of Spinal Cord Tumors. *Neuroimaging Clin. N. Am.* **2023**, *33*, 389–406. [CrossRef]
19. Baker, K.B.; Moran, C.J.; Wippold, F.J.; Smirniotopoulos, J.G.; Rodriguez, F.J.; Meyers, S.P.; Siegal, T.L. MR Imaging of Spinal Hemangioblastoma. *Am. J. Roentgenol.* **2000**, *174*, 377–382. [CrossRef] [PubMed]
20. Vortmeyer, A.O.; Falke, E.A.; Gläsker, S.; Li, J.; Oldfield, E.H. Nervous system involvement in von Hippel–Lindau disease: Pathology and mechanisms. *Acta Neuropathol.* **2013**, *125*, 333–350. [CrossRef] [PubMed]
21. Hasselblatt, M.; Jeibmann, A.; Gerß, J.; Behrens, C.; Rama, B.; Wassmann, H.; Paulus, W. Cellular and reticular variants of haemangioblastoma revisited: A clinicopathologic study of 88 cases. *Neuropathol. Appl. Neurobiol.* **2005**, *31*, 618–622. [CrossRef] [PubMed]
22. Carney, E.M.; Banerjee, P.; Ellis, C.L.; Albadine, R.; Sharma, R.; Chaux, A.M.; Burger, P.C.; Netto, G.J. PAX2(−)/PAX8(−)/Inhibin A(+) Immunoprofile in Hemangioblastoma: A Helpful Combination in the Differential Diagnosis with Metastatic Clear Cell Renal CellCarcinoma to the Central Nervous System. *Am. J. Surg. Pathol.* **2011**, *35*, 262. [CrossRef] [PubMed]
23. Polydorides, A.D.; Rosenblum, M.K.; Edgar, M.A. Metastatic renal cell carcinoma to hemangioblastoma in von Hippel-Lindau disease. *Arch. Pathol. Lab. Med.* **2007**, *131*, 641–645. [CrossRef]
24. Park, C.H.; Lee, C.-H.; Hyun, S.J.; Jahng, T.-A.; Kim, H.-J.; Kim, K.-J. Surgical outcome of spinal cord hemangioblastomas. *J. Korean Neurosurg. Soc.* **2012**, *52*, 221–227. [CrossRef] [PubMed]
25. Alsereihi, M.; Creatura, D.; D'Onofrio, G.F.; Vandenbulcke, A.; Messerer, M.; Penet, N.; Lozano-Madrigal, R.; Delaidelli, A.; Pessina, F.; Capo, G.; et al. Neurological Outcome of Spinal Hemangioblastomas: An International Observational Multicenter Study About 35 Surgical Cases. *Cancers* **2025**, *17*, 1428. [CrossRef]
26. Le Reste, P.-J.; Henaux, P.-L.; Morandi, X.; Carsin-Nicol, B.; Brassier, G.; Riffaud, L. Sporadic intracranial haemangioblastomas: Surgical outcome in a single institution series. *Acta Neurochir.* **2013**, *155*, 1003–1009; discussion 1009. [CrossRef] [PubMed]
27. Butenschoen, V.M.; Schwendner, M.; Hubertus, V.; Onken, J.; Koegl, N.; Mohme, T.; Maurer, S.; Boeckh-Behrens, T.; Eicker, S.O.; Thomé, C.; et al. Preoperative angiographic considerations and neurological outcome after surgical treatment of intradural spinal hemangioblastoma: A multicenter retrospective case series. *J. Neurooncol.* **2023**, *161*, 107–115. [CrossRef]
28. Siller, S.; Szelényi, A.; Herlitz, L.; Tonn, J.C.; Zausinger, S. Spinal cord hemangioblastomas: Significance of intraoperative neurophysiological monitoring for resection and long-term outcome. *J. Neurosurg. Spine* **2017**, *26*, 483–493. [CrossRef]
29. Sun, H.İ.; Özduman, K.; Usseli, M.İ.; Özgen, S.; Pamir, M.N. Sporadic spinal hemangioblastomas can be effectively treated by microsurgery alone. *World Neurosurg.* **2014**, *82*, 836–847. [CrossRef]
30. Mehta, G.U.; Asthagiri, A.R.; Bakhtian, K.D.; Auh, S.; Oldfield, E.H.; Lonser, R.R. Functional outcome after resection of spinal cord hemangioblastomas associated with von Hippel-Lindau disease. *J. Neurosurg. Spine* **2010**, *12*, 233–242. [CrossRef]
31. Lee, D.K.; Choe, W.J.; Chung, C.K.; Kim, H.J. Spinal Cord Hemangioblastoma: Surgical Strategy and Clinical Outcome. *J. Neurooncol.* **2003**, *61*, 27–34. [CrossRef]
32. Biondi, A.; Ricciardi, G.K.; Faillot, T.; Capelle, L.; Effenterre, R.V.; Chiras, J. Hemangioblastomas of the Lower Spinal Region: Report of Four Cases with Preoperative Embolization and Review of the Literature. *Am. J. Neuroradiol.* **2005**, *26*, 936–945. [PubMed]
33. Pietilä, T.A.; Stendel, R.; Schilling, A.; Krznaric, I.; Brock, M. Surgical Treatment of Spinal Hemangioblastomas. *Acta Neurochir.* **2000**, *142*, 879–886. [CrossRef]
34. Li, J.; Jiang, X.-H.; Chen, A.-Q.; Ying, G.-Y.; Shen, F.; Zhu, Y.-J. Surgical management of a cervical intramedullary hemangioblastoma presenting with intracystic hemorrhage by hemi-semi-laminectomy via a posterior approach. *J. Int. Med. Res.* **2019**, *47*, 3458–3464. [CrossRef] [PubMed]
35. Krüger, M.T.; Steiert, C.; Gläsker, S.; Klingler, J.-H. Minimally invasive resection of spinal hemangioblastoma: Feasibility and clinical results in a series of 18 patients. *J. Neurosurg. Spine* **2019**, *31*, 880–889. [CrossRef]
36. Koh, E.-S.; Nichol, A.; Millar, B.-A.; Ménard, C.; Pond, G.; Laperriere, N.J. Role of fractionated external beam radiotherapy in hemangioblastoma of the central nervous system. *Int. J. Radiat. Oncol. Biol. Phys.* **2007**, *69*, 1521–1526. [CrossRef]
37. Pan, J.; Ho, A.L.; D'Astous, M.; Sussman, E.S.; Thompson, P.A.; Tayag, A.T.; Pangilinan, L.; Soltys, S.G.; Gibbs, I.C.; Chang, S.D. Image-guided stereotactic radiosurgery for treatment of spinal hemangioblastoma. *Neurosurg. Focus* **2017**, *42*, E12. [CrossRef] [PubMed]

38. Yoo, K.H.; Park, D.J.; Marianayagam, N.J.; Gu, X.; Pollom, E.L.; Soltys, S.G.; Chang, S.D.; Meola, A. Stereotactic Radiosurgery for Cranial and Spinal Hemangioblastomas: A Single-Institution Retrospective Series. *Neurosurgery* **2024**, *94*, 630–642. [CrossRef]
39. Cvek, J.; Knybel, L.; Reguli, S.; Lipina, R.; Hanzlikova, P.; Silhan, P.; Resova, K.; Blazek, T.; Palicka, M.; Feltl, D. Stereotactic radiotherapy for spinal hemangioblastoma—Disease control and volume analysis in long-term follow up. *Rep. Pract. Oncol. Radiother.* **2022**, *27*, 134–141. [CrossRef]
40. Daly, M.E.; Choi, C.Y.H.; Gibbs, I.C.; Adler, J.R.; Chang, S.D.; Lieberson, R.E.; Soltys, S.G. Tolerance of the spinal cord to stereotactic radiosurgery: Insights from hemangioblastomas. *Int. J. Radiat. Oncol. Biol. Phys.* **2011**, *80*, 213–220. [CrossRef]
41. Narayan, V.; Jonasch, E. Systemic Therapy Development in Von Hippel–Lindau Disease: An Outsized Contribution from an Orphan Disease. *Cancers* **2022**, *14*, 5313. [CrossRef]
42. Omar, A.I. Bevacizumab for the treatment of surgically unresectable cervical cord hemangioblastoma: A case report. *J. Med. Case Rep.* **2012**, *6*, 238. [CrossRef]
43. Mak, G.; Algird, A.; Greenspoon, J.; Provias, J.; Hirte, H. Cervicomedullary hemangioblastoma treated with bevacizumab. *Neuro-Oncol. Adv.* **2020**, *2*, vdaa076. [CrossRef]
44. Kim, B.Y.S.; Jonasch, E.; McCutcheon, I.E. Pazopanib therapy for cerebellar hemangioblastomas in von Hippel-Lindau disease: Case report. *Target. Oncol.* **2012**, *7*, 145–149. [CrossRef]
45. Jonasch, E.; McCutcheon, I.E.; Gombos, D.S.; Ahrar, K.; Perrier, N.D.; Liu, D.; Robichaux, C.C.; Villarreal, M.F.; Weldon, J.A.; Woodson, A.H.; et al. Pazopanib in patients with von Hippel-Lindau disease: A single-arm, single-centre, phase 2 trial. *Lancet Oncol.* **2018**, *19*, 1351–1359. [CrossRef]
46. Jin, N.; Sun, C.; Hua, Y.; Wu, X.; Li, W.; Yin, Y. Anlotinib for the Treatment of Multiple Recurrent Lumbar and Sacral Cord Hemangioblastomas: A Case Report. *Front. Oncol.* **2022**, *12*, 859157. [CrossRef]
47. Ma, K.; Hong, B.; Zhou, J.; Gong, Y.; Wang, J.; Liu, S.; Peng, X.; Zhou, B.; Zhang, J.; Xie, H.; et al. The Efficacy and Safety of Tyrosine Kinase Inhibitors for Von Hippel–Lindau Disease: A Retrospective Study of 32 Patients. *Front. Oncol.* **2019**, *9*, 1122. [CrossRef] [PubMed]
48. Center for Drug Evaluation and Research (CDER), U.S. Food and Drug Administration (FDA). Approves Belzutifan for Cancers Associated with Von Hippel-Lindau Disease. 2024. Available online: https://www.fda.gov/drugs/resources-information-approved-drugs/fda-approves-belzutifan-cancers-associated-von-hippel-lindau-disease (accessed on 21 January 2026).
49. Chittiboina, P.; Mandal, D.; Bugarini, A.; Asuzu, D.T.; Mullaney, D.; Mastorakos, P.; Stoica, S.; Alvarez, R.; Scott, G.; Maric, D.; et al. Proteostasis Modulation in Germline Missense von Hippel Lindau Disease. *Clin. Cancer Res.* **2023**, *29*, 2199–2209. [CrossRef] [PubMed]
50. Ding, Z.; German, P.; Bai, S.; Reddy, A.S.; Liu, X.-D.; Sun, M.; Zhou, L.; Chen, X.; Zhao, X.; Wu, C.; et al. Genetic and Pharmacological Strategies to Refunctionalize the von Hippel Lindau R167Q Mutant Protein. *Cancer Res.* **2014**, *74*, 3127–3136. [CrossRef]
51. Yang, C.; Huntoon, K.; Ksendzovsky, A.; Zhuang, Z.; Lonser, R.R. Proteostasis modulators prolong missense VHL protein activity and halt tumor progression. *Cell Rep.* **2013**, *3*, 52–59. [CrossRef] [PubMed]
52. Zhang, Y.; Nguyen, C.C.; Zhang, N.T.; Fink, N.S.; John, J.D.; Venkatesh, O.G.; Roe, J.D.; Hoffman, S.C.; Lesniak, M.S.; Wolinsky, J.-P.; et al. Neurological applications of belzutifan in von Hippel-Lindau disease. *Neuro-Oncol.* **2022**, *25*, 827–838. [CrossRef]

Disclaimer/Publisher's Note: The statements, opinions and data contained in all publications are solely those of the individual author(s) and contributor(s) and not of MDPI and/or the editor(s). MDPI and/or the editor(s) disclaim responsibility for any injury to people or property resulting from any ideas, methods, instructions or products referred to in the content.