pets

MDPI

Article

Comparative Secondary-Intention Wound Healing in Dogs and Cats: Species-Specific and Treatment-Related Differences in a Standardized Experimental Model

Theodora Zacharopoulou [1], Pagona G. Gouletsou [2], Vassilis Skampardonis [3], Stefanos G. Georgiou [1], Dimitrios Doukas [4], Apostolos D. Galatos [1], Eugenia Flouraki [1], Eleftheria Dermisiadou [1], Chryssoula Margeti [1] and Vassiliki Tsioli [1,*]

[1] Clinic of Surgery, Faculty of Veterinary Science, School of Health Sciences, University of Thessaly, Trikalon 224, 43100 Karditsa, Greece; stegeorgiou@vet.uth.gr (S.G.G.); agalatos@vet.uth.gr (A.D.G.); eldermis@uth.gr (E.D.)
[2] Clinic of Obstetrics and Reproduction, Faculty of Veterinary Science, School of Health Sciences, University of Thessaly, 14 Trikalon 224, 43100 Karditsa, Greece
[3] Laboratory of Epidemiology, Biostatistics and Animal Health Economics, Faculty of Veterinary Science, School of Health Sciences, University of Thessaly, Trikalon 224, 43100 Karditsa, Greece; bskamp@uth.gr
[4] Laboratory of Pathology, Faculty of Veterinary Science, School of Health Sciences, University of Thessaly, Trikalon 224, 43100 Karditsa, Greece; ddoukas@uth.gr
* Correspondence: vtsioli@uth.gr; Tel.: +30-2441066067

Abstract

Skin wounds in dogs and cats are frequently managed by second-intention healing, yet comparative evidence on topical treatments in these species remains limited. This study investigated wound-healing dynamics in dogs and cats using a standardized experimental model that enabled direct interspecies and within-animal comparison of treatment responses during secondary-intention healing. Standardized full-thickness cutaneous wounds were created on the dorsolateral trunk, with multiple wounds per animal randomly assigned to different treatments, including Manuka honey, Dermapliq, and untreated controls. Healing was evaluated using a multimodal approach, including clinical endpoints, planimetric analysis of epithelialization, contraction and total healing, ultrasonographic assessment, and blinded histopathology. Planimetry-derived total wound healing, the primary endpoint, did not differ significantly among treatments, while treatment-associated differences were identified in selected secondary endpoints. Dermapliq-treated wounds reached complete epithelial coverage earlier and showed smaller ultrasonographic wound areas than untreated controls, whereas Manuka honey was associated with faster complete granulation coverage but greater exudate quantity. Interspecies differences were also identified, with cats generally exhibiting slower progression to key healing endpoints than dogs under identical experimental conditions. These findings suggest species-specific healing responses and phase-dependent treatment-associated differences during secondary-intention wound healing in a controlled experimental model. However, they should not be interpreted as evidence of broad treatment superiority. Further studies in naturally occurring, larger, contaminated, infected, or chronic wounds are required before direct clinical extrapolation.

Keywords: cat; Dermapliq; dog; Manuka honey; skin; wound healing

Check for updates

Academic Editor: Romy M. Heilmann

Received: 19 March 2026
Revised: 7 June 2026
Accepted: 8 June 2026
Published: 11 June 2026

Copyright: © 2026 by the authors. Licensee MDPI, Basel, Switzerland. This article is an open access article distributed under the terms and conditions of the Creative Commons Attribution (CC BY) license.

1. Introduction

In veterinary medicine, skin wounds are frequently managed by second-intention healing depending on the size and location of the wound and various other factors, such as

infection, systemic disease, or concurrent medications [1,2]. Dogs and cats differ in their second-intention healing capacity and appear to utilize distinct mechanisms [3–5]. Dogs possess a richer vascular supply due to a greater density of collateral subcutaneous trunk vessels, which contributes to improved perfusion and generally faster healing [1,2]. In addition, granulation tissue in cats tends to form more peripherally, while in dogs it is located more centrally [1–5]. Bohling et al. [3–5] reported that wound epithelialization, contraction, and overall healing occur faster in dogs compared to cats. As a result, feline wounds generally exhibit delayed healing. Understanding these species-specific healing characteristics, as well as the effects of available topical wound treatments, is essential for optimizing wound care in clinical practice.

A variety of topical agents have been evaluated for their ability to promote second-intention wound healing [1,2,6]. Their effects have been studied across various species, including rats [7–9], horses [10–12], cats [13–17] and dogs [18–22]. In humans, such treatments are commonly used to manage chronic wounds, including ulcers, vasculitis, and pyoderma gangrenosum [23–26].

Medical-grade honey has been successfully used to treat various open-wound types in humans [27–35]. A limited number of studies have explored its effects in dogs [36,37], cats [15,16,38], and rats [39,40]. Manuka honey, in particular, has demonstrated enhanced antimicrobial properties due to its methylglyoxal content [28,41–43]. Its antimicrobial efficacy is attributed to its osmotic activity, low pH, and the presence of methylglyoxal, which can also inhibit biofilm formation [43,44]. It has been studied in humans [45–47], rodents [42], horses [11,48,49], and dogs [37]. However, Repelin et al. [37] reported conflicting results regarding its efficacy in acute cutaneous wounds in dogs, and there is a paucity of data regarding its effect on second-intention healing in cats.

Advancements in veterinary wound management have led to increased interest in regenerative medicine approaches, including mesenchymal stem cells, platelet-rich plasma, and bioelectric dressings [3,17,22,50–54]. Within this field, the extracellular matrix (ECM) plays a central role in tissue repair and in regulating the wound-healing process [55–57]. In both acute and chronic wounds, ECM components may become damaged or degraded [58]. Dermapliq is a commercial wound-healing agent containing a molecule from the ReGeneraTing Agents (RGTA) family—biodegradable polymers engineered to mimic heparan sulfates found in the ECM of injured tissues. Heparan sulfates are essential for maintaining tissue homeostasis [58,59]. The use of RGTAs promotes the replacement of the destroyed HS from enzymes related to inflammation. RGTAs adjust the wound microenvironment by stabilizing and protecting heparin-binding growth factors (HBGFs) and matrix proteins. By these mechanisms, they accelerate granulation tissue formation, cell migration, and angiogenesis, thus enhancing wound healing [55,59,60]. Case reports have described their use in humans [61,62] and dogs [58], but no studies to date have evaluated the effect of RGTAs on second-intention cutaneous wound healing in cats.

Recent veterinary wound-management studies have also evaluated additional approaches for complex or delayed-healing wounds, including negative-pressure wound therapy, platelet-derived biological products, and biological membranes. Negative-pressure wound therapy has been reported as an adjunctive option in canine wound management, including clinical experience in dogs and experimental studies involving graft healing. Autologous leukocyte- and platelet-rich fibrin membranes have recently been evaluated for chronic cutaneous wounds in dogs, with reported improvements in wound closure and tissue regeneration. Amniotic membrane-based treatments have also been investigated experimentally in canine full-thickness skin wounds, with lyophilized amniotic membrane showing favorable effects on wound closure, re-epithelialization, and collagen remodeling. These approaches highlight the growing interest in regenerative and biologically

active strategies for veterinary wound care, but direct comparisons across species and wound-healing modalities remain limited [63–65].

In a previous controlled study performed by the same research team, the aforementioned topical agents (Manuka honey and Dermapliq) were evaluated in dogs and cats with first-intention incisional wound healing, and treatment effects differed across clinical, ultrasonographic, and histological outcomes [66]. However, first-intention and second-intention healing are biologically distinct processes, and findings from surgically apposed incisions cannot be directly extrapolated to open wounds, in which granulation tissue formation, contraction, epithelial migration over an open-wound bed, and exudate management play a central role in repair. Therefore, evaluation of these agents in a standardized second-intention wound model was warranted.

The aim of this study was to characterize treatment- and species-related differences during second-intention wound healing in dogs and cats using a standardized experimental model. We hypothesized that healing dynamics would differ between species and that both topical treatments would produce phase-specific advantages compared with untreated controls.

2. Materials and Methods

2.1. Animal Ethics

All procedures were approved by the National Animal Ethics Committee, in accordance with the European Union directive 2010/63/EU (license numbers:1118/45307 21.3.2017, 411/9.1.2020), and by the Animal Ethics Committee of the Faculty of Veterinary Science, University of Thessaly (license numbers: 32/15.9.2016, 88/5.12.2019). The research protocol was in accordance with the European Union legislation concerning the welfare and humane treatment of laboratory animals. A prospective study protocol was not preregistered.

2.2. Animals

The study included 12 purpose-bred laboratory Beagle dogs aged 3–7 years (7 castrated males and 5 spayed females) and 12 purpose-bred laboratory domestic short-haired cats aged 2–6 years (9 castrated males and 3 spayed females), fully vaccinated. Animal characteristics are summarized in Supplementary Table S1. During the study, all the animals were housed individually; dogs were kept in indoor runs with daily outdoor access and cats in large indoor cages for the first 2 postoperative months and afterwards in large enclosures with plenty of rest areas and hiding places. A standard commercial dry maintenance diet was given, and water was offered ad libitum.

2.3. Inclusion Criteria

Prior to enrollment, animals underwent physical examination, complete blood count, serum biochemistry, urinalysis, fecal parasitology, and testing for feline leukemia virus, feline immunodeficiency virus, feline infectious peritonitis, and Leishmania infantum. No medications had been administered within 60 days before the study, and no pathological skin conditions were present.

2.4. Experimental Design

On day 0 (wound creation) and biopsy days, dogs were premedicated with acepromazine (Acepromazine, Alfasan, Woerden, The Netherlands) at 0.03 mg/kg intramuscularly (IM) and butorphanol (Dolorex, MSD, Boxmeer, The Netherlands) at 0.1 mg/kg IM. Cats were premedicated with dexmedetomidine (Dexdomitor, Orion Pharma, Espoo, Finland) at 20 μg/kg IM and buprenorphine (Bupaq, Neocell, Athens, Greece) at 20 μg/kg IM.

Anesthesia was induced in both species using incremental IV doses of propofol 1% (1–3 mg/kg IV) (Propofol MCT/LCT 1%; Fresenius Kabi Hellas, Athens, Greece) and maintained with isoflurane (2%, Isoflo; Abbott Laboratories, Maidenhead, Berkshire, UK) in oxygen (2 L/min). Fluids (Lactated Ringer's, VIOSER, Trikala, Greece) were administered IV at 3 mL/kg/h and 5 mL/kg/h in cats and dogs, respectively) during anesthesia. Preoperatively, a single dose of cefuroxime (20 mg/kg, intravenously [IV]; Zinacef, GlaxoSmithKline, Athens, Greece) was administered.

All animals were positioned in sternal recumbency, and the dorsolateral area from the cranial aspect of the thorax to the lumbosacral junction was prepared for aseptic surgery. Using a sterile skin marker and a millimeter ruler, 6 circles were drawn, 3 on either side of the dorsal midline.

The circles were 6 and 4 cm away from the dorsal midline in dogs and cats respectively. Each wound was 8 and 6 cm apart from each other in dogs and cats, respectively. The most cranial circle was located just caudally to the caudal border of the scapula, and the most caudal was located just cranially to the iliac crest. Full-thickness skin wounds were created following excision of the cutaneous trunci muscle and subcutaneous tissue by using a disposable dermal biopsy punch of 8 mm in diameter. Wound-to-treatment allocation, for all 3 wounds on each side, was generated using a computer-based random number generator (software used Excel RAND) by an investigator not involved in outcome assessment. On both sides, one wound was treated with Manuka honey (Manuka honey gel, Henry Schein, Melville, NY, USA), one was treated with Dermapliq® (Dermapliq spray, OTR3, Paris, France), and one was used as an untreated control. Treatments were applied once daily aseptically until complete wound healing.

An 8 mm biopsy-punch-wound size was selected to create standardized, reproducible, full-thickness cutaneous defects that were large enough to permit objective planimetric, ultrasonographic, and histologic monitoring of second-intention healing, while remaining sufficiently small to minimize animal discomfort, avoid excessive tissue loss, and allow multiple randomized wounds within the same animal. This size also reduced variability caused by differences in wound geometry and enabled within-animal comparison among topical methods under controlled conditions.

Postoperatively, the wounds were covered with a nonadherent dressing with adhesive edges (Cosmopor, Hartmann, Heidenheim, Germany), a cotton roll pad (Rolta soft padding bandage, Hartmann, Heidenheim, Germany) around the trunk, crossing around the forelimbs and an adhesive bandage (Peha-haft, Hartmann, Heidenheim, Germany) placed around the trunk. An Elizabethan collar was placed on all animals, and meloxicam (Metacam, Boehringer Ingelheim, Ingelheim am Rhein, Germany) at 0.1 mg/kg in cats and 0.2 mg/kg in dogs was delivered subcutaneously (SC).

The left-sided wounds were used to evaluate the second-intention wound healing by subjective clinical evaluation, planimetry and ultrasonography. The right-sided wounds were used for histological evaluation [3,13]. Complete blinding of treatment application was not feasible because the products differed visibly in appearance and handling characteristics. To reduce performance bias, treatments were applied according to a predefined standardized protocol by personnel not involved in outcome assessment. Dressing type, dressing-change frequency, wound handling, and postoperative care were kept consistent across groups. Outcome evaluators, image analysts, and the pathologist were blinded to treatment allocation using coded wound identifiers.

All possible adverse events/complications were recorded during daily clinical examination of the animals and scheduled wound care. Predefined adverse events necessitating removal of an animal from the study included severe uncontrollable pain, infection/sepsis

signs and persistent anorexia. A summary of the experimental design and wound allocation is provided in Supplementary Table S2.

The primary endpoint was planimetry-derived total wound healing (%) of left-sided wounds over time. Secondary planimetry endpoints included percentage epithelialization (%) and percentage wound contraction (%). Secondary clinical endpoints included time to first appearance of granulation tissue, time to complete coverage by granulation tissue, time to wound filling with granulation tissue, and time to complete epithelial coverage, as well as wound fluid quantity and appearance scores recorded during clinical evaluation of wounds. Additional secondary endpoints included ultrasonographic wound area (mm^2) assessed serially until day 150 and histological healing scores assessed on days 12, 120, and 150 from right-sided wounds. Treatment method, species, postoperative day or time, and relevant interaction terms were evaluated in the statistical models as described below.

2.5. Postoperative Care

In dogs, buprenorphine at 10 µg/kg IM was administered during recovery, every 8 h for 2 days, and meloxicam at 0.1 mg/kg SC once daily for 5 days, along with consecutive postoperative pain assessment. In cats, buprenorphine at 10 µg/kg IM was administered postoperatively, every 8 h for 2 days, and meloxicam 0.05 mg/kg SC once daily for the next 4 days. Pain scores were assessed in both species using the Short-Form Glasgow pain scale (Glasgow CMPS-SF for dogs and Glasgow CMPS-Feline). Rescue analgesia was not required in any animal.

Amoxicillin and clavulanic acid (20 mg/kg, sid, SC, Synulox Haupt Pharma Italy, Latina, Italy) were administered until the second day postoperatively. Elizabethan collars were used on all animals. Bandages were changed daily until complete wound healing. During bandage changes, planimetry measurements and ultrasonography, cats were sedated with dexmedetomidine (20 µg/kg, IM, Dexdomitor, Orion Pharma, Espoo, Finland) and butorphanol (0.2 mg/kg, IM, Dolorex, MSD, Boxmeer, the Netherlands)).

A short perioperative antimicrobial protocol was used because the model involved the creation of multiple full-thickness open wounds and serial dressing changes/biopsies under experimental conditions. Cefuroxime was administered preoperatively as surgical prophylaxis, and amoxicillin–clavulanic acid was continued only until the second postoperative day. The duration was intentionally limited to reduce antimicrobial exposure while minimizing the risk of early postoperative contamination-related complications that could confound treatment comparisons.

2.6. Clinical Evaluation

Clinical evaluation was performed daily, although only data recorded on postoperative days 4, 7, 14, 21, and 30 were included in the analysis; all evaluations were performed by the same observer (TZ). The following parameters were evaluated and recorded: first appearance of granulation tissue, complete coverage by granulation tissue, wound filling with granulation tissue, complete epithelial coverage, the quantity and nature of any wound fluid in the bandages, as well as any sign of infection or other abnormalities. The quantity of wound fluid was scored as none (0), slight (1), moderate (2), or extreme (3), and its nature was described as absence of fluid (0), serous (1), serosanguineous (2), sanguineous (3), or purulent (4) [14]. This scoring system is a previously published semi-quantitative veterinary wound fluid scale, rather than a validated multidimensional wound assessment tool such as the Bates-Jensen Wound Assessment Tool [14,67].

2.7. Planimetry

Planimetry was performed on days 0, 4, 7, 14, 21 and 30 after surgery and until complete wound healing. Digital photos of the wounds and computer software (AutoCAD

Software, educational version 2018.0.0; Autodesk, San Francisco, CA, USA) were used to estimate the area of the initial wound and that covered by the advancing epithelium. The percentage of epithelialization, wound contraction, and total wound healing was calculated for each wound according to the previously reported formula [4].

2.8. Ultrasonographic Evaluation

B-mode ultrasonography of the skin was performed by means of a real-time ultrasound machine. The ultrasound unit (Longport Digital Scanner [LDS1], Longport International Ltd., Silchester, UK) was fitted with a 50.0 MHz polyvinylidene difluoride transducer incorporated into a probe filled with distilled water and scanned using a digital stepping motor. The ultrasound beam was propagated through an aperture covered with a disposable rubber membrane; a new membrane was used for each wound. The transducer was applied to the wound area using light pressure and coupling gel as a transmission medium.

All wounds were examined postoperatively every 3 days until day 25, once a week until day 60, on day 120 and finally on day 150. The digitized scans were stored on the associated hard drive and were visualized using a color palette (rainbow). Images were compressed laterally to facilitate viewing of the wound area. The wound-area calculations (in mm^2) were performed by using computer software [68–72].

2.9. Histological Evaluation

Histological evaluation of the healing process was performed on postoperative days 12, 120 and 150 by collecting tissue samples from the wounds' corners along with 1–2 mm of surrounding normal skin of the right side with a disposable biopsy punch of 4 mm diameter. The excised skin on day 0 served as the control. The first sample was taken on day 12 postoperatively from the dorsal and cranial corners of the wound, while the other specimens were collected by rotation in a clockwise fashion. The samples were immediately fixed in 10% buffered formalin and stained with haematoxylin and eosin. The pathologist was unaware of the group corresponding to each specimen. The histological sections were evaluated according to already existing scales [19,72].

Stained sections were microscopically evaluated to assess the degree of inflammatory cell infiltration, edema, presence of fibroblasts, and angiogenesis, in 10 high-power fields per section (400×). The degree of cellular infiltration was evaluated by scoring the number of infiltrating neutrophils, eosinophils, lymphocytes, plasma cells, macrophages, and mast cells as follows: less than 3 cells/field was considered normal (0), 3–10 cells/field mild (1), 11–30 cells/field moderate (2), and more than 31 cells/field substantial increase (3).

Edema was scored as normal (0), mild (1), moderate (2), and substantial increase (3). Absence of separation of cells and collagen by nonstained or poorly stained acellular material was considered normal (0); slight separation was considered mild edema (1), a separation of 30–50 mm was considered moderate edema (2), and a separation of more than 50 mm was considered substantial edema (3).

The presence of fibroblasts was scored as (0) when fewer than 3 fibroblasts were found per field, (1) when 3–10 fibroblasts were found per field, (2) when 11–30 fibroblasts were found per field and [3] when more than 31 fibroblasts were found per field. Angiogenesis was scored as follows: less than 3 capillary buds/field (0), 3–10 (1), 11–30 (2), and more than 31 (3).

2.10. Sample Size Estimation

An a priori sample size estimation was performed for the primary endpoint, defined as planimetry-derived total wound healing (%) over time, and was intended to detect biologically relevant differences under a repeated-measures framework. Calculations were performed using G*Power v3.1.9.7. and assumed a two-sided significance level of

$\alpha = 0.05$ and 80% power. Expected differences in planimetry-derived healing outcomes between dogs and cats were informed by published data [5]. Because the study used a longitudinal design with repeated assessments per wound and multiple wounds per animal randomized to different topical methods, the sample size was estimated under a repeated-measures framework assuming a correlation among repeated measurements of 0.5 and a nonsphericity correction index of 1, with the planned number of postoperative measurements. Under these assumptions, the minimum required sample size was estimated to range from 4 to 10 animals per species. Therefore, 12 dogs and 12 cats were enrolled to meet and exceed the minimum requirement and to allow for potential missing observations. With the enrolled sample size of 12 animals per species, the estimated power for the primary planimetry-derived endpoint was approximately 83% under the same a priori assumptions. However, this power estimate applies only to the primary planimetric endpoint and should not be extrapolated to secondary outcomes, histological variables, subgroup comparisons, or species-by-treatment interaction terms.

2.11. Statistical Analysis

Statistical analyses were performed using Stata 17.0 (StataCorp LLC, College Station, TX, USA). Statistical significance was set at $\alpha = 0.05$ (two-sided). There was no missing data for the planned outcome assessments.

The primary analytical approach used combined models, including both species, rather than fully stratified species-specific models. Species, treatment method, postoperative day or time, and relevant interaction terms were included as fixed effects. The data had a hierarchical structure, with repeated measurements over time clustered within individual wounds, and wounds clustered within animals. Because each animal contributed multiple wounds randomized to different topical methods, within-animal correlation was accounted for using mixed-effects models, shared-frailty survival models, or cluster-robust variance estimation, depending on the outcome. Between-animal heterogeneity was accounted for using a random intercept at the animal level and, where applicable, an additional random intercept for the animal-treatment/wound combination to reflect between-wound heterogeneity within the same animal, consistent with multilevel modeling principles [73]. All possible and applicable two-way interactions between every model's fixed effects were tested for significance; specifically, species-by-treatment, species-by-time and treatment-by-time were examined to determine whether treatment- and/or time-associated effects differed between dogs and cats. Species-specific descriptive summaries and plots were used to illustrate interspecies healing patterns and species-by-treatment interactions.

A summary of the models used for each outcome group is provided in Table 1. Unless otherwise stated, untreated control wounds and dogs were used as the reference categories for treatment and species, respectively. For categorical time variables, the earliest scheduled assessment time point was used as the reference category; when postoperative day was modeled as a continuous variable, estimates were interpreted per one-day increase.

Table 1. Summary of statistical models used for each outcome group.

Outcome Group	Dependent Variable	Statistical Model	Fixed Effects	Interaction Terms Tested	Random Effects and/or Clustering	Reference Categories and Effect Measure
Clinical time-to-event endpoints	Time to first appearance of granulation tissue; time to complete coverage by granulation tissue; time to wound filling with granulation tissue; time to complete epithelial coverage	Parametric shared-frailty survival models interpreted under the accelerated failure time framework. Exponential, Weibull, Gompertz, log-normal, and log-logistic distributions were evaluated, and the final distribution was selected according to hazard-shape assessment and the lowest Akaike's information criterion	Treatment method and species	Species × treatment	Shared frailty at the animal level to account for clustering of multiple wounds within the same animal	Control wounds and dogs were the reference categories. Results are reported as time ratios (TRs) with 95% confidence intervals. TR > 1 indicates a longer time to the event, whereas TR < 1 indicates a shorter time to the event
Wound fluid scores	Wound fluid quantity score (0–3); wound fluid appearance score (0–4)	Mixed-effects ordinal logistic regression	Treatment method, species, and assessment day	Species × treatment; time-related effects were evaluated through the assessment day	Random intercepts at the animal and animal-treatment/wound combination level.	Control wounds, dogs, and the first scheduled clinical assessment day were the reference categories. Results are reported as odds ratios (ORs) with 95% confidence intervals

Table 1. *Cont.*

Outcome Group	Dependent Variable	Statistical Model	Fixed Effects	Interaction Terms Tested	Random Effects and/or Clustering	Reference Categories and Effect Measure
Planimetric outcomes	Total wound healing (%) as the primary endpoint; epithelialization (%); contraction (%)	Fractional logistic regression for fractional/proportional outcomes	Treatment method, species, and postoperative day	Species × post-operative day; treatment × post-operative day; species × treatment, where applicable	Robust variance estimation clustered at the animal and/or animal-treatment/wound level to account for intra-cluster correlation	Control wounds and dogs were the reference categories. Postoperative day was interpreted according to the model structure. Results are reported as ORs with 95% confidence intervals
Ultrasonographic outcome	Ultrasonographic wound area (mm^2)	Quantile regression/median regression	Treatment method, species, and postoperative day	Treatment × post-operative day; species × treatment; species × post-operative day	Robust variance estimation clustered at the animal and/or animal-treatment/wound level to account for intra-cluster correlation	Control wounds and dogs were the reference categories. Results are reported as median differences/regression coefficients with 95% confidence intervals
Histological scores	Inflammatory cell infiltration, edema, fibroblast score, and angiogenesis score	Mixed-effects ordinal logistic regression	Treatment method, species where applicable, and assessment day	Species × treatment; species × assessment day, where applicable	Random intercepts for animal and animal-treatment/ wound combination	Control wounds, dogs, and day 12 were the reference categories. Results are reported as ORs with 95% confidence intervals

Note: OR, odds ratio; TR, time ratio. Control wounds and dogs were used as the main reference categories unless otherwise specified. For longitudinal outcomes, the postoperative day or assessment day was included according to the structure of each endpoint. Interaction terms were evaluated to determine whether treatment-associated effects differed between species or over time; non-significant interactions were not retained in the final models unless required for interpretation.

2.11.1. Clinical Evaluation

Clinical evaluation (time-to-event endpoints).

Times to first appearance of granulation tissue, complete coverage by granulation tissue, wound filling with granulation tissue, and complete epithelial coverage were analyzed as time-to-event outcomes. These endpoints were modeled using parametric shared-frailty survival models to account for clustering of wounds within animals [74]. Five parametric distributions (exponential, Weibull, Gompertz, log-normal, and log-logistic) were evaluated; the final distribution for each endpoint was selected based on hazard-shape assessment and the smallest Akaike's information criterion (AIC) [75]. Models were interpreted using the accelerated failure time (AFT) metric, and results are reported as time ratios (TRs) with 95% confidence intervals; TR > 1 indicates a longer time to the event (slower achievement), whereas TR < 1 indicates a shorter time [75,76]. Hazard functions were estimated to describe method-specific changes in event risk over time. Wound fluid quantity (0–3) and fluid appearance (0–4) were analyzed as ordinal outcomes using mixed-effects ordinal logistic regression with treatment method, species, and assessment day as fixed effects and random intercepts for animal and animal-treatment–(wound) combination. Although wounds were examined daily during routine care, fluid scores were recorded at the scheduled clinical evaluation time points only (days 4, 7, 14, 21, and 30).

2.11.2. Planimetry

Planimetry-derived total wound healing (%) (primary endpoint), epithelialization (%), and contraction (%) were evaluated on postoperative days 0, 4, 7, 14, 21, and 30. Because these outcomes are fractional and were not normally distributed (Shapiro–Wilk tests, $p < 0.001$), associations with treatment were modeled using fractional logistic regression (fractional logit) using the fracreg command. Models included treatment method, species, and postoperative day as predictors. Standard errors were adjusted for clustering within specific animal treatment combinations and/or within-animal, using robust variance estimations clustered at the aforementioned levels.

2.11.3. Ultrasonographic Evaluation

Ultrasonographic wound-area (mm^2) values were continuous and not normally distributed (Shapiro–Wilk, $p < 0.001$); therefore, treatment effects on the median wound area were assessed using quantile regression with treatment method, species, and postoperative day as predictors. Specifically, the *qreg2* command was used to estimate quantile regression, allowing for adjustment of standard errors and t-statistics that are asymptotically

valid under heteroskedasticity and intra-cluster correlation between measurements within specific animal treatment combinations and/or within the same animal, using the *cluster* option. The Parente-Santos Silva test was by default used to examine the assumptions for the existence of intra-cluster correlation [77].

2.11.4. Histological Evaluation

Histologic scores (inflammatory cell infiltration, edema, fibroblasts, and angiogenesis) were analyzed as ordinal outcomes using mixed-effects ordinal logistic regression with treatment method, species (where applicable), and assessment day as fixed effects and random intercepts for animal and animal-treatment–(wound) combination.

3. Results

Treatment- and species-related differences were identified across multiple phases and modalities of secondary-intention wound healing. The most consistent findings were phase-specific treatment effects on granulation tissue progression, epithelial coverage, exudate characteristics, and ultrasonographic wound area, together with clear interspecies differences, with cats generally progressing more slowly than dogs in several clinical healing endpoints. In contrast, several planimetric and histologic outcomes appeared to be driven primarily by time and species rather than treatment. No animal met predefined removal criteria. All 12 dogs and 12 cats completed the study, and all planned wounds were included in the analyses.

3.1. Clinical Evaluation

First appearance of granulation tissue:

Early granulation dynamics differed by both treatment and species. A log-logistic distribution provided the best fit (AIC −87.55). There was no statistically significant difference between Dermapliq and control (p = 0.075). Manuka was associated with a longer time to first granulation tissue compared with control (TR = 1.23, 95% CI: 1.11–1.36, $p < 0.001$) and Dermapliq (TR = 1.12, 95% CI: 1.024–1.23, p = 0.014). Cats required a longer time to reach first granulation tissue appearance than dogs (TR = 1.68, 95% CI: 1.51–1.87, $p < 0.001$). A significant species-by-treatment interaction was detected ($p < 0.001$); in dogs, the control group reached first granulation tissue appearance earlier than the Manuka group (TR = 1.23, 95% CI: 1.08–1.40, p = 0.002).

Complete coverage by granulation tissue:

Progression to complete wound-bed coverage by granulation tissue differed among treatments and between species. A log-logistic distribution provided the best fit (AIC 13.72). Control wounds required a longer time to achieve complete granulation coverage compared to Dermapliq (TR = 1.17, 95% CI: 1.065–1.28, p = 0.001) and to Manuka (TR = 1.21, 95% CI: 1.11–1.33, $p < 0.001$). Cats required a longer time than dogs (TR = 1.94, 95% CI: 1.76–2.14, $p < 0.001$). No species-by-treatment interaction was observed (p = 0.861).

Wound filling with granulation tissue:

Wound filling with granulation tissue was influenced primarily by species rather than treatment. No statistically significant differences were detected between treatments after adjusting for species effect (all $p \geq 0.100$). Dogs reached wound filling earlier than cats (TR = 0.736, 95% CI: 0.624–0.867, $p < 0.001$). No species-by-treatment interaction was observed (p = 0.122).

Complete epithelial coverage:

Differences between treatments became evident again at the epithelialization stage. A log-normal distribution provided the best fit (AIC −75.79). Control wounds took longer to achieve complete epithelial coverage than Dermapliq (TR = 1.15, 95% CI: 1.118–1.187,

$p < 0.001$) and longer than Manuka (TR = 1.09, 95% CI: 1.058–1.125, $p < 0.001$). Manuka also took a longer time than Dermapliq (TR = 1.056, 95% CI: 1.024–1.089, $p < 0.001$). Cats required a longer time to complete epithelial coverage than dogs (TR = 1.48, 95% CI: 1.42–1.53, $p < 0.001$). No species-by-treatment interaction was observed ($p = 0.589$).

Quantity of fluid:

Treatment-related differences were also evident in wound exudate quantity. There was no statistically significant difference between Dermapliq and control ($p = 0.351$). Manuka-treated wounds had higher odds of increased fluid quantity score compared to control (OR = 1.88, 95% CI: 1.07–3.32, $p = 0.027$) and compared to Dermapliq (OR = 2.48, 95% CI: 1.40–4.43, $p = 0.002$). Cats had substantially higher odds of an increased fluid quantity score than dogs (OR = 14.1, 95% CI: 6.57–30.22, $p < 0.001$).

Fluid appearance:

Exudate appearance also differed by treatment, species, and time. Control had higher odds of a worse fluid appearance score than Dermapliq (OR = 2.85, 95% CI: 1.42–5.71, $p = 0.003$), while no significant differences were detected between control and Manuka or between Dermapliq and Manuka ($p = 0.142$, $p = 0.302$ respectively). Cats had higher odds of a worse fluid appearance score than dogs (OR = 8.87, 95% CI: 4.06–19.39, $p < 0.001$). Fluid appearance score improved over time (OR = 0.54, 95% CI: 0.44–0.67, $p < 0.001$); equivalently, each additional day was associated with lower odds of a higher (worse) score.

3.2. Planimetry

Epithelialization:

Planimetric epithelialization increased over time, with species-related differences but no significant treatment effect after adjustment. No statistically significant differences in epithelialization were detected between treatments (control vs. Dermapliq: $p = 0.585$; control vs. Manuka: $p = 0.202$; Dermapliq vs. Manuka: $p = 0.309$). Epithelialization increased over time (OR = 1.33, 95% CI: 1.008–1.75, $p = 0.043$). Species was associated with epithelialization (OR = 20.05, 95% CI: 1.59–252.57, $p = 0.020$), and a significant species-by-time interaction was present (OR = 1.25, 95% CI: 1.03–1.53, $p = 0.026$), indicating a higher rate of increase over time in cats relative to dogs (Figures 1 and 2).

Contraction:

Wound contraction increased over time across all groups, without detectable treatment-related differences. No statistically significant differences in contraction were detected between treatments (Dermapliq vs. control: $p = 0.302$; Manuka vs. control: $p = 0.563$; Manuka vs. Dermapliq: $p = 0.728$). Contraction rate increased over time (OR = 1.06, 95% CI: 1.025–1.094, $p = 0.001$). Species was not significantly associated with contraction ($p = 0.089$), but a significant species-by-time interaction was observed (OR = 1.056, 95% CI: 1.035–1.078, $p < 0.001$) (Figures 3 and 4).

Total wound healing:

Overall wound closure progressed over time in both species, but adjusted total wound-healing proportions did not differ significantly among treatments. According to the applied fractional logistic regression, no statistically significant differences in total wound-healing proportion were detected between treatments after adjusting for species and postoperative day (Dermapliq vs. control: $p = 0.429$; Manuka vs. control: $p = 0.500$; Manuka vs. Dermapliq: $p = 0.854$). Total wound healing increased over time ($p < 0.001$). Dogs demonstrated a higher healing rate than cats (OR: 0.398 for cats vs. dogs, 95% CI: 0.27–0.58, $p < 0.001$). A significant species-by-time interaction was observed ($p < 0.001$) (OR: 1.41, 95% CI:1.36–1.45), indicating different healing patterns over time between species (Figures 5 and 6). Representative photographs illustrating the wound healing process by treatment over time are shown in Figure 7 (dog No 2) and Figure 8 (cat No 5).

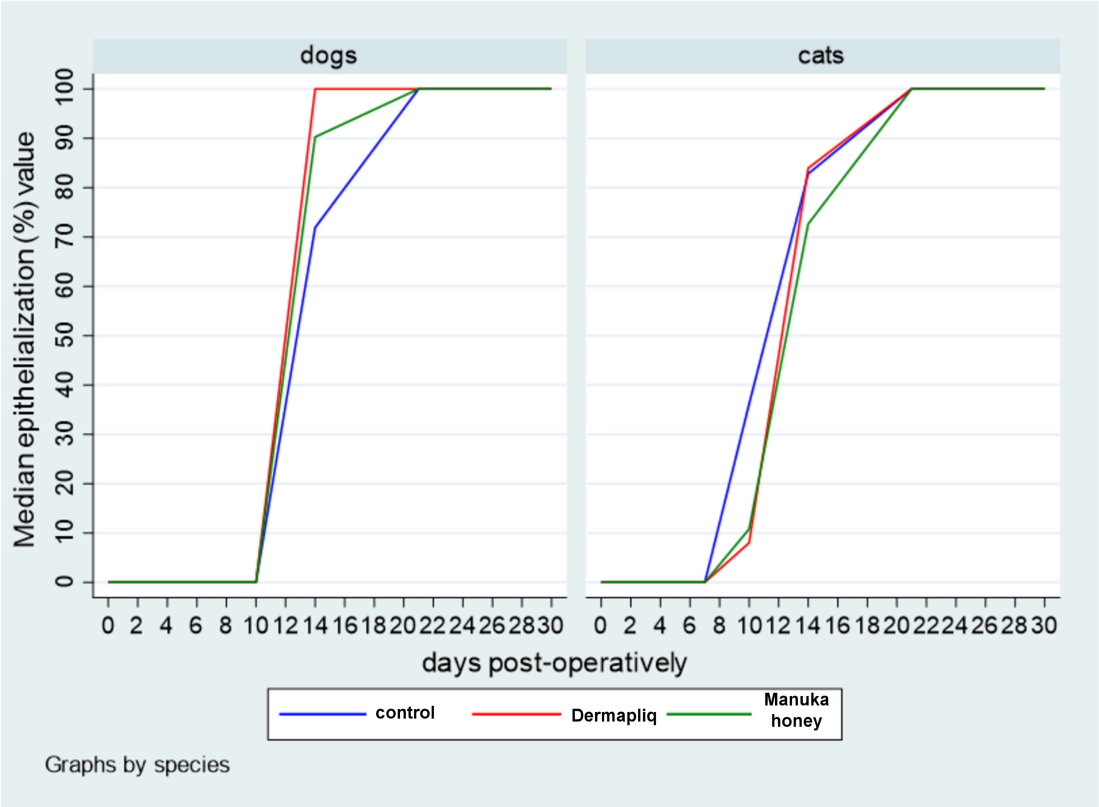

Figure 1. Median value of epithelialization percentage (%) by treatment and species over postoperative days.

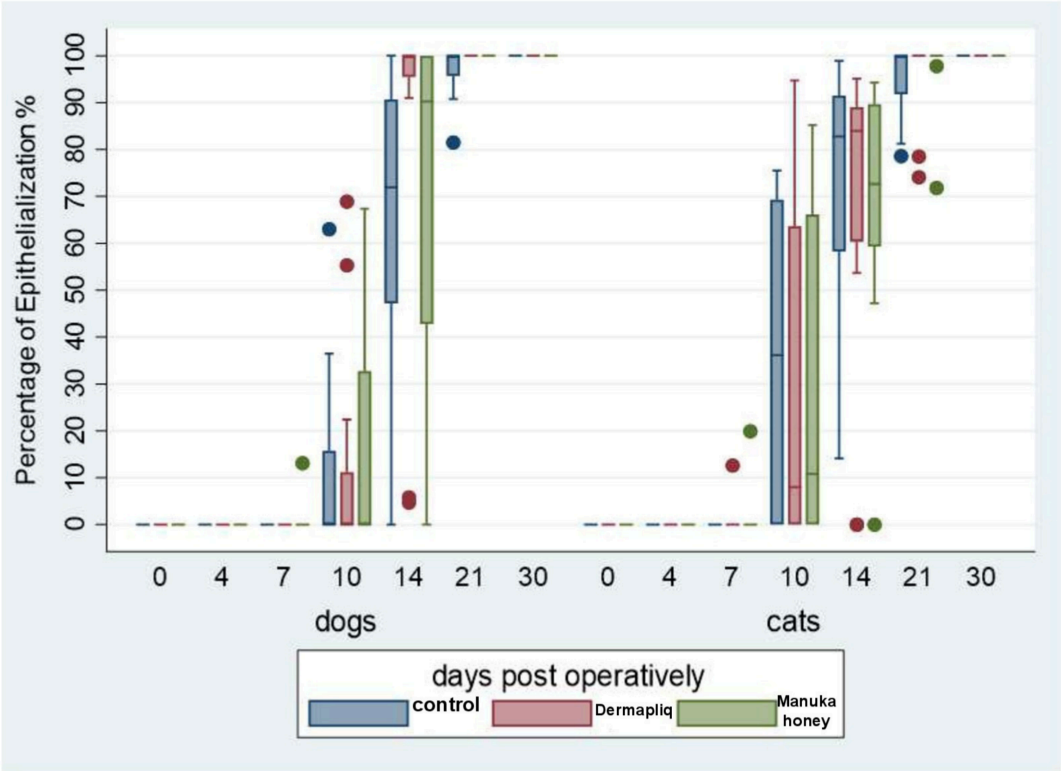

Figure 2. Median value and interquartile range (IQR) of epithelialization percentage (%) by treatment and species over postoperative days.

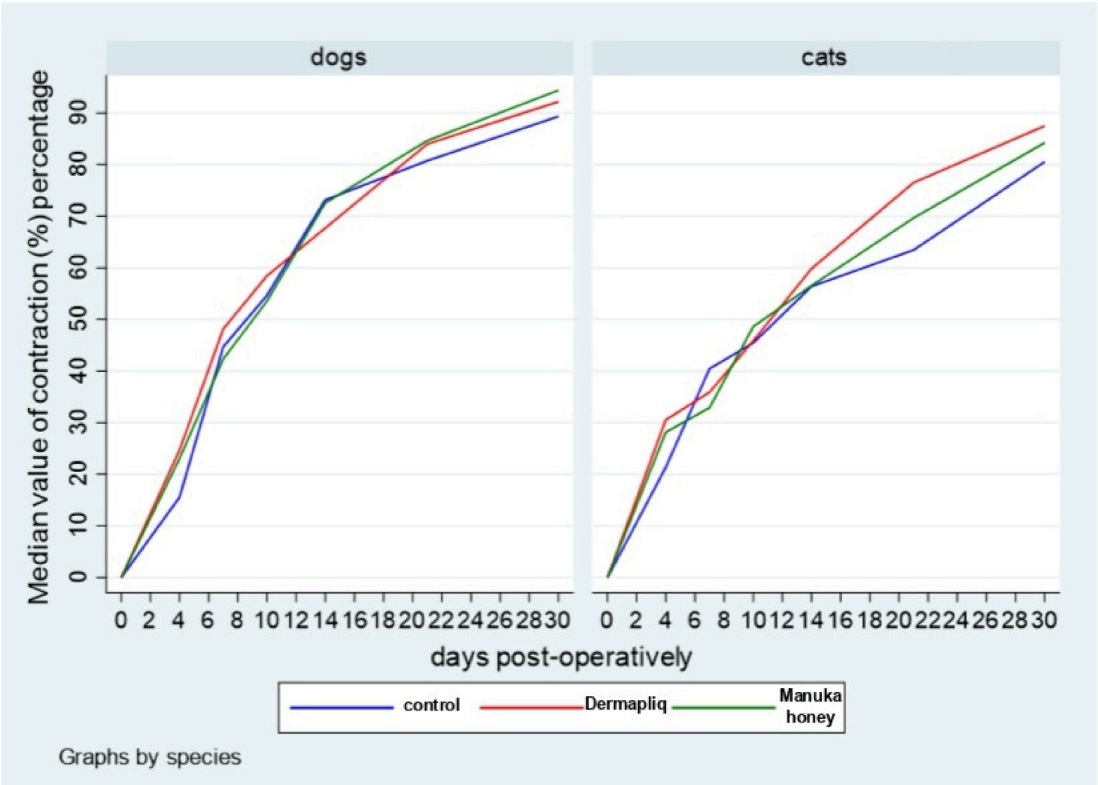

Figure 3. Median value of contraction percentage (%) by treatment and species over postoperative days.

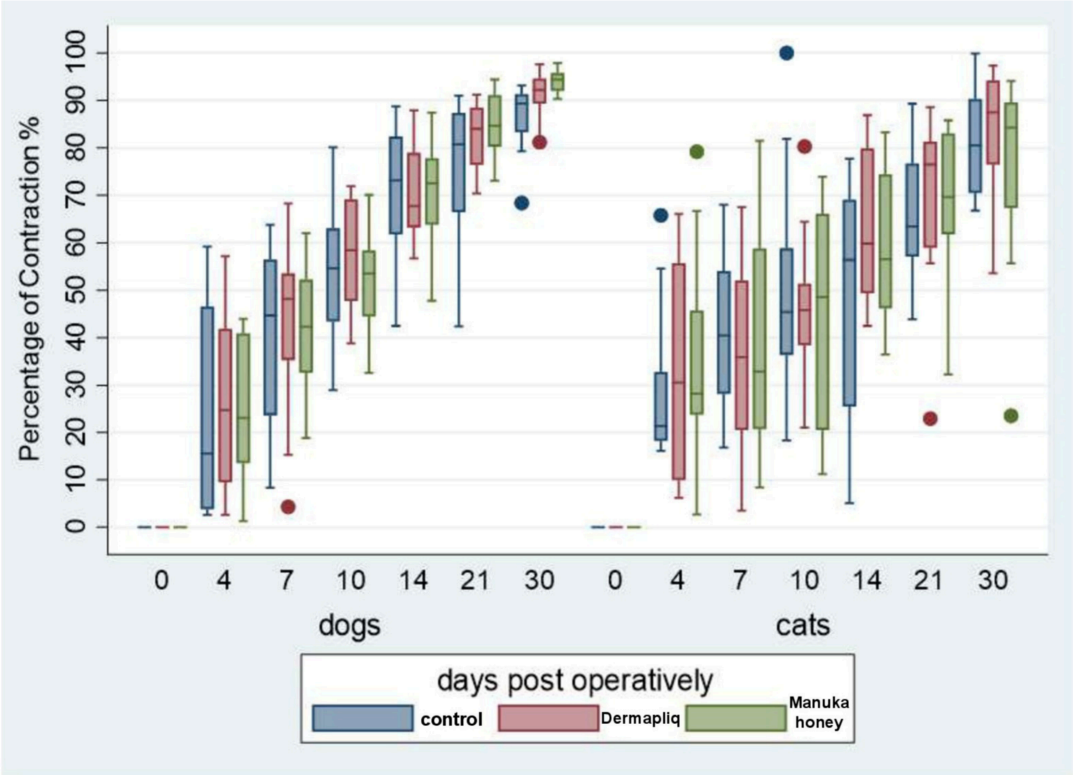

Figure 4. Median value and interquartile range (IQR) of contraction percentage (%) by treatment and species over postoperative days.

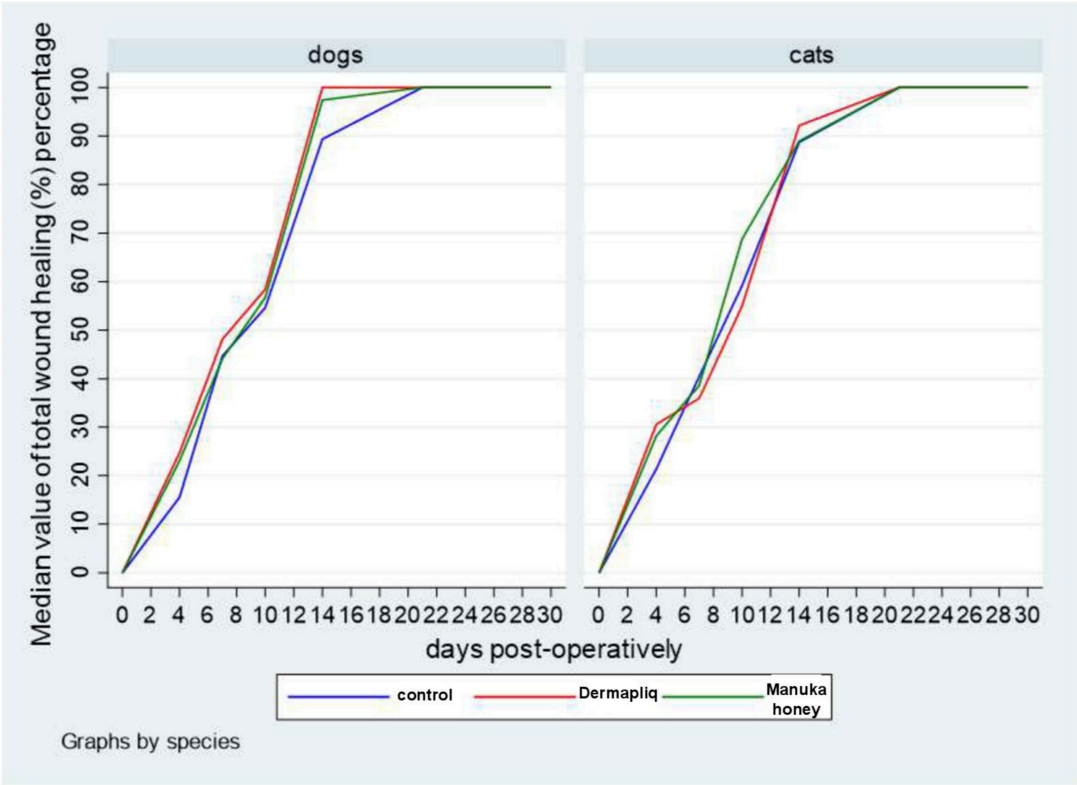

Figure 5. Median total wound-healing value (%) by treatment and species over postoperative days.

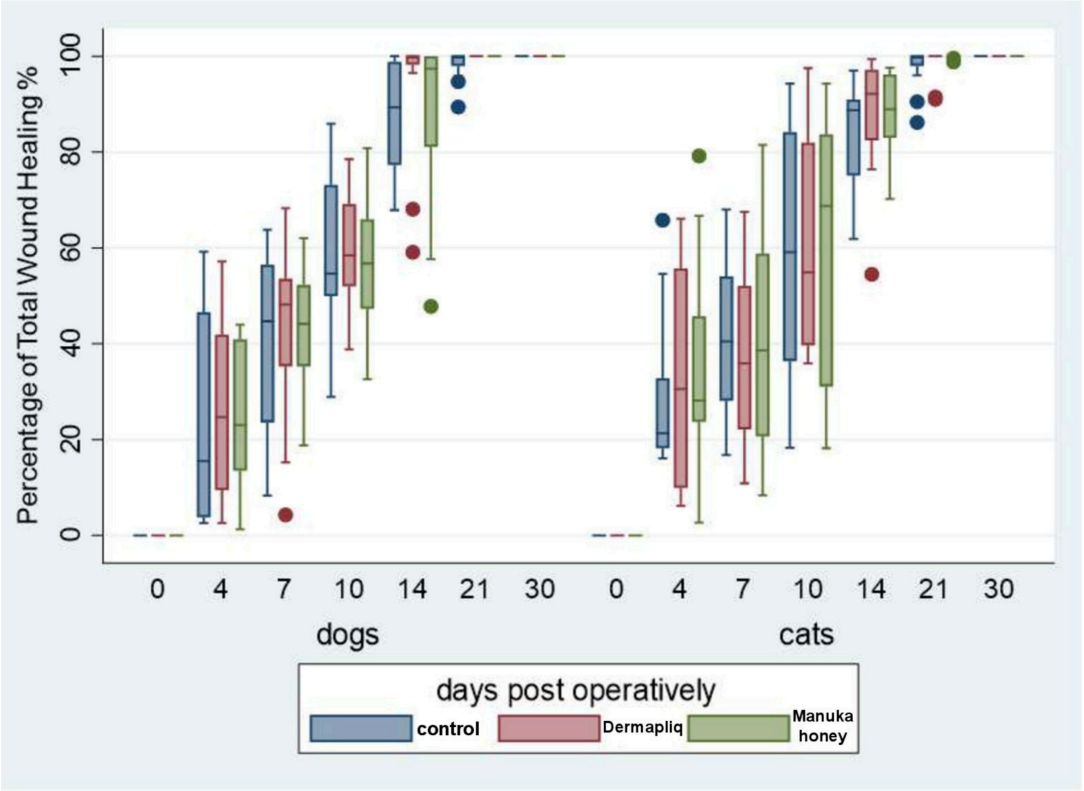

Figure 6. Median and interquartile range (IQR) of total wound-healing percentage (%) by treatment and species over postoperative days.



Figure 7. Representative serial photographs of standardized punch wounds in dog No. 2 treated with control, Dermapliq, or Manuka honey at postoperative days 7, 14, 21, and 30.



Figure 8. Representative serial photographs of standardized punch wounds in cat No. 5 treated with control, Dermapliq, or Manuka honey at postoperative days 7, 14, 21, and 30.

3.3. Ultrasonographic Evaluation (USG)

Ultrasonographic assessment identified treatment-related differences not fully detected by surface planimetry. In median regression, Dermapliq was associated with a smaller ultrasonographic wound area compared with control (difference −0.7, 95% CI: −1.35 to −0.053, $p = 0.034$), whereas differences between control vs. Manuka ($p = 0.107$) and Dermapliq vs. Manuka ($p = 0.641$) were not statistically significant. Wound area decreased over time ($p < 0.001$) (Coef.: −0.03, 95% CI: −0.052 to −0.0016). Species was not significantly associated with overall median wound area ($p = 0.07$). No significant treatment-by-time or species-by-treatment interactions were observed, while a species-by-time interaction was detected (Coef.: −0.011, 95% CI: −0.019 to −0.003, $p = 0.004$) (Figures 9 and 10). Interval-specific analyses (days 0–7, 8–17, 18–35, and 36–150) showed control generally had the largest wound areas in early and later intervals, with Dermapliq (and in some intervals, Manuka) associated with smaller wound areas relative to control. The ultrasound scans of the wound area are shown in Figure 11 (dog No 6) and Figure 12 (cat No 8).

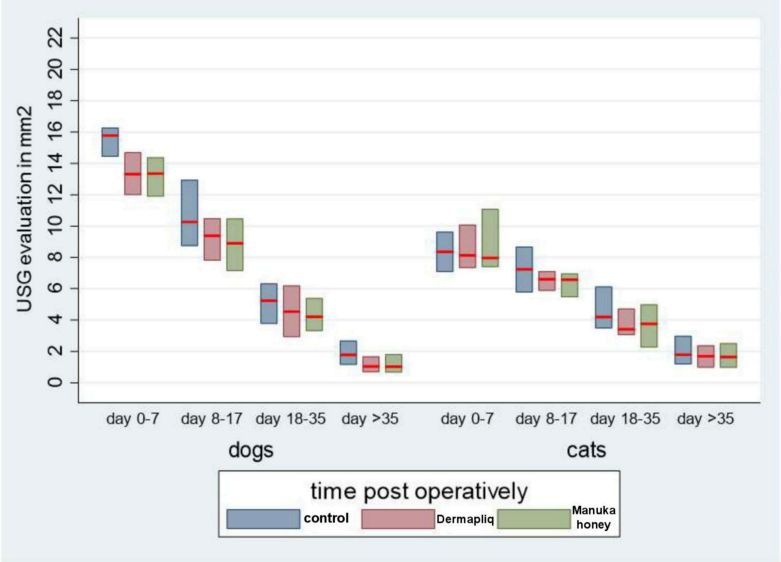

Figure 9. Median and interquartile range (IQR) of USG evaluation (in mm^2) by treatment and species over postoperative days.

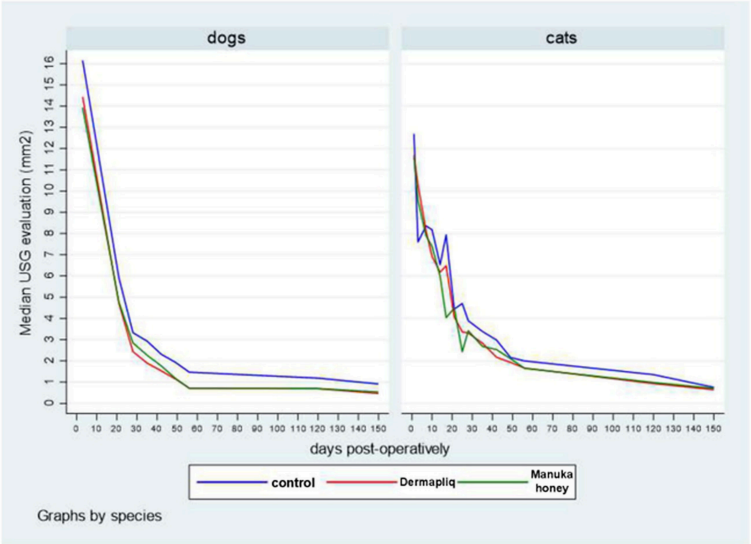

Figure 10. Median USG evaluation (mm^2) by treatment and species over postoperative days.

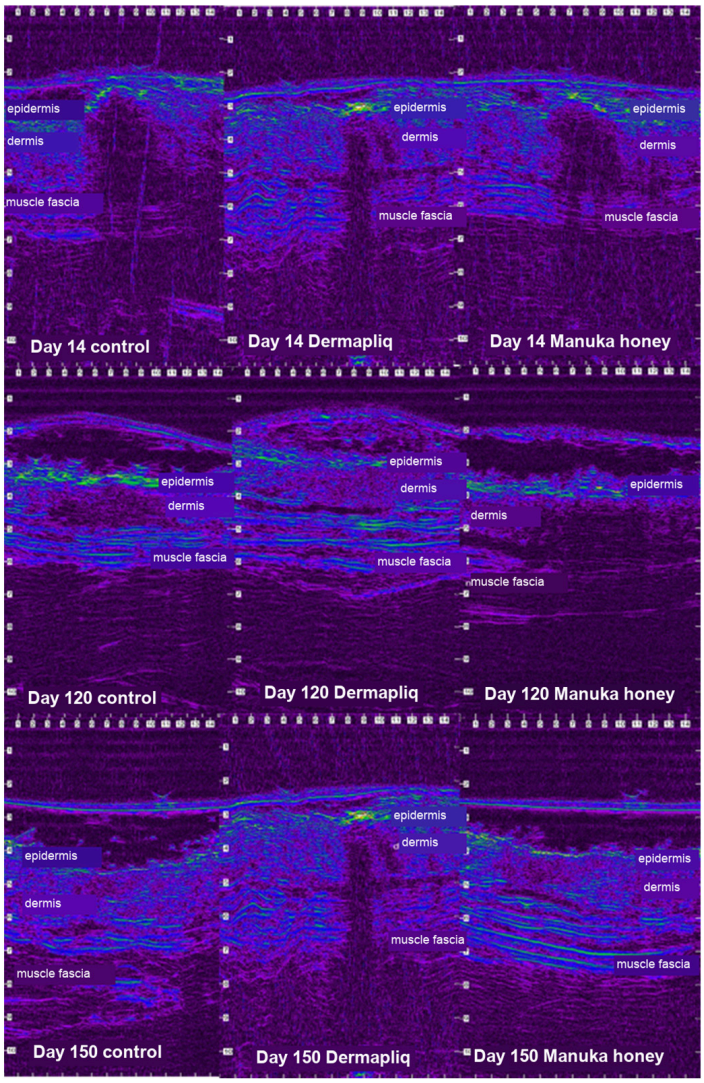

Figure 11. Representative ultrasonographic scans of the wound area in dog No. 6 at postoperative days 14, 120, and 150 for control, Dermapliq, and Manuka honey-treated wounds. Images were laterally compressed and displayed using a rainbow color palette to facilitate visualization. Scale bar in mm.

3.4. Histological Evaluation

Edema:

Edema was influenced primarily by species rather than treatment. No statistically significant differences were detected between treatments (all $p \geq 0.070$). Dogs had higher odds of edema than cats (OR = 6.73, 95% CI: 3.35–13.52, $p < 0.001$). No significant species-by-treatment interaction was observed ($p = 0.246$).

Inflammation:

Inflammation scores showed a clear time-dependent decline, consistent with healing progression, but no significant treatment effect after adjustment. Inflammation scores differed substantially by time point (day 12 > day 120 and day 150; day 120 > day 150; all $p \leq 0.012$). No statistically significant differences were detected between treatments after adjusting for time (Dermapliq vs. control $p = 0.052$; Manuka vs. control $p = 0.090$; Manuka vs. Dermapliq $p = 0.787$). Cats were more likely to have higher odds of increased inflammation scores than dogs (OR = 8.33, 95% CI: 2.32–29.9, $p = 0.001$).

Fibroblasts:

Fibroblast scores varied mainly with healing stage and species rather than treatment. Fibroblast scores were higher at day 12 than at days 120 and 150, and higher at day 120 than at day 150 (all $p \leq 0.002$). No statistically significant differences were detected between treatments. Cats had markedly higher odds of increased fibroblast scores than dogs (OR = 284, 95% CI: 32.75–2463). Time-by-species interaction was significant ($p = 0.001$).

Angiogenesis:

Angiogenesis likewise followed a predominantly time- and species-dependent pattern. Angiogenesis score was higher at day 12 than at days 120 and 150 (both $p < 0.001$), with no difference between days 120 and 150. No statistically significant differences were detected between treatments. Cats had higher odds of increased angiogenesis score than dogs ($p < 0.001$), and a time-by-species interaction was significant ($p = 0.001$).

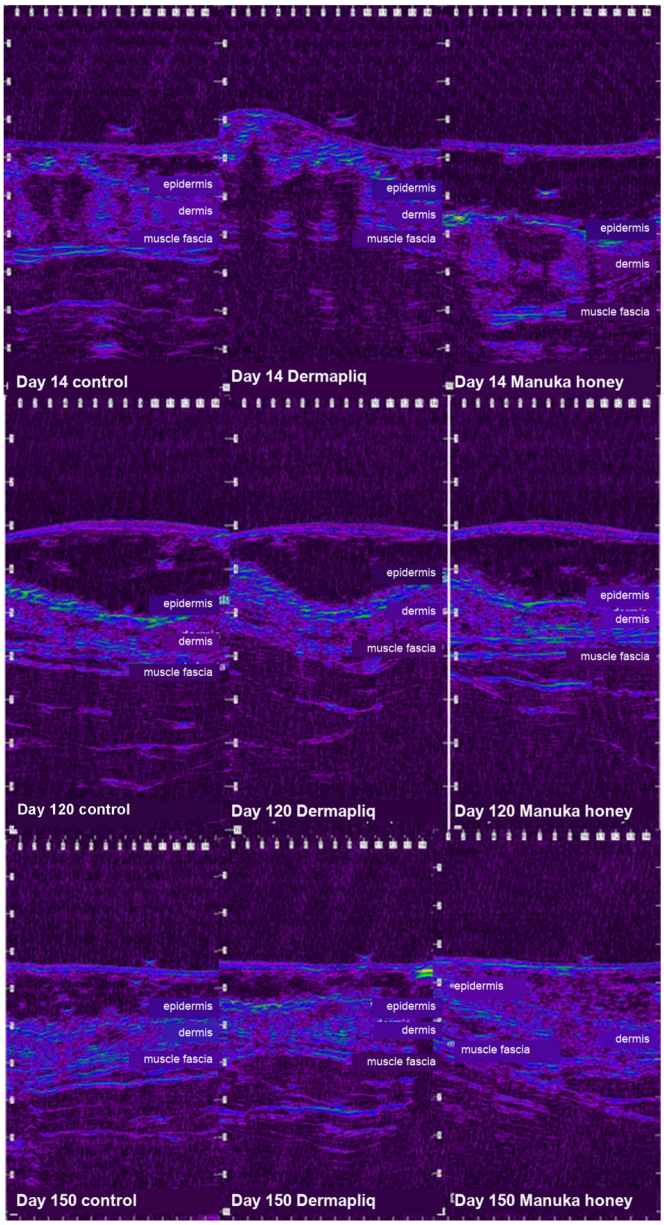

Figure 12. Representative ultrasonographic scans of the wound area in cat No. 8 at postoperative days 14, 120, and 150 for control, Dermapliq, and Manuka honey-treated wounds. Images were laterally compressed and displayed using a rainbow color palette to facilitate visualization. Scale bar in mm.

4. Discussion

The main finding of this study was that, although planimetry-derived total wound healing—the predefined primary endpoint—did not differ significantly among treatments, selected secondary endpoints indicated phase-specific treatment-associated differences. Therefore, the results should not be interpreted as demonstrating the overall superiority of either topical treatment. Instead, they suggest that Dermapliq and Manuka honey may influence different components of second-intention healing under controlled experimental conditions. Because the enrolled sample size was powered for the primary planimetric endpoint rather than for all secondary endpoints, subgroup comparisons, histological variables, or interaction terms, secondary findings should be considered exploratory. This is particularly relevant for histological outcomes, where some estimates showed wide confidence intervals, indicating limited precision and the possibility of type II error for non-significant comparisons.

This experimental model evaluated second-intention healing of standardized punch wounds in dogs and cats managed with three methods: no topical treatment (control), Manuka honey, and Dermapliq (an RGTA-based matrix). Overall, both topical interventions showed treatment-associated differences in selected secondary outcomes, but these findings should be interpreted in the context of the non-significant primary planimetric endpoint. Marked interspecies differences were also confirmed, with cats generally requiring longer to reach several clinical endpoints, while showing distinct time-dependent patterns in planimetric and ultrasonographic measures.

The present study should also be interpreted alongside our previous controlled trial evaluating the same topical agents (Dermapliq and Manuka honey) in dogs and cats undergoing first-intention incisional wound healing [66]. This distinction is biologically and clinically important and likely explains why some treatment effects differ between the two models despite the use of the same species and topical agents. Considered together, the two studies provide complementary information on the performance of Dermapliq and Manuka honey across different wound-healing contexts in small animals.

The translational value of this model lies in its ability to isolate species- and treatment-related differences under standardized conditions. By using uniform wound size, location, dressing protocol, and postoperative care, the model reduces the heterogeneity that characterizes naturally occurring wounds and allows direct comparison between dogs and cats and among treatments. However, this strength is also a limitation. The wounds were small, surgically created, clean, acute defects in healthy laboratory animals and were managed with intensive bandaging and daily care. Therefore, the results should be viewed as mechanistic and comparative rather than directly predictive of outcomes in large traumatic, contaminated, infected or chronic wounds, or wounds in animals with systemic disease.

Dogs exhibited a shorter mean time to first appearance of granulation tissue than cats, consistent with previous comparative studies of cutaneous second-intention healing [1–5,78–81]. In the present study, the mean time to first appearance of granulation tissue in dogs was approximately 2 days across all methods, whereas cats showed later onset (Supplementary Table S3).

Treatment effects were phase- and species-dependent. Manuka honey was associated with a significantly longer mean time to first granulation tissue compared with both control and Dermapliq, and a significant species-by-treatment interaction was detected. This finding is clinically relevant because it contrasts with the common expectation that honey, by providing antimicrobial activity and a moist environment, would accelerate early macroscopic granulation. A plausible explanation is that Manuka honey (which has high osmolarity, acidic pH, and methylglyoxal-related bioactivity) modifies the early wound microenvironment and exudate dynamics, such that clinically apparent granu-

lation tissue may become visible later without necessarily delaying subsequent healing milestones [34,35,42,82,83].

In contrast to the delayed coverage of the bottom of the wound with granulation tissue in untreated control wounds, both Dermapliq and Manuka shortened the time to complete granulation tissue coverage of the wound bed. This suggests that even if early macroscopic granulation onset is not accelerated, these products may support faster establishment and expansion of granulation tissue once proliferation is underway. Cats required longer than dogs to achieve complete wound-bed granulation coverage, in agreement with previous interspecies comparisons [2–5,84].

Mean time to wound filling with granulation tissue did not differ significantly among control, Dermapliq, and Manuka when adjusting for species. Although some studies have reported prolonged filling in untreated wounds depending on treatment type and study design, absence of between-group differences has also been documented in comparable experimental frameworks [13,17,18,85].

Dogs reached wound filling sooner than cats, consistent with reports that dogs tend to generate more abundant granulation tissue, often more centrally distributed compared with the peripherally located granulation tissue in cats [1,2,14,21].

Heparan sulphates (HSs) are glycosaminoglycans involved in forming the extracellular matrix and serve as reservoirs for growth factors, contributing to cellular homeostasis. Additionally, they aid in recruiting cells, mobilizing chemokines and creating a supportive local environment conducive to the implantation and growth of pluripotent cells [86]. However, HSs are rapidly broken down during tissue injury.

Dermapliq contains RGTA® (ReGeneraTing Agent) technology that mimics certain functions of heparan sulfates within the extracellular matrix and can protect matrix proteins and heparin-binding growth factors from proteolytic degradation [59,86,87]. While this mechanism could theoretically enhance granulation tissue deposition, the standardized nature of the punch-wound model and overall favorable healing conditions may have reduced the detectable impact on this particular endpoint.

In the context of skin wound healing, RGTAs have demonstrated the ability to enhance both the rate and quality of healing in preclinical studies [88–91]. In clinical applications, RGTAs have been used in patients with severe burn injuries [61], bedsores and ulcers [92] and ischemic skin wounds [61], showing notable improvements in the healing process.

Complete epithelial coverage occurred sooner in Dermapliq-treated wounds compared with both Manuka and untreated control, and Manuka also outperformed the control. The Dermapliq advantage is consistent with the proposed ability of RGTAs to improve the local healing milieu and support re-epithelialization, as reported in preclinical work and clinical applications, particularly in ocular surface disease and non-healing corneal lesions [58,59,93–97].

The Manuka benefit over control for complete epithelial coverage may relate to antimicrobial activity, maintenance of a moist wound environment, and acidification, which can support keratinocyte migration and reduce bioburden [34,35,42,82]. Differences from studies that reported no advantage of honey over control in cats may reflect variation in honey type, dressing management, scoring, and sample characteristics [38].

As expected, cats required longer to achieve complete epithelial coverage than dogs, consistent with the broader literature documenting slower clinical wound closure in cats [1–5,78–81].

Manuka-treated wounds were more likely to exhibit higher exudate quantity than Dermapliq or control (Supplementary Table S4). Manuka honey has antibacterial effects, promotes wound healing and offers a moist wound environment [34,35,42,82]. Clinically, a moist environment may facilitate autolytic debridement and epithelial cell migration;

however, excessive exudate can dilute or displace honey if dressing retention is suboptimal, potentially reducing bioactive contact time [1,98]. Therefore, practical success with honey dressings likely depends on appropriate secondary dressings and change frequency.

Cats had substantially higher odds of increased exudate quantity and higher exudate appearance scores than dogs. This contrasts with reports describing canine wounds as more exudative and more erythematous early after injury, potentially related to species differences in dermal vascularity [3–5]. These discrepancies may reflect differences in study design, scoring systems, wound location, or postoperative management, but they underline that exudate control can be a key practical challenge in feline wound care.

Exudate appearance scores were lower with Dermapliq than with control, which may reflect improved wound-bed quality and/or modulation of local inflammation [56,59,87,99]. Additionally, exudate appearance improved over postoperative time, as expected with progression beyond the inflammatory phase.

Unlike our previous first-intention incisional model, in which the main clinically detectable differences concerned scar-related variables (e.g., skin thickening/scar width) [68], the present open-wound model revealed treatment-specific effects on exudate and granulation kinetics, highlighting the stronger influence of topical agents on the proliferative phase of second-intention healing. In the surgically closed incisional model, Manuka honey did not significantly improve cosmetic outcomes versus controls and was associated with increased skin thickening (and a higher total clinical score), although ultrasonographic wound area was smaller than in controls. In contrast, the present open-wound model showed initially greater exudate and delayed first visible granulation, followed by faster wound-bed granulation coverage and improved epithelial coverage relative to controls. These differences likely reflect the distinct biology of open-wound repair, in which moisture balance, exudate handling, and granulation-bed dynamics have a greater influence on clinically detectable healing milestones.

Planimetric analysis did not detect significant differences in epithelialization rate between treatments after accounting for time and species (Supplementary Table S5). This apparent divergence from the time-to-event endpoint (complete epithelial coverage), where Dermapliq showed a clear advantage, is not unexpected: planimetry captures proportional changes between discrete time points, whereas time-to-event analyses can be more sensitive to small but consistent differences near full closure.

Interestingly, cats showed a higher epithelialization rate in the planimetric model, despite longer times to complete epithelial coverage and lower total wound-healing rates. This suggests that, in cats, surface epithelial advancement may not translate directly into faster overall closure, potentially due to differences in granulation tissue development, contraction dynamics, or remodeling quality. Across the literature, treatment effects on planimetric epithelialization are variable and often absent, supporting the idea that outcomes are highly dependent on wound type, protocol, and measurement approach [3–5,13–15,21,22,38].

Contraction rate did not differ among treatments, and no clear species main effect was detected, contrasting with earlier findings of greater contraction in dogs [4]. Time had a strong effect, and the significant species-by-time interaction indicates different contraction rates between dogs and cats. Because contraction is closely linked to the formation of granulation tissue, which serves as a scaffold for myofibroblast function and epithelial migration, the absence of treatment differences is consistent with the lack of differences in time to wound filling with granulation tissue [2,80].

In the applied planimetric model, total wound healing did not differ among treatment groups, but cats had a significantly reduced healing rate compared with dogs, consistent with previous studies (Supplementary Table S6) [3–5]. These findings emphasize that different endpoints capture different dimensions of healing: clinically meaningful benefits

may manifest as earlier achievement of key milestones (e.g., complete epithelial coverage) or improved tissue quality rather than as a uniformly higher overall rate of surface area reduction.

Serial ultrasonographic monitoring provided an objective quantitative assessment of wound healing and supported a treatment effect favoring Dermapliq over control in the overall model (Supplementary Table S7). The reduction in ultrasonographic wound area in the Dermapliq group compared with the control suggests a treatment-associated difference in deeper wound-area dynamics, although its clinical relevance requires further evaluation. In contrast, differences between Dermapliq and Manuka and between Manuka and control were not statistically significant in the overall model. Interval-based analyses suggested more favorable wound-area patterns for both topical treatments during some healing periods, but these findings should be interpreted cautiously. The significant time effect reflects the expected progressive reduction in wound size with advancing healing stages and is in agreement with prior investigations employing serial ultrasonographic assessment of incisional or experimental wounds in dogs [66,68–71].

Interval-based analyses also showed more favorable ultrasonographic wound-area patterns for Dermapliq and Manuka than for control during early postoperative periods (days 0–17), when modulation of inflammation and support of early proliferative events, including fibroplasia, collagen deposition, and angiogenesis, may influence tissue repair. These findings are consistent with prior reports in which ultrasonography was used to monitor experimental wound healing and with proposed regenerative mechanisms for biologically active matrices and honey-based dressings [66,70,71].

Species-related USG patterns were time-dependent: cats showed smaller ultrasonographic wound areas early (days 0–17), whereas dogs showed more favorable trends later (days 36–150). This may reflect differences in early inflammatory responses versus later remodeling and matrix organization and could help explain why cats may exhibit favorable early imaging metrics yet still require longer to achieve complete clinical closure. Similar interspecies differences have been noted in previous experimental and clinical wound-healing studies [66,70,71].

Overall, ultrasonographic evaluation supported a treatment effect favoring Dermapliq over control in the overall model, while interval-based analyses suggested more favorable wound-area patterns for both topical treatments during some healing periods. These findings provide additional evidence that ultrasonographic monitoring can detect treatment-related differences during secondary-intention healing that may not be fully reflected by surface measurements alone. However, the clinical relevance of these imaging findings should be interpreted cautiously and warrants further evaluation in naturally occurring wounds.

No significant differences in edema scores were detected among treatments, while dogs were more likely to exhibit higher edema scores than cats. This suggests that, in this model, edema may be driven primarily by species-related intrinsic factors (e.g., vascular responses and dermal microanatomy) rather than topical treatment. Similar lack of treatment effects has been reported in studies using other dressings and protocols [13,14,17,38], although edema commonly decreases with time irrespective of group assignment [21].

Inflammation scores were markedly higher at day 12 than at days 120 and 150, consistent with the expected transition from the proliferative to the remodeling phase. No differences among treatments were detected, while cats were more likely to have higher inflammation scores than dogs. Although some studies have reported reduced inflammatory cell infiltrates with Manuka honey at earlier time points, direct comparison is limited by differences in timing, wound type, and histological scoring [13,21,22,38,84].

Fibroblast scores peaked at day 12 and declined substantially by days 120 and 150, reflecting the normal course of fibroplasia followed by maturation and remodeling. Fibrob-

last proliferation and differentiation are driven by macrophages, cytokines, growth factors, and local wound conditions and play a major role in collagen and elastin synthesis [2,80].

Cats showed higher fibroblast scores independent of treatment and time. This is noteworthy given that feline wounds may show delayed appearance of differentiated fibroblasts/myofibroblasts, but once contraction begins, the process may progress rapidly [3,4,81,100]. No treatment differences were detected, aligning with the planimetric contraction results.

Angiogenesis scores were higher at day 12 than at days 120 and 150, consistent with active granulation tissue formation early in healing. No treatment effects were detected, while cats were more likely to have higher angiogenesis scores than dogs. Interpretation should be cautious because baseline dermal vascular architecture differs between species, with dogs reported to have a higher density of tertiary and higher-order cutaneous vessels, particularly on the trunk [5,78,81]. Histological angiogenesis scoring likely reflects phase-dependent neovascularization within granulation tissue rather than baseline vascular density.

Although increased angiogenesis with honey or other interventions has been reported in some studies, differences in timing and models may explain why no between-treatment differences were detected here [21,48,49,84].

Histologic comparison with our previous first-intention study further supports the identified species-related differences [66]. In both studies, species-related differences were evident, and some patterns were directionally similar, particularly the tendency for cats to show higher inflammation and angiogenesis scores and lower edema than dogs. At the same time, the histologic profiles were not identical across all parameters, which is unsurprising given the different wound architectures (apposed incisions versus open wounds), the differing contribution of granulation tissue to repair, and differences in how healing phases are expressed and sampled over time in the two models. Thus, the repeated identification of species effects across both studies strengthens the conclusion that canine and feline wound healing should be evaluated separately, while the between-study differences highlight the importance of healing mode when interpreting histologic findings.

The absence of significant treatment-related histological differences does not necessarily indicate that the clinical differences were merely superficial. Histology was assessed at selected biopsy time points and using ordinal semi-quantitative scores, whereas clinical and ultrasonographic endpoints were measured serially and may have been more sensitive to dynamic changes in wound progression. Nevertheless, the lack of histological confirmation indicates that the observed treatment-associated clinical differences should be interpreted cautiously and cannot be assumed to represent superior structural tissue quality. Future studies incorporating collagen organization, collagen type I/III ratio, tensile strength, immunohistochemistry, and molecular markers of inflammation and remodeling would be needed to determine whether these clinical differences correspond to deeper structural or functional benefits.

Limitations and future directions:

The limitations of the study include the use of standardized experimental punch wounds (which may not fully represent the heterogeneity of clinical wounds), the fact that different outcome domains (clinical, planimetric, ultrasonographic, histological) capture partially distinct biological processes, and potential residual within-animal correlation despite statistical adjustment. Some clinical scores (e.g., exudate appearance) are also inherently semi-quantitative and may introduce observer-related variability. Because wound fluid quantity and appearance were evaluated using a semi-quantitative scale rather than a fully validated multidimensional wound score, these results should be interpreted as supportive secondary clinical observations. Although comparison with our previous

first-intention trial is valuable because the same species and topical agents were evaluated, direct cross-study inference should be made cautiously due to differences in wound model (sutured incisions versus open punch wounds), clinical endpoint structure, and the relative biological contribution of granulation tissue, contraction, and exudate to the healing process.

The use of systemic antimicrobials is an additional limitation. Although the duration was short and intended to reduce infection-related confounding in an experimental open-wound model, antimicrobial administration may have influenced the wound microbiological environment and may reduce extrapolation to clinical wounds managed without antibiotics. In line with antimicrobial stewardship principles, future studies should evaluate similar topical protocols with microbiological monitoring and without routine systemic antimicrobials where ethically and clinically appropriate.

Although the enrolled sample size provided adequate estimated statistical power for the primary planimetry-derived endpoint under the a priori assumptions, this does not imply equivalent power for secondary endpoints, histological variables, subgroup comparisons, or species-by-treatment interaction terms. Therefore, secondary endpoint analyses, particularly histological scores and interaction analyses, should be interpreted as exploratory, and type II error cannot be excluded for non-significant treatment comparisons. The within-animal design improved comparability by reducing interindividual variability and was consistent with the 3R principles by allowing direct comparison of treatments while limiting the number of animals required. However, this design also means that wounds within the same animal were not fully independent, because systemic biological responses to wounding, inflammation, analgesia, antimicrobials, or topical treatments could theoretically influence all wounds within that individual. Thus, the model is best interpreted as assessing relative local wound responses under shared systemic conditions, rather than fully independent treatment responses. This issue was partly addressed statistically by accounting for clustering within animals, but it remains an inherent limitation of within-animal wound-healing designs.

Future studies should evaluate these products in clinical populations with larger, contaminated, or chronic wounds; compare different application protocols (dressing retention and change frequency, especially for honey); and incorporate objective measures of scar quality and tissue function (e.g., tensile strength, collagen organization, and type I/III balance) alongside time-to-closure endpoints.

5. Conclusions

In this standardized experimental model of second-intention healing in dogs and cats, the primary endpoint, planimetry-derived total wound healing, did not differ significantly among untreated control, Dermapliq, and Manuka honey-treated wounds. Nevertheless, selected secondary endpoints suggested phase-specific treatment-associated differences. Dermapliq was associated with earlier complete epithelial coverage and a smaller ultrasonographic wound area compared with control, whereas Manuka honey was associated with faster complete granulation coverage but increased exudate quantity. Cats generally required longer than dogs to reach several clinical healing endpoints, confirming relevant interspecies differences. Because the model used small, clean, acute wounds in healthy laboratory animals under intensive postoperative care, these findings should be considered controlled comparative data rather than direct evidence of clinical efficacy in large, contaminated, infected, chronic, or otherwise compromised wounds. Further clinical studies are required before broad treatment recommendations can be made.

Supplementary Materials: The following supporting information can be downloaded at: https://www.mdpi.com/article/10.3390/pets3020023/s1, Table S1: Animals; Table S2: Study design and sample allocation; Table S3: Clinical evaluation variables (first appearance of granulation tissue, complete coverage by granulation tissue, wound filling with granulation tissue, complete epithelial coverage) by species and method; Table S4: Quantity of fluid (0–3) and fluid appearance (0–4) scores by species and treatment; Table S5: Planimetry variables (epithelialization, contraction, total wound healing) by species and method; Table S6: Planimetry variables (epithelialization, contraction, total wound healing) by species; Table S7: Ultrasonographic wound area (mm^2) by species and treatment.

Author Contributions: Conceptualization, V.T. and P.G.G.; methodology, V.T., A.D.G. and P.G.G.; validation, D.D., V.T. and E.F.; formal analysis, V.S.; investigation, T.Z., D.D., V.T., P.G.G., E.D., S.G.G., E.F. and C.M.; resources, A.D.G., V.T. and P.G.G.; data curation, T.Z.; writing—original draft preparation, T.Z.; writing—review and editing, V.T., A.D.G., P.G.G., E.F., V.S. and D.D.; visualization, T.Z., and V.S.; supervision, V.T.; project administration, V.T., P.G.G. and A.D.G. All authors have read and agreed to the published version of the manuscript.

Funding: This research received no external funding.

Institutional Review Board Statement: All procedures were approved by the National Animal Ethics Committee, in accordance with the European Union directive 2010/63/EU, and by the Animal Ethics Committee of the Faculty of Veterinary Science, University of Thessaly (license numbers:1118/45307 21.3.2017, 411/9.1.2020, 32/15.9.2016, 88/5.12.2019).

Informed Consent Statement: Not applicable.

Data Availability Statement: The data presented in this study are included in the main article and the Supplementary Materials. Further inquiries can be directed to the corresponding author.

Acknowledgments: The authors would also like to thank Elanco Hellas S.A. and Pet Health, Greece, for providing some of the products used in the study. In addition, the authors are grateful to Longport INC. High-Resolution Ultrasound company, for the provision of the specialized ultrasound instrumentation to the Clinic of Surgery and the continuing support.

Conflicts of Interest: The authors declare no conflicts of interest.

Abbreviations

The following abbreviations are used in this manuscript:

ECM	Extracellular matrix
RGTA	ReGeneraTing Agents
HSs	Heparan sulfates
HBGFs	Heparin-binding growth factors
USG	Ultrasonographic evaluation
IV	Intravenously
IM	Intramuscularly
SC	Subcutaneously

References

1. Balsa, I.M.; Culp, W.T. Wound Care. *Vet. Clin. N. Am. Small Anim. Pract.* **2015**, *45*, 1049–1065. [CrossRef]
2. Buote, N.J. Updates in Wound Management and Dressings. *Vet. Clin. Small Anim.* **2022**, *52*, 289–315. [CrossRef]
3. Bohling, M.W.; Henderson, R.A.; Swaim, S.F.; Kincaid, S.A.; Wright, J.C. Cutaneous wound healing in the cat: A macroscopic description and comparison with cutaneous wound healing in the dog. *Vet. Surg.* **2004**, *33*, 579–587. [CrossRef]
4. Bohling, M.W.; Henderson, R.A. Differences in cutaneous wound healing between dogs and cats. *Vet. Clin. N. Am. Small Anim. Pract.* **2006**, *36*, 687–692. [CrossRef]
5. Bohling, M.W.; Henderson, R.A.; Swaim, S.F.; Kincaid, S.A.; Wright, J.C. Comparison of the role of the subcutaneous tissues in cutaneous wound healing in the dog and cat. *Vet. Surg.* **2006**, *35*, 3–14. [CrossRef] [PubMed]
6. Devriendt, N.; de Rooster, H. Initial Management of Traumatic Wounds. *Vet. Clin. N. Am. Small Anim. Pract.* **2017**, *47*, 1123–1134. [CrossRef]

7. Lusby, P.E.; Coombes, A.L.; Wilkinson, J.M. A Comparison of Wound Healing Following Treatment with *Lavandula* × *allardii* Honey or Essential Oil. *Phytother. Res.* **2006**, *20*, 755–757. [CrossRef]
8. Tanideh, N.; Abdordideh, E.; Yousefabad, S.L.A.; Daneshi, S.; Hosseinabadi, O.K.; Samani, S.M.; Derakhshan far, A. Evaluation of the Healing Effect of Honey and Colostrum in Treatment of Cutaneous Wound in Rat. *Comp. Clin. Pathol.* **2017**, *26*, 71–77. [CrossRef]
9. Paydar, S.; Ziaeian, B.; Dehghanian, A.; Heidarpour, M.; Alavi Moghadam, R.; Dalfardi, B.; Karladani, A.H. A Comparison of the Effects of Topical Prolavacid Solution (a Polyhexamethylene Biguanide-Based Wound Cleanser) and Medihoney Ointment in a Rat Model of Cutaneous Wound. *Adv. Wound Care* **2017**, *6*, 407–412. [CrossRef] [PubMed]
10. Dart, A.J.; Dowling, B.A.; Smith, C.L. Topical treatments in equine wound management. *Vet. Clin. N. Am. Equine Pract.* **2005**, *21*, 77-vii. [CrossRef]
11. Bischofberger, A.S.; Dart, C.M.; Horadagoda, N.; Perkins, N.R.; Jeffcott, L.B.; Little, C.B.; Dart, A.J. Effect of Manuka Honey Gel on the Transforming Growth Factor B1 and B3 Concentrations, Bacterial Counts and Histomorphology of Contaminated Full-Thickness Skin Wounds in Equine Distal Limbs. *Aust. Vet. J.* **2016**, *94*, 27–34. [CrossRef] [PubMed]
12. Helal, I.E.; Al-Abbadi, H.A.; El-Daharawy, M.H.; Ahmed, M.F. Enhancement of chronic wound healing with maltodextrin/ascorbic acid gel: A clinical evaluation of distal limb wounds in horses. *J. Anim. Sci. Technol.* **2022**, *64*, 997–1007. [CrossRef] [PubMed]
13. Tsioli, V.; Gouletsou, P.G.; Galatos, A.D.; Psalla, D.; Lymperis, A.; Papazoglou, L.G.; Karayannopoulou, M. Effects of two occlusive, hydrocolloid dressings on healing of full-thickness skin wounds in cats. *Vet. Comp. Orthop. Traumatol.* **2016**, *29*, 298–305. [CrossRef] [PubMed]
14. Tsioli, V.; Gouletsou, P.G.; Galatos, A.D.; Psalla, D.; Lymperis, A.; Sideri, A.I.; Papazoglou, L.G. The Effect of a Hydrocolloid Dressing on Second Intention Wound Healing in Cats. *J. Am. Anim. Hosp. Assoc.* **2018**, *54*, 125–131. [CrossRef]
15. Lukanc, B.; Potokar, T.I.; Erjavec, V. Observational study of the effect of L-Mesitran® medical honey on wound healing in cats. *Vet. Arh.* **2018**, *88*, 59–74. [CrossRef]
16. Lukanc, B.; Potokar, T.; Erjavec, V. Complete skin regeneration with medical honey after skin loss on the entire circumference of a leg in a cat. *J. Tissue Viability* **2020**, *29*, 148–152. [CrossRef]
17. Angelou, V.; Psalla, D.; Dovas, I.C.; Kazakos, G.M.; Marouda, C.; Chatzimisios, K.; Kyrana, Z.; Moutou, E.; Karayannopoulou, M.; Papazoglou, L.G. Locally Injected Autologous Platelet-Rich Plasma Improves Cutaneous Wound Healing in Cats. *Animals* **2022**, *12*, 1993. [CrossRef]
18. Swaim, S.F.; Gillette, R.L.; Sartin, E.A.; Hinkle, S.H.; Coolman, S.L. Effects of a hydrolyzed collagen dressing on the healing of open wounds in dogs. *Am. J. Vet. Res.* **2000**, *61*, 1574–1578. [CrossRef]
19. Winkler, J.T.; Swaim, S.F.; Sartin, E.A.; Henderson, R.A.; Welch, J.A. The Effect of a Porcine-Derived Small Intestinal Submucosa Product on Wounds with Exposed Bone in Dogs. *Vet. Surg.* **2002**, *31*, 541–551. [CrossRef]
20. Karayannopoulou, M.; Loukopoulos, P.; Papazoglou, L.G.; Tsioli, V.; Anagnostou, T.L.; Assaloumidis, N.; Constantinidis, T.C.; Assimopoulou, A.N.; Kaldrymidou, E.; Papageorgiou, V.P. Naturally occurring isohexenylnaphthazarins and wound healing: Experimental study in dogs. *J. Cutan. Med. Surg.* **2010**, *14*, 62–70. [CrossRef]
21. Karayannopoulou, M.; Tsioli, V.; Loukopoulos, P.; Anagnostou, T.L.; Giannakas, N.; Savvas, I.; Papazoglou, L.G.; Kaldrymidou, E. Evaluation of the effectiveness of an ointment based on Alkannins/ Shikonins on second intention wound healing in the dog. *Can. J. Vet. Res.* **2011**, *75*, 42–48. [PubMed Central]
22. Karayannopoulou, M.; Psalla, D.; Kazakos, G.; Loukopoulos, P.; Giannakas, N.; Savvas, I.; Kritsepi-Konstantinou, M.; Chantes, A.; Papazoglou, L.G. Effect of locally injected autologous platelet-rich plasma on second intention wound healing of acute full-thickness skin defects in dogs. *Vet. Comp. Orthop. Traumatol.* **2015**, *28*, 172–178. [CrossRef] [PubMed]
23. Bonomo, R.A.; Van Zile, P.S.; Li, Q.; Shermock, K.M.; McCormick, W.G.; Kohut, B. Topical Triple-antibiotic Ointment as a Novel Therapeutic Choice in Wound Management and Infection Prevention: A Practical Perspective. *Expert Rev. Anti Infect. Ther.* **2007**, *5*, 773–782. [CrossRef]
24. Fonder, M.A.; Lazarus, G.S.; Cowan, D.A.; Aronson-Cook, B.; Kohli, A.R.; Mamelak, A.J. Treating the Chronic Wound: A Practical Approach to the Care of Nonhealing Wounds and Wound Care Dressings. *J. Am. Acad. Dermatol.* **2008**, *58*, 185–206. [CrossRef] [PubMed]
25. Rüttermann, M.; Maier-Hasselmann, A.; Nink-Grebe, B.; Burckhardt, M. Lokal therapie Chronischer Wunden. *Dtsch. Arztebl. Int.* **2013**, *110*, 25–31. [CrossRef] [PubMed]
26. Powers, J.G.; Higham, C.; Broussard, K.; Phillips, T.J. Wound Healing and Treating Wounds Chronic Wound Care and Management. *J. Am. Acad. Dermatol.* **2016**, *74*, 607–625. [CrossRef]
27. Namias, N. Honey in the Management of Infections. *Surg. Infect.* **2003**, *4*, 219–226. [CrossRef]
28. Mandal, M.D.; Mandal, S. Honey: Its Medicinal Property and Antibacterial Activity. *Asian Pac. J. Trop. Biomed.* **2011**, *1*, 154–160. [CrossRef]
29. Biglari, B.; Vd Linden, P.H.; Simon, A.; Aytac, S.; Gerner, H.J.; Moghaddam, A. Use of Medihoney as a Non-Surgical Therapy for Chronic Pressure Ulcers in Patients with Spinal Cord Injury. *Spinal Cord* **2012**, *50*, 165–169. [CrossRef]

30. Maleki, H.; Gharehaghaji, A.A.; Dijkstra, P.J. A Novel Honey-Based Nanofibrous Scaffold for Wound Dressing Application. *J. Appl. Polym. Sci.* **2013**, *127*, 4086–4092. [CrossRef]
31. Majtan, J.; Bohova, J.; Garcia-Villalba, R.; Tomas-Barberan, F.A.; Madakova, Z.; Majtan, T.; Majtan, V.; Klaudiny, J. Fir Honeydew Honey Flavonoids Inhibit TNF-α-Induced MMP-9 Expression in Human Keratinocytes: A New Action of Honey in Wound Healing. *Arch. Dermatol. Res.* **2013**, *305*, 619–627. [CrossRef]
32. Mayer, A.; Slezak, V.; Takac, P.; Olejnik, J.; Majtan, J. Treatment of Non-Healing Leg Ulcers with Honeydew Honey. *J. Tissue Viability* **2014**, *23*, 94–97. [CrossRef]
33. Labban, L. Honey as a Promising Treatment for Diabetic Foot Ulcers (DFU). *J. Med. Soc.* **2014**, *28*, 64–68. [CrossRef]
34. Oryan, A.; Alemzadeh, E.; Moshiri, A. Biological Properties and Therapeutic Activities of Honey in Wound Healing: A Narrative Review and Meta-Analysis. *J. Tissue Viability* **2016**, *25*, 98–118. [CrossRef]
35. Saikaly, S.K.; Khachemoune, A. Honey and Wound Healing: An Update. *Am. J. Clin. Dermatol.* **2017**, *18*, 237–251. [CrossRef]
36. Abu-Seida, A.M. Effect of Propolis on Experimental Cutaneous Wound Healing in Dogs. *Vet. Med. Int.* **2015**, *2015*, 672643. [CrossRef] [PubMed]
37. Repellin, R.L.; Pitt, K.A.; Lu, M.; Welker, J.; Noland, E.L.; Stanley, B.J. The effects of a proprietary Manuka honey and essential oil hydrogel on the healing of acute full-thickness wounds in dogs. *Vet. Surg.* **2021**, *50*, 1634–1643. [CrossRef] [PubMed]
38. Chatzimisios, K.; Tsioli, V.; Dovas, C.; Kazakos, G.; Moutou, E.; Angelou, V.; Pratsinakis, E.; Papazoglou, L. The effect of medical-grade honey or hypericum on matrix metalloproteinases expression in feline wound healing. *J. Hell. Vet. Med. Soc.* **2024**, *75*, 6879–6886.
39. Bergman, A.; Yanai, J.; Weiss, J.; Weiss, J.; Bell, D.; David, M.P. Acceleration of Wound Healing by Topical Application of Honey: An Animal Model. *Am. J. Surg.* **1983**, *145*, 374–376. [CrossRef]
40. Iftikhar, F.; Arshad, M.; Rasheed, F.; Amraiz, D.; Anwar, P.; Gulfraz, M. Effects of Acacia Honey on Wound Healing in Various Rat Models Effects of Acacia Honey on Wound Healing in Various Rat Models. *Phytother. Res.* **2010**, *24*, 583–586. [CrossRef]
41. Patel, S.; Cichello, S. Manuka Honey: An Emerging Natural Food with Medicinal Use. *Nat. Prod. Bioprospect.* **2013**, *3*, 121–128. [CrossRef]
42. Scagnelli, A.M. Therapeutic review: Manuka honey. *J. Exot. Pet Med.* **2016**, *25*, 168–171. [CrossRef]
43. Ogwu, M.C.; Izah, S.C. Honey as a Natural Antimicrobial. *Antibiotics* **2025**, *14*, 255. [CrossRef] [PubMed]
44. Jodidio, M.; Schwartz, R.A. Honey therapies for dermatological disorders: More than just a sweet elixir. *Int. J. Dermatol.* **2024**, *63*, 422–430. [CrossRef]
45. Cooper, R.; Molan, P.; Krishnamoorthy, L.; Harding, K. Manuka Honey Used to Heal a Recalcitrant Surgical Wound. *Eur. J. Clin. Microbiol. Infect. Dis.* **2001**, *20*, 758–759. [CrossRef]
46. Visavadia, B.G.; Honeysett, J.; Danford, M.H. Manuka Honey Dressing: An Effective Treatment for Chronic Wound Infections. *Br. J. Oral Maxillofac. Surg.* **2008**, *46*, 55–56. [CrossRef] [PubMed]
47. Kamaratos, A.V.; Tzirogiannis, K.N.; Iraklianou, S.A.; Panoutsopoulos, G.I.; Kanellos, I.E.; Melidonis, A.I. Manuka honey-impregnated dressings in the treatment of neuropathic diabetic foot ulcers. *Int. Wound J.* **2014**, *11*, 259–263. [CrossRef]
48. Bischofberger, A.S.; Dart, C.M.; Perkins, N.R.; Dart, A.J. A preliminary study on the effect of manuka honey on second-intention healing of contaminated wounds on the distal aspect of the forelimbs of horses. *Vet. Surg.* **2011**, *40*, 898–902. [CrossRef]
49. Bischofberger, A.S.; Dart, C.M.; Perkins, N.R.; Kelly, A.; Jeffcott, L.; Dart, A.J. The effect of short- and long-term treatment with manuka honey on second intention healing of contaminated and noncontaminated wounds on the distal aspect of the forelimbs in horses. *Vet. Surg.* **2013**, *42*, 154–160. [CrossRef] [PubMed]
50. Tambella, A.M.; Attili, A.R.; Dini, F.; Palumbo Piccionello, A.; Vullo, C.; Serri, E.; Scrollavezza, P.; Dupre, G. Autologous platelet gel to treat chronic decubital ulcers: A randomized, blind controlled clinical trial in dogs. *Vet. Surg.* **2014**, *43*, 726–733. [CrossRef]
51. Farghali, H.A.; AbdElKader, N.A.; Khattab, M.S.; AbuBakr, H.O. Evaluation of subcutaneous infiltration of autologous platelet-rich plasma on skin-wound healing in dogs. *Biosci. Rep.* **2017**, *37*, BSR20160503. [CrossRef] [PubMed]
52. Iacopetti, I.; Patruno, M.; Melotti, L.; Martinello, T.; Bedin, S.; Badon, T.; Righetto, E.M.; Perazzi, A. Autologous Platelet-Rich Plasma Enhances the Healing of Large Cutaneous Wounds in Dogs. *Front. Vet. Sci.* **2020**, *7*, 575449. [CrossRef]
53. Cortese, L.; Christopherson, P.W.; Pelagalli, A. Platelet Function and Therapeutic Applications in Dogs: Current Status and Future Prospects. *Animals* **2020**, *10*, 201. [CrossRef] [PubMed]
54. Sharun, K.; Jambagi, K.; Dhama, K.; Kumar, R.; Pawde, A.M.; Amarpal. Therapeutic Potential of Platelet-Rich Plasma in Canine Medicine. *Arch. Razi Inst.* **2021**, *76*, 721–730. [CrossRef] [PubMed]
55. Mulder, G.; Wallin, K.; Tenenhaus, M. Regenerative Materials That Facilitate Wound Healing. *Clin. Plast. Surg.* **2012**, *39*, 249–267. [CrossRef]
56. Volk, S.W.; Iqbal, S.A.; Bayat, A. Interactions of the Extracellular Matrix and Progenitor Cells in Cutaneous Wound Healing. *Adv. Wound Care* **2013**, *2*, 261–272. [CrossRef]
57. Rasouli, M.; Rahimi, A.; Soleimani, M.; Heidari Keshel, S. The Interplay between Extracellular Matrix and Progenitor/Stem Cells during Wound Healing: Opportunities and Future Directions. *Acta Histochem.* **2021**, *123*, 151785. [CrossRef]

58. Martinez, J.M.; Chiappini, F.; Barritault, D. Case Reports for Topical Treatment of Corneal Ulcers. *Vet. Sci.* **2019**, *6*, 103. [CrossRef]
59. Barritault, D.; Desgranges, P.; Meddahi-Pelle, A.; Denoix, J.-M.; Saffar, J.-L. RGTA®-based matrix therapy—A new branch of regenerative medicine in locomotion. *Jt. Bone Spine* **2017**, *84*, 283–292. [CrossRef]
60. Gould, L.J. Topical Collagen-Based Biomaterials for Chronic Wounds: Rationale and Clinical Application. *Adv. Wound Care* **2015**, *5*, 19–31. [CrossRef]
61. Ahmad, R.S.; Barritault, D. ReGeneraTing Agents (RGTA®): A New Option for Healing and Improving Treatment Outcomes for Traumatic and Burn Injuries of the Hand. *Clin. Case Rep.* **2019**, *7*, 619–625. [CrossRef]
62. Ahmad, R.S.; Barritault, D. ReGeneraTing Agents (RGTA®) are a new option to improve amputation outcomes in the recovery of severe hand injuries. *Clin. Case Rep.* **2018**, *6*, 2061–2069. [CrossRef]
63. Aragosa, F.; Fatone, G.; Caterino, C.; Cavalli, S.; Piscitelli, A.; Vallefuoco, R.; Lamagna, F.; Della Valle, G. Evaluation of the Effects of Autologous Leukocyte- and Platelet-Rich Fibrin Membranes for Treating Chronic Wounds: A Prospective Study. *Animals* **2025**, *15*, 112. [CrossRef]
64. Hussein, K.H.; Motiea, E.; Hussein, M.T. Efficacy of xenogeneic fresh and lyophilized amniotic membranes on the healing of experimentally induced full-thickness skin wounds in dogs. *Sci. Rep.* **2025**, *15*, 15605. [CrossRef]
65. Pitt, K.A.; Stanley, B.J. Negative pressure wound therapy: Experience in 45 dogs. *Vet. Surg.* **2014**, *43*, 380–387. [CrossRef] [PubMed]
66. Gouletsou, P.G.; Zacharopoulou, T.; Skampardonis, V.; Georgiou, S.G.; Doukas, D.; Galatos, A.D.; Flouraki, E.; Dermisiadou, E.; Margeti, C.; Barbagianni, M.; et al. First-Intention Incisional Wound Healing in Dogs and Cats: A Controlled Trial of Dermapliq and Manuka Honey. *Vet. Sci.* **2024**, *11*, 64. [CrossRef] [PubMed]
67. Harris, C.; Bates-Jensen, B.; Parslow, N.; Raizman, R.; Singh, M.; Ketchen, R. Bates-Jensen wound assessment tool: Pictorial guide validation project. *J. Wound Ostomy Cont. Nurs.* **2010**, *37*, 253–259. [CrossRef]
68. Mantis, P.; Lloyd, D.H.; Pfeiffer, D.; Stevens, K.; Auxilia, S.; Noli, C.; Abramo, F. High-resolution ultrasonography of experimentally induced full-thickness canine skin wounds: Efficacy in imaging canine skin and comparison of 2 methods of measuring wound size. *Wounds* **2005**, *17*, 107–113.
69. Mantis, P.; Lloyd, D.H.; Pfeiffer, D.; Stevens, K.; Auxilia, S.; Noli, C.; Auxilia, S.; Noli, C.; Abramo, F.; Miolo, A. Assessment of the Effect of an Aliamide-containing Topical Gel by Evaluation of the Reduction of Wound Volume Measured by High R. *Wounds* **2007**, *19*, 113–119. [PubMed]
70. Balomenos, D.B.; Gouletsou, P.G.; Galatos, A.D. Comparison of Absorbable and Nonabsorbable Sutures for Intradermal Skin Closure in Dogs. *Vet. Sci.* **2023**, *10*, 105. [CrossRef] [PubMed]
71. Balomenos, D.B.; Gouletsou, P.G.; Galatos, A.D. Evaluation of Incisional Wound Healing in Dogs after Closure with Staples or Tissue Glue and Comparison to Intradermal Suture Pattern. *Animals* **2023**, *13*, 426. [CrossRef]
72. Gillette, R.L.; Swaim, S.F.; Sartin, E.A.; Bradley, D.M.; Coolman, S.L. Effects of a bioactive glass on healing of closed skin wounds in dogs. *Am. J. Vet. Res.* **2001**, *62*, 1149–1153. [CrossRef] [PubMed]
73. Rabe-Hesketh, S.; Skrondal, A. *Multilevel and Longitudinal Modeling Using Stata*, 2nd ed.; Stata Press Publication, StataCorp+: College Staton, TX, USA, 2008; pp. 433–442.
74. Gutierrez, R.G. Parametric frailty and shared frailty survival models. *Stata J.* **2002**, *2*, 22–44. [CrossRef]
75. Meadows, C.; Rajala-Schultz, P.J.; Frazer, G.S.; Phillips, G.; Meiring, R.W.; Hoblet, K.H. Evaluation of a contract breeding management program in selected Ohio dairy herds with event-time analysis II. Parametric frailty models. *Prev. Vet. Med.* **2007**, *80*, 89–102. [CrossRef] [PubMed]
76. Klein, J.P.; Moeschberger, M.L. *Survival Analysis: Techniques for Censored and Truncated Data*, 2nd ed.; Springer: New York, NY, USA, 2003; p. 536.
77. Parente, P.M.D.C.; Santos Silva, J.M.C. Quantile Regression with Clustered Data. *J. Econ. Methods* **2016**, *5*, 1–15. [CrossRef]
78. Taylor, G.I.; Minabe, T. The angiosomes of the mammals and other vertebrates. *Plast. Reconstr. Surg.* **1992**, *89*, 181–215. [CrossRef]
79. Affolter, V.K.; Moore, P.F. Histologic features of normal canine and feline skin. *Clin. Dermatol.* **1994**, *12*, 491–497. [CrossRef]
80. Lux, C.N. Wound healing in animals: A review of physiology and clinical evaluation. *Vet. Dermatol.* **2022**, *33*, 91-e27. [CrossRef]
81. Perc, B.; Erjavec, V. Overview of wound healing differences between dogs and cats. *Proc. Socrat. Lect.* **2022**, *7*, 167–171. [CrossRef]
82. Vallianou, N.G.; Gounari, P.; Skourtis, A.; Panagos, J.; Kazazis, C. Honey and its Anti-Inflammatory, Anti-Bacterial and Anti-Oxidant Properties. *Gen. Med. Open* **2014**, *2*, 132. [CrossRef]
83. Johnston, M.; McBride, M.; Dahiya, D.; Owusu-Apenten, R.; Singh Nigam, P. Antibacterial activity of Manuka honey and its components: An overview. *AIMS Microbiol.* **2018**, *4*, 655–664. [CrossRef]
84. Zhang, S.; Tan, H.; Cheng, X.; Dou, X.; Fang, H.; Zhang, C.; Yang, G.; Yang, H.; Zhao, Y.; Feng, T.; et al. Autologous platelet-rich fibrin enhances skin wound healing in a feline trauma model. *BMC Vet. Res.* **2024**, *20*, 504. [CrossRef]
85. Choi, C.; Linder, T.; Kirby, A.; Rosenkrantz, W.; Mueller, M. Use of a tilapia skin xenograft for management of a large bite wound in a dog. *Can. Vet. J.* **2021**, *62*, 1071–1076. [PubMed] [PubMed Central]

86. Zakine, G.; Le Louarn, C. First applications of matrix therapy in plastic and aesthetic surgery. *Ann. Chir. Plast. Esthet.* **2010**, *55*, 421–428. [CrossRef] [PubMed]
87. Barritault, D.; Caruelle, J.P. Regenerating agents (RGTAs): A new therapeutic approach. *Ann. Pharm. Fr.* **2006**, *64*, 135–144. [CrossRef]
88. Tong, M.; Zbinden, M.M.; Hekking, I.J.; Vermeij, M.; Barritault, D.; van Neck, J.W. RGTA OTR 4120, a heparan sulfate proteoglycan mimetic, increases wound breaking strength and vasodilatory capability in healing rat full-thickness excisional wounds. *Wound Repair Regen.* **2008**, *16*, 294–299. [CrossRef]
89. Tong, M.; Tuk, B.; Hekking, I.M.; Vermeij, M.; Barritault, D.; van Neck, J.W. Stimulated neovascularization, inflammation resolution and collagen maturation in healing rat cutaneous wounds by a heparan sulfate glycosaminoglycan mimetic, OTR4120. *Wound Repair Regen.* **2009**, *17*, 840–852. [CrossRef] [PubMed]
90. Barbier-Chassefiere, V.; Garcia-Filipe, S.; Yue, X.L.; Kerros, M.E.; Petit, E.; Kern, P.; Saffar, J.L.; Papy-Garcia, D.; Caruelle, J.P.; Barritault, D. Matrix therapy in regenerative medicine, a new approach to chronic wound healing. *J. Biomed. Mater. Res. Part A* **2009**, *90*, 641–647. [CrossRef]
91. Tong, M.; Tuk, B.; Hekking, I.M.; Pleumeekers, M.M.; Boldewijn, M.B.; Hovius, S.E.; van Neck, J.W. Heparan sulfate glycosaminoglycan mimetic improves pressure ulcer healing in a rat model of cutaneous ischemia-reperfusion injury. *Wound Repair Regen.* **2011**, *19*, 505–514. [CrossRef]
92. Groah, S.L.; Libin, A.; Spungen, M.; Nguyen, K.L.; Woods, E.; Nabili, M.; Ramella-Roman, J.; Barritault, D. Regenerating matrix-based therapy for chronic wound healing: A prospective within-subject pilot study. *Int. Wound J.* **2011**, *8*, 85–95. [CrossRef]
93. Chebbi, C.K.; Kichenin, K.; Amar, N.; Nourry, H.; Warnet, J.M.; Barritault, D.; Baudouin, C. Pilot study of a new matrix therapy agent (RGTA OTR4120) in treatment-resistant corneal ulcers and corneal dystrophy. *J. Fr. Ophtalmol.* **2008**, *31*, 465–471. [CrossRef]
94. Brignole-Baudouin, F.; Warnet, J.M.; Barritault, D.; Baudouin, C. RGTA-based matrix therapy in severe experimental corneal lesions: Safety and efficacy studies. *J. Fr. Ophtalmol.* **2013**, *36*, 740–747. [CrossRef] [PubMed]
95. Chappelet, M.A.; Bernheim, D.; Chiquet, C.; Aptel, F. Effect of a New Matrix Therapy Agent in Persistent Epithelial Defects After Bacterial Keratitis Treated with Topical Fortified Antibiotics. *Cornea* **2017**, *36*, 1061–1068. [CrossRef] [PubMed]
96. Guerra, M.; Marques, S.; Gil, J.Q.; Campos, J.; Ramos, P.; Rosa, A.M.; Quadrado, M.J.; Murta, J.N. Neurotrophic Keratopathy: Therapeutic Approach Using a Novel Matrix Regenerating Agent. *J. Ocul. Pharmacol. Ther.* **2017**, *33*, 662–669. [CrossRef]
97. Jullienne, R.; Garcin, T.; Crouzet, E.; He, Z.; Renault, D.; Thuret, G.; Gain, P. Evaluation of corneal epithelial wound healing after penetrating keratoplasty in patients receiving a new matrix therapy agent (regenerating agent). *Eur. J. Ophthalmol.* **2020**, *30*, 119–124. [CrossRef]
98. Molan, P.C. The evidence supporting the use of honey as a wound dressing. *Int. J. Low. Extrem. Wounds* **2006**, *5*, 40–54. [CrossRef] [PubMed]
99. Tracy, L.E.; Minasian, R.A.; Caterson, E.J. Extracellular Matrix and Dermal Fibroblast Function in the Healing Wound. *Adv. Wound Care* **2016**, *5*, 119–136. [CrossRef]
100. Rudolph, R.; Vande Berg, J.; Ehrlich, H.P. Wound contraction and scar contracture. In *Wound Healing: Biochemical and Clinical Aspects*; Cohen, I.K., Diegelmann, R.F., Lindblad, W.J., Eds.; Saunders: Philadelphia, PA, USA, 1992; pp. 96–114.

Disclaimer/Publisher's Note: The statements, opinions and data contained in all publications are solely those of the individual author(s) and contributor(s) and not of MDPI and/or the editor(s). MDPI and/or the editor(s) disclaim responsibility for any injury to people or property resulting from any ideas, methods, instructions or products referred to in the content.