Journal of the Oman Medical Association

MDPI

Review

Clinical Application of the EOS Imaging System—The Broader Horizon

Karen Brage [1,2,3,*], Bo Mussmann [3,4,5], Malene Roland Pedersen [6,7,8], Marcus Nissen [9], Oliver Brage [1,2], Svea Deppe Mørup [6], Mats Geijer [10], Palle Larsen [2] and Janni Jensen [3,5,11]

1 Education of Radiography, UCL University College, 5230 Odense, Denmark; olbr@ucl.dk
2 Health Sciences Research Centre, UCL University College, 5230 Odense, Denmark; pala@ucl.dk
3 Research and Innovation Unit of Radiology, University of Southern Denmark, 5000 Odense, Denmark; bo.mussmann@rsyd.dk (B.M.); janni.jensen@rsyd.dk (J.J.)
4 Faculty of Health Sciences, Oslo Metropolitan University, 0130 Oslo, Norway
5 Department of Radiology, Odense University Hospital, J. B. Winsløws Vej 4, 5000 Odense, Denmark
6 Department of Radiology, University Hospital of Southern Denmark, 7100 Vejle, Denmark; malene.roland.vils.pedersen@rsyd.dk (M.R.P.); svea.deppe.morup@rsyd.dk (S.D.M.)
7 Department of Regional Health Research, University of Southern Denmark, 5230 Odense, Denmark
8 Discipline of Medical Imaging and Radiation Therapy, School of Medicine, University College Cork, T12 YN60 Cork, Ireland
9 Emergency Department, Zealand University Hospital, 4600 Køge, Denmark; marcusnissen@live.dk
10 Department of Radiology, Institute of Clinical Sciences, Sahlgrenska Academy, University of Gothenburg, 40530 Göteborg, Sweden; mats.geijer@gu.se
11 Centre for Clinical Artificial Intelligence (CAI-X), Odense University Hospital, University of Southern Denmark, 5000 Odense, Denmark
* Correspondence: kabr2@ucl.dk

Abstract: Purpose: The purpose of this scoping review was to systematically identify and summarize the existing literature on non-spinal clinical applications of EOS imaging and identify related evidence gaps. Method: The study followed the PRISMA-ScR guidelines. A systematic literature search was conducted in Embase, MEDLINE, CINAHL, Scopus, Cochrane, Academic Search Premier, and OpenGrey databases in November 2022 and updated in December 2023. Original research from 2003 to 2023 was eligible if in English, Danish, French, German, Norwegian, or Swedish. Two authors screened articles by title and abstract, while data extraction from full texts was performed by seven authors using a structured template. Results: A total of 8176 articles were identified, with 1350 selected for full-text review and 268 included in data extraction. Among adults, 187 articles were included, with 88 focused on surgical applications like hip arthroplasty or osteotomy. In pediatrics, 68 general and 13 surgery-related articles were included. Lower extremity analysis was the most frequent topic, with other uses identified, such as rib cage geometry, patellar dislocation, and X-linked hypophosphatemia. Conclusions: Key clinical applications of EOS imaging include lower extremity analysis, e.g., leg length assessment and knee/hip arthroplasty planning), pelvic and spinal alignment studies, and emerging uses in rib cage geometry. Evidence gaps include limited research on the diagnostic accuracy of EOS for cerebral shunt placement, reliability in bone age estimation, and an unclear role in foot and ankle morphology.

Keywords: clinical application; EOS imaging system; image quality; radiation safety; slot scanner

check for updates

Academic Editor: Rashid Al Abri

Received: 9 December 2024
Revised: 19 March 2025
Accepted: 16 May 2025
Published: 29 May 2025

Citation: Brage, K.; Mussmann, B.; Pedersen, M.R.; Nissen, M.; Brage, O.; Mørup, S.D.; Geijer, M.; Larsen, P.; Jensen, J. Clinical Application of the EOS Imaging System—The Broader Horizon. *J. Oman Med. Assoc.* **2025**, *2*, 7. https://doi.org/10.3390/joma2010007

Copyright: © 2025 by the authors. Published by MDPI on behalf of the Oman Medical Association. Licensee MDPI, Basel, Switzerland. This article is an open access article distributed under the terms and conditions of the Creative Commons Attribution (CC BY) license (https://creativecommons.org/licenses/by/4.0/).

1. Introduction

The EOS imaging system was originally designed to capture full-body radiographs with a focus on the spine, hips, and knees obtained in the weight-bearing position. The system depicts anatomical structures at their true size using slot scanning technology and allows for the simultaneous acquisition of two orthogonal radiographs [1]. The slot scanning technology used in the EOS imaging system is self-collimated and minimizes scattered radiation, which improves image quality and reduces the radiation dose compared to conventional X-ray [2–4]. The lower dose, in combination with high image quality, makes EOS a popular modality, particularly in pediatric and adolescent populations [5].

The EOS imaging system is particularly valuable in the evaluation of scoliosis, providing high-resolution, low-dose radiographs at a true size, enabling accurate assessment of spinal curvature [6]. Additionally, its ability to capture orthogonal images simultaneously allows for a comprehensive understanding of the three-dimensional nature of the deformity by subsequent three-dimensional modeling of the spine and individual vertebrae [6–8]. EOS has also become an important tool in presurgical planning for total hip arthroplasty (THA), allowing for optimized component positioning, potentially enhancing stability and minimizing wear-related complications [9].

A systematic review and economic evaluation of EOS systems concluded that, due to the higher cost compared to traditional radiographic systems, the key determinant of cost-effectiveness lies in optimal utilization [3]. This underscores the importance of optimizing EOS machine utilization to maximize efficiency and cost-effectiveness.

The low-dose aspect of the EOS system raises questions about whether this modality has additional clinical applications that could benefit patients through reduced radiation exposure, thereby improving patient safety. The potential for a broader clinical use of EOS technology has been discussed, for instance, in connection with chest radiography [10] and in the confirmation of the integrity of cerebral shunts [11]. To the best of our knowledge, there are no ongoing or published scientific reviews comprehensively addressing the broader clinical applications of the EOS system.

Therefore, the objective of this scoping review is to map and summarize the existing literature on non-spinal clinical applications of EOS imaging. Specifically, the objectives of this review were to do the following:

Identify the range of clinical applications of EOS imaging beyond spinal conditions.

Summarize the key areas where EOS has been utilized, including musculoskeletal imaging, surgical planning, and functional assessment.

Highlight gaps in the existing literature and provide recommendations for future research directions.

2. Materials and Methods

2.1. Methodology

The scoping review was conducted following the Joanna Briggs Institute (JBI) methodology for scoping reviews [12,13] and adhering to the Preferred Reporting Items for Systematic Reviews and Meta-Analyses extension for Scoping Reviews (PRISMA-ScR) [14]. The review protocol is reported in Open Science Framework (https://osf.io/yc85j/, accessed on 19 March 2025) and published as a scoping review protocol in JBI Evidence Synthesis [15].

2.2. Amendment to Protocol

The planned forward and backward citation searches, as well as author searching, were not executed due to the substantial number of articles retrieved. Secondly, it was initially planned to investigate whether EOS was in clinical use. However, due to inconsistencies in how EOS is reported across different settings, determining its clinical status proved uncertain. To maintain reliability, we decided to exclude this question from our analysis.

2.3. Search Strategy

The search strategy adhered to JBI's 3-phased process [13]. The objective of the search strategy was to find both published and unpublished original articles. The search was developed with input from a science librarian using the following keywords: biplanar X-ray, biplanar radiograph, biplanar imaging, EOS imaging, and slot scanning (Appendix A). The literature databases Embase (Elsevier, Amsterdam, The Netherlands), MEDLINE (PubMed, U.S. National Library of Medicine, Bethesda, MD, USA), CINAHL Complete (EBSCO, Ipswich, MA, USA), Scopus (Elsevier, Amsterdam, The Netherlands), The Cochrane Library (The Cochrane Collaboration, London, UK), Academic Search Premier (EBSCO, Ipswich, MA, USA), and OpenGrey (INIST-CNRS, Vandoeuvre-lès-Nancy, France) were searched on 11 November 2022 and updated on 14 December 2023.

2.4. Eligibility Criteria

Although the EOS system was initially implemented in clinical settings in 2007 [1], the search filter included articles from 2003 onwards, as the prototype was tested in the years leading up to 2007. Quantitative articles describing the use of the EOS in a clinical setting were eligible for inclusion. Articles published in English, Danish, Norwegian, Swedish, French, and German were eligible for inclusion, given the proficiency of the author team in these languages. Language filters were incorporated into the search strategy, and the included languages were verified during the screening process. Non-original research was excluded.

2.5. Study Selection

All identified articles were uploaded into EndNote v.x20 (Clarivate Analytics, Philadelphi, PA, USA) where duplicates were removed from the dataset. The remaining articles were imported into Covidence (Veritas Health Innovation, Melbourne, Australia), where a second duplicate search was made. Two authors (KB and JJ) independently screened articles for applicability based on title and abstract. Subsequently, articles potentially eligible for inclusion were screened by full text. Exclusion reasons for full-text articles failing to meet the inclusion criteria were documented, such as lack of EOS modality usage, focus on spine-related research, absence of original research, and articles based on cadavers or within experimental frameworks. In cases where disagreements occurred between the reviewers at any stage of the selection process, they were resolved through discussion or with the involvement of a third reviewer. The screening process is presented in the PRISMA flow diagram [16] (Figure 1).

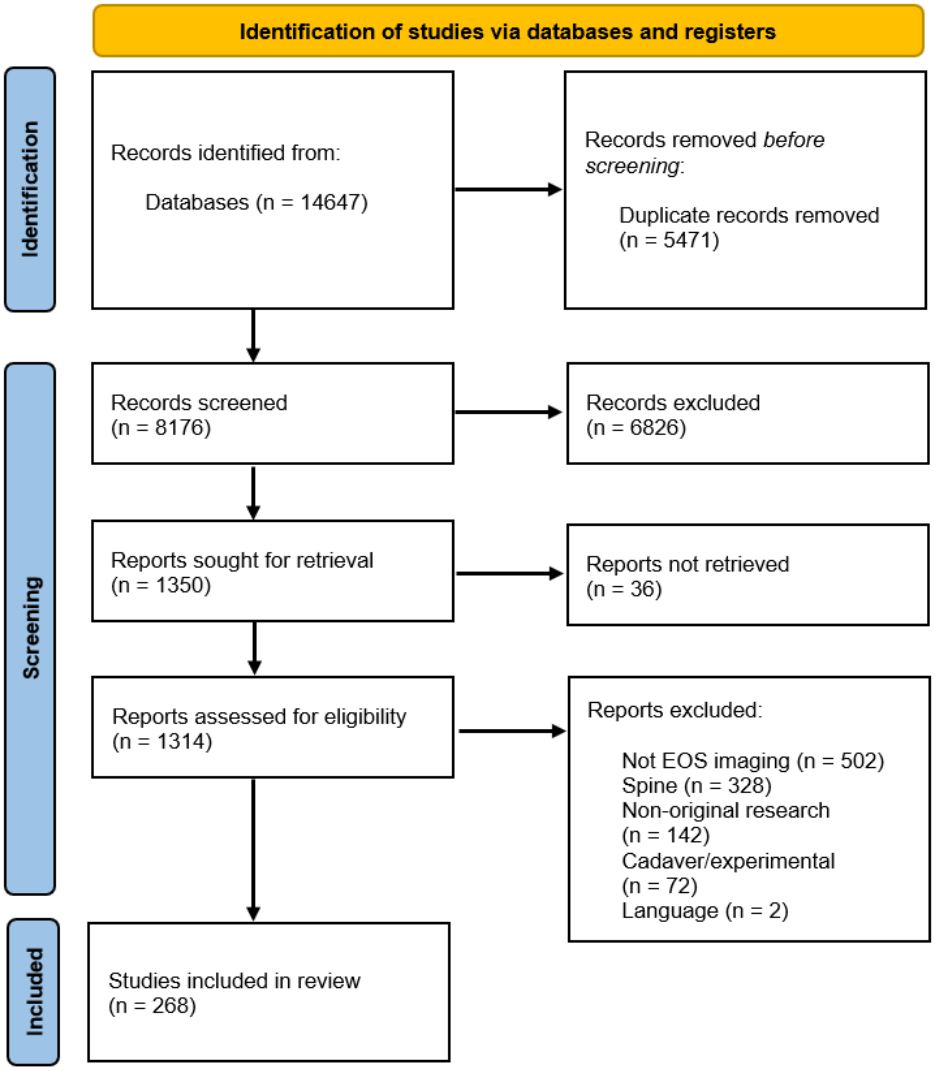

Figure 1. PRISMA flowchart of articles.

2.6. Data Extraction

Data extraction from included articles was carried out by pairs of two authors from a group of six (KB, JJ, BRM, MRP, SDM, MN), while validation was later performed by one of three authors (KB, JJ, and OB) using a data extraction tool developed by the authors [15].

Through various pilot tests, encompassing data extraction from a total of 50 articles, the original extraction sheet underwent a series of iterative modifications and revisions. These adjustments were made with the objective of augmenting the reliability and validity of the extracted data and, furthermore, to ensure the readability of the tables. Data were extracted on author and publication, clinical endpoints, age group and number of study participants, study type, and study design. Included articles were organized into four subcategories: Adult, Adult Surgery, Pediatric (including studies with mixed-age populations), and Pediatric Surgery (including studies with mixed-age populations). The articles within each table were organized under relevant headings and subheadings for easier navigation and reference. The categories were established after the completion of all data extraction processes. While all articles have been assigned a category, not all articles have been designated a subcategory.

3. Results

3.1. Search and Screening

A comprehensive search of the selected databases identified 8176 articles for potential inclusion. After applying the inclusion criteria and conducting title/abstract screening, 1350 articles were selected for full-text review. From these articles, 268 articles underwent data extraction. The included articles were primarily from Europe (n = 141), with France being the top contributor (n = 91), North America (n = 66), and Asia (n = 56). Additionally, articles were obtained from Oceania (n = 4) and South America (n = 1). The number of published articles grew substantially from 2004 to 2023, with a marked increase starting in 2012. The publication rate peaked at 41 articles in 2022, followed by a slight decline in 2023 (Figure 2).

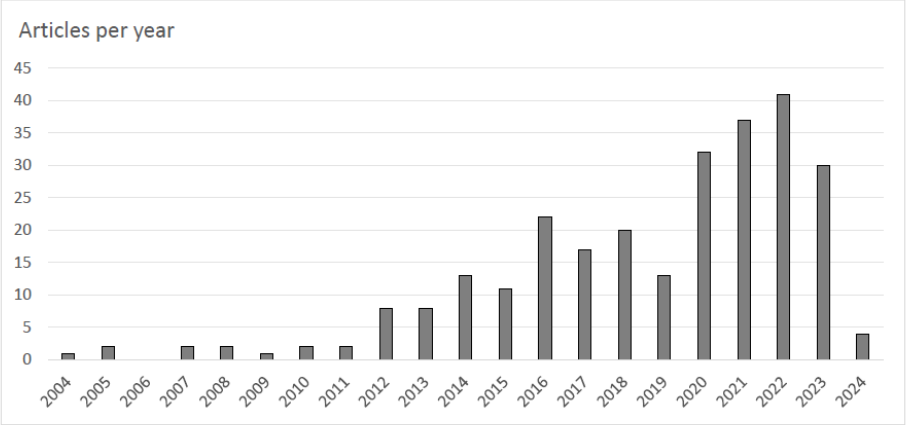

Figure 2. Number of EOS articles per year.

Out of 268 articles included, 138 were prospective, 117 were retrospective, and 10 were both prospective and retrospective, while the methodology of 3 articles was unclear. The included articles encompassed various study designs, including 120 case–control/cohort/non-RCTs, 113 cross-sectional/case-series/case-reports, 107 articles that included reliability and/or accuracy, and two RCTs.

3.2. Adults

For the adult category, a total of 99 articles were found. The majority were on the lower extremity (34 articles), of which three specifically focused on leg length, followed by 31 articles that combined pelvis and lower extremity analysis, 11 of which focused on gait. The most prevalent subcategories were imaging comparison, followed by spine-related research. Rarer topics were subjects such as osteoarthritis, economics, obstructive sleep apnea syndrome, pain syndrome, and shoulder morphology (Appendix B).

3.3. Adult Surgery

For the adult surgery category, 88 articles were included. Articles focused predominantly on hip arthroplasty, totaling 53, and knee arthroplasty, with 21 articles. Additionally, there were articles on topics such as shoulder arthroplasty, tibial osteotomy, and femoral shaft fractures. The most common subcategory was risk factors and safety, followed by imaging comparison (Appendix C).

3.4. Pediatric

In the pediatric group, a total of 68 articles were included. The most examined topic was lower extremity analysis, with 29 articles, of which five focused specifically on gait and four on leg length. Rib cage geometry and thoracic analysis were covered in eight

articles, and articles on maturity totaled six. Rarer topics were machine learning and foot and ankle analysis. In terms of subcategories for the pediatric group, the most common category was scoliosis, followed by cerebral palsy. The less frequent topics covered were patellar dislocation, X-linked hypophosphatemia, and cerebral shunt status (Appendix D).

3.5. Pediatric Surgery

Thirteen articles were included in the pediatric surgery category, six of which focused on rib cage geometry and thoracic analysis. In the subcategories for the pediatric surgery category, scoliosis was the most extensively studied area, followed by fracture, imaging comparison, Down's syndrome, and shoulder (Appendix E).

4. Discussion

This scoping review provides a comprehensive overview of the non-spinal clinical applications of EOS imaging. Our findings indicate that EOS has been widely utilized in lower extremity analysis, particularly for assessing leg length discrepancies, knee and hip arthroplasty planning, and gait analysis. It also plays a role in pelvic and spinal alignment studies, offering precise weight-bearing assessments that contribute to surgical planning and biomechanical evaluations. Additionally, EOS has shown promise in rib cage geometry and thoracic assessments, including applications in pulmonary function evaluation and postural compensation analysis. Emerging uses have been identified in cerebral shunt assessment and bone age estimation, though these areas remain underexplored and warrant further research. The low radiation dose and high imaging precision of EOS make it particularly valuable in pediatric and orthopedic settings, where minimizing exposure while maintaining diagnostic accuracy is crucial. These findings highlight the diverse and expanding role of EOS imaging in clinical practice, with opportunities for further investigation into its full diagnostic potential.

To the best of our knowledge, this scoping review is the first to collate topics beyond spinal conditions that have been investigated or assessed in clinical articles using the EOS imaging modality. Providing a keyword summary of existing articles on non-spinal topics facilitates easy access, enabling practitioners and researchers to explore the current state of knowledge within these areas.

We included 268 articles that explored applications of the EOS system with a primary focus on non-spinal uses. As expected, many articles focused on topics such as leg length or knee and hip arthroplasty. Nonetheless, our search also identified several lesser-explored areas that could have a substantial clinical impact on further investigation. As an example, the use of EOS in diagnosing myeloma showed promising results; however, when the body mass index exceeded 30, diagnostic performance diminished significantly [17]. The upcoming updated EOS system with a photon-counting detector may improve noise reduction and potentially address this issue [18]. On the other hand, computed tomography is a well-established method for diagnosing myeloma, offering true 3D reconstruction and cross-sectional images. Another less explored topic is that of shunt control in children with hydrocephalus, where the diagnostic potential of EOS has been examined, showing promising results [11,19]. However, the limited number of articles, their retrospective designs, and their small sample sizes underscore the need for additional research. Nonetheless, given that many shunt patients are young and often undergo repeated follow-up imaging, additional exploration of this topic is warranted, as this group of patients could benefit from the reduced radiation dose provided by EOS imaging compared with conventional digital radiography. The low-dose capability of EOS imaging has been confirmed in multiple articles [20–23]. For instance, with the use of the Microdose feature in EOS, it has been shown that leg length can be measured accurately in an adolescent population [5], while

EOS imaging for the pelvis delivered approximately half the radiation dose of conventional radiography [24].

Radiostereometric analysis (RSA) is a research method used to estimate micromotion between an orthopedic implant and the surrounding bone or between fracture fragments [25–27]. Traditionally, RSA involves the use of a setup with two X-ray tubes for simultaneous exposure [28]. The biplane simultaneous exposure capability of the EOS imaging system makes it a promising modality for exploring its capabilities in relation to RSA. A recent study found that when assessing knee implant motion, the precision of EOS was comparable to that of the traditional RSA method [29]. Additionally, the potential of using EOS and RSA for evaluating fracture stability has been investigated in relation to slipped capital femoral epiphysis with accuracy and precision comparable to that obtained with the traditional RSA system [30].

Within the adult population, the EOS system has demonstrated promising results, especially in the context of orthopedic procedures, with a particular focus on total hip arthroplasty (THA). One study introduced the "femur first" technique using EOS imaging for intraoperative guidance during THA, eliminating the need for computer-based navigation and highlighting its potential for real-time assistance and streamlined surgical procedures [31]. The use of EOS for analyzing THA component positioning in a standing position has been explored, utilizing the system's capability to capture weight-bearing images, thus enhancing our understanding of implant behavior under typical loading conditions [32]. Exploring the post-surgical alignment, posture, and balance following THA are also topics of interest in recent EOS articles [33–35]. The 3D modeling abilities were used after surgery to check the placement of the femoral stem in hip replacements, offering a non-invasive alternative to CT scans that could lower radiation exposure [36]. This method might be useful for tracking how well hip prostheses work as patients move from standing to sitting [37]. The three-dimensional capabilities of the EOS system have also been explored to reconstruct the rib cage before and after surgery, enhancing the understanding of pulmonary function in patients with adolescent idiopathic scoliosis [38–40]. The ability to visualize rib cage alignment in a weight-bearing position may improve our understanding of thoracic biomechanics and respiratory function, but further research is needed to integrate EOS findings into routine clinical practice for pulmonary assessments. Additionally, the three-dimensional capabilities of the EOS system were explored regarding shoulder morphology [40,41] and kinematics [42–44], with the system showing promise as a low-dose supplement and/or alternative to existing imaging.

Despite the strengths of EOS imaging, this review identifies several key evidence gaps. The lack of standardized protocols for certain applications, such as bone age estimation and cerebral shunt assessment, limits its widespread adoption. Additionally, while EOS has been validated for reliability and accuracy in orthopedic applications, fewer studies have evaluated its diagnostic efficacy in comparison to gold-standard imaging modalities like MRI and CT.

Furthermore, the economic feasibility of implementing EOS in diverse clinical settings remains an important consideration. The relatively high initial cost of EOS systems raises questions about their cost-effectiveness, particularly in hospitals with limited imaging resources. However, its ability to reduce radiation dose and potentially replace multiple imaging sessions could lead to long-term cost savings, a hypothesis that warrants further economic evaluation studies.

Unlike systematic reviews, scoping reviews do not synthesize results through a formal quality appraisal of evidence, as their primary objective is to map the breadth of existing research rather than critically evaluate study validity [13]. While systematic reviews provide deeper analysis with specific criteria, they might miss broader ongoing research.

This scoping review, however, identified key research areas and gaps, paving the way for future, more focused, systematic articles. The study's comprehensive methodology is evident as it adhered to the JBI methodology for scoping reviews and followed the PRISMA-ScR guidelines, ensuring a rigorous and systematic approach [14]. The quality control measures applied in the data extraction, which involved iterative modifications and pilot tests of the data extraction tool, enhanced the reliability and validity of the data.

Resource limitations and time constraints led to deviations from the established protocol, such as omitting forward and backward citation searches and author searching. This approach could risk missing relevant articles and introduce potential biases in the study selection. However, the inclusion of more than 250 articles in this review is substantial, providing ample coverage of existing trends and developments in the field. The process of determining if articles were included in this article, i.e., non-spinal focus, was guided by their principal focus. In cases where articles touched upon themes pertinent to both the spine and broader applications, the decision necessitated a nuanced evaluation, where the decision to include or exclude was made to the best of our knowledge and judgment.

5. Conclusions

This review examined the literature on clinical applications of the EOS imaging system. The articles included demonstrate a consistent increase in research publications over time, with significant contributions from various global regions. We identified insights into its use across various areas. Key clinical applications of EOS imaging include lower extremity analysis, e.g., leg length assessment and knee/hip arthroplasty planning), pelvic and spinal alignment studies, and emerging uses in rib cage geometry. Evidence gaps include limited research on the diagnostic accuracy of EOS for cerebral shunt placement, reliability in bone age estimation, and an unclear role in foot and ankle morphology.

The relatively high economic break-even of the EOS system cannot be ignored. However, a broader application of the system may lead to more efficient planning and, consequently, lower costs per examination. This is, however, speculative and requires further economic evaluation.

Author Contributions: Conceptualization, K.B., J.J. and B.M.; methodology, K.B., J.J., P.L., M.G. and B.M.; validation, K.B. and J.J.; formal analysis, K.B. and J.J.; investigation, K.B., J.J., M.R.P., M.N., O.B., S.D.M., M.G. and B.M.; writing—original draft preparation, K.B. and J.J.; writing—review and editing, K.B., J.J., M.R.P., M.N., O.B., S.D.M., M.G., P.L. and B.M.; project administration, K.B., J.J. and B.M. All authors have read and agreed to the published version of the manuscript.

Funding: This research received no external funding.

Institutional Review Board Statement: Not applicable.

Informed Consent Statement: Not applicable.

Data Availability Statement: The original contributions presented in this study are included in the article. Further inquiries can be directed to the corresponding author.

Conflicts of Interest: The authors declare no conflicts of interest.

Appendix A. Search Strings

MEDLINE (PubMed)	Embase (Elsevier)	The Cochrane Library	Scopus	CINAHL Complete (EBSCO)	Academic Search Premier (EBSCO)	OpenGrey
((((((((((((((((((((Biplanar x-ray) OR (Biplanar x ray)) OR (Biplanar xray)) OR (Biplanar radiograph)) OR (Biplanar radiography)) OR (Biplanar imaging)) OR (Biplane x-ray)) OR (Biplane x ray)) OR (Biplane radiograph)) OR (Biplane radiography)) OR (Biplane imaging)) OR (eos imaging)) OR (eos image)) OR (Eos images)) OR (eos radiography)) OR (Eos system)) OR (eos x-ray)) OR (eos x ray)) OR (slot scanner)) OR (slot scanners)) OR (slot scanning)	'biplanar x ray' OR (biplanar AND x AND ray) OR 'biplanar xray' OR (biplanar AND xray) OR 'biplanar radiograph' OR (biplanar AND ('radiograph'/exp OR radiograph)) OR 'biplanar radiography'/exp OR 'biplanar radiography' OR (biplanar AND ('radiography'/exp OR radiography)) OR 'biplanar imaging' OR (biplanar AND ('imaging'/exp OR imaging)) OR 'biplane x ray' OR (('biplane'/exp OR biplane) AND x AND ray) OR 'biplane xray' OR (('biplane'/exp OR biplane) AND xray) OR 'biplane radiograph' OR (('biplane'/exp OR biplane) AND ('radiograph'/exp OR radiograph)) OR 'biplane radiography' OR (('biplane'/exp OR biplane) AND ('radiography'/exp OR radiography)) OR 'biplane imaging' OR (('biplane'/exp OR biplane) AND ('imaging'/exp OR imaging)) OR 'eos imaging'/exp OR 'eos imaging' OR (('eos'/exp OR eos) AND ('imaging'/exp OR imaging)) OR 'eos image' OR (('eos'/exp OR eos) AND ('image'/exp OR image)) OR 'eos images' OR (('eos'/exp OR eos) AND images) OR 'eos radiography' OR (('eos'/exp OR eos) AND ('radiography'/exp OR radiography)) OR 'eos system'/exp OR 'eos system' OR (('eos'/exp OR eos) AND system) OR 'eos x ray' OR (('eos'/exp OR eos) AND x AND ray) OR 'eos xray' OR (('eos'/exp OR eos) AND xray) OR 'slot scanner' OR (slot AND ('scanner'/exp OR scanner)) OR 'slot scanners' OR (slot AND scanners) OR 'slot scanning' OR (slot AND scanning)	Biplanar x-ray OR Biplanar x ray OR Biplanar xray OR Biplanar radiograph OR Biplanar radiography OR Biplanar imaging OR Biplane x-ray OR Biplane x ray OR Biplane xray OR Biplane radiograph OR Biplane radiography OR Biplane imaging OR eos imaging OR eos image OR Eos images OR Eos system OR eos x-ray OR eos x ray OR eos xray OR slot scanner OR slot scanners OR slot scanning	(TITLE-ABS-KEY (biplanar W/3 x-ray) OR TITLE-ABS-KEY (biplanar W/3 x AND ray) OR TITLE-ABS-KEY (biplanar W/3 radiograph) OR TITLE-ABS-KEY (biplanar W/3 radiography) OR TITLE-ABS-KEY (biplanar W/3 imaging) OR TITLE-ABS-KEY (biplane W/3 x-ray) OR TITLE-ABS-KEY (biplane W/3 x AND ray) OR TITLE-ABS-KEY (biplane W/3 radiograph) OR TITLE-ABS-KEY (biplane W/3 radiography) OR TITLE-ABS-KEY (biplane W/3 imaging) OR TITLE-ABS-KEY (eos W/3 imaging) OR TITLE-ABS-KEY (eos W/3 image) OR TITLE-ABS-KEY (eos W/3 images) OR TITLE-ABS-KEY (eos W/3 radiography) OR TITLE-ABS-KEY (eos W/3 system) OR TITLE-ABS-KEY (eos W/3 x-ray) OR TITLE-ABS-KEY (eos W/3 x AND ray) OR TITLE-ABS-KEY (slot W/3 scanner) OR TITLE-ABS-KEY (slot W/3 scanners) OR TITLE-ABS-KEY (slot W/3 scanning))	Biplanar x-ray OR Biplanar x ray OR Biplanar radiograph OR Biplanar radiography OR Biplanar imaging OR Biplane x-ray OR Biplane x ray OR Biplane xray OR Biplane radiograph OR Biplane radiography OR Biplane imaging OR eos imaging OR eos image OR Eos images OR eos radiography OR Eos system OR eos x-ray OR eos x ray OR slot scanner OR slot scanners OR slot scanning	Eos images OR eos radiography OR Eos system OR eos x-ray OR eos x ray OR slot scanner OR slot scanners OR slot scanning OR Biplanar x-ray OR Biplanar x ray OR Biplanar radiograph OR Biplanar radiography OR Biplanar imaging OR Biplane x-ray OR Biplane x ray OR Biplane radiograph OR Biplane radiography OR Biplane imaging OR eos imaging OR eos image OR eos images OR eos radiography OR eos system OR eos x-ray OR eos x ray OR slot scanner OR slot scanners OR slot scanning	(biplane AND x-ray) OR (biplane AND x ray) OR (biplane AND xray) OR (biplane AND imaging) OR (eos AND imaging) OR (eos AND image) OR (eos AND images) OR (eos AND system)

Appendix B. Adult Imaging Using the EOS Imaging System

Author, Year, Country	Title	Clinical Endpoints (Parameters)	Total n	Timeline	Study Type	
	Center of mass analysis					
Amabile, 2015, FR [45]	Alignment of centers of mass of body segments with the gravity line	Spinal/balance	20	→	👁	
	Head analysis					
Berg, 2020, CH [46]	Experiences with a new biplanar low-dose X-ray device for imaging the facial skeleton: a feasibility study	Cephalometric angles/distances	12	←	👁	
Kerbrat, 2021, FR [47]	Biplanar low-dose radiograph is suitable for cephalometric analysis in patients requiring 3D evaluation of the whole skeleton	Cephalometric angles/distances	13	←	👁	🎯
	Lower extremity analysis					
Buck, 2012, CH [48]	Femoral and tibial torsion measurements with 3D models based on low-dose biplanar radiographs in comparison with standard CT measurements	Femoral; Tibial	35	→	👁	🎯
Cebulski-Delebarre, 2016, FR [49]	Correlation between primary flat foot and lower extremity rotational misalignment in adults	Femoral; Knee; Leg length; Pelvic; Tibial	54	→	🔎	
Clément, 2014, CA [50]	Influence of biomechanical multi-joint models used in global optimisation to estimate healthy and osteoarthritis knee kinematics	Knee	10	→	🔎	
Clément, 2018, CA [51]	Comparison of soft tissue artifact and its effects on knee kinematics between non-obese and obese subjects performing a squatting activity recorded using an exoskeleton	Femoral; Knee; Tibial	17	→	🔎	
Dagneaux, 2020, FR [52]	Three-dimensional biometrics to correlate hindfoot and knee coronal alignments using modern weightbearing imaging	Foot/ankle; Knee	59	←	🔎	
Dufrénot, 2023, FR [53]	Three-dimensional biometrics using weight-bearing imaging shows relationship between knee and hindfoot axial alignment	Femoral; Foot/ankle; Tibial	99	←	👁	
Dumas, 2004, CA [54]	Determination of personalized inertial parameters of lower limb by biplanar low-dose radiography	Femoral	12	→	👁	
Dumas, 2005, CA [55]	Personalized body segment parameters from biplanar low-dose radiography	Femoral	16	→	👁	
Guenoun, 2012, FR [56]	Reliability of a new method for lower-extremity measurements based on stereoradiographic three-dimensional reconstruction	Femoral; Leg length; Tibial	25	→	👁	🎯
Hecker, 2021, CH [57]	The EOS 3D imaging system reliably measures posterior tibial slope	Tibial	56	←	👁	🎯
Kümmerlin, 2022, GE [58]	Measuring knee joint laxity in three degrees-of-freedom in vivo using a robotics- and image-based technology	Knee	4	→	👁	
Lo, 2024, TW [59]	Associations between femoral 3D curvature and sagittal imbalance of spine	Femoral; Foot/ankle; Knee; Pelvic; Spinal/balance	105	←	👁	
Morin, 2016, CA [60]	Assessment of femur geometrical parameters using EOS™ imaging technology in patients with atypical femur fractures; preliminary results	Femoral	16	→	🔎	
Moon, 2020, KR [61]	The effect of knee joint rotation in the sagittal and axial plane on the measurement accuracy of coronal alignment of the lower limb	Femoral; Knee; Pelvic; Tibial	90	←		🎯
Nam, 2014, US [62]	Evaluation of the 3-dimensional, weight-bearing orientation of the normal adult knee	Femoral; Knee; Pelvic; Tibial	100	→	👁	
Serrurier, 2012, FR [63]	Robust femur condyle disambiguation on biplanar X-rays	Femoral	30	←	🔎	

Author, Year, Country	Title	Clinical Endpoints (Parameters)	Total n	Timeline	Study Type	
Zeighami, 2020, CA [64]	A method for quantitative evaluation of a valgus knee orthosis using biplane X-ray images	Health outcomes; Knee	1	⇨	👁	
	Lower extremity analysis—imaging comparison					
Cho, 2021, KR [65]	Evaluation of the reliability of lower extremity alignment measurements using EOS imaging system while standing in an even weight-bearing posture	Femoral; Knee; Pelvic; Tibial	52	⇦⇨	👁	🎯
Choi, 2022, KR [66]	Comparison of lower-limb alignment in patients with advanced knee osteoarthritis: EOS biplanar stereoradiography versus conventional scanography	Knee; Pelvic; Tibial	52	⇦	👁	🎯
Cosentino, 2022, CH [67]	MRI signal and morphological alterations of the suprapatellar fat pad in asymptomatic subjects: are these normal variants?	Knee; Leg length	110	⇨	👁	
Folinais, 2013, FR [68]	Measuring femoral and rotational alignment: EOS system versus computed tomography	Femoral; Image quality; Tibial	30	⇦	👁	🎯
Mayr, 2021, GE [69]	Anteversion angle measurement in suspected torsional malalignment of the femur in 3-dimensional EOS vs computed tomography—a validation study	Femoral	19	⇨	👁	🎯
Narahashi, 2024, BR [70]	Measurement of tibial slope using biplanar stereoradiography (EOS®)	Knee; Tibial	30	⇦		🎯
Rosskopf, 2019, CH [71]	3D hindfoot alignment measurements based on low-dose biplanar radiographs: a clinical feasibility study	Foot/ankle; Tibial	50	⇨		🎯
Störmann, 2021, GE [72]	Comparison of medial distal tibial angle in EOS imaging and weightbearing X-ray	Foot/ankle; Tibial	41	⇦	👁	
Wise, 2020, US [73]	Reliability of EOS compared to conventional radiographs for evaluation of lower extremity deformity in adult patients	Femoral; Knee; Leg length; Tibial	10	⇨	👁	🎯
Yan, 2019, CN [74]	Femoral and tibial torsion measurements based on EOS imaging compared to 3D CT reconstruction measurements	Femoral; Tibial	18	⇨	👁	
	Lower extremity analysis—knee osteoarthritis					
Huang, 2021, HK [75]	Exploring the relationship between pain intensity and knee moments in participants with medial knee osteoarthritis: a cross-sectional study	Knee	47	⇨	👁	
Huang, 2021, HK [76]	Knee joint loadings are related to tibial torsional alignments in people with radiographic medial knee osteoarthritis	Knee; Tibial	47	⇨	👁	
Koliogiannis, 2021, GE [77]	Is the EOS imaging system as accurate as conventional radiography in grading osteoarthritis of the knee?	Knee	142	⇦		🎯
Zeighami, 2017, CA [78]	Tibio-femoral joint contact in healthy and osteoarthritic knees during quasi-static squat: a bi-planar X-ray analysis	Femoral parameters; Knee parameters; Tibial parameters	19	⇨	🔎	
	Lower extremity analysis—leg length					
Clavé, 2018, FR [79]	Reproducibility of length measurements of the lower limb by using EOS™	Femoral; Knee; Leg length; Pelvic; Tibial	112	⇦	🔎	🎯
Guggenberger, 2014, CH [80]	Assessment of lower limb length and alignment by biplanar linear radiography: comparison with supine CT and upright full-length radiography	Foot/ankle; Knee; Leg length	51	⇨	👁	🎯
Lazennec, 2016, FR [81]	Do patients' perceptions of leg length correlate with standing 2- and 3-dimensional radiographic imaging?	Femoral; Knee; Leg length; Tibial	70	⇨	👁	
	Patient safety and radiation exposure					
Ben Abdennebi, 2017, FR [82]	Comparative dose levels between CT-scanner and slot-scanning device (EOS system) in pregnant women pelvimetry	Radiation dose	20	⇨	👁	

Author, Year, Country	Title	Clinical Endpoints (Parameters)	Total n	Timeline	Study Type	
Boutry, 2013, FR [17]	Low-dose biplanar skeletal survey versus digital skeletal survey in multiple myeloma	Health outcomes; Radiation dose/Image quality	56	⇨	👁	
Dietrich, 2013, CH [83]	Comparison of radiation dose, workflow, patient comfort and financial break-even of standard digital radiography and a novel biplanar low-dose X-ray system for upright full-length lower limb and whole spine radiography	Financials/Workflow; Health outcomes; Radiation dose	445	⇨	🔎	
Wood, 2021, US [84]	Incidental extraspinal imaging findings on adult EOS full body radiographs: prevalence and clinical importance	Incidental findings	503	⇦	🔎	
	Pelvis analysis					
Bordes, 2023, FR [85]	The influence of the sacral slope on pelvic kinematics and clinical manifestations in femoroacetabular impingement	Pelvic; Spinal/balance	200	⇨	🔎	
Buckland, 2017, US [86]	Sagittal pelvic orientation a comparison of two methods of measurement	Pelvic; Spinal/balance	100	⇦	👁	🎯
Fritz, 2019, CH [87]	Acetabular coverage differs between standing and supine positions: model-based assessment of low-dose biplanar radiographs and comparison with CT	Pelvic	50	⇦	👁	🎯
Gasparutto, 2023, CH [88]	Definition and reliability of 3D acetabular and global offset measurements from bi-plane X-rays	Pelvic	28	⇦		🎯
Kim, 2019, FR [89]	Stand-to-sit kinematics of the pelvis is not always as expected: hip and spine pathologies can have an impact	Pelvic	90	⇨	🔎	
Mussmann, 2019, DK [90]	Radiographic signs of acetabular retroversion using a low-dose slot-scanning radiographic system (EOS®)	Pelvic; Radiation dose/Image quality	34	⇨	👁	🎯
Rouissi, 2017, FR [91]	Intra and inter-observer reliability of determining degree of pelvic obliquity in neuromuscular scoliosis using the EOS-CHAIR® protocol	Pelvic; Spinal/balance	36	⇦	👁	
Thelen, 2017, FR [92]	Normative 3D acetabular orientation measurements by the low-dose EOS imaging system in 102 asymptomatic subjects in standing position: analyses by side, gender, pelvic incidence and reproducibility	Pelvic	102	⇨	👁	
	Pelvis and lower extremity analysis					
Bendaya, 2015, FR [93]	Healthy vs. osteoarthritic hips: a comparison of hip, pelvis and femoral parameters and relationships using the EOS® system	Femoral; Pelvic	60	⇨	🔎	
Canetti, 2020, FR [94]	Spinopelvic parameters in greater trochanteric pain syndrome: a retrospective case–control study	Pelvic	86	⇦	🔎	
Coulomb, 2023, FR [95]	Radiological signs of femoroacetabular impingement are linked to pelvic version in asymptomatic subjects	Pelvic; Spinal/balance	118	⇦	🔎	
Frasson, 2022, CA [96]	Do femoral version abnormalities play a role in hip function of patients with hip pain?	Femoral	31	⇨	👁	
Hodel, 2022, CH [97]	The relationship between pelvic tilt, frontal, and axial leg alignment in healthy subjects	Foot/ankle; Knee; Pelvic	30	⇨	👁	
Hodel, 2023, CH [98]	The relationship between frontal, axial leg alignment, and ankle joint line orientation-a radiographic analysis of healthy subjects	Femoral; Foot/ankle; Knee; Pelvic; Tibial	30	⇨	👁	🎯
Huang, 2020, CN [99]	Reliability and concurrent validity of angle measurements in lower limb: EOS 3D goniometer versus 2D manual goniometer	Femoral; Knee; Pelvic; Tibial	50	⇨		🎯
Pillet, 2014, FR [100]	A reference method for the evaluation of femoral head joint center location technique based on external markers	Pelvic	17	⇨		🎯
Than, 2012, HU [101]	Geometrical values of the normal and arthritic hip and knee detected with the EOS imaging system	Femoral; Knee; Pelvic; Tibial	197	?	🔎	

Author, Year, Country	Title	Clinical Endpoints (Parameters)	Total n	Timeline	Study Type	
Vaynrub, 2021, US [102]	The ankle-pelvic angle (APA) and global lower extremity angle (GLA): summary measurements of pelvic and lower extremity compensation	Foot/ankle; Femoral; Pelvic; Spinal/balance	518	⇦	🔍	
	Pelvis and lower extremity analysis—imaging comparison					
Ferre, 2014, FR [103]	Evaluation of a method for the assessment of anterior acetabular coverage and hip joint space width	Femoral; Pelvic; Radiation dose/Image quality	28	⇨	👁	🎯
Krug, 2014, GE [104]	Comparison of image quality using a X-ray stereotactical whole-body system and a direct flat-panel X-ray device in examinations of the pelvis and knee	Image quality	114	⇦	👁	
Rosskopf, 2016, CH [105]	Assessment of two-dimensional (2D) and three-dimensional (3D) lower limb measurements in adults: comparison of micro-dose and low-dose biplanar radiographs	Radiation dose/Image quality	100	⇦⇨	👁	🎯
Sailhan, 2017, FR [106]	Differences in limb alignment and femoral mechanical-anatomical angles using two dimension versus three dimension radiographic imaging	Femoral; Knee; Tibial	127	⇦	👁	
	Pelvis and lower extremity analysis—spine					
Katsumi, 2022, US [107]	The influence of knee osteoarthritis on spinopelvic alignment and global sagittal balance	Femoral; Knee; Pelvic; Spinal/balance; Tibial	108	⇦	🔍	
Kouyoumdjian, 2022, FR [108]	Hip-spine relationship between sagittal balance of the lumbo-pelvi-femoral complex and hip extension capacity: an EOS evaluation in a healthy caucasian population	Pelvic; Spinal/balance	120	⇨	👁	
Lazennec, 2015, FR [109]	Measuring extension of the lumbar-pelvic-femoral complex with the EOS system	Femoral; Pelvic	46	⇨	👁	🎯
Mekhael, 2021, LB [110]	Toward understanding the underlying mechanisms of pelvic tilt reserve in adult spinal deformity: the role of the 3D hip orientation	Pelvic	227	⇨	🔍	
Park, 2022, KR [111]	Knee extension is related to the posteriorly deviated gravity line to the pelvis in young adults: radiographic analysis using low-dose biplanar X-ray	Knee; Pelvic; Spinal/balance	124	⇦	🔍	
Shimizu, 2021, US [112]	Understanding sagittal compensation in adult spinal deformity patients: relationship between pelvic tilt and lower-extremity position	Femoral; Pelvic; Spinal/balance; Tibial	200	⇦	👁	
	Pelvis and lower extremity analysis—gait					
Assi, 2023, LB [113]	ASD with high pelvic retroversion develop changes in their acetabular orientation during walking	Pelvic; Spinal/balance	126	⇨	🔍	
Bakouny, 2017, LB [114]	Roussouly's sagittal spino-pelvic morphotypes as determinants of gait in asymptomatic adult subjects	Foot/ankle; Gait; Knee; Pelvic; Spinal/balance	91	⇨	👁	
De Pieri, 2021, CH [115]	Subject-specific modeling of femoral torsion influences the prediction of hip loading during gait in asymptomatic adults	Pelvic	37	⇨	👁	
Fu, 2023, CN [116]	Relationship between spinal imbalance and knee osteoarthritis by using full-body EOS	Knee; Pelvic; Spinal/balance	213	⇨	🔍	
Huang, 2023, CN [117]	The association between tibial torsion, knee flexion excursion and foot progression during gait in people with knee osteoarthritis: a cross-sectional study	Femoral; Knee; Tibial	47	⇨	👁	
Ould-Slimane, 2021, FR [118]	Optoelectronic study of gait kinematics in sagittal spinopelvic imbalance	Gait	35	⇨	👁	
Sangeux, 2014, AU [119]	Which method of hip joint centre localisation should be used in gait analysis?	Femoral	17	⇨	👁	

Author, Year, Country	Title	Clinical Endpoints (Parameters)	Total n	Timeline	Study Type	
Sauret, 2016, FR [120]	On the use of knee functional calibration to determine the medio-lateral axis of the femur in gait analysis: comparison with EOS biplanar radiographs as reference	Femoral; Foot/ankle; Knee; Tibial	13	⇨	👁	
Südhoff, 2007, FR [121]	Comparing three attachment systems used to determine knee kinematics during gait	Knee	18	⇨	👁	
van Drongelen, 2020, GE [122]	Determination of leg alignment in hip osteoarthritis patients with the EOS® system and the effect on external joint moments during gait	Femoral; Knee; Pelvic; Tibial	36	⇨	🔎	
Yared, 2023, LB [123]	Differences in kinematic changes from self-selected to fast speed gait in asymptomatic adults with radiological signs of femoro-acetabular impingement	Femoral; Pelvic	130	⇨	👁	
	Rib cage geometry and thoracic analysis					
Attali, 2019, FR [124]	Compensation of respiratory-related postural perturbation is achieved by maintenance of head-to-pelvis alignment in healthy humans	Spinal/balance; Ribcage/lung	48	⇨	👁	
Bertrand, 2008, FR [125]	Three-dimensional reconstruction of the rib cage from biplanar radiography	Ribcage/lung	15	⇨		🎯
Bousigues, 2023, FR [126]	3D reconstruction of the scapula from biplanar X-rays for pose estimation and morphological analysis	Shoulder	18	⇦	👁	🎯
Vergari, 2022, FR [127]	Functional analysis of the human rib cage over the vital capacity range in standing position using biplanar X-ray imaging	Pelvic; Ribcage/lung; Spinal/balance	58	⇨	🔎	
	Special topics in imaging					
Herrou, 2022, FR [128]	Prevalence of enthesopathies in adults with x-linked hypophosphatemia: analysis of risk factors	Foot/ankle parameters; Pelvic parameters; Spinal parameters/balance	114	⇦	👁	
	Spinal and pelvis analysis					
Fader, 2018, US [129]	The role of lumbar lordosis and pelvic sagittal balance in femoroacetabular impingement	Pelvic; Spinal/balance	20	⇨	🔎	
Ferenczi, 2020, FR [130]	Relationship between spinal-pelvic sagittal balance and pelvic-femoral injuries in professional soccer players	Leg length; Pelvic; Spinal/balance	61	⇨	🔎	
Hey, 2021, SG [131]	Pelvic and sacral morphology and their correlation with pelvic incidence, lumbar lordosis, and lumbar alignment changes between standing and sitting postures	Pelvic; Spinal/balance	110	⇨	👁	
	Spinal and posture analysis					
Amabile, 2018, FR [132]	Invariance of head-pelvis alignment and compensatory mechanisms for asymptomatic adults older than 49 years	Pelvic; Spinal/balance	110	⇨	🔎	
Okamoto, 2018, JP [133]	Sagittal balance measures are more reproducible when measured in 3D vs in 2D using full-body EOS® images	Pelvic; Spinal/balance	60	⇦		🎯
Park, 2023, US [134]	The posterior cranial vertical line: a novel radiographic marker for classifying global sagittal alignment	Knee; Pelvic; Health outcomes; Spinal/balance	334	⇦	🔎	
	Upper extremity analysis					
Cauchon, 2020, CA [135]	Morphologic and radiologic parameters correlating to shoulder function at diagnosis for patients with rotator cuff tear	Shoulder	52	⇨	👁	🎯
Kaneko, 2016, JP [136]	Validation study of arm positions for evaluation of global spinal balance in EOS imaging	Spinal/balance	34	⇨	👁	
Lagacé, 2012, CA [44]	Analysis of humeral head displacements from sequences of biplanar X-rays: repeatability study and preliminary results in healthy subjects	Shoulder	9	⇨		🎯

Author, Year, Country	Title	Clinical Endpoints (Parameters)	Total n	Timeline	Study Type	
Borotikar, 2019, FR [137]	Effects of gleno-humeral joint centre mislocation on gleno-humeral kinematics and kinetics	Shoulder	11	⇨	👁	
Loisel, 2023, FR [138]	Three-dimensional reconstruction of the hand from biplanar X-rays: assessment of accuracy and reliability	Image quality	6	⇨	👁	🎯
Ohl, 2010, FR [41]	Shoulder bony landmarks location using the EOS low-dose stereoradiography system: a reproducibility study	Shoulder	22	⇨		🎯
Zhang, 2015, CA [42]	Investigation of 3D glenohumeral displacements from 3D reconstruction using biplane X-ray images: accuracy and reproducibility of the technique and preliminary analysis in rotator cuff tear patients	Shoulder	45	⇨		🎯
Retrospective study:				⇦		
Prospective study.				⇨		
Cross-sectional, case-series, case-reports:				👁		
Case–control, cohort, non-randomized controlled trials:				🔎		
Reliability/accuracy/agreement:				🎯		

Appendix C. Adult Surgery Imaging Using the EOS System

Author, Year, Country	Title	Clinical Endpoints (Parameters)	Total n	Timeline	Study Type	
	Femoral shaft fractures					
Knafo, 2016, FR [139]	Reproducibility of low-dose stereography measurements of femoral torsion after IM nailing of femoral shaft fractures and in intact femurs	Femoral	45	⇨		🎯
	Hip arthroplasty					
Verdier, 2016, FR [140]	EOS-based cup navigation: randomised controlled trial in 78 total hip arthroplasties	Pelvic	78	⇨	RCT	
Billaud, 2015, FR [141]	Acetabular component navigation in lateral decubitus based on EOS imaging: a preliminary study of 13 cases	Pelvic	10	⇨	🔎	
Xie, 2023, CN [142]	A comparison of radiographic outcomes after total hip arthroplasty between the direct lateral approach and posterior lateral approach with EOS 2D/3D X-ray imaging system	Femoral; Pelvic	321	⇦	🔎	🎯
Demzik, 2016, US [143]	Inter-rater and intra-rater repeatability and reliability of EOS 3-dimensional imaging analysis software	Femoral; Pelvic	25	⇦		🎯
Lazennec, 2012, FR [37]	THA Patients in standing and sitting positions: a prospective evaluation using the low-dose "full-body" EOS® imaging system	Femoral; Pelvic; Radiation dose	150	⇨	🔎	
Windsor, 2022, US [144]	Spinopelvic hypermobility corrects after staged bilateral total hip arthroplasty	Pelvic	42	⇦	🔎	
	Hip arthroplasty—acetabular and femoral components					
Loppini, 2017, IT [31]	Femur first surgical technique: a smart non-computer-based procedure to achieve the combined anteversion in primary total hip arthroplasty	Pelvic	40	⇨	🔎	

Author, Year, Country	Title	Clinical Endpoints (Parameters)	Total n	Timeline	Study Type	
Morvan, 2016, FR [32]	Standing radiological analysis with a low-dose biplanar imaging system (EOS system) of the position of the components in total hip arthroplasty using an anterior approach	Femoral; Pelvic	102	⇨	🔎	
Tiberi, 2015, US [145]	What is the fate of total hip arthroplasty (THA) acetabular component orientation when evaluated in the standing position?	Leg length; Pelvic	113	⇦	👁	
	Hip arthroplasty—imaging comparison					
Anderson, 2022, US [146]	Validating the use of 3D biplanar radiography versus CT when measuring femoral anteversion after total hip arthroplasty: a comparative study	Pelvic	45	⇦		🎯
Auberger, 2021, FR [147]	Pelvic position, lying on a traction table, during THA by direct anterior approach. comparison with the standing position and influence on the acetabular cup anteversion	Pelvic	58	⇨	👁	
Brenneis, 2021, GE [148]	Accuracy of preoperative templating in total hip arthroplasty with special focus on stem morphology: a randomized comparison between common digital and three-dimensional planning using biplanar radiographs	Pelvic	51	⇨	RCT	🎯
Buller, 2021, US [149]	EOS imaging is accurate and reproducible for preoperative total hip arthroplasty templating	Femoral; Pelvic	43	⇦		🎯
Esposito, 2020, US [150]	Biplanar low-dose radiography is accurate for measuring combined anteversion after total hip arthroplasty	Femoral; Pelvic	20	⇨	👁	🎯
Guenoun, 2014, FR [36]	Reliability of a new method for evaluating femoral stem positioning after total hip arthroplasty based on stereoradiographic 3D reconstruction	Femoral	30	⇦	👁	🎯
Harold, 2020, US [151]	Are single plane intraoperative and biplanar postoperative radiographic measurements of acetabular cup position the same?	Pelvic	48	⇨	👁	🎯
Lazenne, 2015, FR [152]	Offset and anteversion reconstruction after cemented and uncemented total hip arthroplasty: an evaluation with the low-dose EOS system comparing two- and three-dimensional imaging	Pelvic	110	⇨		🎯
Lazennec, 2011, FR [153]	Pelvis and total hip arthroplasty acetabular component orientations in sitting and standing positions: measurements reproducibility with EOS imaging system versus conventional radiographies	Pelvic	50	⇨		🎯
Ma, 2022, CN [154]	Assessing component orientation of total hip arthroplasty using the low-dose bi-planar radiographs	Pelvic	44	⇦	👁	🎯
Mainard, 2017, FR [155]	Accuracy and reproducibility of preoperative three-dimensional planning for total hip arthroplasty using biplanar low-dose radiographs: a pilot study	Pelvic	31	⇦	👁	🎯
Polkowsk, 2012, US [156]	Does standing affect acetabular component inclination and version after THA?	Pelvic	46	⇦⇨	🔎	
Sun, 2023, US [157]	Validation of a novel method of measuring cup orientation using biplanar simultaneous radiographic images	Pelvic	40	⇨		🎯
Tokunaga, 2018, JP [158]	Implant orientation measurement after THA using the EOS X-ray image acquisition system	Femoral; Pelvic	90	⇨		🎯

Author, Year, Country	Title	Clinical Endpoints (Parameters)	Total n	Timeline	Study Type
	Hip arthroplasty—pelvic positioning and orientation				
Barbier, 2017, FR [159]	Changes In pelvic orientation after total hip arthroplasty: a prospective study with EOS™	Pelvic	40	⇨	🔎
Innmann, 2022, CA [160]	The accuracy in determining pelvic tilt from anteroposterior pelvic radiographs in patients awaiting hip arthroplasty	Pelvic	100	⇨	👁 🎯
Loppini, 2022, IT [161]	Pelvic tilt and functional acetabular position after total hip arthroplasty: an EOS 2D/3D radiographic study	Pelvic	45	⇨	🔎
Premkumar, 2021, US [162]	Variability of pelvic axial rotation in patients undergoing total hip arthroplasty	Pelvic	156	⇨	🔎
	Hip arthroplasty—planning				
Barbier, 2014, FR [163]	The reliability of the anterior pelvic plane for computer navigated acetabular component placement during total hip arthroplasty: prospective study with the EOS imaging system	Pelvic	44	⇨	🔎
Ben-Ari, 2023, US [164]	Calibration of magnification in two-dimensional low-dose full-body imaging for preoperative planning of total hip arthroplasty	Pelvic	137	⇦	👁
Fischer, 2020, JP [165]	Preoperative factors improving the prediction of the postoperative sagittal orientation of the pelvis in standing position after total hip arthroplasty	Health outcomes; Pelvic	196	⇦	🔎
Huang, 2020, HK [166]	A novel method for accurate preoperative templating for total hip arthroplasty using a biplanar digital radiographic (EOS) system	Femoral	41	⇨	🎯
Knafo, 2019, FR [167]	Value of 3D preoperative planning for primary total hip arthroplasty based on biplanar weightbearing radiographs	Femoral; Leg length	33	⇨	🔎 🎯
Pour, 2023, US [168]	Is it necessary to obtain lateral pelvic radiographs in flexed seated position for preoperative total hip arthroplasty planning?	Pelvic	93	⇦	🔎
Sutphen, 2020, US [169]	Treatment of recurrent dislocation after total hip arthroplasty using advanced imaging and three-dimensional modeling techniques: a case series	Pelvic	8	⇦	👁
	Hip arthroplasty—risk factors and safety				
Bendaya, 2016, FR [170]	Good vs poor results after total hip arthroplasty: an analysis method using implant and anatomic parameters with the EOS imaging system	Health outcomes; Leg length; Pelvic	35	⇦	🔎
Esposito, 2018, US [171]	Total hip arthroplasty patients with fixed spinopelvic alignment are at higher risk of hip dislocation	Pelvic; Spinal	1000	⇨	👁
Jang, 2022, US [172]	Abnormal spinopelvic mobility as a risk factor for acetabular placement error in total hip arthroplasty using optical computer-assisted surgical navigation system	Femoral; Pelvic	338	⇨	🎯
Kim, 2022, JP [173]	Low pelvic incidence is a risk factor for intraoperative complications in minimally invasive anterolateral approach for total hip arthroplasty	Femoral, Health outcomes; Pelvic	310	⇦	🔎
Kouyoumdjian, 2023, FR [174]	Influence of kinematics of the lumbopelvic complex in hip arthroplasty dislocation: from assessment to recommendations	Pelvic; Spinal/balance	80	⇨	🔎

Author, Year, Country	Title	Clinical Endpoints (Parameters)	Total n	Timeline	Study Type	
Lazennec, 2011, FR [175]	The EOS imaging system for understanding a patellofemoral disorder following THR	Femoral; Knee; Pelvic	1	⇦	👁	
Lazennec, 2017, FR [176]	Acetabular and femoral anteversions in standing position are outside the proposed safe zone after total hip arthroplasty	Pelvic	66	⇦	🔎	
Perronne, 2021, FR [177]	How is quality of life after total hip replacement related to the reconstructed anatomy? A study with low-dose stereoradiography	Femoral; Health outcomes; Pelvic	123	⇦⇨	🔎	🎯
Reina, 2020, FR [178]	The delta of correction: a novel, more reliable variable than limb-length discrepancy at predicting outcome after total hip arthroplasty	Health outcomes; Leg length	121	⇨	🔎	🎯
Sarpong, 2024, US [179]	Dislocation following anterior and posterior total hip arthroplasty in the setting of spinal deformity and stiffness: evolving trends using a high-risk protocol at a single tertiary center	Leg length; Pelvic; Spinal/balance	367	⇦	👁	🎯
	Hip arthroplasty—spine					
Bassani, 2022, IT [180]	Simultaneous L5-S1 anterior lumbar interbody fusion and total hip arthroplasty through minimally invasive anterior approaches in hip-spine syndrome	Health outcomes; Pelvic; Spinal/balance; Financials/Workflow	1	⇨	👁	
Bizdikian, 2023, LB [181]	Role of bilateral staged hip arthroplasty in hip-spine syndrome: a case report	Gait; Health outcomes; Pelvic; Spinal/balance	1	⇨	👁	
Esposito, 2016, US [182]	Does degenerative lumbar spine disease influence femoroacetabular flexion in patients undergoing total hip arthroplasty?	Femoral; Pelvic; Spinal/balance	242	⇨	👁	
Haffer, 2022, GE [183]	Acetabular cup position differs in spinopelvic mobility types: a prospective observational study of primary total hip arthroplasty patients	Pelvic; Spinal/balance	197	⇨	👁	
Haffer, 2022, GE [184]	Total hip replacement influences spinopelvic mobility: a prospective observational study	Pelvic; Spinal/balance	197	⇨	🔎	
Vigdorchik, 2022, US [185]	Does low back pain improve following total hip arthroplasty?	Health outcomes; Pelvic	500	⇦	🔎	
	Hip arthroplasty—alignment					
Kobayashi, 2020, JP [34]	Association of femoral rotation with whole-body alignment in patients who underwent total hip arthroplasty	Health outcomes; Pelvic; Spinal/balance	65	⇨	🔎	
Haffer, 2021, GE [186]	Does obesity affect acetabular cup position, spinopelvic function and sagittal spinal alignment? A prospective investigation with standing and sitting assessment of primary hip arthroplasty patients	Femoral; Pelvic; Spinal/balance	190	⇦⇨	🔎	
Haffer, 2022, GE [187]	Effect of coronal and sagittal spinal malalignment on spinopelvic mobility in patients undergoing total hip replacement: a prospective observational study	Pelvic; Spinal/balance	197	⇨	🔎	🎯
Shintaro, 2021, JP [188]	Prediction of pelvic mobility using whole-spinal and pelvic alignment in standing and sitting position in total hip arthroplasty patients	Pelvic; Spinal/balance	78	⇦	🔎	
	Hip arthroplasty—leg alignment and length					
Clavé, 2015, FR [189]	Comparison of the reliability of leg length and offset data generated by three hip replacement CAOS systems using EOS™ imaging	Leg length	106	⇦	🔎	🎯

Author, Year, Country	Title	Clinical Endpoints (Parameters)	Total n	Timeline	Study Type	
van Drongelen, 2019, GE [190]	Are changes in radiological leg alignment and femoral parameters after total hip replacement responsible for joint loading during gait?	Femoral; Gait; Health Outcomes; Tibial	37	⇨	🔎	
Di Laura, 2021, UK [191]	Reconstruction of acetabular defects greater than Paprosky Type 3b: the importance of functional imaging	Health outcomes; Pelvic; Leg length	25	⇨	🔎	🎯
Gharanizadeh, 2023, IR [192]	Assessing leg length discrepancy is necessary before arthroplasty in patients with unilateral Crowe Type IV hip dislocation	Femoral; Knee; Leg length; Tibial	61	⇨	👁	
Waibel, 2021, CH [193]	Symptomatic leg length discrepancy after total hip arthroplasty is associated with new onset of lower back pain	Health outcomes; Leg length	79	⇦	👁	
Lazennec, 2018, FR [194]	Does patients' perception of leg length after total hip arthroplasty correlate with anatomical leg length?	Femoral; Foot/ancle; Knee; Leg length; Pelvic	101	⇦	👁	
Lecoanet, 2018, FR [195]	Leg length discrepancy after total hip arthroplasty: can leg length be satisfactorily controlled via anterior approach without a traction table? Evaluation in 56 patients with EOS 3D	Health outcomes; Leg length	56	⇦	🔎	
van Drongelen, 2022, GE [196]	Influence of implantation of a total hip endoprosthesis on the ipsilateral leg alignment: the effect of sex and dysplasia of the hip	Femoral; Knee; Leg length; Pelvic; Tibial	27	⇨	🔎	
	Knee arthroplasty					
Chalmers, 2022, US [197]	Characterizing the magnitude of and risk factors for functional limb lengthening in patients undergoing primary total knee arthroplasty	Knee; Leg length	782	⇦	🔎	
Nam, 2015, US [198]	Planned bone resections using an MRI-based custom cutting guide system versus 3-dimensional, weight-bearing images in total knee arthroplasty	Femoral; Knee; Tibial	53	⇦	👁	
Man, 2024, HK [199]	Accuracy and outcome of a handheld accelerometer-based navigation device compared to conventional alignment method in total knee arthroplasty in a Chinese population	Femoral; Knee; Tibial	123	⇦		🎯
Hau, 2020, UK [200]	Two-dimensional/three-dimensional EOS™ imaging is reliable and comparable to traditional X-ray imaging assessment of knee osteoarthritis aiding surgical management	Femoral; Foot/ankle; Knee; Pelvic; Tibial	20	⇨		🎯
Hurry, 2023, CA [29]	A low-dose biplanar X-ray imager has RSA level precision in total knee arthroplasty	Knee	15	⇨		🎯
Elkins, 2018, US [201]	Lower extremity geometry in morbid obesity-considerations for total knee arthroplasty	Health outcomes; Femoral; Knee; Pelvic; Tibial	232	⇦	👁	
Bahadır, 2018, US [202]	Guidelines for instrumentation for total knee replacement based on frontal plane radiographs	Femoral; Foot/ancle; Knee; Tibial	66	⇦	👁	
Finsterwald, 2021, AU [203]	Accuracy of one-dimensional templating on linear EOS radiography allows template-directed instrumentation in total knee arthroplasty	Femoral; Finan-cials/Workflow; Knee; Tibial	113	⇦		🎯
Ji, 2022, CN [204]	Pre-operative predictive factors of residual varus on the mechanical axis after Oxford unicompartmental knee arthroplasty	Femoral; Health outcomes; Knee; Pelvic; Tibial	880	⇦	🔎	
Vigdorchik, 2020, US [205]	Stiffness after total knee arthroplasty: is it a result of spinal deformity?	Health outcomes; Knee; Pelvic; Spinal/balance	78	⇦	👁	

Author, Year, Country	Title	Clinical Endpoints (Parameters)	Total n	Timeline	Study Type	
Liow, 2016, US [206]	Does 3-dimensional in vivo component rotation affect clinical outcomes in unicompartmental knee arthroplasty?	Femoral; Health outcomes; Knee; Tibial	58	⇐	🔎	
Schlatterer, 2009, MC [207]	Skeletal landmarks for TKR implantations: evaluation of their accuracy using EOS imaging acquisition system	Femoral; Knee	7	?		🎯
	Knee arthroplasty—alignment					
Meijer, 2017, NL [208]	Do CAS measurements correlate with EOS 3D alignment measurements in primary TKA?	Femoral; Knee; Tibial	52	⇒	🔎	🎯
Corbett, 2023, AU [209]	Comparison of CT and EOS in assessing coronal lower limb alignment when planning total knee arthroplasty	Knee; Pelvic; Tibial	96	⇐		🎯
Nam, 2016, US [210]	The impact of imaging modality on the measurement of coronal plane alignment after total knee arthroplasty	Femoral; Knee; Tibial	160	⇐	👁	🎯
Bar Ziv, 2022, IL [211]	Excessive sagittal slope of the tibia component during kinematic alignment-safety and functionality at a minimum 2-year follow-up	Femoral; Health outcomes; Knee; Pelvic; Tibial	337	⇐	🔎	
Bar Ziv, 2022, IL [212]	Minimum 2-year radiographic and clinical outcomes of unrestricted kinematic alignment total knee arthroplasty in patients with excessive varus of the tibia component	Femoral; Health outcomes; Knee; Pelvic; Tibial	338	⇐	🔎	
Kim, 2021, KR [213]	Effects of total knee arthroplasty on coronal and sagittal whole-body alignments: serial assessments using whole-body EOS	Femoral; Pelvic; Spinal/balance; Tibial	101	⇐	🔎	🎯
Meijer, 2014, NL [214]	Assessment of prosthesis alignment after revision total knee arthroplasty using EOS 2D and 3D imaging: a reliability study	Femoral; Knee: Tibial	37	⇐		🎯
Tsai, 2016, US [215]	Three-dimensional imaging analysis of unicompartmental knee arthroplasty evaluated in standing position: component alignment and in vivo articular contact	Femoral; Knee; Tibial	68	⇐	🔎	🎯
Yoo, 2020, KR [216]	Pitfalls in assessing limb alignment affected by rotation and flexion of the knee after total knee arthroplasty: analysis using sagittal and coronal whole-body EOS radiography	Femoral; Knee; Tibial	115	⇐	🔎	
	Shoulder arthroplasty					
Linderman, 2022, US [217]	Return of scapulohumeral rhythm in patients after reverse shoulder arthroplasty: a midterm stereoradiographic imaging analysis	Shoulder	10	⇒	👁	
	Tibial osteotomy					
Yoo, 2023, KR [218]	Changes in parameters after high tibial osteotomy: comparison of EOS system and computed tomographic analysis	Femoral; Knee; Tibial	30	⇒	🔎	🎯
Oh, 2023, KR [219]	Coronal and sagittal alignment of ankle joint is significantly affected by high tibial osteotomy	Femoral; Foot/angle; Knee; Tibial	46	⇐	🔎	

Retrospective study: ⇐
Prospective study: ⇒
Cross-sectional, case-series, case-reports: 👁
Case–control, cohort, non-randomized controlled trials: 🔎
Reliability/accuracy/agreement: 🎯
Randomized controlled trial. RCT

Appendix D. Pediatric Imaging Using EOS Imaging System

Author, Year, Country	Title	Clinical Endpoints (Parameters)	Total n	Timeline	Study Type		Pediatric/Adults	
	Center of mass analysis—fracture							
Sandoz, 2008, FR [220]	Subject-specific mass and 3D localisation of the mass centre of child body segments using biplanar X-rays	Spinal/balance	12	⇇⇉	🔍		😊	👤
	Foot and ankle analysis							
Rampal, 2018, FR [221]	Assessing 3D paediatric foot morphology using low-dose biplanar radiography: parameter reproducibility and preliminary values	Foot/ankle	10	⇉	👁	🎯	😊	
Rungprai, 2014, US [222]	Validation and reproducibility of a biplanar imaging system versus conventional radiography of foot and ankle radiographic parameters	Femoral; Foot/ankle; Leg length; Tibial	50	⇉	🔍	🎯	😊	👤
	Head and neck analysis—cerebral shunt status							
Ben-Sira, 2018, IL [11]	Use of EOS low-dose biplanar X-ray for shunt series in children with hydrocephalus: a preliminary study	Shunt	9	⇇	👁		😊	
Monuszko, 2021, US [19]	Image quality of EOS low-dose radiography in comparison with conventional radiography for assessment of ventriculoperitoneal shunt integrity	Image quality/radiation dose; Shunt	57	⇇	🔍	🎯	😊	👤
	Image quality							
Dubousset, 2005, FR [223]	A new imaging 2D and 3D for musculo-skeletal physiology and pathology with low radiation dose and standing position: the EOS system	Image quality/radiation dose	45	⇉		🎯	😊	
Welborn, 2020, US [224]	Image distortion in biplanar slot scanning: patient-specific factors	Image quality	43	⇇	🔍	🎯	?	
	Image quality—scoliosis							
Hui, 2016, HK [225]	Radiation dose of digital radiography (DR) versus micro-dose X-ray (EOS) on patients with adolescent idiopathic scoliosis: 2016 SOSORT- IRSSD "John Sevastic Award" winner in imaging research	Image quality/radiation dose	131	⇉	🔍		😊	👤
	Lower extremity analysis							
Brooks, 2021, US [226]	Reliability of low-dose biplanar radiography in assessing pediatric torsional pathology	Femoral; Tibial	17	⇇		🎯	😊	
Gaumétou, 2014, FR [227]	EOS analysis of lower extremity segmental torsion in children and young adults	Femoral; Tibial	114	⇇	👁		😊	👤
Ghanem, 2023, LB [228]	Towards a better understanding of knee angular deformities: discrepancies between clinical examination and 2D/3D assessments	Knee	329	⇇	🔍	🎯	😊	👤
Gheno, 2012, FR [229]	Three-dimensional measurements of the lower extremity in children and adolescents using a low-dose biplanar X-ray device	Femoral; Knee; Tibial	27	⇉	🔍	🎯	😊	
Lerisson, 2018, FR [230]	Assessment of micro-dose biplanar radiography in lower limb measurements in children	Femoral; Leg length; Knee; Tibial; Image quality/radiation dose	260	⇉	🔍	🎯	😊	
Meyrignac, 2014, FR [231]	Low-dose biplanar radiography can be used in children and adolescents to accurately assess femoral and tibial torsion and greatly reduce irradiation	Femoral parameters; Tibial parameters	30	⇉	🔍		😊	

Author, Year, Country	Title	Clinical Endpoints (Parameters)	Total n	Timeline	Study Type		Pediatric/Adults	
Ries, 2023, US [232]	Interobserver reliability of biplanar radiography is unaffected by clinical factors relevant to individuals at risk of pathological lower limb torsion	Femoral; Tibial	44	←	🔍	🎯	😊	👤
Rosskopf, 2013, CH [233]	Femoral and tibial torsion measurement in children and adolescents: comparison of 3D models based on low-dose biplanar radiography and low-dose CT	Femoral; Tibial	50	→	🔍	🎯	😊	
Rosskopf, 2017, CH [234]	Femoral and tibial torsion measurements in children and adolescents: comparison of MRI and 3D models based on low-dose biplanar radiographs	Femoral; Tibial	60	←	🔍	🎯	😊	
Schlégl, 2022, HU [235]	Neck-shaft angle measurement in children: accuracy of the conventional radiography-based (2D) methods compared to 3D reconstructions	Femoral	156	←	👁	🎯	😊	
Westberry, 2019, US [236]	3D modeling of lower extremities with biplanar radiographs: reliability of measures on subsequent examinations	Femoral; Knee; Leg length; Pelvic; Tibial	53	←	👁	🎯	😊	
	Lower extremity analysis—bone lesions							
Yucekul, 2022, TR [237]	Prevalence of benign bone lesions of the lower extremity in the pediatric spinal disorders: a whole-body imaging study	Tumor	1378	←	👁	🎯	😊	
	Lower extremity analysis—cerebral palsy							
Assi, 2007, FR [238]	Specific 3D reconstruction for children lower limbs using a low dose biplanar X-ray system. reproducibility of clinical parameters for cerebral palsy patients	Femoral; Knee; Pelvic; Tibial	12	?	🔍	🎯	😊	👤
Assi, 2013, FR [239]	Three-dimensional reconstructions for asymptomatic and cerebral palsy children's lower limbs using a biplanar X-ray system: a feasibility study	Femoral; Leg Length; Tibial	10	→	🔍		😊	
	Lower extremity analysis—x-linked hypophosphatemia							
Bonnet-Lebrun, 2020, FR [240]	Quantitative analysis of lower limbs and pelvis deformities in children with x-linked hypophosphatemic rickets	Femoral; Pelvic; Tibial	75	→	🔍		😊	
	Lower extremity analysis—scoliosis							
Burkus, 2019, HU [241]	Analysis of proximal femoral parameters in adolescent idiopathic scoliosis	Femoral; Spinal/balance	670	←	🔍	🎯	😊	
Karam, 2020, LB [242]	Alterations of 3D acetabular and lower limb parameters in adolescent idiopathic scoliosis	Femoral; Knee; Leg length; Pelvic; Spinal/balance; Tibial	360	←	🔍		😊	
Márkus, 2018, HU [243]	The effect of coronal decompensation on the biomechanical parameters in lower limbs in adolescent idiopathic scoliosis	Femoral; Knee; Leg length; Pelvic; Spinal/balance; Tibial	336	←	🔍	🎯	😊	
	Lower extremity analysis—patellar dislocation							
Miao, 2023, CN [244]	Analysis of lower extremity alignment (LEA) in children with recurrent patellar dislocation by EOS system	Femoral; Knee; Tibial	50	←	🔍		😊	
	Lower extremity analysis—clubfoot							
Rampal, 2020, FR [245]	Combined 3D analysis of lower-limb morphology and function in children with idiopathic equinovarus clubfoot: a preliminary study	Femoral; Foot/ankle; Gait; Pelvic; Tibial	10	→	🔍		😊	

Author, Year, Country	Title	Clinical Endpoints (Parameters)	Total n	Timeline	Study Type		Pediatric/Adults	
	Lower extremity analysis—gait							
Westberry, 2018, US [246]	Femoral anteversion assessment: comparison of physical examination, gait analysis, and EOS biplanar radiography	Femoral; Gait	110					
	Lower extremity analysis—gait—cerebral palsy							
Assi, 2016, LB [247]	Validation of hip joint center localization methods during gait analysis using 3D EOS imaging in typically developing and cerebral palsy children	Pelvic	28					
Bailly, 2021, FR [248]	3-D lower extremity bone morphology in ambulant children with cerebral palsy and its relation to gait	Femoral; Gait; Knee; Leg length; Tibial	523					
Bailly, 2022, FR [249]	Relationship between 3D lower limb bone morphology and 3D gait variables in children with uni and bilateral cerebral palsy	Femoral; Foot/ankle; Gait; Knee; Pelvic; Tibial	121					
	Lower extremity analysis—gait—x-linked hypophosphatemia							
Bonnet-Lebrun, 2023, FR [250]	Combined gait analysis and radiologic examination in children with x-linked hypophosphatemia	Gait; Femoral, Foot/ankle; Knee; Pelvic	55					
	Lower extremity analysis—leg length							
Chen, 2023, US [251]	Normative femoral and tibial lengths in a modern population of twenty-first-century U.S. children	Femoral; Leg length; Tibial	700					
Jensen, 2017, DK [5]	Microdose acquisition in adolescent leg length discrepancy using a low-dose biplane imaging system	Femoral; Leg length; Tibial	22					
Rampal, 2018, FR [252]	Lower-limb lengths and angles in children older than six years: reliability and reference values by EOS(®) stereoradiography	Femoral; Tibial	?					
	Lower extremity analysis—leg length—scoliosis							
Sekiya, 2018, JP [253]	Evaluation of functional and structural leg length discrepancy in patients with adolescent idiopathic scoliosis using the EOS imaging system: a prospective comparative study	Leg length; Pelvic; Spinal/balance	82					
	Pelvis and lower extremity analysis							
Khalifé, 2023, FR [254]	Femoral neck version in the spinopelvic and lower limb 3D alignment: a full-body EOS® study in 400 healthy subjects	Femoral; Foot/ankle; Knee; Pelvic; Spinal/balance	400					
Loppini, 2017, IT [255]	Analysis of the pelvic functional orientation in the sagittal plane: a radiographic study with EOS 2D/3D technology	Pelvic	109					
Passmore, 2018, AU [256]	Defining the medial-lateral axis of the femur: medical imaging, conventional and functional calibration methods lead to differences in hip rotation kinematics for children with torsional deformities	Femoral; Gait; Knee	20					
Prum, 2022, FR [257]	Can early golfing lead to acetabular and lower limb changes? A cross-sectional study	Femoral; Pelvic; Tibial; Pelvic	35					

Author, Year, Country	Title	Clinical Endpoints (Parameters)	Total n	Timeline	Study Type		Pediatric/Adults	
Pytiak, 2016, US [258]	Analysis of spinal alignment and pelvic parameters on upright radiographs: implications for acetabular development	Pelvic; Spinal/balance	99	⇐	👁	🎯	😊	
Rampal, 2013, FR [259]	Three-dimensional morphologic study of the child's hip: which parameters are reproducible?	Pelvic	33	⇒	🔍	🎯	😊	
Schlégl, 2015, HU [260]	Three dimensional radiological imaging of normal lower-limb alignment in children	Femoral; Knee; Tibial	523	⇐	🔍	🎯	😊	
Szuper, 2015, HU [261]	Three-dimensional quantitative analysis of the proximal femur and the pelvis in children and adolescents using an upright biplanar slot-scanning X-ray system	Femoral; Pelvic	508	⇐	🔍	🎯	😊	
	Pelvis and lower extremity analysis—cerebral palsy							
Massaad, 2016, LB [262]	Three-dimensional evaluation of skeletal deformities of the pelvis and lower limbs in ambulant children with cerebral palsy	Femoral; Pelvic; Tibial	49	⇒	🔍		😊	
Neirynck, 2019, BE [263]	The migration percentage measured on EOS® standing full-leg radiographs: equivalent and advantageous in ambulant children with cerebral palsy	Pelvic	21	⇒	🔍	🎯	😊	
Thépaut, 2016, FR [264]	Measuring physiological and pathological femoral anteversion using a biplanar low-dose X-ray system: validity, reliability, and discriminative ability in cerebral palsy	Pelvic parameters	38	⇐	🔍		😊	
	Pelvis and lower extremity analysis—dysplasia							
Powell, 2020, US [265]	Can EOS imaging substitute for conventional radiography in measurement of acetabular morphology in the young dysplastic hip?	Pelvic	21	⇐	🔍	🎯	😊	
	Pelvis and lower extremity analysis—leg length							
Park, 2022, KR [266]	The comparison of lower extremity length and angle between computed radiography-based teleoroentgenogram and EOS ® imaging system	Femoral; Knee; Leg length; Tibial	101	⇐⇒	🔍	🎯	😊	👤
	Pelvis and lower extremity analysis—impingement							
Schmitz, 2013, US [267]	Spectrum of radiographic femoroacetabular impingement morphology in adolescents and young adults: an EOS-based double-cohort study	Pelvic; Spinal/balance	90	⇐	🔍	🎯	😊	👤
	Maturity							
Hughes, 2020, US [268]	The clavicle continues to grow during adolescence and early adulthood	Maturity	57	⇐	🔍	🎯	😊	👤
Nguyen, 2020, US [269]	Hand bone age radiography: comparison between slot-scanning and conventional techniques	Image quality/radiation dose; Maturity	194	⇐	🔍	🎯	😊	
O'Sullivan, 2021, HU [270]	Femoral neck-shaft angle and bone age in 4- to 24-year-olds based on 1005 EOS three-dimensional reconstructions	Femoral; Maturity	1005	⇐	👁		😊	👤
Schlégl, 2017, HU [271]	Determination and correlation of lower limb anatomical parameters and bone age during skeletal growth (based on 1005 cases)	Femoral; Leg length; Maturity; Tibial	1005	⇐	👁	🎯	😊	👤

Author, Year, Country	Title	Clinical Endpoints (Parameters)	Total n	Timeline	Study Type		Pediatric/Adults	
Schlégl, 2022, HU [272]	Alternative methods for skeletal maturity estimation with the EOS scanner-experience from 934 patients	Maturity	934	⇐	👁	🎯	😊	👤
Xie, 2023, CN [273]	Identification of adolescent menarche status using biplanar X-ray images: a deep learning-based method	Maturity	259	⇐	👁	🎯	😊	
	Machine learning							
Vafadar, 2021, FR [274]	A novel dataset and deep learning-based approach for marker-less motion capture during gait	Gait	31	⇒	👁	🎯	😊	
	Machine learning—leg length							
Tsai, 2021, US [275]	Anatomical landmark localization via convolutional neural networks for limb-length discrepancy measurements	Femoral; Leg length; Tibial	359	⇐	👁		😊	👤
	Rib cage geometry and thoracic analysis							
Aubert, 2016, FR [276]	3D reconstruction of rib cage geometry from biplanar radiographs using a statistical parametric model approach	Ribcage/lung; Spinal/balance	79	⇐	👁	🎯	😊	
Khalifé, 2022, FR [277]	The rib cage: a new element in the spinopelvic chain	Pelvic; Ribcage/lung; Spinal/balance; Thoracic	256	⇐	👁		😊	👤
	Rib cage geometry and thoracic analysis—scoliosis							
Assi, 2021, LB [278]	A novel classification of 3D rib cage deformity in subjects with adolescent idiopathic scoliosis	Pelvic; Ribcage/lung; Spinal/balance	271	⇐⇒	🔎		😊	
Bouloussa, 2019, FR [279]	Biplanar stereoradiography predicts pulmonary function tests in adolescent idiopathic scoliosis: a cross-sectional study	Spinal/balance; Ribcage/lung	54	⇒	👁		😊	
Courvoisier, 2013, FR [280]	Evaluation of a three-dimensional reconstruction method of the rib cage of mild scoliotic patients	Spinal parameters/balance; Ribcage/lung parameters	22	⇒	👁	🎯		
Machino, 2020, JP [281]	Accuracy of rib cage parameters from 3-dimensional reconstruction images obtained using simultaneous biplanar radiographic scanning technique in adolescent idiopathic scoliosis: comparison with conventional computed tomography	Ribcage/lung	28	⇒	🔎	🎯	😊	
Vergari, 2020, FR [282]	A novel method of anatomical landmark selection for rib cage 3D reconstruction from biplanar radiography	Ribcage/lung; Spinal/balance	20	⇐	👁	🎯	😊	
Yaszay, 2016, US [283]	The effects of the three-dimensional deformity of adolescent idiopathic scoliosis on pulmonary function	Spinal/balance; Ribcage/lung	163	⇐	👁		😊	
	Spinal and posture analysis—spine							
Clement, 2020, US [284]	What are normal radiographic spine and shoulder balance parameters among adolescent patients?	Spinal parameters/balance; Shoulder parameters	117	⇐	👁		😊	

Retrospective study: ⇐
Prospective study: ⇒
Cross-sectional, case-series, case-reports: 👁
Case–control, cohort, non-randomized controlled trials: 🔎
Reliability/accuracy/agreement: 🎯
Adult: 👤
Pediatric: 😊

Appendix E. Pediatric Surgery Imaging Using EOS Imaging System

Author, Year, Country	Title	Clinical Endpoints (Parameters)	Total n	Timeline	Study Type	Pediatric/Adults
	Lower extremity analysis—fracture					
Boscher, 2022, FR [285]	Femoral shaft fractures treated by antegrade locked intramedullary nailing: EOS stereoradiographic imaging evaluation of rotational malalignment having a functional impact	Femoral; Health outcomes; Pelvic	30	⇨	👁	😊 👤
Orfeuvre, 2021, FR [286]	EOS stereographic assessment of femoral shaft malunion after intramedullary nailing: a prospective series of 48 patients at 9 months' follow-up	Health outcomes; Femoral; Knee; Tibial	48	⇨	👁	😊 👤
Simon, 2018, FR [287]	Pediatric tibial shaft fractures treated by open reduction and stabilization with monolateral external fixation	Knee; Leg length; Maturity	45	⇦	🔎	😊 👤
	Lower extremity analysis—imaging comparison					
Chua, 2022, SG [288]	Accuracy of biplanar linear radiography versus conventional radiographs when used for lower limb and implant measurements	Femoral; Knee; Tibial	43	⇦	🎯	😊 👤
	Lower extremity analysis—leg length					
Lecoanet, 2020, FR [289]	Medium-term evaluation of leg lengthening by ISKD® intramedullary nail in 28 patients: should we still use this lengthening system?	Health outcomes; Leg length	28	⇦	🔎	😊 👤
	Pelvis and lower extremity analysis—Down's syndrome					
Bakouny, 2020, LB [290]	Combining acetabular and femoral morphology improves our understanding of the Down syndrome hip	Femoral; Knee; Pelvic; Tibial	82	⇨	👁	😊 👤
	Rib cage geometry and thoracic analysis—scoliosis					
Deng, 2022, HK [291]	Statistical changes of lung morphology in patients with adolescent idiopathic scoliosis after spinal fusion surgery: a prospective nonrandomized study based on low-dose biplanar X-ray imaging	Ribcage/lung; Spinal/balance	25	⇨	🔎	😊 👤
Machino, 2021, JP [38]	Three-dimensional analysis of preoperative and postoperative rib cage parameters by simultaneous biplanar radiographic scanning technique in adolescent idiopathic scoliosis: minimum 2-year follow-up	Pelvic; Ribcage/lung Spinal/balance	67	⇨	🔎	😊
Machino, 2021, JP [39]	Three-dimensional reconstruction image by biplanar stereoradiography reflects pulmonary functional states in adolescent idiopathic scoliosis	Health outcomes; Ribcage/lung; Spinal/balance	67	⇨	👁	😊
Machino, 2022, JP [40]	Factors affecting postoperative pulmonary function deterioration in adolescent idiopathic scoliosis: a prospective study using 3-dimensional image reconstruction by biplanar stereoradiography	Pelvic; Spinal/balance; Ribcage/lung	67	⇨	👁	😊
Pietton, 2022, FR [292]	Estimating pulmonary function after surgery for adolescent idiopathic scoliosis using biplanar radiographs of the chest with 3D reconstruction	Health outcomes; Ribcage/lung; Spinal/balance	45	⇨	🔎	😊

Author, Year, Country	Title	Clinical Endpoints (Parameters)	Total n	Timeline	Study Type		Pediatric/Adults	
Sabourin, 2010, FR [293]	Three-dimensional stereoradiographic modeling of rib cage before and after spinal growing rod procedures in early-onset scoliosis	Pelvic; Spinal/balance	8					
	Spinal and posture analysis—shoulder							
Ha, 2021, US [294]	Can spinal deformity patients maintain proper arm positions while undergoing full-body X-ray?	Arm positioning	370					
Retrospective study:								
Prospective study:								
Cross-sectional, case-series, case-reports:								
Case–control, cohort, non-randomized controlled trials:								
Reliability/accuracy/agreement:								
Adult:								
Pediatric:								

References

1. Illés, T.; Somoskeöy, S. The EOS™ imaging system and its uses in daily orthopaedic practice. *Int. Orthop.* **2012**, *36*, 1325–1331. [CrossRef] [PubMed]
2. Escott, B.G.; Ravi, B.; Weathermon, A.C.; Acharya, J.; Gordon, C.L.; Babyn, P.S.; Kelley, S.P.; Narayanan, U.G. EOS low-dose radiography: A reliable and accurate upright assessment of lower-limb lengths. *J. Bone Jt. Surg. Am.* **2013**, *95*, e1831–e1837. [CrossRef] [PubMed]
3. McKenna, C.; Wade, R.; Faria, R.; Yang, H.; Stirk, L.; Gummerson, N.; Sculpher, M.; Woolacott, N. EOS 2D/3D X-ray imaging system: A systematic review and economic evaluation. *Health Technol. Assess.* **2012**, *16*, 1–188. [CrossRef]
4. Yvert, M.; Diallo, A.; Bessou, P.; Rehel, J.L.; Lhomme, E.; Chateil, J.F. Radiography of scoliosis: Comparative dose levels and image quality between a dynamic flat-panel detector and a slot-scanning device (EOS system). *Diagn. Interv. Imaging* **2015**, *96*, 1177–1188. [CrossRef]
5. Jensen, J.; Mussmann, B.R.; Hjarbæk, J.; Al-Aubaidi, Z.; Pedersen, N.W.; Gerke, O.; Torfing, T. Microdose acquisition in adolescent leg length discrepancy using a low-dose biplane imaging system. *Acta Radiol.* **2017**, *58*, 1108–1114. [CrossRef] [PubMed]
6. Girdler, S.; Cho, B.; Mikhail, C.M.; Cheung, Z.B.; Maza, N.; Cho, S.K.-W. Emerging Techniques in Diagnostic Imaging for Idiopathic Scoliosis in Children and Adolescents: A Review of the Literature. *World Neurosurg.* **2020**, *136*, 128–135. [CrossRef]
7. Garg, B.; Mehta, N.; Bansal, T.; Malhotra, R. EOS® imaging: Concept and current applications in spinal disorders. *J. Clin. Orthop. Trauma.* **2020**, *11*, 786–793. [CrossRef]
8. Wybier, M.; Bossard, P. Musculoskeletal imaging in progress: The EOS imaging system. *Jt. Bone Spine* **2013**, *80*, 238–243. [CrossRef] [PubMed]
9. Delsole, E.M.; Mercuri, J.J. Utility of Upright Weight-bearing Imaging in Total Hip Arthroplasty. *Semin. Musculoskelet. Radiol.* **2019**, *23*, 603–608. [CrossRef]
10. Hey, H.W.D.; Chan, C.X.; Wong, Y.M.; Sng, J.W.; Ong, H.Y.; Tan, C.S.; Liu, G.K.; Wong, H.K.; Quek, S.T. The Effectiveness of Full-body EOS Compared With Conventional Chest X-ray in Preoperative Evaluation of the Chest for Patients Undergoing Spine Operations: A Preliminary Study. *Spine (Phila Pa 1976)* **2018**, *43*, 1502–1511. [CrossRef]
11. Ben-Sira, L.; Shiran, S.I.; Pratt, L.-T.; Precel, R.; Ovadia, D.; Constantini, S.; Roth, J. Use of EOS Low-Dose Biplanar X-Ray for Shunt Series in Children with Hydrocephalus: A Preliminary Study. *World Neurosurg.* **2018**, *116*, e273–e277. [CrossRef] [PubMed]
12. Peters, M.D.J.; Godfrey, C.; McInerney, P.; Khalil, H.; Larsen, P.; Marnie, C.; Pollock, D.; Tricco, A.C.; Munn, Z. Best practice guidance and reporting items for the development of scoping review protocols. *JBI Evid. Synth.* **2022**, *20*, 953–968. [CrossRef] [PubMed]
13. Aromataris, E.M. JBI Manual for Evidence Synthesis 2020. 2022. Available online: https://synthesismanual.jbi.global (accessed on 19 March 2025).
14. Tricco, A.C.; Lillie, E.; Zarin, W.; O'Brien, K.K.; Colquhoun, H.; Levac, D.; Moher, D.; Peters, M.D.J.; Horsley, T.; Weeks, L.; et al. PRISMA Extension for Scoping Reviews (PRISMA-ScR): Checklist and Explanation. *Ann. Intern. Med.* **2018**, *169*, 467–473. [CrossRef] [PubMed]
15. Brage, K.; Mussmann, B.; Geijer, M.; Larsen, P.; Jensen, J. Clinical application of EOS imaging system: A scoping review protocol. *JBI Evid. Synth.* **2023**, *21*, 1009–1015. [CrossRef]

16. Page, M.J.; McKenzie, J.E.; Bossuyt, P.M.; Boutron, I.; Hoffmann, T.C.; Mulrow, C.D.; Shamseer, L.; Tetzlaff, J.M.; Akl, E.A.; Brennan, S.E.; et al. 2020 statement: An updated guideline for reporting systematic reviews. *BMJ* **2021**, *372*, n71. [CrossRef] [PubMed]
17. Boutry, N.; Dutouquet, B.; Leleu, X.; Vieillard, M.H.; Duhamel, A.; Cotten, A. Low-dose biplanar skeletal survey versus digital skeletal survey in multiple myeloma. *Eur. Radiol.* **2013**, *23*, 2236–2245. [CrossRef]
18. EOS Imaging, EOSedge. Available online: https://www.eos-imaging.com/our-expertise/imaging-solutions/eosedge (accessed on 19 March 2025).
19. Monuszko, K.; Malinzak, M.; Yang, L.Z.; Niedzwiecki, D.; Fuchs, H.; Muh, C.R.; Gingrich, K.; Lark, R.; Thompson, E.M. Image quality of EOS low-dose radiography in comparison with conventional radiography for assessment of ventriculoperitoneal shunt integrity. *J. Neurosurg. Pediatr.* **2021**, *27*, 375–381. [CrossRef]
20. Wade, R.; Yang, H.; McKenna, C.; Faria, R.; Gummerson, N.; Woolacott, N. A systematic review of the clinical effectiveness of EOS 2D/3D X-ray imaging system. *Eur. Spine J.* **2013**, *22*, 296–304. [CrossRef]
21. Hamzian, N.; Roozmand, Z.; Abrisham, S.M.J.; Abdollahi-Dehkordi, S.; Afereydoon, S.; Ghorbani, M.; Deevband, M.R. Monte Carlo evaluation of effective dose and risk of exposure induced cancer death (REID) for common examinations in stereo radiography (EOS) imaging: Considering age and gender. *J. Med. Imaging Radiat. Sci.* **2022**, *53*, 283–290. [CrossRef]
22. Hamzian, N.; Afereydoon, S.; Ghorbani, M.; Abrisham, S.M.J.; Roozmand, Z.; Abdollahi-Dehkordi, S.; Javan, M.S.; Deevband, M.R. Equivalent Dose and Risk of Exposure Induced Cancer Death of Different Organs due to Various Image Techniques of EOS Imaging System. *J. Biomed. Phys. Eng.* **2021**, *11*, 289–296. [CrossRef]
23. Pacult, M.A.; Walker, C.T.; Godzik, J.; Turner, J.D.; Uribe, J.S. Emerging Technologies in Spinal Surgery: Ultra-Low Radiation Imaging Platforms. *Oper. Neurosurg.* **2021**, *21* (Suppl. S1), S39–S45. [CrossRef] [PubMed]
24. Chiron, P.; Demoulin, L.; Wytrykowski, K.; Cavaignac, E.; Reina, N.; Murgier, J. Radiation dose and magnification in pelvic X-ray: EOS™ imaging system versus plain radiographs. *Orthop. Traumatol. Surg. Res.* **2017**, *103*, 1155–1159. [CrossRef] [PubMed]
25. Bragdon, C.H.W. Radiostereometric analysis (RSA) studies at Massachusetts general hospital. *Psychol. Harv. Orthop. J.* **2003**, *5*, 104–107.
26. Lorenzen, N.D.; Stilling, M.; Jakobsen, S.S.; Gustafson, K.; Søballe, K.; Baad-Hansen, T. Marker-based or model-based RSA for evaluation of hip resurfacing arthroplasty? A clinical validation and 5-year follow-up. *Arch. Orthop. Trauma Surg.* **2013**, *133*, 1613–1621. [CrossRef] [PubMed]
27. Jensen, J.; Tromborg, H.B.; Rasmussen, B.S.B.; Gerke, O.; Torfing, T.; Precht, H.; Graumann, O. The effect of forearm rotation on radiographic measurements of the wrist: An experimental study using radiostereometric analyses on cadavers. *Eur. Radiol. Exp.* **2021**, *5*, 15. [CrossRef]
28. Valstar, E.R.; Gill, R.; Ryd, L.; Flivik, G.; Borlin, N.; Karrholm, J. Guidelines for standardization of radiostereometry (RSA) of implants. *Acta Orthop.* **2005**, *76*, 563–572. [CrossRef]
29. Hurry, J.K.; Spurway, A.J.; Laende, E.K.; Rehan, S.; Wilson, J.L.A.; Dunbar, M.J.; El-Hawary, R. A low-dose biplanar X-ray imager has RSA level precision in total knee arthroplasty. *Acta Orthop.* **2023**, *94*, 555–559. [CrossRef]
30. Hurry, J.K.; Rehan, S.; Spurway, A.J.; Laende, E.K.; Wilson, J.L.A.; Logan, K.J.; Dunbar, M.J.; El-Hawary, R. The reliability of radiostereometric analysis in determining physeal motion in slipped capital femoral epiphysis in standard uniplanar and low-dose EOS biplanar radiography: A phantom model study. *J. Pediatr. Orthop. B* **2018**, *27*, 496–502. [CrossRef] [PubMed]
31. Loppini, M.; Longo, U.G.; Caldarella, E.; Rocca, A.D.; Denaro, V.; Grappiolo, G. Femur first surgical technique: A smart non-computer-based procedure to achieve the combined anteversion in primary total hip arthroplasty. *BMC Musculoskelet. Disord.* **2017**, *18*, 331. [CrossRef]
32. Morvan, A.; Combourieu, B.; Pansard, E.; Marmorat, J.L.; Carlier, R.; Judet, T.; Moreau, S.; Lonjon, G. Standing radiological analysis with a low-dose biplanar imaging system (EOS system) of the position of the components in total hip arthroplasty using an anterior approach. *Bone Jt. J.* **2016**, *98*, 326–333. [CrossRef]
33. Kobayashi, D.; Choe, H.; Kobayashi, N.; Watanabe, S.; Inaba, Y. Effects of changes in whole-body alignment on ipsilateral knee pain after total hip arthroplasty. *J. Orthop. Sci. Off. J. Jpn. Orthop. Assoc.* **2023**, *28*, 398–402. [CrossRef] [PubMed]
34. Kobayashi, D.; Choe, H.; Kobayashi, N.; Tezuka, T.; Ike, H.; Inaba, Y. Association of Femoral Rotation With Whole-Body Alignment in Patients Who Underwent Total Hip Arthroplasty. *Arthroplast. Today* **2020**, *6*, 532–537. [CrossRef] [PubMed]
35. Weng, W.; Wu, H.; Wu, M.; Zhu, Y.; Qiu, Y.; Wang, W. The effect of total hip arthroplasty on sagittal spinal-pelvic-leg alignment and low back pain in patients with severe hip osteoarthritis. *Eur. Spine J.* **2016**, *25*, 3608–3614. [CrossRef] [PubMed]
36. Guenoun, B.; El Hajj, F.; Biau, D.; Anract, P.; Courpied, J.P. Reliability of a New Method for Evaluating Femoral Stem Positioning After Total Hip Arthroplasty Based on Stereoradiographic 3D Reconstruction. *J. Arthroplast.* **2015**, *30*, 141–144. [CrossRef] [PubMed]
37. Lazennec, J.Y.; Brusson, A.; Rousseau, M.-A.; Standing, T.H.P.I.; Positions, S. "Full-Body" EOS® Imaging System. *Semin. Arthroplast. JSES* **2012**, *23*, 220–225. [CrossRef]

38. Machino, M.; Kawakami, N.; Ohara, T.; Saito, T.; Tauchi, R.; Imagama, S. Three-Dimensional Analysis of Preoperative and Postoperative Rib Cage Parameters by Simultaneous Biplanar Radiographic Scanning Technique in Adolescent Idiopathic Scoliosis: Minimum 2-Year Follow-Up. *Spine (Phila Pa 1976)* **2021**, *46*, E105–E113. [CrossRef]
39. Machino, M.; Kawakami, N.; Ohara, T.; Saito, T.; Tauchi, R.; Imagama, S. Three-dimensional reconstruction image by biplanar stereoradiography reflects pulmonary functional states inadolescent idiopathic scoliosis. *J. Clin. Neurosci.* **2021**, *88*, 178–184. [CrossRef]
40. Machino, M.; Kawakami, N.; Ohara, T.; Saito, T.; Tauchi, R.; Imagama, S. Factors affecting postoperative pulmonary function deterioration in adolescent idiopathic scoliosis: A prospective study using 3-dimensional image reconstruction by biplanar stereoradiography. *J. Clin. Neurosci.* **2022**, *98*, 182–188. [CrossRef] [PubMed]
41. Ohl, X.; Stanchina, C.; Billuart, F.; Skalli, W. Shoulder bony landmarks location using the EOS low-dose stereoradiography system: A reproducibility study. *Surg. Radiol. Anat.* **2010**, *32*, 153–158. [CrossRef]
42. Zhang, C.; Skalli, W.; Lagacé, P.-Y.; Billuart, F.; Ohl, X.; Cresson, T.; Bureau, N.J.; Rouleau, D.M.; Roy, A.; Tétreault, P.; et al. Investigation of 3D glenohumeral displacements from 3D reconstruction using biplane X-ray images: Accuracy and reproducibility of the technique and preliminary analysis in rotator cuff tear patients. *J. Electromyogr. Kinesiol.* **2016**, *29*, 12–20. [CrossRef]
43. Lempereur, M.; Leboeuf, F.; Brochard, S.; Rémy-Néris, O. Effects of glenohumeral joint centre mislocation on shoulder kinematics and kinetics. *Comput. Methods Biomech. Biomed. Eng.* **2014**, *17*, 130–131. [CrossRef] [PubMed]
44. Lagacé, P.-Y.; Billuart, F.; Ohl, X.; Skalli, W.; Tétreault, P.; de Guise, J.; Hagemeister, N. Analysis of humeral head displacements from sequences of biplanar X-rays: Repeatability study and preliminary results in healthy subjects. *Comput. Methods Biomech. Biomed. Eng.* **2012**, *15*, 221–229. [CrossRef] [PubMed]
45. Amabile, C.; Nérot, A.; Choisne, J.; Pillet, H.; Lafage, V.; Skalli, W. Alignment of centers of mass of body segments with the gravity line. *Comput. Methods Biomech. Biomed. Eng.* **2015**, *18* (Suppl. S1), 1870–1871. [CrossRef] [PubMed]
46. Berg, B.I.; Laville, A.; Courvoisier, D.S.; Rouch, P.; Schouman, T. Experiences with a new biplanar low-dose X-ray device for imaging the facial skeleton: A feasibility study. *PLoS ONE* **2020**, *15*, e0235032. [CrossRef] [PubMed]
47. Kerbrat, A.; Rivals, I.; Dupuy, P.; Dot, G.; Berg, B.I.; Attali, V.; Schouman, T. Biplanar Low-Dose Radiograph Is Suitable for Cephalometric Analysis in Patients Requiring 3D Evaluation of the Whole Skeleton. *J. Clin. Med.* **2021**, *10*, 5477. [CrossRef] [PubMed]
48. Buck, F.M.; Guggenberger, R.; Koch, P.P.; Pfirrmann, C.W. Femoral and tibial torsion measurements with 3D models based on low-dose biplanar radiographs in comparison with standard CT measurements. *AJR Am. J. Roentgenol.* **2012**, *199*, W607–W612. [CrossRef] [PubMed]
49. Cebulski-Delebarre, A.; Boutry, N.; Szymanski, C.; Maynou, C.; Lefebvre, G.; Amzallag-Bellenger, E.; Cotten, A. Correlation between primary flat foot and lower extremity rotational misalignment in adults. *Diagn. Interv. Imaging* **2016**, *97*, 1151–1157. [CrossRef]
50. Clément, J.; Hagemeister, N.; Dumas, R.; Kanhonou, M.; de Guise, J.A. Influence of biomechanical multi-joint models used in global optimisation to estimate healthy and osteoarthritis knee kinematics. *Comput. Methods Biomech. Biomed. Eng.* **2014**, *17* (Suppl. S1), 76–77. [CrossRef]
51. Clément, J.; de Guise, J.A.; Fuentes, A.; Hagemeister, N. Comparison of soft tissue artifact and its effects on knee kinematics between non-obese and obese subjects performing a squatting activity recorded using an exoskeleton. *Gait Posture* **2018**, *61*, 197–203. [CrossRef]
52. Dagneaux, L.; Dufrenot, M.; Bernasconi, A.; Bedard, N.A.; de Cesar Netto, C.; Lintz, F. Three-Dimensional Biometrics to Correlate Hindfoot and Knee Coronal Alignments Using Modern Weightbearing Imaging. *Foot Ankle Int.* **2020**, *41*, 1411–1418. [CrossRef] [PubMed]
53. Dufrénot, M.; Dagneaux, L.; Fernando, C.; Chabrand, P.; Ollivier, M.; Lintz, F. Three-dimensional biometrics using weight-bearing imaging shows relationship between knee and hindfoot axial alignment. *Orthop. Traumatol. Surg. Res.* **2023**, *109*, 103482. [CrossRef] [PubMed]
54. Dumas, R.; Aissaoui, R.; Mitton, D.; Skalli, W.; de Guise, J.A. Determination of personalized inertial parameters of lower limb by biplanar low-dose radiography. *Int. Congr. Ser.* **2004**, *1268*, 19–24. [CrossRef]
55. Dumas, R.; Aissaoui, R.; Mitton, D.; Skalli, W.; de Guise, J.A. Personalized body segment parameters from biplanar low-dose radiography. *IEEE Trans. Biomed. Eng.* **2005**, *52*, 1756–1763. [CrossRef] [PubMed]
56. Guenoun, B.; Zadegan, F.; Aim, F.; Hannouche, D.; Nizard, R. Reliability of a new method for lower-extremity measurements based on stereoradiographic three-dimensional reconstruction. *Orthop. Traumatol. Surg. Res.* **2012**, *98*, 506–513. [CrossRef] [PubMed]
57. Hecker, A.; Lerch, T.D.; Egli, R.J.; Liechti, E.F.; Klenke, F.M. The EOS 3D imaging system reliably measures posterior tibial slope. *J. Orthop. Surg. Res.* **2021**, *16*, 388. [CrossRef]

58. Kümmerlin, J.; Fabro, H.K.; Pedersen, P.H.; Jensen, K.K.; Pedersen, D.; Andersen, M.S. Measuring Knee Joint Laxity in Three Degrees-of-Freedom In Vivo Using a Robotics- and Image-Based Technology. *J. Biomech. Eng.* **2022**, *144*, 084502. [CrossRef] [PubMed]
59. Lo, C.H.; Fang, Y.H.D.; Wang, J.Y.; Yu, T.P.; Chuang, H.C.; Liu, Y.F.; Chang, C.J.; Lin, C.L. Associations between femoral 3D curvature and sagittal imbalance of spine. *JOR Spine* **2024**, *7*, e1305. [CrossRef]
60. Morin, S.N.; Wall, M.; Belzile, E.L.; Godbout, B.; Moser, T.P.; Michou, L.; Ste-Marie, L.-G.; de Guise, J.A.; Rahme, E.; Brown, J.P. Assessment of femur geometrical parameters using EOS™ imaging technology in patients with atypical femur fractures; preliminary results. *Bone* **2016**, *83*, 184–189. [CrossRef]
61. Moon, H.-S.; Choi, C.-H.; Jung, M.; Lee, D.-Y.; Kim, J.-H.; Kim, S.-H. The effect of knee joint rotation in the sagittal and axial plane on the measurement accuracy of coronal alignment of the lower limb. *BMC Musculoskelet. Disord.* **2020**, *21*, 470. [CrossRef]
62. Nam, D.; Shah, R.R.; Nunley, R.M.; Barrack, R.L. Evaluation of the 3-dimensional, weight-bearing orientation of the normal adult knee. *J. Arthroplast.* **2014**, *29*, 906–911. [CrossRef] [PubMed]
63. Serrurier, A.; Quijano, S.; Nizard, R.; Skalli, W. Robust femur condyle disambiguation on biplanar X-rays. *Med. Eng. Phys.* **2012**, *34*, 1433–1440. [CrossRef] [PubMed]
64. Zeighami, A.; Dumas, R.; Bleau, J.; Lavoie, F.; Guise, J.; Aissaoui, R. A method for quantitative evaluation of a valgus knee orthosis using biplane x-ray images. *Annu. Int. Conf. IEEE Eng. Med. Biol. Soc.* **2020**, *2020*, 4815–4818. [PubMed]
65. Cho, B.W.; Lee, T.H.; Kim, S.; Choi, C.H.; Jung, M.; Lee, K.Y.; Kim, S.H. Evaluation of the reliability of lower extremity alignment measurements using EOS imaging system while standing in an even weight-bearing posture. *Sci. Rep.* **2021**, *11*, 22039. [CrossRef]
66. Choi, H.U.; Kim, D.H.; Lee, S.W.; Choi, B.C.; Bae, K.C. Comparison of Lower-Limb Alignment in Patients with Advanced Knee Osteoarthritis: EOS Biplanar Stereoradiography versus Conventional Scanography. *Clin. Orthop. Surg.* **2022**, *14*, 370–376. [CrossRef] [PubMed]
67. Cosentino, A.; Richard, R.; Baron, M.; Demondion, X.; Favre, J.; Omoumi, P. MRI signal and morphological alterations of the suprapatellar fat pad in asymptomatic subjects: Are these normal variants? *Skelet. Radiol.* **2022**, *51*, 1995–2007. [CrossRef]
68. Folinais, D.; Thelen, P.; Delin, C.; Radier, C.; Catonne, Y.; Lazennec, J.Y. Measuring femoral and rotational alignment: EOS system versus computed tomography. *Orthop. Traumatol. Surg. Res.* **2013**, *99*, 509–516. [CrossRef]
69. Mayr, H.O.; Schmidt, J.-P.; Haasters, F.; Bernstein, A.; Schmal, H.; Prall, W.C. Anteversion Angle Measurement in Suspected Torsional Malalignment of the Femur in 3-Dimensional EOS vs Computed Tomography-A Validation Study. *J. Arthroplast.* **2021**, *36*, 379–386. [CrossRef]
70. Narahashi, É.; Guimarães, J.B.; Filho, A.G.O.; Nico, M.A.C.; Silva, F.D. Measurement of tibial slope using biplanar stereoradiography (EOS®). *Skelet. Radiol.* **2024**, *53*, 1091–1101. [CrossRef]
71. Rosskopf, A.B.; Sutter, R.; Pfirrmann, C.W.A.; Buck, F.M. 3D hindfoot alignment measurements based on low-dose biplanar radiographs: A clinical feasibility study. *Skelet. Radiol.* **2019**, *48*, 707–712. [CrossRef]
72. Störmann, S.; Chraga-Urban, A.; Lüring, C.; Bouillon, B.; Gutteck, N.; Arbab, D. Comparison of medial distal tibial angle in EOS imaging and weightbearing X-ray. *Foot Ankle Surg.* **2021**, *27*, 855–859. [CrossRef]
73. Wise, K.L.; Kelly, B.J.; Agel, J.; Marette, S.; Macalena, J.A. Reliability of EOS compared to conventional radiographs for evaluation of lower extremity deformity in adult patients. *Skelet. Radiol.* **2020**, *49*, 1423–1430. [CrossRef] [PubMed]
74. Yan, W.; Xu, X.; Xu, Q.; Yan, W.; Sun, Z.; Jiang, Q.; Shi, D. Femoral and tibial torsion measurements based on EOS imaging compared to 3D CT reconstruction measurements. *Ann. Transl. Med.* **2019**, *7*, 460. [CrossRef] [PubMed]
75. Huang, C.; Chan, P.K.; Chiu, K.Y.; Yan, C.H.; Yeung, S.S.; Fu, S.N. Exploring the relationship between pain intensity and knee moments in participants with medial knee osteoarthritis: A cross-sectional study. *BMC Musculoskelet. Disord.* **2021**, *22*, 685. [CrossRef] [PubMed]
76. Huang, C.; Chan, P.K.; Chiu, K.Y.; Yan, C.H.; Yeung, D.S.S.; Lai, C.W.K.; Fu, S.N. Knee joint loadings are related to tibial torsional alignments in people with radiographic medial knee osteoarthritis. *PLoS ONE* **2021**, *16*, e0255008. [CrossRef] [PubMed]
77. Koliogiannis, V.K.A.; Brandlhuber, M.; Messerschmidt, V.; Stahl, R.; Melcher, C.; Schinner, R.; Birkenmaier, C.; Ricke, J.; Baur-Melnyk, A. Is the EOS imaging system as accurate as conventional radiography in grading osteoarthritis of the knee? *Eur. Radiol.* **2021**, *31*, 3491–3497. [CrossRef]
78. Zeighami, A.; Dumas, R.; Kanhonou, M.; Hagemeister, N.; Lavoie, F.; de Guise, J.A.; Aissaoui, R. Tibio-femoral joint contact in healthy and osteoarthritic knees during quasi-static squat: A bi-planar X-ray analysis. *J. Biomech.* **2017**, *53*, 178–184. [CrossRef]
79. Clavé, A.; Maurer, D.G.; Nagra, N.S.; Fazilleau, F.; Lefèvre, C.; Stindel, E. Reproducibility of length measurements of the lower limb by using EOS™. *Musculoskelet. Surg.* **2018**, *102*, 165–171. [CrossRef] [PubMed]
80. Guggenberger, R.; Pfirrmann, C.W.; Koch, P.P.; Buck, F.M. Assessment of lower limb length and alignment by biplanar linear radiography: Comparison with supine CT and upright full-length radiography. *AJR Am. J. Roentgenol.* **2014**, *202*, W161–W167. [CrossRef]
81. Lazennec, J.Y.; Brusson, A.; Rousseau, M.A.; Robbins, C.B.; Pour, A.E. Do Patients' Perceptions of Leg Length Correlate With Standing 2- and 3-Dimensional Radiographic Imaging? *J. Arthroplast.* **2016**, *31*, 2308–2313. [CrossRef] [PubMed]

82. Abdennebi, A.B.; Aubry, S.; Ounalli, L.; Fayache, M.S.; Delabrousse, E.; Petegnief, Y. Comparative dose levels between CT-scanner and slot-scanning device (EOS system) in pregnant women pelvimetry. *Phys. Med.* **2017**, *33*, 77–86. [CrossRef]
83. Dietrich, T.J.; Pfirrmann, C.W.; Schwab, A.; Pankalla, K.; Buck, F.M. Comparison of radiation dose, workflow, patient comfort and financial break-even of standard digital radiography and a novel biplanar low-dose X-ray system for upright full-length lower limb and whole spine radiography. *Skelet. Radiol.* **2013**, *42*, 959–967. [CrossRef]
84. Wood, L.; Martin, C.; Polly, D.; Luchsinger, S.; Takahashi, T. Incidental extraspinal imaging findings on adult EOS full body radiographs: Prevalence and clinical importance. *BMC Med. Imaging* **2021**, *21*, 83. [CrossRef]
85. Bordes, M.; Thaunat, M.; Maury, É.; Bonin, N.; May, O.; Tardy, N.; Martz, P.; Gedouin, J.-E.; Kouyoumdjian, P.; Krantz, N.; et al. The influence of the sacral slope on pelvic kinematics and clinical manifestations in femoroacetabular impingement. *Orthop. Traumatol. Surg. Res.* **2023**, *109* (Suppl. S8), 103688. [CrossRef] [PubMed]
86. Buckland, A.; DelSole, E.; George, S.; Vira, S.; Lafage, V.; Errico, T.; Vigdorchik, J. Sagittal Pelvic Orientation A Comparison of Two Methods of Measurement. *Bull. Hosp. Jt. Dis.* **2017**, *75*, 234–240.
87. Fritz, B.; Agten, C.A.; Boldt, F.K.; Zingg, P.O.; Pfirrmann, C.W.A.; Sutter, R. Acetabular coverage differs between standing and supine positions: Model-based assessment of low-dose biplanar radiographs and comparison with CT. *Eur. Radiol.* **2019**, *29*, 5691–5699. [CrossRef] [PubMed]
88. Gasparutto, X.; Besonhe, P.; DiGiovanni, P.L.; Armand, S.; Hannouche, D. Definition and reliability of 3D acetabular and global offset measurements from bi-plane X-rays. *Sci. Rep.* **2023**, *13*, 591. [CrossRef] [PubMed]
89. Kim, Y.; Vergari, C.; Girinon, F.; Lazennec, J.Y.; Skalli, W. Stand-to-Sit Kinematics of the Pelvis Is Not Always as Expected: Hip and Spine Pathologies Can Have an Impact. *J. Arthroplast.* **2019**, *34*, 2118–2123. [CrossRef] [PubMed]
90. Mussmann, B.; Jensen, C.; Bensen, A.S.; Torfing, T.; Ovesen, O.; Overgaard, S. Radiographic signs of acetabular retroversion using a low-dose slot-scanning radiographic system (EOS(®)). *Radiography* **2019**, *25*, e53–e57. [CrossRef] [PubMed]
91. Rouissi, J.; Arvieu, R.; Dubory, A.; Vergari, C.; Bachy, M.; Vialle, R. Intra and inter-observer reliability of determining degree of pelvic obliquity in neuromuscular scoliosis using the EOS-CHAIR® protocol. *Childs Nerv. Syst.* **2017**, *33*, 337–341. [CrossRef]
92. Thelen, T.; Thelen, P.; Demezon, H.; Aunoble, S.; Le Huec, J.C. Normative 3D acetabular orientation measurements by the low-dose EOS imaging system in 102 asymptomatic subjects in standing position: Analyses by side, gender, pelvic incidence and reproducibility. *Orthop. Traumatol. Surg. Res.* **2017**, *103*, 209–215. [CrossRef]
93. Bendaya, S.; Lazennec, J.Y.; Anglin, C.; Allena, R.; Sellam, N.; Thoumie, P.; Skalli, W. Healthy vs. osteoarthritic hips: A comparison of hip, pelvis and femoral parameters and relationships using the EOS® system. *Clin. Biomech.* **2015**, *30*, 195–204. [CrossRef] [PubMed]
94. Canetti, R.; de Saint Vincent, B.; Vieira, T.D.; Fière, V.; Thaunat, M. Spinopelvic parameters in greater trochanteric pain syndrome: A retrospective case-control study. *Skelet. Radiol.* **2020**, *49*, 773–778. [CrossRef] [PubMed]
95. Coulomb, R.; Michaud, J.; Maury, E.; Bonin, N.; Krantz, N.; May, O.; Thaunat, M.; Bordes, M.; Tardy, N.; Martz, P.; et al. Radiological signs of femoroacetabular impingement are linked to pelvic version in asymptomatic subjects. *Orthop. Traumatol. Surg. Res.* **2023**, *109*, 103719. [CrossRef] [PubMed]
96. Frasson, V.B.; Herzog, W.; Johnston, K.; Pauchard, Y.; Vaz, M.A.; Baroni, B.M. Do femoral version abnormalities play a role in hip function of patients with hip pain? *Clin. Biomech.* **2022**, *97*, 105708. [CrossRef] [PubMed]
97. Hodel, S.; Flury, A.; Hoch, A.; Zingg, P.O.; Vlachopoulos, L.; Fucentese, S.F. The relationship between pelvic tilt, frontal, and axial leg alignment in healthy subjects. *J. Orthop. Sci.* **2022**, *28*, 1353–1358. [CrossRef] [PubMed]
98. Hodel, S.; Cavalcanti, N.; Fucentese, S.; Vlachopoulos, L.; Viehöfer, A.; Wirth, S. The Relationship between Frontal, Axial Leg Alignment, and Ankle Joint Line Orientation-a Radiographic Analysis of Healthy Subjects. *Orthop. Surg.* **2022**, *15*, 79–84. [CrossRef]
99. Huang, J.; Tian, F.; Zhang, Z.; Shi, W.; Lin, J.; Chen, L.; Yang, H. Reliability and concurrent validity of angle measurements in lower limb: EOS 3D goniometer versus 2D manual goniometer. *J. Orthop. Translat.* **2020**, *24*, 96–102. [CrossRef]
100. Pillet, H.; Sangeux, M.; Hausselle, J.; El Rachkidi, R.; Skalli, W. A reference method for the evaluation of femoral head joint center location technique based on external markers. *Gait Posture* **2014**, *39*, 655–658. [CrossRef]
101. Than, P.; Szuper, K.; Somoskeöy, S.; Warta, V.; Illés, T. Geometrical values of the normal and arthritic hip and knee detected with the EOS imaging system. *Int. Orthop.* **2012**, *36*, 1291–1297. [CrossRef]
102. Vaynrub, M.; Tishelman, J.; Buckland, A.J.; Errico, T.J.; Protopsaltis, T.S. The Ankle-Pelvic Angle (APA) and Global Lower Extremity Angle (GLA): Summary Measurements of Pelvic and Lower Extremity Compensation. *Int. J. Spine Surg.* **2021**, *15*, 130–136. [CrossRef]
103. Ferre, R.; Gibon, E.; Hamadouche, M.; Feydy, A.; Drapé, J.L. Evaluation of a method for the assessment of anterior acetabular coverage and hip joint space width. *Skelet. Radiol.* **2014**, *43*, 599–605. [CrossRef]
104. Krug, K.B.; Weber, C.; Schwabe, H.; Sinzig, N.M.; Wein, B.; Müller, D.; Wegmann, K.; Peters, S.; Sendler, V.; Ewen, K.; et al. Comparison of image quality using a X-ray stereotactical whole-body system and a direct flat-panel X-ray device in examinations of the pelvis and knee. *Rofo* **2014**, *186*, 67–76. [CrossRef] [PubMed]

105. Rosskopf, A.; Pfirrmann, C.; Buck, F.; Rosskopf, A.B.; Pfirrmann, C.W.A.; Buck, F.M. Assessment of two-dimensional (2D) and three-dimensional (3D) lower limb measurements in adults: Comparison of micro-dose and low-dose biplanar radiographs. *Eur. Radiol.* **2016**, *26*, 3054–3062. [CrossRef] [PubMed]
106. Sailhan, F.; Jacob, L.; Hamadouche, M. Differences in limb alignment and femoral mechanical-anatomical angles using two dimension versus three dimension radiographic imaging. *Int. Orthop.* **2017**, *41*, 2009–2016. [CrossRef] [PubMed]
107. Katsumi, R.; Mannen, E.M.; Bajaj, G.; Smith, J.R.; Mears, S.C.; Stambough, J.B.; Barnes, C.L. The Influence of Knee Osteoarthritis on Spinopelvic Alignment and Global Sagittal Balance. *J. Knee Surg.* **2022**, *36*, 917–924. [CrossRef] [PubMed]
108. Kouyoumdjian, P.; Mansour, J.; Haignère, V.; Demattei, C.; Maury, E.; George, D.; Coulomb, R. Hip-Spine Relationship between Sagittal Balance of the Lumbo-Pelvi-Femoral Complex and Hip Extension Capacity: An EOS Evaluation in a Healthy Caucasian Population. *Glob. Spine J.* **2022**, *14*, 265–271. [CrossRef] [PubMed]
109. Lazennec, J.; Brusson, A.; Folinais, D.; Zhang, A.; Pour, A.; Rousseau, M. Measuring extension of the lumbar-pelvic-femoral complex with the EOS system. *Eur. J. Orthop. Surg. Traumatol.* **2015**, *25*, 1061–1068. [CrossRef] [PubMed]
110. Mekhael, M.; Kawkabani, G.; Saliby, R.M.; Skalli, W.; Saad, E.; Jaber, E.; Rachkidi, R.; Kharrat, K.; Kreichati, G.; Ghanem, I.; et al. Toward understanding the underlying mechanisms of pelvic tilt reserve in adult spinal deformity: The role of the 3D hip orientation. *Eur. Spine J.* **2021**, *30*, 2495–2503. [CrossRef] [PubMed]
111. Park, J.Y.; Cho, B.W.; Kwon, H.M.; Park, K.K.; Lee, W.S. Knee Extension Is Related to the Posteriorly Deviated Gravity Line to the Pelvis in Young Adults: Radiographic Analysis Using Low-Dose Biplanar X-ray. *Yonsei Med. J.* **2022**, *63*, 933–940. [CrossRef]
112. Shimizu, T.; Cerpa, M.; Lenke, L.G. Understanding sagittal compensation in adult spinal deformity patients: Relationship between pelvic tilt and lower-extremity position. *J. Neurosurg. Spine* **2021**, *35*, 616–623. [CrossRef] [PubMed]
113. Assi, A.; Rebeyrat, G.; El Rachkidi, R.; Semaan, K.; Saad, E.; Mekhael, E.; Nassim, N.; Massaad, A.; Lafage, V.; Ghanem, I.; et al. ASD with high pelvic retroversion develop changes in their acetabular orientation during walking. *Brain Spine* **2023**, *3*, 101752. [CrossRef] [PubMed]
114. Bakouny, Z.; Assi, A.; Massaad, A.; Saghbini, E.; Lafage, V.; Skalli, W.; Ghanem, I.; Kreichati, G. Roussouly's sagittal spino-pelvic morphotypes as determinants of gait in asymptomatic adult subjects. *Gait Posture* **2017**, *54*, 27–33. [CrossRef]
115. De Pieri, E.; Friesenbichler, B.; List, R.; Monn, S.; Casartelli, N.C.; Leunig, M.; Ferguson, S.J. Subject-Specific Modeling of Femoral Torsion Influences the Prediction of Hip Loading During Gait in Asymptomatic Adults. *Front. Bioeng. Biotechnol.* **2021**, *9*, 679360. [CrossRef] [PubMed]
116. Fu, P.; Xu, W.; Xu, P.; Huang, J.; Guo, J.J. Relationship between spinal imbalance and knee osteoarthritis by using full-body EOS. *BMC Musculoskelet. Disord.* **2023**, *24*, 402. [CrossRef] [PubMed]
117. Huang, C.; Chan, P.K.; Chiu, K.Y.; Yan, C.H.; Yeung, S.S.; Lai, C.W.; Leung, A.K.; Fu, S.N. The association between tibial torsion, knee flexion excursion and foot progression during gait in people with knee osteoarthritis: A cross-sectional study. *BMC Sports Sci. Med. Rehabil.* **2023**, *15*, 110. [CrossRef]
118. Ould-Slimane, M.; Bouyge, B.; Chastan, N.; Ferrand-Devouge, E.; Dujardin, F.; Bertucchi, W.; Michelin, P.; Gillibert, A.; Gauthé, R. Optoelectronic Study of Gait Kinematics in Sagittal Spinopelvic Imbalance. *World Neurosurg.* **2022**, *158*, e956–e963. [CrossRef]
119. Sangeux, M.; Pillet, H.; Skalli, W. Which method of hip joint centre localisation should be used in gait analysis? *Gait Posture* **2014**, *40*, 20–25. [CrossRef] [PubMed]
120. Sauret, C.; Pillet, H.; Skalli, W.; Sangeux, M. On the use of knee functional calibration to determine the medio-lateral axis of the femur in gait analysis: Comparison with EOS biplanar radiographs as reference. *Gait Posture* **2016**, *50*, 180–184. [CrossRef] [PubMed]
121. Südhoff, I.; Van Driessche, S.; Laporte, S.; de Guise, J.A.; Skalli, W. Comparing three attachment systems used to determine knee kinematics during gait. *Gait Posture* **2007**, *25*, 533–543. [CrossRef]
122. van Drongelen, S.; Kaldowski, H.; Fey, B.; Tarhan, T.; Assi, A.; Stief, F.; Meurer, A. Determination of Leg Alignment in Hip Osteoarthritis Patients with the EOS® System and the Effect on External Joint Moments during Gait. *Appl. Sci.* **2020**, *10*, 7777. [CrossRef]
123. Yared, F.; Massaad, A.; Bakouny, Z.; Otayek, J.; Bizdikian, A.J.; Ghanimeh, J.; Labaki, C.; Ghanem, D.; Ghanem, I.; Skalli, W.; et al. Differences in Kinematic Changes From Self-Selected to Fast Speed Gait in Asymptomatic Adults With Radiological Signs of Femoro-Acetabular Impingement. *Cureus* **2023**, *15*, e43733. [CrossRef] [PubMed]
124. Attali, V.; Clavel, L.; Rouch, P.; Rivals, I.; Rémy-Néris, S.; Skalli, W.; Sandoz, B.; Similowski, T. Compensation of Respiratory-Related Postural Perturbation Is Achieved by Maintenance of Head-to-Pelvis Alignment in Healthy Humans. *Front. Physiol.* **2019**, *10*, 441. [CrossRef]
125. Bertrand, S.; Laporte, S.; Parent, S.; Skalli, W.; Mitton, D. Three-dimensional reconstruction of the rib cage from biplanar radiography. *IRBM* **2008**, *29*, 278–286. [CrossRef]
126. Bousigues, S.; Gajny, L.; Abihssira, S.; Heidsieck, C.; Ohl, X.; Hagemeister, N.; Skalli, W. 3D reconstruction of the scapula from biplanar X-rays for pose estimation and morphological analysis. *Med. Eng. Phys.* **2023**, *120*, 104043. [CrossRef] [PubMed]

127. Vergari, C.; Skalli, W.; Clavel, L.; Demuynck, M.; Valentin, R.; Sandoz, B.; Similowski, T.; Attali, V. Functional analysis of the human rib cage over the vital capacity range in standing position using biplanar X-ray imaging. *Comput. Biol. Med.* **2022**, *144*, 105343. [CrossRef] [PubMed]
128. Herrou, J.; Picaud, A.S.; Lassalle, L.; Pacot, L.; Chaussain, C.; Merzoug, V.; Hervé, A.; Gadion, M.; Rothenbuhler, A.; Kamenický, P.; et al. Prevalence of Enthesopathies in Adults With X-linked Hypophosphatemia: Analysis of Risk Factors. *J. Clin. Endocrinol. Metab.* **2022**, *107*, e224–e235. [CrossRef]
129. Fader, R.R.; Tao, M.A.; Gaudiani, M.A.; Turk, R.; Nwachukwu, B.U.; Esposito, C.I.; Ranawat, A.S. The role of lumbar lordosis and pelvic sagittal balance in femoroacetabular impingement. *Bone Jt. J.* **2018**, *100*, 1275–1279. [CrossRef] [PubMed]
130. Ferenczi, A.; Moraux, A.; Gall, F.L.; Thevenon, A.; Wieczorek, V. Relationship Between Spinal-Pelvic Sagittal Balance and Pelvic-Femoral Injuries in Professional Soccer Players. *Orthop. J. Sports Med.* **2020**, *8*, 2325967119894962. [CrossRef]
131. Hey, H.W.D.; Tan, J.H.; Ong, B.; Kumar, A.; Liu, G.; Wong, H.K. Pelvic and sacral morphology and their correlation with pelvic incidence, lumbar lordosis, and lumbar alignment changes between standing and sitting postures. *Clin. Neurol. Neurosurg.* **2021**, *211*, 107019. [CrossRef]
132. Amabile, C.; Le Huec, J.C.; Skalli, W. Invariance of head-pelvis alignment and compensatory mechanisms for asymptomatic adults older than 49 years. *Eur. Spine J.* **2018**, *27*, 458–466. [CrossRef]
133. Okamoto, M.; Jabour, F.; Sakai, K.; Hatsushikano, S.; Le Huec, J.C.; Hasegawa, K. Sagittal balance measures are more reproducible when measured in 3D vs in 2D using full-body EOS® images. *Eur. Radiol.* **2018**, *28*, 4570–4577. [CrossRef] [PubMed]
134. Park, P.J.; Hassan, F.M.; Ferrer, X.E.; Morrissette, C.; Lee, N.J.; Cerpa, M.; Sardar, Z.M.; Kelly, M.P.; Bourret, S.; Hasegawa, K.; et al. The Posterior Cranial Vertical Line: A Novel Radiographic Marker for Classifying Global Sagittal Alignment. *Neurospine* **2023**, *20*, 790–797. [CrossRef] [PubMed]
135. Cauchon, A.M.; Tétreault, P.; Bascans, C.; Skalli, W.; Hagemeister, N. Morphologic and radiologic parameters correlating to shoulder function at diagnosis for patients with rotator cuff tear. *J. Shoulder Elb. Surg.* **2020**, *29*, 2272–2281. [CrossRef] [PubMed]
136. Kaneko, K.; Aota, Y.; Sekiya, T.; Yamada, K.; Saito, T. Validation study of arm positions for evaluation of global spinal balance in EOS imaging. *Eur. J. Orthop. Surg. Traumatol.* **2016**, *26*, 725–733. [CrossRef]
137. Borotikar, B.; Lempereur, M.; Brochard, S.; Rémy-Néris, O.; Leboucher, J.; Leboeuf, F. Effects of gleno-humeral joint centre mislocation on gleno-humeral kinematics and kinetics. *Comput. Methods Biomech. Biomed. Eng.* **2019**, *22*, 764–771.
138. Loisel, F.; Durand, S.; Goubier, J.N.; Bonnet, X.; Rouch, P.; Skalli, W. Three-dimensional reconstruction of the hand from biplanar X-rays: Assessment of accuracy and reliability. *Orthop. Traumatol. Surg. Res.* **2023**, *109*, 103403. [CrossRef]
139. Knafo, J.; Thelen, T.; Verdier, D.; Creppy, L.; Tournier, C.; Fabre, T. Reproducibility of low-dose stereography measurements of femoral torsion after IM nailing of femoral shaft fractures and in intact femurs. *Orthop. Traumatol. Surg. Res.* **2016**, *102*, 595–599. [CrossRef] [PubMed]
140. Verdier, N.; Billaud, A.; Masquefa, T.; Pallaro, J.; Fabre, T.; Tournier, C. EOS-based cup navigation: Randomised controlled trial in 78 total hip arthroplasties. *Orthop. Traumatol. Surg. Res.* **2016**, *102*, 417–421. [CrossRef]
141. Billaud, A.; Verdier, N.; de Bartolo, R.; Lavoinne, N.; Chauveaux, D.; Fabre, T. Acetabular component navigation in lateral decubitus based on EOS imaging: A preliminary study of 13 cases. *Orthop. Traumatol. Surg. Res.* **2015**, *101*, 271–275. [CrossRef]
142. Xie, R.; Huang, J.; Wu, Q.; Qian, Y.F.; Jiang, D.; Li, L.; Huang, L. A Comparison of Radiographic Outcomes after Total Hip Arthroplasty between the Direct Lateral Approach and Posterior Lateral Approach with EOS 2D/3D X-Ray Imaging System. *Orthop. Surg.* **2023**, *15*, 1312–1324. [CrossRef]
143. Demzik, A.L.; Alvi, H.M.; Delagrammaticas, D.E.; Martell, J.M.; Beal, M.D.; Manning, D.W. Inter-Rater and Intra-Rater Repeatability and Reliability of EOS 3-Dimensional Imaging Analysis Software. *J. Arthroplast.* **2016**, *31*, 1091–1095. [CrossRef]
144. Windsor, E.N.; Sculco, P.K.; Mayman, D.J.; Vigdorchik, J.M.; Jerabek, S.A. Spinopelvic Hypermobility Corrects After Staged Bilateral Total Hip Arthroplasty. *Hss J.* **2022**, *18*, 541–549. [CrossRef] [PubMed]
145. Tiberi, J.V., III; Antoci, V.; Malchau, H.; Rubash, H.E.; Freiberg, A.A.; Kwon, Y.M. What is the Fate of Total Hip Arthroplasty (THA) Acetabular Component Orientation When Evaluated in the Standing Position? *J. Arthroplast.* **2015**, *30*, 1555–1560. [CrossRef] [PubMed]
146. Anderson, C.G.; Brilliant, Z.R.; Jang, S.J.; Sokrab, R.; Mayman, D.J.; Vigdorchik, J.M.; Sculco, P.K.; Jerabek, S.A. Validating the use of 3D biplanar radiography versus CT when measuring femoral anteversion after total hip arthroplasty: A comparative study. *Bone Jt. J.* **2022**, *104*, 1196–1201. [CrossRef]
147. Auberger, G.; Pansard, E.; Bouche, P.A.; Marmorat, J.L.; Judet, T.; Lonjon, G. Pelvic position, lying on a traction table, during THA by direct anterior approach. Comparison with the standing position and influence on the acetabular cup anteversion. *Orthop. Traumatol. Surg. Res.* **2021**, *107*, 103077. [CrossRef]
148. Brenneis, M.; Braun, S.; van Drongelen, S.; Fey, B.; Tarhan, T.; Stief, F.; Meurer, A. Accuracy of Preoperative Templating in Total Hip Arthroplasty With Special Focus on Stem Morphology: A Randomized Comparison Between Common Digital and Three-Dimensional Planning Using Biplanar Radiographs. *J. Arthroplast.* **2021**, *36*, 1149–1155. [CrossRef] [PubMed]

149. Buller, L.T.; McLawhorn, A.S.; Maratt, J.D.; Carroll, K.M.; Mayman, D.J. EOS Imaging is Accurate and Reproducible for Preoperative Total Hip Arthroplasty Templating. *J. Arthroplast.* **2021**, *36*, 1143–1148. [CrossRef]
150. Esposito, C.I.; Miller, T.T.; Lipman, J.D.; Carroll, K.M.; Padgett, D.E.; Mayman, D.J.; Jerabek, S.A. Biplanar Low-Dose Radiography Is Accurate for Measuring Combined Anteversion After Total Hip Arthroplasty. *Hss J.* **2020**, *16*, 23–29. [CrossRef] [PubMed]
151. Harold, R.E.; Delagrammaticas, D.; Keller, T.; Butler, B.; Stover, M.D.; Manning, D.W. Are single plane intraoperative and biplanar postoperative radiographic measurements of acetabular cup position the same? *Hip Int.* **2020**, *30*, 530–535. [CrossRef] [PubMed]
152. Lazennec, J.; Brusson, A.; Dominique, F.; Rousseau, M.-A.; Pour, A. Offset and anteversion reconstruction after cemented and uncemented total hip arthroplasty: An evaluation with the low-dose EOS system comparing two- and three-dimensional imaging. *Int. Orthop.* **2015**, *39*, 1259–1267. [CrossRef]
153. Lazennec, J.Y.; Rousseau, M.A.; Rangel, A.; Gorin, M.; Belicourt, C.; Brusson, A.; Catonné, Y. Pelvis and total hip arthroplasty acetabular component orientations in sitting and standing positions: Measurements reproductibility with EOS imaging system versus conventional radiographies. *Orthop. Traumatol. Surg. Res.* **2011**, *97*, 373–380. [CrossRef]
154. Ma, Z.; Tang, H.; Zhou, Y.; Wang, S.; Yang, D.; Guo, S. Assessing component orientation of total hip arthroplasty using the low-dose bi-planar radiographs. *BMC Musculoskelet. Disord.* **2022**, *23*, 886. [CrossRef] [PubMed]
155. Mainard, D.; Barbier, O.; Knafo, Y.; Belleville, R.; Mainard-Simard, L.; Gross, J.B. Accuracy and reproducibility of preoperative three-dimensional planning for total hip arthroplasty using biplanar low-dose radiographs: A pilot study. *Orthop. Traumatol. Surg. Res.* **2017**, *103*, 531–536. [CrossRef] [PubMed]
156. Polkowski, G.; Nunley, R.; Ruh, E.; Williams, B.; Barrack, R. Barrack, Does Standing Affect Acetabular Component Inclination and Version After THA? *Clin. Orthop. Relat. Res.* **2012**, *470*, 2988–2994. [CrossRef] [PubMed]
157. Sun, D.C.; Murphy, W.S.; Amundson, A.J.; Lane, P.M.; Kowal, J.H.; Murphy, S.B. Validation of a Novel Method of Measuring Cup Orientation Using BiPlanar Simultaneous Radiographic Images. *J. Arthroplast.* **2023**, *38*, S252–S256. [CrossRef]
158. Tokunaga, K.; Okamoto, M.; Watanabe, K. Implant Orientation Measurement After THA Using the EOS X-Ray Image Acquisition System. *Adv. Exp. Med. Biol.* **2018**, *1093*, 335–343.
159. Barbier, O.; Skalli, W.; Mainard, D. Changes In Pelvic Orientation After Total Hip Arthroplasty: A Prospective Study With EOS™. *Acta Orthop. Belg.* **2017**, *83*, 360–366.
160. Innmann, M.M.; McGoldrick, N.P.; Ratra, A.; Merle, C.; Grammatopoulos, G. The accuracy in determining pelvic tilt from anteroposterior pelvic radiographs in patients awaiting hip arthroplasty. *J. Orthop. Res.* **2022**, *40*, 854–861. [CrossRef] [PubMed]
161. Loppini, M.; Pisano, A.; Ruggeri, R.; Della Rocca, A.; Grappiolo, G. Pelvic tilt and functional acetabular position after total hip arthroplasty: An EOS 2D/3D radiographic study. *HIP Int.* **2022**, *33*, 365–370. [CrossRef]
162. Premkumar, A.; Almeida, B.; Ranawat, C.S.; Jerabek, S.A.; Esposito, C.I.; Mayman, D.J. Variability of pelvic axial rotation in patients undergoing total hip arthroplasty. *HIP Int.* **2021**, *31*, 215–222. [CrossRef]
163. Barbier, O.; Skalli, W.; Mainard, L.; Mainard, D. The reliability of the anterior pelvic plane for computer navigated acetabular component placement during total hip arthroplasty: Prospective study with the EOS imaging system. *Orthop. Traumatol. Surg. Res.* **2014**, *100* (Suppl. S6), S287–S291. [CrossRef] [PubMed]
164. Ben-Ari, E.; Shichman, I.; Sissman, E.; Oakley, C.; Hepinstall, M.; Schwarzkopf, R. Calibration of magnification in two-dimensional low-dose full-body imaging for preoperative planning of total hip arthroplasty. *Arch. Orthop. Trauma. Surg.* **2023**, *143*, 6875–6881. [CrossRef] [PubMed]
165. Fischer, M.C.M.; Tokunaga, K.; Okamoto, M.; Habor, J.; Radermacher, K. Preoperative factors improving the prediction of the postoperative sagittal orientation of the pelvis in standing position after total hip arthroplasty. *Sci. Rep.* **2020**, *10*, 15944. [CrossRef] [PubMed]
166. Huang, J.; Zhu, Y.; Ma, W.; Zhang, Z.; Shi, W.; Lin, J. A Novel Method for Accurate Preoperative Templating for Total Hip Arthroplasty Using a Biplanar Digital Radiographic (EOS) System. *JBJS Open Access* **2020**, *5*, e20.00078. [CrossRef]
167. Knafo, Y.; Houfani, F.; Zaharia, B.; Egrise, F.; Clerc-Urmès, I.; Mainard, D. Value of 3D Preoperative Planning for Primary Total Hip Arthroplasty Based on Biplanar Weightbearing Radiographs. *Biomed. Res. Int.* **2019**, *2019*, 1932191. [CrossRef] [PubMed]
168. Pour, A.E.; Green, J.H.; Christensen, T.H.; Muthusamy, N.; Schwarzkopf, R. Is It Necessary to Obtain Lateral Pelvic Radiographs in Flexed Seated Position for Preoperative Total Hip Arthro-plasty Planning? *Arthroplast. Today* **2023**, *21*, 101133. [CrossRef] [PubMed]
169. Sutphen, S.A.; Lipman, J.D.; Jerabek, S.A.; Mayman, D.J.; Esposito, C.I. Treatment of Recurrent Dislocation after Total Hip Arthroplasty Using Advanced Imaging and Three-Dimensional Modeling Techniques: A Case Series. *Hss J.* **2020**, *16* (Suppl. S2), 245–255. [CrossRef]
170. Bendaya, S.; Anglin, C.; Lazennec, J.Y.; Allena, R.; Thoumie, P.; Skalli, W. Good vs Poor Results After Total Hip Arthroplasty: An Analysis Method Using Implant and Anatomic Parameters With the EOS Imaging System. *J. Arthroplast.* **2016**, *31*, 2043–2052. [CrossRef]
171. Esposito, C.I.; Carroll, K.M.; Sculco, P.K.; Padgett, D.E.; Jerabek, S.A.; Mayman, D.J. Total Hip Arthroplasty Patients With Fixed Spinopelvic Alignment Are at Higher Risk of Hip Dislocation. *J. Arthroplast.* **2018**, *33*, 1449–1454. [CrossRef]

172. Jang, S.J.; Vigdorchik, J.M.; Windsor, E.W.; Schwarzkopf, R.; Mayman, D.J.; Sculco, P.K. Abnormal spinopelvic mobility as a risk factor for acetabular placement error in total hip arthroplasty using optical computer-assisted surgical navigation system. *Bone Jt. Open* **2022**, *3*, 475–484. [CrossRef]
173. Kim, Y.; Pour, A.E.; Lazennec, J.Y. Low pelvic incidence is a risk factor for intraoperative complications in minimally invasive anterolateral approach for total hip arthroplasty. *Hip Int.* **2022**, *32*, 304–311. [CrossRef] [PubMed]
174. Kouyoumdjian, P.; Mansour, J.; Marouby, S.; Canovas, F.; Dagneaux, L.; Coulomb, R. Influence of kinematics of the lumbopelvic complex in hip arthroplasty dislocation: From assessment to recommendations. *Arch. Orthop. Trauma. Surg.* **2023**, *143*, 4773–4783. [CrossRef] [PubMed]
175. Lazennec, J.Y.; Rangel, A.; Baudoin, A.; Skalli, W.; Catonne, Y.; Rousseau, M.A. The EOS imaging system for understanding a patellofemoral disorder following THR. *Orthop. Traumatol. Surg. Res.* **2011**, *97*, 98–101. [CrossRef] [PubMed]
176. Lazennec, J.Y.; Thauront, F.; Robbins, C.B.; Pour, A.E. Acetabular and Femoral Anteversions in Standing Position are Outside the Proposed Safe Zone After Total Hip Arthroplasty. *J. Arthroplast.* **2017**, *32*, 3550–3556. [CrossRef] [PubMed]
177. Perronne, L.; Haehnel, O.; Chevret, S.; Wybier, M.; Hannouche, D.; Nizard, R.; Bousson, V. How is quality of life after total hip replacement related to the reconstructed anatomy? A study with low-dose stereoradiography. *Diagn. Interv. Imaging* **2021**, *102*, 101–107. [CrossRef]
178. Reina, N.; Hourtal, J.; Salib, C.G.; Gracia, G.; Cavaignac, E.; Chiron, P. The Delta of Correction: A novel, more reliable variable than limb-length discrepancy at predicting outcome after total hip arthroplasty. *Hip Int.* **2020**, *30*, 536–543. [CrossRef] [PubMed]
179. Sarpong, N.O.; Rodriguez, S.; Kuyl, E.V.; Lyman, S.; Della Valle, A.G.; Vigdorchik, J.M.; Rodriguez, J.A. Dislocation Following Anterior and Posterior Total Hip Arthroplasty in the Setting of Spinal Deformity and Stiffness: Evolving Trends Using a High-Risk Protocol at a Single Tertiary Center. *J. Arthroplast.* **2024**, *39*, 1019–1024.e1. [CrossRef]
180. Bassani, R.; Sirtori, P.; Morselli, C.; Cirullo, A.; Ciliberto, R.; Mangiavini, L.; Peretti, G.M. Simultaneous L5-S1 anterior lumbar interbody fusion and total hip arthroplasty through minimally invasive anterior approaches in hip-spine syndrome. *J. Biol. Regul. Homeost. Agents* **2022**, *36*, 239–245. [CrossRef]
181. Bizdikian, A.J.; Assi, A.; Semaan, K.; Otayek, J.; Karam, M.; Massaad, A.; Jaber, E.; Ghanem, I.; El Rachkidi, R. Role of bilateral staged hip arthroplasty in Hip-spine syndrome: A case report. *Medicine* **2023**, *102*, e36296. [CrossRef]
182. Esposito, C.I.; Miller, T.T.; Kim, H.J.; Barlow, B.T.; Wright, T.M.; Padgett, D.E.; Jerabek, S.A.; Mayman, D.J. Does Degenerative Lumbar Spine Disease Influence Femoroacetabular Flexion in Patients Undergoing Total Hip Arthroplasty? *Clin. Orthop. Relat. Res.* **2016**, *474*, 1788–1797. [CrossRef]
183. Haffer, H.; Wang, Z.; Hu, Z.; Hipfl, C.; Pumberger, M. Acetabular cup position differs in spinopelvic mobility types: A prospective observational study of primary total hip arthroplasty patients. *Arch. Orthop. Trauma. Surg.* **2022**, *142*, 2979–2989. [CrossRef]
184. Haffer, H.; Wang, Z.; Hu, Z.; Hipfl, C.; Perka, C.; Pumberger, M. Total Hip Replacement Influences Spinopelvic Mobility: A Prospective Observational Study. *J. Arthroplast.* **2022**, *37*, 316–324.e2. [CrossRef] [PubMed]
185. Vigdorchik, J.M.; Shafi, K.A.; Kolin, D.A.; Buckland, A.J.; Carroll, K.M.; Jerabek, S.A. Does Low Back Pain Improve Following Total Hip Arthroplasty? *J. Arthroplast.* **2022**, *37*, S937–S940. [CrossRef] [PubMed]
186. Haffer, H.; Wang, Z.; Hu, Z.; Becker, L.; Müllner, M.; Hipfl, C.; Pumberger, M.; Palmowski, Y. Does obesity affect acetabular cup position, spinopelvic function and sagittal spinal alignment? A prospective investigation with standing and sitting assessment of primary hip arthroplasty patients. *J. Orthop. Surg. Res.* **2021**, *16*, 640. [CrossRef]
187. Haffer, H.; Wang, Z.; Hu, Z.; Muellner, M.; Hipfl, C.; Pumberger, M. Effect of Coronal and Sagittal Spinal Malalignment on Spinopelvic Mobility in Patients Undergoing Total Hip Replacement: A Prospective Observational Study. *Clin. Spine Surg.* **2022**, *35*, E510–E519. [CrossRef] [PubMed]
188. Shintaro, W.; Hyonmin, C.; Naomi, K.; Hiroyuki, I.; Daigo, K.; Yutaka, I.; Watanabe, S.; Choe, H.; Kobayashi, N.; Ike, H.; et al. Prediction of pelvic mobility using whole-spinal and pelvic alignment in standing and sitting position in total hip arthroplasty patients. *J. Orthop. Surg.* **2021**, *29*, 10225536.
189. Clavé, A.; Fazilleau, F.; Cheval, D.; Williams, T.; Lefèvre, C.; Stindel, E. Comparison of the reliability of leg length and offset data generated by three hip replacement CAOS systems using EOS™ imaging. *Orthop. Traumatol. Surg. Res.* **2015**, *101*, 647–653. [CrossRef] [PubMed]
190. van Drongelen, S.; Kaldowski, H.; Tarhan, T.; Assi, A.; Meurer, A.; Stief, F. Are changes in radiological leg alignment and femoral parameters after total hip replacement responsible for joint loading during gait? *BMC Musculoskelet. Disord.* **2019**, *20*, 526. [CrossRef]
191. Di Laura, A.; Henckel, J.; Gal, E.D.; Monem, M.; Moralidou, M.; Hart, A.J. Reconstruction of acetabular defects greater than Paprosky type 3B: The importance of functional imaging. *BMC Musculoskelet. Disord.* **2021**, *22*, 207. [CrossRef] [PubMed]
192. Gharanizadeh, K.; Mahmoudi, M.; Shiva, F.; Ghazavi, M.; Abolghasemian, M. Assessing Leg Length Discrepancy Is Necessary Before Arthroplasty in Patients With Unilateral Crowe Type IV Hip Dislocation. *Clin. Orthop. Relat. Res.* **2023**, *481*, 1783–1789. [CrossRef]

193. Waibel, F.W.A.; Berndt, K.; Jentzsch, T.; Farei-Campagna, J.; Rahm, S.; Dora, C.; Zingg, P.O. Symptomatic leg length discrepancy after total hip arthroplasty is associated with new onset of lower back pain. *Orthop. Traumatol. Surg. Res.* **2021**, *107*, 102761. [CrossRef] [PubMed]
194. Lazennec, J.Y.; Folinais, D.; Florequin, C.; Pour, A.E. Does Patients' Perception of Leg Length After Total Hip Arthroplasty Correlate With Anatomical Leg Length? *J. Arthroplast.* **2018**, *33*, 1562–1566. [CrossRef]
195. Lecoanet, P.; Vargas, M.; Pallaro, J.; Thelen, T.; Ribes, C.; Fabre, T. Leg length discrepancy after total hip arthroplasty: Can leg length be satisfactorily controlled via anterior approach without a traction table? Evaluation in 56 patients with EOS 3D. *Orthop. Traumatol. Surg. Res.* **2018**, *104*, 1143–1148. [CrossRef] [PubMed]
196. van Drongelen, S.; Fey, B.; Stief, F.; Meurer, A. Influence of implantation of a total hip endoprosthesis on the ipsilateral leg alignment: The effect of sex and dysplasia of the hip. *Arch. Orthop. Trauma Surg* **2022**, *143*, 3541–3549. [CrossRef] [PubMed]
197. Chalmers, B.P.; LaGreca, M.; Addona, J.; Sculco, P.K.; Haas, S.B.; Mayman, D.J. Characterizing the Magnitude of and Risk Factors for Functional Limb Lengthening in Patients Undergoing Primary Total Knee Arthroplasty. *Hss J.* **2022**, *18*, 271–276. [CrossRef] [PubMed]
198. Nam, D.; Williams, B.; Hirsh, J.; Johnson, S.R.; Nunley, R.M.; Barrack, R.L. Planned bone resections using an MRI-based custom cutting guide system versus 3-dimensional, weight-bearing images in total knee arthroplasty. *J. Arthroplast.* **2015**, *30*, 567–572. [CrossRef] [PubMed]
199. Man, S.L.-C.; Chau, W.-W.; Zheng, X.; Ong, M.T.-Y.; Ho, K.K.-W. Accuracy and outcome of a handheld accelerometer-based navigation device compared to conventional alignment method in total knee arthroplasty in a Chinese population, Journal of Orthopaedics. *Trauma. Rehabil.* **2024**, *31*, 34–47. [CrossRef]
200. Hau, M.Y.T.; Menon, D.K.; Chan, R.J.N.; Chung, K.Y.; Chau, W.W.; Ho, K.W. Two-dimensional/three-dimensional EOS™ imaging is reliable and comparable to traditional X-ray imaging assessment of knee osteoarthritis aiding surgical management. *Knee* **2020**, *27*, 970–979. [CrossRef]
201. Elkins, J.M.; Simoens, K.J.; Callaghan, J.J. Lower Extremity Geometry in Morbid Obesity-Considerations for Total Knee Arthroplasty. *J. Arthroplast.* **2018**, *33*, 3304–3312. [CrossRef] [PubMed]
202. Bahadır, T.; Werner, J.; Clair, A.J.; Walker, P.S. Guidelines for Instrumentation for Total Knee Replacement Based on Frontal Plane Radiographs. *Bull. Hosp. Jt. Dis.* **2018**, *76*, 238–245.
203. Finsterwald, M.A.; Sobhi, S.; Isaac, S.; Scott, P.; Khan, R.J.K.; Fick, D.P. Accuracy of one-dimensional templating on linear EOS radiography allows template-directed instrumentation in total knee arthroplasty. *J. Orthop. Surg. Res.* **2021**, *16*, 664. [CrossRef] [PubMed]
204. Ji, S.; Huang, Y.; Zhou, Y.; Wang, C.; Wang, X.; Ma, C.; Jiang, X. Pre-operative predictive factors of residual varus on the mechanical axis after Oxford unicompartmental knee arthroplasty. *Front. Surg.* **2022**, *9*, 1054351. [CrossRef]
205. Vigdorchik, J.M.; Sharma, A.K.; Feder, O.I.; Buckland, A.J.; Mayman, D.J.; Carroll, K.M.; Sculco, P.K.; Long, W.J.; Jerabek, S.A. Stiffness After Total Knee Arthroplasty: Is It a Result of Spinal Deformity? *J. Arthroplast.* **2020**, *35*, S330–S335. [CrossRef] [PubMed]
206. Liow, M.H.; Tsai, T.Y.; Dimitriou, D.; Li, G.; Kwon, Y.M. Does 3-Dimensional In Vivo Component Rotation Affect Clinical Outcomes in Unicompartmental Knee Arthroplasty? *J. Arthroplast.* **2016**, *31*, 2167–2172. [CrossRef] [PubMed]
207. Schlatterer, B.; Suedhoff, I.; Bonnet, X.; Catonne, Y.; Maestro, M.; Skalli, W. Skeletal landmarks for TKR implantations: Evaluation of their accuracy using EOS imaging acquisition system. *Orthop. Traumatol. Surg. Res.* **2009**, *95*, 2–11. [CrossRef] [PubMed]
208. Meijer, M.; Boerboom, A.; Bulstra, S.; Reininga, I.; Stevens, M.; Meijer, M.F.; Boerboom, A.L.; Bulstra, S.K.; Reininga, I.H.F. Do CAS measurements correlate with EOS 3D alignment measurements in primary TKA? *Knee Surg. Sports Traumatol. Arthrosc.* **2017**, *25*, 2894–2903. [CrossRef] [PubMed]
209. Corbett, J.; Tai, J.; Salmon, L.; Roe, J. Comparison of CT and EOS in assessing coronal lower limb alignment when planning total knee arthroplasty. *Knee* **2023**, *42*, 400–408. [CrossRef]
210. Nam, D.; Vajapey, S.; Nunley, R.M.; Barrack, R.L. The Impact of Imaging Modality on the Measurement of Coronal Plane Alignment After Total Knee Arthroplasty. *J. Arthroplast.* **2016**, *31*, 2314–2319. [CrossRef]
211. Ziv, Y.B.; Livshits, G.; Lamykin, K.; Khatib, S.; Sira, Y.B.; Rabau, O.; Shohat, N.; Essa, A. Excessive Sagittal Slope of the Tibia Component during Kinematic Alignment-Safety and Functionality at a Minimum 2-Year Follow-Up. *J. Pers. Med.* **2022**, *12*, 1407.
212. Ziv, Y.B.; Essa, A.; Lamykin, K.; Chacar, N.; Livshits, G.; Khatib, S.; Comaya, Y.; Shohat, N. Minimum 2-Year Radiographic and Clinical Outcomes of Unrestricted Kinematic Alignment Total Knee Arthroplasty in Patients with Excessive Varus of the Tibia Component. *J. Pers. Med.* **2022**, *12*, 1206.
213. Kim, S.C.; Choi, H.G.; Kim, J.S.; Kim, T.W.; Lee, Y.S. Effects of Total Knee Arthroplasty on Coronal and Sagittal Whole-Body Alignments: Serial Assessments Using Whole-Body EOS. *J. Clin. Med.* **2021**, *10*, 3242. [CrossRef] [PubMed]
214. Meijer, M.F.; Boerboom, A.L.; Stevens, M.; Bulstra, S.K.; Reininga, I.H. Assessment of prosthesis alignment after revision total knee arthroplasty using EOS 2D and 3D imaging: A reliability study. *PLoS ONE* **2014**, *9*, e104613. [CrossRef] [PubMed]

215. Tsai, T.-Y.; Dimitriou, D.; Liow, M.H.L.; Rubash, H.E.; Li, G.; Kwon, Y.-M. Three-Dimensional Imaging Analysis of Unicompartmental Knee Arthroplasty Evaluated in Standing Position: Component Alignment and In Vivo Articular Contact. *J. Arthroplast.* **2016**, *31*, 1096–1101. [CrossRef] [PubMed]
216. Yoo, H.J.; Kim, J.E.; Kim, S.C.; Kim, J.S.; Yang, H.J.; Kim, T.W.; Lee, Y.S. Pitfalls in assessing limb alignment affected by rotation and flexion of the knee after total knee arthroplasty: Analysis using sagittal and coronal whole-body EOS radiography. *Knee* **2020**, *27*, 1551–1559. [CrossRef] [PubMed]
217. Linderman, S.E.; Hall, J.R.L.; Johnson, J.E.; Caceres, A.P.; Hettrich, C.M.; Anderson, D.D. Return of Scapulohumeral Rhythm in Patients After Reverse Shoulder Arthroplasty: A Midterm Stereoradiographic Imaging Analysis. *Iowa Orthop. J.* **2022**, *42*, 227–237.
218. Yoo, H.-J.; Choi, J.-K.; Heo, Y.-M.; Moon, S.-J.; Oh, B.-H. Changes in Parameters after High Tibial Osteotomy: Comparison of EOS System and Computed Tomographic Analysis. *J. Clin. Med.* **2023**, *12*, 5638. [CrossRef]
219. Oh, B.H.; Seo, K.D.; Heo, Y.M.; Kim, T.K.; Choi, J.K.; Song, J.H. Coronal and sagittal alignment of ankle joint is significantly affected by high tibial osteotomy. *Knee Surg. Sports Traumatol. Arthrosc.* **2023**, *31*, 4878–4885. [CrossRef]
220. Sandoz, B.; Laporte, S.; Skalli, W.; Mitton, D. Subject-specific mass and 3D localisation of the mass centre of child body segments using biplanar X-rays. *Comput. Methods Biomech. Biomed. Eng.* **2008**, *11*, 203–204. [CrossRef]
221. Rampal, V.; Rohan, P.Y.; Saksik, R.; Wicart, P.; Skalli, W. Assessing 3D paediatric foot morphology using low-dose biplanar radiography: Parameter reproducibility and preliminary values. *Orthop. Traumatol. Surg. Res.* **2018**, *104*, 1083–1089. [CrossRef] [PubMed]
222. Rungprai, C.; Goetz, J.E.; Arunakul, M.; Gao, Y.; Femino, J.E.; Amendola, A.; Phisitkul, P. Validation and reproducibility of a biplanar imaging system versus conventional radiography of foot and ankle radiographic parameters. *Foot Ankle Int.* **2014**, *35*, 1166–1175. [CrossRef]
223. Dubousset, J.; Charpak, G.; Dorion, I.; Skalli, W.; Lavaste, F.; Deguise, J.; Kalifa, G.; Ferey, S. A new 2D and 3D imaging approach to musculoskeletal physiology and pathology with low-dose radiation and the standing position: The EOS system. *Bull. Acad. Natl. Med.* **2005**, *189*, 287–297, discussion 297. [PubMed]
224. Welborn, M.C.; Bouton, D.; Baksh, N.; Degan, T.; Sienko, S. Image Distortion in Biplanar Slot Scanning: Patient-specific Factors. *J. Pediatr. Orthop.* **2020**, *40*, 468–473. [CrossRef] [PubMed]
225. Hui, S.C.; Pialasse, J.P.; Wong, J.Y.; Lam, T.P.; Ng, B.K.; Cheng, J.C.; Chu, W.C. Radiation dose of digital radiography (DR) versus micro-dose x-ray (EOS) on patients with adolescent idiopathic scoliosis: 2016 SOSORT-IRSSD "John Sevastic Award" Winner in Imaging Research. *Scoliosis Spinal Disord.* **2016**, *11*, 46. [CrossRef] [PubMed]
226. Brooks, J.T.; Bomar, J.D.; Jeffords, M.E.; Farnsworth, C.L.; Pennock, A.T.; Upasani, V.V. Reliability of Low-dose Biplanar Radiography in Assessing Pediatric Torsional Pathology. *J. Pediatr. Orthop.* **2021**, *41*, 33–39. [CrossRef]
227. Gaumétou, E.; Quijano, S.; Ilharreborde, B.; Presedo, A.; Thoreux, P.; Mazda, K.; Skalli, W. EOS analysis of lower extremity segmental torsion in children and young adults. *Orthop. Traumatol. Surg. Res.* **2014**, *100*, 147–151. [CrossRef] [PubMed]
228. Ghanem, D.; Ghoul, A.; Assi, A.; Ghanem, I. Towards a better understanding of knee angular deformities: Discrepancies between clinical examination and 2D/3D assessments. *Arch. Orthop. Trauma. Surg.* **2024**, *144*, 1005–1011. [CrossRef] [PubMed]
229. Gheno, R.; Nectoux, E.; Herbaux, B.; Baldisserotto, M.; Glock, L.; Cotten, A.; Boutry, N. Three-dimensional measurements of the lower extremity in children and adolescents using a low-dose biplanar X-ray device. *Eur. Radiol.* **2012**, *22*, 765–771. [CrossRef]
230. Lerisson, H.; Amzallag-Bellenger, É.; Cebulski-Delebarre, A.; Nectoux, E.; Desmulliez, G.; Duhamel, A.; Drumez, E.; Herbaux, B.; Boutry, N. Assessment of micro-dose biplanar radiography in lower limb measurements in children. *Eur. Radiol.* **2018**, *28*, 1778–1787. [CrossRef]
231. Meyrignac, O.; Moreno, R.; Baunin, C.; Vial, J.; Accadbled, F.; Sommet, A.; De Gauzy, J.S.; Sans, N. Low-dose biplanar radiography can be used in children and adolescents to accurately assess femoral and tibial torsion and greatly reduce irradiation. *Eur. Radiol.* **2014**, *25*, 1752–1760. [CrossRef]
232. Ries, A.J.; Duffy, E.A.; Schwartz, M.H.; Novacheck, T.F.; Chau, M.M. Interobserver reliability of biplanar radiography is unaffected by clinical factors relevant to individuals at risk of pathological lower limb torsion. *Gait Posture* **2023**, *100*, 126–131. [CrossRef] [PubMed]
233. Rosskopf, A.B.; Ramseier, L.E.; Sutter, R.; Pfirrmann, C.W.; Buck, F.M. Femoral and tibial torsion measurement in children and adolescents: Comparison of 3D models based on low-dose biplanar radiography and low-dose CT. *AJR Am. J. Roentgenol.* **2014**, *202*, W285–W291. [CrossRef] [PubMed]
234. Rosskopf, A.; Buck, F.; Pfirrmann, C.; Ramseier, L.; Rosskopf, A.B.; Buck, F.M.; Pfirrmann, C.W.A.; Ramseier, L.E. Femoral and tibial torsion measurements in children and adolescents: Comparison of MRI and 3D models based on low-dose biplanar radiographs. *Skelet. Radiol.* **2017**, *46*, 469–476. [CrossRef] [PubMed]
235. Schlégl, Á.T.; Nyakas, V.; Kovács, D.; Maróti, P.; Józsa, G.; Than, P. Neck-shaft angle measurement in children: Accuracy of the conventional radiography-based (2D) methods compared to 3D reconstructions. *Sci. Rep.* **2022**, *12*, 16494.
236. Westberry, D.E.; Carpenter, A.M. 3D Modeling of Lower Extremities With Biplanar Radiographs: Reliability of Measures on Subsequent Examinations. *J. Pediatr. Orthop.* **2019**, *39*, 521–526. [CrossRef] [PubMed]

237. Yucekul, A.; Karaytug, K.; Bakircioglu, S.; Zulemyan, T.; Sirin, B.K.; Karaarslan, E.; Yilgor, C.; Alanay, A. Prevalence of benign bone lesions of the lower extremity in the pediatric spinal disorders: A whole-body imaging study. *J. Pediatr. Orthop. B* **2022**, *31*, 583–590. [CrossRef]
238. Assi, A.; Presedo, A.; Baudoin, A.; Mitton, D.; Ghanem, I.; Skalli, W. Specific 3D reconstruction for children lower limbs using a low dose biplanar X-ray system. Reproducibility of clinical parameters for cerebral palsy patients. *Comput. Methods Biomech. Biomed. Eng.* **2007**, *10*, 27–28. [CrossRef]
239. Assi, A.; Chaibi, Y.; Presedo, A.; Dubousset, J.; Ghanem, I.; Skalli, W. Three-dimensional reconstructions for asymptomatic and cerebral palsy children's lower limbs using a biplanar X-ray system: A feasibility study. *Eur. J. Radiol.* **2013**, *82*, 2359–2364. [CrossRef]
240. Bonnet-Lebrun, A.; Linglart, A.; De Tienda, M.; Ouchrif, Y.; Berkenou, J.; Assi, A.; Wicart, P.; Skalli, W. Quantitative analysis of lower limbs and pelvis deformities in children with X-linked hypophosphatemic rickets. *Orthop. Traumatol. Surg. Res.* **2022**, *109*, 103187. [CrossRef] [PubMed]
241. Burkus, M.; Schlégl, Á.T.; József, K.; O'Sullivan, I.; Márkus, I.; Tunyogi-Csapó, M. Analysis of Proximal Femoral Parameters in Adolescent Idiopathic Scoliosis. *Adv. Orthop.* **2019**, *2019*, 3948595. [CrossRef]
242. Karam, M.; Bizdikian, A.J.; Khalil, N.; Bakouny, Z.; Obeid, I.; Ghanimeh, J.; Labaki, C.; Mjaess, G.; Karam, A.; Skalli, W.; et al. Alterations of 3D acetabular and lower limb parameters in adolescent idiopathic scoliosis. *Eur. Spine J.* **2020**, *29*, 2010–2017. [CrossRef] [PubMed]
243. Márkus, I.; Schlégl, Á.T.; Burkus, M.; József, K.; Niklai, B.; Than, P.; Tunyogi-Csapó, M. The effect of coronal decompensation on the biomechanical parameters in lower limbs in adolescent idiopathic scoliosis. *Orthop. Traumatol. Surg. Res.* **2018**, *104*, 609–616. [CrossRef] [PubMed]
244. Miao, M.; Cai, H.; Zhang, L.; Cai, H. Analysis of lower extremity alignment (LEA) in children with recurrent patellar dislocation by EOS system. *Front. Pediatr.* **2023**, *11*, 1291739. [CrossRef] [PubMed]
245. Rampal, V.; Rohan, P.Y.; Pillet, H.; Bonnet-Lebrun, A.; Fonseca, M.; Desailly, E.; Wicart, P.; Skalli, W. Combined 3D analysis of lower-limb morphology and function in children with idiopathic equinovarus clubfoot: A preliminary study. *Orthop. Traumatol. Surg. Res.* **2020**, *106*, 1333–1337. [CrossRef] [PubMed]
246. Westberry, D.E.; Wack, L.I.; Davis, R.B.; Hardin, J.W. Femoral anteversion assessment: Comparison of physical examination, gait analysis, and EOS biplanar radiography. *Gait Posture* **2018**, *62*, 285–290. [CrossRef] [PubMed]
247. Assi, A.; Sauret, C.; Massaad, A.; Bakouny, Z.; Pillet, H.; Skalli, W.; Ghanem, I. Validation of hip joint center localization methods during gait analysis using 3D EOS imaging in typically developing and cerebral palsy children. *Gait Posture* **2016**, *48*, 30–35. [CrossRef] [PubMed]
248. Bailly, R.; Lempereur, M.; Pons, C.; Houx, L.; Thepaut, M.; Borotikar, B.; Gross, R.; Brochard, S. 3-D lower extremity bone morphology in ambulant children with cerebral palsy and its relation to gait. *Ann. Phys. Rehabil. Med.* **2021**, *64*, 101254. [CrossRef]
249. Bailly, R.; Lempereur, M.; Thepaut, M.; Pons, C.; Houx, L.; Brochard, S. Relationship between 3D lower limb bone morphology and 3D gait variables in children with uni and bilateral Cerebral Palsy. *Gait Posture* **2022**, *92*, 51–59. [CrossRef] [PubMed]
250. Bonnet-Lebrun, A.; Linglart, A.; De Tienda, M.; Khac, V.N.; Ouchrif, Y.; Berkenou, J.; Pillet, H.; Assi, A.; Wicart, P.; Skalli, W. Combined gait analysis and radiologic examination in children with X-linked hypophosphatemia. *Clin. Biomech.* **2023**, *105*, 105974. [CrossRef]
251. Chen, C.; Milbrandt, T.A.; Babadi, E.; Duong, S.Q.; Larson, D.R.; Shaughnessy, W.J.; Stans, A.A.; Hull, N.C.; Peterson, H.A.; Larson, A.N. Normative Femoral and Tibial Lengths in a Modern Population of Twenty-First-Century U.S. Children. *J. Bone Jt. Surg. Am.* **2023**, *105*, 468–478. [CrossRef]
252. Rampal, V.; Rohan, P.Y.; Assi, A.; Ghanem, I.; Rosello, O.; Simon, A.L.; Gaumetou, E.; Merzoug, V.; Skalli, W.; Wicart, P. Lower-limb lengths and angles in children older than six years: Reliability and reference values by EOS(®) stereoradiography. *Orthop. Traumatol. Surg. Res.* **2018**, *104*, 389–395. [CrossRef]
253. Sekiya, T.; Aota, Y.; Yamada, K.; Kaneko, K.; Ide, M.; Saito, T. Evaluation of functional and structural leg length discrepancy in patients with adolescent idiopathic scoliosis using the EOS imaging system: A prospective comparative study. *Scoliosis Spinal Disord.* **2018**, *13*, 7. [CrossRef] [PubMed]
254. Khalifé, M.; Vergari, C.; Rebeyrat, G.; Ferrero, E.; Guigui, P.; Assi, A.; Skalli, W. Femoral neck version in the spinopelvic and lower limb 3D alignment: A full-body EOS(®) study in 400 healthy subjects. *Eur. Spine J.* **2024**, *33*, 1807–1815. [CrossRef]
255. Loppini, M.; Longo, U.G.; Ragucci, P.; Trenti, N.; Balzarini, L.; Grappiolo, G. Analysis of the Pelvic Functional Orientation in the Sagittal Plane: A Radiographic Study With EOS 2D/3D Technology. *J. Arthroplast.* **2017**, *32*, 1027–1032. [CrossRef]
256. Passmore, E.; Graham, H.K.; Sangeux, M. Defining the medial-lateral axis of the femur: Medical imaging, conventional and functional calibration methods lead to differences in hip rotation kinematics for children with torsional deformities. *J. Biomech.* **2018**, *69*, 156–163. [CrossRef] [PubMed]
257. Prum, G.; Sauret, C.; Bourgain, M.; Rouillon, O.; Rouch, P.; Thoreux, P. Can early golfing lead to acetabular and lower limb changes? A cross-sectional study. *Int. J. Sports Sci. Coach.* **2022**, *18*, 270–277. [CrossRef]

258. Pytiak, A.; Bomar, J.D.; Peterson, J.B.; Schmitz, M.R.; Pennock, A.T.; Wenger, D.R.; Upasani, V.V. Analysis of spinal alignment and pelvic parameters on upright radiographs: Implications for acetabular development. *J. Hip Preserv. Surg.* **2016**, *3*, 208–214. [CrossRef]
259. Rampal, V.; Hausselle, J.; Thoreux, P.; Wicart, P.; Skalli, W. Three-dimensional morphologic study of the child's hip: Which parameters are reproducible? *Clin. Orthop. Relat. Res.* **2013**, *471*, 1343–1348. [CrossRef] [PubMed]
260. Schlégl, Á.T.; Szuper, K.; Somoskeöy, S.; Than, P. Three dimensional radiological imaging of normal lower-limb alignment in children. *Int. Orthop.* **2015**, *39*, 2073–2080. [CrossRef]
261. Szuper, K.; Schlégl, Á.; Vermes, C.; Somoskeöy, S.; Than, P.; Leidecker, E. Three-dimensional quantitative analysis of the proximal femur and the pelvis in children and adolescents using an upright biplanar slot-scanning X-ray system. *Pediatr. Radiol.* **2015**, *45*, 411–421. [CrossRef]
262. Massaad, A.; Assi, A.; Bakouny, Z.; Sauret, C.; Khalil, N.; Skalli, W.; Ghanem, I. Three-dimensional evaluation of skeletal deformities of the pelvis and lower limbs in ambulant children with cerebral palsy. *Gait Posture* **2016**, *49*, 102–107. [CrossRef] [PubMed]
263. Neirynck, J.; Proost, R.; Van Campenhout, A. The migration percentage measured on EOS® standing full-leg radiographs: Equivalent and advantageous in ambulant children with cerebral palsy. *BMC Musculoskelet. Disord.* **2019**, *20*, 366. [CrossRef]
264. Thépaut, M.; Brochard, S.; Leboucher, J.; Lempereur, M.; Stindel, E.; Tissot, V.; Borotikar, B.; Borotikar, B.S. Measuring physiological and pathological femoral anteversion using a biplanar low-dose X-ray system: Validity, reliability, and discriminative ability in cerebral palsy. *Skelet. Radiol.* **2016**, *45*, 243–250. [CrossRef]
265. Powell, J.; Gibly, R.F.; Faulk, L.W.; Carry, P.; Mayer, S.W.; Selberg, C.M. Can EOS Imaging Substitute for Conventional Radiography in Measurement of Acetabular Morphology in the Young Dysplastic Hip? *J. Pediatr. Orthop.* **2020**, *40*, 294–299. [CrossRef] [PubMed]
266. Park, K.R.; Lee, J.H.; Kim, D.S.; Ryu, H.; Kim, J.; Yon, C.J.; Lee, S.W. The Comparison of Lower Extremity Length and Angle between Computed Radiography-Based Teleoroentgenogram and EOS(®) Imaging System. *Diagnostics* **2022**, *12*, 1052. [CrossRef] [PubMed]
267. Schmitz, M.R.; Bittersohl, B.; Zaps, D.; Bomar, J.D.; Pennock, A.T.; Hosalkar, H.S. Spectrum of radiographic femoroacetabular impingement morphology in adolescents and young adults: An EOS-based double-cohort study. *J. Bone Jt. Surg. Am.* **2013**, *95*, e90. [CrossRef] [PubMed]
268. Hughes, J.L.; Newton, P.O.; Bastrom, T.; Fabricant, P.D.; Pennock, A.T. The Clavicle Continues to Grow During Adolescence and Early Adulthood. *Hss J.* **2020**, *16* (Suppl. S2), 372–377. [CrossRef] [PubMed]
269. Nguyen, J.C.; Guariento, A.; Nicholson, A.; Nguyen, M.K.; Gendler, L.; Ho-Fung, V.; Zhu, X.; Talwar, D.; Darge, K.; Flynn, J.M.; et al. Hand Bone Age Radiography: Comparison Between Slot-scanning and Conventional Techniques. *J. Pediatr. Orthop.* **2021**, *41*, e167–e173. [CrossRef]
270. O'Sullivan, I.R.; Schégl, Á.T.; Varga, P.; Than, P.; Vermes, C. Femoral neck-shaft angle and bone age in 4- to 24-year-olds based on 1005 EOS three-dimensional reconstructions. *J. Pediatr. Orthop. B* **2021**, *30*, 337–345. [CrossRef]
271. Schlégl, Á.T.; O'Sullivan, I.; Varga, P.; Than, P.; Vermes, C. Determination and correlation of lower limb anatomical parameters and bone age during skeletal growth (based on 1005 cases). *J. Orthop. Res.* **2017**, *35*, 1431–1441. [CrossRef] [PubMed]
272. Schlégl, Á.T.; O'Sullivan, I.; Varga, P.; Than, P.; Vermes, C. Alternative methods for skeletal maturity estimation with the EOS scanner-Experience from 934 patients. *PLoS ONE* **2022**, *17*, e0267668. [CrossRef]
273. Xie, L.; Ge, T.; Xiao, B.; Han, X.; Zhang, Q.; Xu, Z.; He, D.; Tian, W. Identification of Adolescent Menarche Status Using Biplanar X-ray Images: A Deep Learning-Based Method. *Bioengineering* **2023**, *10*, 769. [CrossRef] [PubMed]
274. Vafadar, S.; Skalli, W.; Bonnet-Lebrun, A.; Khalifé, M.; Renaudin, M.; Hamza, A.; Gajny, L. A novel dataset and deep learning-based approach for marker-less motion capture during gait. *Gait Posture* **2021**, *86*, 70–76. [CrossRef] [PubMed]
275. Tsai, A. Anatomical landmark localization via convolutional neural networks for limb-length discrepancy measurements. *Pediatr. Radiol.* **2021**, *51*, 1431–1447. [CrossRef]
276. Aubert, B.; Vergari, C.; Ilharreborde, B.; Courvoisier, A.; Skalli, W. 3D reconstruction of rib cage geometry from biplanar radiographs using a statistical parametric model approach. *Comput. Methods Biomech. Biomed. Eng. Imaging Vis.* **2016**, *4*, 281–295. [CrossRef]
277. Khalifé, M.; Vergari, C.; Ferrero, E.; Attali, V.; Heidsieck, C.; Assi, A.; Skalli, W. The rib cage: A new element in the spinopelvic chain. *Eur. Spine J.* **2022**, *31*, 1457–1467. [CrossRef]
278. Assi, A.; Karam, M.; Skalli, W.; Vergari, C.; Vialle, R.; Pietton, R.; Bizdikian, A.J.; Kharrat, K.; Dubousset, J.; Ghanem, I. A Novel Classification of 3D Rib Cage Deformity in Subjects With Adolescent Idiopathic Scoliosis. *Clin. Spine Surg.* **2021**, *34*, 331–341. [CrossRef] [PubMed]
279. Bouloussa, H.; Pietton, R.; Vergari, C.; Haen, T.X.; Skalli, W.; Vialle, R. Biplanar stereoradiography predicts pulmonary function tests in adolescent idiopathic scoliosis: A cross-sectional study. *Eur. Spine J.* **2019**, *28*, 1962–1969. [CrossRef] [PubMed]

280. Courvoisier, A.; Ilharreborde, B.; Constantinou, B.; Aubert, B.; Vialle, R.; Skalli, W. Evaluation of a Three-Dimensional Reconstruction Method of the Rib Cage of Mild Scoliotic Patients. *Spine Deform.* **2013**, *1*, 321–327. [CrossRef] [PubMed]
281. Machino, M.; Kawakami, N.; Ohara, T.; Saito, T.; Tauchi, R.; Imagama, S. Accuracy of rib cage parameters from 3-Dimensional reconstruction images obtained using simultaneous biplanar radiographic scanning technique in adolescent idiopathic scoliosis: Comparison with conventional computed tomography. *J. Clin. Neurosci.* **2020**, *75*, 94–98. [CrossRef]
282. Vergari, C.; Aubert, B.; Lallemant-Dudek, P.; Haen, T.X.; Skalli, W. A novel method of anatomical landmark selection for rib cage 3D reconstruction from biplanar radiography. *Comput. Methods Biomech. Biomed. Eng. Imaging Vis.* **2020**, *8*, 15–23. [CrossRef]
283. Yaszay, B.; Bastrom, T.; Bartley, C.; Parent, S.; Newton, P.; Bastrom, T.P.; Bartley, C.E.; Newton, P.O. The effects of the three-dimensional deformity of adolescent idiopathic scoliosis on pulmonary function. *Eur. Spine J.* **2017**, *26*, 1658–1664. [CrossRef] [PubMed]
284. Clement, R.C.; Anari, J.; Bartley, C.E.; Bastrom, T.P.; Shah, R.; Talwar, D.; Upasani, V.V. What are normal radiographic spine and shoulder balance parameters among adolescent patients? *Spine Deform.* **2020**, *8*, 621–627. [CrossRef]
285. Boscher, J.; Alain, A.; Vergnenegre, G.; Hummel, V.; Charissoux, J.L.; Marcheix, P.S. Femoral shaft fractures treated by antegrade locked intramedullary nailing: EOS stereoradiographic imaging evaluation of rotational malalignment having a functional impact. *Orthop. Traumatol. Surg. Res.* **2022**, *108*, 103235. [CrossRef]
286. Orfeuvre, B.; Tonetti, J.; Kerschbaumer, G.; Barthelemy, R.; Moreau-Gaudry, A.; Boudissa, M. EOS stereographic assessment of femoral shaft malunion after intramedullary nailing. A prospective series of 48 patients at 9 months' follow-up. *Orthop. Traumatol. Surg. Res.* **2021**, *107*, 102805. [CrossRef] [PubMed]
287. Simon, A.L.; Apostolou, N.; Vidal, C.; Ferrero, E.; Mazda, K.; Ilharreborde, B. Paediatric tibial shaft fractures treated by open reduction and stabilization with monolateral external fixation. *J. Child. Orthop.* **2018**, *12*, 20–28. [CrossRef]
288. Chua, C.X.K.; Tan, S.H.S.; Lim, A.K.S.; Hui, J.H. Accuracy of biplanar linear radiography versus conventional radiographs when used for lower limb and implant measurements. *Arch. Orthop. Trauma. Surg.* **2022**, *142*, 735–745. [CrossRef] [PubMed]
289. Lecoanet, P.; Legallois, Y.; Ribes, C.; Lefevre, Y.; Cadennes, A.; Fabre, T. Medium-term evaluation of leg lengthening by ISKD® intramedullary nail in 28 patients: Should we still use this lengthening system? *Orthop. Traumatol. Surg. Res.* **2020**, *106*, 1433–1440. [CrossRef] [PubMed]
290. Bakouny, Z.; Assi, A.; Yared, F.; Khalil, N.; Mansour, E.; Yaacoub, J.J.; Skalli, W.; Ghanem, I. Combining acetabular and femoral morphology improves our understanding of the down syndrome hip. *Clin. Biomech.* **2018**, *58*, 96–102. [CrossRef]
291. Deng, M.; Chen, Q.; Deng, Q.; Shi, L.; Cheng, C.C.N.; Yeung, K.H.; Zhang, R.; Yu, W.P.F.; Lam, T.P.; Cheng, J.C.Y.; et al. Statistical changes of lung morphology in patients with adolescent idiopathic scoliosis after spinal fusion surgery-a prospective nonrandomized study based on low-dose biplanar X-ray imaging. *Quant. Imaging Med. Surg.* **2022**, *12*, 3325–3339. [CrossRef]
292. Pietton, R.; Bouloussa, H.; Langlais, T.; Taytard, J.; Beydon, N.; Skalli, W.; Vergari, C.; Vialle, R. Estimating pulmonary function after surgery for adolescent idiopathic scoliosis using biplanar radiographs of the chest with 3D reconstruction. *Bone Joint J.* **2022**, *104*, 112–119. [CrossRef] [PubMed]
293. Sabourin, M.; Jolivet, E.; Miladi, L.; Wicart, P.; Rampal, V.; Skalli, W. Three-dimensional stereoradiographic modeling of rib cage before and after spinal growing rod procedures in early-onset scoliosis. *Clin. Biomech.* **2010**, *25*, 284–291. [CrossRef] [PubMed]
294. Ha, A.S.; Lee, N.; Blake, R.; Mathew, J.; Cerpa, M.; Lenke, L.G. Can spinal deformity patients maintain proper arm positions while undergoing full-body X-ray? *Spine Deform.* **2021**, *9*, 387–394. [CrossRef] [PubMed]

Disclaimer/Publisher's Note: The statements, opinions and data contained in all publications are solely those of the individual author(s) and contributor(s) and not of MDPI and/or the editor(s). MDPI and/or the editor(s) disclaim responsibility for any injury to people or property resulting from any ideas, methods, instructions or products referred to in the content.