lymphatics

MDPI

Review

Indolent T- and Natural Killer-Cell Lymphomas and Lymphoproliferative Diseases—Entities in Evolution

Chi Sing Ng

Department of Pathology, Caritas Medical Center, Shamshuipo, Kowloon, Hong Kong; cs.ng3@ha.org.hk; Tel.: +852-3408-7756; Fax: +852-2745-1804

Abstract

Indolent lymphoproliferative diseases or disorders (LPDs) derived from T cells or Natural Killer (NK) cells may be neoplastic or non-neoplastic, which are often difficult to distinguish from each other and from their aggressive counterparts. The etiology and pathogenesis are mostly nebulous and may be related to infections or immune dysfunction. Indolent lymphomas differ from the high-grade aggressive counterparts by a prolonged clinical course of persistent or relapsing disease, histology, immunophenotype, and genetics. In recent decades, indolent lymphomas or LPD of T or NK cell derivation have been increasingly recognized, causing diagnostic and nosologic confusion. The issue is particularly challenging in the arena of indolent intestinal lymphomas and LPD, as evidenced by the myriad of names given to the indolent intestinal T- and NK-cell lymphomas and LPD. Confounding the picture are also reports of Epstein–Barr virus (EBV) positivity in various indolent non-intestinal LPD and, rarely, even in indolent intestinal T-cell lymphoma, which have been widely accepted to be typically EBV-negative. This review aims to curate current information and understanding of these diseases with the goal of resolving these issues. The recently described indolent T-lymphoblastic proliferation (iTLBP) and the re-classified indolent primary cutaneous CD4-positive small or medium T-cell LPDs and primary cutaneous acral CD8-positive T-cell LPDs also require greater awareness and recognition. It is important to diagnose these indolent entities in order to avoid over-treatment and unnecessary therapeutic intervention and to provide for accurate prognostic prediction and appropriate follow-up.

Keywords: indolent; T-/NK-cell; lymphoma; lymphoproliferative diseases; intestinal; EBV

check for updates

Academic Editor: Manlio Ferrarini

Received: 23 October 2025
Revised: 10 November 2025
Accepted: 27 November 2025
Published: 29 November 2025

Citation: Ng, C.S. Indolent T- and Natural Killer-Cell Lymphomas and Lymphoproliferative Diseases—Entities in Evolution. *Lymphatics* **2025**, *3*, 41. https://doi.org/10.3390/lymphatics3040041

Copyright: © 2025 by the author. Licensee MDPI, Basel, Switzerland. This article is an open access article distributed under the terms and conditions of the Creative Commons Attribution (CC BY) license (https://creativecommons.org/licenses/by/4.0/).

1. Introduction

Most primary gastrointestinal (GI) NK- or T-cell lymphomas are aggressive high-grade lymphomas [1]. In the past three decades, there have been reports of indolent T- and NK-cell LPDs of the GI tract, designated by a plethora of names. The myriad names given to these entities reflect the enigma of their biology, behavior, and nosology. These are clonal proliferations and widely accepted to be EBV-negative [2–51]. This compares with their high-grade counterparts, which may be EBV+ (in extranodal NK/T-cell lymphoma of the GI tract-ENNKTL) [52] or EBV− (in monomorphic epitheliotropic intestinal T-cell lymphoma- MEITCL and enteropathy-associated T-cell lymphoma-EATCL) [53–55]. Interestingly, there are also rare reports of EBV positivity in indolent intestinal T-cell lymphoma (iITCL) [7,26,29] and EBV-positive indolent non-intestinal NK- or T-cell LPDs [56–65]. This observation subjects the widely accepted belief that indolent T-cell GI lymphomas (ilTCL) are EBV-negative to question. The reported molecular features of indolent GI LPD also

differ from those of ENNKTL, MEITCL, and EATCL [2–4,7,19,22,25–28,31,32,49,50,52], despite some overlap in alterations of genes related to the JAK/STAT pathway. There are other recently recognized or re-categorized indolent T-cell LPDs, including indolent T-lymphblastic proliferation (iTLBP), primary cutaneous CD4+ small or medium T-cell LPD (PcutCD4+TLPD), and primary cutaneous acral CD8+ T-cell LPD (PcutacCD8+TLPD), that require greater attention [32,66–73]. This review summarizes the hitherto reported clinical, morphologic, and immunophenotypic features; the evolving genetic landscape; and the dubious possible role of EBV in these entities.

2. Indolent Intestinal Lymphoma and LPD

These have received attention in the past three decades. This review retrieved papers on these entities by searching Scopus and Google Scholar for the period 1990 to 2025 with the keywords "indolent, T-cell, NK-cell, lymphoma, lymphoproliferative disease, lymphomatoid gastropathy and enteropathy, intestinal, gastrointestinal, colon". Fifty-six publications were retrieved. The major difficulty for inclusion is the lack of a numerical definition for the durati

n of indolence. "Indolence" linguistically means "laziness", "sluggishness", "languishment", or "lethargia". Medically, an indolent disease is slow-moving, often asymptomatic, and requires no treatment [32]. For the purpose of inclusion in this review, the empirical disease duration of "over one year" was adopted. Based on this empirical inclusion criterion and other keywords used in the search, three case reports/series were excluded because the disease durations were less than 1 year. Five review articles were also excluded because no additional cases of indolent lymphomas or LPD were described. As a result, 48 publications were included for review. A total of 85 cases of indolent intestinal T-cell lymphoma (iITCL) and 58 cases of indolent intestinal NK-cell LPD (iINKLPD) were identified and analyzed.

2.1. Indolent Intestinal T-Cell Lymphoma

This was first described by Carbonnel et al. in 1994 under the name of "extensive small intestinal lymphoma of low-grade malignancy associated with a new chromosomal translocation" [4]. The reported case manifested non-specific abdominal symptoms with insignificant intestinal endoscopic findings. The patient eventually developed acute small bowel obstruction, and the resected small bowel featured dilatation, thickened walls, and multiple 1–2 cm diameter serosal tumors associated with enlarged mesenteric lymph nodes. Small bowel histology revealed massive involvement that was limited to the mucosa by a diffuse infiltrate of small atypical lymphoid cells, associated with multiple non-caseating granulomas. The mesenteric lymph nodes and the liver portal tracts were involved with a similar atypical lymphoid infiltrate. Immunophenotypically, the lymphoid cells were T-cells expressing CD3, CD4, and betaF1, but negative for CD8. There was negligible Ki67 staining. A chromosomal translocation t(4;16)(q26;p13) involving the *interleukin-2 (IL-2)* gene was also detected.

This report was followed by many other similar reports under designations of "small intestinal, gut, GI tract, stomach, indolent T-cell, CD4−positive lymphoma, lymphoprolferative disease" in varying word combinations [4–32]. This great variability in the use of designations reflects uncertainty within the then academia about the nature of this entity. This review collected 85 cases of iITCL. There were 55 males and 30 females, with an age range of 14–80 years and a median age of 50 years. The reported cases had a wide geographic distribution from Europe, Asia, to Africa. As in the case reported in 1994 [4], all presented with non-specific abdominal symptoms, including bloating, pain, diarrhea, and weight loss. One was complicated by intestinal obstruction [4] and another by intestinal perforation [12]. Extraintestinal involvement or metastasis was reported in mesenteric

lymph nodes [4,7,12,14,15,26–29,31,32], liver [4,7], peripheral blood [4,7,12,32], bone marrow [13,14,18,22,32], tonsil [14], lungs [4,7], skin [4,7,32], and epiglottis [32]. In two cases, inguinal lymph node involvement was reported [22], which was unusual, as metastasis to peripheral lymph nodes has been regarded to be very rare or absent in iITCL. The histology of the reported iITCL cases was similar to those described by Carbonnel [4].

2.1.1. Involved Sites and Gross Presentation

iITCL involves mostly the small intestine and the colon. However, other GI sites, including the stomach, esophagus, and oral cavity, may also be involved [5,6,8,10,12–14,16,18,22–24,32]. Multifocal involvement of the GI tract is common [1–32], with gross presentations of polyps, folds, nodules, fissures, or ulcers [1–32].

2.1.2. Histology

iITCL is characterized by non-destructive, partial involvement of the intestinal wall, often restricted to the lamina propria of the mucosa. A proportion of cases, however, may also show an involvement of the muscularis mucosae or submucosa. There is usually no epitheliotropism, and the surface and glandular epithelium are usually spared. In some cases, there are non-caseating granulomas or conspicuous eosinophils [2,4–32]. The infiltrate is typically composed of atypical small to medium lymphoid cells with irregular dark nuclei and infrequent mitotic activity. There is no angiocentricity or angioinvasion (Figure 1) [2,4–32].

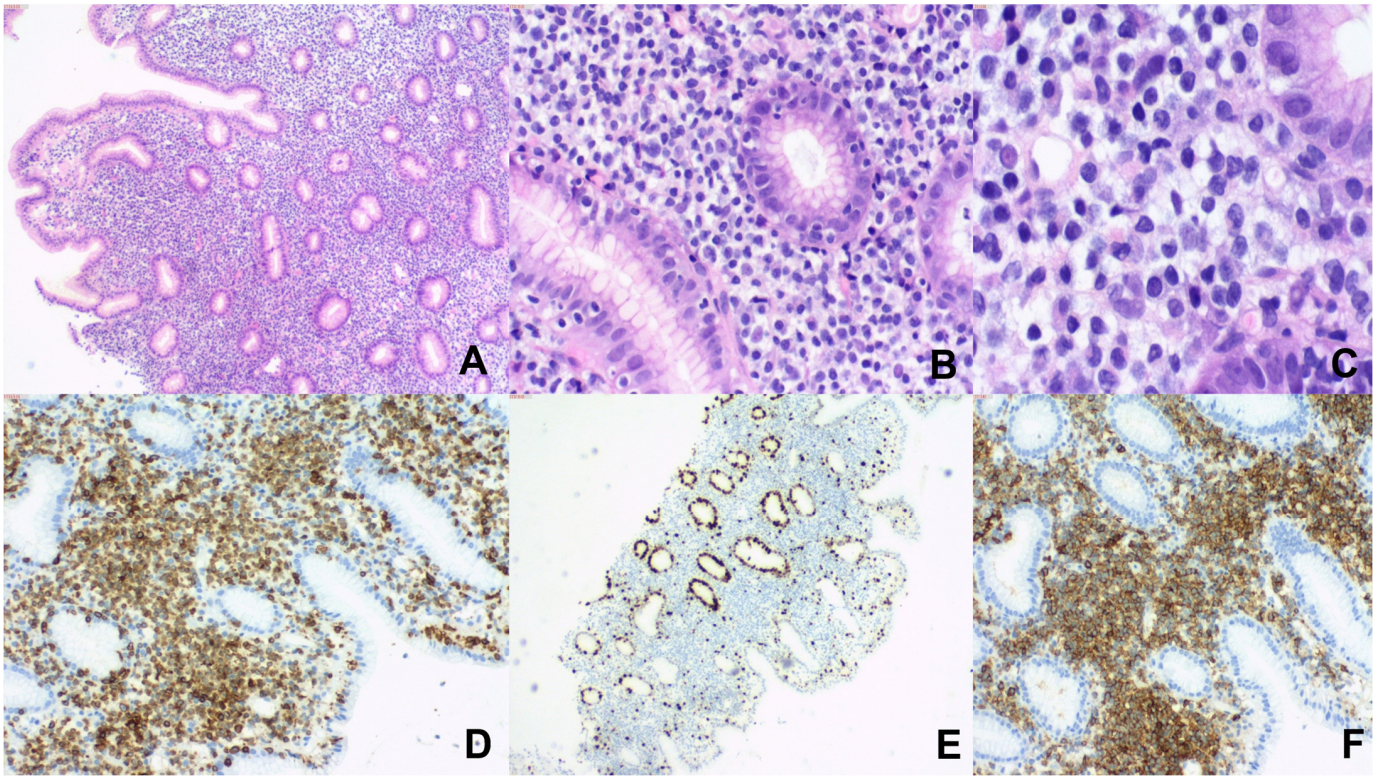

Figure 1. (**A**) Male, 46 years, vague abdominal symptoms. Multifocal GI involvement. Colonic biopsy. (**A**) Non-destructive mucosal atypical lymphoid infiltrates. The glands were displaced but not invaded by the infiltrates. H&E, ×50. (**B**,**C**) Mucosal small atypical lymphoid cells infiltrate. Focal intraepithelial involvement is present. The atypical cells showed mildly enlarged and irregular nuclei. H&E, (**B**) ×200, (**C**) ×400. (**D**) $CD3^+$, ×100. (**E**) Ki67 low, ×100. (**F**) Aberrant $CD20^+$, ×100.

2.1.3. Immunophenotype

The atypical lymphoid cells exhibit a T-cell phenotype and are positive for T-cell receptor (TCR, mostly beta and uncommonly gamma), CD3, CD2, CD4, CD5, CD7, and CD8. There are more CD4+ than CD8+ iITCLs. According to the pattern of expression of CD4 and CD8, iITCL can be categorized as CD4+/CD8−, CD4−/CD8+, CD4+/CD8+ and CD4−/CD8− [2,4–32]. This immunophenotypic categorization appears to correlate well with non-neoplastic T cells. CD8+ iITCL more frequently express TIA1 (but not granzyme B or perforin [13,21,22,24–29]. These different immunophenotypes of iITCL show different genetic features (see Section 2.1.4) and may have a bearing on pathogenetic mechanisms. Though there had been reports of CD4+ iITCL running higher risks of disease progression [7,12,18,19,22], this association is no longer documented in the fifth edition of the WHO Classification [2]. The sentence "Cases expressing CD4 rather than CD8 appear to be at higher risk for progression, although data are limited" appeared in the 2017 edition of the WHO Classification [33]. The references cited were works of Carbonnel et al. [7] and Margolskee et al. [12]. Despite additional reported CD4+ iITCL cases that progressed to higher-grade disease since 2017 [18,19,22], the paraphrase from the 2017 WHO Classification was no longer included in the fifth edition [2]. It is speculated that the conclusion was not made due to the paucity of reported CD4+ iITCL cases with disease progression. Ki67 proliferation index is low and mostly <10%. Ki67 index is apparently not correlated with the risk of disease progression, since it was low in two cases [12,22] and not reported in three cases [7,18,19].

2.1.4. Genetic Alterations

(a) *TCR* rearrangement

Clonal *TCR* rearrangement is present in all iITCL, more commonly *TCR beta* and less commonly *TCR gamma* [1,2,4–16,18–32].

(b) JAK/STAT and NF-κB-pathway-related genes

There are more frequent in CD4+/CD8−, CD4+/CD8+, and CD4−/CD8− iITCL [19,22,25–28,31]. Using Next-Generation Sequencing (NGS), alterations in *STAT3* and *JAK2*, resulting in *JAK2::STAT3* fusion, have been demonstrated [19,22,25–28]. Other genes with demonstrated alterations include *STAT3 SH2* mutation, *STAT5* alteration, and *SOCS1* deletion. Mutations in epigenetic modifier genes *DNMT3A*, *EZH2*, *KMT2D*, *TET2*, and *TNFAIP3* that contribute to JAK/STAT pathway activation are also identified, more commonly in CD4+/CD8− and CD4−/CD8− iITCL [2,27,28,31]. Activation of the NF-KB pathway through histone modification of *KMT2D* and methylation of *TET2* may also contribute to pathogenesis.

(c) *IL2* gene

IL2 gene alterations occur more commonly in CD8+ than CD4+ cases [2,22,28,31]. Implication of the *IL2* gene in iITCL was first demonstrated by traditional G-banding cytogenetic study [4], and later also by NGS. NGS uncovered *IL2::RHOH* (Ras homolog family member H) fusion due to inversion of chromosome 4 and *IL2:TNIP3* (TNFAIP3 interacting protein 3) fusion [22,28]. RHOH deficiency has been shown to be associated with T helper 17 cell polarization and T-cell defects [74,75]. In CD4−/CD8+ iITCL, deletion of 3′ untranslated regions of *IL2* and mutation of *MCM5* (minichromosomal maintenance complex 5) have been demonstrated [22].

(d) Other genetic alterations

Alterations in *DIS3*, *MAPK1*, *TP53*, *POLE*, *SMAD4*, *SFB1*, and *CDKN2A* have also been reported in some cases of CD4+ iITCL [22].

The number of studies and reported cases, however, is hitherto small, and it is too early for a definitive conclusion on distinctive pathogenetic and genetic differences among the different immunophenotypic categories of iITCL to be made. Furthermore, the number of genes and gene panels studied so far is limited, and the technological methods used vary from study to study. With future evolution in molecular methodology, the discovery of more genetic alterations in these indolent T-cell lymphomas may be made. It remains to be seen whether better correlation of immunophenotype, genetics, pathogenesis, and prognosis in iITCL can be achieved in the future.

2.1.5. Etiology and Role of EBV

The etiology of iITCL has remained nebulous. It has been etiologically associated with persistent antigenic stimulation [22], Crohn's disease [10,76], autoimmune enteropathy [14], and coeliac disease [7]. None of these postulations, however, has been substantiated by further evidence. It is widely accepted that iITCL is not associated with EBV and is typically EBV-negative. Among the eighty-five cases identified by this review, however, only twenty-two cases had been tested for EBV (22/85, 26%). Of those tested for EBV, nineteen were EBV-negative (19/22, 86%) and three were EBV-positive (3/22,13%) [7,26,29]. It is notable that the status of EBV infection was unknown in the remaining majority of reported iITCL cases (63/85,74%). Therefore, the common belief that iITCL is EBV-negative was founded on a small percentage of EBV-tested cases. The methodology of EBV detection was not mentioned in a significant number of reports, but in situ hybridization for EBV-encoded small RNA (EBER) in tissue sections was the most frequently used methodology, including the three EBV-positive cases [7,26,29]. Though EBER is regarded as the preferred method for detecting latent EBV infection in tissue sections [77–80], there are alternative methods of EBV detection [56,57,59,77,78]. By using these alternative methods, it may be possible that the reported EBV-negative cases may be reclassified as EBV-positive. Testing the remaining EBV-unknown cases may also skew the hitherto reported EBV status in iITCL. Since there were documented cases of EBV+ iITCL (three cases, 13%) [7,26,29], with 1 CD8+ case showing a high Ki67 index of 90% [29], the role of EBV in iITCL remains to be explored. The possibility of two groups of iITCL, namely EBV- and EBV+, therefore, remains to be further studied. These two possible groups may be different in immunophenotype, genetics, and clinical behavior. It is well known that EBV+ NK-/T-cell lymphomas and leukemias carry a grave prognosis and require aggressive treatment [55]; the implication of EBV-positivity in iITCL needs to be further studied.

2.1.6. Neoplastic Nature of iITCL

The true biological nature of indolent intestinal T-cell proliferations had been enigmatic, as reflected by the plethora of names ranging from "proliferative disorders, diseases to lymphomas" given to these entities in the literature in the past three decades [4–32]. The body of cumulative information and evidence hitherto on this entity is in favor of its neoplastic nature, as follows:

1. Ability to disseminate. There have been multiple reports of dissemination to various non-intestinal distant sites, including mesenteric lymph nodes, liver, lungs, skin, tonsils, epiglottis, peripheral blood, and bone marrow, as described in Section 2.1 above [4,7,12–15,18,22,26–29,31]. More importantly, dissemination to inguinal lymph nodes had also been reported in 2020 in two cases [22]. This is in striking contrast to the former belief that lymph nodes spread from iITCL should be limited within the abdomen.
2. Disease Progression. Progression or transformation to higher-grade lymphoma was documented in five of eighty-five cases (6%) [19,20,22]. Three cases transformed to

overt T-cell lymphoma [19,20], with one demonstrated to share the same *STAT3::JAK2* fusion as the pre-existing iITCL.

3. *Frequent Genetic Mutations.* Alterations in *TCR* genes, genes of the JAK/STAT signaling pathway, and epigenetic modifier genes that contribute to JAK/STAT activation, *IL2* gene, and *DIS3*, *MAPK1*, *TP53*, *POLE*, *SMAD4*, *SFB1*, and *CDKN2A* gene alterations in many cases, as discussed in Section 2.1.3 [2,4,16,18–29,31].

In the fifth edition of the WHO Classification of Hematolymphoid Tumors [1,2], the neoplastic nature of iITCL is recognized due to the significant morbidities related to the disease and its ability to disseminate. This entity is redesignated to "Indolent T-cell Lymphoma of the Gastrointestinal Tract" [33]. The reclassification of these entities as lymphomas represents formal recognition of their neoplastic biologic nature. iITCL thus requires greater awareness, accurate diagnosis, and proper management.

2.1.7. Treatment

Among the eighty-five reported cases, twenty-three cases did not receive any specific treatment, one was treated with surgery, nineteen with chemotherapy, five with steroids, eight with a gluten-free diet, one with mogamulizumab, and whether treatment was instituted was not mentioned for the remaining twenty-eight patients. Though the initial response was favorable in a handful of treated cases, the clinical course of iITCL was indolent with persistent or relapsing disease, irrespective of the treatment modality or whether treatment was instituted or not [4–32].

2.2. Indolent Intestinal NK-Cell Lymphoproliferative Disease (iINKLPD)

iINKLPD is a more recently recognized entity than iITCL [3,34–51], and was initially designated lymphomatoid gastropathy (in the stomach) and NK-cell enteropathy (in the remaining intestine tract). It behaves in an indolent fashion as a persistent or relapsing disease over long durations. The common presentations include vague abdominal symptoms or may be asymptomatic, only to be discovered incidentally on endoscopy. This review uncovered fifty-eight cases of iINKLPD from eighteen case reports or case series. There were twenty-three males, thirty-three females, and two cases with unidentified sex. The age ranged from 14 to 76 years (median 52 years). One case also showed concomitant involvement of the glans penis [48], while all the remaining fifty-five cases showed only involvement of the GI tract [34–47,49,50].

2.2.1. Sites of Involvement and Gross Findings

The stomach and small/large intestines are more commonly involved. The gall bladder was also rarely implicated [31,45,47,50]. The disease may present as single or multiple elevated lesions or ulcers with hemorrhage and edema, measuring 1–2 cm in size [34–51].

2.2.2. Histology

The disease is usually limited to the lamina propria, featuring expansion by confluent, generally non-destructive infiltrates of mostly medium-sized atypical lymphoid cells with irregular nuclei and pale granular cytoplasm. This contrasts with iITCL, where small atypical lymphoid cells are more common, and the cytoplasm is agranular. Epithelial invasion with destruction and displacement of intestinal glands can rarely occur. Mucosal ulceration and focal necrosis are occasionally present. The muscularis mucosae is usually intact, but may be involved. There is no angiocentricity or angioinvasion. Admixture with other inflammatory cells is usually present (Figure 2) [3,34–51].

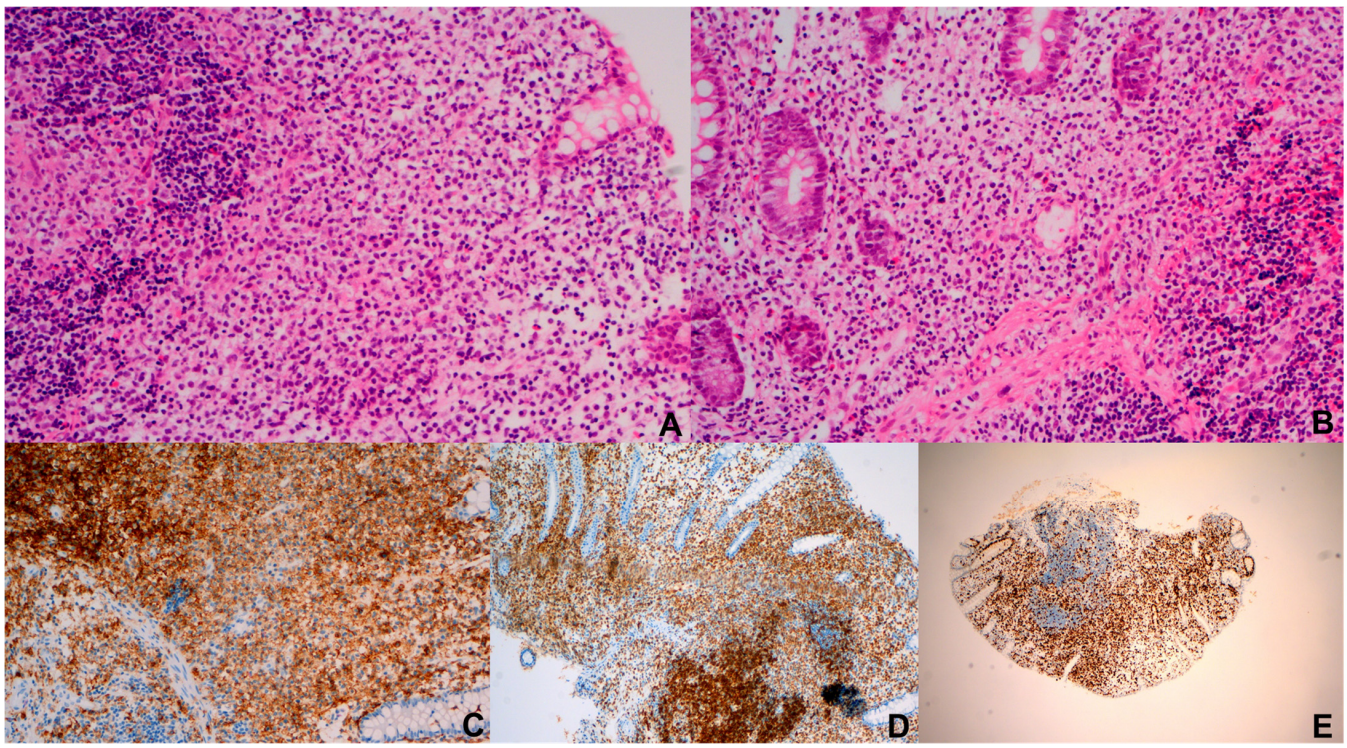

Figure 2. Male, 48 years, abdominal pain. Jejunal biopsy. (**A**,**B**) Non-destructive mucosal medium-sized atypical lymphoid cell infiltrates with pale granular cytoplasm. There was no glandular invasion. Involvement of muscularis mucosae in (**B**). H&E, ×200. (**C**) CD56+, ×100. (**D**) CD3+, ×100. (**E**) Ki67 high (about 60%), ×100.

2.2.3. Immunophenotype

By definition, the atypical lymphoid cells do not express TCR antigens and surface CD3. They frequently express CD56 and cytotoxic effector proteins TIA1 and granzyme B. CD2, CD7, CD8, and cytoplasmic CD3 may be expressed. The Ki67 positivity rate is usually low (<10%) but may be higher and up to 80% [3,34,36–38,42,44,46,49,50]. The significance of this difference in Ki67 positivity rate from iITCL is unknown.

2.2.4. Etiology and EBV Status

The etiology of iINKLPD is unknown, though Helicobacter pylori (HP) infection has been suggested to play a role, as response of iINKLPD to anti-HP treatment has been reported [3,28,35,40,44]. This, however, was not universally observed in the reported cases. In the fifty-six reported cases, all were EBV-negative. Though the number of cases reported was too small to be conclusive on the role of EBV in iINKLPD, it appears that EBV is probably not etiologically or pathogenetically related to iINKLPD.

2.2.5. Neoplastic or Non-Neoplastic?

Unlike iITCL, the biological nature of iINKLPD has not been clearly defined. Among the fifty-eight reported cases, there was no observation of distant dissemination, progression, or transformation of the disease. However, genetic alterations, including mutations in *JAK3*, *RUNX1*, *CIC*, *ERBB4*, and *SETD5*, were reported in iINKLPD [3,28,49,50]. Phosphorylated STAT3 [3,50] and STAT5 [8] proteins had also been demonstrated in some cases of iINKLPD. These genetic and epigenetic anomalies point to a possible neoplastic nature of iINKLPD. However, the small number of reported cases with these genetic and epigenetic changes precludes making definitive conclusions. The biological nature of iINKLPD requires further study on a larger number of cases.

2.2.6. Treatment

Among the fifty-eight reported cases, thirty-six were not given any specific treatment, four received surgery, seven received chemotherapy (with two given concomitant bone marrow transplant), one received anti-HP therapy, and there were ten cases without a reported treatment modality. Despite the treatment modality, the indolent course of persistent or relapsing disease appeared unaffected [34–50]. More work is required on a greater number of cases for a better understanding of the clinical outcome and optimal management of iINKLPD.

2.3. Differential Diagnoses of iITCL and iINKLPD from Other Intestinal NK- or T-Cell Lymphomas

The major differential diagnoses (DDX) are monomorphic epitheliotropic intestinal T-cell lymphoma (MEITCL), enteropathy-associated T-cell lymphoma (EATCL), and primary GI extranodal NK/T-cell lymphoma (ENNKTL) of the intestine. Intestinal metastasis from primary non-GI ENNKTL may also cause diagnostic confusion, but can be distinguished by the presence of a primary (nasal or other non-nasal sites) in another location. MEITCL, EATCL, and GI ENNKTL can be distinguished by their distinctive clinical manifestations, aggressive behavior, high-grade morphology, immunophenotypic, and genetic differences. In EATCL, there is often histological evidence of residual coeliac disease. Primary GI ENNKTL may be distinguished by characteristic histological evidence of frequent angiocentricity, angioinvasion, and extensive geographic necrosis. Further, EBV is always positive in ENNKTL, in contrast to the usual EBV negativity in iITCL and almost always EBV negativity in iINKLPD [52–55]. A summary of the differences among these entities is depicted in Table 1.

Table 1. Comparative features of gastrointestinal NK-/T-cell lymphomas and LPD.

	iITCL	iINKLPD	ENNKTL	MEITL	EATL
Age (years)	CD4+: Median 51 CD8+: Median 45	30–90	35–58	Median 54–67	Median 61
Sex	M > F	M > F	M > F	M > F	M > F
Predominant sites involved	Small intestine, colon	Stomach, small intestine, colon, gall bladder	GI tract	Small intestine	Small intestine (mostly jejunum)
Multifocality	Common	Yes	27%	20–35%	32–54%
Enteropathy association	No	No	No	No	80%
Metastasis	BM, PB, tonsil, mesenteric LN	Rarely mesenteric LN	Multiple extraintestinal sites, frequently Stage IV	LN, lung, liver, brain, skin	LN, BM, lung, liver
Transformation	Reported	NR	NA	NA	NA
Depth involved	Mucosa, sometimes also MM and SM	Mucosa	Full thickness	Full thickness	Often full thickness
Histology	Small/medium atypical cells, non-destructive dense infiltrate, no/rare epithelial invasion, no angioinvasion	Medium atypical cells, small nucleoli, pale granular cytoplasm, circumscribed confluent infiltrate, glands displaced, epithelial invasion +/−, necrosis +/−	Range of atypical cells, geographic necrosis, epithelial invasion, angiocentricity, angioinvasion, angiodestruction	Monotonous atypical cell infiltrates, necrosis, epithelial invasion, severe inflammatory backdrop, “starry sky” appearance	Range of atypical cells, epithelial invasion, angioinvasion, angiodestruction, features of CD

Table 1. *Cont.*

	iITCL	iINKLPD	ENNKTL	MEITL	EATL
Molecular/genetic alterations	*STAT3*, *JAK2*,, *JAK2::STAT3* fusion, *STAT5*, *SOCS1*, *KMT2D*, *TET2*, *DNMT3A*, *EZH2*, *TNFAIP3*, *IL2*, *RHOH*, *TNIP3*, *TCR*	*JAK3*, *RUNX1T1*, *CIC*, *ERB4*, *SETD5*	*PRDM1*, *PTPRK*, *HACE1*, *FOXO3*, *STAT3*, *JAK3*, *STAT5B*, *BCOR*, *KMT2D*, *ARID1A*, *EP300*, *TCR* (in T-cell type)	*Myc*, *SETD2*, *STAT3*, *STAT5*, *JAK1*, *KAK3*, *TCR*	*JAK1*, *STAT3*, *TET2*, *KMT2D*, *DOX3X*, *TNFA1P3*, *TNIP3*, *POT1*, *TP53*, *CD58*, *FAS*, *B2M*, *TCR*
Immunophenotype	CD3+, CD4+CD8−, CD4−CD8+, CD4+CD8+, CD4−CD8−, TCR+, KI67 low *	CD56+, CD2+, cCD3+, CD7+, TIA1+, GZB+, TCR-, Ki67 high	CD56+ (NK-cell type), cCD3+, sCD3+ (T-cell type), CD2+, TIA1+, GZB+, perforin+, TCR- (in NK-cell type), TCR+ (in T-cell type), Ki 67 high	CD2+, sCD3+, CD7+, CD8+, CD56+/−, TIA1+, TCR+, Ki67 high	CD3+, CD7+, TIA1+, GZB+, perforin+, Ki67 > 50%, CD30+/EMA+ (in anaplastic cases)
EBV	Negative @	Negative	Positive	Negative	Negative

Footnote: * Some cases reported Ki67 high, @ Some cases reported EBV+, +: positive, − negative, +/−: weak or focal positive, cCD3: cytoplasmic CD3, CD: Coeliac disease, BM: bone marrow, EATL: enteropathy associated T-cell lymphoma, ENNKTL: extranodal NK-/T-cell lymphoma, F: female, GZB: granzyme B, iINKLPD: indolent intestinal NK-cell lymphoproliferative disorder, iITCL: indolent intestinal T-cell lymphoma, LN: lymph node, M: male, MEITL: monomorphic epitheliotropic intestinal T-cell lymphoma, MM: muscularis mucosae, NA: not applicable, NR: not reported, PB: peripheral blood, sCD3: surface CD3, SM: submucosa, TCR: T-cell receptor.

3. Indolent Non-Intestinal NK- or T-Cell LPD

This review uncovered 11 cases of indolent NK- or T-cell LPD that arose from non-intestinal sites. Four cases occurred in the nose, one in the nasopharynx (NP), three in the skin, one in the lymph node, one in the pericardium, and one in the vagina [50,56–65]. All cases were characterized by indolent clinical behavior of persistent or relapsing disease over long periods. Four cases were of T-cell lineage (two nose, one pericardium, one lymph node), and seven were of NK-cell lineage (two nose, three skin, one NP, and one vagina) [50,56–65]. Apart from the EBV-unknown NK-cell NP case [50] and the EBV-negative vaginal case [65], the remaining four T-cells (one lymph node, two nose, and one pericardium) and five NK-cells (two nose and three skin) were all EBV-positive. There was an indolent NKLPD of the skin, which was not tested for EBV at presentation but progressed to an EBV+ ENNKTL after a prolonged relapsing disease [58]. This case is particularly intriguing, as it raises the issue of whether the timing of EBV infection is a significant factor in the disease. Contracting EBV later in the course of the indolent disease may be a triggering event in disease progression. The rate of EBV-positivity among indolent non-intestinal NK- or T-cell LPD was 82% (9/11).

The majority (5/6 tested cases, 83%) [59–64] showed a high Ki67 positivity rate, with a reported rate of over 90% in a pericardial case [64]. Two NK EBV-positive cases of the skin showed high-grade transformation to ENNKTL (2/2, 100%) after long durations of indolent disease [57,58]. This compares with the overall lower rate of disease transformation in iITCL (5/86, 6%) [18,19,22], and that none of the nineteen EBV-negative iITCL and thirty-nine EBV-negative iINKLPD cases resulted in disease progression or transformation [4–50].

It appears that EBV-positivity is more prevalent in indolent non-intestinal NK- or T-cell LPD. They showed a higher KI67 proliferation index [59–64] and a higher rate of disease progression [57,58]. It may be argued that indolent EBV-positive non-intestinal NK- or T-cell LPDs should not be compared with other indolent EBV-negative intestine counterparts and should be grouped together with the high-grade primary GI EBV-positive ENNKTL [52,55]. However, ENNKTL is clearly different from indolent EBV+ NK- or T-cell LPD in clinical behavior, histology, immunophenotype, genetics, and outcome and should be separately categorized [52,55]. Despite this, indolent EBV+ NK- or T-cell LPDs

can mimic some ENNKTL with a predominant small cell component morphologically and immunophenotypically [52,55]. This may cause great diagnostic difficulty without clinical follow-up. The indolent EBV+ NK- or T-cell LPD may also cause confusion with chronic active EBV disease (CAEBV). The former, however, could be distinguished by its lack of severe systemic symptoms and deranged liver functions at presentation that are characteristic of CAEBV [55]. It should also be mentioned that indolent EBV+ T-cell LPDs of the skin may be confused with various other cutaneous lymphomas or LPDs, which are also often indolent. The latter are distinguishable by always being negative for EBV. Since the hitherto number of reported cases of indolent EBV+ non-intestinal NK- or T-cell LPD is so far very small, it is not possible to define this as a distinctive biologic entity. Further work on many more cases is required for elucidation on the biological nature and role of EBV in these entities. Table 2 summarizes the miscellaneous features of the nine reported EBV+ indolent non-intestinal NK- or T-cell LPD.

Table 2. Summary of reported EBV+ non-intestinal indolent T- and NK-cell LPDs.

Series (Reference, Year)	Sex	Age	LPD Duration (Years)	Site(s)	Disease Progression	Px of Progressed Disease	Clinical Outcome	Histology of LPD	Immunophenotype	Genotype	Lineage	EBV/EBER of LPD	Ki67
Rahemtullah et al. [54] (2008)	M	71	4	neck LN	EBV+ BCL with plasmacytic differentiation	CT	DOD (66 m)	LG	CD2+, CD3+, CD5+, CD7+, CD4+, CD20+, CD30+(dim), CD56+(dim)	*TCR*: GL *Ig*: polyclonal	T	+ (EBV clonal)	NR
Watabe et al. [55] (2009)	F	39	10	skin (legs)	ENNKTL, nasal type (skin)	CT	DOD (128 m)	LG *	CD3+, CD56+, GZB+, CD8+/−, perforin +/−	*TCR*: GL	NK	+ (LMP+) (EBV biclonal)	NR
Seishima FM et al [56] (2010)	F	60	11.5	skin (lip and cheek)	EBV+ ENNKTL, nasal type (nose and multiple skin sites)	CT	DOD (146m)	LG *	CD56−, CD4+/−, CD8+/−, cytotoxic (ND)	NR	NK (CD56 turned + on progression)	NR	NR
Jiang QP et al [57] (2012)	F	78	10	nose	NP	NA	AWD	LG	CD3+, CD56+, Cytotoxic+, CD20+	*TCR*: GL *Ig*: GL	NK	+ (EBV genome)	60%
Zuriel D et al [58] (2012)	F	55	22	skin (recurrent, right upper arm)	NP	NA	AWD (recurrence 192 m and 264 m, skin right upper arm)	LG	CD2+, CD3+, cytotoxic+, CD56+ (at 264 m) Ki67 > 90%	*TCR*: GL	NK	+	90%
Tabeanelli V et al [59] (2014)	F	52	13	nose	NP	NA	AWD at 156 m	LG	CD2+, CD3+, CD5+, CD7+, CD56+, βF1+, TCR α/δ+, cytotoxic+, Ki67 (moderately high)	*TCR*: clonal	T	+	Moderate high
Zhang QF et al [60] (2016)	M	53	20	nose	NR	NA	AWD at 242 m	LG	CD3+, CD56+, cytotoxic+, Ki67(80%)	NR	NK	+	80%
Devins K et al [61] (2018)	F	71	long standing	nose	NR	NA	AWD (many years)	LG	CD2+, CD3+, CD3+/−, CD5+/−, CD7+/−, CD56− cytotoxic+, Ki67 (<1%)	*TCR*: clonal *KIT* mutation+	T	+	<1%
Wang Z et al. [62] (2020)	M	64	19	Pericardium	NP	NA	AW	LG	CD3+,CD30+,CD43+, TIA1+, MUM1+, BCL2+	*TCR*: clonal	T	+	>90%

AW: alive and well; AWD: alive with disease; BCL: B-cell lymphoma; CT: chemotherapy; DOD: died of disease; ENNKTL: extranodal NK/T-cell lymphoma; GZB: Granzyme B; LG: low grade; LN: lymph node; LPD: lymphoproliferative disease; NA: not applicable; NP: no progression of disease; NR: not reported; *TCR*: T-cell receptor gene; *: interpreted from published images; +: positive, +/−: weak or focal positive.

4. Indolent T-Lymphoblastic Proliferation (iTLBP)

iTLBP was first described in 1999 in the upper aerodigestive tract of a male subject who remained indolent and stable for over 16 years without treatment [32,66,67]. iTBLP is rare, and about 50 cases have been reported in various nodal and non-nodal sites. The latter includes mandibular, cervical, supraclavicular, parotid, inguinal, abdominal, liver, adrenal, retroperitoneal, nasopharyngeal, and mediastinal locations [32,66–68]. iTBLP may affect reactive lymph nodes [68], occurs in Castleman disease, myasthenia gravis, paraneoplastic autoimmune multiorgan syndrome, and may be associated with neoplasms (hepatocellular carcinoma, dendritic follicular cell sarcoma, and acinic cell carcinoma) [32,66–68]. The clinical course is benign and indolent and does not require treatment. It is characterized histologically as non-destructive tumor-like, tumor-infiltrating lymphocyte-like, or focal cellular cluster (>50 cells) lesions [66]. The cells are small to medium-sized and lack significant atypia. Immunophenotypically, they are positive for Tdt and CD3, with variable positivity for CD1a, CD4, CD7, CD8, CD10, CD34, and CD99. This immunophenotype is in keeping with that of a common lymphoid precursor [66–68]. Genotypically, clonal *TCR* rearrangement is not present. The most important DDX is T-cell lymphoblastic lymphoma (TLBL). TLBL is distinguishable by tissue destruction, larger atypical lymphoblastic cells, aberrant immunophenotypic features, including expression of LMO2, and presence of clonal *TCR* rearrangement. The rarity of TLBL in adults should also be helpful in distinguishing it from iTBLP in adult patients. It is important to recognize the association of iTBLP in a variety of malignant tumors, in order to avoid confusion and misinterpretation [66–68].

5. Indolent Cutaneous LPD

Many cutaneous T-cell lymphomas or LPDs are clinically indolent and include primary cutaneous CD4-positive small or medium T-cell LPD (PcutCD4+TLPD), primary cutaneous acral CD8-positive T-cell LPD (PcutacCD8+TLPD), mycosis fungoides, lymphomatoid papulosis, and primary cutaneous anaplastic large cell lymphoma. PcutCD4+TLPD was a provisional entity in the 2017 WHO Classification, and PcutacCD8+TLPD was originally designated as a lymphoma. These are recently reclassified as LPD due to the benign indolent clinical course. These two entities are highlighted below.

5.1. PcutCD4^{+}TLPD

This was a provisional entity in the 2017 revised fourth edition of the WHO Classification [32,69]. It is currently designated an LPD because of the benign indolent clinical behavior, with spontaneous regression in about 30% of cases [32,69,70,72]. It is a clonal disease, and *TCR* gene rearrangement is demonstrable in the majority of tested cases [70]. It affects a wide age range, with a median of 59 years. Both sexes are affected almost equally. Clinically, it affects most commonly the head and neck and presents as an asymptomatic erythematous solitary nodule and less frequently as a tumor, papule, macule, or plaque, with a size ranging from 4 to 60 mm. Histologically, two patterns were reported. The entire dermis is involved in one pattern, sometimes with extension to the subcutis. The other pattern features a subepidermal band-like infiltrate of the superficial dermis. Epidermotropism and folliculotropism may be present, rendering mycosis fungoides a differential diagnosis. The infiltrate consists mostly of small to medium atypical lymphoid cells and contains no more than 40% large cells. Immunophenotypically, the lymphoid cells are CD3+, CD4+, CD8−, CD30−, follicular T-helper cell markers+ (mostly PD-1+) and low Ki67 proliferation index. Reactive B cells and CD8+ T cells may be present. The prognosis is excellent. Treatment with intralesional steroids, excision, or radiotherapy is effective, and spontaneous remission without treatment occurs in 30% cases. The major DDX are

mycosis fungoides, primary cutaneous marginal zone lymphoma, and cutaneous lymphoid hyperplasia [32,70,72].

5.2. PcutacCD8⁺TLPD

It was designated as a lymphoma in the 2017 revised fourth edition of the WHO Classification and has been recently regarded as an LPD in view of the indolent benign clinical behavior. It is a slow-growing, solitary, reddish-purple skin nodule or plaque measuring up to several centimeters. It affects acral sites, including the face, ear, nose, hands, or feet. It is histologically characterized by a dense, monotonous, atypical dermal lymphoid infiltrate consisting of medium-sized cells. Extension into the subcutis is common. Immunophenotypically, the lymphoid cells are CD3+, CD4−, CD8+, CD30−, cytotoxic cell phenotype+ (TIA1+ mostly), CD56−, and PD1-. CD68 is positive, showing the characteristic Golgi-dot-like positivity. Ki67 proliferation index is low. Clonal TCR rearrangement is present in nearly all cases. The prognosis is excellent, with complete remission after excision or local irradiation [32,71,73].

6. Conclusions

Indolent NK- or T-cell LPD are less recognized and characterized, compared to the B-cell counterparts. The latter include B-cell lymphocytic lymphoma/leukemia, marginal-zone lymphoma of mucosa-associated lymphoid tissue, lymphoplasmacytic lymphoma, indolent mantle cell lymphoma (leukemic type), and follicular lymphoma. They are well delineated morphologically, immunophenotypically, genotypically, and nosologically [81]. iITCL was first described three decades ago, followed almost a decade later by reports of iINKLPD. The indolent clinical behavior of these entities has been the major confounding factor in delineating their biological nature. The significant morbidities, ability to disseminate, potential for disease progression and transformation, and multiple genetic alterations identified in iITCL have led to its recent recognition as a lymphoma [2,27,31]. iINKLPD, on the other hand, appears less definitive. However, the frequent presence of *JAK3* and other genetic mutations, as well as the expression of the phosphorylated STAT3 and STAT5 proteins, points to the possible neoplastic nature of iINKLPD [3,8,28,49,50].

The role of EBV in these indolent NK- or T-cell lymphomas or LPD is also perplexing. Though it is commonly believed that EBV-negativity is a feature of iITCL and iINKLPD, the reports of EBV+ iITCL challenge this commonplace conviction [7,26,29]. The more frequent reports of EBV-positivity in indolent non-intestinal NK- or T-cell LPD cast a more conjectural aura on this belief [56–64]. The small number of reported cases of iITCL that were tested and confirmed to be EBV-negative, amid an even larger number of cases with unknown EBV status (63/85,74%), raises the need for accumulation of further evidence before a firm dogma can be made on the role of EBV in these entities. Ki67 proliferation index is low in most iITCL cases. However, it is higher in iINKLPD and indolent non-intestinal EBV+ NK- or T-cell LPD. This finding is interesting, but the significance is unknown.

The recognition of iTBLP is eye-opening since the presence of lymphoblasts often conveys the notion of proliferation and neoplasia. The indolent behavior of iTLBP warrants greater awareness of the entity in order to avoid unnecessary radical therapy. Though many cutaneous T-cell lymphomas are indolent in behavior, PcutCD4+LPD and PcutacCD8+LPD have recently been reclassified as LPD instead of lymphoma due to the uniformly excellent clinical behavior. Such redesignation is important for better recognition of their biological nature and avoidance of over-treatment.

Funding: This work received no external funding.

Institutional Review Board Statement: This review article requires no IRB approval for the purposes of literature review and educational examples.

Data Availability Statement: The original contributions presented in this study are included in the review article material. Further inquiries can be directed to the corresponding author.

Acknowledgments: The author thanks Xingen Wang, Department of Pathology, Peking University Shenzhen Hospital, for supplying images of Figures 1 and 2. These images were taken from the teaching set of the Peking University Shenzhen Hospital.

Conflicts of Interest: The author declares no conflicts of interest.

Abbreviations

The following abbreviations are used in this manuscript:

DDX	differential diagnosis
EATCL	enteropathy-associated T-cell lymphoma
EBV	Epstein–Barr virus
EBER	EBV encoded small RNA
ENNKTL	extranodal natural killer-/T-cell lymphoma
GI	gastrointestinal
iINKLPD	indolent intestinal natural killer-cell lymphoproliferative disease
iITCL	indolent intestinal T-cell lymphoma
LPD	lymphoproliferative disease
MEITCL	monomorphic epitheliotropic intestinal T-cell lymphoma
NGS	next-generation sequencing
NK	natural killer
PcutacCD8+TLPD	primary cutaneous acral CD8+ T-cell LPD
PcutCD4+TLPD	primary cutaneous CD4+ T-cell LPD
TCR	T-cell receptor
TLBL	T-cell lymphoblastic lymphoma

References

1. Chan, J.; Alaggio, R. Intestinal T-cell and NK-cell lymphoid proliferations and lymphomas. Introduction. In *WHO Classification of Haematolymphoid Tumours*, 5th ed.; IARC: Lyons, France, 2025. Available online: https://tumourclassification.iarc.who.int/chapters/63 (accessed on 23 October 2025).
2. Bhagat, G.; Takeuchi, K.; Naresh, K.N.; Dave, S.S. Indolent T-cell lymphoma of the gastrointestinal tract. In *WHO Classification of Haematolymphoid Tumours*, 5th ed.; Chan, J., Washington, M.K., de Jong, D., Eds.; IARC: Lyons, France, 2025. Available online: https://tumourclassification.iarc.who.int/chapters/63 (accessed on 23 October 2025).
3. Xiao, W.; Takeuchi, K.; Ferry, J.A.; Chang, C.L. Indolent NK-cell lymphoproliferative disorder of the gastrointestinal tract. In *WHO Classification of Haematolymphoid Tumours*, 5th ed.; Chan, J., Lee Wood, B., Eds.; IARC: Lyons, France, 2025. Available online: https://tumourclassification.iarc.who.int/chapters/63 (accessed on 23 October 2025).
4. Carbonnel, F.; Lavergne, A.; Messing, B.; Tsapis, A.; Berger, R.; Galian, A.; Nemeth, J.; Brouet, J.C.; Rambaud, J.C. Extensive Small Intestinal T-Cell Lymphoma of Low-Grade Malignancy Associated with a New Chromosomal Translocation. *Cancer* **1994**, *73*, 1286–1291. [CrossRef] [PubMed]
5. Egawa, N.; Fukayama, N.; Kawaguchi, K.; Hishima, Y.; Funata, N.; Ibuka, T.; Koike, M.; Miyashita, H.; Tajima, T. Relapsing Oral and Colonic Ulcers with Monoclonal T-cell Infiltration. *Cancer* **1995**, *75*, 1728–1733. [CrossRef] [PubMed]
6. Hirakawa, K.; Fuchigam, T.; Nakamura, S.; Daimaru, Y.; Ohshima, K.; Sakai, Y.; Ichimaru, T. Primary Gastrointestinal T-cell Lymphoma Resembling Multiple Lymphomatous Polyposis. *Gastroenterology* **1996**, *111*, 778–782. [CrossRef]
7. Carbonnel, F.; d'Almagne, H.; Lavergne, A.; Matuchansky, C.; Brouet, J.C.; Sigaux, F.; Beaugerie, L.; Nemeth, J.; Coffin, B.; Cosnes, J.; et al. The Clinicopathological Features of Extensive Small Intestinal CD4 T Cell Infiltration. *Gut* **1999**, *45*, 662–667. [CrossRef] [PubMed]
8. Zivny, J.; Banner, B.F.; Agrawal, S.; Pihan, G.; Barnard, G. CD4+ T-cell Lymphoproliferative Disorder of the Gut Clinically Mimicking Coeliac Sprue. *Dig. Dis. Sci.* **2004**, *49*, 551–555. [CrossRef]

9. Svrcek, M.; Garderet, L.; Sebbagh, V.; Rosenzwajg, M.; Parc, Y.; Lagrange, M.; Bennis, M.; Lavergne-Slove, A.; Flejou, J.; Fabiani, B. Small Intestinal CD4+ T-cell Lymphoma: A Rare Distinctive Clinicopathological Entity Associated with Prolonged Survival. *Virchows Arch.* **2007**, *451*, 1091–1093. [CrossRef] [PubMed]
10. Perry, A.M.; Warnke, R.A.; Hu, Q.; Gaulard, P.; Copie-Bergman, C.; Alkan, S.; Wang, H.; Cheng, J.X.; Bacon, C.M.; Delabie, J.; et al. Indolent T-cell Lymphoproliferative Disease of the Gastrointestinal Tract. *Blood* **2013**, *122*, 3599–3606. [CrossRef] [PubMed]
11. Ranheim, E.A.; Jones, C.; Zehnder, J.L.; Warnke, R.A.; Yuen, A. Spontaneously Relapsing Clonal, Mucosal Cytotoxic T-cell Lymphoproliferative Disorder: Case Report and Review of the Literature. *Am. J. Surg. Pathol.* **2000**, *24*, 296–301. [CrossRef]
12. Margolskee, E.; Jobanputra, V.; Lewis, S.K.; Alobeid, B.; Green, P.H.R.; Bhagat, G. Indolent Small Intestinal CD4+ T-cell Lymphoma is a Distinct Entity with Unique Biologic and Clinical Features. *PLoS ONE* **2013**, *8*, e68343. [CrossRef]
13. Leventaki, V.; Manning, J.T., Jr.; Luthra, R.; Mehta, P.; Oki, Y.; Romaguera, J.; Medeiros, L.J.; Vega, F. Indolent Peripheral T-cell Lymphoma Involving the Gastrointestinal Tract. *Hum. Pathol.* **2014**, *45*, 421–426. [CrossRef] [PubMed]
14. Malamut, G.; Meresse, B.; Kaltenbach, S.; Derrieux, C.; Verkarre, V.; Macintyre, E.; Ruskone-Fourmestraux, A.; Fabiani, B.; Radford-Weiss, I.; Brousse, N.; et al. Small Intestinal CD4+ T-cell Lymphoma is a Heterogeneous Entity with Common pathology features. *Clin. Gastroenterol. Hepatol.* **2014**, *12*, 599–608. [CrossRef]
15. Mendes, L.S.T.; Attygalle, A.D.; Cunningham, D.; Benson, M.; Andreyev, J.; Gonzales-de-Castro, D.; Wootherspoon, A. CD4-positive Small T-cell Lymphoma of the Intestine Presenting with Severe Bile-acid Malabsorption: A Supportive Symptom Approach. *Br. J. Haematol.* **2014**, *167*, 265–269. [CrossRef]
16. Wang, X.; Ng, C.S.; Chen, C.; Yu, G.; Yin, W. An Unusual Case Report of Indolent T-cell Lymphoproliferative Disorder with Aberrant CD20 Expression Involving the Gastrointestinal Tract and Bone Marrow. *Diagn. Pathol.* **2018**, *13*, 82. [CrossRef] [PubMed]
17. Nagaishi, T.; Yamada, D.; Suzuki, K.; Fukuyo, R.; Saito, E.; Fukuda, M.; Watanabe, T.; Tsugawa, N.; Takeuchi, K.; Yamaoto, K. Indolent T Cell Lymphoproliferativ Disorder with Villous Atrophy in Small Intestine Diagnosed by Single-Balloon Enteroscopy. *Clin. J. Gastroenterol.* **2019**, *12*, 434–440. [CrossRef] [PubMed]
18. Perry, A.M.; Bailey, N.G.; Bonnett, M.; Jaffe, E.S.; Chan, W.C. Disease Progression in a Patient with Indolent T-cell Lymphoproliferative Disease of the Gastrointestinal Tract. *Int. J. Surg. Pathol.* **2019**, *27*, 102–107. [CrossRef] [PubMed]
19. Sharma, A.; Oishi, N.; Boddicker, R.L.; Hu, G.; Benson, H.K.; Ketterling, R.P.; Greipp, P.T.; Knutson, D.L.; Kloft-Nelson, S.M.; Eckloff, B.W.; et al. Recurrent *STAT3-JAK2* Fusions in Indolent T-cell Lymphoproliferative Disorder of the Gastrointestinal Tract. *Blood* **2018**, *131*, 2262–2266. [CrossRef]
20. Guo, L.; Wen, Z.; Su, X.; Xiao, S.; Wang, Y. Indolent T-cell Lymphoproliferative Disease with Synchronous Diffuse Large B-cell Lymphoma. *Case Rep. Med.* **2019**, *98*, e15323. [CrossRef]
21. Wu, J.; Li, L.G.; Zhang, X.Y.; Wang, L.L.; Zhang, L.; Xiao, Y.J.; Xing, X.M.; Lin, D.L. Indolent T-cell Lymphoproliferative Disorder of the Gastrointestinal Tract: An Uncommon Case with Lymph Node Involvement and the Classic Hodgkin's Lymphoma. *J. Gastroenterol. Oncol.* **2020**, *11*, 812–819. [CrossRef]
22. Soderquist, C.R.; Patel, N.; Murty, V.V.; Betman, S.; Aggarwai, N.; Young, K.H.; Xerri, L.; Leeman-Neill, R.; Lewis, S.K.; Green, P.H.; et al. Genetic and Phenotypic Characterization of Indolent T-cell Lymphoproliferative Disorder of the Gastrointestinal Tract. *Haematologica* **2020**, *105*, 1895–1906. [CrossRef]
23. Zanelli, M.; Zizzo, M.; Sanguedolce, F.; Martino, G.; Soriano, A.; Ricci, S.; Ruiz, C.C.; Anessi, V.; Ascani, S. Indolent T-cell Lymphoproliferative Disorder of the Gastrointestinal Tract: A Tricky Diagnosis of a Gastric Case. *Gastroenterology* **2020**, *20*, 336. [CrossRef]
24. Takahashi, N.; Tsukasaki, K.; Kohri, M.; Akuzawa, Y.; Saeki, T.; Okamura, D.; Ishikawa, M.; Maeda, T.; Kawai, N.; Matsuda, A.; et al. Indolent T-cell Lymphoproliferative Disorder of the Stomach Successfully Treated by Radiotherapy. *J. Clin. Exp. Hematopathol.* **2020**, *60*, 7–10. [CrossRef] [PubMed]
25. Nishimura, M.F.; Nishimura, Y.; Nishikori, A.; Yoshino, T.; Sato, Y. Primary Gastrointestinal T-cell Lymphoma and Indolent Lymphoproliferative Disorders: Practical Diagnostic and Treatment Approaches. *Cancers* **2021**, *13*, 5774. [CrossRef] [PubMed]
26. Montes-Moreno, S.; King, R.L.; Oschlies, I.; Ponzoni, M.; Goodlad, J.R.; Dotlic, S.; Traverse-Glehen, A.; Ott, G.; Ferry, J.A.; Calaminici, M. Update on Lymphoproliferative Disorders of the Gastrointestinal Tract: Disease Spectrum from Indolent lymphoproliferations to Aggressive Lymphomas. *Virchows Archiv.* **2020**, *476*, 667–681. [CrossRef] [PubMed]
27. Miranda, R.N.; Amador, C.; Chan, J.K.C.; Guitart, J.; Rech, K.L.; Medeiros, L.J.; Naresh, K.N. Fifth Edition of the World Health Organization Classification of Tumors of the Hematopoietic and Lymphoid Tissues: Mature T-cell, NK-cell, and Stroma-Derived Neoplasms of Lymphoid Tissues. *Mod. Pathol.* **2024**, *37*, 100512. [CrossRef] [PubMed]
28. Wang, X.; Yin, W.; Wang, H. Indolent T-cell/Natural Killer-Cell Lymphomas/Lymphoproliferative Disorders of the Gastrointestinal Tract—What Have We Learned in the Last Decade? *Lab. Investig.* **2024**, *104*, 102028. [CrossRef]
29. Chuang, S.; Tzioni, M.; Chen, Z.; Feng, Y.; Shih, C.; Casa, C.; Du, M. Indolent EBV-positive T-cell Lymphoma of the Gastrointestinal with Metachronous Lesions Involved by Different Neoplastic Clones. *Pathology* **2024**, *56*, 431–434. [CrossRef]

30. Yuan, D.; Liang, N.; Wang, D.; Wang, J.; Jia, C. Clinical and Pathological Analysis of Indolent T-cell Lymphoproliferative Disease of the Gastrointestinal Tract. *Front. Immunol.* **2025**, *16*, 1530149. [CrossRef]
31. Attygalle, A.D.; Karube, K.; Jeon, Y.K.; Cheuk, W.; Bhagat, G.; Chan, J.K.C.; Naresh, K.N. The Fifth Edition of the WHO Classification of Mature T Cell, NK Cell and Stroma-Derived Neoplasms. *J. Clin. Pathol.* **2025**, *78*, 217–232. [CrossRef] [PubMed]
32. Quintanilla-Martinez, L.; Bosch-Schips, J.; Gasljevic, G.; van den Brand, M.; Balague, O.; Anagnostopoulos, I.; Ponzoni, M.; Cook, J.R.; Dirnhofer, S.; Sander, B.; et al. Exploring the Boundaries between Neoplastic and Reactive Lymphoproliferations: Lymphoid Neoplasms with Indolent Behavior and Clonal Lymphoproliferations—A Report of the 2024 EA4HP/SH Lymphoma Workshop. *Virchows Archiv.* **2025**, *487*, 327–347. [CrossRef] [PubMed]
33. Jaffe, E.S.; Bhagat, G.; Chott, A.; Tan, S.Y.; Ott, G.; Stein, H.; Chan, J.K.C.; Isaacson, P.G. Indolent T-cell Lymphoproliferative Disorder of the Gastrointestinal tract. In *WHO Classification of Haematolymphoid Tumours*, 4th ed.; Swerlow, S.H., Campo, E., Harris, N.L., Jaffe, E.S., Pileri, S.A., Stein, H., Thiele, J., Eds.; IARC: Lyons, France, 2017; pp. 379–380.
34. Vega, F.; Chang, C.; Schwartz, M.R.; Preti, H.A.; Younes, M.; Ewton, A.; Verm, R.; Jaffe, E.S. Atypical NK-cell Proliferation of the Gastrointestinal Tract in a Patient with Antigliadin Antibodies but not Coeliac Disease. *Am. J. Surg. Pathol.* **2006**, *30*, 539–544. [CrossRef] [PubMed]
35. Takeuchi, K.; Yokoyama, M.; Ischizawa, S.; Terui, Y.; Nomura, K.; Marutsuka, K.; Nunomura, M.; Fukushima, N.; Yagyuu, T.; Nakamine, H.; et al. Lymphomatoid Gastropathy: A Distinct Clinicopathologic Entity of Self-limited Pseudomalignant NK-cell Proliferation. *Blood* **2010**, *116*, 5631–5637. [CrossRef] [PubMed]
36. Mansoor, A.; Pittaluga, S.; Beck, P.L.; Wilson, W.H.; Ferry, J.A.; Jaffe, E.S. NK-cell Enteropathy: A Benign NK-cell Lymphoproliferative Disease Mimicking Intestinal Lymphoma: Clinicopathologic Features and Follow-up in a Unique Case Series. *Blood* **2011**, *117*, 1447–1452. [CrossRef] [PubMed]
37. Tanaka, T.; Megahed, N.; Takata, K.; Asano, N.; Niwa, Y.; Hirooka, Y.; Goto, H. A Case of Lymphomatoid Gastropathy: An Indolent CD56-positive Atypical Gastric Lymphoid Proliferation, Mimicking Aggressive NK/T Cell Lymphomas. *Pathol. Res. Pract.* **2011**, *207*, 786–789. [CrossRef] [PubMed]
38. Yamamoto, J.; Fujishima, F.; Ichinohasama, R.; Imatani, A.; Asano, N.; Harigae, H. A Case of Benign Natural Killer Cell Proliferative Disorder of the Stomach (Gastric Manifestation of Natural Killer Cell Lymphomatoid Gastropathy) Mimicking Extranodal Natural Killer/T-cell Lymphoma. *Lek. Lymphoma* **2011**, *52*, 1803–1805. [CrossRef] [PubMed]
39. McElroy, M.K.; Read, W.L.; Harmon, G.S.; Weidner, N. A Unique Case of an Indolent CD56-positive T-cell Lymphoproliferative Disorder of the Gastrointestinal Tract: A Lesion Potentially Misdiagnosed As Natural Killer/T-cell Lymphoma. *Ann. Diagn. Pathol.* **2011**, *15*, 370–375. [CrossRef]
40. Terai, T.; Sugimoto, M.; Uozaki, H.; Kitagawa, T.; Kinoshita, M.; Baba, S.; Yamada, T.; Osawa, S.; Sugimoto, K. Lymphomatoid Gastropathy Mimicking Extranodal NK/T Cell Lymphoma, Nasal Type: A case Report. *World J. Gastroenterol.* **2012**, *18*, 2140–2144. [CrossRef] [PubMed]
41. Ishibashi, Y.; Matsuzono, E.; Yokoyama, F.; Ohara, Y.; Sugai, N.; Seki, H.; Miura, A.; Fujita, J.; Suzuki, J.; Fujisawa, T.; et al. ACase of Lymphomatoid Gastropathy: A Self-limited Pseudomalignant Natural Killer (NK)-Cell Proliferative Disease Mimicking NK/T-Cell Lymphomas. *Clin. J. Gastroenterol.* **2013**, *6*, 287–290. [CrossRef]
42. Koh, J.; Go, H.; Lee, W.A.; Jeon, Y.K. Benign Indolent CD56-positive NK-cell Lymphoproliferative Lesion Involving Gastrointestinal Tract in an Adolescent. *Korean J. Pathol.* **2014**, *48*, 73–76. [CrossRef]
43. Hong, M.; Kim, W.S.; Ko, Y.H. Indolent CD56-positive Clonal T-cell Lymphproliferative Disease of the Stomach Mimicking Lymphomatoid Gastropathy. *Korean J. Pathol.* **2014**, *48*, 430–433. [CrossRef]
44. Takata, K.; Noujima-Harada, M.; Miyata-Takata, T.; Ichimura, K.; Sato, Y.; Miyata, T.; Naruse, K.; Iwamoto, T.; Tari, A.; Masunari, T.; et al. Clinicopathologic Analysis of 6 Lyphomatoid Gastropathy Cases Expanding the Disease Spectrum to CD4-CD8- Cases. *Am. J. Surg. Pathol.* **2015**, *39*, 1259–1266. [CrossRef]
45. Hwang, S.H.; Park, J.S.; Jeong, S.H.; Yim, H. Indolent NK Cell Proliferative Lesion mimicking NK/T Cell Lymphoma in the Gallbladder. *Hum. Pathol. Case Rep.* **2016**, *5*, 39–42. [CrossRef]
46. Wang, R.; Kariappa, S.; Toon, C.; Varikatt, W. NK-cell Enteropathy, a Potential Diagnostic Pitfall of Intestinal Lymphoproliferative Disease. *Pathology* **2019**, *51*, 338–340. [CrossRef]
47. Xia, D.; Morgan, E.A.; Berger, D.; Pinkus, G.S.; Ferry, J.A.; Zukerberg, L.R. NK-cell Enteropathy and Similar Indolent Lymphoproliferative Disorders. A Case Series with Literature Review. *Am. J. Clin. Pathol.* **2019**, *151*, 75–85. [CrossRef] [PubMed]
48. Panigraphi, M.K.; Patra, S.; Kumar, C.; Kumar Nayak, H.; Ayyanar, P.; Bhat, S.J.; Chouhan, M.I.; Samal, S.C. Natural Killer Cell Enteropathy with Extraaintestinal Involvement: Presenting as Symptomatic Anemia. *ACG Case Rep. J.* **2021**, *8*, e00599. [CrossRef]
49. Xiao, W.; Gupta, G.K.; Yao, J.; Yang, Y.J.; Xi, L.; Baik, J.; Sigler, A.; Kumar, A.; Moskowitz, A.J.; Arcila, M.E.; et al. recurrent Somatic JAK3 mutations in NK-cell Enteropathy. *Blood* **2019**, *134*, 986–991. [CrossRef]
50. Yi, H.; Li, A.; Ouyang, B.; Da, Q.; Dong, L.; Liu, Y.; Xu, H.; Zhang, X.; Zhang, W.; Jin, X.; et al. Clinicopathological and Molecular Features of Indolent Naturall Killer-Cell Lymphoproliferative Disorder of the Gastrointestinal Tract. *Histopathology* **2023**, *82*, 567–575. [CrossRef]

51. de Castro, J.V.A.; D'Almeida Costa, F.; Ferreira, C.R. Indolent NK-cell Lymphoproliferative Disorder of the Gastrointestinal Tract—A Report of Two Cases of a New Provisional Entity on the World Health Organization Classification of Hematolymphoid Tumors. *Int. J. Surg. Pathol.* **2023**, *31*, 596–599. [CrossRef] [PubMed]
52. Chuang, S.S.; Li, G.D.; Cheng, C.L.; Ng, S.B.; Huang, Y.; Zhao, S.; Yamaguchi, M.; Zhao, W.L.; Kwong, Y.L. Extranodal NK/T-cell Lymphoma. In *WHO Classification of Haematolymphoid Tumours*, 5th ed.; Chan, J., Lee Wood, B., Eds.; IARC: Lyons, France, 2025. Available online: https://tumourclassification.iarc.who.int/chapters/63 (accessed on 23 October 2025).
53. Bhagat, G.; Naresh, K.N.; Dave, S.S.; Cerf-Benussan, N. Enteropathy-associated T-cell Lymphoma. In *WHO Classification of Haematolymphoid Tumours*, 5th ed.; Chan, J., Washington, N.K., de Jong, D., Eds.; IARC: Lyons, France, 2015. Available online: https://tumourclassification.iarc.who.int/chapters/63 (accessed on 23 October 2025).
54. Chan, J.; Bhagat, G.; Chuang, S.S.; Naresh, K.N.; Dave, S.S.; Nakamura, N.; Kato, S.; Tan, S.Y. Monomorphic Epitheliotropic Intestinal T-cell Lymphoma. In *WHO Classification of Haematolymphoid Tumours*, 5th ed.; de Jong, D., Washington, N.K., Eds.; IARC: Lyons, France, 2015. Available online: https://tumourclassification.iarc.who.int/chapters/63 (accessed on 23 October 2025).
55. Ng, C.S. From the Midfacial Destructive Drama to the Unfolding EBV Story: A Short History of EBV-positive NK-cell and T-cell Lymphoproliferative Diseases. *Pathology* **2024**, *56*, 773–785. [CrossRef]
56. Rahemtullah, A.; Longtine, J.A.; Harris, N.L.; Dorn, M.; Zembowicz, A.; Quintanilla-Fend, L.; Preffer, F.I.; Ferry, J.A. CD20+ T-cell Lymphoma. Clinicopathologic Analysis of 9 Cases and a Review of the Literature. *Am. J. Surg. Pathol.* **2008**, *32*, 1593–1607. [CrossRef] [PubMed]
57. Watabe, D.; Kanno, H.; Inoue-Narita, T.; Onodera, H.; Izumida, W.; Kowata, S.; Sawai, T.; Akasaka, T. A Case of primary Cutaneous Natural Killer/T-cell Lymphoma, Nasal Type, with Indolent Clinical Course: Monoclonal Expansion of Epstein-Barr Virus Genome Correlating with the Terminal Aggressive Behaviour. *Br. J. Haematol.* **2009**, *160*, 197–228. [CrossRef]
58. Seishima, M.; Yuge, M.; Kosugi, H.; Nagasaka, T. Extranodal NK/T-Cell lymphoma, Nasal Type, Possibly arising from Chronic Epstein-Barr Virus Infection. *Acta Derm. Venerol.* **2010**, *90*, 102–103. [CrossRef] [PubMed]
59. Jiang, Q.; Liu, S.; Yang, Y.; Tan, X.; Peng, J.; Xiong, Z.; Li, Z. CD20-positive NK/T-cell Lymphoma with Indolent Clinical Course: Report of Case and Review of Literature. *Diagn. Pathol.* **2012**, *7*, 133. [CrossRef]
60. Zuriel, D.; Fink-Puches, R.; Cerroni, L. A Case of Primary Cutaneous Extranodal Natural Killer/T-cell Lymphoma, Nasal Type, with a 22-Year Indolent Clinical Course. *Am. J. Dermatopathol.* **2012**, *34*, 194–197. [CrossRef] [PubMed]
61. Tabanelli, V.; Valli, R.; Zanelli, M.; Righi, S.; Gazzola, A.; Mannu, C.; Pileri, S.; Sabattini, E. A Case of Sinonasal Extranodal NK/T-cell Lymphoma with Indolent Behaviour and Low-Grade Morphology. *Case Rep. Clin. Med.* **2014**, *3*, 596–600. [CrossRef]
62. Zhang, Q.F.; Hau, Y.N.; Sun, L.M.; Tian, Y.; Qiu, X.S. Nasal Extranodal NK/T-cell Lymphoma Mimicking Inflammatory Polyps: A Case with Indolent Clinical Behavior. *Int. J. Clin. Exp. Pathol.* **2016**, *9*, 336–340.
63. Devins, K.; Schuster, S.J.; Caponetti, G.C.; Bogusz, M. Rare Case of Low-Grade Extranodal NK/T-cell Lymphoma, Nasal Type, Arising in the Setting of Chronic Rhinosinusitis and Harboring a Novel N-Terminal *KIT* Mutation. *Diagn. Pathol.* **2018**, *13*, 92. [CrossRef]
64. Wang, Z.; Gong, Q.; Zhao, Y.; Xu, H.; Hu, S.; Zhang, Z. Indolent EBV-positive T-cell Lymphoproliferative Disorder Arising in a Chronic Pericardial Hematoma: The T-cell Counterpart of Fibrin-associated Diffuse Large B-cell Lymphoma? *Haematologica* **2020**, *105*, e437. [CrossRef]
65. Krishman, R.; Ring, K.; Williams, E.; Portell, C.; Jaffe, E.S.; Gru, A.A. An Enteropathy-like Indolent NK-cell proliferation Presenting in the Female Genital Tract. *Am. J. Surg. Pathol.* **2020**, *44*, 561–565. [CrossRef]
66. Saglam, A.; Singh, K.; Gollapudi, S.; Kumar, J.; Brar, N.; Butzmann, A.; Warnke, R.; Ohgami, R.S. Indolent T-lymphoblastic Proliferation: A Systemic Review of the Literature Analyzing the Epidemiologic, Clinical, and Pathologic Features of 45 Cases. *Int. J. Lab. Hematol.* **2022**, *44*, 700–711. [CrossRef] [PubMed]
67. Ohgami, R.S.; Arber, D.A.; Zehnder, J.L.; Nathunam, Y.; Warnke, R. Indolent T-lymphoblastic Proliferation (iT-LBP): A Review of Clinical and Pathologic Features and Distinction from Malignant T-lymphoblastic Lymphoma. *Adv. Anat. Pathol.* **2013**, *20*, 137–140. [CrossRef] [PubMed]
68. Pizzi, M.; Brignola, S.; Righi, S.; Algostinelli, C.; Bertuzzi, C.; Pillon, M.; Semenzato, G.; Rugge, M.; Sabattini, E. Benign Tdt-positive Cells in Pediatric and Adult Lymph Nodes: A Potential Diagnostic Pitfall. *Hum. Pathol.* **2018**, *81*, 131–137. [CrossRef]
69. Goodlad, J.R.; Cerroni, L.; Swerdlow, S.H. Recent Advances in Cutaneous Lymphoma—Implications for Current and Future Classifications. *Virchows Archiv.* **2023**, *482*, 281–298. [CrossRef] [PubMed]
70. Beltzung, F.; Ortonne, N.; Pelletier, L.; Beylot-Berry, M.; Ingen-Housz-Oro, S.; Franck, F.; Pereira, B.; Godfraind, C.; Delfau, M.; D'Incan, M.; et al. Primary Cutaneous CD4+ Small/Medium T-cell Lymphoproliferative Disorders: A Clinical Pathologic Molecular Study of 60 Cases Presenting with a Single Lesion: A Multicenter Study Group. *Am. J. Surg. Pathol.* **2020**, *44*, 862–872. [CrossRef] [PubMed]
71. Greenblatt, D.; Ally, M.; Child, F.; Scarisbrick, L.; Whittaker, S.; Morris, S.; Calonje, E.; Petrella, T.; Robson, A. Indolent $CD8^+$ Lymphoid Proliferation of Acral Sites: A Clinicopathologic Study of Six Patients with Some Atypical Features. *J. Cutan. Pathol.* **2013**, *40*, 248–258. [CrossRef] [PubMed]

72. Vergier, B.; Jansen, P.M.; Ortonne, N.; Pulitzar, M.; Williemze, T.; Mitteldorf, C. Primary Cutaneous CD4-positive Small or Medium T-cell Lymphoprolifewrative Disorders. In *WHO Classificarion of Haematolymphoid Tumours*, 5th ed.; Lazar, A.J., Coupland, S.E., Akkari, Y., Eds.; IARC: Lyons, France, 2025. Available online: https://tumourclassification.iarc.who.int/chapters/63 (accessed on 23 October 2025).
73. Kemp, W.; Pulitzer, M.; Robson, A.; Mitteldorf, C. Primary Cutaneous Acral CD8-positive T-cell Lymphoproliferative Disorders. In *WHO Classification of Haematolymphoid Tumours*, 5th ed.; Lazar, A.J., Coupland, S.E., Akkar, Y., Eds.; IARC: Lyons, France, 2025. Available online: https://tumourclassification.iarc.who.int/chapters/63 (accessed on 23 October 2025).
74. Tamehiro, N.; Nishida, K.; Sugita, Y.; Hayakawa, K.; Oda, H.; Nitta, T.; Nakano, M.; Nishioka, A.; Yanobu-Takanashi, R.; Goto, M.; et al. Ras Homolog Gene Family H (RhoH) Deficiency Induces Psoriasis-like Chronic Fermatitis by Promoting TH17 Cell Polarization. *J. Allergy Clin. Immunol.* **2019**, *143*, 1878–1891. [CrossRef] [PubMed]
75. Crequer, A.; Troeger, A.; Patin, E.; Ma, C.S.; Picard, C.; Pederana, V.; Fieschi, C.; Lim, A.; Abhyankar, A.; Gineau, L.; et al. Human RHOH Deficiency Causes T Cell Defects and Susceptibility to EV-HPV Infection. *J. Clin. Investig.* **2012**, *122*, 3239–3247. [CrossRef] [PubMed]
76. Edison, N.; Belhanes-Peled, H.; Eitan, Y.; Gutthmann, Y.; Yeremenko, Y.; Raffeld, M.; Elmalah, I.; Troughuboff, P. Indolent T-cell Lymphoproliferative Disease of the Gastrointestinal Tract after a Treatment with adaloimumab in Resistant Crohn's Colitis. *Hum. Pathol.* **2016**, *5*, 45–50. [CrossRef] [PubMed]
77. Chen, K.; Wang, M.; Zhang, R.; Li, J. Detection of Epstein-Barr Virus Encoded RNA in Fixed Cells and Tissues using CRISPR/Cas-mediated R Cas FISH. *Anal Biochem.* **2021**, *625*, 114211. [CrossRef]
78. Qi, Z.; Han, X.; Hu, J.; Wang, G.; Gao, J.; Wang, X.; Liang, D. Comparison of Three Methods for Detection of Epstein-Barr Virus in Hodgkin's Lymphoma in Paraffin-Embedded Tissues. *Mol. Med. Rep.* **2013**, *7*, 89–92. [CrossRef]
79. Leenman, E.E.; Panzer-Grumayer, R.E.; Fischer, S.; Leitch, H.A.; Horsman, D.E.; Lion, T.; Gadner, H.; Ambros, P.F.; Leston, V.S. Rapid Determination of Epstein-Barr Virus Latent or Lytic Infection in Single Human Cells Using In situ Hybridization. *Mod. Pathol.* **2024**, *17*, 1564–1572. [CrossRef]
80. Sun, Y.; Ling, S.; Tang, D.; Yang, M.; Shen, C. Advances in Epstein-Barr Virus Detection: From Traditional Methods to Modern Technologies. *Viruses* **2005**, *17*, 1026. [CrossRef] [PubMed]
81. Naresh, K.N.; Ferry, J.A.; Du, M. Introduction to B-cell Lymphproliferative Disorders and Neoplasms. In *WHO Classfication of Haematolymphoid Tumours*, 5th ed.; IARC: Lyons, France, 2025. Available online: https://tumourclassification.iarc.who.int/chapters/63 (accessed on 23 October 2025).

Disclaimer/Publisher's Note: The statements, opinions and data contained in all publications are solely those of the individual author(s) and contributor(s) and not of MDPI and/or the editor(s). MDPI and/or the editor(s) disclaim responsibility for any injury to people or property resulting from any ideas, methods, instructions or products referred to in the content.