Journal of
Clinical & Translational Ophthalmology

MDPI

Perspective

Imaging the Anterior Segment in Spaceflight: Understanding and Preserving Astronaut Ocular Health for Long-Duration Missions

Joshua Ong [1,*], Ritu Sampige [2], Ryung Lee [3], Hamza Memon [4], Nicholas Panzo [4], Cihan Mehmet Kadipasaoglu [5], Yannie Guo [2], Baltaj S. Sandhur [6], Benjamin Soares [7], Daniela Osteicoechea [4], Ethan Waisberg [8], Alex Suh [9], Tuan Nguyen [10], Mouayad Masalkhi [11], Prithul Sarker [12], Nasif Zaman [12], Alireza Tavakkoli [12], John Berdahl [13], Patricia Chévez-Barrios [4,7,14,15] and Andrew G. Lee [4,7,16,17,18,19,20]

1 Department of Ophthalmology and Visual Sciences, University of Michigan Kellogg Eye Center, Ann Arbor, MI 48105, USA
2 Department of Ophthalmology, Baylor College of Medicine, Houston, TX 77030, USA
3 Touro College of Osteopathic Medicine, New York, NY 10027, USA
4 Texas A&M School of Medicine, Bryan, TX 77807, USA
5 Department of Neurology, Blanton Eye Institute, Houston Methodist Hospital, Houston, TX 77030, USA
6 Jacobs School of Medicine and Biomedical Sciences, State University of New York at Buffalo, Buffalo, NY 14203, USA
7 Chobanian & Avedisian School of Medicine, Boston University School of Medicine, Boston, MA 02118, USA
8 Department of Clinical Neurosciences, University of Cambridge, Cambridge CB2 1TN, UK
9 Tulane University School of Medicine, New Orleans, LA 70112, USA
10 Weill Cornell/Rockefeller/Sloan-Kettering Tri-Institutional MD-PhD Program, New York, NY 10065, USA
11 School of Medicine, University College Dublin, Belfield, D04 C1P1 Dublin, Ireland
12 Human-Machine Perception Laboratory, Department of Computer Science and Engineering, University of Nevada, Reno, Reno, NV 89512, USA
13 Vance Thompson Vision, Sioux Falls, SD 57108, USA
14 Department of Pathology and Genomic Medicine, Houston Methodist Hospital, Houston, TX 77030, USA
15 University of Texas MD Anderson Cancer Center, Houston, TX 77030, USA
16 Center for Space Medicine, Baylor College of Medicine, Houston, TX 77030, USA
17 The Houston Methodist Research Institute, Houston Methodist Hospital, Houston, TX 77030, USA
18 Departments of Ophthalmology, Neurology, and Neurosurgery, Weill Cornell Medicine, New York, NY 10065, USA
19 Department of Ophthalmology, University of Texas Medical Branch, Galveston, TX 77555, USA
20 Department of Ophthalmology, The University of Iowa Hospitals and Clinics, Iowa City, IA 52242, USA
* Correspondence: ongjo@med.umich.edu

Abstract: In light of the potential effects of spaceflight on the anterior segment of the eye, there is a pressing need for anterior segment imaging to be available and accessible to monitor astronauts' ocular health, including alterations to the cornea and lens. We aim to highlight the clinical basis and need for anterior segment imaging for astronauts. We explore the impacts of spaceflight-associated hazards, including microgravity and radiation, on astronauts' risk of developing anterior segment pathology including risk of ocular trauma, infection, dry eye symptoms, cataracts, and possibly additional pathologies from increased radiation exposure. Such risks highlight the potential value that longitudinal assessment of anterior ocular structures would offer in future spaceflight missions. Specifically, anterior segment imaging would enable evaluations of corneal morphology, including longitudinal monitoring for microgravity-induced changes, and evaluation of interventions that aim to preserve anterior segment health during spaceflight. Lastly, non-invasive anterior segment imaging allows for unique insights into astronaut ocular health and can be performed routinely through modalities such as anterior segment optical coherence tomography (AS-OCT) and ultrasound biomicroscopy (UBM). We discuss these modalities and their implications for astronaut health during future spaceflight.

check for updates

Academic Editor: Sotiria Palioura

Received: 14 November 2024
Revised: 6 March 2025
Accepted: 10 March 2025
Published: 18 March 2025

Citation: Ong, J.; Sampige, R.; Lee, R.; Memon, H.; Panzo, N.; Kadipasaoglu, C.M.; Guo, Y.; Sandhur, B.S.; Soares, B.; Osteicoechea, D.; et al. Imaging the Anterior Segment in Spaceflight: Understanding and Preserving Astronaut Ocular Health for Long-Duration Missions. *J. Clin. Transl. Ophthalmol.* **2025**, *3*, 5. https://doi.org/10.3390/jcto3010005

Copyright: © 2025 by the authors. Licensee MDPI, Basel, Switzerland. This article is an open access article distributed under the terms and conditions of the Creative Commons Attribution (CC BY) license (https://creativecommons.org/licenses/by/4.0/).

Keywords: cornea; spaceflight; ocular surface; space medicine ophthalmology; imaging

1. Introduction

Space exploration has long been associated with physiological challenges for astronauts, with ocular health emerging as a prominent concern. Early space missions, such as the Apollo and Skylab programs, reported visual disturbances and changes in intraocular pressure among crew members [1,2]. Subsequent research, including studies conducted aboard the International Space Station (ISS), has further elucidated the impact of microgravity on the visual system [3,4]. In fact, these findings have highlighted the need for further research to ensure the safety and well-being of astronauts during long-duration missions. To date, research efforts have been focused on the posterior segment compared to the anterior segment for imaging, likely in part due to the discovery of spaceflight-associated neuro-ocular syndrome (SANS), which has been at the forefront of recent studies. SANS is a significant physiological barrier to future spaceflight and, thus, an incredibly important research area [3,4]. Additionally, there may also be areas for further advancement for understanding the anterior segment of the eye in microgravity (Figure 1).

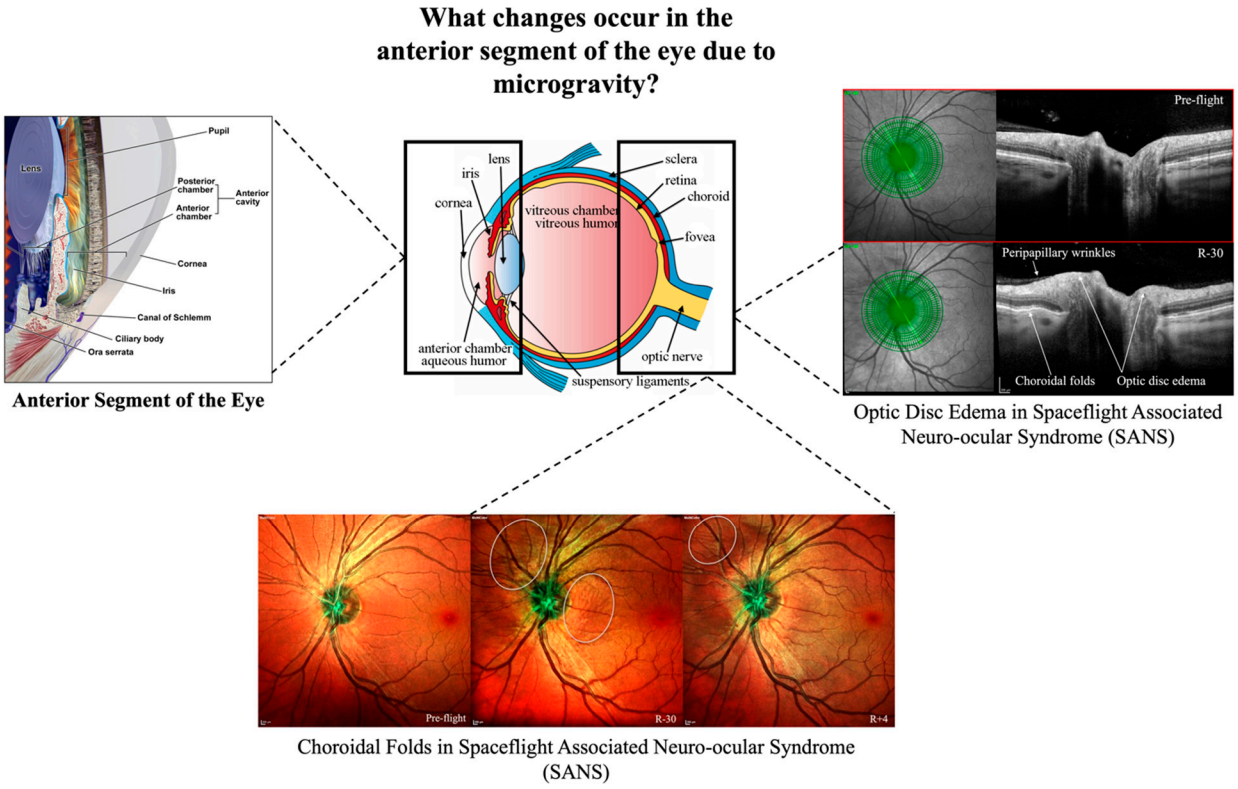

Figure 1. Spaceflight-associated neuro-ocular syndrome (SANS) is a well-characterized phenomenon partly due to in-flight posterior segment imaging techniques such as fundus photography and optical coherence tomography (OCT). Are there changes that occur in the anterior segment of the eye due to microgravity and can these be detected with anterior segment imaging? Image reprinted with permission from Ong J et al., Holly Fischer (WikiMedia Commons), and BruceBlaus (WikiMedia Commons) under Creative Common Licenses [5–7].

The anterior segment of the eye comprises structures such as the cornea, iris, lens, and aqueous humor dynamics, each of which plays a critical role in visual function and ocular health [8,9]. Alterations in the anterior segment, induced by microgravity and fluid shifts, can significantly impact astronaut vision, refractive power, and intraocular

pressure regulation [10–12]. Consequently, understanding anterior segment ophthalmic considerations in spaceflight is essential for mitigating vision-related risks. These in turn help to optimize astronaut performance, as well as mission success. Within this paper, we aim to examine the need for anterior segment imaging modalities in spaceflight, particularly exploring anterior segment optical coherence tomography (AS-OCT) and ultrasound biomicroscopy (UBM). By highlighting anterior segment anatomical changes, physiological adaptations, and potential clinical implications for astronauts, this article explores the need for anterior segment imaging to be increasingly accessible for astronauts to promptly assess ocular changes, such as through in-flight and ISS-housed imaging modalities. Finally, this article seeks to inform future research directions, intervention strategies, and mission planning efforts to safeguard astronauts' ocular health and well-being by synthesizing current knowledge and identifying gaps in understanding regarding the anterior segment of the eye.

2. Impacts of Spaceflight on the Anterior Segment of the Eye

2.1. Microgravity

A notable ophthalmic finding in spaceflight is SANS, which has been observed in astronauts following long-duration spaceflight [3]. SANS highlights changes in the posterior segment of the eye and is characterized by optic disc edema, chorioretinal folds, posterior globe flattening, and hyperopic refractive shifts [3]. There are various hypotheses for the underlying etiology of SANS, and while we still lack a definite model for SANS pathogenesis at this time, it is clear that the physiological changes resulting from microgravity exposure are associated with vision changes during spaceflight [3].

Another important consideration is the relationship between anterior segment/corneal changes and microgravity. In microgravity environments, particles that are typically harmless on Earth may instead remain airborne in space, increasing the risk of corneal abrasions or damage to the corneal epithelium and subsequent complications of bacterial ulcerative keratitis [11]. Furthermore, murine spaceflight studies from the STS-133 mission revealed histopathological evidence of corneal acanthosis and epithelial edema presumed to have developed as a result of microgravity-induced ocular fluid shifts [13]. Delays in corneal epithelial wound healing in microgravity have also been demonstrated in murine hindlimb suspension experiments [14]. Additionally, rabbit experiments performed under simulated microgravity have demonstrated changes in corneal stromal cell morphology, yielding cell aggregates [15]. Stem cell differentiation is further disrupted in spaceflight, leading to potential unforeseen tissue responses because the corneal epithelial limbal stem cells provide corneal replenishment [16,17]. Lastly, with regards to the lens, fluid shifts due to microgravity raise the risk of the movement of the lens in the axial direction, a factor that may be contributing to the hyperopic changes and visual acuity deficits reported in astronauts [10]. In each of the disease processes discussed, easy and reliable access to anterior segment imaging would facilitate prompt diagnosis and timely in-flight management determinations if necessary. Furthermore, the collection of concrete data about transpired ocular events during spaceflight would greatly aid the development of future appropriate countermeasures. Beyond the effects of microgravity, radiation exposure is a serious concern that needs to be considered. Understanding these risks is essential for developing protection strategies for long-term spaceflight.

2.2. Radiation

It has been well studied that radiation can stimulate the production of specific pro-inflammatory cytokines, such as tumor necrosis factor-alpha (TNF-α) and interleukin-1 (IL-1), resulting in states of chronic inflammation [18]. On Earth, the ozone layer serves

a critical role as a protective barrier by absorbing harmful UV radiation between 190 and 350 nm along with oxygen, which absorbs radiation between 195 and 220 nm [19]. However, in space, astronauts face much higher levels of radiation due to the lack of protection from the atmosphere and ozone layer.

Astronauts are susceptible to various forms of radiation such as galactic cosmic radiation (GCR) and solar cosmic radiation (SCR), which can penetrate deeper structures compared to UV radiation [19]. While traveling in low earth orbit, the Earth's magnetic field helps to protect against these types of radiation, but those who travel beyond this region are vulnerable to these rays [20]. The longest time spent outside of low earth orbit was during the Apollo 17 mission, which lasted a total of 12 days. While the long-term effects of GCR and SCR remain unclear, a mission to Mars, which could take upwards of 3 years, would undoubtedly expose the body to significantly higher radiation levels, the effects of which remain unknown at this time [20–22].

Notably, current astronauts and murine studies have not supported a direct inflammatory-mediated mechanism of corneal injury, which would result in corneal opacification due to its avascular and transparent tissue properties. Taking findings from terrestrial studies into account, the risks may be secondary, resulting from inflammatory changes in the adjacent anterior-chamber elements (such as within the conjunctiva), where persistent inflammation may induce tear film changes, leading to dry eyes, corneal surface lesions, impaired wound healing, and tissue regeneration deficits [23]. In the worst-case scenario, this could theoretically lead to corneal surface erosions and ulcers. To date, evidence from astronauts and mice does not demonstrate this degree of injury.

It is also well studied terrestrially that increased radiation exposure leads to increases in ocular surface squamous neoplasia and other anterior segment pathologies [24–26]. Although this has not been observed in astronauts, increased radiation exposure during future space missions will continue to increase the risk and, thus, it is critical to be prepared to diagnose these concerning diseases. The development of effective countermeasures to mitigate such risks would depend upon in-flight data collected via reliable anterior segment imaging modalities. In the setting of increased radiation exposure, molecular research on the ocular surface conjunctiva and cornea represents a critical area of investigation to ensure the safety and well-being of astronauts.

Multiple studies on NASA astronauts have investigated the effects of radiation and cataract formation, and current evidence appears to support a dose-dependent relationship between radiation exposure and the increased risk of earlier cataract development in astronauts [27]. More specifically, ionizing radiation exposure during spaceflight increases the risk of early-onset lens opacification [28,29]. Beyond low earth orbit, even low doses of ionizing radiation may induce cataracts due to high linear energy transfer [30]. In one analysis of 295 astronauts, those exposed to higher radiation doses (>8 mSv) had a higher risk of developing cataracts compared to those exposed to lower doses (<8 mSv) [28]. The NASA Study on Cataract in Astronauts (NASCA) identified a link between space radiation exposure and increased posterior subcapsular (PSC) lens opacities, with astronauts who received higher radiation doses exhibiting larger PSC sizes [31]. Moreover, NASA astronauts were shown to have a greater density of cataracts compared to personnel in other flight operations, such as the U.S. Air Force (USAF) and Navy (USN) [27].

At the cellular level, radiation damages the generation of necessary enzymes due to upstream damage of the lens cell membrane and DNA, leading to detrimental changes to protein levels and ensuing lens opacification [29]. During space travel, astronauts remain continuously exposed to higher quantities of all forms of radiation [32]; thus, longitudinal imaging is needed to track lens changes over time to ensure the timely identification

of cataract development so that appropriate countermeasures can be initiated prior to significant or irreversible visual acuity compromise.

3. Imaging the Anterior Segment of the Eye

3.1. The Critical Role That Imaging Plays in Ocular Health

Imaging the anterior segment is of critical importance both in acute and longitudinal settings. For example, lens dislocation from microgravity-induced trauma is an ophthalmic emergency that requires timely diagnosis and management, particularly if the dislocation is inciting intraocular inflammation. Thus, having access to anterior segment imaging will allow for the rapid identification of significant changes to the lens and, thus, adequate management in a timely manner [33]. By observing anterior chamber depth and angles, we may also be able to elicit a better understanding regarding fluidics and IOP fluctuations that are observed in spaceflight [34,35]. Astronauts are also exposed to high levels of radiation during spaceflight; thus, monitoring for dysplastic diseases such as ocular surface squamous neoplasia that may grow over the course of many months is critically important. Additionally, advancements in telemedicine technologies enable the real-time monitoring of astronaut ocular health parameters and facilitate timely intervention in cases of ocular emergencies and concerning ocular diseases. However, there are hindrances to telemedicine technologies, including relay bandwidth limitations on missions leaving low earth orbit, further emphasizing the need for easy-to-implement ophthalmic imaging such as AS-OCT onboard [36].

The incorporation of possible artificial gravity systems into spacecraft design may help to mitigate the physiological changes associated with microgravity exposure and reduce the risk of ocular complications during long-duration space missions [37]. Additionally, by further elucidating the molecular pathways involved in the cornea's response to space radiation, research can pinpoint potential targets for therapeutic interventions. These interventions may include antioxidant supplementation or anti-inflammatory medications that safeguard the cornea from radiation-induced damage and preserve astronauts' vision during long-duration space missions.

Eyedrops such as artificial tears (carboxymethylcellulose, Hypromellose, mineral oil and white petroleum), steroids, cycloplegics (cyclopentolate, Tropicamide), and antibiotics (Tobramycin/Dexamethasone, Moxifloxacin, Erythromycin) currently available on NASA medical kits can address some of the anterior segment issues once detected by anterior segment imaging modalities [38]. Continued research and innovation in these areas are crucial for enhancing the effectiveness of ocular health countermeasures and ensuring the safety and well-being of astronauts during space exploration.

3.2. Ultrasound Biomicroscopy (UBM)

One modality of anterior segment imaging is UBM, which may serve as a low-mass, non-invasive imaging technique that utilizes high-frequency ultrasound waves to generate detailed cross-sectional images of the anterior segment of the eye, including the cornea, anterior chamber angle, and iris and the distances between these structures (Figure 2) [39]. Rather than using the 10 MHz frequency of ophthalmic diagnostic ultrasound, UBM utilizes frequencies of 50–100 MHz [12]. This increased frequency allows UBM to produce higher-resolution images at the cost of a decreased tissue depth. In the case of anterior segment imaging, however, the limited tissue penetration of the ultrasound waves is not a concern due to the subsurface ocular location of the anterior segment. As such, the location of the anterior segment allows UBM to be ideal for imaging a variety of conditions [12]. UBM offers the ability to obtain non-invasive, high-quality images for the diagnosis and

management of anterior chamber angle and various pathologies such as primary angle closure glaucoma [40].

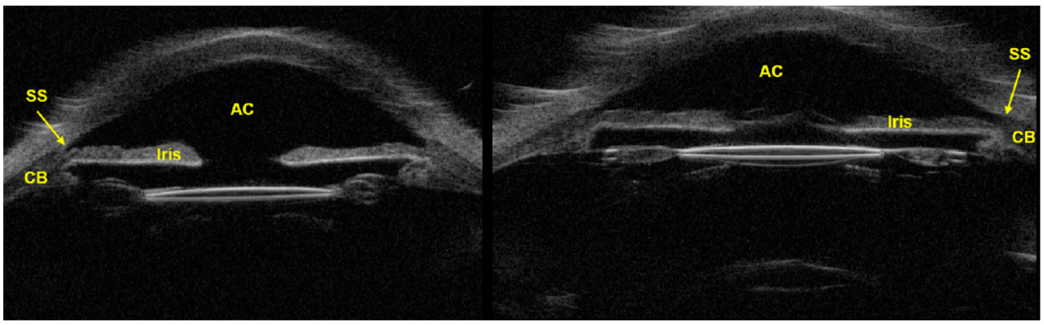

Figure 2. Anterior segment ultrasound biomicroscopy (UBM) visualizing anterior segment structures including the anterior chamber (AC), scleral spur (SS), iris, and structures posterior to the iris, such as the ciliary body (CB). Image reprinted with permission from Helms et al. under a Creative Commons License [41].

3.3. Anterior Segment Optical Coherence Tomography (AS-OCT)

AS-OCT can also serve as a very powerful technology for imaging the cornea [42]. AS-OCT non-invasively utilizes infrared light ranging from 1050 to 1310 nm to collect data regarding the depth, width, and volume of the anterior chamber via two- and three-dimensional cross-sectional images [12,43]. Heidelberg Engineering's OCT is already available on the International Space Station (ISS), and it has been primarily used for posterior segment imaging and, thus, may be a versatile modality to understand anterior segment changes for future spaceflight [44,45]. OCT imaging aids in the understanding of glaucoma mechanisms and the diagnosis and treatment of dry eye syndrome [8].

With the array of potential anterior segment complications that astronauts may experience during spaceflight, there is a need for AS-OCT to be available for astronauts' utilization, especially since AS-OCT focuses on anterior segment data, including the width and volume of the anterior chamber (Figure 3) [12]. Other benefits of AS-OCT include its non-invasiveness, high resolution, shorter preparation time, and reproducibility [46,47].

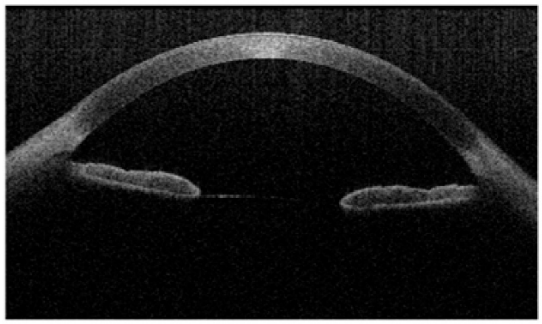

Figure 3. Anterior segment optical coherence tomography demonstrating normal iridocorneal anatomy including sclera, scleral spur, trabecular meshwork, and iris. Image reprinted with permission from Li et al. under a Creative Commons License [33].

3.4. Topography, Tomography, and Wavefront Imaging in Space

Mapping corneal topography and tomography in space is highly salient for non-invasively elucidating astronauts' visual quality, ocular pathology, and corneal changes that occur during spaceflight [14,48]. For instance, corneal topography and tomography imaging can identify early corneal scarring from trauma or infection, current keratoconus or risk of future keratoconus, and pterygia in space, which is necessary to capture in light

of astronauts' reports of keratitis, corneal abrasions, trauma, and corneal ulcers in past NASA space missions [20,22]. Moreover, topography can help to detect dryness and space-associated changes, while tomography could additionally detect volumetric changes in the anterior segment. Three major methods for measuring corneal topography include the Placido method, slit scanning method, and Schiempflug method (Figure 4), with the latter two representing corneal tomography methods in addition to AS-OCT [22,46–48]. While corneal topography maps the anterior surface of the cornea, tomography measures the full corneal thickness and maps both the anterior and posterior corneal surfaces [49–52]. By monitoring corneal thickness via AS-OCT and pachymetry, we can help to link findings such as corneal edema and bullae, which is what we have seen in murine studies [13].

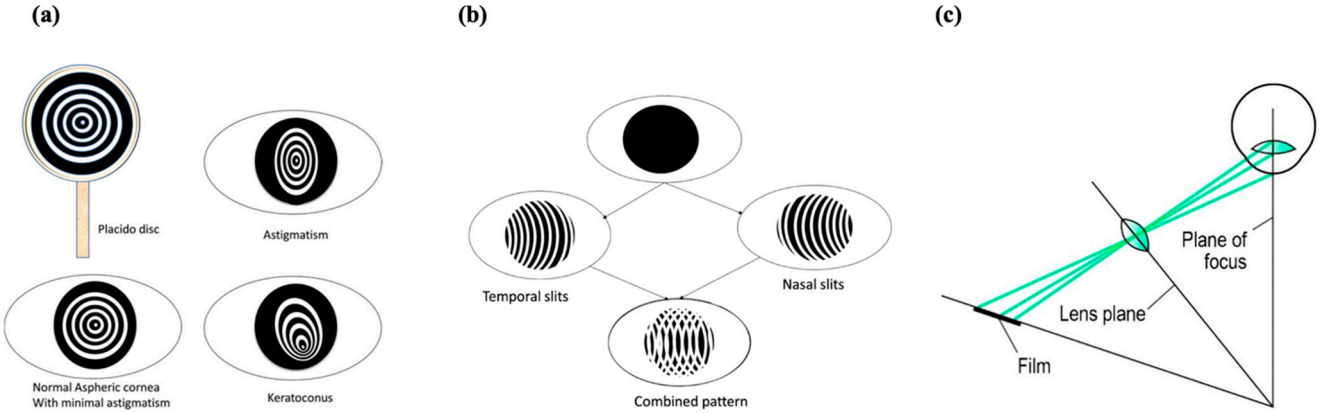

Figure 4. A visual depiction of corneal topography and tomography techniques, including the (**a**) Placido method, (**b**) slit scanning method, and (**c**) Scheimpflug imaging method. Images adapted and reprinted with permission from Liu et al. under a Creative Commons License [49].

The Placido method for identifying corneal topography is a non-invasive method that entails casting images of Placido discs as black and white concentric rings on the cornea, capturing the reflection, and converting the reflection as colored rings that correspond with the curvature and slope of the anterior cornea [49,50,52]. A subsequent analysis of how the rings reflect off of the cornea, including the deformation of the rings, maps anterior corneal topography [49,50,52]. This is the basis for the function of keratoscopes, including computer-based videokeratoscopes, which incorporate mathematical algorithms to identify minute changes in corneal topography [49,50,52]. Though not a method for capturing corneal topography specifically, keratometers measure corneal radius and surface curvature and, thus, evaluate refractive error, astigmatism, and keratoconus by similarly projecting an image and measuring the size of the reflected image to calculate corneal metrics [49,50,52]. Both the use of Placido discs in keratoscopes and the use of keratometers in space would allow for the collection of salient data on corneal health, including the risk of keratoconus and the propensity for dry eye. Next, the slit scanning method includes the projection of slit beams of light, a camera capturing the reflection of the light, and an analyzer within the camera that converts the reflection to a three-dimensional representation of the cornea to identify corneal curvature [49,50,52]. While the Placido method is limited to the anterior corneal surface, the slit scanning method captures the anterior and posterior corneal surfaces [49,50,52]. Lastly, the Scheimpflug imaging method is also a non-invasive technique that images the entire anterior segment with an analysis of the entire corneal thickness and with better focus depth than the slit scanning method [49,50,52]. The Scheimpflug imaging method is based on the use of a rotating camera that captures cross-sectional images of the anterior segment, including data on corneal curvature, thickness, elevation-based topography, and tomography [49,50,52]. Current topographers, which may be used in space,

utilize variations in the aforementioned techniques. For example, the Orbscan topographer utilizes the Placido method, the Pentacam® utilizes the Scheimpflug imaging method, and the Galilei combines the Scheimpflug imaging method with the Placido method [53–55].

Beyond topography and tomography mapping, corneal wavefront imaging utilizes a wavefront aberrometer to form three-dimensional images after projecting light waves, measuring the returning waves, and comparing the returning wavefront to the ideal wavefront for any distortions [56,57]. While primarily used to measure refractive error and corneal aberrations, including during laser eye surgery, wavefront imaging has great potential for further use and the identification of low-order and high-order visual aberrations during spaceflight, especially among astronauts after laser vision correction. The described imaging methods, such as corneal tomography and wavefront imaging, are not mutually exclusive. For instance, astronauts may benefit from a combined AS-OCT and wavefront-based aberrometer system that identifies wavefront distortions after projecting the OCT beam [58]. With the use of a single light source and light beam for both technologies [58], such imaging technology becomes more compact and integrated for use in space-limited spacecrafts.

3.5. Importance, Comparison, and Limitations of Anterior Segment Imaging

Risks to the anterior segment during spaceflight highlight the importance of integrating ocular health monitoring into pre-flight assessments and in-flight medical protocols. As discussed in the previous sections, various modalities can image the anterior segment. It is, thus, important to compare and contrast the clinical advantages of UBM and AS-OCT and how these imaging modalities impact clinical decision making [59–61]. Compared to AS-OCT, UBM is deemed superior in its ability to image anterior segment tumors (69% vs. 31%), pigmented tumors (66% vs. 34%), ciliary body tumors (93% vs. 7%), and iris melanoma (72% vs. 28%) [62]. Thus, this gives it a possible advantage in tumor monitoring when taking into consideration the increased radiation exposure in space. At this time, UBM does not exist on the ISS; however, its superior imaging quality may serve as a useful modality to image structures behind the iris, including the ciliary body and lens for close monitoring of iris nevi, cysts, melanomas, and ciliary body tumors, an area that AS-OCT is less optimized to capture [63,64]. Furthermore, in light of the more accessible usability of AS-OCT, in comparison to UBM, AS-OCT may be straightforwardly incorporated for astronauts' use [12]. While UBM allows for the visualization of ciliary body pathology, AS-OCT provides precise and comparably accurate measurements and a sharper definition of the scleral spur [59]. It is, thus, important for future research to determine the most high-risk anterior segment pathologies that astronauts may face that would lend to using one imaging modality over the other.

Regardless of the modality, in the context of spaceflight, anterior segment imaging can be immensely beneficial for understanding the dynamics of the cornea and other surrounding ocular structures in a microgravity environment with the following considerations.

1. Corneal Morphology: It will be important to capture high-resolution images of the cornea, allowing researchers and clinicians to visualize its structure with exceptional detail. This includes assessing corneal thickness, curvature, and any changes in shape or morphology that may occur during spaceflight. This is especially salient for monitoring conditions like corneal edema, epithelial defects, or changes in the angle structures of the eye.
2. Longitudinal Monitoring: By conducting anterior segment imaging before, during, and after spaceflight missions, researchers and clinicians can track the evolution of corneal and anterior segment changes over time. This longitudinal monitoring

provides valuable insights into the progression of ocular alterations in response to microgravity and space radiation exposure.

3. Evaluation of Interventions: Anterior segment imaging can also be used to assess the efficacy of interventions aimed at mitigating the effects of microgravity on ocular health. These interventions include pharmacological treatments, protective eyewear, and shielding techniques for protection from space radiation. In essence, anterior segment imaging can help space medicine clinicians to evaluate the impact of various interventions on anterior segment anatomy and physiology.

While UBM has certain advantages, it also has its own limitations. UBM requires the addition of a coupling medium in order to gather an image [12]. This requirement may be more cumbersome in a microgravity setting where handling gels or liquids can be tricky. Traditionally, when using this device, patients are required to be placed in a supine position, one which allows the iris diaphragm to fall back and theoretically helps to deepen the anterior chamber and open the angle [59]. The need for repositioning to a supine position may serve as a disadvantage when compared to AS-OCT, which allows patients to remain in a seated position. Additionally, UBM can only image a single quadrant at a time compared to AS-OCT, which can capture all four quadrants at once [59]. The need for multiple scans to image the entire anterior segment with UBM introduces variability in image quality and is something to consider, especially in an environment like space.

Although AS-OCT has immense potential to benefit astronaut vision, there are also various limitations. For instance, although the AS-OCT speed of image collection is faster than that of UBM, tissue penetration is far less compared to UBM, as the pigmented posterior layer of the iris limits passage of infrared light, thereby causing the ciliary body and suprachoroidal space to not be visualized [12,42,43,47]. Furthermore, when comparing AS-OCT versus UBM, AS-OCT has been shown to yield smaller anterior chamber angle values and higher depth measurements [42,59]. Time-domain AS-OCT is limited by the duration of the reference mirror collecting tissue reflectivity data [43]. Despite these limitations, AS-OCT remains as a powerful imaging tool for the anterior segment.

With regard to corneal topography, the Placido method is limited to solely analyzing the anterior cornea surface without data from the posterior surface and to only limited information about the paracentral and peripheral corneal surface [49,50,52]. Additionally, this technique is limited by the integrity of the tear film; any abnormalities of the tear film may distort the reflection of the discs and, thus, the results obtained [46]. Lastly, astronauts' movement in spaceflight may also distort results. Although the Placido method is limited to the anterior cornea surface while the slit scanning method captures both anterior and posterior surfaces of the cornea, there are limitations in the quality of the data regarding the posterior surface due to the central position of the slit scanning camera and limitations with focus depth, in comparison to Scheimpflug imaging [49]. Ultimately, the investigation of anterior segment risks in microgravity and the ability to capture these risks is the critical deciding factor for selecting an anterior segment imaging modality.

4. Future Directions and Conclusions

Anterior segment imaging including AS-OCT and UBM during spaceflight can serve as a powerful tool for comprehensively assessing the impact of spaceflight and microgravity on the anterior segment structures of the eye. Astronauts' risk for developing anterior segment pathology underscores the need for high-resolution, non-invasive, and accessible anterior segment imaging for adequate ophthalmic management, and development of countermeasures. Current work is underway to further understand how anterior segment imaging can be tested terrestrially to understand its utility and deployment for future spaceflight, as well as the development of technologies to better understand ocular physi-

ology in space [12]. This current work also involves developing mechanistic models that mathematically characterize fluid flow in the anterior segment, which rely on high-quality imaging modalities to define ocular geometry and tissue behavior. This is particularly important with regard to applications to space medicine, as the pool of astronaut data is much more limited than in terrestrial studies. Models of high fidelity rely on the foundations of well-defined parameters. The application of anterior segment imaging during spaceflight will allow researchers to obtain a variety of measurements to build representative models of anterior segment fluid flow. Ultimately, the goal of these quantitative hydrodynamic models is to contribute towards a more comprehensive understanding of the anterior segment in space.

However, the practical implementation of imaging systems in spaceflight presents several challenges. These devices must be made more compact, which may require modifications to the systems. However, such adjustments are becoming increasingly feasible as technology advances. Astronauts will also need additional training on how to operate these devices in order to obtain high-quality images. Currently, on the ISS, Heidelberg Engineering's Spectralis OCT2 module is primarily used to evaluate the posterior segment. With the use of an anterior segment module, this device has the capabilities of anterior segment imaging, albeit with reduced functionality compared to devices solely designed for AS-OCT imaging [65]. This can serve as another method for implementing anterior segment imaging in space without requiring an entirely new device, thus improving task and spatial efficiency.

By providing detailed anatomical information critical to astronaut vision, anterior segment imaging will likely increase our understanding of ocular health in space and facilitate the development of targeted strategies to protect astronauts' vision during extended missions beyond Earth's atmosphere. Continued collaboration between researchers, clinicians, and space agencies will be critical for advancing our understanding of anterior segment physiology in space for future spaceflight missions such as the mission to Mars.

Author Contributions: Conceptualization, J.O., C.M.K. and A.G.L. investigation, J.O., R.S., B.S.S., D.O., C.M.K., E.W., A.S., T.N., M.M., P.S., N.Z., A.T., J.B., P.C.-B. and A.G.L.; writing—original draft preparation, J.O., R.S., R.L., H.M., N.P., C.M.K. and Y.G. writing—review and editing, J.O., R.S., B.S.S., D.O., C.M.K., E.W., A.S., T.N., Y.G., M.M., P.S., N.Z., A.T., J.B., P.C.-B., A.G.L., R.L., H.M., N.P. and B.S.; supervision, A.G.L.; project administration, J.O.; All authors have read and agreed to the published version of the manuscript.

Funding: This research received no external funding.

Data Availability Statement: No new data were created or analyzed in this study. Data sharing is not applicable to this article.

Conflicts of Interest: Andrew G. Lee reports these financial disclosures: Alexion: speaker Amgen/Horizon: speaker, AstraZeneca: consultant, Bristol Mayers Squibb: consultant, National Football League: consultant, Catalyst: consultant, Viridian: consultant, Ethyreal: consultant, NASA: consultant, US Dept of Justice: consultant, Dompe: consultant, Stoke: consultant. John Berdahl reports these financial disclosures: AbbVie, Aerpio, ALJ Health, Alcon, Aldeyra, Aquea Health, Aurion Biotech, Avelino, Balance Ophthalmics, Bausch And Lomb, Belkin, CorneaGen, Dakota Lions Eye Bank, Elios Vision INC, Expert Opinion, Glaukos, Gore, Greenman, Horizon Surgical, Iacta Pharmaceuticals, Imprimis, iRenix, IVERIC bio, Inc, JNJ, Kala, LayerBio, MELT Pharmaceuticals, MicroOptx, New World Medical, Ocular Surgical Data, Ocular Theraputix, Omega Ophthalmic, Orasis, Oyster Point, RxSight, Santen, Sight Sciences, Surface Inc, Tarsus, TavoBio, Tear Clear, Tissue Gen, True North CRO, Vance Thompson Vision, Verana Health, Versea Biologics, Vertex Ventures, ViaLase. The remaining authors declare that the research was conducted in the absence of any commercial or financial relationships that could be construed as potential conflicts of interest.

References

1. Nelson, E.; Mulugeta, L.; Myers, J. Microgravity-Induced Fluid Shift and Ophthalmic Changes. *Life* **2014**, *4*, 621–665. [CrossRef]
2. McNulty, P.J.; Pease, V.P.; Bond, V.P. *Comparison of the Light Flash Phenomena Observed in Space and in Laboratory Experiments*; Brookhaven National Lab. (BNL): Upton, NY, USA, 1976; p. 7312082. [CrossRef]
3. Martin Paez, Y.; Mudie, L.I.; Subramanian, P.S. Spaceflight Associated Neuro-Ocular Syndrome (SANS): A Systematic Review and Future Directions. *Eye Brain* **2020**, *12*, 105–117. [CrossRef]
4. Makarov, I.A.; Voronkov, Y.I.; Aslanjan, M.G. Ophthalmic changes associated with long-term exposure to microgravity. *Hum. Physiol.* **2017**, *43*, 105–113. [CrossRef]
5. Ong, J.; Tarver, W.; Brunstetter, T.; Mader, T.H.; Gibson, C.R.; Mason, S.S.; Lee, A. Spaceflight associated neuro-ocular syndrome: Proposed pathogenesis, terrestrial analogues, and emerging countermeasures. *Br. J. Ophthalmol.* **2023**, *107*, 895–900. [CrossRef]
6. Holly Fischer (WikiMedia Commons). Available online: https://commons.wikimedia.org/wiki/File:Three_Main_Layers_of_the_Eye.png (accessed on 11 November 2024).
7. BruceBlaus (WikiMedia Commons). Available online: https://commons.wikimedia.org/wiki/File:Blausen_0390_EyeAnatomy_Sectional.png (accessed on 11 November 2024).
8. Ang, M.; Baskaran, M.; Werkmeister, R.M.; Chua, J.; Schmidl, D.; dos Santos, V.A.; Garhöfer, G.; Mehta, J.S.; Schmetterer, L. Anterior segment optical coherence tomography. *Prog. Retin. Eye Res.* **2018**, *66*, 132–156. [CrossRef]
9. Baikoff, G.; Lutun, E.; Ferraz, C.; Wei, J. Static and dynamic analysis of the anterior segment with optical coherence tomography. *J. Cataract Refract. Surg.* **2004**, *30*, 1843–1850. [CrossRef]
10. Mader, T.H.; Gibson, C.R. Early Evidence of Vision Impairment after Long-Duration Spaceflight. In *Intracranial Pressure and Its Effect on Vision in Space and on Earth*; World Scientific: Singapore, 2017; pp. 5–22. [CrossRef]
11. Manuel, F.K.; Mader, T.H. Ophthalmologic Concerns. In *Principles of Clinical Medicine for Space Flight*; Barratt, M.R., Pool, S.L., Eds.; Springer: New York, NY, USA, 2008; pp. 535–544. [CrossRef]
12. He, M.; Wang, D.; Jiang, Y. Overview of Ultrasound Biomicroscopy. *J. Curr. Glaucoma Pract.* **2012**, *6*, 25–53. [CrossRef]
13. Zanello, S.B.; Theriot, C.A.; Ponce, C.M.P.; Chevez-Barrios, P. Spaceflight Effects and Molecular Responses in the Mouse Eye: Preliminary Observations After Shuttle Mission STS-133. *Gravitational Space Res.* **2013**, *1*, 29–46. [CrossRef]
14. Li, Z.; Rivera, C.A.; Burns, A.R.; Smith, C.W. Hindlimb unloading depresses corneal epithelial wound healing in mice. *J. Appl. Physiol.* **2004**, *97*, 641–647. [CrossRef]
15. Li, X.; Yang, Y.; Li, Q.; Dai, Y.; Wang, C.; Chen, J. Morphologic Characteristics and Proliferation of Rabbit Corneal Stromal Cells Onto Complexes of Collagen–Chitosan–Sodium Hyaluronate Under Simulated Microgravity. *Investig. Opthalmol. Vis. Sci.* **2013**, *54*, 6877. [CrossRef]
16. Schlötzer-Schrehardt, U.; Kruse, F.E. Identification and characterization of limbal stem cells. *Exp. Eye Res.* **2005**, *81*, 247–264. [CrossRef] [PubMed]
17. Grimm, D.; Wehland, M.; Corydon, T.J.; Richter, P.; Prasad, B.; Bauer, J.; Egli, M.; Kopp, S.; Lebert, M.; Krüger, M. The effects of microgravity on differentiation and cell growth in stem cells and cancer stem cells. *Stem Cells Transl. Med.* **2020**, *9*, 882–894. [CrossRef]
18. Delic, N.C.; Lyons, J.G.; Di Girolamo, N.; Halliday, G.M. Damaging Effects of Ultraviolet Radiation on the Cornea. *Photochem. Photobiol.* **2017**, *93*, 920–929. [CrossRef]
19. Horneck, G.; Klaus, D.M.; Mancinelli, R.L. Space Microbiology. *Microbiol. Mol. Biol. Rev.* **2010**, *74*, 121–156. [CrossRef] [PubMed]
20. Meer, E.; Grob, S.; Antonsen, E.L.; Sawyer, A. Ocular conditions and injuries, detection and management in spaceflight. *npj Microgravity* **2023**, *9*, 37. [CrossRef] [PubMed]
21. Cucinotta, F.A.; Durante, M. Cancer risk from exposure to galactic cosmic rays: Implications for space exploration by human beings. *Lancet Oncol.* **2006**, *7*, 431–435. [CrossRef]
22. Meer, E.; Grob, S.R.; Lehnhardt, K.; Sawyer, A. Ocular complaints and diagnoses in spaceflight. *npj Microgravity* **2024**, *10*, 1. [CrossRef]
23. Hessen, M.; Akpek, E.K. Dry eye: An inflammatory ocular disease. *J. Ophthalmic. Vis. Res.* **2014**, *9*, 240–250.
24. Gichuhi, S.; Ohnuma, S.-I.; Sagoo, M.S.; Burton, M.J. Pathophysiology of ocular surface squamous neoplasia. *Exp. Eye Res.* **2014**, *129*, 172–182. [CrossRef]
25. Nuzzi, R.; Trossarello, M.; Bartoncini, S.; Marolo, P.; Franco, P.; Mantovani, C.; Ricardi, U. Ocular Complications After Radiation Therapy: An Observational Study. *Clin. Ophthalmol.* **2020**, *14*, 3153–3166. [CrossRef]
26. Durkin, S.R.; Roos, D.; Higgs, B.; Casson, R.J.; Selva, D. Ophthalmic and adnexal complications of radiotherapy. *Acta Ophthalmol. Scand.* **2007**, *85*, 240–250. [CrossRef] [PubMed]
27. Jones, J.A.; McCarten, M.; Manuel, K.; Djojonegoro, B.; Murray, J.; Feiversen, A.; Wear, M. Cataract formation mechanisms and risk in aviation and space crews. *Aviat. Space Environ. Med.* **2007**, *78*, A56–A66.
28. Cucinotta, F.A.; Manuel, F.K.; Jones, J.; Iszard, G.; Murrey, J.; Djojonegro, B.; Wear, M. Space Radiation and Cataracts in Astronauts. *Radiat. Res.* **2001**, *156*, 460–466. [CrossRef]

29. Lipman, R.M.; Tripathi, B.J.; Tripathi, R.C. Cataracts induced by microwave and ionizing radiation. *Surv. Ophthalmol.* **1988**, *33*, 200–210. [CrossRef]
30. Blakely, E.A.; Chang, P.Y. Late Effects of Space Radiation: Cataracts. In *Handbook of Bioastronautics*; Young, L.R., Sutton, J.P., Eds.; Springer International Publishing: Cham, Switzerland, 2021; pp. 277–286. [CrossRef]
31. Chylack, L.T.; Peterson, L.E.; Feiveson, A.H.; Wear, M.L.; Manuel, F.K.; Tung, W.H.; Hardy, D.S.; Marak, L.J.; Cucinotta, F.A. NASA Study of Cataract in Astronauts (NASCA). Report 1: Cross-Sectional Study of the Relationship of Exposure to Space Radiation and Risk of Lens Opacity. *Radiat. Res.* **2009**, *172*, 10–20. [CrossRef] [PubMed]
32. Rastegar, Z.; Eckart, P.; Mertz, M. Radiation-induced cataract in astronauts and cosmonauts. *Graefe's Arch. Clin. Exp. Ophthalmol.* **2002**, *240*, 543–547. [CrossRef]
33. Li, J.; Zhang, H.; Wang, X.; Wang, H.; Hao, J.; Bai, G. Inpainting Saturation Artifact in Anterior Segment Optical Coherence Tomography. *Sensors* **2023**, *23*, 9439. [CrossRef] [PubMed]
34. Dalal, S.R.; Ramachandran, V.; Khalid, R.; Keith Manuel, F.; Knowles, J.R.; Jones, J.A. Increased Intraocular Pressure in Glaucomatous, Ocular Hypertensive, and Normotensive Space Shuttle Crew. *Aerosp. Med. Hum. Perform.* **2021**, *92*, 728–733. [CrossRef]
35. Huang, A.S.; Stenger, M.B.; Macias, B.R. Gravitational Influence on Intraocular Pressure: Implications for Spaceflight and Disease. *J. Glaucoma* **2019**, *28*, 756–764. [CrossRef]
36. De Paula, R.P.; Edwards, C.D.; Flamini, E. Evolution of the communications systems and technology for Mars exploration. *Acta Astronaut.* **2002**, *51*, 207–212. [CrossRef]
37. Isasi, E.; Isasi, M.E.; Van Loon, J.J.W.A. The application of artificial gravity in medicine and space. *Front. Physiol.* **2022**, *13*, 952723. [CrossRef] [PubMed]
38. NASA. 001 MEDICAL KIT-CONTENTS AND REFERENCE. 2015. Available online: https://www.nasa.gov/wp-content/uploads/2015/03/medical_kit_checklist_-_full_release.pdf (accessed on 1 November 2024).
39. Kapoor, R.; Parameswarappa, D.C.; Dhurandhar, D.; Peguda, H.K.; Rani, P.K. Peering into the eye: A comprehensive look at ultrasound biomicroscopy (UBM) and its diagnostic value in anterior segment disorders. *Indian J. Ophthalmol.* **2023**, *71*, 3118. [CrossRef]
40. Patel, A.S.; Akkara, J.D.; DelMonte, D.W.; Morkin, M.; Murchison, A.; Alexander, J.L.; Giaconi, J.A.; Desai, M.; Sheybani, A.; Sollenberger, E.L. Ultrasound Biomicroscopy. Available online: https://eyewiki.org/Ultrasound_Biomicroscopy (accessed on 14 September 2024).
41. Helms, R.W.; Minhaz, A.T.; Wilson, D.L.; Örge, F.H. Clinical 3D Imaging of the Anterior Segment With Ultrasound Biomicroscopy. *Trans. Vis. Sci. Technol.* **2021**, *10*, 11. [CrossRef] [PubMed]
42. Shan, J.; DeBoer, C.; Xu, B.Y. Anterior Segment Optical Coherence Tomography: Applications for Clinical Care and Scientific Research. *Asia Pac. J. Ophthalmol.* **2019**, *8*, 146–157. [CrossRef]
43. Wang, S.B.; Cornish, E.E.; Grigg, J.R.; Mccluskey, P.J. Anterior segment optical coherence tomography and its clinical applications. *Clin. Exp. Optom.* **2019**, *102*, 195–207. [CrossRef]
44. Macias, B.R.; Patel, N.B.; Gibson, C.R.; Samuels, B.C.; Laurie, S.S.; Otto, C.; Ferguson, C.R.; Lee, S.M.C.; Ploutz-Snyder, R.; Kramer, L.A.; et al. Association of Long-Duration Spaceflight With Anterior and Posterior Ocular Structure Changes in Astronauts and Their Recovery. *JAMA Ophthalmol.* **2020**, *138*, 553–559. [CrossRef]
45. Muscat, S.; McKay, N.; Parks, S.; Kemp, E.; Keating, D. Repeatability and reproducibility of corneal thickness measurements by optical coherence tomography. *Investig. Ophthalmol. Vis. Sci.* **2002**, *43*, 1791–1795.
46. Jancevski, M.; Foster, C.S. Anterior Segment Optical Coherence Tomography. *Semin. Ophthalmol.* **2010**, *25*, 317–323. [CrossRef]
47. Mansouri, K.; Sommerhalder, J.; Shaarawy, T. Prospective comparison of ultrasound biomicroscopy and anterior segment optical coherence tomography for evaluation of anterior chamber dimensions in European eyes with primary angle closure. *Eye* **2010**, *24*, 233–239. [CrossRef]
48. Konstantopoulos, A.; Hossain, P.; Anderson, D.F. Recent advances in ophthalmic anterior segment imaging: A new era for ophthalmic diagnosis? *Br. J. Ophthalmol.* **2007**, *91*, 551–557. [CrossRef]
49. Liu, B.; Kang, C.; Fang, F. Biometric Measurement of Anterior Segment: A Review. *Sensors* **2020**, *20*, 4285. [CrossRef] [PubMed]
50. Martin, R. Cornea and anterior eye assessment with placido-disc keratoscopy, slit scanning evaluation topography and scheimpflug imaging tomography. *Indian J. Ophthalmol.* **2018**, *66*, 360–366. [CrossRef]
51. Belin, M.W.; Ambrósio, R. Scheimpflug imaging for keratoconus and ectatic disease. *Indian J. Ophthalmol.* **2013**, *61*, 401–406. [CrossRef]
52. Fan, R.; Chan, T.C.; Prakash, G.; Jhanji, V. Applications of corneal topography and tomography: A review. *Clin. Exp. Ophthalmol.* **2018**, *46*, 133–146. [CrossRef]
53. Crawford, A.Z.; Patel, D.V.; McGhee, C.N.J. Comparison and Repeatability of Keratometric and Corneal Power Measurements Obtained by Orbscan II, Pentacam, and Galilei Corneal Tomography Systems. *Am. J. Ophthalmol.* **2013**, *156*, 53–60. [CrossRef]

54. Motlagh, M.N.; Moshirfar, M.; Murri, M.S.; Skanchy, D.F.; Momeni-Moghaddam, H.; Ronquillo, Y.C.; Hoopes, P.C. Pentacam® Corneal Tomography for Screening of Refractive Surgery Candidates: A Review of the Literature, Part I. *Med. Hypothesis Discov. Innov. Ophthalmol.* **2019**, *8*, 177–203.
55. Moshirfar, M.; Tenney, S.; McCabe, S.; Schmid, G. Repeatability and reproducibility of the galilei G6 and its agreement with the pentacam® AXL in optical biometry and corneal tomography. *Expert Rev. Med. Devices* **2022**, *19*, 375–383. [CrossRef]
56. Maeda, N. Clinical applications of wavefront aberrometry—A review. *Clin. Exp. Ophthalmol.* **2009**, *37*, 118–129. [CrossRef] [PubMed]
57. Charman, W.N. Wavefront technology: Past, present and future. *Contact Lens Anterior Eye* **2005**, *28*, 75–92. [CrossRef] [PubMed]
58. Ruggeri, M.; Belloni, G.; Chang, Y.-C.; Durkee, H.; Masetti, E.; Cabot, F.; Yoo, S.H.; Ho, A.; Parel, J.-M.; Manns, F. Combined anterior segment OCT and wavefront-based autorefractor using a shared beam. *Biomed. Opt. Express* **2021**, *12*, 6746–6761. [CrossRef]
59. Dada, T.; Sihota, R.; Gadia, R.; Aggarwal, A.; Mandal, S.; Gupta, V. Comparison of anterior segment optical coherence tomography and ultrasound biomicroscopy for assessment of the anterior segment. *J. Cataract Refract. Surg.* **2007**, *33*, 837–840. [CrossRef] [PubMed]
60. Radhakrishnan, S. Comparison of Optical Coherence Tomography and Ultrasound Biomicroscopy for Detection of Narrow Anterior Chamber Angles. *Arch. Ophthalmol.* **2005**, *123*, 1053. [CrossRef]
61. Vodapalli, H.; Murthy, S.; Jalali, S.; Ali, M.; Rani, P. Comparison of immersion ultrasonography, ultrasound biomicroscopy and anterior segment optical coherence tomography in the evaluation of traumatic phacoceles. *Indian J. Ophthalmol.* **2012**, *60*, 63. [CrossRef] [PubMed]
62. Bianciotto, C.; Shields, C.L.; Guzman, J.M.; Romanelli-Gobbi, M.; Mazzuca, D.; Green, W.R.; Shields, J.A. Assessment of anterior segment tumors with ultrasound biomicroscopy versus anterior segment optical coherence tomography in 200 cases. *Ophthalmology* **2011**, *118*, 1297–1302. [CrossRef]
63. Krema, H.; Santiago, R.A.; Gonzalez, J.E.; Pavlin, C.J. Spectral-Domain Optical Coherence Tomography Versus Ultrasound Biomicroscopy for Imaging of Nonpigmented Iris Tumors. *Am. J. Ophthalmol.* **2013**, *156*, 806–812.e1. [CrossRef]
64. Ramos, J.L.B.; Li, Y.; Huang, D. Clinical and research applications of anterior segment optical coherence tomography—A review. *Clin. Exp. Ophthalmol.* **2009**, *37*, 81–89. [CrossRef]
65. Heidelberg Engineering's SPECTRALIS OCT2 Module Headed to the International Space Station | Heidelberg Engineering Inc. 22 May 2018. Available online: https://www.heidelbergengineering.com/us/press-releases/heidelberg-engineerings-spectralis-oct2-module-headed-to-the-international-space-station/ (accessed on 5 November 2024).

Disclaimer/Publisher's Note: The statements, opinions and data contained in all publications are solely those of the individual author(s) and contributor(s) and not of MDPI and/or the editor(s). MDPI and/or the editor(s) disclaim responsibility for any injury to people or property resulting from any ideas, methods, instructions or products referred to in the content.