Journal of
Clinical & Translational Ophthalmology

MDPI

Review

Corneal Graft Dehiscence in Patients on Oral Angiotensin-Inhibiting Medications: Plausible Relationship and Review of the Literature

Jie Zhang and Jay J Meyer *

Department of Ophthalmology, Faculty of Medical and Health Sciences, University of Auckland, Auckland 1024, New Zealand; jie.zhang@auckland.ac.nz
* Correspondence: jay.meyer@auckland.ac.nz

Abstract: Wound dehiscence is a rare complication after penetrating keratoplasty (PK) that may occur with or without prior trauma. Multiple factors may influence corneal wound healing, including patient factors, corneal wound characteristics, and other external factors. There is also the possibility that systemic medications could impact corneal wound healing. Possible factors that may predispose a cornea to experience wound dehiscence are discussed. We propose a hypothesis that oral angiotensin-inhibiting medications could play a role in reduced corneal wound healing. A literature review was conducted to investigate the effect of angiotensin inhibitors on corneal wound healing. Five patients on systemic oral angiotensin-inhibiting medications at the time of PK developed dehiscence of the graft–host wound junction following removal of sutures. The dehiscence required resuturing in all cases and resulted in an expulsive choroidal hemorrhage and complete loss of vision in one eye. Age, diabetes, lack of corneal neovascularization, early suture removal, underlying epithelial basement membrane dystrophy, corneal oedema, slower tapering of topical corticosteroid dosage, and glaucoma medication with preservatives were possible predisposing factors for some of these instances of wound dehiscence. However, oral angiotensin-inhibiting medications were taken by all patients in this series, and the literature suggests that ACE inhibitors and ARBs can reduce corneal fibrosis, resulting in inadequate healing. Oral angiotensin-inhibiting medications could have played an anti-fibrotic role in these corneae and predisposed them to wound dehiscence with minimal trauma. Despite limited evidence, these medications warrant further investigation as potential modulators of corneal wound healing.

Keywords: corneal graft dehiscence; penetrating keratoplasty; corneal wound healing; angiotensin; ACE inhibitor; ARB

check for updates

Academic Editors: Giulia Coco and Davide Romano

Received: 18 April 2024
Revised: 19 February 2025
Accepted: 25 February 2025
Published: 27 February 2025

Citation: Zhang, J.; Meyer, J.J. Corneal Graft Dehiscence in Patients on Oral Angiotensin-Inhibiting Medications: Plausible Relationship and Review of the Literature. *J. Clin. Transl. Ophthalmol.* **2025**, *3*, 4. https://doi.org/10.3390/jcto3010004

Copyright: © 2025 by the authors. Licensee MDPI, Basel, Switzerland. This article is an open access article distributed under the terms and conditions of the Creative Commons Attribution (CC BY) license (https://creativecommons.org/licenses/by/4.0/).

1. Introduction

Corneal transplantation represents the most common organ transplant performed worldwide [1]. Penetrating keratoplasty (PK) is a form of corneal transplantation that requires the generation of a full-thickness, 360° corneal wound followed by suturing of a donor corneal button to the host corneal rim. Dehiscence of the corneal wound is a potential vision-threatening complication following PK and typically occurs as a result of trauma [2–7].

Traumatic ruptures can occur following many other ocular surgeries, such as deep anterior lamellar keratoplasty [2–7], radial keratotomy [8,9], cataract extraction [10,11], and laser in situ keratomileusis (LASIK) [12–15]. The wound following PK is particularly

susceptible to traumatic dehiscence when compared to other types of ocular surgery, owing to the large surgical wound [16]. Traumatic ruptures typically occur at the site of the original surgery while eyes that have never had surgery often develop a traumatic rupture at the corneoscleral limbus or at the site of muscle insertions onto the sclera [17]. Traumatic wound dehiscence can occur at any time following surgery, although the first 1–2 years represents the period of highest risk [4,18–21]. In particular, the period immediately following suture removal has been identified as a high-risk period [16].

Wound dehiscence can also occur spontaneously after suture removal and has even been reported following a forceful Valsalva [18,22–26]. Wound dehiscence of the graft–host junction following suture removal after PK, with or without associated wound leakage, has been reported to occur in approximately 2–3% of cases [25,27]. Potential complications subsequent to wound dehiscence include infection with keratitis or endophthalmitis, increased astigmatism, and need for further resuturing [25,27].

We present five cases of wound dehiscence following suture removal after PK that were identified over a 15-year period in patients on oral angiotensin-inhibiting medications, including angiotensin-converting enzyme inhibitors (ACEi) and angiotensin receptor blockers (ARBs). We review the potential factors in these cases and propose a hypothesis that oral angiotensin-inhibiting medications could play a role in reduced corneal wound healing. A literature review was conducted to investigate the effect of angiotensin inhibitors on corneal wound healing and mechanisms.

2. Case Presentations

1. A male in his mid-60s underwent PK (8.25 mm donor sutured with a single continuous 10-0 nylon suture) for Fuchs' dystrophy. Past medical history included hypertension, hyperlipidemia, and type II diabetes. Systemic medications included quinapril 20 mg (an ACEi), once daily. Topical prednisolone acetate 1% was given 6 times per day for 1 month, 4 times per day for 1 month, 3 times per day for 6 months, then discontinued due to a steroid-induced intraocular pressure increase (30 mmHg). Fluorometholone 0.1% and dorzolamide/timolol were given twice daily until removal of the continuous suture at 15 months postoperatively. Two weeks later at a routine follow-up, a 10 clock hour dehiscence was noted and resutured with 16 interrupted 10-0 nylon sutures which were left in place for 3 years.

2. A female in her late 70s underwent PK (8.0 mm donor sutured with 16 interrupted 10-0 nylon sutures) for pseudophakic bullous keratopathy in the setting of an anterior chamber intraocular lens and glaucoma. Past medical history included hypertension, hyperlipidemia, and gastric reflux. Systemic medications included quinapril 20 mg daily and topical medications included latanoprost daily. Topical prednisolone acetate 1% was administered 4 times daily for 6 months, 3 times daily for 4 months, and 2 times daily until suture removal of all sutures in the operating theatre at 25 months following surgery. Three days later, a 4 clock hour area of dehiscence without aqueous leak was noted and resutured with 10 interrupted 10-0 nylon sutures which were removed 2.5 years later without incident.

3. A female in her mid-70s underwent PK (7.75 mm donor sutured with 16 interrupted 10-0 nylon sutures) for pseudophakic bullous keratopathy in the setting of pseudoexfoliative glaucoma and prior trabeculectomy. Medical history included hypertension and type II diabetes. Systemic medications included quinapril 5 mg and topical medications included timolol 0.5% twice daily. Prednisolone acetate 1% was administered 4 times daily for 3 months, 3 times daily for 6 months, twice daily for 6 months, and once daily until suture removal. Removal of all sutures was performed at 24 months postoperatively in the operating theatre. Dehiscence of the graft host junction for 4 clock hours with

wound leakage was noted intraoperatively, and the graft was resutured with 16 interrupted 10-0 nylon sutures.

4. A female in her early 60s underwent right PKP for corneal opacity (8.25 mm donor, 16 interrupted 10-0 nylon sutures) with histological features of epithelial basement membrane dystrophy. Past medical history included hypertension. Systemic medications included candesartan 16 mg (an ARB), once daily. Prednisolone acetate 1% was prescribed 6 times daily for 1 month, 4 times daily for 6 months, 3 times daily for 2 months, and once daily until suture removal. Removal of all sutures was performed at 12.5 months postoperatively in the operating theatre with no dehiscence or leak noted at that time. The following day, the patient developed pain, decreased vision, and bleeding with no perception of light vision. She was taken to the operating theatre and found to have a nearly 360 degree dehiscence and prolapse of choroidal tissue secondary to choroidal hemorrhage, with no visible phakic lens. The graft was resutured with 16 interrupted 10-0 nylon sutures (Figure 1). No vision was regained, and the eye became phthisical with a disorganized anterior segment.

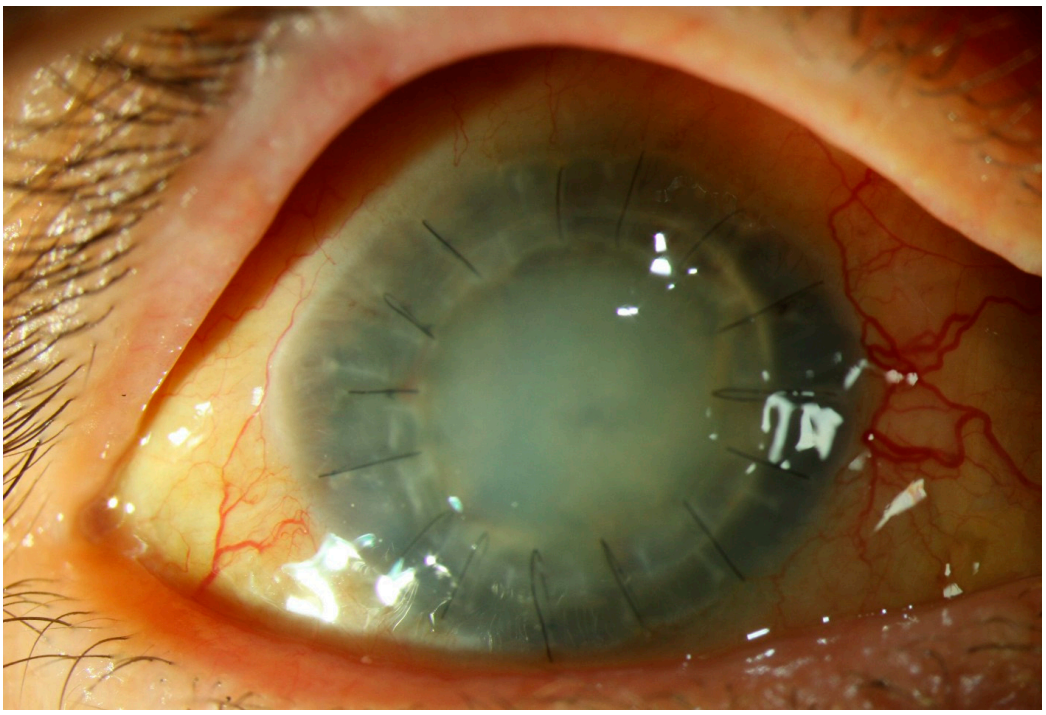

Figure 1. Postoperative appearance at 1 month postoperatively following resuturing of a dehisced graft and choroidal hemorrhage. The graft is hazy and edematous with some loose sutures and a poor view to the disorganized anterior segment.

5. A male in his mid-70s underwent PK for Fuchs dystrophy (7.75 mm donor with 16 interrupted 10-0 nylon sutures). Past ocular history included pseudophakia and vitrectomy with epiretinal membrane peel. Medical history included heart failure and gastric reflux. Systemic medications included cilazapril 5 mg (an ACEi). Prednisolone acetate 1% was administered 4 times daily for 4 months, 3 times daily for 2 months, and 2 times daily until suture removal. Removal of all sutures was planned at 19 months postoperatively in the operating theatre. Dehiscence of the graft host junction for 2 clock hours without wound leak was noted intraoperatively; 2 sutures were replaced, and the 7 remaining sutures were left in place.

3. Discussion

Wound dehiscence of the graft–host junction following keratoplasty is a potentially sight-threatening complication following suture removal [25]. There is reduced tensile strength in a wounded cornea when compared to that of a normal cornea, which persists for years following surgery [28,29]. This reduced tensile strength is a characteristic of both full-thickness corneal wounds (which occur in PK), and partial-thickness wounds (which occur in radial keratotomy or deep anterior lamellar keratoplasty) [4,16,30–36]. It has been reported that sutured full-thickness wounds may only regain up to 50–70% of their original strength [36]. Several factors may contribute to weakness of the wound, including patient factors, corneal wound characteristics, and other external factors.

A significant patient-related factor in these cases is age, as all patients were 60 years or older. It has been noted that elderly patients may be more likely to experience dehiscence following minor trauma, such as contact with the eye during self-instillation of topical medication [37,38], and that the graft–host junction may heal more slowly given that wound leaks following suture removal have been reported to occur more frequently in older patients [25]. In addition, two patients in this series had diabetes, which is a known risk factor for poor corneal wound healing [39].

Several characteristics of PK corneal wounds may contribute to weakness of the graft–host junction, such as avascularity of the tissue interface, poor apposition of wound edges, and suture-related complications such as breakage or early removal [19,38]. A unique feature of corneal wounds is their avascularity in the undiseased state. In this series, no eyes had documentation of corneal vascularization to the graft–host junction which, if present, might have strengthened the wound. There were no cases of poor antero-posterior alignment of the graft–host junction that could have reduced the tensile strength of the wound. Graft size has not been demonstrated to be a significant risk factor for dehiscence [40]. However, peripheral corneal incisions may heal more quickly than central incisions due to proximity to the corneoscleral limbus and vasculature [36]. As such, it might be expected that dehiscence could occur in smaller (more central) grafts more frequently due to slower wound healing compared to larger grafts which are subsequently located closer to the limbal vasculature. However, a larger graft has a longer circumferential scar that could, theoretically, be more vulnerable to dehiscence due to the larger size. In this series, no grafts were extremely large or small, as all grafts ranged from 7.75 mm to 8.25 mm.

Timing of suture removal could affect the risk for dehiscence [16]. It has been noted that a particularly high-risk period is that immediately following suture removal, since the eye is entirely dependent on wound healing at that stage, and spontaneous dehiscence is more common in this period [23]. In one series, a rate of wound dehiscence of 28.6% (8 of 28) occurred in patients with a continuous suture removed 3–8 months after PK [22]. In the present series, sutures were removed at 1.5 years or later following keratoplasty for four of the cases, which is typically when sutures are removed at our institution. In one case, sutures were removed at approximately 1 year postoperatively, and the timing of suture removal could have potentially been a factor in this case. In addition, the underlying condition of severe epithelial basement membrane dystrophy may have hindered wound healing in this eye. In one other eye, corneal oedema could have also contributed to poor wound healing [23,41]. In all cases, there were no instances of broken sutures that may have contributed to poor wound healing by reducing the apposition of the wound edges.

Following PK, topical corticosteroids are routinely prescribed for 1–2 years to reduce the risk of graft rejection [42]. However, corticosteroids may delay the healing of tissues through interfering with inflammation, fibroblast proliferation, and collagen synthesis [43]. At our institution, most patients are tapered down to prednisolone acetate 1% once daily by

12–16 months following surgery. However, some of the presented cases were tapered more slowly and it is possible that topical corticosteroid use could have been a factor in these cases. In addition, two eyes received topical preserved glaucoma medications that could have potentially affected wound healing due to either the glaucoma medication itself, the preservative, or a combination of the two [44].

4. Review on the Effects of Angiotensin-Inhibiting Medications on Corneal Wound Healing

The effects of common systemic medications on corneal wound healing are not well studied. However, there is accumulating in vitro and in vivo evidence that use of angiotensin-inhibiting or blocking medications, used to treat hypertension, could affect corneal wound healing by reducing corneal scarring fibrosis.

In the present series, all patients were on an oral angiotensin-inhibiting or blocking medication at the time of PK and throughout the healing process until wound dehiscence.

Angiotensin-II (Ang-II) is a 'pathological' hormone in various cardiovascular diseases [45]. Angiotensinogen is converted into angiotensin-I by renin, and angiotensin-I is converted into Ang-II by angiotensin-converting enzyme (ACE). Ang-II acts on mainly angiotensin type 1 receptors (AT1R) to cause vasoconstriction, increased vascular tone, and sodium and fluid retention. Ang-II also acts on angiotensin type 2 receptors (AT2R), but the roles of these receptors are still being defined. ACE also degrades bradykinin, a vasodilator and natriuretic. ACE inhibitors such as quinapril and cilazapril (taken by cases 1, 2, 3, and 5) are widely used to treat high blood pressure, heart diseases including heart failure, heart attacks, and stroke, and kidney disease, by decreasing angiotensin-II and blocking the degradation of bradykinin. AT1R inhibitors, also known as angiotensin receptor blockers (ARBs), such as candesartan (taken by case 4) are also on the market for similar indications.

At a cellular level, Ang-II has the effect of promoting proliferation, migration, and hypertrophy of endothelial and vascular smooth muscle cells in vitro [46,47]. ACEi and ARBs have growth-arresting effects on many normal and neoplastic cell lines [48,49]. In a mouse model of dystrophic epidermolysis bullosa (an exaggerated skin fibrosis condition), Losartan treatment for 7 weeks diminished fibrosis by inhibition of the transforming growth factor-beta (TGFβ) Smad2/3 pathway [50]. In contrast, oral Captopril did not affect wound strength, the number of new blood vessels, nor collagen scar formation in rats after incisional skin wounds or sponge implantation, which may have been due to the milder injuries or the lower dose of Captopril [51]. Topical or intralesional ACEi have demonstrated efficacy in the treatment of pathological scars in human skin [52,53]. In patients with post-thyroidectomy scars, the use of ACEi or ARBs in hypertensive patients were associated with an approximately 20% narrower scar, compared to those on other antihypertensive drugs and those that were not hypertensive [54]. Therefore, it is possible that the anti-fibrotic effects of ACEi can reduce the scarring associated with skin healing.

Similar to skin healing, corneal healing after keratoplasty involves a similar cascade of cell transdifferentiation into fibroblasts and myofibroblasts, stromal remodeling, and the laydown of new collagen fibers [55], in line with the aforementioned actions of Ang-II. However, the problem with the graft–host junction in the aforementioned cases is the slow and incomplete healing; the cornea never reaches its pre-operative strength [16].

Proteins of the renin–angiotensin system are expressed in all eye tissues—including the cornea, tear film, conjunctiva, sclera, aqueous humor, trabecular meshwork, lens, iris, ciliary body, vitreous, retina, and optic nerve head—in various species, including humans [56]. The human corneal epithelium, endothelium, and conjunctival epithelium strongly express ACE and Ang-II [57]. The stromal keratocytes express Ang-II [57]. Injury in hamster sclera-corneas increased ACE activity for 21 days, coinciding with the timeline

of fibroblast proliferation, tissue granulation, replacement of granulation by collagen, and scar formation [58]. Mouse corneas upregulated Ang-II and AT1R expression when corneal neovascularization was induced by suturing close to the limbus [59].

In recent years, there has been accumulating evidence of the anti-fibrotic effect of ACEi and ARBs in animal corneas. A literature review was conducted in PubMed using the key words (cornea) and ((ACE inhibitor) or (ARB)), matched to the respective MeSH terms, and all of the relevant literature has been included below.

The ACEi lisinopril inhibited myofibroblast formation (assessed by morphology and protein and gene expression analysis) of fibroblastic markers in cultured canine corneal fibroblasts [60]. More remarkably, the ARB Losartan was effective in reversing established fibrosis when delivered topically six times daily, simply dissolved in a balanced salt solution [61]. The fibrosis was initiated by an alkali burn in rabbit corneas and leaving it to develop for one month before treatment [61]. Effects observed included the disappearance of α-smooth muscle actin (αSMA)-positive myofibroblasts at one month after treatment, via apoptosis seen with TUNEL labelling at one week and one month [61]. Topical Losartan seemed to have additive effects to prednisolone acetate compared to Losartan alone or prednisolone alone in a similar rabbit alkaline corneal burn model, but with treatment initiated immediately after injury [62]. All three groups had decreased corneal opacity area and intensity, and αSMA, at 1 month compared to vehicle control; Losartan plus prednisolone further reduced the αSMA area and intensity compared to prednisolone alone [62].

On the other hand, Losartan did not appear to affect wound closure in rabbit corneas with deep (0.35 mm) radial incision wounds, nor did it affect the development of fibroblasts or wound opacity at 1 month; it only decreased myofibroblast generation [63]. There is no published study on the effects of other ACE inhibitors or ARBs on penetrating incisional wounds like that in penetrating keratoplasty.

Regarding whether ACEi and ARBs can reach the cornea after systemic administration, there are a few animal studies. One compared the anti-fibrotic effects of topical or oral (or both) Losartan in rabbit corneas after 8 mm diameter Descemetorhexis [64]; it suggested that topical Losartan was effective in reducing stromal scarring, αSMA area, and collagen IV deposition, whereas oral was not effective, although the duration of administration was only 4 weeks and wound strength/integrity was not studied [64]. In a rabbit model of corneal neovascularization induced by the implantation of a VEGF pellet in the stroma, intramuscular Enalapril (an ACEi) reduced the area of corneal neovascularization by 31% at 14 days [65]. Expression of Ang-II and AT1R was upregulated in mouse neovascularized corneas induced by suturing close to the limbus; intraperitoneal Telmisartan (an ARB) resulted in a 70% reduction in the area of corneal neovascularization at 7 days [59]. Most importantly, these two studies [59,65] suggest that systemically delivered ACEi and ARBs can reach the cornea, at least when it is injured.

Some evidence is now available on the effects of ACEi and ARBs on the human cornea. In a case report, corneal haze and scarring developed after a 20-year-old patient received collagen crosslinking; scarring persisted despite topical corticosteroids. Treatment with topical losartan 0.8 mg/mL 6 times a day for 3 months, starting 80 days after crosslinking, was effective in reducing corneal haze, as demonstrated by a reduction in total corneal densitometry (32.2 GSU to 27.9 GSU), and an improvement in vision from 20/150 to 20/40-1 [66].

The anti-fibrotic effects of ACEi and ARBs have also been seen in other ocular tissues. The migration and proliferation of pterygium fibroblasts cultured from patient samples were inhibited by Valsartan (an ARB), although not to the same extent as mitomycin-C [67]. Valsartan also inhibited fibrosis in the lacrimal gland of a mouse model of chronic graft-

versus-host disease [68]. Intravenous captopril in normal rabbits lowered their intraocular pressure, and in rabbits subject to topical application of the irritant neutral formaldehyde to the eye, it inhibited an increase in the intraocular pressure and breakdown of the blood–aqueous barrier [69].

Fibrosis in the eye and other organs involves the transforming growth factor-β (TGF-β) cascade, with contributions from other pro-fibrotic growth factors, such as connective tissue growth factor (CTGF, now CCN2), platelet-derived growth factor (PDGF), and mechanical interactions with the underlying matrix [70]. TGF-β1 is normally found in the tear film, corneal epithelium, corneal endothelium, and aqueous humor, whereas TGF-β2 is found in the tear film and aqueous humor [71] (Figure 2). Both are unable to enter the corneal stroma due to separation by the epithelial basement membrane and Descemet's membrane [71]. When a corneal injury results in breaks in either basement membrane, TGF-β enters the stroma, activating TGF-β receptors (1 and 2) on cell membranes [71,72]. Penetrating keratoplasty results in breaks in both membranes, and will involve the influx of TGFβ from both sides. This activates two pathways, the canonical Smad2/3 pathway and the non-canonical pathway [72].

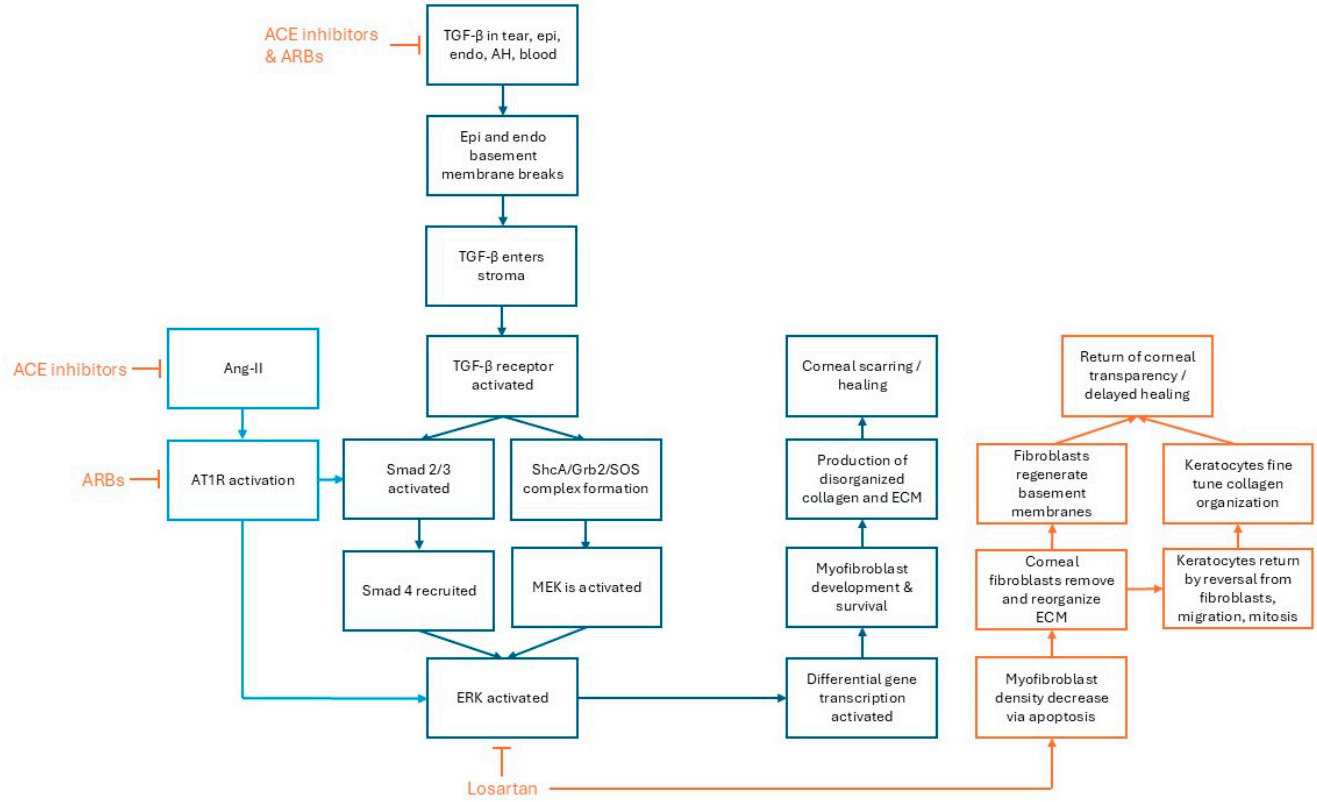

Figure 2. Mechanism of corneal scarring/healing induced by activation of the TGFβ pathways, interactions with Ang-II, and proposed effects of ACE inhibitors and ARBs resulting in delayed healing. ACE inhibitors, angiotensin converting enzyme inhibitors; AH, aqueous humor; Ang-II, angiotensin II; AT1R, angiotensin type 1 receptor; ARB, angiotensin receptor blockers ECM, extracellular matrix; Epi, epithelium; endo, endothelium; ERK, extracellular signal-regulated kinase; Grb2, growth factor receptor-bound protein 2; MEK, mitogen-activated protein kinase kinase; ShcA, Src homology and Collagen A; Smad2/3, Smad2 protein and Smad 3 protein; SOS, son of sevenless protein; TGF-β, transforming growth factor-beta.

In the canonical pathway, Smad 2 and Smad 3 proteins are activated, recruiting Smad 4 [73]. This results in the activation of ERK-1 or 2 (extracellular signal-regulated kinase). In the non-canonical pathway, TGF-β receptor activation causes the phosphorylation

of ShcA (Src homology and Collagen A), which bind to Grb2 (growth factor receptor-bound protein2) and SOS (son of sevenless protein) to form a ShcA/Grb2/SOS complex [72]. The complex activates the RAS (rat sarcoma) family of proteins into the active GTP-bound form, which activate RAF by phosphorylation, which then activates MEK (mitogen-activated protein kinase kinase) by phosphorylation [72]. This leads to ERK-1 or 2 activation, the point of convergence with the canonical pathway [72]. This is an important molecular switch with >600 direct and >1800 indirect downstream effectors in the nucleus, cytoplasm, and cell membrane, including differential gene transcription that supports the proliferation and development of myofibroblasts precursors, including local fibroblasts and fibrocytes from the blood stream [72]. Once developed, the survival of myofibroblasts is also supported by ERK-1/2 activation [72]. Myofibroblasts produce disorganized collagen and extracellular matrix, resulting in corneal scarring [72], but also essential for wound healing after keratoplasty where the host and donor stromata need to be 'stitched' together.

There are a few places in this cascade that ACEi and ARBs appear to have an effect. It is possible that they could reduce TGFβ levels at the top of the cascade. Although evidence in the eye or corneal tissue is not yet available, oral ramipril (ACEi), Candesartan (ARB), or combined, reduced urinary TGFβ in type 2 diabetic patients [74]. Oral Losartan also reduced urinary TGFβ and renal injury in a mouse model of nephropathy [75]. Therefore, it is plausible that local tissue-level TGFβ could be reduced by oral ACEi or ARB. Work in the renal system demonstrated that the activation of AT1R activates Smad2/3, and that ARBs reversed this activation [73,76], suggesting that ACEi and ARBs could block the canonical TGFβ pathway. The work of Wilson et al. provided convincing evidence that Losartan (an ARB) decreased the density of myofibroblasts via apoptosis and possibly other mechanisms, allowing the return of corneal fibroblasts which can remove and reorganize the extracellular matrix and regenerate the basement membrane [72]. Eventually keratocytes return by reversal from fibroblasts or mitosis and migration from the surrounding stroma, and start to fine-tune collagen organization, allowing the return of corneal transparency [72]. The cascade described above was in the context of corneal wound healing, with formation of disorganized collagen and extracellular matrix, followed by treatment with ACEi/ARBs, and subsequent disappearance of myofibroblasts. However, if the patients were on ACEi/ARBs before and after penetrating keratoplasty, it is possible that myofibroblast development was dampened to the extent that the collagen and extracellular matrix deposition required for wound healing was not achieved.

In addition to being a corneal wound, penetrating keratoplasty also involves the grafting of an allogenic donor cornea into a host rim; therefore, inflammation is an important consideration, as excessive inflammation will lead to graft rejection instead of healing [77]. The surgery induces MHC-II expression in the resident antigen presenting cells (corneal dendritic cells), which enter into a mature state; donor and/or host dendritic cells migrate into the peripheral host cornea to the lymph nodes, where antigen presentation to naïve T cells occurs [78]. T cells induce an immune response by induction of cytotoxic T cells and production of proinflammatory IgG antibodies in B cells [78]. This causes a delayed-type hypersensitivity response which can lead to graft rejection. Fortunately, this is held back by anterior chamber-associated immune deviation and the intraocular immunosuppressive environment [78], so that the average global 5-year survival rate of corneal grafts is 72.8%, without any systemic immunosuppressants [79]. In the former, corneal dendritic cells also travel via the trabecular meshwork to reach the spleen, where presentation of antigens to naïve T cells also occurs [78]. However, the result is that the responding T cells differentiate into Tregs (regulatory T cells) that inhibit the delayed-type hypersensitivity response [78]. The intraocular immunosuppressive environment comprises of cell surface molecules within the cornea, iris, and ciliary body, and soluble factors in the

anterior chamber; together, they inhibit corneal dendritic cell motility, reducing antigen presentation [78].

To date, Ang-II is known to be pro-inflammatory by causing Toll-like receptor (TLR), TLR4 coreceptor myeloid differentiation factor 2 (MD2), and nuclear factor κB (NF-κB) activation, followed by the secretion of pro-inflammatory mediators and adhesion molecules [80]. Inhibition of Ang-II production or receptor activation by ACEi or ARBs have anti-inflammatory effects in general [80]. After corneal wounding and transplantation, ACEi/ARBs could have contributed to less inflammation, reducing the risk of corneal rejection; however, this is unproven and an area that deserves further investigation.

Therefore, it is plausible that the anti-collagen [81], anti-angiogenic [59,65], anti-fibrotic [64], and anti-inflammatory effects of ACE inhibitors and ARBs could have contributed to delayed and incomplete corneal healing, resulting in a predisposition to wound dehiscence following the minimal trauma of removal of sutures in the operating theatre in a controlled environment. Given their clear efficacy in the cardiovascular system and skin, and the experimental efficacy in animal models of corneal injury, future studies are warranted to further investigate any effects of orally administered ACE inhibitors on corneal wound healing.

There are multiple limitations of this case series, such that no definitive conclusions can be made. Further research is required, as case reports represent a low level of scientific evidence. This case series was presented to propose a hypothesis and does not provide any significant evidence to support that hypothesis, given that it was a non-comparative, retrospective study with no control group. Future research should further evaluate any potential long-term effects of systemic angiotensin-inhibiting medications on corneal wound healing.

5. Conclusions

Based on our literature review, there may be a potential association between oral angiotensin-inhibiting medications and corneal wound dehiscence after keratoplasty. Further study is required to determine whether these medications may influence corneal wound healing when administered orally.

Author Contributions: Conceptualization, J.J.M. and J.Z.; writing—original draft preparation, J.J.M. and J.Z.; writing—review and editing, J.J.M. and J.Z. All authors have read and agreed to the published version of the manuscript.

Funding: This research received no external funding.

Institutional Review Board Statement: The study was conducted in accordance with the Declaration of Helsinki and approved by the University of Auckland Human Participants Ethics Committee (UAHPEC—013907, approval date: 12 March 2018).

Informed Consent Statement: Verbal informed consent was obtained from the participants. The rationale for utilizing verbal consent is the minimal risk for participation in the study. Written informed consent for publication of clinical details and images was obtained from one patient.

Data Availability Statement: The data presented in this study are available on request from the corresponding author due to ethical reasons.

Conflicts of Interest: The authors declare no conflicts of interest.

References

1. Gain, P.; Jullienne, R.; He, Z.; Aldossary, M.; Acquart, S.; Cognasse, F.; Thuret, G. Global Survey of Corneal Transplantation and Eye Banking. *JAMA Ophthalmol.* **2016**, *134*, 167–173. [CrossRef]
2. Chaurasia, S.; Ramappa, M. Traumatic wound dehiscence after deep anterior lamellar keratoplasty. *J. Am. Assoc. Pediatr. Ophthalmol. Strabismus* **2011**, *15*, 484–485. [CrossRef] [PubMed]

3. Jafarinasab, M.R.; Feizi, S.; Esfandiari, H.; Kheiri, B.; Feizi, M. Traumatic Wound Dehiscence following Corneal Transplantation. *J. Ophthalmic Vis. Res.* **2012**, *7*, 214–218.
4. Kawashima, M.; Kawakita, T.; Shimmura, S.; Tsubota, K.; Shimazaki, J. Characteristics of traumatic globe rupture after keratoplasty. *Ophthalmology* **2009**, *116*, 2072–2076. [CrossRef] [PubMed]
5. Lee, W.B.; Mathys, K.C. Traumatic wound dehiscence after deep anterior lamellar keratoplasty. *J. Cataract. Refract. Surg.* **2009**, *35*, 1129–1131. [CrossRef] [PubMed]
6. Sari, E.S.; Koytak, A.; Kubaloglu, A.; Culfa, S.; Erol, M.K.; Ermis, S.S.; Ozerturk, Y. Traumatic wound dehiscence after deep anterior lamellar keratoplasty. *Am. J. Ophthalmol.* **2013**, *156*, 767–772. [CrossRef]
7. Zarei-Ghanavati, S.; Zarei-Ghanavati, M.; Sheibani, S. Traumatic wound dehiscence after deep anterior lamellar keratoplasty: Protective role of intact descemet membrane after big-bubble technique. *Cornea* **2010**, *29*, 220–221. [CrossRef] [PubMed]
8. Sony, P.; Panda, A.; Pushker, N. Traumatic corneal rupture 18 years after radial keratotomy. *J. Refract. Surg.* **2004**, *20*, 283–284. [CrossRef] [PubMed]
9. Artola, A.; Ayala, M.J.; Ruiz-Moreno, J.M.; De La Hoz, F.; Alió, J.L. Rupture of radial keratotomy incisions by blunt trauma 6 years after combined photorefractive keratectomy/radial keratotomy. *J. Refract. Surg.* **2003**, *19*, 460–462. [CrossRef]
10. Hurvitz, L.M. Late clear corneal wound failure after trivial trauma. *J. Cataract. Refract. Surg.* **1999**, *25*, 283–284. [CrossRef] [PubMed]
11. Ball, J.L.; McLeod, B.K. Traumatic wound dehiscence following cataract surgery: A thing of the past? *Eye* **2001**, *15*, 42–44. [CrossRef] [PubMed]
12. Xiao, J.; Jiang, C.; Zhang, M.; Jiang, H.; Li, S.; Zhang, Y. When case report became case series: 45 cases of late traumatic flap complications after laser-assisted in situ keratomileusis and review of Chinese literature. *Br. J. Ophthalmol.* **2014**, *98*, 1282–1286. [CrossRef] [PubMed]
13. Iskander, N.G.; Peters, N.T.; Anderson Penno, E.; Gimbel, H.V. Late traumatic flap dislocation after laser in situ keratomileusis. *J. Cataract. Refract. Surg.* **2001**, *27*, 1111–1114. [CrossRef] [PubMed]
14. Melki, S.A.; Talamo, J.H.; Demetriades, A.M.; Jabbur, N.S.; Essepian, J.P.; O'Brien, T.P.; Azar, D.T. Late traumatic dislocation of laser in situ keratomileusis corneal flaps. *Ophthalmology* **2000**, *107*, 2136–2139. [CrossRef]
15. Kim, H.J.; Silverman, C.M. Traumatic dislocation of LASIK flaps 4 and 9 years after surgery. *J. Refract. Surg.* **2010**, *26*, 447–452. [CrossRef] [PubMed]
16. Elder, M.J.; Stack, R.R. Globe rupture following penetrating keratoplasty: How often, why, and what can we do to prevent it? *Cornea* **2004**, *23*, 776–780. [CrossRef]
17. Cherry, P.M. Rupture of the globe. *Arch. Ophthalmol.* **1972**, *88*, 498–507. [CrossRef]
18. Meyer, J.J.; McGhee, C.N. Incidence, severity and outcomes of traumatic wound dehiscence following penetrating and deep anterior lamellar keratoplasty. *Br. J. Ophthalmol.* **2016**, *100*, 1412–1415. [CrossRef]
19. Lam, F.C.; Rahman, M.Q.; Ramaesh, K. Traumatic wound dehiscence after penetrating keratoplasty-a cause for concern. *Eye* **2007**, *21*, 1146–1150. [CrossRef]
20. Tseng, S.H.; Lin, S.C.; Chen, F.K. Traumatic wound dehiscence after penetrating keratoplasty: Clinical features and outcome in 21 cases. *Cornea* **1999**, *18*, 553–558. [CrossRef] [PubMed]
21. Kartal, B.; Kandemir, B.; Set, T.; Kugu, S.; Keles, S.; Ceylan, E.; Akmaz, B.; Apil, A.; Ozerturk, Y. Traumatic wound dehiscence after penetrating keratoplasty. *Ulus. Travma Acil Cerrahi Derg.* **2014**, *20*, 181–188. [CrossRef]
22. Brown, S.I.; Tragakis, M.P. Wound dehiscence with keratoplasty: Complication of the continuous-suture technique. *Am. J. Ophthalmol.* **1971**, *72*, 115–116. [CrossRef]
23. Binder, P.S.; Abel, R., Jr.; Polack, F.M.; Kaufman, H.E. Keratoplasty wound separations. *Am. J. Ophthalmol.* **1975**, *80*, 109–115. [CrossRef] [PubMed]
24. Spigelman, A.V.; Doughman, D.J.; Lindstrom, R.L.; Nelson, J.D. Visual loss following suture removal postkeratoplasty. *Cornea* **1988**, *7*, 214–217. [CrossRef]
25. Crawford, A.Z.; Meyer, J.J.; Patel, D.V.; Ormonde, S.E.; McGhee, C. Complications related to sutures following penetrating and deep anterior lamellar keratoplasty. *Clin. Exp. Ophthalmol.* **2016**, *44*, 142–143. [CrossRef] [PubMed]
26. Abou-Jaoude, E.S.; Brooks, M.; Katz, D.G.; Van Meter, W.S. Spontaneous wound dehiscence after removal of single continuous penetrating keratoplasty suture. *Ophthalmology* **2002**, *109*, 1291–1296. [CrossRef]
27. Christo, C.G.; van Rooij, J.; Geerards, A.J.; Remeijer, L.; Beekhuis, W.H. Suture-related complications following keratoplasty: A 5-year retrospective study. *Cornea* **2001**, *20*, 816–819. [CrossRef]
28. Simonsen, A.H.; Andreassen, T.T.; Bendix, K. The healing strength of corneal wounds in the human eye. *Exp. Eye Res.* **1982**, *35*, 287–292. [CrossRef] [PubMed]
29. Pettinelli, D.J.; Starr, C.E.; Stark, W.J. Late traumatic corneal wound dehiscence after penetrating keratoplasty. *Arch. Ophthalmol.* **2005**, *123*, 853–856. [CrossRef]

30. Binder, P.S.; Waring, G.O., 3rd; Arrowsmith, P.N.; Wang, C. Histopathology of traumatic corneal rupture after radial keratotomy. *Arch. Ophthalmol.* **1988**, *106*, 1584–1590. [CrossRef]
31. Lang, G.K.; Green, W.R.; Maumenee, A.E. Clinicopathologic studies of keratoplasty eyes obtained post mortem. *Am. J. Ophthalmol.* **1986**, *101*, 28–40. [CrossRef]
32. Larson, B.C.; Kremer, F.B.; Eller, A.W.; Bernardino, V.B., Jr. Quantitated trauma following radial keratotomy in rabbits. *Ophthalmology* **1983**, *90*, 660–667. [CrossRef]
33. Luttrull, J.K.; Jester, J.V.; Smith, R.E. The effect of radial keratotomy on ocular integrity in an animal model. *Arch. Ophthalmol.* **1982**, *100*, 319–320. [CrossRef]
34. Swan, K.C.; Meyer, S.L.; Squires, E. Late wound separation after cataract extraction. *Ophthalmology* **1978**, *85*, 991–1003. [CrossRef] [PubMed]
35. Viola, R.S.; Kempski, M.H.; Nakada, S.; del Cerro, M.; Aquavella, J.V. A new model for evaluating corneal wound strength in the rabbit. *Investig. Ophthalmol. Vis. Sci.* **1992**, *33*, 1727–1733.
36. Gasset, A.R.; Dohlman, C.H. The tensile strength of corneal wounds. *Arch. Ophthalmol.* **1968**, *79*, 595–602. [CrossRef]
37. Agrawal, V.; Wagh, M.; Krishnamachary, M.; Rao, G.N.; Gupta, S. Traumatic wound dehiscence after penetrating keratoplasty. *Cornea* **1995**, *14*, 601–603. [CrossRef] [PubMed]
38. Nagra, P.K.; Hammersmith, K.M.; Rapuano, C.J.; Laibson, P.R.; Cohen, E.J. Wound dehiscence after penetrating keratoplasty. *Cornea* **2006**, *25*, 132–135. [CrossRef]
39. Chikama, T.; Wakuta, M.; Liu, Y.; Nishida, T. Deviated mechanism of wound healing in diabetic corneas. *Cornea* **2007**, *26*, S75–S81. [CrossRef]
40. Bowman, R.J.; Yorston, D.; Aitchison, T.C.; McIntyre, B.; Kirkness, C.M. Traumatic wound rupture after penetrating keratoplasty in Africa. *Br. J. Ophthalmol.* **1999**, *83*, 530–534. [CrossRef] [PubMed]
41. Friedman, A.H. Late traumatic wound rupture following successful partial penetrating keratoplasty. *Am. J. Ophthalmol.* **1973**, *75*, 117–120. [CrossRef] [PubMed]
42. Shimazaki, J.; Iseda, A.; Satake, Y.; Shimazaki-Den, S. Efficacy and safety of long-term corticosteroid eye drops after penetrating keratoplasty: A prospective, randomized, clinical trial. *Ophthalmology* **2012**, *119*, 668–673. [CrossRef] [PubMed]
43. Anstead, G.M. Steroids, retinoids, and wound healing. *Adv. Wound Care* **1998**, *11*, 277–285. [PubMed]
44. Pinheiro, R.; Panfil, C.; Schrage, N.; Dutescu, R.M. The Impact of Glaucoma Medications on Corneal Wound Healing. *J. Glaucoma* **2016**, *25*, 122–127. [CrossRef] [PubMed]
45. Vukelic, S.; Griendling, K.K. Angiotensin II, from vasoconstrictor to growth factor: A paradigm shift. *Circ. Res.* **2014**, *114*, 754–757. [CrossRef] [PubMed]
46. Lin, Q.Y.; Bai, J.; Liu, J.Q.; Li, H.H. Angiotensin II Stimulates the Proliferation and Migration of Lymphatic Endothelial Cells Through Angiotensin Type 1 Receptors. *Front. Physiol.* **2020**, *11*, 560170. [CrossRef]
47. St Paul, A.; Corbett, C.B.; Okune, R.; Autieri, M.V. Angiotensin II, Hypercholesterolemia, and Vascular Smooth Muscle Cells: A Perfect Trio for Vascular Pathology. *Int. J. Mol. Sci.* **2020**, *21*, 4525. [CrossRef]
48. Molteni, A.; Ward, W.F.; Ts'ao, C.H.; Taylor, J.; Small, W., Jr.; Brizio-Molteni, L.; Veno, P.A. Cytostatic properties of some angiotensin I converting enzyme inhibitors and of angiotensin II type I receptor antagonists. *Curr. Pharm. Des.* **2003**, *9*, 751–761. [CrossRef]
49. Steckelings, U.M.; Wollschläger, T.; Peters, J.; Henz, B.M.; Hermes, B.; Artuc, M. Human skin: Source of and target organ for angiotensin II. *Exp. Dermatol.* **2004**, *13*, 148–154. [CrossRef]
50. Silva, I.M.S.; Assersen, K.B.; Willadsen, N.N.; Jepsen, J.; Artuc, M.; Steckelings, U.M. The role of the renin-angiotensin system in skin physiology and pathophysiology. *Exp. Dermatol.* **2020**, *29*, 891–901. [CrossRef]
51. Qiu, J.G.; Factor, S.; Chang, T.H.; Knighton, D.; Nadel, H.; Levenson, S.M. Wound healing: Captopril, an angiogenesis inhibitor, and Staphylococcus aureus peptidoglycan. *J. Surg. Res.* **2000**, *92*, 177–185. [CrossRef] [PubMed]
52. Ardekani, G.S.; Aghaie, S.; Nemati, M.H.; Handjani, F.; Kasraee, B. Treatment of a Postburn Keloid Scar with Topical Captopril: Report of the First Case. *Plast. Reconstr. Surg.* **2009**, *123*, 112e–113e. [CrossRef]
53. Skaria, A.M. Prevention and treatment of keloids with intralesional verapamil. *Dermatology* **2004**, *209*, 71. [CrossRef] [PubMed]
54. Hu, Y.Y.; Fang, Q.Q.; Wang, X.F.; Zhao, W.Y.; Zheng, B.; Zhang, D.D.; Tan, W.Q. Angiotensin-converting enzyme inhibitor and angiotensin II type 1 receptor blocker: Potential agents to reduce post-surgical scar formation in humans. *Basic Clin. Pharmacol. Toxicol.* **2020**, *127*, 488–494. [CrossRef] [PubMed]
55. Bukowiecki, A.; Hos, D.; Cursiefen, C.; Eming, S.A. Wound-Healing Studies in Cornea and Skin: Parallels, Differences and Opportunities. *Int. J. Mol. Sci.* **2017**, *18*, 1257. [CrossRef]
56. Giese, M.J.; Speth, R.C. The ocular renin-angiotensin system: A therapeutic target for the treatment of ocular disease. *Pharmacol. Ther.* **2014**, *142*, 11–32. [CrossRef] [PubMed]

57. Savaskan, E.; Loffler, K.U.; Meier, F.; Muller-Spahn, F.; Flammer, J.; Meyer, P. Immunohistochemical localization of angiotensin-converting enzyme, angiotensin II and AT1 receptor in human ocular tissues. *Ophthalmic Res.* **2004**, *36*, 312–320. [CrossRef] [PubMed]
58. Sakaguchi, H.; Takai, S.; Sakaguchi, M.; Sugiyama, T.; Ishihara, T.; Yao, Y.; Miyazaki, M.; Ikeda, T. Chymase and angiotensin converting enzyme activities in a hamster model of glaucoma filtering surgery. *Curr. Eye Res.* **2002**, *24*, 325–331. [CrossRef] [PubMed]
59. Usui, T.; Sugisaki, K.; Iriyama, A.; Yokoo, S.; Yamagami, S.; Nagai, N.; Ishida, S.; Amano, S. Inhibition of corneal neovascularization by blocking the angiotensin II type 1 receptor. *Investig. Ophthalmol. Vis. Sci.* **2008**, *49*, 4370–4376. [CrossRef]
60. Routh, B.L.; Tripathi, R.; Giuliano, E.; Lujin, P.; Sinha, P.R.; Mohan, R.R. Anti-fibrotic effects of lisinopril (ACE inhibitor) and fasudil (ROCK inhibitor) in combination for canine corneal fibrosis in vitro. *Vet. Ophthalmol.* **2024**. *ahead of print*. [CrossRef]
61. Martinez, V.V.; Dutra, B.A.L.; Santhiago, M.R.; Wilson, S.E. Effect of Topical Losartan in the Treatment of Established Corneal Fibrosis in Rabbits. *Transl. Vis. Sci. Technol.* **2024**, *13*, 22. [CrossRef] [PubMed]
62. Sampaio, L.P.; Hilgert, G.S.L.; Shiju, T.M.; Santhiago, M.R.; Wilson, S.E. Topical Losartan and Corticosteroid Additively Inhibit Corneal Stromal Myofibroblast Generation and Scarring Fibrosis After Alkali Burn Injury. *Transl. Vis. Sci. Technol.* **2022**, *11*, 9. [CrossRef] [PubMed]
63. Martinez, V.V.; Dutra, B.A.L.; Sampaio, L.P.; Shiju, T.M.; Santhiago, M.R.; Wilson, S.E. Topical Losartan Inhibition of Myofibroblast Generation in Rabbit Corneas With Acute Incisions. *Cornea* **2024**, *43*, 883–889. [CrossRef] [PubMed]
64. Sampaio, L.P.; Hilgert, G.S.L.; Shiju, T.M.; Murillo, S.E.; Santhiago, M.R.; Wilson, S.E. Topical losartan inhibits corneal scarring fibrosis and collagen type IV deposition after Descemet's membrane-endothelial excision in rabbits. *Exp. Eye Res.* **2022**, *216*, 108940. [CrossRef]
65. Sharma, A.; Bettis, D.I.; Cowden, J.W.; Mohan, R.R. Localization of angiotensin converting enzyme in rabbit cornea and its role in controlling corneal angiogenesis in vivo. *Mol. Vis.* **2010**, *16*, 720–728.
66. Rodgers, E.G.; Al-Mohtaseb, Z.; Chen, A.J. Topical Losartan for Treating Corneal Haze After Ultraviolet-A/Riboflavin Collagen Cross-Linking. *Cornea* **2024**, *43*, 1165–1170. [CrossRef] [PubMed]
67. Küçük, E.; Aydemir, I.; Zor, K.R.; Özkan, O. Inhibitory Effect of Valsartan on Pterygium Fibroblasts. *Cornea* **2020**, *39*, 1139–1144. [CrossRef]
68. Yaguchi, S.; Ogawa, Y.; Kawakita, T.; Shimmura, S.; Tsubota, K. Tissue Renin-Angiotensin System in Lacrimal Gland Fibrosis in a Murine Model of Chronic Graft-Versus-Host Disease. *Cornea* **2015**, *34*, S142–S152. [CrossRef]
69. Krootila, K.; Oksala, O.; Von Dickhoff, K.; Palkama, A.; Uusitalo, H. Effect of captopril on ocular irritative response to topical neutral formaldehyde and YAG-laser capsulotomy in the rabbit. *J. Ocul. Pharmacol. Ther. Off. J. Assoc. Ocul. Pharmacol. Ther.* **1995**, *11*, 243–252. [CrossRef]
70. AlQudah, M.; Hale, T.M.; Czubryt, M.P. Targeting the renin-angiotensin-aldosterone system in fibrosis. *Matrix Biol. J. Int. Soc. Matrix Biol.* **2020**, *91–92*, 92–108. [CrossRef] [PubMed]
71. Wilson, S.E.; Shiju, T.M.; Sampaio, L.P.; Hilgert, G.S.L. Corneal fibroblast collagen type IV negative feedback modulation of TGF beta: A fibrosis modulating system likely active in other organs. *Matrix Biol. J. Int. Soc. Matrix Biol.* **2022**, *109*, 162–172. [CrossRef] [PubMed]
72. Wilson, S.E. Two-phase mechanism in the treatment of corneal stromal fibrosis with topical losartan. *Exp. Eye Res.* **2024**, *242*, 109884. [CrossRef]
73. Rajabi, S.; Saberi, S.; Najafipour, H.; Askaripour, M.; Rajizadeh, M.A.; Shahraki, S.; Kazeminia, S. Interaction of estradiol and renin-angiotensin system with microRNAs-21 and -29 in renal fibrosis: Focus on TGF-β/smad signaling pathway. *Mol. Biol. Rep.* **2024**, *51*, 137. [CrossRef] [PubMed]
74. Song, J.H.; Cha, S.H.; Lee, H.J.; Lee, S.W.; Park, G.H.; Lee, S.W.; Kim, M.J. Effect of low-dose dual blockade of renin-angiotensin system on urinary TGF-beta in type 2 diabetic patients with advanced kidney disease. *Nephrol. Dial. Transpl.* **2006**, *21*, 683–689. [CrossRef] [PubMed]
75. Silveira, K.D.; Barroso, L.C.; Vieira, A.T.; Cisalpino, D.; Lima, C.X.; Bader, M.; Arantes, R.M.; Dos Santos, R.A.; Simões, E.S.A.C.; Teixeira, M.M. Beneficial effects of the activation of the angiotensin-(1–7) MAS receptor in a murine model of adriamycin-induced nephropathy. *PLoS ONE* **2013**, *8*, e66082. [CrossRef] [PubMed]
76. Yang, F.; Huang, X.R.; Chung, A.C.; Hou, C.-C.; Lai, K.N.; Lan, H.Y. Essential role for Smad3 in angiotensin II-induced tubular epithelial–mesenchymal transition. *J. Pathol.* **2010**, *221*, 390–401. [CrossRef]
77. Di Zazzo, A.; Lee, S.M.; Sung, J.; Niutta, M.; Coassin, M.; Mashaghi, A.; Inomata, T. Variable Responses to Corneal Grafts: Insights from Immunology and Systems Biology. *J. Clin. Med.* **2020**, *9*, 586. [CrossRef] [PubMed]
78. Allen, N.E.; Zhang, J.; McGhee, C.N.J. COVID-19 vaccination and corneal allograft rejection- a review. *Front. Cell Infect. Microbiol.* **2023**, *13*, 1307655. [CrossRef] [PubMed]
79. Qureshi, S.; Dohlman, T.H. Penetrating Keratoplasty: Indications and Graft Survival by Geographic Region. *Semin. Ophthalmol.* **2023**, *38*, 31–43. [CrossRef]

80. Cantero-Navarro, E.; Fernandez-Fernandez, B.; Ramos, A.M.; Rayego-Mateos, S.; Rodrigues-Diez, R.R.; Sanchez-Nino, M.D.; Sanz, A.B.; Ruiz-Ortega, M.; Ortiz, A. Renin-angiotensin system and inflammation update. *Mol. Cell. Endocrinol.* **2021**, *529*, 111254. [CrossRef]
81. Sun, Y.; Ramires, F.J.A.; Zhou, G.; Ganjam, V.K.; Weber, K.T. Fibrous tissue and angiotensin II. *J. Mol. Cell. Cardiol.* **1997**, *29*, 2001–2012. [CrossRef]

Disclaimer/Publisher's Note: The statements, opinions and data contained in all publications are solely those of the individual author(s) and contributor(s) and not of MDPI and/or the editor(s). MDPI and/or the editor(s) disclaim responsibility for any injury to people or property resulting from any ideas, methods, instructions or products referred to in the content.