anatomia

MDPI

Opinion

Definition and Classification of the Palatine Torus—A Proposed System

Philipp Christians [1], Michael J. Schmeisser [2] and Sven Schumann [1,2,*]

[1] Department of Integrated Basic Medical Science - Macroscopic Anatomy, Medical University Lausitz - Carl Thiem, 03048 Cottbus, Germany; ph.christians@gmail.com
[2] Institute of Anatomy, University Medical Center of the Johannes Gutenberg University Mainz, 55131 Mainz, Germany
* Correspondence: s.schumann@mul-ct.de

Abstract

A palatine torus (torus palatinus) is a bony mass in the midline of the hard palate. Its prevalence varies widely in different populations, ranging from around 1% to over 60%. Females seem to be affected more often. Despite its benign nature, a palatine torus might cause problems with removable prosthetics, phonation, and mastication. Here, we propose a novel classification system for the systematic description of a palatine torus. Our system includes symmetry, localization, shape, and size of a palatine torus. This might help to standardize future investigations on this topic.

Keywords: maxilla; exostosis; palate; dentistry; oral cavity

1. Introduction

The hard palate (palatum durum) is the anterior portion of the palate, which forms a partition between both the nasal and the oral cavity. It consists of a bony plate, which is covered by a mucosa. The bony plate is formed by three paired bones: the palatine process of the maxilla, the horizontal plate of the palatine bone, and the incisive bone. The palatine process and horizontal plate are separated by the transverse palatine suture (sutura palatina transversa). The palatine processes of the left and right maxilla meet each other in the anterior portion of the median palatine suture (sutura palatina mediana), while the horizontal plates of the left and right palatine bone meet in the posterior portion of the median palatine suture, respectively. The border between the maxilla and the incisive bone is called the incisive suture (sutura incisiva), while the suture between the left and the right incisive bone is called the interincisive suture (sutura interincisiva) [1]. Since the incisive bone is treated as an anterior portion of the maxilla by some authors, the interincisive suture (between the anterior nasal spine and the incisive foramen) might be confused with the most anterior portion of the median palatine suture. The crossing point of the median palatine suture with the transverse palatine suture is called the staurion (Figure 1A). The mucosa is thin in the midline where it forms the palatine raphe (raphe palatini) and becomes thicker in the lateral parts. Additionally, the thickness of the mucosa increases in the ventrodorsal direction [2]. The mucosa forms an incisive papilla (papilla incisiva), which covers the incisive foramen (foramen incisivum), and lateral folds, called palatine rugae (rugae palatinae).

Check for updates

Academic Editor: Gianfranco Natale

Received: 18 February 2026
Revised: 27 March 2026
Accepted: 15 April 2026
Published: 21 April 2026

Copyright: © 2026 by the authors. Licensee MDPI, Basel, Switzerland. This article is an open access article distributed under the terms and conditions of the Creative Commons Attribution (CC BY) license.

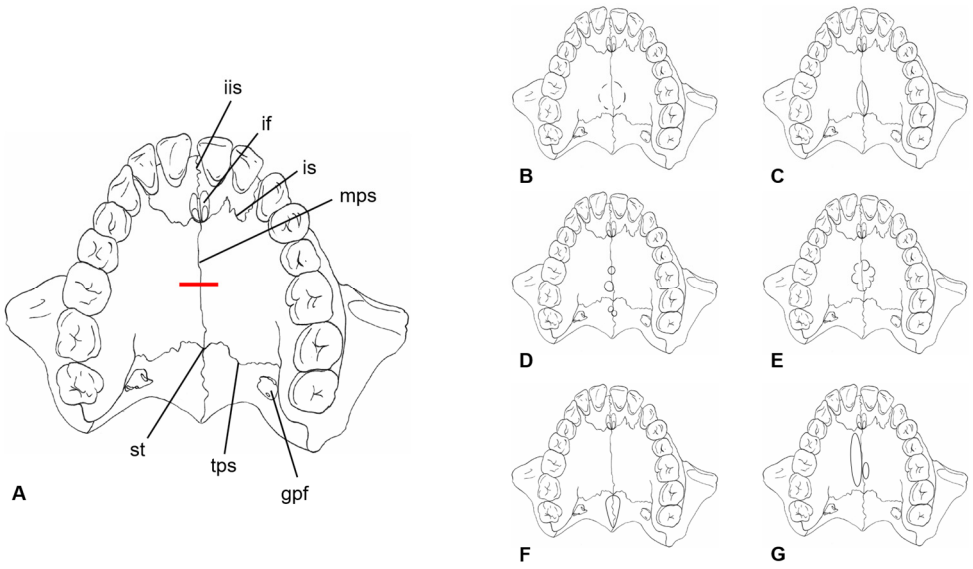

Figure 1. Schematic images of the hard palate without (**A**) and with different types of palatine torus (**B**–**G**). In (**A**), important anatomical landmarks were marked: if—incisive foramen; gpf—greater palatine foramen; is—incisive suture; iis—interincisive suture; mps—median palatine suture; tps—transverse palatine suture; st—staurion. The red line indicates the halfway point between the incisive foramen and the staurion. (**B**) Flat palatine torus of the posterior portion of the palatine process of the maxilla. (**C**) Spindle-shaped palatine torus of the posterior portion of the palatine process of the maxilla. (**D**) Nodular palatine torus of the posterior portion of the palatine process of the maxilla and the palatine bones. (**E**) Lobular palatine torus of the anterior portion and the posterior portion of the palatine process of the maxilla. (**F**) Spindle-shaped palatine torus of the palatine bones. (**G**) Asymmetrical nodular torus of the anterior portion and the posterior portion of the palatine process of the maxilla.

A palatine torus (torus palatinus) is a bony protrusion or mass in the midline of the hard palate (Figure 2). The term "torus palatinus" was introduced in a letter of the German anatomist Carl Wilhelm Kupffer in 1879 [3]. According to Carabelli (1842) [4] and Kopsch (1911) [5], the torus palatinus is more an anatomical variation than a pathological structure. It consists of both compact bone and cancellous bone and derives from the oral compact layer and the palatine substantia spongiosa, while the nasal compact layer remains unchanged [6]. The mucosa covering a palatine torus is pale and thin and could be easily traumatized. The prevalence of the palatine torus varies widely in different populations, ranging from 1.2% in Gizan boys [7] to 67.6% in Thai women [8]. In general, females seem to be affected more often. A review of reported prevalences among sexes in people from Europe, Africa, and Asia was published by El Sergani et al. [9].

The etiology and developmental dynamic of a torus palatinus remain poorly understood. There might be an interplay of genetic and environmental factors, as well as masticatory hyperfunction. A palatine torus is benign in nature. However, it might interfere with removable prosthetics, lead to problems in phonation and mastication, and may cause concern or anxiety for patients who fear malignancy.

A palatine torus must be distinguished from a constant palatine spine (spina palatina) but mainly from inconstant palatine tubercles (tubercula palatina). Palatine tubercles are located medial to the second and third molars, as well as lateral and anterior to the greater palatine foramen (foramen palatinum majus). These protuberances seem to have higher prevalences among males and African Americans [10]. In contrast to a palatine torus, palatine tubercles never reach or cross the midline of the palate.

The palatine torus is a well-known entity in anatomy, anthropology, and dentistry. However, there is no classification system, which includes common morphological as-

pects of this anatomical variation. Here, we propose a novel classification system for the palatine torus.

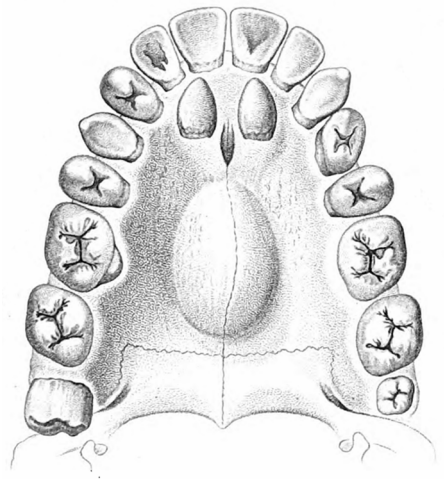

Figure 2. Copperplate print of a palatine torus from Carabelli's famous monography "Anatomie des Mundes" (Anatomy of the Mouth) [4]. According to our classification, this torus is symmetrical, flat, and localized in both the anterior portion and the posterior portion of the palatine process of the maxilla.

2. Proposed Classification System

Since the palate is covered by mucosa, accurate diagnosis and classification of a palatine torus is only possible when looking at the bone itself. This is the case when working with skulls in anatomy/anthropology, during surgery on the hard palate, or via imaging. When only performing inspection of the oral cavity in living patients, the presence and classification of a palatine torus should be indicated as a suspected diagnosis. Especially in the anterior portion of the palate, a palatine torus must not be confused with a hypertrophic incisive papilla or palatine rugae. However, when radiological imaging (e.g., cone beam computed tomography) of the palate is performed for other clinical reasons (e.g., endodontics, implantology) or prior to removing a large torus, a definitive diagnosis and classification of a palatine torus are also possible in living patients [11,12].

2.1. Localization

A palatine bony mass must reach or cross the midline of the palate to be considered a palatine torus. Importantly, a palatine torus must be distinguished from outgrowths of bone from the alveolar process (e.g., maxillary torus, buccal exostosis). Additionally, it should be mentioned whether the palatine torus is symmetrical (type 1) or asymmetrical (type 2) to the midline of the palate (Figure 1G). We recommend using the median palatine suture to determine the midline of the palate.

When the palatine torus is localized on the level of the horizontal plates, it might be classified as a palatine torus of the palatine bones. Between incisive foramen and staurion, a palatine torus might be classified as a palatine torus of the maxilla. It is probably useful to distinguish between a palatine torus of the anterior maxilla and a palatine torus of the posterior maxilla (Table 1). A palatine torus anterior to the incisive foramen might be called an incisive palatine torus. For a great torus covering multiple regions, combinations might be used: A palatine torus covering both the posterior portion of the palatine process and the horizontal plate could be called the "palatine torus of the posterior maxilla and the palatine bones". Using abbreviations, these combinations of localization could be indicated by a "/" (e.g.,pm/p-PT).

Table 1. Classification of a palatine torus by symmetry and localization.

	Description	Classification	Possible Abbreviation
Symmetry	Symmetrical to the midline of the palate.	Symmetrical palatine torus	1
	Asymmetrical to the midline of the palate.	Asymmetrical palatine torus	2
Localization	Anterior to the incisive foramen. In the region of the incisive bone.	Incisive palatine torus	i-PT
	Anterior half of the distance between the incisive foramen and the staurion. In the anterior portion of the palatine process of the maxilla.	Palatine torus of the anterior maxilla	am-PT
	Posterior half of the distance between the incisive foramen and the staurion. In the posterior portion of the palatine process of the maxilla.	Palatine torus of the posterior maxilla	pm-PT
	Posterior to the staurion, in the region of the horizontal plate of the palatine bone.	Palatine torus of the palatal bones	p-PT

According to our experience, identification of the incisive foramen and the staurion is possible in most cases when working with macerated dry skulls or computed tomography images. However, when the staurion is not visible, a line between the incisive foramen and the posterior nasal spine might be used as an approximation: The anterior third and the middle third of this line represent the maxillary portions of the hard palate, whereas the posterior third of this line equals the region of the palatine bones. This line might also be used as an approximation to determine the midline of the hard palate.

Some authors classified the location of the palate torus according to its relationship to the teeth (e.g., premolar area, molar area, premolar to molar area, incisor to premolar area, and incisor to molar area, by Apinhasmit et al. [13]). This classification system, however, might cause problems when working with edentulous skulls.

2.2. Shape

According to Thoma [14], a palatine torus might be called flat, spindle-shaped, nodular, or lobular (Figure 1B–G). For definitions, see Table 2. Examples from the literature are summarized in Table 3.

Table 2. Classification of a palatine torus by different shapes.

Description	Classification	Possible Abbreviation
Slightly convex protuberance with a smooth surface and a broad base.	Flat palatine torus	f-PT
Ridge at the palatal midline. A median groove might be present.	Spindle-shaped palatine torus	s-PT
Multiple protuberances with individual bases. Nodules may coalesce forming a single mass with grooves, but individual bases indicate multiple origins.	Nodular palatine torus	n-PT
Large bony mass with grooves on the surface but with a single base.	Lobular palatine torus	l-PT

Table 3. Representative images of different torus shapes.

Torus Shape	Reference
Flat torus	Jainkittivong et al. [15], Figure 1A
Spindle-shaped torus	Baumann et al. [16], Figure 1
Lobular torus	Ghahremani et al. [11], Figure 5; Jainkittivong et al. [15], Figure 1D
Nodular torus	Ghahremani et al. [11], Figure 7; Artanty and Artaria [17], Figure 1B; Jainkittivong et al. [18], Figure 1B

2.3. Size

A palatine torus might be classified as small, medium-sized, and large. Following Kronenberger [19], we suggest that a palatine torus must have a height of at least 2 mm and a width of at least 5 mm. Below these dimensions a palatal mass should not be classified as a fully developed palatine torus. Future studies about the developmental dynamics of the palatine torus might clarify whether all small bony protrusions in the midline of the palate represent precursors of a torus. A size-dependent classification, inspired by Woo's classification [18], is shown in Table 4. If a torus falls into different size categories, we suggest mentioning both the smallest and the largest category reached (e.g., small to medium-sized palatal torus, small to large palatal torus). Using abbreviations, these combinations of size could be indicated by *a* "/" (e.g., small/medium, small/large). An exemplary classification of two tori is shown in Figure 3.

Table 4. Size dependent classification of a palatine torus.

	Length in mm	Height in mm	Width in mm
Small	10–14.9	2–2.9	5–9.9
Medium	15–24.9	3–4.9	10–14.9
Large	≥25	≥5	≥15



Figure 3. (**A**) Skull from the anatomical collection Mainz with a palatine torus (length 12 mm, height 3 mm, width 6 mm). This torus (red circle) might be classified as a small to medium-sized symmetrical flat palatine torus of the posterior maxilla and the palatine bones (small/medium-1-f-pm/p-TP). (**B**) Skull from the anatomical collection Mainz with a palatine torus (length 10 mm, height 3 mm, width 5 mm). This torus (red circle) might be classified as a small to medium-sized symmetrical spindle-shaped palatine torus of the palatine bones (small/medium-1-s-p-TP).

Qualitative systems for size grading were developed by different authors: According to Axelsson and Hedegaard, a palatine torus could be classified as absent, palpable, visible, or large [20]. Baumann et al. distinguished between "no torus" (0), "small torus" (1),

"medium torus" (2), "large torus" (3), and "extreme torus" (4) [19]. Limitations of these classification systems are poor reproducibility and high inter- and intra-observer variability.

3. Conclusions

In this opinion paper, we advocate for the scientific community to use an accurate classification system for a palatine torus in academic discourse. Here, we present a classification system, which includes symmetry, localization, shape, and size. To our knowledge, no prior classification system used these aspects in combination. Additionally, adhering to minimum size requirements might help to determine precise prevalences in different populations. Our proposal seeks to encourage the adoption of a standardized classification system for the palatine torus in forthcoming anatomical and anthropological studies.

Author Contributions: Conceptualization, S.S.; writing—original draft preparation, S.S.; writing—review and editing, P.C., M.J.S. and S.S.; visualization, P.C. All authors have read and agreed to the published version of the manuscript.

Funding: This research received no external funding.

Institutional Review Board Statement: Since no research was performed on the human skeletal specimens, additional ethical approval was not required. The present work was conducted within the parameters of the written permission we received from the body donor during lifetime and in accordance with the local legislation and institutional requirements.

Informed Consent Statement: All body donors provided their written informed consent during lifetime.

Data Availability Statement: Data sharing is not applicable.

Acknowledgments: We sincerely thank those who donated their bodies to science so that anatomical research could be performed. Results from such research can potentially increase mankind's overall knowledge that can then improve patient care. Therefore, these donors and their families deserve our highest gratitude.

Conflicts of Interest: The authors declare no conflicts of interest.

References

1. Graef, J.J.; Staeber, M.; Schmeisser, M.J.; Schumann, S. Age-dependent development of the interincisive suture: A CT-based study on prevalence and dimensions. *Anat. Sci. Int.* 2025, *Online ahead of print*. [CrossRef]
2. Schumacher, S. Die Mundhöhle. In *Verdauungsapparat*; Hellman, T., Schumacher, S., Seifert, E., Zimmermann, K.W., Eds.; Handbuch der Mikroskopischen Anatomie des Menschen; Springer: Berlin/Heidelberg, Germany, 1927; Volume 5/1. [CrossRef]
3. Kupffer, C.W. Abgüsse von Gaumen ostpreussischer Schädel. In *Verhandlungen der Berliner Gesellschaft für Anthropologie, Ethnologie und Urgeschichte. Zeitschrift fur Ethnologie*; Wiegandt, Hempel & Parey: Berlin, Germany, 1879; Volume 11, pp. 70–72.
4. Carabelli, G. *Systematisches Handbuch der Zahnheilkunde. Vol 2. Anatomie des Mundes*; Braumüller u. Seidel: Vienna, Austria, 1842.
5. Kopsch, F. *Rauber's Lehrbuch der Anatomie des Menschen*; Georg Thieme: Leipzig, Germany, 1911; Volume 2.
6. Vidić, B. The structure of the palatum osseum and its toral overgrowths. *Acta Anat.* **1968**, *71*, 94–99. [CrossRef] [PubMed]
7. Salem, G.; Holm, S.A.; Fattah, R.; Basset, S.; Nasser, C. Developmental oral anomalies among schoolchildren in Gizan region, Saudi Arabia. *Community Dent. Oral Epidemiol.* **1987**, *15*, 150–151. [CrossRef] [PubMed]
8. Kerdpon, D.; Sirirungrojying, S. A clinical study of oral tori in southern Thailand: Prevalence and the relation to parafunctional activity. *Eur. J. Oral Sci.* **1999**, *107*, 9–13. [CrossRef] [PubMed]
9. El Sergani, A.M.; Anderton, J.; Brandebura, S.; Obniski, M.; Ginart, M.T.; Padilla, C.; Butali, A.; Adeyemo, W.L.; Long, R.E., Jr.; Moreno, L.M.; et al. Prevalence of Torus Palatinus and association with dental arch shape in a multi-ethnic cohort. *Homo* **2020**, *71*, 273–280. [CrossRef] [PubMed]
10. Sonnier, K.E.; Horning, G.M.; Cohen, M.E. Palatal tubercles, palatal tori, and mandibular tori: Prevalence and anatomical features in a U.S. population. *J. Periodontol.* **1999**, *70*, 329–336. [CrossRef] [PubMed]
11. Ghahremani, G.G.; Naimi, D.R.; Ghahremani, Z.K. Imaging Torus Lesions of Jaw Bones. *Appl. Radiol.* **2022**, *1*, 12–15. [CrossRef] [PubMed]
12. Dean, R.; Ahmed, B.; Sapa, H. Surgical removal of torus palatinus in a patient with a history of bisphosphonates. *Fac. Dent. J.* **2022**, *13*, 56–61. [CrossRef]

13. Apinhasmita, W.; Jainkittivong, A.; Swasdison, S. Torus Palatinus and Torus Mandibularis in a Thai population. *ScienceAsia* **2002**, *28*, 105–111. [CrossRef]
14. Thoma, K. *Oral Pathology: A Histological, Roentgenological, and Clinical Study of the Diseases of the Teeth, Jaws and Mouth*, 3rd ed.; CV Mosby: St. Louis, MO, USA, 1950.
15. Jainkittivong, A.; Apinhasmit, W.; Swasdison, S. Prevalence and clinical characteristics of oral tori in 1520 Chulalongkorn University Dental School patients. *Surg. Radiol. Anat.* **2007**, *29*, 125–131. [CrossRef] [PubMed]
16. Baumann, M.; Lynnerup, N.; Scott, G.R. Stable Isotopes and Oral Tori in Greenlandic Norse and Inuit. *Int. J. Osteoarchaeol.* **2017**, *27*, 312–319. [CrossRef]
17. Artanty, D.; Artaria, M.D. Prevalence of Torus Palatinus for Forensic Anthropological Identification. *J. Syiah Kuala Dent. Soc. (JDS)* **2024**, *9*, 11–15. [CrossRef]
18. Woo, J.K. Torus palatinus. *Am. J. Phys. Anthropol.* **1950**, *8*, 81–111. [CrossRef] [PubMed]
19. Kronenberger, H. Untersuchungen zum Problem des Torus palatinus [The torus palatinus]. *Anthropol. Anz.* **1981**, *39*, 150–157. (In German) [PubMed]
20. Axelsson, G.; Hedegaard, B. Torus palatinus in Icelandic schoolchildren. *Am. J. Phys. Anthropol.* **1985**, *67*, 105–112. [CrossRef] [PubMed]

Disclaimer/Publisher's Note: The statements, opinions and data contained in all publications are solely those of the individual author(s) and contributor(s) and not of MDPI and/or the editor(s). MDPI and/or the editor(s) disclaim responsibility for any injury to people or property resulting from any ideas, methods, instructions or products referred to in the content.