anatomia

MDPI

Article

A Cadaveric Study of the Hypoglossal Nerve Landmarks: What Does ChatGPT Know and Suggest?

Elio Kmeid [1,2,*], Martin Hitier [1,3], Edmond Jalkh [2] and Marion Perreard [1,*]

[1] Department of Otolaryngology-Head and Neck Surgery, CHU de Caen, Avenue de La Côte de Nacre, 14000 Caen, France; mart1_hit@yahoo.fr
[2] Faculty of Medicine and Medical Sciences, Holy Spirit University of Kaslik (USEK), Jounieh P.O. Box 446, Lebanon; edmonjalkh@hotmail.com
[3] Department of Anatomy, Normandie University, UNICAEN, 14000 Caen, France
* Correspondence: elio.kmeid@hotmail.com (E.K.); perreard-m@chu-caen.fr (M.P.)

Abstract: Background/Objectives: The hypoglossal nerve plays a crucial role in cervical surgery, requiring precise anatomical knowledge to prevent iatrogenic injury. This study examined its position relative to key structures using cadaveric dissections and assessed ChatGPT-4's reliability in providing anatomical insights. **Methods**: Ten cadavers were dissected to identify the hypoglossal nerve's course in relation to the internal jugular vein, carotid arteries, thyro-linguo-facial trunk, hyoid bone, and digastric muscle. Measurements were taken, and ChatGPT was queried for anatomical guidance and surgical recommendations. **Results**: The hypoglossal nerve was consistently medial to the internal jugular vein and lateral to the carotid arteries. The measured distances to the surrounding structures showed notable variability, particularly with the thyro-linguo-facial trunk. ChatGPT accurately described major landmarks but overlooked lesser-known anatomical triangles and provided no additional dissection guidance. It primarily suggested intraoperative monitoring and preoperative imaging. **Conclusions**: The carotid and submandibular triangles serve as reliable landmarks for identifying the hypoglossal nerve. This study highlights an unreported variability in its relationship with the thyro-linguo-facial trunk. ChatGPT, while informative, lacked detailed surgical applicability for dissection.

Keywords: hypoglossal nerve; thyro-linguo-facial trunk; carotid triangle; submandibular triangle; cervical anatomy; cadaveric dissection; nerve injury prevention

check for updates

Academic Editor: Francesco Fornai

Received: 14 February 2025
Revised: 19 March 2025
Accepted: 8 April 2025
Published: 21 April 2025

Citation: Kmeid, E.; Hitier, M.; Jalkh, E.; Perreard, M. A Cadaveric Study of the Hypoglossal Nerve Landmarks: What Does ChatGPT Know and Suggest? *Anatomia* **2025**, *4*, 6. https://doi.org/10.3390/anatomia4020006

Copyright: © 2025 by the authors. Licensee MDPI, Basel, Switzerland. This article is an open access article distributed under the terms and conditions of the Creative Commons Attribution (CC BY) license (https://creativecommons.org/licenses/by/4.0/).

1. Introduction

The hypoglossal nerve is a cranial nerve (cranial nerve XII) that has two parts: intracranial (cisternal, intracanalicular) and extracranial [1]. It exits the cranium through the hypoglossal canal in the occipital bone to innervate the intrinsic and extrinsic muscles of the tongue (except the palatoglossus). Since this canal is medial to the jugular foramen, the hypoglossal nerve is initially posteromedial to the internal carotid artery and other related vessels and nerves (IX, X, XI) [2]. The extracranial part is divided into vertical (descending), horizontal, and ascending segments [3] before it disappears deep to the suprahyoid muscles in the sublingual space [4]. There, it passes between the anterior edge of the hyoglossus muscle and the posterior edge of the mylohyoid muscle, in a space below the lingual nerve and the duct of the submandibular gland [2].

The triangles of the neck are useful landmarks for surgeons to avoid any iatrogenic injury to the contained structures. These are conceptual triangles formed by anatomical elements that help identify and delineate specific regions. On each side of the neck, there

are two main triangles: anterior and posterior. They are covered by the deep cervical fascia. Only after the removal of this fascia can the secondary triangles be observed. The anterior triangle is subdivided into the carotid (superior carotid), muscular (inferior carotid), submandibular, and the unpaired submental triangle. The posterior triangle is subdivided into the occipital and subclavian triangles [5]. Other triangles have also been described: the suboccipital triangle, the triangle of the vertebral artery, the scalene triangle, and the colliscalene triangle [6].

For the purposes of this discussion, only the carotid and the submandibular triangles will be detailed, as they are relevant for locating the hypoglossal nerve.

The carotid triangle is bordered posteriorly by the anterior border of the sternocleidomastoid muscle, anteriorly by the superior belly of the omohyoid, and superiorly by the posterior belly of the digastric muscle [5–7].

Farabeuf's triangle is located within the carotid triangle and its boundaries are the hypoglossal nerve superiorly, the internal jugular vein posteriorly, and the common facial vein inferiorly [5–7].

The submandibular triangle is bordered anteriorly by the anterior belly of the digastric muscle, posteriorly by the posterior belly of the digastric muscle, and superiorly by the inferior border of the mandible.

Lesser's, Pirogov's, and Beclard's triangles are included inside the submandibular triangle [5–7].

Lesser's triangle, also known as the lingual triangle, is bounded anteriorly and posteriorly by the anterior and posterior bellies of the digastric muscle, respectively, and superiorly by the hypoglossal nerve. Its floor is formed by the hyoglossus muscle, beneath which the lingual artery is found [5–7].

Pirogov's triangle is the posterior part of Lesser's triangle. It is bounded by the hypoglossal nerve superiorly, the posterior border of the mylohyoid muscle anteriorly, and the intermediate tendon of the digastric muscle inferoposteriorly. The lingual artery is also found deep within the hyoglossus muscle [7].

However, a cadaveric study found that Lesser's triangle and Pirogov's triangle were absent in 4 out of 30 sides because the hypoglossal nerve remained inferior to the digastric muscle [7].

Beclard's triangle is bounded superiorly by the posterior belly of the digastric muscle, inferiorly by the greater horn of the hyoid bone, and posteriorly by the posterior border of the hyoglossus muscle. The lingual artery and the hypoglossal nerve are located within this triangle [5–7].

Another helpful landmark for locating the hypoglossal nerve is the sternocleidomastoid artery, a branch of the occipital artery. The occipital artery originates from the external carotid artery and travels supero-posteriorly, crossing over the internal carotid artery. As it ascends, it extends the sternocleidomastoid branch before continuing beneath the mastoid process [8].

Hypoglossal nerve injury can occur during several surgical procedures, such as neck dissection, carotid endarterectomy [9], submandibular gland resection, and C2–C3 cervical disk procedures [4].

The course of the hypoglossal nerve has been described in the literature in several populations, but not in any French population. Our study aims to examine the relationships of the cervical portion of cranial nerve XII through cadaveric dissections in a French population, compare our findings with those in other populations, and discuss the relevance of these landmarks in cervical surgery. Additionally, with the rise of artificial intelligence (AI) and its applications in surgery [10,11], we aimed to compare the available data in the literature with those generated by ChatGPT.

2. Methods

Ten cadavers (seven males, three females), all fresh-frozen specimens rather than formalin-preserved, were obtained from the Department of Laboratory Anatomy at the University of Caen, France. Their ages ranged from 60 to 80 years (mean age: 75). All were of European descent (French). Dissections were conducted between November 2023 and July 2024 to determine the position of the cervical portion of cranial nerve XII. The same individual performed all dissections. For better visualization during dissection and analysis of the vessels, the subclavian arteries and veins were injected with red and blue latex, respectively.

The dissections began with a linear skin incision, starting at the mastoid process and extending along the posterior border of the sternocleidomastoid muscle toward the midline. The skin and subcutaneous tissues were retracted to expose the underlying structures. The external jugular vein was identified and sectioned, and the sternocleidomastoid muscle was reflected laterally to provide better access to the deeper structures. The internal jugular vein and carotid arteries were exposed, and their anatomical relationship to the hypoglossal nerve was noted. The hypoglossal nerve was identified and traced bilaterally, from its origin at the cranial base to where it disappears under the mylohyoid muscle.

The measurements presented in Figure 1 indicate the distances between the hypoglossal nerve and the hyoid bone (A), posterior belly of the digastric muscle (B), venous thyro-linguo-facial trunk (C), internal carotid artery (D) and external carotid artery (E).

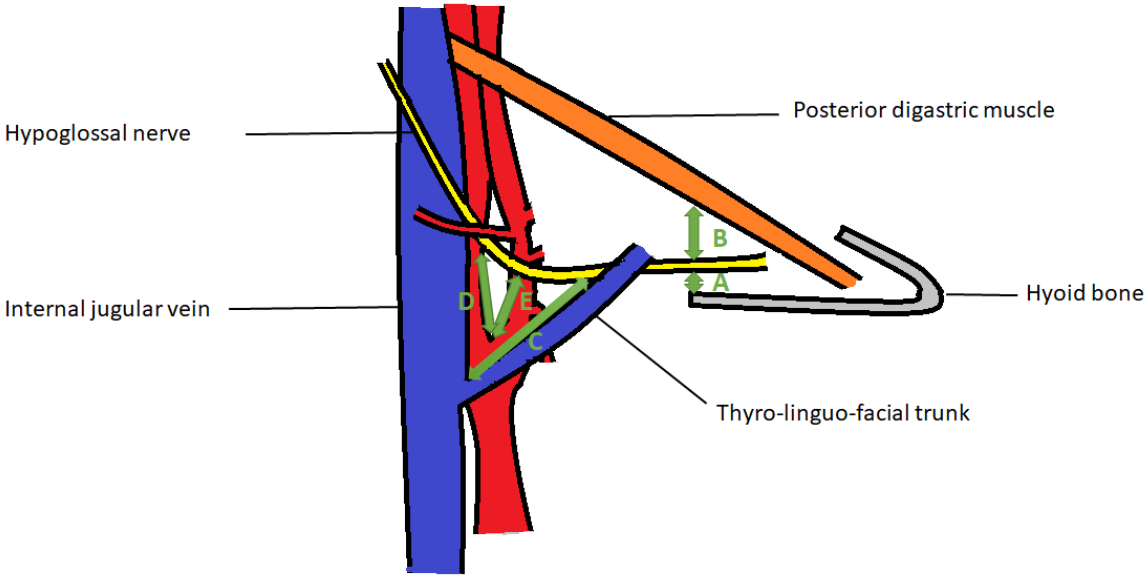

Figure 1. Schematic representation of the anatomical relationships of the hypoglossal nerve in the neck. Measurements A, B, C, D, and E indicate the distances between the hypoglossal nerve and the hyoid bone (A), posterior belly of the digastric muscle (B), venous thyro-linguo-facial trunk (C), internal carotid artery (D), and external carotid artery (E), respectively.

In parallel, ChatGPT was asked about relevant anatomical landmarks to help us locate the hypoglossal nerve to assess whether it could provide additional insights into the dissection. The question prompt was, "What are the anatomical landmarks for finding the hypoglossal nerve?" ChatGPT was then asked to analyze the obtained results to assess how artificial intelligence (AI) could guide efforts to avoid injuring the nerve.

This study utilized a descriptive statistical approach to analyze the positional relationship of the hypoglossal nerve with key anatomical landmarks. A total of 10 cadavers (n = 10) were examined, and all measurements were recorded in millimeters. Mean values, standard deviations (SD), and ranges were calculated to assess variability across specimens.

To ensure the accuracy and reliability of measurements, each distance was measured twice by the same observer at different time points, and an average value was recorded. In cases of significant discrepancy, a second independent observer re-evaluated the measurement.

Given the relatively small sample size, inferential statistical tests (e.g., *t*-tests, ANOVA) were not applied. Instead, the study focused on descriptive analyses, and a comparison was made with previously published data from other populations (e.g., Turkish, American, Kenyan cadaveric studies). Observed anatomical differences were analyzed both quantitatively and qualitatively in comparison to prior research to contextualize the findings.

3. Results

The hypoglossal nerve was identified in all cadaveric dissections. It was positioned medial to the internal jugular vein and lateral to the carotid arteries. In all dissections, the nerve was located inferior to the digastric muscle and superior to the carotid bifurcation and the hyoid bone, making it easily identifiable within Beclard's triangle. These findings are illustrated in Figures 2 and 3, which provide an overview of the nerve's trajectory, and its association with the aforementioned triangles and surrounding structures. Further observations revealed that the hypoglossal nerve crosses below the origin of the sternocleidomastoid branch of the occipital artery, as highlighted in Figure 4.



Figure 2. Cervical trajectory of the hypoglossal nerve (right side). Thyro-lingo-facial trunk (1); internal jugual vein (2); hypoglossal nerve (3); hyoid bone (4); posterior digastric muscle (5); lingual artery (6); anterior digastric muscle (7); mylohyoid muscle (8); external carotid artery (9); common carotid artery (10); superior thyroid artery and vein (11).

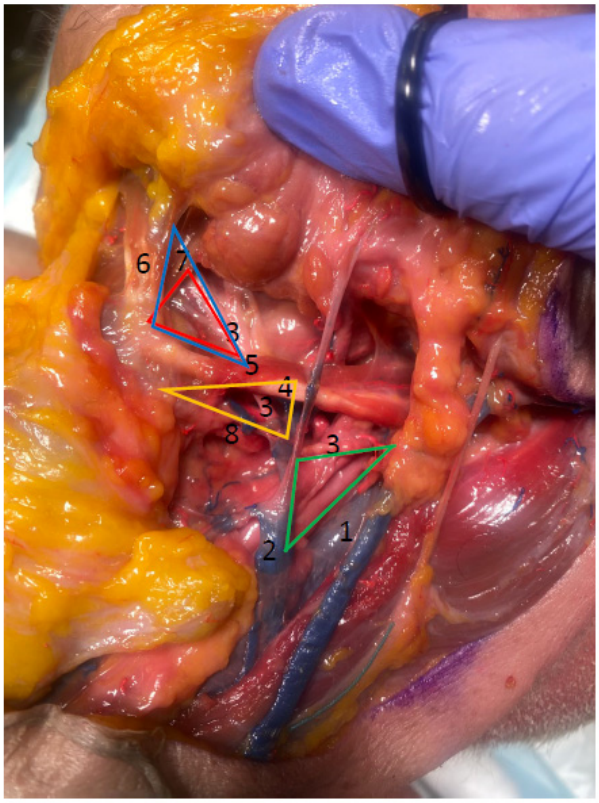

Figure 3. Cervical trajectory of the hypoglossal nerve (left side) with the different triangles. Internal jugular vein (1); thyro-lingo-facial vein (2); hypoglossal nerve (3); posterior digastric muscle (4); stylohyoid muscle (5); anterior digastric muscle (6); mylohyoid muscle (7); hyoid bone (8); green triangle: Farabeuf triangle; orange triangle: Beclard's triangle; red triangle: Pirogov's triangle; blue triangle: Little's triangle.

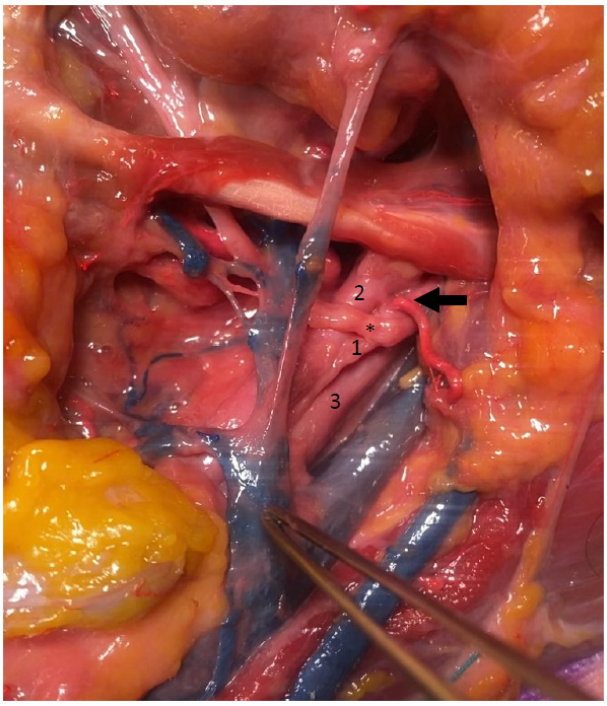

Figure 4. Farabeuf triangle (left side). You can see the hypoglossal nerve (*) passing under the origin of the sternocleidomastoid artery (arrow), a branch of the occipital artery (1). External carotid artery (2); internal carotid artery (3).

Upon the inquiry regarding the anatomical landmarks for locating the hypoglossal nerve in the neck, ChatGPT provided the following guidance: optimal visualization requires neck extension and identification of the carotid triangle, where the nerve is typically found. The hypoglossal nerve traverses the external carotid artery near the level of the greater horn of the hyoid bone. It is positioned slightly superior to the hyoid bone, coursing deep to the digastric and stylohyoid muscles before becoming superficial to the hyoglossus. Additionally, the nerve can be identified in proximity to the occipital artery, crossing it laterally.

ChatGPT suggested that, in cases of uncertainty, locating the digastric muscle and the hyoid bone may aid in identifying the nerve. While the initial response did not include references to lesser-known anatomical subdivisions such as Lesser's and Beclard's triangles, ChatGPT recognized their relevance when prompted specifically, acknowledging that these structures are "less commonly discussed". On the other hand, these triangles were mentioned and explained in detail in several articles during our literature review [5–7].

4. Measurements

In this study, we measured the position of the hypoglossal nerve in relation to several anatomical landmarks, including the venous thyro-linguo-facial trunk as it emerges from the internal jugular vein, the carotid arteries (internal and external), the greater horn of the hyoid bone, and the digastric muscle (Table 1).

Table 1. Position of the hypoglossal nerve in relation to regional anatomical landmarks.

Anatomical Landmark	Mean +/− Standard Deviation (cm)
Venous thyro-linguo-facial trunk	1.78 ± 0.78
External carotid artery	1.18 ± 0.33
Internal carotid artery	1.93 ± 0.45
Greater horn of hyoid bone	1.03 ± 0.19
Digastric muscle	0.70 ± 0.30

The mean distance between the hypoglossal nerve and the thyro-linguo-facial trunk within the Farabeuf triangle was 1.78 cm (±0.78 cm). The distance from the carotid bifurcation to the hypoglossal nerve was, on average, 1.18 cm (±0.33 cm) along the external carotid artery and 1.93 cm (±0.45 cm) along the internal carotid artery. The nerve was consistently located 1.03 ± 0.19 cm above the greater horn of the hyoid bone and 0.70 ± 0.30 cm inferior to the digastric muscle.

When ChatGPT was asked to analyze these findings, it concluded the following: "These measurements provide critical quantitative and qualitative data that can aid in understanding the localization of the hypoglossal nerve in relation to adjacent structures. These landmarks and their associated metrics provide a valuable framework for safe surgical practice in the cervical region while minimizing complications involving the hypoglossal nerve". It also suggested the following: "Surgeons should use these measurements to anticipate and avoid injury to the nerve, particularly when ligating branches of the venous thyro-linguo-facial trunk. Detailed preoperative imaging (such as CT angiography) should be used to map out this relationship, as variations in arterial anatomy could influence the position of the nerve. Incorporating intraoperative nerve monitoring (IONM) can complement these anatomical landmarks for better precision". When further questioned whether these suggestions were based on interpreting the current study's data or referencing the broader literature, ChatGPT clarified that the recommendations were derived from the broader literature.

5. Discussion

As demonstrated in the figures, the hypoglossal nerve is easily located within the identified triangles. Our study confirms that in this population, these triangles are a reliable reference for locating the nerve.

The mean distance between the hypoglossal nerve and the internal carotid artery was 1.93 ± 0.45 cm, while the distance from the external carotid artery was 1.18 ± 0.33 cm. In contrast, previous studies reported different measurements for the location of the carotid bifurcation. Studies on Korean populations reported that the distance between the internal carotid artery (ICA) bifurcation and the hypoglossal nerve was 2.09 ± 0.77 cm, and the distance to the external carotid artery (ECA) bifurcation was 1.53 ± 0.78 cm [12]. In the Kenyan population, the distance to the ICA bifurcation was found to be 2.99 ± 0.59 cm, and to the ECA bifurcation was 1.51 ± 0.66 cm [3].

Regarding the greater horn of the hyoid bone, the present study recorded the hypoglossal nerve as being 1.03 ± 0.19 cm above this structure. In contrast, the nerve was 1.22 ± 0.37 cm above the greater horn of the hyoid in the Kenyan population [3].

The hypoglossal nerve was consistently found below the digastric muscle, consistent with findings from a Turkish study [1]. However, an American study found the nerve superior to the digastric muscle in 58% of 91 cadaveric dissections [13]. In a more recent Kenyan study, the nerve was at the same level as the digastric tendon in 27% of 41 cases with the remainder positioned inferior to the tendon [3]. Salame et Al. found that the hypoglossal nerve was superior to the digastric tendon in 46% of cases, while it was at the same level in 54% of cases [14]. These variations highlight how the position of the hypoglossal nerve differs across populations (Table 2). Notably, we were unable to find any French studies that describe the course of the hypoglossal nerve.

Table 2. Hypoglossal nerve landmarks across different populations. CN: cranial nerve; ICA: internal carotid artery; ECA: external carotid artery.

Anatomical Landmark	Current Study (Mean ± SD)	Korean Population (Mean ± SD)	Kenyan Population (Mean ± SD)	American Study	Turkish Study
Distance between CN XII and ICA	1.93 ± 0.45 cm	2.09 ± 0.77 cm	2.99 ± 0.59 cm	-	-
Distance between CN XII and ECA	1.18 ± 0.33 cm	1.53 ± 0.78 cm	1.51 ± 0.66 cm	-	-
Distance between CN XII and Greater Horn of the Hyoid Bone	1.03 ± 0.19 cm	-	1.22 ± 0.37 cm	-	-
Position relative to Digastric Muscle	Below the digastric muscle	-	27% same level 73% below the digastric muscle	58% superior to digastric muscle 42% below the muscle	Below the digastric muscle
Distance between CN XII and Thyro-linguo-facial Trunk	1.78 ± 0.78 cm				

However, given our small sample size, future studies with larger sample sizes and formal statistical comparisons are recommended to validate these findings and assess potential population-based variations in the course of the hypoglossal nerve.

On the other hand, we found no studies that calculated the distance between the venous thyro-linguo-facial trunk and the hypoglossal nerve. This finding in our study is interesting, as it highlights more variations compared to the other anatomical landmarks. This implies that we may sometimes need to dissect further from the trunk to locate the hypoglossal nerve.

Limitations in the precision of measurements include the following: slight rotational movements of the head may influence the distances between structures by altering the tension on surrounding tissues. Another factor that can impact these measurements is the degree of dissection; as the nerve is further dissected, it may become more relaxed and assume a more caudal position.

On the other hand, this study is the first to measure the distance between the venous thyro-linguo-facial trunk and the hypoglossal nerve. This finding is interesting, as it highlights greater variations compared to other anatomical landmarks. This suggests that, in some cases, further dissection beyond the trunk may be required to locate the hypoglossal nerve. In other words, this relates to the size of the Farabeuf triangle. While we frequently discuss its role in helping locate the hypoglossal nerve, we rarely address how far we may need to dissect beyond the trunk before reaching the nerve.

The relevance of Beclard, Pirogoff, and Lesser triangles cannot be overstated. They offer reliable landmarks for identifying the hypoglossal nerve in, for example, lingual artery ligation, deep cervical lymphadenectomy, or submandibular gland resection.

Reviewing these triangles and integrating them into routine anatomical teaching and surgical planning could enhance procedural safety.

ChatGPT began its analysis by stating that the studied landmarks are helpful for localizing the hypoglossal nerve and that they should be carefully dissected to avoid injury to the nerve. This analysis was logical and consistent with our findings. However, ChatGPT emphasized the importance of incorporating intraoperative nerve monitoring and preoperative imaging. These methods are time-consuming, costly, and not typically practiced in our daily routine. ChatGPT mentioned that its analysis was based on a review of the literature, rather than on our study results. However, when reviewing the literature, only a few authors have reported their use in complex surgical situations [15–17].

In the end, ChatGPT is just a small part of the AI world. AI consists of learning machines that operate based on algorithms. Radiologists and pathologists are already using AI to minimize their error rates. Surgeons could also benefit from the potential of these algorithm-driven machines [18]. AI was found to be helpful in identifying anatomical landmarks during laparoscopic surgery and detecting parathyroid glands during thyroidectomy [19]. It has already demonstrated its effectiveness in colorectal surgery, neurosurgery, orthopedic surgery, cardiology, and gynecology [20]. Other studies have also demonstrated its ability to outperform specialists in general surgery, thoracic surgery, vascular surgery, and urology [21]. This does not preclude the fact that AI has its own limitations. AI output is limited by the accuracy of both our scientific questions and the available data. This suggests that AI tools, like ChatGPT, can be misused or manipulated using inappropriate prompts. Furthermore, when patient data are uploaded into AI systems (e.g., for medical diagnostic purposes or facial esthetics in plastic surgery), ethical concerns arise [18,21,22].

6. Conclusions

The hypoglossal nerve can be easily identified using the well-known, though often overlooked, triangles of the neck. Subtle variations can exist between individuals, particularly when relying on the thyro-linguo-facial trunk, as this joins the internal jugular vein to predict the position of the hypoglossal nerve. When compared to other populations, our findings show both similarities and notable differences, such as the position of the

hypoglossal nerve relative to the digastric muscle. Furthermore, while ChatGPT can offer some guidance, it may overlook certain landmarks that are well-documented in the medical literature (such as the triangles mentioned in the study) and may suggest unnecessary tests on a routine basis. As such, its use must remain cautious, and our knowledge should be based on reliable sources.

Author Contributions: Conceptualization: E.K. and M.H.; Methodology: E.K. and M.P.; Formal Analysis: E.K. and E.J.; Investigation: E.K. and M.H.; Resources: M.H.; Data Curation: E.K.; Writing—Original Draft Preparation: E.K.; Writing—Review and Editing: E.K., M.H., M.P. and E.J.; Visualization: E.K.; Supervision: M.H. and M.P.; Project Administration: M.H. and M.P.; Funding Acquisition: Not applicable. All authors have read and agreed to the published version of the manuscript.

Funding: This research received no specific grant from any funding agency in the public, commercial, or not-for-profit sectors.

Institutional Review Board Statement: This study received ethical approval from the 'comité d'éthique du centre des don du corps' on 1 November 2023.

Informed Consent Statement: Given by the donor during their lifetime, consenting to donate for the purpose of teaching and research. This was performed in accordance with French law and regulatory procedures, which are increasingly reiterated by the ethics committee.

Data Availability Statement: Data available upon request.

Acknowledgments: The authors sincerely thank those who donated their bodies to science so that anatomical research could be performed. The results from such research can potentially increase mankind's overall knowledge and hence improve patient care. Therefore, these donors and their families deserve our highest gratitude. I would also like to extend my gratitude to the Laboratory of Anatomy at the University of Caen Normandy for their assistance and support throughout this project. Their expertise and resources have been instrumental in ensuring its success. On the other hand, I have certainly gained valuable experience and knowledge in dissection. Dissecting is fundamentally different from reading; it is essential for understanding anatomy and mastering the surgical steps before operating. During the preparation of this manuscript, the authors used ChatGPT (OpenAI, GPT-4, accessed 2024) for the purposes of analyzing study findings, generating anatomical descriptions, and summarizing comparisons across literature.

Conflicts of Interest: The authors have no relevant financial or non-financial interests to disclose.

References

1. Bademci, G.; Yaşargil, M.G. Microsurgical Anatomy of the Hypoglossal Nerve. *J. Clin. Neurosci.* **2006**, *13*, 841–847. [CrossRef] [PubMed]
2. Rea, P. Chapter 1—Introduction to the Nervous System. In *Essential Clinical Anatomy of the Nervous System*; Rea, P., Ed.; Academic Press: San Diego, CA, USA, 2015; pp. 1–50, ISBN 978-0-12-802030-2.
3. Kariuki, B.N.; Butt, F.; Mandela, P.; Odula, P. Surgical Anatomy of the Cervical Part of the Hypoglossal Nerve. *Craniomaxillofac. Trauma Reconstr.* **2018**, *11*, 21–27. [CrossRef] [PubMed]
4. Hypoglossal Nerve Injury—An Overview | ScienceDirect Topics. Available online: https://www.sciencedirect.com/topics/medicine-and-dentistry/hypoglossal-nerve-injury (accessed on 24 August 2024).
5. Singh, M.; Vashistha, A.; Chaudhary, M.; Kaur, G. Forgotten Triangles of Neck. *Ann. Maxillofac. Surg.* **2016**, *6*, 91–93. [CrossRef] [PubMed]
6. Kikuta, S.; Iwanaga, J.; Kusukawa, J.; Tubbs, R.S. Triangles of the Neck: A Review with Clinical/Surgical Applications. *Anat. Cell Biol.* **2019**, *52*, 120–127. [CrossRef] [PubMed]
7. Tubbs, R.S.; Rasmussen, M.; Loukas, M.; Shoja, M.; Cohen-Gadol, A. Three Nearly Forgotten Anatomical Triangles of the Neck: Triangles of Beclard, Lesser and Pirogoff and Their Potential Applications in Surgical Dissection of the Neck. *Surg. Radiol. Anatomy SRA* **2011**, *33*, 53–57. [CrossRef] [PubMed]
8. Varun Kashyap, A.M.G. *Anatomy, Head and Neck, Occipital Bone, Artery, Vein, and Nerve*; StatPearls: Tampa, FL, USA, 2023.

9. Yigit, E.; Dursun, E.; Omeroglu, E.; Sunter, A.V.; Edizer, D.T.; Terzi, S.; Coskun, Z.O.; Demirci, M. The Course of Lower Cranial Nerves within the Neck: A Cadaveric Dissection Study. *Eur. Arch. Otorhinolaryngol.* **2018**, *275*, 2541–2548. [CrossRef] [PubMed]
10. Bektaş, M.; Pereira, J.K.; Daams, F.; van der Peet, D.L. ChatGPT in Surgery: A Revolutionary Innovation? *Surg. Today* **2024**, *54*, 964–971. [CrossRef] [PubMed]
11. Au, K.; Yang, W. Auxiliary Use of ChatGPT in Surgical Diagnosis and Treatment. *Int. J. Surg.* **2023**, *109*, 3940–3943. [CrossRef] [PubMed]
12. Kim, T.; Chung, S.; Lanzino, G. Carotid Artery-Hypoglossal Nerve Relationships in the Neck: An Anatomical Work. *Neurol. Res.* **2009**, *31*, 895–899. [CrossRef] [PubMed]
13. Homze, E.J.; Harn, S.D.; Bavitz, B.J. Extraoral Ligation of the Lingual Artery: An Anatomic Study. *Oral Surg. Oral Med. Oral Pathol. Oral Radiol. Endod.* **1997**, *83*, 321–324. [CrossRef] [PubMed]
14. Salame, K.; Masharawi, Y.; Rochkind, S.; Arensburg, B. Surgical Anatomy of the Cervical Segment of the Hypoglossal Nerve. *Clin. Anat.* **2006**, *19*, 37–43. [CrossRef] [PubMed]
15. Kojima, A.; Saga, I.; Fukumura, M. Intraoperative Neuromonitoring of Hypoglossal Nerves Using Transcranial and Direct Electrical Stimulation During Extracranial Internal Carotid Artery Surgery. *World Neurosurg.* **2023**, *172*, e701–e707. [CrossRef] [PubMed]
16. Duque, C.S.; Londoño, A.F.; Penagos, A.M.; Urquijo, D.P.; Dueñas, J.P. Hypoglossal Nerve Monitoring, a Potential Application of Intraoperative Nerve Monitoring in Head and Neck Surgery. *World J. Surg. Oncol.* **2013**, *11*, 225. [CrossRef] [PubMed]
17. Kojima, A.; Saga, I.; Ishikawa, M. Intraoperative Hypoglossal Nerve Mapping During Carotid Endarterectomy: Technical Note. *World Neurosurg.* **2018**, *113*, 249–253. [CrossRef] [PubMed]
18. Hashimoto, D.A.; Rosman, G.; Rus, D.; Meireles, O.R. Artificial Intelligence in Surgery: Promises and Perils. *Ann. Surg.* **2018**, *268*, 70–76. [CrossRef] [PubMed]
19. Hamilton, A. The Future of Artificial Intelligence in Surgery. *Cureus* **2024**, *16*, e63699. [CrossRef] [PubMed]
20. Mithany, R.H.; Aslam, S.; Abdallah, S.; Abdelmaseeh, M.; Gerges, F.; Mohamed, M.S.; Manasseh, M.; Wanees, A.; Shahid, M.H.; Khalil, M.S.; et al. Advancements and Challenges in the Application of Artificial Intelligence in Surgical Arena: A Literature Review. *Cureus* **2023**, *15*, e47924. [CrossRef] [PubMed]
21. Amin, A.; Cardoso, S.A.; Suyambu, J.; Abdus Saboor, H.; Cardoso, R.P.; Husnain, A.; Isaac, N.V.; Backing, H.; Mehmood, D.; Mehmood, M.; et al. Future of Artificial Intelligence in Surgery: A Narrative Review. *Cureus* **2024**, *16*, e51631. [CrossRef] [PubMed]
22. Dhawan, R.; Brooks, K.D. Limitations of Artificial Intelligence in Plastic Surgery. *Aesthet. Surg. J.* **2023**, *44*, NP323–NP324. [CrossRef] [PubMed]

Disclaimer/Publisher's Note: The statements, opinions and data contained in all publications are solely those of the individual author(s) and contributor(s) and not of MDPI and/or the editor(s). MDPI and/or the editor(s) disclaim responsibility for any injury to people or property resulting from any ideas, methods, instructions or products referred to in the content.