anatomia

MDPI

Case Report

Transnasal Brain Sampling for Human Rabies Diagnosis

Moses Barima Djimatey [1,*], Abdul-Rahim Abubakar [1], Augustina Angelina Sylverken [2,3], Theophilus Odoom [4], Braimah Baba Abubakari [1], John Akwasi Ohemeng [5], Gowri Yale [6], Frederic Lohr [7], Luke Gamble [7] and Anita Mahadevan [8]

1 Regional Health Directorate, Ghana Health Service, North East Region, Gambaga P.O. Box 2, Ghana
2 Kumasi Centre for Collaborative Research in Tropical Medicine, Kwame Nkrumah University of Science and Technology, KCCR, UPO, PMB, KNUST, Kumasi 00233, Ghana
3 Department of Theoretical and Applied Biology, Kwame Nkrumah University of Science and Technology, KNUST, Kumasi P.O. Box Up 1279, Ghana
4 Accra Veterinary Laboratory, Ministry of Food and Agriculture, Accra P.O. Box M161, Ghana
5 Veterinary Service Division, North East Region, Nalerigu P.O. Box 29, Ghana
6 Mission Rabies India, Flat # B-C2, Veterinary Hospital Complex, Tonca, Panaji 403002, Goa, India; drgowrieyale@gmail.com
7 Mission Rabies, Cranborne, Dorset BH21 5PZ, UK
8 Department of Neuropathology, National Institute of Mental Health, and Neurosciences (NIMHANS), Bangalore 560029, India
* Correspondence: bm.djimatey@gmail.com; Tel.: +233-20-701-4512

Abstract: Introduction: Rabies remains a significant global threat, yet accurate estimations of its impact are hindered by the lack of confirmatory diagnoses. Postmortem diagnosis of rabies traditionally involves invasive brain tissue testing, a process met with resistance from deceased patients' families, impeding consent. This paper presents and evaluates an innovative yet unpublished transnasal approach for postmortem brain tissue collection, offering a minimally invasive, easier, faster, and safer method. This method preserves the cadaver's integrity, potentially easing family reluctance towards autopsies. The limited testing of both human and animal rabies in Ghana highlights the challenges in diagnosing this fatal disease. Scarce diagnostic resources and the complexity of obtaining brain tissue samples exacerbate the issue. Cultural and religious beliefs surrounding autopsies contribute to familial hesitation, as families view these procedures as disruptive and disfiguring, further complicating consent. **Methodology:** The transnasal technique involves approaching the brain tissue through the nostrils and cribriform plate without any superficial manipulation of the patient's head and face, thereby preserving the aesthetics and natural features of the person. **Results:** Technological advancements and seamless One Health collaboration among governmental, non-governmental, and research entities locally and globally have culminated in Ghana's first confirmed rabies diagnosis using this method of brain tissue collection. This success emphasizes the efficiency and feasibility of the transnasal brain collection approach and the invaluable role of the One Health approach and collaborative efforts in overcoming diagnostic challenges in rabies control.

Keywords: rabies; brain tissue; diagnosis; autopsy; transnasal; one health

check for updates

Citation: Djimatey, M.B.; Abubakar, A.-R.; Sylverken, A.A.; Odoom, T.; Abubakari, B.B.; Ohemeng, J.A.; Yale, G.; Lohr, F.; Gamble, L.; Mahadevan, A. Transnasal Brain Sampling for Human Rabies Diagnosis. *Anatomia* **2024**, *3*, 221–226. https://doi.org/10.3390/anatomia3040018

Academic Editor: Francesco Fornai

Received: 4 June 2024
Revised: 13 September 2024
Accepted: 18 September 2024
Published: 25 September 2024

Copyright: © 2024 by the authors. Licensee MDPI, Basel, Switzerland. This article is an open access article distributed under the terms and conditions of the Creative Commons Attribution (CC BY) license (https://creativecommons.org/licenses/by/4.0/).

1. Introduction

Rabies, an infectious disease mainly caused by the rabies virus, presents a significant global health concern, leading to an estimated 59,000 preventable human deaths annually [1]. This disease predominantly affects rural populations in Eastern Asian and African countries, including the most vulnerable demographic comprising children under 15 years of age [2,3]. Human rabies manifests with certainty of fatality upon the development of clinical signs and symptoms. However, it is crucial to underscore that rabies remains preventable through the timely administration of post-exposure prophylaxis (PEP). The overwhelming majority, approximately 99%, of human fatalities due to rabies stem

from bites inflicted by rabid dogs [4]. The World Health Organization (WHO) Expert Technical Report Series No.1012 emphasizes the need for available and quality data for priority setting for rabies prevention and control at the regional, national, and sub-national levels [5].

The Challenge of Human Rabies Confirmation

The WHO, World Organization for Animal Health (WOAH), and Food and Agriculture Organization of the United Nations (FAO) have established a milestone aiming to eliminate dog-mediated human rabies by 2030 by employing the One Health approach—a synergistic collaboration between animal, human, and environmental health systems and aligning with the Sustainable Development Goals described by the United Nations [6]. Achieving this target necessitates precise data for informed decision-making, efficient post-exposure prophylaxis, and rigorous monitoring mechanisms to comprehensively evaluate the progression of initiatives such as the paramount mass vaccination of canines [5].

In the control of infectious diseases, a precise diagnosis is fundamental to accurately gauge the disease's impact and track intervention effectiveness. A significant challenge hindering progress in global and regional rabies control activities is the scarcity of confirmed data regarding rabies-related fatalities, leading to a cycle of neglect of the disease. On the African continent, a region attributed to more than a third of all global human rabies deaths, countries are confronted with challenges when it comes to the accurate confirmation of human and animal rabies cases [7]. In Ghana, the health service reported only a limited number of laboratory-confirmed rabies cases [8,9]. Otolorin et. al. (2015) discovered in Nigeria that among 78 reported cases of rabies-related deaths, none were confirmed through laboratory testing [10]. Similarly, a retrospective study in Malawi observed that 11.5% (3 out of 26) cases initially diagnosed as cerebral malaria were, in fact, instances of human rabies [11]. The Northeast Region, established in 2019 as one of Ghana's six newly created regions, has 2.2% (658,946) of the country's population, comprising 322,149 males and 336,797 females, among which 296,448 are children under 15 years of age [12,13]. The region has two municipalities, four districts, and a total of 128 health facilities under diverse ownership, including government, mission, and private agencies.

Since October 2022, the region has been actively employing the One Health approach in managing incidents of dog bites through a close collaboration between the regional Ghana Health Service and the Directorate of Veterinary Services. This work is part of their interventions towards rabies control in the region. Samples from suspected human rabies cases undergo analysis at both the Accra Veterinary Laboratory and the Kumasi Centre for Collaborative Research (KCCR), a research centre affiliated with the Kwame Nkrumah University of Science and Technology.

2. Materials and Methods

2.1. Case Report

The scarcity of pathologists capable of performing the required autopsy, compounded by geographical barriers and funding limitations, posed significant challenges. The lead author of this report, on learning the news of a possible rabies death, attempted to invite the only willing pathologist at the time with expertise in brain tissue collection, who was approximately 900 kms away and would require 17 h by road. Stymied, the corresponding author contacted two authors who put him in touch with a team member at the Department of Neuropathology, National Institute of Mental Health and Neurosciences, Bengaluru, India, who guided him towards an alternate method of brain collection, the transnasal approach.

The patient, a female aged 63 years, reported to the outpatient department (OPD) of Binde hospital, a community health facility in the district, on 4 April 2023 with complaints of earache for one week. There was a history of dog bite on 25 March 2023, approximately 10 days prior to reporting. The dog had died four days after the bite, so the patient approached Binde hospital for care. The patient did not receive Post Exposure Prophylaxis

(PEP) with the assumption that she needed to go with her health insurance, which had expired, even though the vaccine was available free of charge. On 9 June 2023, 11 weeks following the bite, the patient reported to Faith Community Hospital, a private health facility in the same district, with complaints of vomiting, excessive sweating, inability to drink water, and hydrophobia. A provisional diagnosis of rabies was made based on the history and clinical signs. The patient was referred to the Baptist Medical Centre, a larger primary hospital at the regional capital, for isolation and palliative care until death.

2.2. Autopsy

The corresponding author, along with three assistants involved in the sample taking, was recommended PEP, as referred in the WHO Expert Consultation on Rabies: Third Report, 2018 [4]. The orbitofrontal cortex was sampled through the transcribrifom route. As illustrated in Figure 1 below, an artery forceps was gently advanced through the nasal cavity until the resistance of the cribriform plate was encountered. Pressure was exerted gently to break though the cribriform plate, which, being a wafer-thin and perforated bone, yielded easily to pressure. There was a "give" when the cribriform plate broke, and the forceps was easily advanced into the brain tissue. Anatomically, the orbitofrontal cortex rests above the orbital plate on either side of the cribriform plate. This is the region of the brain that is sampled in the transcribriform route. The artery forceps was opened once inside, and brain tissue was caught between the artery forceps and gently extracted via the nose. The extracted brain tissue was suspended in a vial containing sterile saline (0,9% sodium chloride) for PCR and 10% neutral buffered formalin for histopathological examination. The process was repeated multiple times to obtain adequate amounts of brain tissue. The same procedure was repeated through the opposite nasal cavity. Following the procedure, care was taken to pack both nasal cavities with alcohol-soaked gauze. This served to decontaminate the region and prevent any leakage of blood/fluid from the nostrils. All personnel handling the cadaver and brain tissue were previously immunized against rabies.

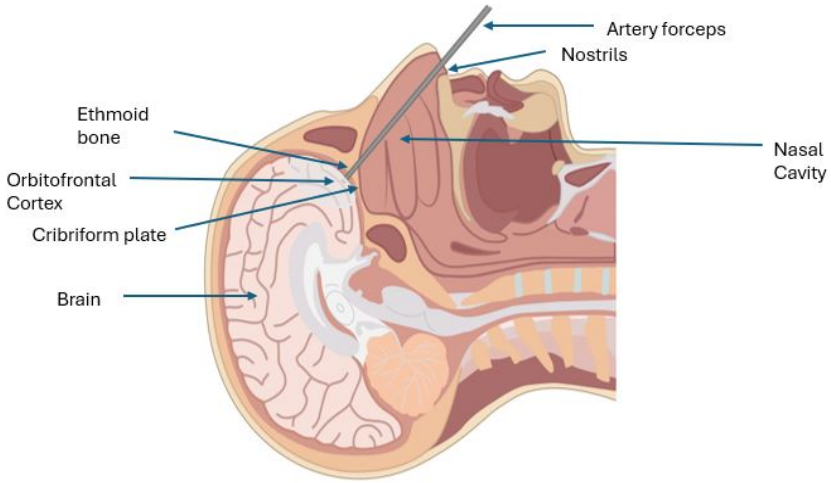

Figure 1. Illustration of the head and the sample taking pathway.

The execution of this technique was guided remotely by neuropathologist from Bangalore, India via WhatsApp audio call. Following the collection process, the samples underwent a triple packaging procedure and were placed on ice packs housed in cooler boxes. The samples were then transported to two different destinations: The Kumasi Centre for Collaborative Research in Tropical Medicine at the Kwame Nkrumah University of Science and Technology and the Accra Veterinary Laboratory, located in the capital city of Ghana, for further testing.

2.3. Laboratory Diagnosis

The direct Fluorescent Antibody Technique (dFAT) is the gold-standard diagnostic test for rabies; however, RT-PCR is a standard diagnostic test recognized by the WHO [5]. The samples were analyzed at the Kumasi Centre for Collaborative Research using RT-PCR with rabies virus primers and probes as per the method described by Faye et al. [14]. The sample was also tested at the Accra Veterinary Laboratory using the one-step RT-PCR pyro method described by De Benedictis et. al. (2011) [15]. The results from both laboratories confirmed that the brain tissue was positive for rabies virus.

3. Discussion

This is a description of a case of human rabies confirmed by laboratory diagnosis in postmortem brain tissue obtained via transnasal biopsy without the need to open the skull to reach the brain tissue. The limited availability and accessibility of diagnostic facilities and tools pose a significant obstacle, compounded by the difficulty in obtaining brain tissue samples from deceased individuals. Cultural and religious beliefs strongly deter the acceptance of autopsies, as they are perceived to disturb the peaceful rest of the deceased, as well as cause disfigurement and fear of a delayed funeral, leading to reluctance among family members to provide consent [16–18].

Introducing the transnasal approach for brain tissue collection emerges as a simple and effective solution, described here for the first time. This method, as with needle biopsies, leaves no mark on the body. It offers a feasible and culturally sensitive alternative, potentially applicable globally. Physicians play a pivotal role in advocating for this method, emphasizing its necessity for disease confirmation while assuring families of its relatively non-invasive nature [19]. Tong et. al. (1999) described a trucut needle biopsy through the supraorbital fissure [20] for obtaining a brain sample for rabies diagnosis; however, this requires a high level of expertise which is not easily available in the rural communities of the world where rabies deaths occur. Suitable training of medical professionals to emphasize the importance of diagnosis and awareness of this simple bedside procedure will help in addressing the families' concerns and obtaining consent.

Confirmation of a rabies diagnosis holds significant value for the formulation of effective post-exposure prophylaxis (PEP) strategies, catering not only to the affected family members but also to the medical practitioners involved in patient care. Furthermore, the inherent simplicity, rapidity, and reduced risk of viral exposure associated with this diagnostic method emphasize its potential for extensive integration into global human rabies diagnosis protocols. This broader implementation not only facilitates PEP planning for other victims and offers solace to bereaved families but also serves as a valuable tool for gathering epidemiological data to establish the burden of the disease in the country. This is crucial for the implementation of preventive and protective measures targeting both animal hosts and human populations.

The success of this first human brain collection in Ghana from a 63-year-old woman in June 2023 paved the way for the confirmation of two other cases, reiterating the feasibility and efficiency of this collection method.

4. Conclusions

The transnasal approach provides a promising method for postmortem brain tissue collection in human rabies diagnosis. However, more work needs to be done to establish the reliability of the method. Technological advancements, coupled with easy communication avenues and extensive intersectoral collaborations among governmental, non-governmental, and research entities—both local and international—led to the landmark achievement of the first reported case of confirmed human rabies diagnosis in Ghana using this simple postmortem sample collection method. This milestone underscores the invaluable benefits derived from cross-sector cooperation and collaborative efforts, showcasing the profound impact of One Health and collaborative efforts in advancing disease diagnosis and control measures in rabies control.

Author Contributions: M.B.D.: Lead investigator and initiator of this work. Involved in concept development, sample collection, and manuscript development and writing. A.-R.A.: Biomedical scientist and laboratory consultant in sample collection, packaging, and transportation. Contributed to concept development. A.A.S.: Analyser of the sample at the Kumasi Centre for Tropical Medicine of the Kwame Nkrumah University of Science and Technology. Contributed to manuscript development. T.O.: Veterinary laboratory scientist and analyser of the sample at the Accra Veterinary Laboratory. Contributed to manuscript development. B.B.A.: Supervisor of the Ghana investigation team. Contributed to the concept and manuscript development. J.A.O.: Member of the concept development team. Contributed to manuscript development. G.Y.: Member of the concept development team; contributed to writing and reviewing of the manuscript. F.L.: Coordinator of the team outside Ghana and member of the concept development team. Contributed to manuscript writing and reviewing. L.G.: Supervisor of the investigation team outside Ghana and part of the concept development team. A.M.: Source of the methodology and instructor for undertaking the sample taking process. Member of the concept development team. Also contributed to manuscript development and writing. All authors have read and agreed to the published version of the manuscript.

Funding: This research received no external funding.

Institutional Review Board Statement: Ethical review and approval were waived for this study due to the fact that it was routine work and decision to publish made retrospectively.

Informed Consent Statement: Informed consent was obtained from the family of the deceased.

Data Availability Statement: Pictures of team ready for sample taking and results from the testing laboratories could be accessed directly from the laboratories or through the corresponding author.

Acknowledgments: We acknowledge the contributions of Emmanuel Nalibe, who supported the team in contacting the bereaved family for their consent for the procedure. The leadership of Binde Hospital and mortuary staff also deserves mention for the role they played in preserving the body and their assistance in the autopsy.

Conflicts of Interest: The authors declare no conflicts of interest. The funders had no role in the design of the study; in the collection, analyses, or interpretation of data; in the writing of the manuscript; or in the decision to publish the results.

References

1. Hampson, K.; Coudeville, L.; Lembo, T.; Sambo, M.; Kieffer, A.; Attlan, M.; Barrat, J.; Blanton, J.D.; Briggs, D.J.; Cleaveland, S.; et al. Estimating the Global Burden of Endemic Canine Rabies. *PLoS Neglect. Trop. Dis.* **2015**, *9*, e0003709.
2. Rana, S.; Siddiqi, U.R.; Ghosh, S.; Jahan, A.A.; Islam, K.; Shah, A.R.; Ullah, S.M.; Ali, S.E.; Ahmed, B.N.; Shamsuzzaman, A.K. Epidemiological study of human rabies cases in Bangladesh through verbal autopsy. *Heliyon* **2020**, *6*, e05521. [CrossRef] [PubMed]
3. Knobel, D.L.; Cleaveland, S.; Coleman, P.G.; Fèvre, E.M.; Meltzer, M.I.; Miranda, M.E.G.; Shaw, A.; Zinsstag, J.; Meslin, F.-X. Re-evaluating the burden of rabies in Africa and Asia. *Bull. World Health Organ.* **2005**, *83*, 360–368. [PubMed]
4. WHO. *WHO Expert Consultation on Rabies: Second Report. Geneva PP—Geneva: World Health Organization*; WHO Technical Report Series; WHO: Geneva, Switzerland, 2013.
5. WHO. *WHO Expert Consultation on Rabies, Third Report. Geneva: World Health Organization*; WHO Technical Report Series; WHO: Geneva, Switzerland, 2018; Licence: CC BY-NC-SA 3.0 IGO.
6. Cleaveland, S.; Thumbi, S.; Sambo, M.; Lugelo, A.; Lushasi, K.; Hampson, K.; Lankester, F. Proof of concept of mass dog vaccination for the control and elimination of canine rabies. *Rev. Sci. Tech.* **2018**, *37*, 559–568. [CrossRef] [PubMed]
7. Banyard, A.C.; Horton, D.L.; Freuling, C.; Müller, T.; Fooks, A.R. Control and prevention of canine rabies: The need for building laboratory-based surveillance capacity. *Antivir. Res.* **2013**, *98*, 357–364. [CrossRef] [PubMed]
8. Punguyire, D.T.; Osei-Tutu, A.; Aleser, E.V.; Letsa, T. Level and pattern of human rabies and dog bites in Techiman Municipality in the Middle Belt of Ghana: A six year retrospective records review. *PAMJ* **2017**, *28*, 281. [CrossRef] [PubMed]
9. Amoako, Y.A.; El-Duah, P.; Sylverken, A.A.; Owusu, M.; Yeboah, R.; Gorman, R.; Adade, T.; Bonney, J.; Tasiame, W.; Nyarko-Jectey, K.; et al. Rabies is still a fatal but neglected disease: A case report. *J. Med. Case Rep.* **2021**, *15*, 575. [CrossRef] [PubMed]
10. Otolorin, G.R.; Olaniyi, A.J.; Paul, M.P.; Odinya, A.V.; Adamu, D.A.; Atinuke, D.M.; Audu, D.F. A Review on Human Deaths Associated with Rabies in Nigeria. 2015. Available online: http://irepos.unijos.edu.ng/jspui/handle/123456789/2587 (accessed on 5 March 2024).
11. Mallewa, M.; Fooks, A.R.; Banda, D.; Chikungwa, P.; Mankhambo, L.; Molyneux, E.; Molyneux, M.E.; Solomon, T. Rabies Encephalitis in Malaria-Endemic Area, Malawi, Africa. *Emerg. Infect. Dis.* **2007**, *13*, 136. [CrossRef] [PubMed]

12. Ghana Statistical Service. Ghana 2021 Population and Housing Census, Population of Regions and Districts, Volume 3A. 2021. Available online: https://statsghana.gov.gh/gssmain/fileUpload/pressrelease/2021%20PHC%20General%20Report%20Vol%203A_Population%20of%20Regions%20and%20Districts_181121.pdf (accessed on 5 March 2024).
13. Ghana Statistical Services. Ghana 2021 Population and Housing Census, Age and Sex Profile, Volume 3B. 2021. Available online: https://census2021.statsghana.gov.gh/gssmain/fileUpload/reportthemelist/2021%20PHC%20General%20Report%20Vol%203B_Age%20and%20Sex%20Profile_181121b.pdf (accessed on 5 March 2024).
14. Faye, M.; Dacheux, L.; Weidmann, M.; Diop, S.A.; Loucoubar, C.; Bourhy, H.; Sall, A.A.; Faye, O. Development and validation of sensitive real-time RT-PCR assay for broad detection of rabies virus. *J. Virol. Methods* **2017**, *243*, 120–130. [CrossRef] [PubMed]
15. De Benedictis, P.; De Battisti, C.; Dacheux, L.; Marciano, S.; Ormelli, S.; Salomoni, A.; Caenazzo, S.T.; Lepelletier, A.; Bourhy, H.; Capua, I.; et al. Lyssavirus detection and typing using pyrosequencing. *J. Clin. Microbiol.* **2011**, *49*, 1932–1938. [CrossRef] [PubMed]
16. Chariot, P.; Witt, K.; Pautot, V.; Porcher, R.; Thomas, G.; Zafrani, E.S.; Lemaire, F. Editorial Consortium Declining Autopsy Rate in a French Hospital Physicians' Attitudes to the Autopsy and Use of Autopsy Material in Research Publications. *Arch. Pathol. Lab. Med.* **2000**, *124*, 739–745. [CrossRef] [PubMed]
17. Blum, L.S.; Karia, F.P.; Msoka, E.F.; Mwanga, M.O.; Crump, J.A.; Rubach, M.P. An in-depth examination of reasons for autopsy acceptance and refusal in Northern Tanzania. *Am. J. Trop. Med. Hyg.* **2020**, *103*, 1670–1680. [CrossRef] [PubMed]
18. Namuju, O.C.; Kwizera, R.; Lukande, R.; Pastick, K.A.; Taylor, J.M.; Nicol, M.R.; Boulware, D.R.; Meya, D.B. Rates of refusal of clinical autopsies among HIV-positive decedents and an overview of autopsies in Uganda. *Wellcome Open Res.* **2021**, *6*, 302. [CrossRef] [PubMed]
19. Cox, J.A.; Lukande, R.L.; Kateregga, A.; Mayanja-Kizza, H.; Manabe, Y.C.; Colebunders, R. Autopsy acceptance rate and reasons for decline in Mulago Hospital, Kampala, Uganda. *Trop. Med. Int. Health* **2011**, *16*, 1015–1018. [CrossRef] [PubMed]
20. Tong, T.R.; Leung, K.M.; Lee, K.C.; Lam, A.W. Trucut needle biopsy through superior orbital fissure for the diagnosis of rabies. *Lancet* **1999**, *354*, 2137–2138. [CrossRef] [PubMed]

Disclaimer/Publisher's Note: The statements, opinions and data contained in all publications are solely those of the individual author(s) and contributor(s) and not of MDPI and/or the editor(s). MDPI and/or the editor(s) disclaim responsibility for any injury to people or property resulting from any ideas, methods, instructions or products referred to in the content.