poultry

MDPI

Article

Pathological and Ileal Microbiota Findings in Seven-Day-Old Chicks with Gizzard Lesions and Growth Delay

Dayse Helena Lages da Silva [1], Luana Ferreira Marques Cordeiro [1], Diego Lisboa Rios [2], Oliveiro Caetano de Freitas Neto [3], Leonardo José Camargos Lara [4], Juan Carlos Ariute Oliveira [3], Flávia Figueira Aburjaile [3] and Roselene Ecco [1,*]

1 Pathology Sector and Multilab, Department of Veterinary Clinic and Surgery, Veterinary School, Universidade Federal de Minas Gerais (UFMG), Belo Horizonte 31270-901, MG, Brazil
2 Department of Microbiology, Institute of Biological Sciences, Universidade Federal de Minas Gerais (UFMG), Belo Horizonte 31270-901, MG, Brazil
3 Department of Preventive Veterinary Medicine, Veterinary School, Universidade Federal de Minas Gerais (UFMG), Belo Horizonte 31270-901, MG, Brazil; oliveirocaetano@yahoo.com.br (O.C.d.F.N.); jcarlosariute@gmail.com (J.C.A.O.); faburjaile@gmail.com (F.F.A.)
4 Department of Zootechnics, Veterinary School, Universidade Federal de Minas Gerais (UFMG), Belo Horizonte 31270-901, MG, Brazil; leonardo@vet.ufmg.br
* Correspondence: ecco@vet.ufmg.br

Abstract: Gizzard erosion and ulceration (GEU) is characterized by defects and necrosis in the koilin layer, particularly in broilers. This condition has been associated with growth retardation, runting, and economic implications for poultry producers; nevertheless, its influence on gut microbiota remains unknown. This study investigated the compositional changes in the bacterial community of the ileum of seven-day-old broiler chicks with GEU using next-generation sequencing (NGS) technology. Twenty-two samples were obtained from the ileal mucosa and contents of sixteen chicks with GEU and six without GEU raised in a conventional system located on a farm in southeast Brazil. The results revealed that bacterial phyla in both groups exhibited a similar composition, with Firmicutes representing the most abundant. *Porphyromonas*, Candidatus *Arthromitus*, and *Limosilactobacillus* were statistically more abundant in the group without GEU. The most prevalent genera in the group with GEU were *Lactobacillus* and *Enterococcus*, and the relative abundance of *Enterococcus* in the ilea of some chicks with GEU was considerable. Based on the results of the current study, necrosis in the koilin layer can change the composition of ileal microbiota. Therefore, further studies should be carried out to clarify whether GEU and consequently poor digestibility of the feed cause significant changes in the intestinal microbiota.

Keywords: broiler chickens; intestine; gizzard erosion; microbiota

check for updates

Citation: da Silva, D.H.L.; Cordeiro, L.F.M.; Rios, D.L.; de Freitas Neto, O.C.; Lara, L.J.C.; Oliveira, J.C.A.; Aburjaile, F.F.; Ecco, R. Pathological and Ileal Microbiota Findings in Seven-Day-Old Chicks with Gizzard Lesions and Growth Delay. *Poultry* **2024**, *3*, 409–419. https://doi.org/10.3390/poultry3040031

Academic Editor: Alessandra Piccirillo

Received: 28 July 2024
Revised: 15 September 2024
Accepted: 22 October 2024
Published: 14 November 2024

Copyright: © 2024 by the authors. Licensee MDPI, Basel, Switzerland. This article is an open access article distributed under the terms and conditions of the Creative Commons Attribution (CC BY) license (https://creativecommons.org/licenses/by/4.0/).

1. Introduction

Gizzard erosion and ulceration (GEU) represents a significant digestive condition that predominantly affects avian species, particularly young broilers. This condition is characterized by gross erosion and ulcers in the koilin layer of the gizzard. Histologic examination of the gizzards reveals necrosis and disruption of the koilin layer, and heterophils and lymphohistiocytic inflammation in the mucosa that underlie the necrotic koilin membrane [1,2]. The etiology of GEU is multifactorial, and several factors have been identified as potential contributors. These include water and food deprivation [3], ingestion of nonsoluble fiber as oat hulls and wood shavings [1], nutritional deficiencies (vitamin B6, B12, and choline) [1,4], environmental stressors [5], mycotoxins (T-2 toxin, moniliformin, fumonisins B1 and B2) [1], high levels of dietary cooper, and the possible association of cooper and *Clostridium perfringens* [2]. Infection with species A and E of avian adenovirus has also been implicated in the onset of GEU [2,6]. GEU is a serious condition with major

impacts on bird health, often resulting in reduced productivity, welfare, and economic implications for poultry producers [7]. Therefore, understanding the underlying causes and mechanisms of GEU is imperative for effective management and preventive strategies in poultry farming. Despite the significant advancements that have been made in the field of avian medicine, GEU remains a challenge due to its complex multifactorial etiology [1]. The aim of this study was to investigate the possible consequences for the ileal microbiota in seven-day-old broiler chicks with GEU and growth retardation. We hypothesized that lesions in the gizzard mucosa could cause changes in digestibility and the composition of the intestinal microbiota.

2. Materials and Methods

The seven-day-old Ross 308 broiler chicks were raised in a conventional system located on a farm in southeast Brazil. For prompting clinic and pathologic investigation, samples from 22 chicks were selected due to a history of reduced feed consumption, watery diarrhea, retarded weight gain, lack of uniformity in the flock, and a mild increase in mortality. Viral enteritis was suspected as the cause of the delayed growth and stunting. After euthanasia, a complete necropsy and gross examination were performed along with sample collection for histopathology and molecular studies. Duodenum, jejunum, ileum, spleen, thymus, cloacal bursa, liver, lung, heart, kidney, ventricle, proventriculus, pancreas, cecal tonsils, and cecum were collected and fixed for 48 h in 10% buffered formalin. The fixed tissues were routinely processed, embedded in paraffin, and trimmed at 4 µm thick sections using a microtome. The sections were stained with hematoxylin-eosin (HE) and analyzed under a common light microscope [8].

Gizzard tissue samples from chicks with GEU were collected and frozen (−20 °C) until processing. The total DNA from gizzard samples was extracted using a commercial kit (DNeasy Blood and Tissue Kit, Qiagen Inc., Toronto, ON, Canada), following the manufacturer's recommendation. Adenovirus PCR was performed using the hexon A and B primers as previously described [9].

The ilea were collected and stored at −80 °C until processing. The ileal segment was chosen because of the function of nutrient absorption and the specific bacterial community present in this segment [10,11]. Initially, a pretreatment was performed to lyse the cell walls of Gram-positive bacteria with a mix of the following reagents: dithiothreitol (10% in PBS, pH 7.2); 200 mM Tris HCl solution; 20 mM EDTA solution; Triton X100; and lysozyme solution (100 mg/mL in PBS, pH 7.2). Additionally, 0.3 g of 0.1 mm zirconia beads per sample were added, and the samples were homogenized in a TissueLyser LT bead mill for 10 min at the maximum speed. Subsequently, total DNA from the ileal mucosa and contents was extracted using a commercial kit (DNeasy Blood and Tissue Kit, Qiagen Inc., Toronto, ON, Canada) in accordance with the manufacturer's instructions. The quantification of DNA was determined utilizing the NanoDrop® 2000/2000 c spectrophotometer (ThermoFisher Scientific, Waltham, MA, USA). The initial polymerase chain reaction (PCR) for genomic sequencing was employed using forward and reverse primers (5′ to 3′), which targeted the V3–V4 regions of the 16S rRNA gene, according to the Illumina protocol for MiSeq. PCR was performed using the Platinum™ Taq DNA Polymerase High Fidelity enzyme mixture (Invitrogen, Carlesbad, CA, USA). The cycles included an initial denaturation at 94 °C for 3 min, followed by 40 cycles of denaturation at 94 °C for 15 s, annealing at 58 °C for 30 s, and extension at 68 °C for 1 min, with a final extension at 68 °C for 7 min. Subsequently, the PCR products were purified utilizing Agencourt AMPure beads (Beckman Coulter, Indianapolis, IN, USA). Purified amplicons were amplified with distinct pairs of i5 forward index and i7 reverse index from the Nextera XT Index Kit (Illumina, San Diego, CA, USA). Each PCR set included extraction and PCR blank controls. Both [i5] and [i7] represent unique 10 bp barcode sequences that enable the sequencing of pooled libraries simultaneously, a method known as sample multiplexing. Barcoded amplicons were further purified using Agencourt AMPure beads (Beckman Coulter) and quantified using Qubit® 2.0 Fluorometer along with Qubit™ dsDNA HS and BR Assay

Kits (Thermo Fisher Scientific, Waltham, MA, USA). Subsequently, equal quantities of each purified barcode-containing amplicon were pooled to construct libraries. The libraries were sequenced on the MiSeq platform utilizing the MiSeq Reagent Kit v3 (600-cycle) protocol at paired-end 2 × 300 bp. Bioinformatics and statistical analysis were conducted using QIIME 2 and the phyloseq R package. The raw sequence data underwent processing with DADA2, including quality filtering, merging paired ends, and removing chimeras and singletons, resulting in an amplicon sequence variant (ASV) feature table. Low-quality regions were removed, and sequences were truncated at 260. OUT to ASVs were aligned to MAFFT version 7, and phylogenetic analysis was performed using FastTree2. A machine-learning taxonomy classifier was trained against the eHOMD database for taxonomic assignment. Diversity analyses included alpha and beta diversity calculations, with group comparisons using the Mann-Whitney test and PERMANOVA. The relative abundance was estimated using STAMP 2.1.3 and R Studio 2022.07.2+576.

Raw data were deposited in the NCBI database using the following identification: Bioproject PRJNA1029160 (https://www.ncbi.nlm.nih.gov/sra/PRJNA1029160 accessed on 17 October 2023).

3. Results

On the fourth day of life, the chicks began to consume less feed, presented with watery diarrhea or poorly digested feed, and were observed to be clustered together, showing environmental discomfort (cold) (Figure 1). On the sixth and seventh days of life, the chicks exhibited a decline in performance, delayed growth, and a lack of uniformity (approximately 50%), accompanied by a slight increase in mortality. Of the 22 chicks that exhibited clinical signs, 6 had no gizzard erosions (Group A), while 16 had gross lesions in the gizzard (Group B).



Figure 1. Six-day-old chicks clustered together appearing cold.

3.1. Gross and Microscopic Results

The lesions were characterized by multiple millimetric areas or locally extensive necrosis and brown discoloration of the koilin membrane (Figure 2a). The intestines of these birds were frequently distended by gas and contained watery contents with undigested food. Histopathological examination revealed marked necrosis and disruption of the koilin layer associated with cellular debris, exfoliation of necrotic epithelial cells, mild to moderate heterophils infiltration, fibrin, and hemorrhage (Figure 2b). In the mucosal layer, heterophils, lymphocytes, and fibroplasia were present in mild amounts in the lamina propria. No intranuclear adenoviral inclusion bodies or intralesional bacilli were identified in the gizzard mucosa. All gizzard samples tested negative for adenovirus PCR. In all other organs, including the small and large intestines, no histological changes were identified.

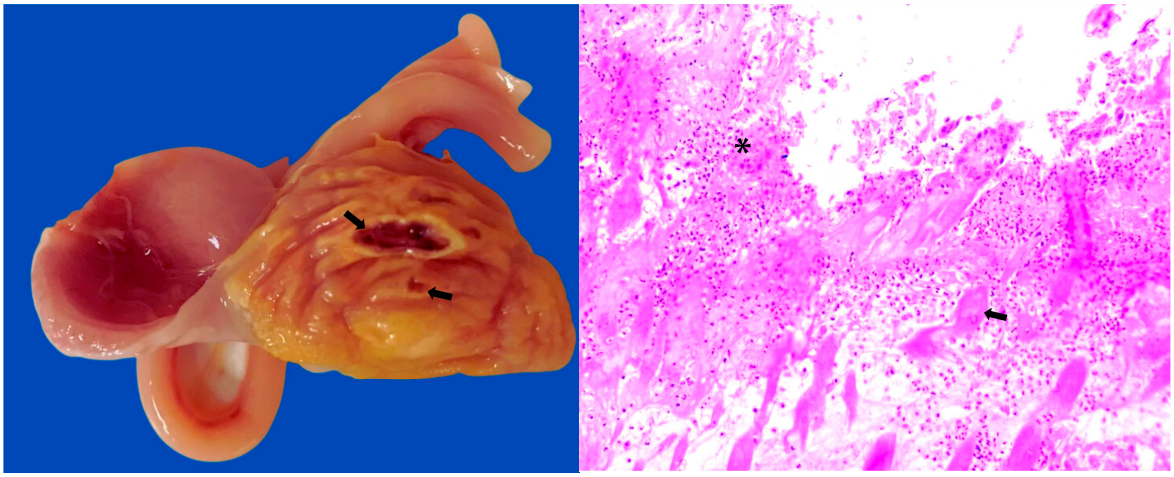

(**a**) (**b**)

Figure 2. Gross and microscopic images of the gizzard of seven-day-old chicks. (**a**) Deep and locally extensive necrosis (arrow) in the koilin membrane with brown center (ulcer) and some millimetric erosions (arrow). (**b**) Necrosis and disruption of the koilin membrane (arrow) with cellular debris and inflammatory cells (*). Hematoxylin and eosin (HE) 100×.

3.2. Sequencing Data

A total of 1,048,972 raw reads were obtained by sequencing the contents and mucosa of the ileum from seven-day-old chicks. After assembly and quality filtering, a total of 509,138 reads passed the filters applied in QIIME, with an average of 23,142 reads/sample and a sequence length of 300 bp. The rarefaction curve generated from the OTUs indicated a high sample coverage; therefore, the sequenced samples reached the depth required to observe all taxa and infer the total diversity of the sampled community. The Shannon and Simpson tests showed an increase in species diversity in the ileal microbiota of chicks with gizzard erosion (B) (Figure 3), although there was no statistical difference ($p > 0.05$) in diversity between the groups without GEU (A) and with GEU (B) using the Mann–Whitney tests.

Beta diversity was generated by measuring the Bray–Curtis distances between the groups of chicks with and without gizzard erosion. Adonis analysis based on the weighted UniFrac distance matrix showed no significant statistical difference between the groups without and with gizzard erosion (R2 = 0.02065, $p = 0.964$).

The composition of bacterial phyla in the groups exhibited a similar composition, with Firmicutes representing the most abundant, followed by Bacteroidota. At the genus level, *Porphyromonas*, Candidatus *Arthromitus*, and *Limosilactobacillus* were statistically more abundant in group A (without GEU) ($p < 0.005$). The most prevalent genera in group B (with GEU) were *Lactobacillus* and *Enterococcus* (Figure 4).

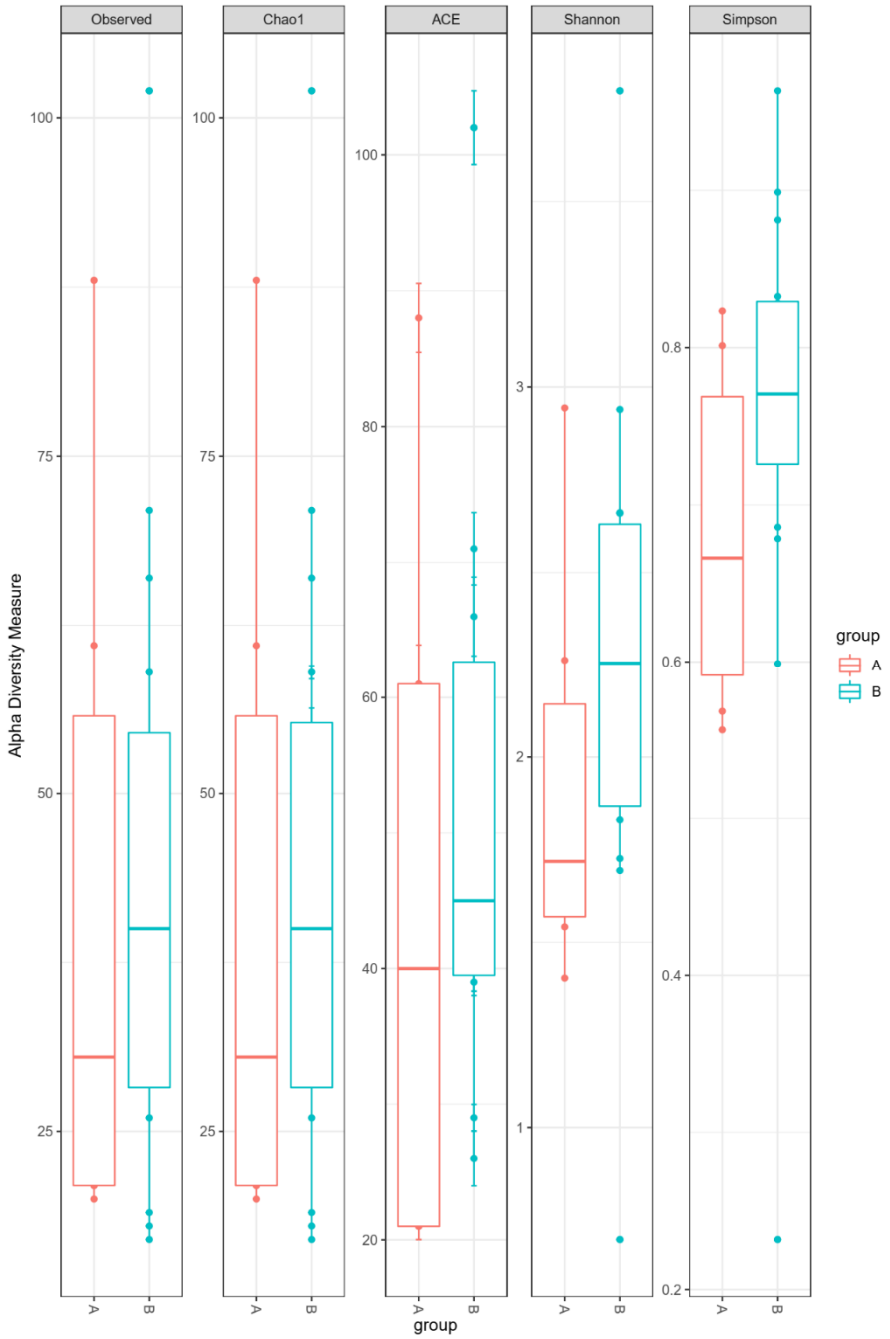

Figure 3. Seven-day-old-chicks. Group A (without gizzard erosion and ulceration) and group B (with gizzard erosion and ulceration). The graph of observed species richness and alpha diversity measures: Chao1, ACE (species richness estimator), Shannon, and Simpson tests (species diversity indices). Only in the Shannon and Simpson test was there a difference, with more diversity in the group with gizzard erosion (B). No significant differences were observed between the groups using the Mann–Whitney tests ($p > 0.05$).

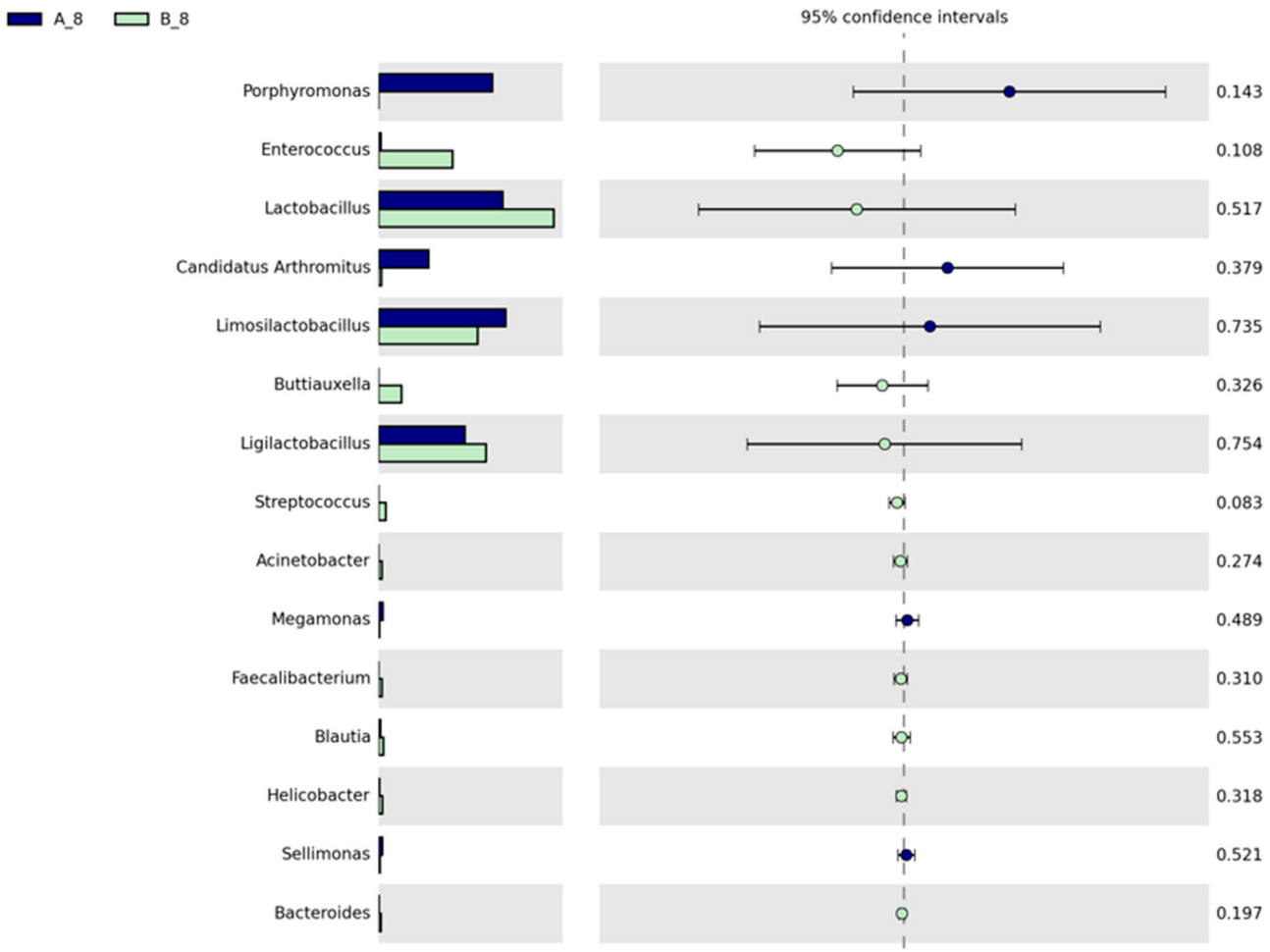

Figure 4. Statistical chart representing the main genera (top 15 genera) found in groups A, without gizzard erosion and ulceration (blue color), and B, with gizzard erosion and ulceration (green color). *Porphyromonas*, Candidatus *Arthromitus*, and *Limosilactobacillus* were statistically more abundant in group A ($p < 0.005$).

Despite no significant difference between the two groups, the relative abundance of the Enterococcaceae family and *Enterococcus* genus in the ilea of some chicks with gizzard koilin membrane lesions (B) was considerable (Figures 5 and 6).

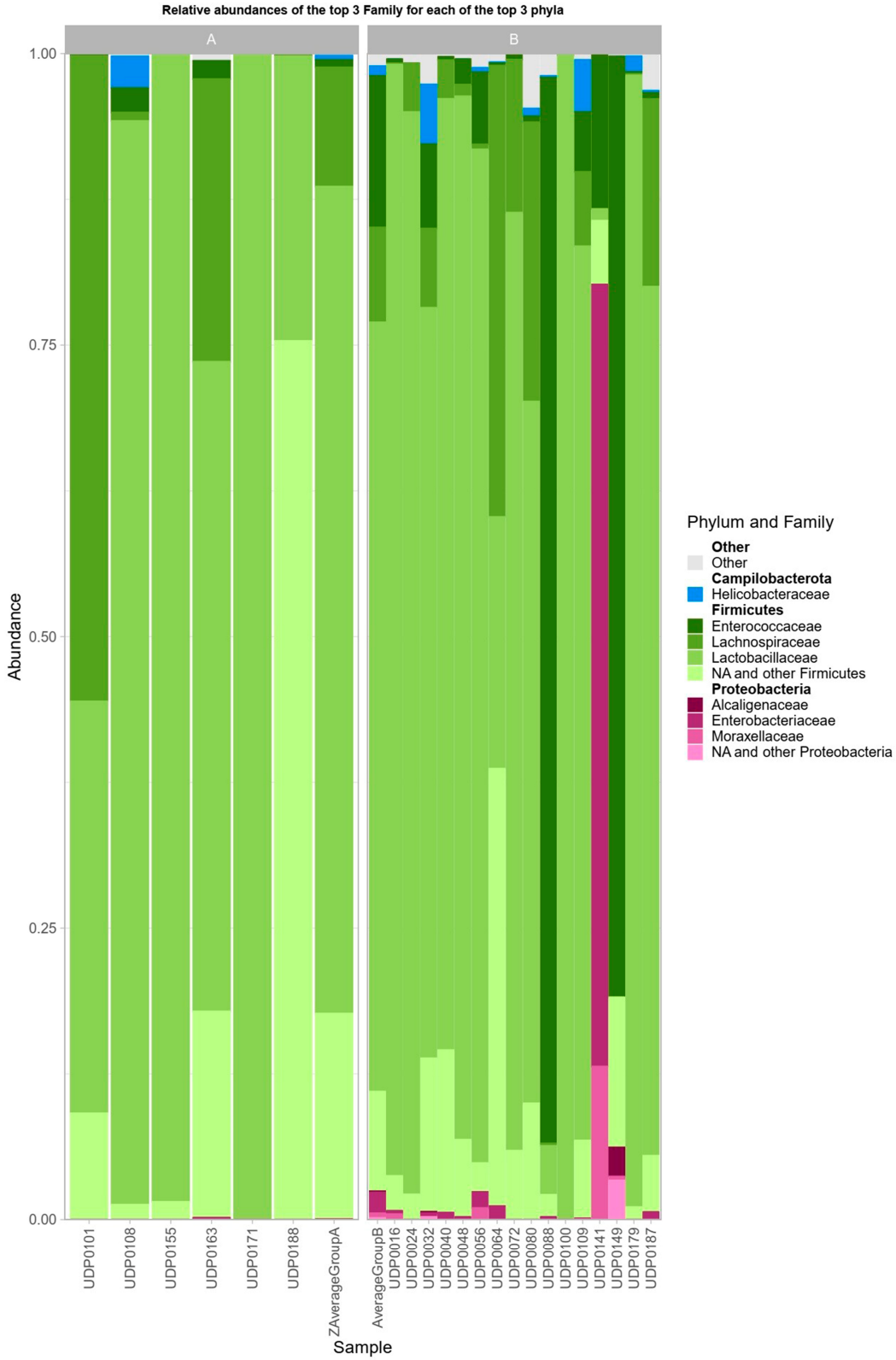

Figure 5. Stacked bar chart of the abundance of the main phyla and families present in the ileum of chicks, group A (without gizzard erosion and ulceration), and group B (with gizzard erosion and ulceration). Each column represents a seven-day-old chick.

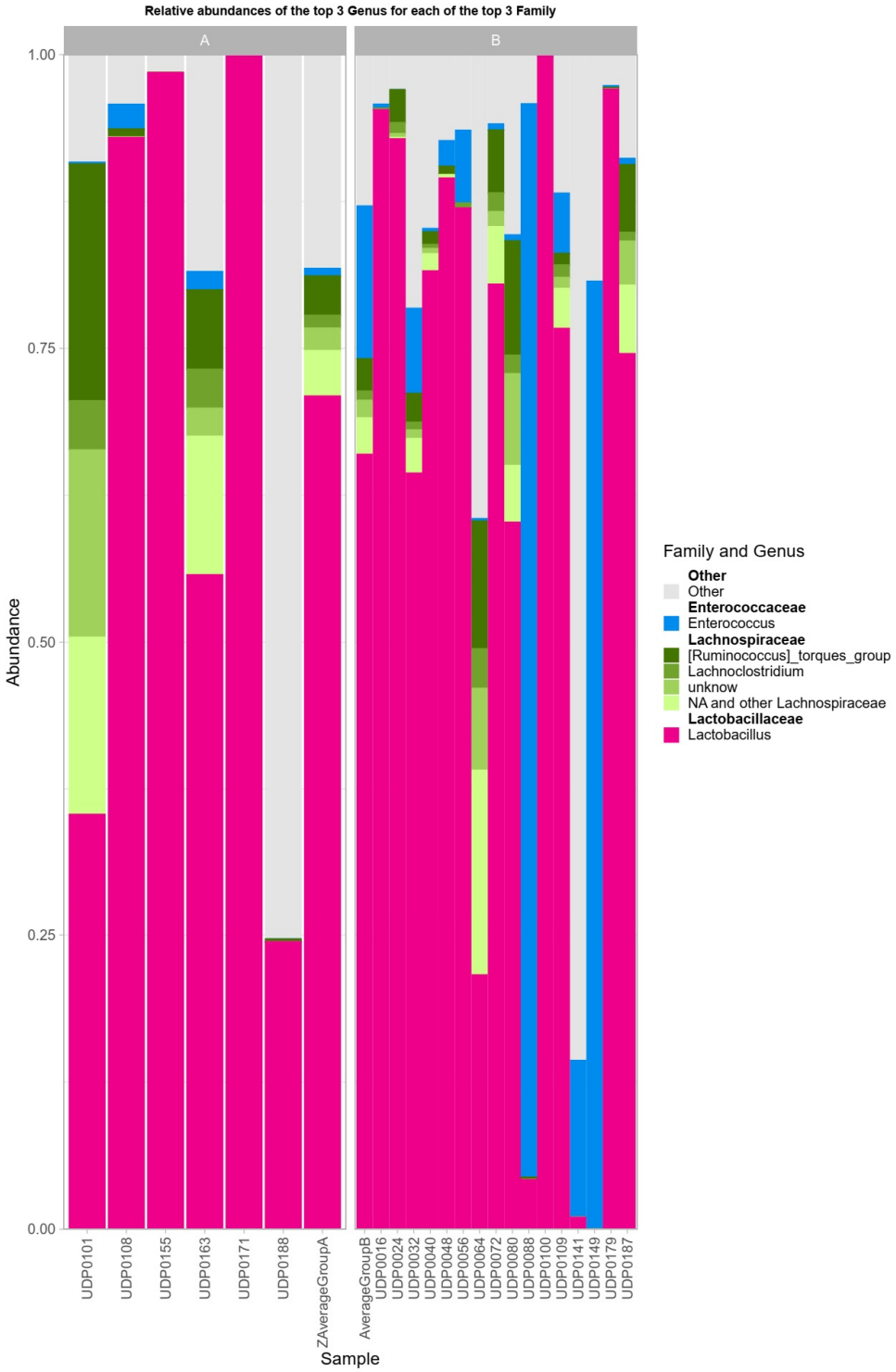

Figure 6. Stacked bar chart of the abundance of the main families and genera present in the ileum of chicks, group A (without gizzard erosion and ulceration), and group B (with gizzard erosion and ulceration). Each column represents a seven-day-old chick. *Lactobacillus* is predominant in both groups, but the *Enterococcus* genus is more abundant in the group with gizzard lesions.

4. Discussion

To ascertain the underlying cause of growth retardation and culling, it is first necessary to conduct an initial examination of the affected tissue. This should entail both a gross and microscopic analysis. Histopathology of the intestines allows for the exclusion or confirmation of viral enteritis, which was the initial clinical suspicion. However, this was

not confirmed following the histopathological examination in the chicks of the present study. The findings of gizzard erosions in conjunction with poorly digested intestinal contents in several of the chicks prompted the investigation of the potential causes of the gizzard lesion and the comparison of the intestinal microbiota of the chicks with and without gizzard erosions. In consideration of infectious causes for gizzard erosion and ulceration, intranuclear inclusion bodies that would indicate an adenoviral etiology were not identified, and adenovirus PCR was negative for all gizzard samples [6]. It was therefore necessary to consider other potential causes for the gizzard lesions in these birds, undertaking a comprehensive evaluation of epidemiological information, the environment, and the diet [12]. The other possible differential was *Clostridium perfringens* [2], although considered unlikely because no intralesional bacilli were seen in our cases.

Based on the environment in which these chicks were housed, there was environmental discomfort, considered a stress factor, similar to previous reports [13], in which reduced feed intake and weight gain were the main signs presented. Behavioral manifestations of stress in broilers can result in decreased feed intake, lower nutrient digestibility, and reduced feed efficiency [7]. In the present study, the chicks exhibited signs of environmental discomfort and consequently reduced feed intake and growth retardation. Reduced food intake and stress factors can lead to increased production of acetylcholine and histamine, resulting in increased gastric acid production and consequently erosion of the koilin membrane in the gizzard [5].

The differential diagnosis of gizzard erosion in chicks also includes non-infectious causes such as vitamin B6 deficiency [3], gizzard erosion caused by gizzerotoxin [14], histamine [15], mycotoxins [12], copper added to broiler diets in excess, and stress, probably related to the increase in gastric acid [2]. In the present study, the feed did not contain any fish meal derivatives, thus excluding gizzerosin toxicity. It was not possible to analyze the feed for the presence of mycotoxins, a cause that should not be ruled out in the differential diagnosis of gizzard erosion and ulceration in these chicks.

Microscopically, no intestinal lesions were seen in the examined chicks. Particularly in the chicks with gizzard erosion, the passage of poorly digested feedstuffs to the intestines could cause maldigestion and malabsorption. Thus, these nutrients within the intestinal lumen may contribute to diarrhea by creating an osmotic effect [16]. In addition, maldigestion could be a reason for microbiota changes as a result of competition for nutrients and the production of toxic and anti-nutritional compounds within the gastrointestinal tract [11].

The genera *Enterococcus* and *Streptococcus*, both known as pathogenic bacteria, were predominant in some chicks of the group with gizzard lesions, suggesting a potential role of gizzard lesions and changes in the ileal microbiota. The current investigation scrutinized the ileal microbiota through metagenomic sequencing, unveiling some rise in alpha diversity among chicks displaying gizzard erosion compared to those lacking such erosion. The scrutiny of the gut microbiota in birds under stress has been a subject of continuous examination, revealing varying outcomes in the alterations within this microbial community. The diversity of the intestinal microbiota is important for promoting stability and performance. Increased alpha diversity of the microbiota has been used as an indicator of assessing intestinal health or changes in its composition [17].

In the current study, the genera *Porphyromonas*, Candidatus *Arthromitus*, and *Limosilactobacillus* were statistically more abundant in group A ($p < 0.005$). This difference may indicate that genera of bacteria with probiotic potential are present in greater quantities in the group without ventricular lesions (group A) (Figure 2). The genus Candidatus *Arthromitus* is considered a segmented filamentous bacteria (SFB) that colonizes the digestive tract of many animal species [18]. In the intestinal environment, these Gram-positive, endospore-producing organisms adhere to the epithelial linings using holdfast structures. Avian species host SFB in their ceca. Notably, no detrimental effects associated with SFB have been observed, even in animals with compromised immune systems [18]. Additionally, the bacteria *Limosilactobacillus fermentum* isolated from poultry have shown probiotic potential, with the ability to inhibit *Salmonella* Gallinarum in vitro, suggesting that these strains could

be used as probiotics to help control fowl typhoid in poultry [19]. Chicken ileum, similarly to the duodenum, is dominated by *Lactobacillus*, and this segment can be rapidly inhabited by other bacteria in the first three weeks of life. Because of the nutrient absorption in the ileum, an increase in undesirable bacteria may influence nutrient availability and absorption rate and consequently the bird performance [18]. The intestinal microbiota of the gizzard and other intestinal segments was not investigated in our study; therefore, further studies may provide additional results regarding alterations in the intestinal microbiota in chicks with gizzard erosion.

5. Conclusions

In this study, clinical signs and gizzard lesions were observed in chicks, which may have been caused by environmental stress and/or mycotoxins, with no evidence of a viral cause. GEU has multiple causes, emphasizing the importance of ancillary tests for a definitive diagnosis. Furthermore, it is of paramount importance to observe and monitor the flock's behavior to identify any environmental changes that may disrupt the welfare and well-being of the chicks. Our investigation indicates that GEU could be linked to changes in the intestinal microbiota as a consequence of poor digestion related to lesions in the gizzard. This observation warrants further investigation to elucidate whether GEU and subsequent poor feed digestibility result in substantial and meaningful alterations in the intestinal microbiota and delayed growth.

Author Contributions: Conceptualization, R.E., L.J.C.L. and D.H.L.d.S.; methodology, D.H.L.d.S. and D.L.R.; formal analysis, D.L.R., F.F.A. and J.C.A.O.; resources, R.E., L.J.C.L. and O.C.d.F.N.; data curation, D.H.L.d.S. and F.F.A.; writing—original draft preparation, D.H.L.d.S., J.C.A.O. and L.F.M.C.; writing—review and editing, R.E., F.F.A. and O.C.d.F.N.; supervision, R.E.; project administration, R.E.; funding acquisition, R.E. All authors have read and agreed to the published version of the manuscript.

Funding: This research was funded by the Fundação de Amparo à Pesquisa do Estado de Minas Gerais [FAPEMIG], grant number APQ-02714-18. R.E. and O.C.d.F.N. were supported by a fellowship from the Conselho Nacional de Desenvolvimento Científico e Tecnológico (CNPq-National Council for Scientific and Technological Development), Brazil. D.H.L.d.S., D.L.R. and J.C.A.O. were supported by the Coordenação de Aperfeiçoamento de Pessoal de Nível Superior, Brazil (CAPES-Coordination of Improvement of Higher Education Personnel), Finance Code 001.

Institutional Review Board Statement: The animal study protocol was approved by the Ethics Committee of the Universidade Federal de Minas Gerais (protocol code 62/2017).

Informed Consent Statement: Not applicable.

Data Availability Statement: Raw data were deposited in the NCBI database using the following identification: Bioproject PRJNA1029160 (https://www.ncbi.nlm.nih.gov/sra/PRJNA1029160 accessed on 17 October 2023).

Conflicts of Interest: The authors declare no conflicts of interest.

References

1. Gjevre, A.G.; Kaldhusdal, M.; Eriksen, G.S. Gizzard erosion and ulceration syndrome in chickens and turkeys: A review of causal or predisposing factors. *Avian Path.* **2013**, *42*, 297–303. [CrossRef] [PubMed]
2. Jones, M.K.; Hofacre, C.L.; Hoerr, F.J.; Baxter, V.A.; Berghaus, R.D.; Sellers, H.S.; Ferguson-Noel, N.; Smith, J.A. Investigations into Increased Incidence of Severe Gizzard Erosions and Ulcerations in U.S. Commercial Broilers. *Avian Dis.* **2024**, *67*, 349–365. [CrossRef] [PubMed]
3. Bierer, B.W.; Carll, W.T.; Eleazer, T.H.; Barnett, B.D. Gizzard erosion and lower intestinal congestion and ulceration due to feed and water deprivation in chickens of various ages. *Poult. Sci.* **1966**, *45*, 1408–1411. [CrossRef] [PubMed]
4. Daghir, N.J.; Haddad, K.S. Vitamin B6 in the etiology of gizzard erosion in growing chickens. *Poult. Sci.* **1980**, *60*, 988–992. [CrossRef] [PubMed]
5. Grabarevic, Z.; Tisljar, M.; Dzaja, P.; Artuković, B.; Sikirić, P. Stress induced gizzard erosion in chicks. I. Gross and histopathological findings. *J. Vet. Med. (Zentralbl Vet.)* **1993**, *40*, 265–270. [CrossRef] [PubMed]

6. Goodwin, M.A. Adenovirus inclusion body ventriculitis in chickens and captive bobwhite quail (*Colinus virginianus*). *Avian Dis.* **1993**, *37*, 568–571. [CrossRef] [PubMed]
7. Branco, T.; Moura, D.J.; Nääs, I.A.; Lima, N.D.S.; Klein, D.R.; Oliveira, S.R.M. The sequential behavior pattern analysis of broiler chickens exposed to heat stress. *AgriEngineering* **2021**, *3*, 447–457. [CrossRef]
8. Luna, L.G. *Manual of Histologic Staining Methods of the Armed Forces Institute of Pathology*, 3rd ed.; McGraw-Hill: New York, NY, USA, 1968.
9. Muelemans, G.; Boschmans, M.; Van Den Berg, T.P.; Decaesstecker, M. Polymerase chain reaction combined with restriction enzyme analysis for detection and differentiation of fowl adenoviruses. *Avian Path.* **2001**, *30*, 655–660. [CrossRef] [PubMed]
10. Lu, J.; Idris, U.; Harmon, B.; Hofacre, C.; Maurer, J.J.; Lee, D.M. Diversity and succession of the intestinal bacterial community of the maturing broiler chicken. *Appl. Environ. Microbiol.* **2003**, *69*, 6816–6824. [CrossRef] [PubMed]
11. Stanley, D.; Hughes, R.J.; Moore, R.J. Microbiota of the chicken gastrointestinal tract: Influence on health, productivity and disease. *Appl. Microbiol. Biotechnol.* **2014**, *98*, 4301–4310. [CrossRef] [PubMed]
12. Hoerr, F.J.; Carlton, W.W.; Yagen, B. Mycotoxicosis caused by a single dose of T-2 toxin or diacetoxyscirpenol in broiler chickens. *Vet. Path* **1981**, *18*, 652–664. [CrossRef] [PubMed]
13. Han, H.; Zhou, Y.; Liu, Q.; Wang, G.; Feng, J.; Zhang, M. Effects of ammonia on gut microbiota and growth performance of broiler chickens. *Animals* **2021**, *11*, 1716. [CrossRef]
14. Okazaki, T.; Noguchi, T.; Igarashi, K.; Sakagami, Y.; Seto, H.; Mori, K.; Naito, H.; Masumura, T.; Sugahara, M. Gizzerosine, a new toxic substance in fish meal, causes severe gizzard erosion in chicks. *Agric. Biol. Chem.* **1983**, *47*, 2949–2952. [CrossRef]
15. Ohh, M.; Kim, S.; Pak, S.C.; Chee, K. Effects of dietary supplementation with astaxanthin on histamine induced lesions in the gizzard and proventriculus of broiler chicks. *Asian-Australas. J. Anim. Sci.* **2016**, *29*, 872–878. [CrossRef] [PubMed]
16. Moon, H.W. Mechanisms in the pathogenesis of diarrhea: A review. *J. Am. Vet. Med. Assoc.* **1978**, *4*, 443–448.
17. Girard, C.; Chabrillat, T.; Kerros, S.; Fravalo, P.; Thibodeau, A. Essential oils mix effect on chicks ileal and caecal microbiota modulation: A metagenomics sequencing approach. *Front. Vet. Sci.* **2024**, *4*, 1350151. [CrossRef] [PubMed]
18. Snel, J.; Heinen, P.P.; Blok, H.J.; Carman, R.J.; Duncan, A.J.; Allen, P.C.; Collin, M.D. Comparison of 16S rRNA sequences of segmented filamentous bacteria isolated from mice, rats, and chickens and proposal of Candidatus *Arthromitus*. *IJSEM* **1995**, *45*, 780–782. [CrossRef] [PubMed]
19. Mehmood, A.; Nawaz, M.; Rabbani, M.; Mushtaq, M.H. In vitro characterization of probiotic potential of Limosilactobacillus fermentum against Salmonella Gallinarum causing fowl typhoid. *Animals* **2023**, *13*, 1284. [CrossRef] [PubMed]

Disclaimer/Publisher's Note: The statements, opinions and data contained in all publications are solely those of the individual author(s) and contributor(s) and not of MDPI and/or the editor(s). MDPI and/or the editor(s) disclaim responsibility for any injury to people or property resulting from any ideas, methods, instructions or products referred to in the content.