



## Review

# Passive Microwave Radiometry as a Component of Imaging Diagnostics in Juvenile Idiopathic Arthritis

Alexander V. Tarakanov <sup>1</sup>, Elena S. Ladanova <sup>1</sup>, Alexander A. Lebedenko <sup>1</sup>, Tatyana D. Tarakanova <sup>1</sup>, Sergey G. Vesnin <sup>2</sup>, Tatyana Kharybina <sup>3</sup> and Igor I. Goryanin <sup>4,5,\*</sup>

<sup>1</sup> Department of Postgraduate Education, Rostov State Medical University, 344022 Rostov-on-Don, Russia; dr-tarakanov@yandex.ru (A.V.T.); leno4ka\_l90@mail.ru (E.S.L.); leb.rost@rambler.ru (A.A.L.); drtarakanov@yandex.ru (T.D.T.)

<sup>2</sup> Medical Microwave Radiometry Ltd., Edinburgh EH10 5LZ, UK; vesnin47@gmail.com

<sup>3</sup> Library for Natural Sciences of the Russian Academy of Sciences, 119890 Moscow, Russia; tkharybina@mmwr.co.uk

<sup>4</sup> Biological Systems Unit, Okinawa Institute Science and Technology, Okinawa 904-0495, Japan

<sup>5</sup> School of Informatics, University of Edinburgh, Edinburgh EH8 9YL, UK

\* Correspondence: goryanin@ed.ac.uk

**Abstract:** Juvenile idiopathic arthritis (JIA) is a disease with unknown causes in all forms of arthritis in children under 16 years of age. It is diagnosed when other joint pathologies are excluded. Difficulties in early and differential diagnoses lead to rapid disability and an unfavorable life prognosis. Therefore, a timely diagnosis is necessary to prevent irreversible damage to joints and preserve their function. Due to the widespread use of new technologies, modern multimodal imaging has gained recognition, including radiography, ultrasound, and MRI. The combination of methods plays a key role in confirming the diagnosis, monitoring the disease activity, the prognosis during the disease course, and the outcome in children with JIA. Each method has its advantages and disadvantages. The introduction of passive microwave radiometry (MWR), in combination with other imaging methods, makes it possible to expand the possibilities of screening the disease in the preclinical and early clinical phases.

**Keywords:** juvenile idiopathic arthritis; X-ray; ultrasound; MRI; passive microwave radiometry (MWR)



**Citation:** Tarakanov, A.V.; Ladanova, E.S.; Lebedenko, A.A.; Tarakanova, T.D.; Vesnin, S.G.; Kharybina, T.; Goryanin, I.I. Passive Microwave Radiometry as a Component of Imaging Diagnostics in Juvenile Idiopathic Arthritis. *Rheumato* **2022**, *2*, 55–68. <https://doi.org/10.3390/rheumato2030008>

Academic Editor: Bruce M. Rothschild

Received: 17 March 2022

Accepted: 28 June 2022

Published: 4 July 2022

**Publisher's Note:** MDPI stays neutral with regard to jurisdictional claims in published maps and institutional affiliations.



**Copyright:** © 2022 by the authors. Licensee MDPI, Basel, Switzerland. This article is an open access article distributed under the terms and conditions of the Creative Commons Attribution (CC BY) license (<https://creativecommons.org/licenses/by/4.0/>).

## 1. Introduction

Due to the absence of a single pathognomonic laboratory or clinical sign, JIA is an exception that unites all forms of childhood arthritis, the etiology of which has not yet been determined. It is one of the most frequent and disabling rheumatic diseases in children [1].

JIA is characterized by a high prevalence in the population. Among European and North American populations, the prevalence ranges from 2–20 and 16–150 cases per 100,000, respectively [2]. A noticeable difference in the frequency of JIA subtypes has been observed in different geographic regions and/or ethnic groups. In Western countries, oligoarthritis is the most common subtype. At the same time, this category is rarely found in Costa Rica, India, New Zealand, and South Africa, where polyarthritis predominates [3,4]. In Asia, systemic arthritis is the cause of a large number of childhood arthritis cases, with reported incidences in India and Japan of up to 25% and 50%, respectively [5,6]. In the territory of the Russian Federation, the prevalence of JIA reaches 62.3 per 100,000 children, and girls are more likely to be affected [7].

An early diagnosis and differential diagnoses are difficult with respect to JIA, which subsequently leads to rapid disability and an unfavorable life prognosis for patients. Therefore, timely diagnosis and treatment are essential to prevent irreversible damage to the joints and maintain their function. Clinical evidence supports a “window of opportunity”

at an early stage of the disease. In this case, treatment induced higher rates of remission and improved the long-term results [8].

The joints in children undergo drastic changes during their dynamic growth. Therefore, it is necessary to differentiate between pathological and physiological changes. Joint diseases in children are characterized by an idiopathic inflammatory process. It is believed that the disease has a multifactorial polygenic nature, and the mechanisms of the disease (activation of the immune response) differ in different variants of the disease. JIA is currently regarded as an autoinflammatory disease based on the production of proinflammatory cytokines by activated T-lymphocytes and macrophages with the development of chronic inflammation [7].

The inflammatory process begins in the synovial membrane of the joint, with a violation of microcirculation and damage to the cells lining the synovial membrane (the inner layer of the joint capsule). Synovitis occurs early during the natural history of arthritis. Inflammation manifests as an increase in vascularization, capillary leakage, and joint effusion. Joint edema in rheumatoid arthritis (RA) reflects inflammation of the synovium and is realized by both congenital cells (e.g., monocytes, mast cells, and congenital lymphoid cells) and adaptive immune cells (e.g., T-helper cells and B- cells). This inflammatory process ultimately triggers an osteoclastic reaction that leads to bone erosion. They are an important pathological feature of RA and are associated with disease severity and functional outcomes. The majority of erosions develop in the first two years of the disease and often occur within six months with an aggressive disease. Therefore, it is important for proper treatment to determine the degree of joint involvement in the inflammatory process in a timely manner using diagnostic methods [9].

The diagnosis of JIA is based on anamnesis, physical examination, and biochemical data [10]. There are frequent complaints of pain in bones and joints, swelling, and limitations of mobility. The most characteristic symptom of the disease is joint stiffness, which increases with a prolonged stay in a certain position (e.g., sleep and prolonged sitting). However, these symptoms are difficult to assess in young children. At the same time, edema in arthritis is often incorrectly identified. Joint pain may be absent, particularly in young children (peak incidence is in children 1–3 years old). Therefore, pain is unnecessary for the diagnosis of JIA. In fact, if joint pain is the only complaint in the absence of stiffness, swelling, or activity restrictions, the likelihood of arthritis is low [11,12].

In the classic version, upon physical examination, active arthritis is characterized by edema, skin flushing, hot joints, and a decreased range of motion with pain. The differential diagnosis of suspected childhood arthritis is critical to prevent delayed diagnosis and complications and predict the outcome and response to treatment.

Laboratory diagnostics can also help in the diagnosis of JIA. However, the absence of laboratory inflammatory markers in JIA (leukocytosis, increased platelet count, erythrocyte sedimentation rate, C-reactive protein, anemia, and hypoalbuminemia) does not exclude this diagnosis [13].

In the past 10–15 years, owing to the widespread use of new technologies, modern multimodal imaging has gained recognition, including radiography, ultrasound, and MRI. This approach is becoming increasingly important and plays a key role in confirming the diagnosis, monitoring the disease activity, and predicting the course and outcome in children with JIA. Imaging techniques have been widely integrated into clinical practice to improve diagnosis, disease control, and outcomes in children. For a mutual understanding and comparative analysis of the results in several countries over the past decades, several international groups for the standardization and validation of various imaging methods have been created: the American College of Rheumatology Pediatric Rheumatology Imaging Study Group; European League Against Rheumatism; Pediatric Rheumatology European Society; Pediatric Rheumatology European Society Imaging Working Party; the Norwegian Juvenile Idiopathic Arthritis Study; Childhood Arthritis and Rheumatology Research Alliance Ultrasound Group; and others [14].

The widespread imaging methods cannot yet directly determine the functional parameters in tissues during inflammation. The inflamed tissues have a higher temperature than the surrounding tissues. This does not depend on the etiological factor but may depend on the time of inflammation and the predominance of the exudative or proliferative process. An important factor may be the reactivity of the organism.

A biological object (including the human body) is a source of electromagnetic radiation, the intensity of which is determined by the rate of metabolic processes and other factors. Modern medical devices and methods make it possible to determine the degree of internal passive radiation. One such method is passive microwave radiometry (MWR). It allows for the measurement of the intensity of the intrinsic radiation of internal tissues in the microwave and infrared frequency ranges. In the review, we will discuss MWR and how it could be used in conjunction with other visualization methods.

## 2. Visualization Methods

### 2.1. Radiography

Conventional radiography remains an important diagnostic and monitoring tool for arthritis treatment. Currently, radiography is the reference research method, with a reasonable level of reproducibility [15]. Modern radiography is an inexpensive and readily available method that allows for a wide coverage of affected areas. In addition, there are validated assessment methods and scoring systems that provide longitudinal comparisons in JIA [16].

The main disadvantage of radiography in pediatric patients is the use of ionizing radiation. In addition, the method is not sufficiently sensitive for detecting early osteochondral changes and assessing the inflammatory process, as it allows for only bone structure assessment, while the pathological process begins in the synovial membrane. The destruction of the epiphyseal cartilage leads to persistent inflammation and hypertrophy of the synovial membrane. Only erosive changes after a significant loss of cartilage become evident on radiographs [17]. Therefore, the value of this method is undeniable in the diagnosis of RA in the presence of erosion.

Radiographs are rarely useful in the diagnosis of JIA because, in the early stages, they are often normal, and the growth of bone tissue may occur earlier with the disease [18,19]. For example, on radiographs, the presence of growth lines or transverse lines migrating from the growth plate may indicate underlying chronic inflammation. Although they are not specific to inflammation, they can manifest as malnutrition, endocrinopathies, or fractures. In the early stages of the disease, the narrowing of the joint spaces can be observed in 5% of patients, erosion in 10%, and accelerated bone growth in 20% (more often with damage to the knee joint) [7]. Radiographs can also reveal a disease pattern that suggests a rare alternative diagnosis, such as congenital chondrocalcinosis (pyrophosphate arthropathy). At the same time, a competent assessment of the X-ray images of bones and joints in children—considering age and, in many cases, sex characteristics—will help reduce the number of “errors in the work of a rheumatologist” [15]. Thus, radiography plays an important but limited role in the early diagnosis of RA.

### 2.2. Ultrasound

Ultrasound plays an important role in pediatric rheumatology and is one of the most commonly used techniques. This method is cost-effective, readily available, and non-radiating. It allows for the outlining of inflammatory and structural changes in arthritis, aids in the narrowing of the differential diagnosis, and helps to determine the activity of the disease, identify subclinical diseases, monitor treatment, and assess the severity of joint damage.

The criteria for evaluating ultrasound data are as follows: the amount of intra-articular effusion, the thickness of the synovial membrane, and articular hyaline cartilage. The most common ultrasound result in arthritis is the establishment of inflammatory lesions of the

peripheral joints, articular cavity (synovitis), and tendon sheaths (tenosynovitis), along with the detection of bursitis, enthesopathy, and erosions [20].

For example, after arthroplasty, an ultrasound is used to diagnose and monitor post-operative complications, which include the abnormal accumulation of fluid in the area of the endoprosthesis, hematomas at various stages of resorption and organization, abscesses, tendon damage, and neuropathies, such as peroneal nerve palsy after knee joint and sciatic nerve injury during hip arthroplasty [21]. However, the visual image in this method significantly depends on the anatomical and physiological characteristics of a particular patient, which can present difficulties in childhood, considering the characteristics of a growing organism [22]. For example, for juvenile groups, there are no norms/pathological metric criteria for the thickness of the synovial membrane and cartilage. An ultrasound examination is significantly inferior in identifying central erosive changes located in the center of large joints. It cannot penetrate the bone because of the acoustic shadow from the overlying bone (some areas are inaccessible) and the low penetration of the ultrasound beam into the central part of the connection with high-frequency transducers. The limitations of this method include the inability to investigate changes in the bone marrow associated with the active phase of the course [23].

In young children, for whom synovial tissue is difficult to distinguish from the adjacent hypoechoic epiphyseal cartilage, the assessment of the synovium is challenging. In patients with an advanced stage of the disease, the thickening of the synovial membrane and its vascularization may reflect very little restructuring activity against the background of long-term inflammation [22]. The Doppler ultrasound analyzes synovial blood flow and can show the activity of the process; however, the physiologically profuse vascularization of the epiphyseal cartilage must be distinguished from the synovial hypervascularization associated with inflammation. A potential trap for error in the ultrasound study may be the physiologically pronounced vascularization of the synovial membrane and entheses in healthy children due to the differentiation of the bone and joint system and the abundant blood supply to the emerging tissues [19].

According to Sudoł-Szopińska et al. [24], the disadvantages of ultrasound include the following: low specificity in the ability to assess the state of the bone marrow, since several arthropathies exhibit the same spectrum of symptoms; a limited field of vision; a significant dependence on the expert's experience and the quality of the equipment; and the need for special training.

To conduct a high-quality ultrasound scan, the doctor must be familiar with the changes occurring in a healthy developing joint; the change in the thickness of the epiphyseal cartilage should be compared with that in a healthy child of the same sex and age. According to Cherkasova [25], ultrasound is important for the onset of the disease because it allows for the determination of the expansion of the joint spaces (effusion), the uneven thickening and edema of the synovial membrane, the hyper vascularization of the synovial membrane, intra-articular effusion, the erosion of the contours of the cortical layer of bones, the uneven thickness and heterogeneity of the hyaline cartilage structure, and the infiltration of soft tissues of varying severity.

Given the low level of correlation between clinical data and ultrasound indicators, it is necessary to conduct randomized controlled trials to evaluate not only the therapy received but also new imaging technologies. In the case of remission in a significant number of cases, the residual disease cannot be differentiated from chronic arthritis. The criteria for remission in ultrasound examination, in both adults and children with JIA, have not yet been established [24]. Another disadvantage of ultrasound is that it does not provide any information about the structure of the intramedullary bone. It is known that edematous bone marrow lesions detected on MRI are important prognostic factors and are considered biomarkers of disease progression.

### 2.3. MRI

Owing to its indisputable sensitivity in visualizing early signs of soft tissue inflammation and bone changes, MRI has several advantages: the absence of ionizing radiation, multiplanarity, and the excellent contrast resolution of soft tissues, which makes it possible to evaluate all joint structures. This is the only method that can objectify the bone marrow. This is an indication for treatment to avoid irreversible joint destruction. However, long-term studies are needed to distinguish the bone marrow edema seen in healthy children from the bone marrow edema that develops before erosions in patients with JIA [19]. The clinical significance of bone marrow edema in children with JIA remains unclear, and, owing to its high prevalence in healthy children, it can be considered a sign of normal bone maturation.

It is difficult to differentiate between synovial tissue and intra-articular fluid on MRI. However, the “inflamed” synovium, in contrast to intra-articular fluid, is enhanced by the intravenous administration of paramagnetic Gd-containing contrast agents, which facilitates its recognition [26]. It is known that, on MRI, synovial thickening ( $\geq 2$  mm) that increases after contrast administration is considered an indicator of ongoing inflammation (synovitis), as it has been shown to be treatable. In addition, as reported by Hemke et al. in 2017 [27], the thickness of the synovial membrane in the knee joints of healthy children does not exceed 1.8 mm. When clinical evaluation shows no signs of inflammation but synovial thickening is observed on MRI, it is usually interpreted as subclinical synovitis. It has previously been reported that synovial thickening on MRI is present in approximately 50% of JIA patients who are considered clinically inactive. However, another explanation for the synovial thickening observed on MRI is the persistent synovial changes following chronic inflammation. Because of this controversy, the clinical significance of synovial thickening on MRI remains unclear [28]. According to the results of studies by van Gulik, MRI in younger patients with JIA may be a more effective additional method for monitoring disease activity. A significant proportion of children with clinically inactive JIA showed synovial thickening on MRI (34.6%). These results are consistent with previous studies on patients with JIA that examined the inconsistency between the clinical assessment and MRI findings [29,30].

As there are currently no long-term studies evaluating synovial thickening on MRI in patients with clinically inactive JIA, it remains difficult to determine the causes of the observed synovial thickening on MRI.

In recent years, MRI has become increasingly used in JIA, despite some limitations in its application. During one routine MRI examination, only one joint can be examined with all the required sequential contrast enhancements. However, this increases the likelihood of allergic reactions and stressful conditions among children.

There are also relative contraindications for MRI, such as claustrophobia and embedded metal fragments [26]. MRI also has a high cost, a limited availability, a lack of standardized longitudinal prevalence and prospective studies, and, importantly, the need for sedation in young children (4–6 years of age) for proper examination.

At the same time, indications for MRI have changed, shifting towards the early detection of JIA. There has been an overall increase in the clinical demand for high-quality imaging. If multiple joints are affected, MRI of all the affected joints should be performed. However, these studies are time-consuming and expensive. Children need to lie still during the study, which is not always feasible for them; therefore, an alternative study is proposed. Currently, MRI of the whole body is widely used according to the protocol. Whole-body MRI is a diagnostic technique that allows for images of the entire body to be obtained in a single scan. There is no standard protocol for examining full-body MRIs in patients with JIA. Various pulse sequences are used for this purpose. The examination can be performed in the sagittal, coronal, and axial planes with or without contrast. Whole-body MRI can play an important role in assessing both active and asymptomatic joints for effusion, especially in areas that are not readily accessible to clinical methods (temporomandibular joint and sacroiliac joint) [19,31].



### Composite MRI and Hybrid Imaging (PET-MRI)

PET imaging with  $^{18}\text{F}$ -fluorodeoxyglucose or  $^{18}\text{F}$ -fluoride can show the active metabolism in the articular and periarticular tissues, allowing for the assessment of metabolic activity in the course of JIA. In this case, PET may be useful for evaluating active synovitis, which demonstrates the abnormally high activity of radiotracers. The main limitation of PET imaging (limited anatomical resolution) can be overcome by deploying hybrid PET/MRI, which can be used to assess the early metabolic and morphological markers of OA of the knee. Bone lesions, including bone marrow lesions, osteophytes, and subchondral sclerosis, also show hypermetabolism compared with normal bone on MRI [32,33]. However, to date, hybrid PET/MRI for OA imaging has not been used clinically; it is only used in clinical trials and requires further research [34].

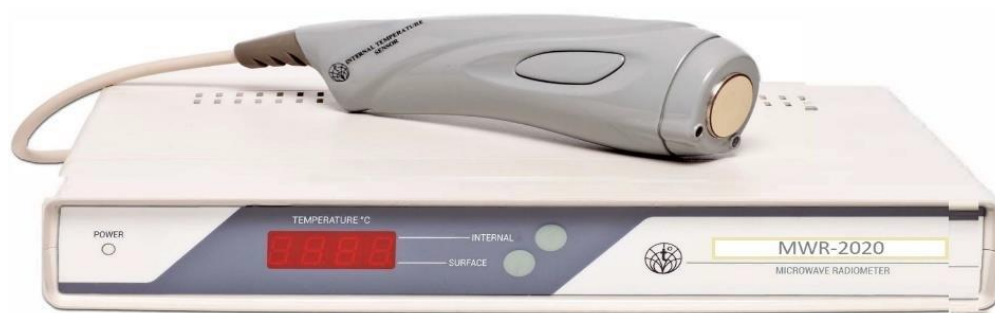Diffusion-weighted imaging (DWI) is an MRI technique based on the measurement of the random Brownian motion of water molecules in a tissue voxel [35]. DWI in JIA is a non-invasive functional imaging modality for detecting synovial inflammation without intravenous contrast. DWI parameters make it possible to distinguish active from inactive JIA [35]. Avoiding intravenous gadolinium-based contrast agents (GBCAs) has several practical benefits for children, as it prolongs the examination time and increases the patient's discomfort. The development of non-contrast approaches is even more attractive considering that the data show that the deposition of gadolinium occurs in the human brain after the repeated administration of GBCA [36].

In vivo optical imaging is a novel approach in the field of imaging chronic inflammatory arthritis. Fluorescent optical imaging (FOI) measures the specific absorption of light passing through tissues by the blood. FOI with indocyanine green enhancement proved to be as sensitive as ultrasound and MRI in detecting joint inflammation in the wrists of patients with JIA. The advantage of this method is the possibility of examining all the joints of both hands in a relatively short time (up to 6 min). However, the reliability and validity of this method have not been sufficiently tested, and the differentiation between synovitis and tenosynovitis remains a problem. Optical scattering limits the imaging depth to less than a few millimeters below the tissue surface, limiting its application to superficial joints [37].

The main goal of JIA is to improve long-term results through the early detection and treatment of disease activity and the identification of children who are at risk of joint destruction and poor functional outcomes. This requires an accurate and sensitive diagnosis of synovitis, which is a sign of disease activity. Modern diagnostic imaging methods do not provide a full-fledged answer for the assessment of the topic, onset, degree, and prognosis of the inflammatory process. In this regard, a broader multifactorial approach to diagnosis involving other methods is required. Simultaneously, an analysis of the literature shows that the method should be informative, provide new data, and not be burdensome for the child.

### 2.4. Passive Microwave Radiometry (MWR)

An analysis of the literature and our own research has identified a relatively new but little developed method for JIA using MWR. Recently, the MWR method of functional diagnostics has begun to spread widely, which consists of the dynamic mapping of physical fields and radiation from the human body and the method of MWR using MWR-2020 (former RTM-01-RES) or similar devices. MWR-2020 ([www.mmwr.co.uk](http://www.mmwr.co.uk), accessed on 1 May 2020) measures the intensity of passive thermal radiation in microwave and infrared (IR) frequencies (Figure 1).



**Figure 1.** MWR2020 (former RTM-01-RES).

The spatial representation of the temperature distribution using MWR and IR inside and on the surface of the body helps to determine the zone of the pathological process and possibly its qualitative properties [38,39]. The essence of the biophysical noninvasive method of MWR is to measure the intrinsic electromagnetic radiation of internal tissues and to identify temperature anomalies of the internal tissues of the body and skin [34]. The methods for detecting skin temperature have a long history. However, individual skin temperature values fluctuate widely, which often leads to diagnostic errors. In recent years, methods have been developed for measuring the temperature distribution from the surface to the interior of the body, with the detection of the internal temperature profile [40,41]. The ambient temperature is of great methodological importance for the accurate measurement of the depth temperature [42]. The method has several positive properties: no radiation exposure; the ability to carry out multiple measurements; non-invasiveness; high sensitivity, which allows for the detection of pathology at the preclinical stage; the simplicity and compactness of the equipment; the clarity of the results; and no contraindications [43,44].

The rationale for using MWR is the increase in temperature during inflammation. The development of chronic inflammation in JIA is mediated by various disorders of the immune system. The inflammation correlates with changes in the synthesis of a significant spectrum of immune mediators and cytokines. At the same time, proinflammatory cascades of cytokines in different forms of the disease often differ [45]. The use of MWR in JIA involves the search for a local inflammatory process because of the biochemical processes of local, complex vascular-mesenchymal tissue reactions in response to injury.

The inflammatory process, including immunopathological a priori, as a rule, has a higher temperature than those of the surrounding tissues. This does not depend on the etiological factor but may depend on the time of inflammation and the predominance of the exudative or proliferative process. The reactivity of an organism can also be a significant factor.

Systemic signs are recorded using clinical, biochemical, immunological, and other methods. As a rule, local temperature changes precede structural changes. Therefore, in a clinically inactive state, it is possible to visually assess the presence or absence of an inflammatory process in the osteoarticular system (e.g., synovitis, tenosynovitis, and enthesitis).

JIA is characterized by a chronic non-suppurative inflammatory process of the synovial membrane. The morphological substrate of arthritis manifestations, especially those associated with enthesitis, is an inflammatory fibrosing process with primary localization in tendon-ligamentous structures, its attachment points to the bone, and the synovial membrane of the joints with further lymphoid infiltration and hyperplasia [46,47].

There are few studies on the use of MWR in JIA, particularly in adult patients. The emergence of research has depended significantly on new equipment and computers. For example, as early as 1987, a strong correlation was found between the microwave thermographic index and the measured clinical and laboratory parameters in a study that scanned 52 knees. This method has been proven to be reproducible, fast, and easy to use at the bedside without a controlled environment, but it has not been clinically followed up [48].

One of the first clinical studies was an article in which the concept that an elevated local temperature reflects subclinical inflammation of the synovium was tested using MWR. The ultrasound method was used as a reference method, as there was a possible presence of fluid and/or synovitis. The knees of healthy controls, patients with a recent knee injury, and patients without symptoms of RA or osteoarthritis were examined. Two radio antenna settings were used: in the upper third of the anterior surface of the thigh (control point) and above the patella. The main conclusion of this study was that thermal changes in the knee joint may reflect non-clinically pronounced joint inflammation [49].

In the next study, the aim was to establish a correlation between the depth temperature of small joints, which was obtained using the MWR method, and the parameters commonly used to assess disease activity in RA. Clinical and laboratory examinations, as well as the ultrasound examination of joints and MWR of small joints of the hands and feet at baseline and 15, 30, and 90 days after the start of treatment, were performed in 10 patients with active RA without treatment.

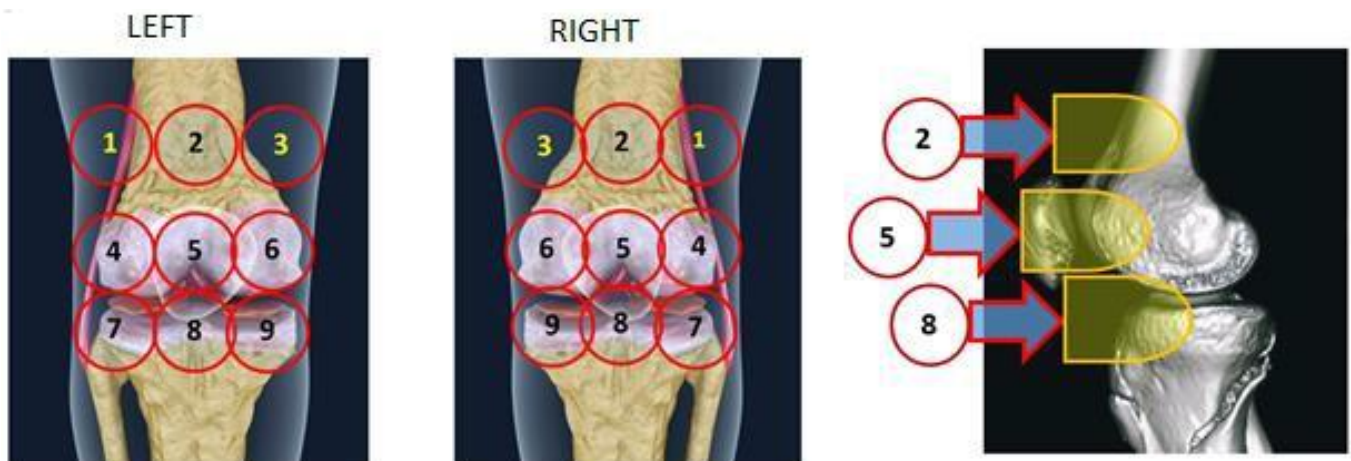
The control subjects included 20 healthy individuals of the same age and sex. We used 1248 individual MWR images from 16 patient joints. It has been established that an increased depth temperature obtained with RTM, indicating the local inflammation of small joints, can serve as an additional RA biomarker [50].

After propaedeutic work on MWR, the authors studied 82 patients with RA and 23 healthy individuals of the same age and sex. Clinical and laboratory studies and ultrasound examinations of the joints were performed. Twenty-one patients were re-examined 2 months after treatment initiation. A decrease in temperature was observed at points that were previously hotter ( $\Delta t$  represents the difference between the temperatures of predetermined joint points). The thermal score was created by summing the temperature values of the seven small joints of the hand, elbow, knee, and lower leg and the clinically dominant upper and lower limbs. The conclusion of this study was as follows: the elevated joint temperature detected by MWR is well suited for detecting inflammation of the knee joint in RA. This method makes it possible to distinguish between the stages of disease activity and mirror the changes in the disease activity caused by treatment [50].

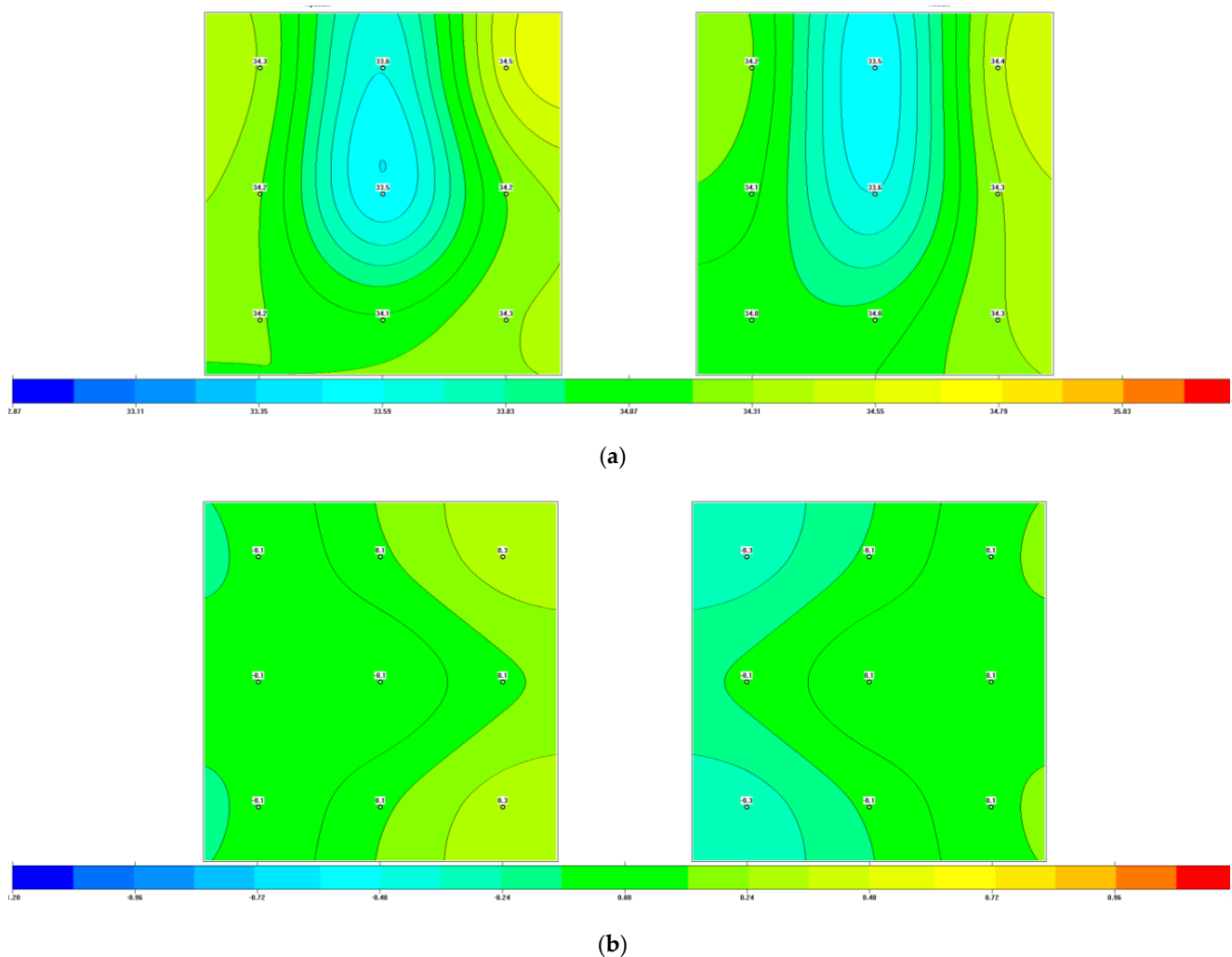
In their work, the team of authors (Laskari et al., 2019) suggested that an elevated joint temperature measured using a fast and easy-to-perform MWR method may reflect inflammation even in the absence of clinical signs. The group of patients ( $n = 243$ ) included those with RA and spondyloarthritis. Parallel studies using clinical examination, ultrasound examination of the joints, and/or MRI have established that a deep increase in the temperature of the joints using MWR reflects both subclinical and clinically evident inflammation and can serve as a biomarker of arthritis [51].

Studies on the application of the MWR method in pediatric patients have since been conducted. The MWR method was used to determine the depth and skin temperatures in the projection of the knee joints in healthy children aged 8–12 years for comparative analysis. This study included girls ( $n = 22$ , age  $10.0 \pm 0.3$  years) and boys ( $n = 21$ , age  $10.1 \pm 0.3$  years). During treatment, children aged 6–17 years ( $n = 43$ ) in the clinic with a diagnosis of JIA were examined. Standards for the depth temperature in the knee joints of healthy children were established, depending on the measurement zone. It was also shown that the  $\Delta T = t_{\max} - t_{\min}$  of the depth temperature in the norm was  $1.5\text{--}1.6^\circ\text{C}$ , and that of the skin was  $1.4\text{--}1.7^\circ\text{C}$ . It was found that the temperature field of the skin under normal conditions practically repeats the pattern of the deep temperature field; the lowest temperature was noted above the patella. Clinical visual assessment of the temperature data provides an instant idea of thermal asymmetry. MWR allows for the comparison of the indicators of children with JIA (knee joints) with those of healthy children, assessing the thermal asymmetry of depth and skin temperatures by fields and fields of temperature difference and thermograms of internal and skin temperatures (Figure 2, Figure 3a,b and Figure 4a–c) [52].

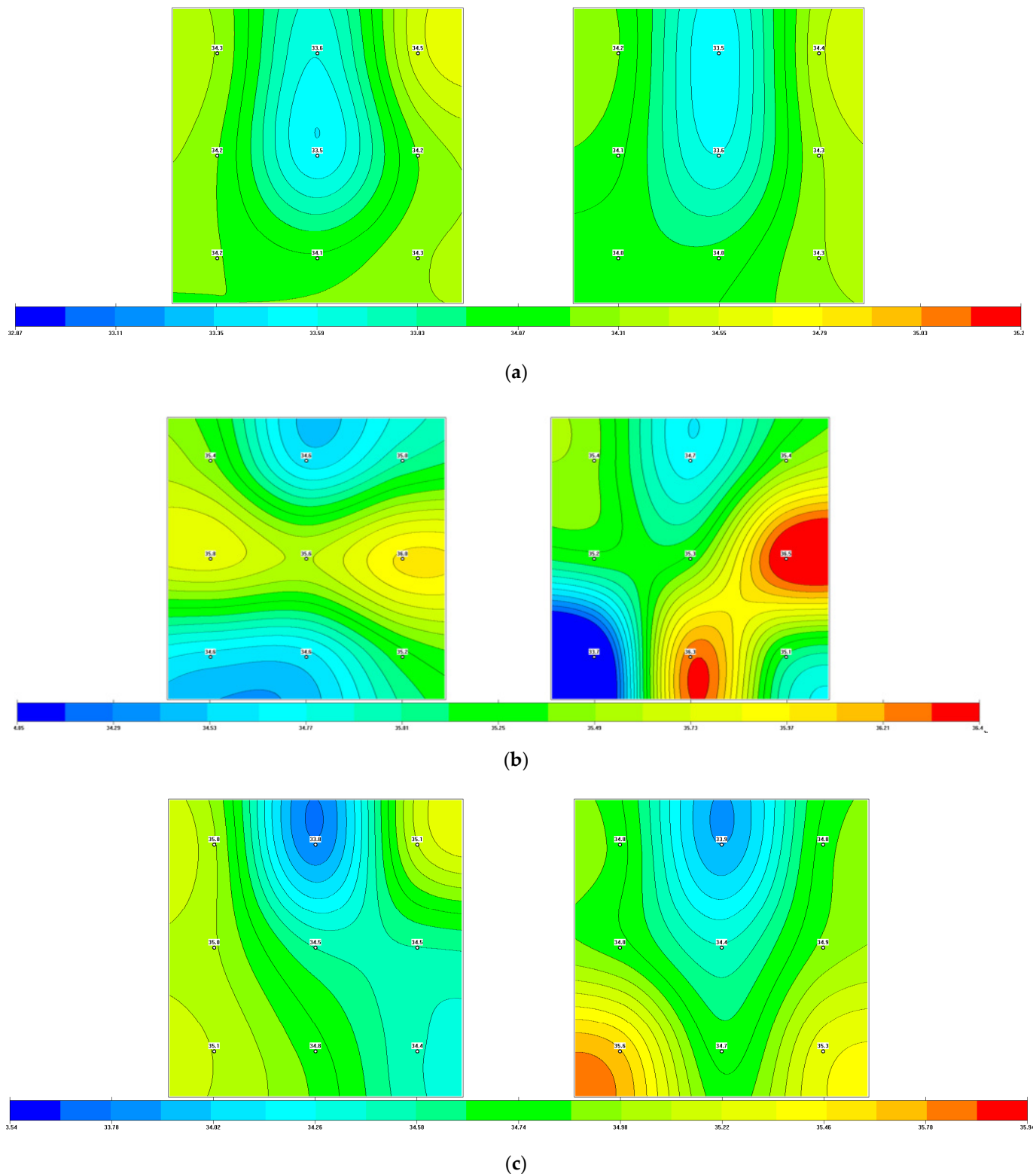




**Figure 2.** Scheme of the study and setting of the MWR sensor and internal temperature measurement by the MWR of the anterior region of the knee joints [52] Numbers represent measurement points.



**Figure 3.** MWR internal temperature (averaged,  $n = 43$ ) of knee joints in children (8–12 years old); deep temperature fields (a), deep temperature difference fields (b) [52].



**Figure 4.** Internal temperature fields: (a) an 11-year-old MWR healthy patient; diagnosis: juvenile idiopathic arthritis; the polyarticular variant with eye involvement (uveitis in remission); degree of activity I; X-ray stage II; functional class I. (b) MWR 6 months after the onset of the disease and (c) 9 months after the first MWR and after treatment [52].

### 3. Discussion

Modern imaging plays a major role in confirming the diagnosis and monitoring the disease activity, prognosis, and outcome of JIA in children. However, each method has its advantages and disadvantages (see Table 1).

**Table 1.** Visualization methods comparison.

Method	Passive	Cost	Structural Visualization	Visualization of Internal Temperature	Side Effects	Early Diagnosis JIA	Portability
Radiography	No	Medium	Yes	No	Yes	No	No
Ultrasound	Yes	Low	Yes	No	No	Yes	Yes
MRI	Yes	Medium	Yes	No	Yes	Yes	No
MRI-PET	No	High	Yes	No	Yes	Yes	No
MWR	Yes	Low	No	Yes	No	Yes	Yes

When using MWR in clinical practice, it is necessary to follow the methodological recommendations, which include: the physiological position of the joint during the study, the optimal temperature in the room, and the adaptation of the joint under study to the external temperature.

First, the temperature fields of symmetrical zones are determined, which makes it possible to reveal the temperature asymmetry and determine the side of the anomaly. It is desirable to highlight the maximum and minimum temperatures and their difference, which increase or decrease depending on the pathology, as in the brain [53] or venous diseases [54]. With the simultaneous measurement of MWR and IR temperatures in case of a disease, the correlations between them decrease.

### 4. Conclusions

The above-mentioned visualization methods mostly show a morphological picture of inflammatory and destructive processes. At the same time, a change in internal temperature is one of the earliest signs of almost any inflammation. It would be beneficial to combine imaging methods with MWR as an accessible, easy, and independent method for the early detection of an inflammatory process in soft tissues. MWR can determine the development of early inflammation, objectively assess the severity of inflammatory processes in arthritis of various origins, including JIA, and control the effectiveness of the therapy in a timely manner.

The correlation between MWR, ultrasound, MRI, biochemical, immunological, and clinical data requires further study.

**Author Contributions:** Conceptualization, A.V.T. and T.D.T.; writing—original draft preparation, A.V.T., E.S.L., A.A.L. and T.D.T.; writing—review and editing, I.I.G. and T.K.; supervision, A.V.T., S.G.V. and I.I.G.; project administration, A.V.T. All authors have read and agreed to the published version of the manuscript.

**Funding:** This research received no external funding.

**Institutional Review Board Statement:** Not applicable.

**Informed Consent Statement:** Not applicable.

**Data Availability Statement:** Not applicable.

**Conflicts of Interest:** The authors declare no conflict of interest.

## References

1. Ravelli, A. *Handbook of Juvenile Idiopathic Arthritis*, 1st ed.; Springer International Publishing: Cham, Switzerland, 2016; 132p, ISBN 103319081012. [\[CrossRef\]](#)
2. Ravelli, A.; Martini, A. Juvenile Idiopathic Arthritis. *Lancet* **2007**, *369*, 767–778. [\[CrossRef\]](#)
3. Petty, R.E.; Cassidy, J.T. Chronic arthritis in childhood. In *Textbook of Pediatric Rheumatology Cassidy*, 6th ed.; Cassidy, J.T., Petty, R.E., Laxer, R.M., Lindsley, C.B., Eds.; Elsevier Saunders: Philadelphia, PA, USA, 2011; pp. 211–235.
4. Szer, I.S.; Kimura, Y.; Malleson, P.N.; Southwood, T.R. (Eds.) *Arthritis in Children and Adolescents: Juvenile Idiopathic Arthritis*; Oxford University Press: New York, NY, USA, 2006; 456p.
5. Schwartz, M.M.; Simpson, P.; Kerr, K.L.; Jarvis, J.N. Juvenile rheumatoid arthritis in African Americans. *J. Rheumatol.* **1997**, *24*, 1826–1829. [\[PubMed\]](#)
6. Prakken, B.; Albani, S.; Martini, A. Juvenile Idiopathic Arthritis. *Lancet* **2011**, *377*, 2138–2149. [\[CrossRef\]](#)
7. Alekseeva, E.I. Juvenile idiopathic arthritis: Clinical presentation, diagnosis, treatment. *Quest. Mod. Pediatr.* **2015**, *14*, 78–94.
8. Malattia, C.; Rinaldi, M.; Martini, A. The role of imaging in juvenile idiopathic arthritis. *Expert Rev. Clin. Immunol.* **2018**, *14*, 681–694. [\[CrossRef\]](#)
9. Teh, J.; Stergaard, M. What the Rheumatologist Is Looking for and What the Radiologist Should Know in Imaging for Rheumatoid Arthritis. *Radiol. Clin. North Am.* **2017**, *55*, 905–916. [\[CrossRef\]](#)
10. Torosyan, G.G.; Zholobova, E.S.; Glazyrina, A.A.; Koltunov, I.E. Difficulties in the diagnosis of systemic juvenile idiopathic arthritis. *Pediatrics* **2016**, *95*, 162–165.
11. Igisheva, L.N.; Pritchina, S.S.; Bykova, Y.A.; Anikeenko, A.A. Juvenile arthritis: Diagnosis and treatment. *Mother Child Kuzbass* **2017**, *1*, 48–61.
12. Crayne, C.B.; Beukelman, T. Juvenile Idiopathic Arthritis Oligoarthritis and Polyarthritis. *Pediatr. Clin. N. Am.* **2018**, *65*, 657–674. [\[CrossRef\]](#)
13. Union of Pediatricians of Russia. Juvenile arthritis: Clinical guidelines. *Clin. Guidel.* **2017**, *8*, 24–28.
14. Nusman, C.M.; de Horatio, L.T.; Hemke, R.; van Gulik, E.C.; Müller, L.-S.O.; Malattia, C.; Avenarius, D.; Toma, P.; Roth, J.; Tzaribachev, N.; et al. Imaging in juvenile idiopathic arthritis-international initiatives and ongoing work. *Pediatr. Radiol.* **2018**, *48*, 828–834. [\[CrossRef\]](#) [\[PubMed\]](#)
15. Kozhevnikov, A.N.; Pozdeeva, N.A.; Konev, M.A.; Maricheva, O.N.; Afonichev, K.A.; Novik, G.A. X-ray diagnosis of juvenile chronic oligoarthritis. *Bull. Sib. Med.* **2017**, *16*, 224–234. [\[CrossRef\]](#)
16. Naredo, E.; D’Agostino, M.A.; Wakefield, R.J.; Möller, I.; Balint, P.V.; Filippucci, E.; Iagnocco, A.; Karim, Z.; Terslev, L.; Bong, D.A.; et al. OMERACT Ultrasound Task Force\*. Reliability of a consensus-based ultrasound score for tenosynovitis in rheumatoid arthritis. *Ann. Rheum. Dis.* **2013**, *72*, 1328–1334. [\[CrossRef\]](#) [\[PubMed\]](#)
17. Hemke, R.; Tzaribachev, N.; Barendregt, A.M.; Merlijn van den Berg, J.; Dori, A.S.; Maas, M. Imaging of the knee in juvenile idiopathic arthritis. *Pediatr. Radiol.* **2018**, *48*, 818–827. [\[CrossRef\]](#) [\[PubMed\]](#)
18. Barut, K.; Adrovic, A.; Şahin, S.; Kasapçopur, Ö. Juvenile Idiopathic Arthritis. *Balkan Med. J.* **2017**, *34*, 90–101. [\[CrossRef\]](#)
19. Christos, D.; Boitsios, G.; Badot, V.; Lê, P.-Q.; Goffin, L.; Simoni, P. Imaging of Juvenile Idiopathic Arthritis. *Radiol. Clin. N. Am.* **2017**, *55*, 1071–1083. [\[CrossRef\]](#)
20. Magni-Manzoni, S. Ultrasound in juvenile idiopathic arthritis. *Pediatr. Rheumatol. Online J.* **2016**, *14*, 33. [\[CrossRef\]](#)
21. Sudół-Szopińska, I.; Schueller-Weidekamm, C.; Plagou, A.; Teh, J. Ultrasound in Arthritis. *Radiol. Clin. N. Am.* **2017**, *55*, 985–996. [\[CrossRef\]](#)
22. Alekseev, D.L.; Nikishina, I.P. Ultrasound examination of the musculoskeletal system in the diagnosis and monitoring of disease activity in juvenile arthritis. *Rheumatol. Sci. Pract.* **2017**, *55*, 647–654. [\[CrossRef\]](#)
23. Traudt, A.K.; Zavadovskaya, V.D.; Zhogina, T.V.; Fedorova, E.I. Magnetic resonance imaging in the diagnosis of juvenile arthritis. *Bull. Sib. Med.* **2015**, *1*, 110–119. [\[CrossRef\]](#)
24. Burge, A.J.; Nwawka, O.K.; Berkowitz, J.L.; Potter, H.G. Imaging of Inflammatory Arthritis in Adults: Status and Perspectives on the Use of Radiographs, Ultrasound, and MRI. *Rheum. Dis. Clin. North Am.* **2016**, *42*, 561–585. [\[CrossRef\]](#) [\[PubMed\]](#)
25. Cherkasova, I.A. Radiation methods of research in the diagnosis of juvenile rheumatoid arthritis. In *Innovative Medical Technologies Sat. Scientific Papers*; Chirkova, N.S., Zhukov, S.V., Eds.; Tver Regional Public Movement to Support Young Scientists: Tver, Russia, 2019; pp. 77–79.
26. Reijnierse, M.; Van der Helm-Mil, A.; Eshed, I.; Schueller-Weidekamm, C. Magnetic Resonance Imaging of Rheumatoid Arthritis: Peripheral Joints and Spine. *Semin. Musculoskelet Radiol.* **2018**, *22*, 127–146. [\[CrossRef\]](#) [\[PubMed\]](#)
27. Hemke, R.; van den Berg, J.M.; Nusman, C.M.; van Gulik, E.C.; Barendregt, A.M.; Schonenberg-Meinema, D.; Dolman, K.M.; Kuijpers, T.W.; Maas, M. Contrast-enhanced MRI findings of the knee in healthy children; establishing normal values. *Eur. Radiol.* **2018**, *28*, 1167–1174. [\[CrossRef\]](#)

28. van Gulik, E.C.; Welsink-Karssies, M.M.; Berg, J.M.V.D.; Schonenberg-Meinema, D.; Dolman, K.M.; Barendregt, A.M.; Nusman, C.M.; Maas, M.; Kuijpers, T.W.; Hemke, R. Juvenile idiopathic arthritis: Magnetic resonance imaging of the clinically unaffected knee. *Pediatr. Radiol.* **2018**, *48*, 333–340. [[CrossRef](#)] [[PubMed](#)]
29. Nusman, C.M.; Hemke, R.; Benninga, M.A.; Schonenberg-Meinema, D.; Kindermann, A.; Van Rossum, M.A.J.; Berg, J.v.D.; Maas, M.; Kuijpers, T.W. Contrast-enhanced MRI of the knee in children unaffected by clinical arthritis compared to clinically active juvenile idiopathic arthritis patients. *Eur. Radiol.* **2018**, *26*, 1141–1148. [[CrossRef](#)]
30. Nusman, C.M.; Hemke, R.; Schonenberg, D.; Dolman, K.M.; van Rossum, M.A.; Berg, J.M.V.D.; Kuijpers, T.W.; Maas, M. Distribution pattern of MRI abnormalities within the knee and wrist of juvenile idiopathic arthritis patients: Signature of disease activity. *AJR Am. J. Roentgenol.* **2014**, *202*, W439–W446. [[CrossRef](#)]
31. Razinova, A.A.; Pozdnyakova, O.F.; Masalova, V.V.; Pozdnyakov, A.V. Magnetic resonance imaging according to the WHOLE BODY protocol in children: Clinical application (literature review). *Vis. Med.* **2020**, *2*, 3–15.
32. Kogan, F.; Fan, A.; McWalter, E.J.; Oei, E.H.G.; Quon, A.; Gold, G.E. PET/MRI of metabolic activity in osteoarthritis: A feasibility study. *J. Magn. Reson. Imaging* **2017**, *45*, 1736–1745. [[CrossRef](#)]
33. Tibrewala, R.; Bahroos, E.; Mehrabian, H.; Foreman, S.C.; Link, T.M.; Padoia, V.; Majumdar, S. [<sup>18</sup>F]-sodium fluoride PET/MR imaging for bone-cartilage interactions in hip osteoarthritis: A feasibility study. *J. Orthop. Res.* **2019**, *37*, 2671–2680. [[CrossRef](#)]
34. Hayashi, D.; Roemer, F.W.; Guermazi, A. Imaging of osteoarthritis by conventional radiography, MR imaging, PET-CT, and PET-MR imaging. *Pet. Clin.* **2019**, *14*, 17–29. [[CrossRef](#)]
35. Barendregt, A.M.; van Gulik, E.C.; Lavini, C.; Nusman, C.M.; Berg, J.v.D.; Schonenberg-Meinema, D.; Dolman, K.M.; Kuijpers, T.W.; Hemke, R.; Maas, M. Diffusion-weighted imaging for assessment of synovial inflammation in juvenile idiopathic arthritis: A promising imaging biomarker as an alternative to gadolinium-based contrast agents. *Eur. Radiol.* **2017**, *27*, 4889–4899. [[CrossRef](#)] [[PubMed](#)]
36. Roberts, D.R.; Welsh, C.A.; Davis, W.C. Gadolinium Deposition in the Pediatric Brain. *JAMA Pediatr.* **2017**, *171*, 1229. [[CrossRef](#)] [[PubMed](#)]
37. Klein, A.; Just, G.W.; Werner, S.G.; Oommen, P.T.; Minden, K.; Becker, I.; Langer, H.E.; Klee, D.; Horneff, G. Fluorescence optical imaging and musculoskeletal ultra-sonography in juvenile idiopathic polyarticular disease before and during antirheumatic treatment—a multicenter non-interventional diagnostic evaluation. *Arthritis Res. Ther.* **2017**, *19*, 147. [[CrossRef](#)]
38. Vaysblat, A.V. *Radio Thermography as a Diagnostic Method in Medicine*; RAMS: Moscow, Russia, 2003; p. 67.
39. Losev, A.G.; Khoperskov, A.V.; Astakhov, A.S.; Suleimanova, H.M. Problems of measurement and modeling of thermal and radiation fields in biological tissues: Analysis of microwave thermometry data. *Vestnik Volgogr. Gos. Univ. Seriya 1. Math. Phys* **2015**, *6*, 31–71. [[CrossRef](#)]
40. Goryanin, I.; Karbainov, S.; Shevelev, O.; Tarakanov, A.; Redpath, K.; Vesnin, S.; Ivanov, Y. Passive microwave radiometry in biomedical studies. *Drug Discov. Today* **2020**, *25*, 757–763. [[CrossRef](#)] [[PubMed](#)]
41. Tarakanov, A.V.; Tarakanov, A.A.; Vesnin, S.; Efremov, V.V.; Roberts, N.; Goryanin, I. Influence of ambient temperature on recording of skin and deep tissue temperature in region of lumbar spine. *Eur. J. Mol. Clin. Med.* **2020**, *7*, 21–26. [[CrossRef](#)]
42. Tarakanov, A.V.; Efremov, V.V.; Tarakanov, A.A. Microwave radiometry for pain in the lumbar spine. Application prospects. *Methods Assess. Diagn. Chronic Pain Cock-Roaches. Russ. J. Pain* **2016**, *2*, 113–114.
43. Tarakanov, A.V.; Tarakanov, A.A.; Vesnin, S.; Efremov, V.V.; Goryanin, I.; Roberts, N. Microwave Radiometry (MWR) temperature measurement is related to symptom severity in patients with Low Back Pain (LBP). *J. Bodyw. Mov. Ther.* **2021**, *26*, 548–552. [[CrossRef](#)]
44. Chernyshova, O.Y.; Konyushevskaya, A.A.; Vayzer, N.V.; Balychevtseva, I.V. Juvenile arthritis: Etiology, pathogenesis, modern aspects (literature review). *Trauma* **2018**, *2*, 99–105. [[CrossRef](#)]
45. Serebrennikova, S.N.; Semensky, I.Z. *Pathophysiology of the Inflammatory Process. Tutorial*; ISMU: Irkutsk, Italy, 2014; 73p.
46. Alekseeva, E.I.; Litvitsky, P.F. *Juvenile Rheumatoid Arthritis: Etiology, Pathogenesis, Clinic, Diagnostic and Treatment Algorithm: Hands for Doctors, Teachers, Researchers*; Baranov, A.A., Ed.; VEDI: Moscow, Russia, 2007; 368p, ISBN 978-5-94624-035-2.
47. Fraser, S.M.; Land, D.V.; Sturrock, R.D. Microwave thermography in rheumatic disease. *Eng. Med.* **1987**, *16*, 209–212. [[CrossRef](#)]
48. Zampeli, E.; Raftakis, I.; Michelongona, A.; Nikolaou, C.; Elezoglou, A.; Toutouzas, K.; Siores, E.; Sfrikakis, P.P. Detection of Sub-clinical Synovial Inflammation by Microwave Radiometry. *PLoS ONE* **2013**, *8*, e64606. [[CrossRef](#)] [[PubMed](#)]
49. Pentazos, G.; Laskari, K.; Prekas, K.; Raftakis, J.; Sfrikakis, P.P.; Siores, E. Microwave. Thermal, R.-D. Changes of Small Joints as Additional Potential Biomarker in Rheumatoid Arthritis: A Prospective Pilot Study. *J. Clin. Rheumatol.* **2018**, *24*, 259–263. [[CrossRef](#)] [[PubMed](#)]
50. Laskari, K.; Pentazos, G.; Konstantonis, G.; Tektonidou, M.; Siores, E.; Sfrikakis, P. Microwave Radiometry As a Novel Additional Method for Rheumatoid Arthritis Disease Activity Assessment: A Prospective Single-Center Study. *Arthritis Rheumatol.* **2018**, *70*. Available online: <https://acrab-stracts.org/abstract/microwave-radiometry-as-a-novel-additional-method-for-rheumatoid-arthritis-disease-activity-assessment-a-prospective-single-center-study> (accessed on 12 February 2022).
51. Laskari, K.; Pentazos, G.; Pitsilka, D.; Raftakis, J.; Konstantonis, G.; Toutouzas, K.; Siores, E.; Tektonidou, M.; Sfrikakis, P. Joint radiometry for inflammatory arthritis assessment. *Rheumatology* **2020**, *59*, 839–844. [[CrossRef](#)]
52. Tarakanov, A.V.; Lebedenko, A.A.; Ladanova, E.S.; Tarakanova, T.D. Prospects for the use of microwave radiometry of the knee joints in children with juvenile idiopathic arthritis. *Mod. Probl. Sci. Educ.* **2020**, *5*, 88. [[CrossRef](#)]



- 
53. Shevelev, O.; Petrova, M.; Smolensky, A.; Osmonov, B.; Toimatov, S.; Vesnin, S.; Goryanin, I. Using medical microwave radiometry for brain temperature measurements. *Drug Discov. Today* **2022**, *3*, 881–889. [[CrossRef](#)] [[PubMed](#)]
  54. Levshinskii, V.; Galazis, C.; Losev, A.; Zamechnik, T.; Kharybina, T.; Vesnin, S.; Goryanin, I. Using AI and passive medical radiometry for diagnostics (MWR) of venous diseases. *Comput. Methods Programs Biomed.* **2022**, *215*, 106611. [[CrossRef](#)]