

Case Report

Severe Post-Traumatic Trismus Unresponsive to Drug Therapy in a 12-Year-Old Patient Treated with a Capacitive-Resistive Electrical Transfer Therapy: A Case Report

Giuseppe Campanella ^{1,*}, Giulia Artuso ², Martina Salvatorina Murgia ³, Germano Orrù ³ and Cinzia Casu ^{3,*} 

¹ Private Dental Practice, 08030 Nuragus, Italy

² Department of Dental Clinic, Vita-Salute San Raffaele University, 20019 Milano, Italy; giulia.artuso94@gmail.com

³ Department of Surgical Science, Oral Biotechnology Laboratory, University of Cagliari, 09121 Cagliari, Italy; martina.murgia.s@gmail.com (M.S.M.); gerorru@gmail.com (G.O.)

* Correspondence: pippocamp70@yahoo.it (G.C.); ginzia.85@hotmail.it (C.C.)

Abstract: (1) Background: Trismus clinically manifests as a reduction of the buccal opening and restricted mouth opening due to different etiologies, but it is often associated with traumatic phenomena. Several treatments have been proposed such as physiotherapy exercises, cryotherapy, laser therapy, hyaluronic acid and platelet-rich fibrin infiltration, but the gold standard is represented by drug therapy based on corticosteroids and NSAIDs, currently the most documented in the scientific literature. Capacitive-resistive electric transfer (Cret) therapy is used to treat musculoskeletal injuries. Cret is a non-invasive electrothermal treatment classified as deep thermo-therapy. (2) Patient: We would like to document a case of particularly traumatic trismus in a 12-year-old patient, not responsive to previous pharmacological therapy and treated with a radiofrequency device called Velvet temporomandibular joint (TMJ). Five capacitive and resistive diathermy sessions with the device were performed. The first four sessions were performed every 4 days and the fifth after 5 days. (3) Result: The maximum opening of the mouth was 10 mm at the initial stage and 38 mm at the end of the six sessions. Pain regressed after the second appointment. (4) Conclusions: Clinical studies with a good number of samples need to be conducted to evaluate the effectiveness of this device which has proved to be an excellent treatment for this refractory case to conventional therapies. Finally, it may be useful to define precise and replicable protocols to make this therapy suitable for patients with TMJ disorders.

Keywords: alternative treatment; closed lock; TMD; trismus



Citation: Campanella, G.; Artuso, G.; Murgia, M.S.; Orrù, G.; Casu, C. Severe Post-Traumatic Trismus Unresponsive to Drug Therapy in a 12-Year-Old Patient Treated with a Capacitive-Resistive Electrical Transfer Therapy: A Case Report. *Oral* **2022**, *2*, 173–181. <https://doi.org/10.3390/oral2020017>

Academic Editor: Alberto Bedogni

Received: 28 December 2021

Accepted: 11 April 2022

Published: 16 May 2022

Publisher's Note: MDPI stays neutral with regard to jurisdictional claims in published maps and institutional affiliations.



Copyright: © 2022 by the authors. Licensee MDPI, Basel, Switzerland. This article is an open access article distributed under the terms and conditions of the Creative Commons Attribution (CC BY) license (<https://creativecommons.org/licenses/by/4.0/>).

1. Introduction

Trismus has a Greek etymology (its meaning is in fact “grind”) and refers to a reduced opening of the oral cavity. It is typically caused by a contracture of the chewing muscles. Initially described as a tetanic condition, today it is recognized as a multifactorial etiology [1]. It can be unilateral or bilateral. In most cases, trismus resolves within a limited time, usually within two weeks. However, it can also be permanent. This pathological condition can limit several functions including swallowing, speaking and chewing [2,3]. This condition is often associated with inflammatory, neoplasms, arthritic disease and traumatic phenomena, including extractive surgery of the lower third molars, but it can be associated more generally with an excessive opening of the mouth [4]. Other factors that can lead to trismus are radiotherapy (oral mucositis) and the apposition of collagen fibers between muscle tissues in patients with submucosal fibrosis [5,6]. Several therapies have been proposed to treat this phenomenon: physiotherapy exercises, cryotherapy, laser therapy [7–9], hyaluronic acid [4] and platelet-rich fibrin infiltration [10]. Particularly, regarding the efficacy of cryotherapy, a recent systematic review suggests that it may have

a small additional benefit in reducing pain after surgical avulsion of third molars but is not effective on facial swelling and trismus [7]. Gondivkar et al. highlight that laser therapy can be useful for relieving trismus related to oral submucous fibrosis despite a great heterogeneity of the parameters used in the literature [9]. Drug therapy based on corticosteroids and NSAIDs is currently the most documented in the scientific literature [11]. Another temporomandibular disorder that must be included in the differential diagnosis is closed lock. In fact, in this case there is also pain in the joint and masticatory muscles and reduced opening of the oral cavity, generally below 35 mm. What occurs is the displacement of the articular disc, most frequently in the antero-medial direction, without reduction [12]. Depending on the duration, closed block can be classified into chronic and acute. An interesting clinical aspect that should not be underestimated is that a limited number of patients have no clinical symptoms. This is due to a multifactorial etiology in which many other factors may predominate (size of the condyle head, glenoid fossa depth, eminence inclination) and inhibit symptoms [13].

Capacitive-resistive electrical transfer therapy (Cret) is used for musculoskeletal diseases. In particular, Cret is a non-invasive electrothermal treatment classified as deep heat therapy. Cret emits electric currents with radiofrequency between 300 kHz and 1.2 MHz. This causes overheating of the deep muscles so as to cause an increase in hemoglobin saturation, temperature, deep and superficial blood flow, cellular mitosis, vasodilation and elimination of exudative fluids. [14]. This type of treatment was successfully proposed for muscular problems in various body areas [15,16] but has never been documented for the treatment of trismus.

The aim of this work is to report a case of particular traumatic trismus which was unresponsive to previous pharmacological therapy and treated with a radiofrequency device called Velvet TMJ.

2. Case Presentation

A 12-year-old Caucasian patient came to our observation for a condition of severe inflammation and post-traumatic trismus. The anamnesis does not show any comorbidities, the patient is healthy and there are no pathologies in the family that may have influenced the disease for which the patient came in the first visit.

He reported the onset of severe constant bilateral pain in the TMJ, ears and face throughout the day and night. Even with pharmacological treatment (NSAIDs, steroids therapy, muscle relaxants) and several referrals, the pain had never regressed. Particularly, the drug therapy administered consisted of valium (5 drops, two or three times a day), methylprednisolone and triamcinolone (4 tablets a day) and ibuprofen 600 mg (2 tablets a day).

While under clinical observation we found an extremely reduced masticatory function with a mouth opening of about 1 cm (Figure 1a). A condition of subluxation of the condyle of the TMJ and a significant bilateral contracture of the masseters were diagnosed. An X-ray and ultrasound evaluation were prescribed. The latter report stated "The investigation bilaterally highlighted a modest thickening of the muscle-tendon bundle of the masseter and an inhomogeneous hypoechoic echo structure. Phlogosis of the temporomandibular ligament on the right and hypoechoicity of the meniscal cartilage as in the initial condition of meniscosis". As far as the etiology of the trismus is concerned, it is likely that it originated from an overload of the masticatory muscles, facilitated by the dento-skeletal class II and deep bite of the patient. Pain was assessed on the VAS scale, initially constant and equal to 10, slightly lower after taking non-steroidal anti-inflammatory drugs. The patient also reported ear pain, tightness and tension-type pain.

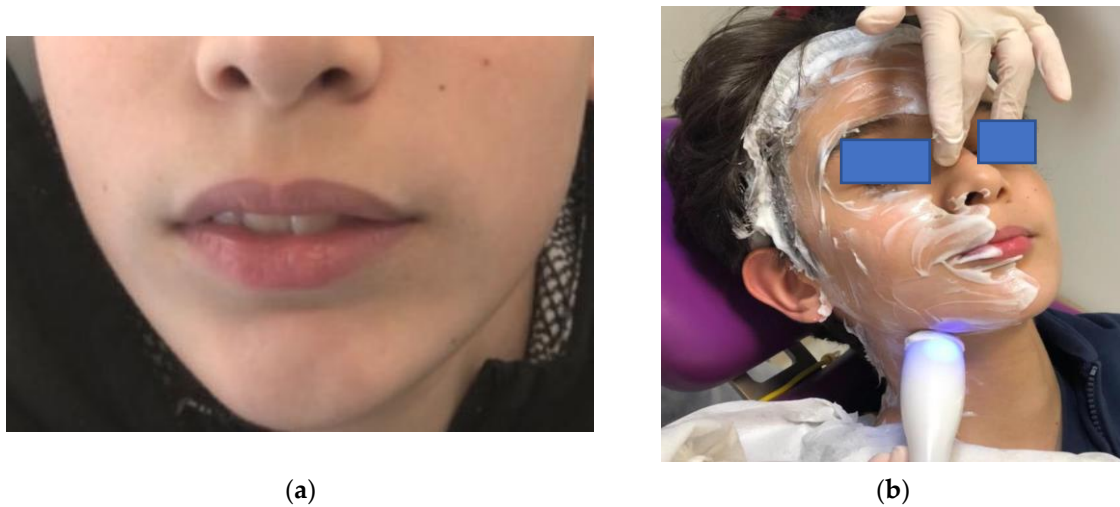


Figure 1. (a) Initial condition characterized by an extremely reduced masticatory function with a mouth opening of about 1 cm. (b) Application of cream with 80% aloe on face and neck and treatment with a dedicated intraoral handpiece (Velvet TMJ, Città di Castello, Italy).

We chose to avoid any other pharmacological or surgical therapy and to try to treat the condition with radiofrequency. Therefore, our aim was to evaluate the therapeutic outcomes of temporomandibular disorders treated with the radiofrequency device. Five capacitive and resistive diathermy sessions with Velvet TMJ were performed. The first four sessions were performed every 4 days and the fifth after 5 days. Each session lasted 14 min. A cream with 80% aloe was applied to the face and neck before treatment with a dedicated intraoral handpiece (Velvet TMJ, Città di Castello, Italy) (Figure 1b). The parameters used in the first appointment were: biostimulation with application of monopolar capacitive technique software muscle hypotonia, at 20% power for 6 min; biostimulation with application of bipolar resistive technique bursitis software, 7% power, 4 min; biostimulation with bipolar resistive technique software contractures software, 7% power, 4 min.

3. Results

After the first session we could see a significant improvement (Figure 2a). In the second, third and fourth sessions the power was reduced, respectively, to 15%, 6% and 6%. The mouth opening immediately after the second session was 2.5 cm (Figure 2b), which became 3.8 cm on completion of the appointments (Figure 3a–d). The pain disappeared after the second session. A new ultrasound evaluation was prescribed, and healing was noticed. Post-treatment pain assessed using the Visual Analogue Scale (VAS) scale showed a significant reduction, equal to 3. After six months of follow-up, the patient has a good mouth opening, has no functional limitations and does not apply any restrictions on hard or chewy foods.



Figure 2. (a) Clinical evaluation after the first appointment. (b) Clinical evaluation after the second session.

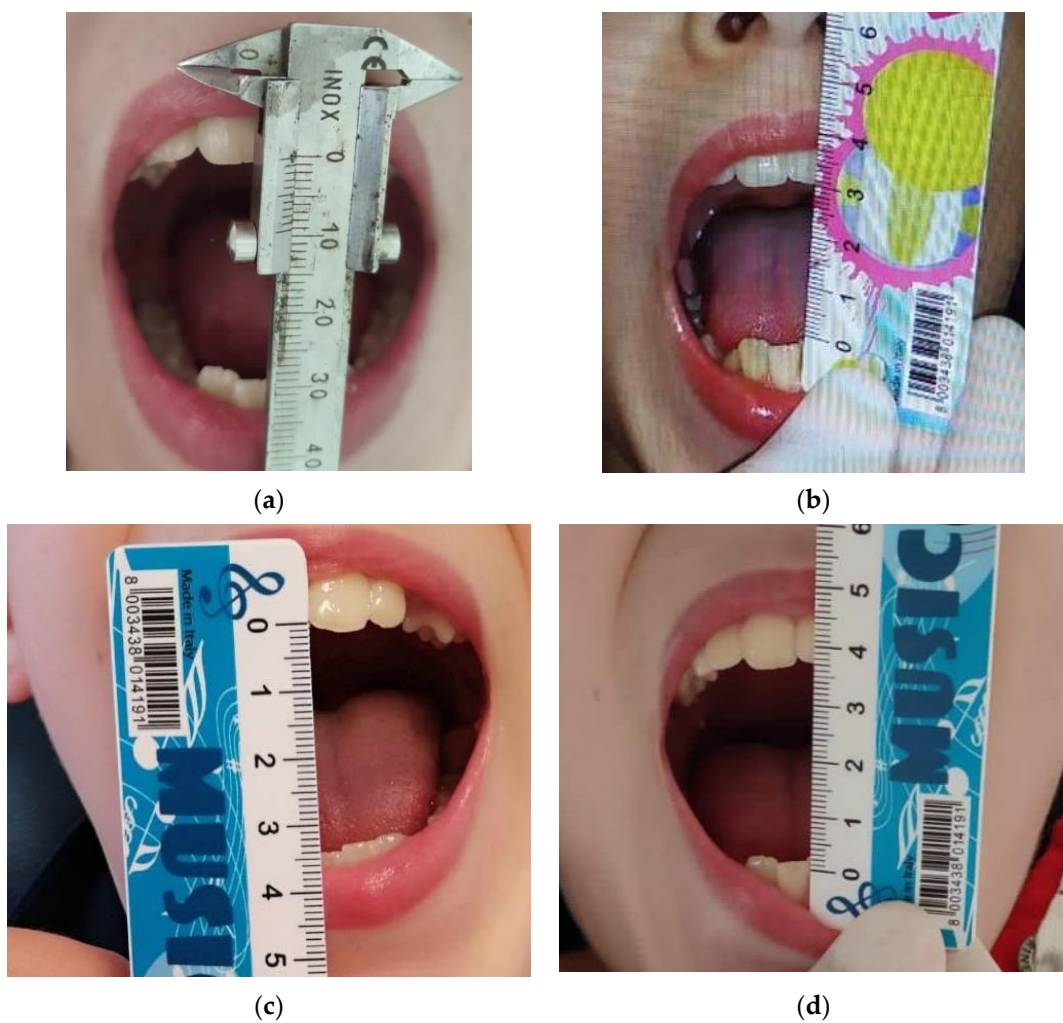


Figure 3. (a) Clinical evaluation after the third appointment. (b) Clinical evaluation after the fourth session (30 mm of maximum opening). (c) Clinical evaluation after fifth appointment (35 mm of maximum opening). (d) Clinical evaluation after last session, with a maximum opening of 38 mm.

4. Discussion

The treatment options currently available for trismus are aimed at improving muscular hypofunction. In the literature, the most recommended physiotherapy exercises are stretching consisting of opening, lateral excursion and closing for 5 min approximately every 3–4 h. Active and passive stretching exercises executed with the aid of different types of therapeutic devices, such as TheraBite apparatus, Dynasplint tools and dynamic bite openers, are usually recommended for supporting the patient affected by trismus in order to improve compliance. Similarly, chewing gum is a trick to promote lateral movement of the temporomandibular joint [17]. The TheraBite device has numerous contraindications: jawbone fractures, bone infection and necrosis. The guidelines suggest the discontinuation of the use of the device in case of severe maxillary pain during the oral cavity opening exercises. In addition, the short-lived, high-torque passive elongation of the device can cause significant iatrogenic damage [18]. No significant effects in terms of mouth opening were found for the stretching devices. Additionally, a greater number of follow-up checks are needed in a short time, so that patients are better followed, both to motivate and to guide them to a better quality of the exercises to be performed. Other problems are related to pain during exercises, no perceived improvement and fitting issues with the stretching device [19]. Drugs used for the treatment of trismus are non-steroidal anti-inflammatory drugs such as diclofenac and ibuprofen, systemic or submucosal injection of corticosteroids such as dexamethasone and methylprednisolone and opioid analgesics such as tramadol [20,21]. Dexamethasone, compared to other drugs, has a half-life between 36 and 54 h; therefore, it is crucial to exploit this time frame to have better performance. Another factor regards the doses used: the dose of dexamethasone administered in the present study was 4 mg, unlike the other ones who administered 8 mg [22,23]. However, there is no direct scientific evidence available and the results are not conclusive due to the heterogeneity and the research methodology carried out [21]. Dexamethasone, like all corticosteroid drugs, causes an increase in blood sugar; therefore, patients with diabetes should be excluded from this research [24]. There is low quality evidence in the scientific literature that submucosal dexamethasone reduced trismus. These studies however are not totally reliable [25] on account of the bias because there was no double blind of the results for the patients on the evaluation of the presence of the trismus (for example, in the method for determining maximum mouth opening or clinical diversity among patients). There is no evidence that a single administration of dexamethasone increased the risk of local and systemic septic complications or delayed surgical site repairs. The only noteworthy aspect is the significant increase in blood glucose in the first 12 h after surgery [25]. The main long-term side effects of NSAIDs involve the gastrointestinal, renal and cardiovascular systems. Limited intake generally does not cause adverse effects; for this reason, they are not recommended over a long period of time [11].

Cryotherapy consists of the application of cold for therapeutic purposes and is commonly used for the management of acute musculoskeletal injuries and swelling after orthopedic surgery. The cold applied to the skin and subcutaneous tissue leads to vasoconstriction, decreasing the excitability of peripheral nerve fibers and lessens the metabolic rate which diminishes the inflammatory response. There are two treatment modalities for cryotherapy: continuous (applied for a definite time and then removed) or intermittent (applied for a shorter time and reapplied several times during the treatment period) [26].

Cryotherapy determines a sudden cooling of the external tissues; however, the surface skin temperature is an unreliable predictor of the deeper temperature (i.e., the intramuscular one). In addition, the possible quantity of adipose tissue can significantly influence the detection of the intramuscular temperature. Furthermore, the deep tissues undergo a gradual decrease in temperature as heat is transferred by conduction to raise that of the more superficial tissues undergoing cryotherapy. Therefore, the short-term duration of cryotherapy treatment for trismus and post-surgical edema may not be sufficient [7].

Numerous studies in the literature suggests that cryotherapy it is not effective in cases of trismus. Due to the heterogeneity of the study data, effective standardized protocols

for the treatment of trismus with cryotherapy are absent. There are conflicting opinions on the methods of cold application (thermogel wrapped in a disposable cloth, bilateral facial ice packs, ice cubes enclosed in a plastic bag and wrapped in a cloth) and duration of therapy (continuous or intermittent). The choice of cryotherapy modality and the intervals of application after wisdom teeth extraction are important, but in the literature, they are poorly described [7,27].

Low-level laser therapy (LLLT) has several effects on tissues: the activation of both local microcirculation and cellular metabolism, producing anti-inflammatory and regenerative effects. LLLT also has an anti-edematous and pain relief effect due to an increased number and diameter of lymph vessels and a decreased blood vessel permeability. At a molecular level, LLLT can increase protein absorption by activating macrophages, modifying hydrostatic and intracapillary pressure and inducing the absorption of interstitial fluids with a consequent reduction of edema [28]. However, laser therapy results are of moderate clinical importance for patients affected by trismus; it has been used for minimizing mouth opening reduction, but only a very small number of patients undergo this type of therapy [29]. However, due to the heterogeneity of the parameters of the devices described in the literature, there is a high risk of bias and limited evidence to demonstrate its certain efficacy. For this, more well-designed randomized controlled trials with larger sample sizes are needed to provide more reliable recommendations [30].

Since the 1990s, hyaluronic acid has been used for its analgesic properties, because it induces greater intra-articular lubrication, especially in the knee and ankle.

Hyaluronic acid is used in dentistry as an anti-inflammatory and antioxidant substance used after tooth extraction to reduce pain, edema and trismus. Compared to a placebo or to no treatment, hyaluronic acid has been shown to promote a lower inflammatory response. This justifies the reduced amount of pain and a faster healing of the edema due to its hydrophilic nature and its osmotic activity (which promotes the elimination of prostaglandins and metalloproteinases). However, hyaluronic acid has no effect on trismus. There is no clear and univocal support or statistically significant results in the literature to indicate that the application of hyaluronic acid may reduce pain and trismus and there are no studies with long-term follow-ups and a large sample of patients [4,31].

Platelet-Rich Fibrin (PRF) infiltration is a concentrate obtained from the patient's own blood. PRF modulates immunological and tissue repair processes, as it contains growth factors and other types of cytokines (such as platelet-derived growth factor, transforming growth factor beta and insulin-like growth factor). The PRF derives from the slow, gradual polymerization occurring during centrifugation [32]. The literature shows that PRF can be useful for reducing pain and swelling after surgical procedures but there are no clear beneficial effects of PRF on trismus. Again, future studies with larger samples and longer follow-up periods are needed to evaluate the efficacy of PRF [33,34]. Cret devices provide radiofrequency energy that passes between an active and a passive electrode to generate therapeutic effects on the body. The Cret device firstly increases the temperature of the tissue and, thus, soft tissue extensibility and muscle flexibility and reduces muscle tension and spasms. Secondly, as the temperature of the tissue increases, vasodilation occurs [14]. The result is an improvement in general blood circulation which produces an influx of nutrients, thus promoting tissue repair and healing. Furthermore, as circulation improves, the hypoxic conditions in damaged tissues are reversed; this stops the production and release of molecules that activate pain signals, reducing pain, spasms, joint contractures and tissue fibrosis [15]. The Cret device provides thermal and non-thermal effects. The ionization of the tissue molecules causes physiological oscillations which create vibratory energy. Part of this energy leads to the production of endogenous heat in the tissues. This leads to vascularization in the tissues and eventually, with the rise in temperature, to hyperactivation [14,35]. Some of the energy is used to directly increase cellular metabolism and increase the synthesis of adenosine triphosphate (ATP) and adenosine diphosphate (ADP) that affects the cell membrane and receptors. This improves cell regeneration and modulates pain sensations. The relationship between thermal and non-thermal effects

depends on the electrical properties of specific tissues and the condition of these tissues. Cret treatments can therefore be very selective [36]. Cret devices can stimulate metabolism and lymphatic drainage improving tissue oxygenation and metabolism and are suitable for acute inflammatory processes and sub-acute healing processes. Furthermore, these devices increase hemodynamic flow, vasodilation and reduce tissue tension; they increase tissue compliance and are useful for chronic processes, repair and regeneration [36]. In the literature, Cret devices have been shown to increase cell proliferation in the common extensor tendon and radiohumeral capsule in living subjects and to increase flexibility of the quadricep muscles in human athletes [37].

Cret therapy is also involved in the stimulation of molecules for collagen synthesis and release fibroblast proliferation and affects markers closely related to collagenogenesis and fibrillogenesis and the biomarkers involved in processes such as skin aging or wound healing and regeneration [38].

These biomarkers of electrically induced overexpression in muscle cells could intervene in the processes of cell migration, contraction of the extracellular matrix, collagenogenesis and fibrillogenesis, essential for tissue repair using Cret therapies. Although promising results have been shown in the literature, long-term Cret effects on factors involved in the regulation of fibrillogenesis and connective tissue regeneration should be further investigated to understand the phenomena underlying the electrically induced cellular responses [39]. In our study, radiofrequency was used to treat trismus that had not yet healed after other drug therapies. The patient, at present, well after six months, has not had relapses or clinical worsening. For this reason, it could be useful to define precise and replicable protocols to make this therapy more easily performed on an outpatient basis. The great advantage is the absence of side effects, often present after taking the drug therapies that are prescribed in these cases. This is particularly important in patients taking other medications for other conditions.

5. Conclusions

Clinical studies with a good number of samples need to be conducted to evaluate the effectiveness of this device which has proved to be an excellent treatment for this refractory case to conventional therapies. Therefore, this study has highlighted the uniqueness and validity of this alternative treatment, which could be a valid therapeutic aid for temporomandibular disorders.

Author Contributions: The case was fully conducted and documented by G.C.; G.A. wrote the materials and methods and the discussion of this work. C.C. wrote the introduction and supervised the writing of the study. M.S.M. took care of the final drafting and documentation of the case. G.O. took care of the final correction of the paper and the integration of some notes in the discussion. All authors have read and agreed to the published version of the manuscript.

Funding: This research received no external funding.

Institutional Review Board Statement: The study was conducted according to the guidelines of the Declaration of Helsinki. The work is an observational study carried out during routinary clinical practice and did not regard uncodified therapeutic protocols from European law. The subject's privacy and confidentiality were never compromised in this study.

Informed Consent Statement: Informed written consent was obtained from the subject and from the subject's parents involved in this study.

Data Availability Statement: Data are available on request from the authors.

Acknowledgment: One of the authors, C.C. performed his/her activity in the framework of the International PhD in Innovation Sciences and Technologies at the University of Cagliari, Italy.

Conflicts of Interest: The authors declare no conflict of interest.

Abbreviations

Cret	capacitive-resistive electrical transfer therapy
NSAID	non-steroidal anti-inflammatory drugs
LLLT	low level laser therapy
PRF	platelet-rich fibrin

References

1. Beddis, H.P.; Davies, S.J.; Budenberg, A.; Horner, K.; Pemberton, M.N. Temporomandibular disorders, trismus and malignancy: Development of a checklist to improve patient safety. *Br. Dent. J.* **2014**, *217*, 351–355. [\[CrossRef\]](#)
2. Dhanrajani, P.J.; Jonaidel, O. Trismus: Aetiology, differential diagnosis and treatment. *Dent. Update* **2002**, *29*, 88–94. [\[CrossRef\]](#)
3. Tveterås, K.; Kristensen, S. The aetiology and pathogenesis of trismus. *Clin. Otolaryngol. Allied Sci.* **1986**, *11*, 383–387. [\[CrossRef\]](#)
4. Maria de Souza, G.; Elias, G.M.; Pereira de Andrade, P.F.; Andrade Sales, K.N.; Galvão, E.L.; Moreira Falci, S.G. The Effectiveness of Hyaluronic Acid in Controlling Pain, Edema, and Trismus After Extraction of Third Molars: Systematic Review and Meta-Analysis. *J. Oral Maxillofac. Surg.* **2020**, *78*, 2154.e1–2154.e12. [\[CrossRef\]](#) [\[PubMed\]](#)
5. Kawashita, Y.; Soutome, S.; Umeda, M.; Saito, T. Oral management strategies for radiotherapy of head and neck cancer. *Jpn. Dent. Sci. Rev.* **2020**, *56*, 62–67. [\[CrossRef\]](#) [\[PubMed\]](#)
6. Shen, Y.W.; Shih, Y.H.; Fuh, L.J.; Shieh, T.M. Oral Submucous Fibrosis: A Review on Biomarkers, Pathogenic Mechanisms, and Treatments. *Int. J. Mol. Sci.* **2020**, *21*, 7231. [\[CrossRef\]](#) [\[PubMed\]](#)
7. do Nascimento-Júnior, E.M.; dos Santos, G.M.S.; Tavares Mendes, M.L.; Cenci, M.; Correa, M.B.; Pereira-Cenci, T.; Martins-Filho, P.R.S. Cryotherapy in reducing pain, trismus, and facial swelling after third-molar surgery: Systematic review and meta-analysis of randomized clinical trials. *J. Am. Dent. Assoc.* **2019**, *150*, 269–277.e1. [\[CrossRef\]](#)
8. Shao, C.H.; Chiang, C.C.; Huang, T.W. Exercise therapy for cancer treatment-induced trismus in patients with head and neck cancer: A systematic review and meta-analysis of randomized controlled trials. *Radiother. Oncol. J. Eur. Soc. Ther. Radiol. Oncol.* **2020**, *151*, 249–255. [\[CrossRef\]](#)
9. Gondivkar, D.; Gadail, D.; Sarode, D.; Gondivkar, D.; Patil, S.; Gaikwad, D.; Dinh-Toi, C.; Yuwanati, D.M. Treatment outcomes of laser therapy in oral submucous fibrosis—a systematic review. *J. Oral Biol. Craniofacial Res.* **2020**, *10*, 253–258. [\[CrossRef\]](#)
10. Zhu, J.; Zhang, S.; Yuan, X.; He, T.; Liu, H.; Wang, J.; Xu, B. Effect of platelet-rich fibrin on the control of alveolar osteitis, pain, trismus, soft tissue healing, and swelling following mandibular third molar surgery: An updated systematic review and meta-analysis. *Int. J. Oral Maxillofac. Surg.* **2021**, *50*, 398–406. [\[CrossRef\]](#)
11. Isirdia-Espinoza, M.A.; Bologna-Molina, R.E.; Hernández-Miramontes, Y.A.; Zapata-Morales, J.R.; Alonso-Castro, A.J.; Martínez-Morales, F.; Sánchez-Enriquez, S.; Serafín-Higuera, N.A.; Pérez-Cortez, G.; Franco-De La Torre, L. Pharmacological Control of Complications Following to Third Molar Removal: Evidence Based on A Meta-Analysis. *Drug Res.* **2019**, *69*, 5–11. [\[CrossRef\]](#) [\[PubMed\]](#)
12. Mlernik, M.; Więckiewicz, W. The basic conservative treatment of temporomandibular joint anterior disc displacement without reduction—Review. *Adv. Clin. Exp. Med. Off. Organ Wroc. Med. Univ.* **2015**, *24*, 731–735. [\[CrossRef\]](#) [\[PubMed\]](#)
13. Becero, M.; Saitua, A.; Argüelles, D.; Sánchez de Medina, A.L.; Castejón-Riber, C.; Riber, C.; Muñoz, A. Capacitive resistive electric transfer modifies gait pattern in horses exercised on a treadmill. *BMC Vet. Res.* **2020**, *16*, 10. [\[CrossRef\]](#) [\[PubMed\]](#)
14. López-De-Celis, C.; Hidalgo-García, C.; Pérez-Bellmunt, A.; Fanlo-Mazas, P.; González-Rueda, V.; Tricás-Moreno, J.M.; Ortiz, S.; Rodríguez-Sanz, J. Thermal and non-thermal effects off capacitive-resistive electric transfer application on the Achilles tendon and musculotendinous junction of the gastrocnemius muscle: A cadaveric study. *BMC Musculoskelet. Disord.* **2020**, *21*, 46. [\[CrossRef\]](#) [\[PubMed\]](#)
15. Rodríguez-Sanz, J.; López-de-Celis, C.; Hidalgo-García, C.; Canet-Vinó, M.; Fanlo-Mazas, P.; Pérez-Bellmunt, A. Temperature and current flow effects of different electrode placement in shoulder capacitive-resistive electric transfer applications: A cadaveric study. *BMC Musculoskelet. Disord.* **2021**, *22*, 139. [\[CrossRef\]](#)
16. Kumaran, B.; Watson, T. Skin thermophysiological effects of 448 kHz capacitive resistive monopolar radiofrequency in healthy adults: A randomised crossover study and comparison with pulsed shortwave therapy. *Electromagn. Biol. Med.* **2018**, *37*, 1–12. [\[CrossRef\]](#)
17. Satheshkumar, P.S.; Mohan, M.P.; Jacob, J. Restricted mouth opening and trismus in oral oncology. *Oral Surg. Oral Med. Oral Pathol. Oral Radiol.* **2014**, *117*, 709–715. [\[CrossRef\]](#)
18. Marunick, M.T.; Garcia-Gazau, S.; Hildebrand, J.M. Mandibular pathological fracture during treatment with a dynamic mouth opening device: A clinical report. *J. Prosthet. Dent.* **2016**, *116*, 488–491. [\[CrossRef\]](#)
19. van der Geer, S.J.; Reintsema, H.; Kamstra, J.I.; Roodenburg, J.; Dijkstra, P.U. The use of stretching devices for treatment of trismus in head and neck cancer patients: A randomized controlled trial. *Support. Care Cancer* **2020**, *28*, 9–11. [\[CrossRef\]](#)
20. Warraich, R.; Faisal, M.; Rana, M.; Shaheen, A.; Gellrich, N.C.; Rana, M. Evaluation of postoperative discomfort following third molar surgery using submucosal dexamethasone—A randomized observer blind prospective study. *Oral Surg. Oral Med. Oral Pathol. Oral Radiol.* **2013**, *116*, 16–22. [\[CrossRef\]](#)
21. Falci, S.; Lima, T.C.; Martins, C.C.; Santos, C.; Pinheiro, M. Preemptive Effect of Dexamethasone in Third-Molar Surgery: A Meta-Analysis. *Anesth. Prog.* **2017**, *64*, 136–143. [\[CrossRef\]](#) [\[PubMed\]](#)

22. Srivastava, N.; Shetty, A.; Kumar, P.; Rishi, D.; Bagga, V.; Kale, S.G. Comparison of Preemptive Effect of Dexamethasone and Methylprednisolone After Third Molar Surgery: A Split-Mouth Randomized Triple-Blind Clinical Trial. *J. Maxillofac. Oral Surg.* **2021**, *20*, 264–270. [[CrossRef](#)] [[PubMed](#)]
23. Moore, R.A.; Derry, S.; Aldington, D.; Wiffen, P.J. Single dose oral analgesics for acute postoperative pain in adults—An overview of Cochrane reviews. *Cochrane Database Syst. Rev.* **2015**, *2015*, CD008659. [[CrossRef](#)] [[PubMed](#)]
24. Fernandes, I.A.; de Souza, G.M.; Pinheiro, M.; Falci, S. Intramuscular injection of dexamethasone for the control of pain, swelling, and trismus after third molar surgery: A systematic review and meta-analysis. *Int. J. Oral Maxillofac. Surg.* **2019**, *48*, 659–668. [[CrossRef](#)] [[PubMed](#)]
25. O'Hare, P.E.; Wilson, B.J.; Loga, M.G.; Ariyawardana, A. Effect of submucosal dexamethasone injections in the prevention of postoperative pain, trismus, and oedema associated with mandibular third molar surgery: A systematic review and meta-analysis. *Int. J. Oral Maxillofac. Surg.* **2019**, *48*, 1456–1469. [[CrossRef](#)] [[PubMed](#)]
26. Polderman, J.; Farhang-Razi, V.; van Dieren, S.; Kranke, P.; DeVries, J.H.; Hollmann, M.W.; Preckel, B.; Hermanides, J. Adverse side-effects of dexamethasone in surgical patients—An abridged Cochrane systematic review. *Anaesthesia* **2019**, *74*, 929–939. [[CrossRef](#)]
27. Larsen, M.K.; Kofod, T.; Starch-Jensen, T. Therapeutic efficacy of cryotherapy on facial swelling, pain, trismus and quality of life after surgical removal of mandibular third molars: A systematic review. *J. Oral Rehabil.* **2019**, *46*, 563–573. [[CrossRef](#)]
28. Al-Khateeb, T.H.; Nusair, Y. Effect of the proteolytic enzyme serrapeptase on swelling, pain and trismus after surgical extraction of mandibular third molars. *Int. J. Oral Maxillofac. Surg.* **2008**, *37*, 264–268. [[CrossRef](#)]
29. He, W.L.; Yu, F.Y.; Li, C.J.; Pan, J.; Zhuang, R.; Duan, P.J. A systematic review and meta-analysis on the efficacy of low-level laser therapy in the management of complication after mandibular third molar surgery. *Lasers Med. Sci.* **2015**, *30*, 1779–1788. [[CrossRef](#)]
30. Brignardello-Petersen, R.; Carrasco-Labra, A.; Araya, I.; Yanine, N.; Beyene, J.; Shah, P.S. Is adjuvant laser therapy effective for preventing pain, swelling, and trismus after surgical removal of impacted mandibular third molars? A systematic review and meta-analysis. *J. Oral Maxillofac. Surg.* **2012**, *70*, 1789–1801. [[CrossRef](#)]
31. Dawdy, J.; Halladay, J.; Carrasco-Labra, A.; Araya, I.; Yanine, N.; Brignardello-Petersen, R. Efficacy of adjuvant laser therapy in reducing postsurgical complications after the removal of impacted mandibular third molars: A systematic review update and meta-analysis. *J. Am. Dent. Assoc.* **2017**, *148*, 887–902. [[CrossRef](#)] [[PubMed](#)]
32. Gocmen, G.; Gonul, O.; Oktay, N.S.; Yarat, A.; Goker, K. The antioxidant and anti-inflammatory efficiency of hyaluronic acid after third molar extraction. *J. Craniomaxillofac. Surg.* **2015**, *43*, 1033–1037. [[CrossRef](#)] [[PubMed](#)]
33. Afat, İ.M.; Akdoğan, E.T.; Gönül, O. Effects of Leukocyte- and Platelet-Rich Fibrin Alone and Combined with Hyaluronic Acid on Pain, Edema, and Trismus After Surgical Extraction of Impacted Mandibular Third Molars. *J. Oral Maxillofac. Surg. Off. J. Am. Assoc. Oral Maxillofac. Surg.* **2018**, *76*, 926–932. [[CrossRef](#)] [[PubMed](#)]
34. Torul, D.; Omezli, M.M.; Kahveci, K. Evaluation of the effects of concentrated growth factors or advanced platelet rich-fibrin on postoperative pain, edema, and trismus following lower third molar removal: A randomized controlled clinical trial. *J. Stomatol. Oral. Maxillofac. Surg.* **2020**, *121*, 646–651. [[CrossRef](#)]
35. Xiang, X.; Shi, P.; Zhang, P.; Shen, J.; Kang, J. Impact of platelet-rich fibrin on mandibular third molar surgery recovery: A systematic review and meta-analysis. *BMC Oral Health* **2019**, *19*, 163. [[CrossRef](#)]
36. López-de-Celis, C.; Rodríguez-Sanz, J.; Hidalgo-García, C.; Cedeño-Bermúdez, S.A.; Zegarra-Chávez, D.; Fanlo-Mazas, P.; Pérez-Bellmunt, A. Thermal and Current Flow Effects of a Capacitive-Resistive Electric Transfer Application Protocol on Chronic Elbow Tendinopathy. A Cadaveric Study. *Int. J. Environ. Res. Public Health* **2021**, *18*, 1012. [[CrossRef](#)]
37. Hernández-Bule, M.L.; Medel, E.; Colastra, C.; Roldán, R.; Úbeda, A. Response of neuroblastoma cells to RF currents as a function of the signal frequency. *BMC Cancer* **2019**, *19*, 889. [[CrossRef](#)]
38. Duñabeitia, I.; Arrieta, H.; Torres-Unda, J.; Gil, J.; Santos-Concejero, J.; Gil, S.M.; Irazusta, J.; Bidaurreazaga-Letona, I. Effects of a capacitive-resistive electric transfer therapy on physiological and biomechanical parameters in recreational runners: A randomized controlled crossover trial. *Phys. Ther. Sport Off. J. Assoc. Chart. Physiother. Sports Med.* **2018**, *32*, 227–234. [[CrossRef](#)]
39. Pang, X.; Dong, N.; Zheng, Z. Small Leucine-Rich Proteoglycans in Skin Wound Healing. *Front. Pharmacol.* **2020**, *10*, 1649. [[CrossRef](#)]