radiation

MDPI

Article

Mepilex Dressings for the Management of Radiation-Induced Moist Desquamation in Breast Cancer

Shely Kagan [1], Yulya Kagan [1], Britney Zhang [1], Christina Yang [1], Shivani Verma [1], Henry C. Y. Wong [2], Amir H. Safavi [1], Irene Karam [1], Shirley S. W. Tse [3,4], Shing Fung Lee [5,6], Sarah Bayrakdarian [1] and Edward Chow [1,*]

[1] Department of Radiation Oncology, Sunnybrook Health Sciences Centre, Odette Cancer Centre, 2075 Bayview Avenue, Toronto, ON M4N 3M5, Canada
[2] Department of Oncology, Princess Margaret Hospital, Kowloon West Cluster, Hong Kong SAR, China
[3] Department of Oncology, United Christian Hospital, Kowloon East Cluster, Hospital Authority, Hong Kong SAR, China
[4] Department of Clinical Oncology, Queen Elizabeth Hospital, Kowloon Central Cluster, Hospital Authority, Hong Kong SAR, China
[5] Department of Radiation Oncology, National University Cancer Institute, National University Hospital, Singapore 119074, Singapore
[6] Department of Medicine, Yong Loo Lin School of Medicine, National University of Singapore, Singapore 119228, Singapore
* Correspondence: edward.chow@sunnybrook.ca

Simple Summary

Radiotherapy is an important treatment for breast cancer, but it can cause skin reactions, including moist desquamation (MD), a painful condition in which the skin breaks down and develops open, weeping areas. These wounds can significantly affect patients' comfort and quality of life, and healing may take several weeks. This prospective study evaluated the use of advanced wound dressings, primarily Mepilex Lite and Mepilex Ag, in ten breast cancer patients who developed MD following radiotherapy. Patients were followed until their skin had healed, with regular assessments of symptoms, wound progression, and treatment satisfaction. The average time to Grade 1 healing was approximately 10 days, with patients reporting improvements in pain, burning, and sensitivity.

Abstract

Background: Radiotherapy (RT) improves survival in breast cancer but often causes acute radiation dermatitis. In severe cases, moist desquamation (MD), a painful loss of epidermal integrity that impairs comfort and quality of life, can occur. This prospective observational study described healing time to Grade 1, symptom changes, and patient experiences among breast cancer patients with radiation-induced MD managed with Mepilex dressings. Methods: Ten breast cancer patients (aged 49–84 years; mean 58.3) who developed grade 2 to 4 MD on an investigator-designed scale during or after adjuvant RT were enrolled and followed until healing. Dressings were applied by oncology nurses and changed every 2 to 3 days. Nurses had the option to apply Mepilex Lite, Mepilex Border Flex Lite, or Mepilex Ag, with the latter reserved for heavier exudation or suspected infection. Parallel patient- and clinician-reported grading tools, 10-item symptom questionnaires, and photographic documentation were used at each dressing change. The primary endpoint was time to MD resolution, defined as the interval from the first study dressing application to the first assessment documenting Grade 1 MD. Secondary endpoints included symptom trajectories and patient satisfaction. Results: The mean healing time to Grade 1 was 10.4 days (median 10; range 7–19) after application of Mepilex dressings. Three patients used Mepilex Ag. Scores for pain, tenderness, burning, and hypersensitivity decreased, while itch and edema showed minimal change. Nurse-reported assessments showed similar patterns of

Check for updates

Academic Editor: Krishan Kumar

Received: 8 October 2026
Revised: 13 November 2026
Accepted: 17 November 2026
Published: 26 November 2026

Copyright: © 2026 by the authors. Licensee MDPI, Basel, Switzerland. This article is an open access article distributed under the terms and conditions of the Creative Commons Attribution (CC BY) license.

change across several symptom domains. Patients reported high satisfaction with Mepilex dressings, citing comfort, reduced friction, and improved daily function. As this was an uncontrolled observational study, symptom and healing changes cannot be attributed to Mepilex dressings independently of natural healing, prior or concurrent treatments, or other aspects of care. Conclusions: These findings provide preliminary information on the clinical course and patient experience of MD during Mepilex-based wound care. Further comparative studies are needed to evaluate the contribution of these dressings to symptom relief and wound healing.

Keywords: breast; cancer; radiotherapy; dermatitis; Mepilex; wound; healing

1. Introduction

Radiotherapy (RT) is a cornerstone of adjuvant treatment for breast cancer, significantly improving local disease control and long-term survival [1,2]. Despite its therapeutic benefits, RT is frequently associated with acute radiation dermatitis, which remains a major clinical concern due to its impact on patient comfort, treatment adherence, and overall quality of life [3,4]. Among these toxicities, moist desquamation (MD) represents a severe manifestation, characterized by the loss of the epidermal barrier, resulting in open, oozing, and often painful lesions [5–7]. MD typically occurs in areas where the skin is subjected to higher radiation doses, friction, or moisture accumulation, and it can significantly impair daily activities, including clothing wear, personal hygiene, and sleep [4,7]. Healing from MD can be particularly slow, often taking several weeks, which underscores the need for effective wound care strategies that support recovery while minimizing pain and further skin injury [8–10].

Current approaches to MD management include advanced wound dressings, topical agents, and supportive care strategies to promote healing, protect skin, and alleviate symptoms [11,12]. Silicone-based dressings, such as Mepilex, are multilayered foams designed to manage exudate while minimizing trauma [13]. They feature a soft silicone Safetac layer that adheres gently without sticking to the wound and an absorbent foam layer that draws away exudate [13,14]. Mepilex Lite is available in different formats, including Mepilex Border Flex Lite, which incorporates an adhesive border to help secure the dressing in place [13,14]. Mepilex Lite is suited for low to moderate exuding wounds, while Mepilex Ag is a silver-containing dressing that provides broad-spectrum antimicrobial activity and may be used for wounds at risk of infection [15].

Although advanced dressings such as Mepilex Lite have been studied in randomized controlled trials [16–18], these interventions were initiated when patients already exhibited erythema rather than more severe dermatitis. Other interventions, including moisturizers and topical corticosteroids, are also effective for managing low-grade radiation dermatitis, making it uncertain how much Mepilex dressings contribute to the treatment of more severe cases, such as MD.

This prospective observational study followed breast cancer patients with radiation-induced MD who received Mepilex dressings as part of their wound care. The study aimed to assess the time to improvement to Grade 1, evaluate changes in patient- and clinician-reported symptoms over the course of treatment, and explore patient and provider experiences with the dressings.

2. Methods

2.1. Study Design and Participants

This prospective study enrolled 10 breast cancer patients who had completed standard adjuvant external beam radiotherapy (EBRT). Participants were recruited between July and August 2025. The breast cancer cohort was enrolled under the same prospective study protocol as a previously reported head and neck cancer cohort. The two cohorts consisted of completely separate, non-overlapping participants.

Eligibility criteria included age ≥18 years; female or male sex; provision of informed consent; histological confirmation of breast malignancy (invasive or in situ carcinoma) or phyllodes tumour; treatment with a non-stereotactic body radiotherapy (non-SBRT) adjuvant radiation dose appropriate for the treatment site; treatment with or without a planned boost or bolus; and the presence of any MD identified by healthcare professionals. Participants were required to communicate in English or have access to a translator. Patients were ineligible if they were planned to receive brachytherapy, had received prior RT to any portion of the planned treatment site, or had a known sensitivity or allergy to silicone and/or Mepilex (Mölnlycke Health Care, Gothenburg, Sweden).

Patients were recruited following completion of RT and followed prospectively until improvement to Grade 1 on the Moist Desquamation Grading Tool for Healthcare Providers (Appendix A). Grade 1 was defined as dry desquamation, representing improvement from moist desquamation rather than necessarily complete epithelialization. Therefore, the primary endpoint reflects the first assessment documenting improvement to Grade 1, rather than confirmed complete wound closure. The patient tool was completed by participants using a standardized photographic atlas; the healthcare-provider tool was completed by nurses and, at scheduled visits, radiation oncologists.

Initial MD severity was assessed by a radiation oncologist at study enrolment. Subsequent assessments during dressing changes were performed by one of five oncology nurses, depending on availability. Radiation oncologists also conducted assessments during scheduled follow-up visits. Nurse and physician assessments were performed independently, without consultation or reconciliation of grading scores. The same investigator-developed HCP grading tool was used by both groups of healthcare professionals. Inter-rater reliability was not formally assessed.

2.2. Dressing Application and Wound Care

All patients were managed with Mepilex dressings (Mölnlycke Health Care, Gothenburg, Sweden). Nurses had the option to apply Mepilex Lite, Mepilex Border Flex Lite, or Mepilex Ag, with the latter reserved for cases with heavier exudation or where there was a clinical concern for local infection, as the incorporation of ionic silver confers broad-spectrum antimicrobial activity while maintaining the same atraumatic properties [15]. The protocol did not randomize dressing type. Because dressing selection was based on clinical presentation, outcomes were not compared between dressing types. Mepilex was applied at RT completion or when a patient was placed on a treatment pause. Dressings were not used concurrently with RT because of the potential for a bolus effect. The study nurse applied a Mepilex dressing to the wound after cleansing it with normal saline on the day of assessment. The dressing was secured with tape and the intended dressing-change interval was every 2–3 days. This interval reflected the actual clinical assessment and dressing-change schedule.

2.3. Data Collection and Outcome Measures

Baseline demographic and clinical data were collected at enrollment, including age, sex, ethnicity, Fitzpatrick skin type, disease site, and RT parameters.

To evaluate MD from both patient and clinician perspectives, two parallel instruments were administered. Patients completed the Moist Desquamation Grading Tool for Patients (Appendix B) and the 10-item Patient-Reported Outcomes for MD (Appendix C) at each dressing change. To support the accuracy of self-reported grading, patients were provided with a standardized photographic atlas. Parallel assessments were conducted by healthcare providers, who independently graded MD severity and assessed symptoms using the Moist Desquamation Grading Tool for Healthcare Providers (Appendix A) and the 10-item HCP-Reported Outcomes for MD (Appendix D).

These evaluations were completed by nurses during each dressing change and by radiation oncologists during scheduled follow-up visits. HCP-reported symptom scores reflected the healthcare provider's clinical assessment, informed by observation of the affected area and discussion with the patient. These ratings represented the HCP's assessment of symptom severity and were not intended to serve as independent objective measurements of subjective symptoms. The grading tools were developed for this study to document the clinical presentation and progression of MD. Although the tools incorporate features relevant to established radiation dermatitis grading systems, including RTOG and CTCAE, they have not been formally validated against these instruments or against RISRAS.

The primary endpoint of this study was the time to improvement to Grade 1 MD, as determined by healthcare-provider grading. Secondary endpoints included patient-reported MD severity and symptom burden, HCP-reported symptom burden, photographic documentation of MD progression, overall dressing utilization, and patient satisfaction with Mepilex dressings.

This study was approved by Sunnybrook Health Sciences Centre's Research Ethics Board (REB #: SUN-6680) on 7 July 2025.

2.4. Statistical Analysis

Analyses were primarily descriptive. Continuous variables were summarized using means and standard deviations (SDs) or medians and ranges/interquartile ranges (IQRs), as appropriate, while categorical variables were reported as frequencies and percentages. The Moist Desquamation Grading Tool was treated as an ordinal scale (grades 0–5). Responses to the 10-item patient- and healthcare provider (HCP)-reported symptom assessments were categorized as none (1), mild (2), moderate (3), or severe (4), with domain scores summarized at baseline and final assessment. No formal power calculation was performed. The study was intended to provide preliminary descriptive data on the clinical course, symptom burden, and feasibility of prospective follow-up, rather than to test clinical effectiveness.

Patients completed assessments at each dressing change, typically every 2–3 days, as did nurses, while physicians assessed patients during scheduled visits. Due to the limited number of physician assessments, these data were summarized descriptively. For the symptom comparisons presented in this manuscript, baseline and final assessment scores were summarized; a separate analysis of symptom scores across every dressing change was not performed. Available-case analyses were performed without estimating missing data.

Lesions were the primary unit of analysis for the time-to-improvement outcome. Given the small sample size, lack of a comparator group, and exploratory design, no inferential statistical testing was performed.

3. Results

3.1. Patient Demographics and Clinical Characteristics

Ten breast cancer patients were enrolled, aged 49–84 years (mean 58.3 ± 10). Fitzpatrick skin types of the patients were type II ($n = 1$), type III ($n = 5$), type IV ($n = 3$), and type V ($n = 1$) (Table 1). Patients' histologies included invasive ductal carcinoma (IDC, $n = 3$),

invasive micropapillary carcinoma (IMC, $n = 1$), invasive lobular carcinoma (ILC, $n = 1$), ductal carcinoma in situ (DCIS, $n = 4$), and phyllodes tumors ($n = 2$). Histological categories were not mutually exclusive, as one patient had both IDC and DCIS. Patients had completed standard adjuvant RT before being treated with Mepilex; two underwent neoadjuvant chemotherapy, while another two underwent adjuvant chemotherapy. No patients received a bolus; all patients developed MD during the last 3–5 fractions of RT. Across the 12 lesions, initial severity was grade 2 ($n = 10$), 3 ($n = 1$), and 4 ($n = 1$). The Grade 4 lesion was classified based on documented clinical signs of infection and was managed with Mepilex Ag. There were no reported adverse events associated with Mepilex dressing use.

Table 1. Baseline patient data.

ID	Fitzpatrick Skin Type	Ethnicity	Chemo-therapy (Intent)	Mepilex Product(s) Used	Diag-nosis	Tx Site(s)	RT Dose/Fx	Boost	Initial MD Grade	Infec-tion (Y/N)	Topical Agents Used Prior to Mepilex
1	IV	Caucasian	N/A	Mepilex Ag	ILC	BREL	40.05 Gy/15	12.5 Gy/5	4	Y	N/A
2	II	Caucasian	Adju-vant	Mepilex Ag	IDC	BREL	40.05 Gy/15	12.5 Gy/5	2	N	N/A
3	V	Black	N/A	Mepilex Border Flex Lite	DCIS	BRER	40.05 Gy/15	12.5 Gy/5	2	N	Proshield
4	III	East Asian	Neoadju-vant	Mepilex Border Flex Lite	IMC	CHWR + SCNR + CHWL	40.05 Gy/15	None	2	N	N/A
5	IV	East Asian	N/A	Mepilex Border Flex Lite	DCIS	BRER + BRBR	40.05 Gy/15	12.5 Gy/5	2	N	Proshield
6	III	Caucasian	Adju-vant	Mepilex Border Flex Lite	IDC + DCIS	CHWR + SCNR	40.05 Gy/15	None	2	N	N/A
7	IV	East Asian	N/A	Mepilex Border Flex Lite	DCIS	BRER + BRBR	40.05 Gy/15	12.5 Gy/5	2	N	Proshield
8	III	East Asian	N/A	Mepilex Border Flex Lite + Mepilex Ag	Phyl-lodes	BREL + BRBL	50 Gy/25	12.5 Gy/5	2, 2	N	Proshield
9	III	Southeast Asian	Neoadju-vant	Mepilex Lite	IDC	BRER + SCNR +BRBR	40.05 Gy/15	12.5 Gy/5	3, 2	N	Proshield
10	III	East Asian	N/A	Mepilex Border Flex Lite	Phyl-lodes	CHWL + CHBL	50 Gy/25	12.5 Gy/5	2	N	Flamazine

Abbreviations: BREL, breast right lateral; BRER, breast right; BRBR, breast right breast region; BRBL, breast left breast region; CHWR, chest wall right; CHWL, chest wall left; CHBL, chest wall bilateral; SCNR, supraclavicular nodes right.

3.2. Healing Time to Grade 1

The primary outcome was time to improvement to Grade 1 (dry desquamation). This endpoint represents the first assessment at which the lesion was documented as Grade 1 and should not be interpreted as the time to complete epithelialization. Time to improvement was calculated separately for each individual lesion, with patients contributing multiple observations when they had more than one lesion. The mean time to improvement was 10.4 days (median, 10 days; range, 7–19 days) (Figure 1). The 10 patients contributed a total of 12 lesions, as patients 8 and 9 presented with two distinct lesions each.

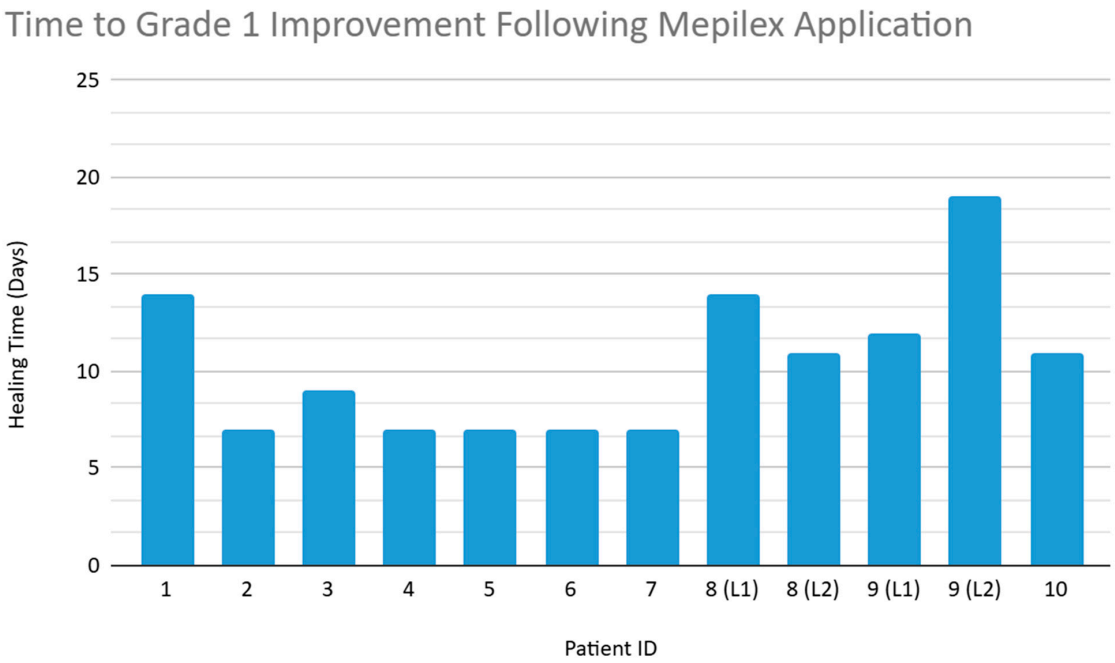

Figure 1. Healing time to grade 1 distribution. Lesion-level healing times across all observed lesions. L1, L2, L3, [...] represent individual lesions for each patient.

3.3. Symptom Trajectories

Patient-reported outcomes demonstrated variable but generally positive trends. Pain, tenderness, and discomfort decreased from 2.90 to 2.30 on average ($\Delta = 0.60$), burning decreased from 2.60 to 1.50 ($\Delta = 1.10$), and hypersensitivity decreased from 3.20 to 1.60 ($\Delta = 1.60$). Blister/ulcer formation, discharge/secretion, and bleeding showed modest improvements ($\Delta = 0.10$–0.30). Interestingly, itch slightly increased from 1.90 to 2.10 ($\Delta = -0.20$) and swelling/edema from 1.50 to 1.60 ($\Delta = -0.10$), suggesting some persistent discomfort in these domains (Figure 2).

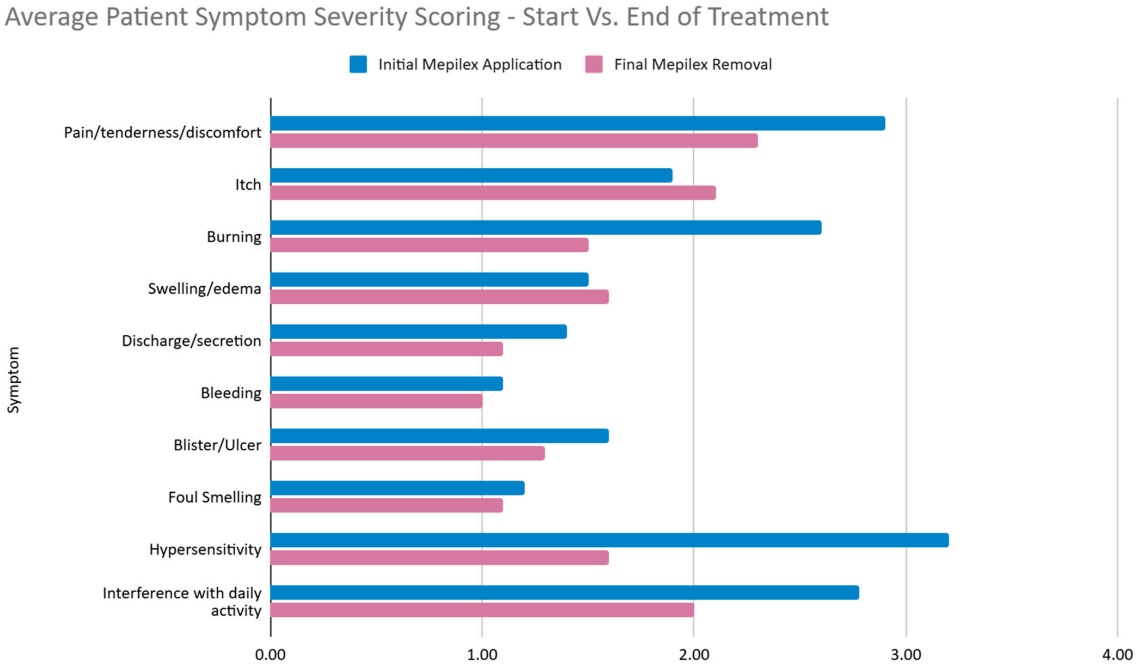

Figure 2. Patient symptom severity scoring—start vs. end of treatment.

Nurse-reported assessments showed reductions in pain/tenderness ($\Delta = 1.00$), burning ($\Delta = 0.70$), and hypersensitivity ($\Delta = 1.30$) (Figure 3). These findings describe changes in HCP-reported symptom scores and were not intended to establish agreement with patient-reported assessments.

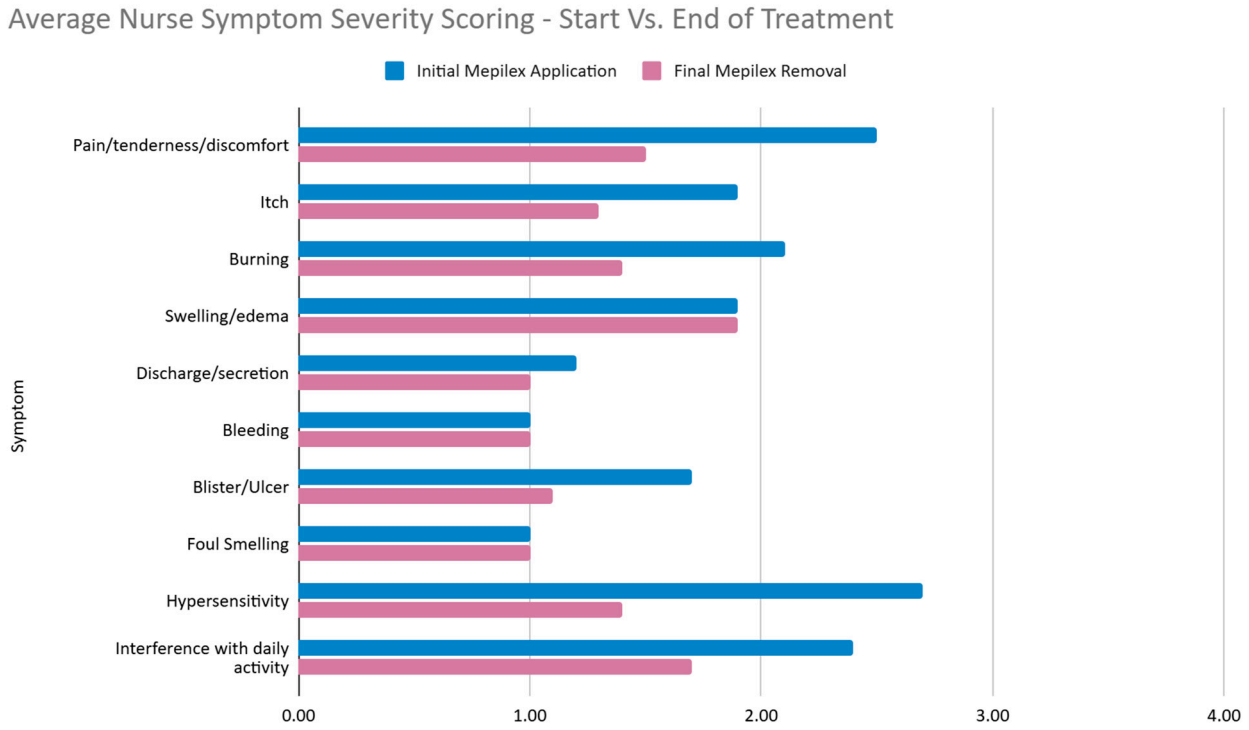

Figure 3. Nurse symptom severity scoring—start vs. end of treatment.

3.4. Additional Observations

Over the course of treatment, the number of dressing changes required varied substantially, ranging from 4 to 15 per patient, including changes performed at home. This variability may reflect differences in lesion severity, wound size, and degree of exudation across patients.

Six participants expressed a clear preference for Mepilex Lite over alternative topical products such as Proshield or Flamazine. Key reasons for this preference included improved coverage of the affected area, reduced friction from clothing or bedding, and enhanced comfort during daily activities. Patients described feeling protected and reassured by the dressing, with several noting that it allowed them to continue normal routines, including sleeping, dressing, and moving without significant pain or irritation.

4. Discussion

Current standards of practice for MD management, as outlined in international and national guidelines, emphasize the use of advanced wound dressings, topical agents, and supportive care strategies to promote healing, reduce symptoms, and protect affected skin [19]. The MASCC guidelines and Canadian clinical practice recommendations specifically endorse silicone-based foam dressings, such as Mepilex Lite, for the management of radiation-induced skin reactions [20,21].

MacBride et al. (2008) [22] evaluated Mepilex Lite in 16 patients (five breast, eleven head and neck cancer). While precise healing times were not reported, RISRAS scores improved faster than expected, with significant relief in pain and discomfort, better sleep, and improved daily functioning. Two patients withdrew due to itching, highlighting the

need for individualized sensitivity testing. Patients were also able to tailor dressings for comfort, a strategy reflected in the current study [22].

Diggelmann et al. (2010) assessed Mepilex Lite in 24 breast cancer patients with 34 erythematous areas in a randomized trial. Although healing time was not measured, RISRAS scores significantly decreased compared with standard aqueous cream ($p < 0.001$), without affecting skin temperature or radiation dose [17].

Paterson et al. (2012) conducted a randomized intra-patient-controlled trial comparing Mepilex Lite dressings with aqueous cream in women receiving postmastectomy radiotherapy. Of the 80 women recruited, 74 contributed complete data for analysis. Each participant's first erythematous chest-wall area was divided into two comparable regions, with one treated using Mepilex Lite and the other with aqueous cream. Although Mepilex Lite did not significantly reduce the incidence of MD (15% vs. 19%, $p = 0.55$) or the average time to healing (11 ± 2 vs. 13 ± 2 days, $p = 0.49$), it was associated with a lower average MD severity score (0.18 vs. 0.37, $p = 0.043$). The cumulative duration of MD across all patches was also 28% lower in the Mepilex Lite group, decreasing from 25 to 18 weeks. Most participants preferred Mepilex Lite, reporting that it was comfortable, easy to use, and helped protect the skin from friction [18].

Zhong et al. (2013) performed a single-center RCT with 88 nasopharyngeal carcinoma patients. Median MD healing time was 16 days for Mepilex Lite versus 23 days for controls ($p = 0.009$). Pain decreased significantly (VAS 5.31 vs. 6.89, $p = 0.02$) and sleep quality improved ($p = 0.005$), though neck mobility and appearance were not significantly affected [16].

Further evidence is provided by Wong et al. (2026) [23], who conducted a systematic review and meta-analysis of three randomized controlled trials involving 186 patients with radiation dermatitis, including two breast cancer cohorts and one nasopharyngeal cancer cohort. Their meta-analysis demonstrated significantly improved Radiation-Induced Skin Reaction Assessment Scale (RISRAS) scores with Mepilex Lite compared with standard care (mean difference −0.98, 95% CI −1.41 to −0.56; $p < 0.01$). However, substantial heterogeneity was observed ($I^2 = 96\%$). Although fewer cases of MD occurred in Mepilex-treated areas, the pooled reduction was not statistically significant (RR 0.73, 95% CI 0.40–1.31; $p = 0.29$). Healing outcomes also varied: Zhong et al. [16] reported shorter median healing time with Mepilex Lite (16 vs. 23 days; $p = 0.009$), whereas Paterson et al. [18] found no significant difference in average healing time (11 vs. 13 days; $p = 0.49$). Importantly, the included trials differed in when dressings were initiated, with some evaluating prevention following erythema and others treating established MD.

The present study builds on our previously published prospective observational study evaluating Mepilex dressings for radiation-induced MD in patients with head and neck (H&N) cancer [24]. Both studies used the same institutional research protocol, assessment tools, and general approach to dressing selection and follow-up, but involved separate, non-overlapping patient cohorts. In the H&N cohort, all 10 patients achieved improvement to Grade 1, with a mean time of 8.6 days (SD 3.9; median 7 days; range 2–17). Similarly, all patients in the present breast cohort improved to Grade 1, with a mean time of 10.4 days (median 10 days; range 7–19). Although the observed time was slightly longer in the breast cohort, direct comparisons are limited by differences in anatomical site, wound characteristics, radiation treatment parameters, and baseline severity [25].

Despite differences in the anatomical presentation of MD between H&N and breast cancer patients, both cohorts demonstrated favorable wound and symptom trajectories following Mepilex application. However, as both studies were uncontrolled observational investigations, these findings cannot establish treatment efficacy or distinguish the effects of Mepilex from the natural healing process following RT. Together, these studies provide

additional prospective evidence regarding the feasibility and tolerability of Mepilex-based wound care across different radiotherapy treatment sites.

The evidence underpinning these recommendations primarily derives from small cohort studies and randomized trials with varying designs and patient populations (Table 2). Paterson et al. and Diggelmann et al. evaluated Mepilex dressings initiated when patients exhibited erythema, rather than established MD, limiting conclusions about their effectiveness for full-thickness skin breakdown [17,18]. Zhong et al. focused on patients with nasopharyngeal carcinoma, not breast cancer, and did not report trajectories of patient-reported outcomes or detailed tolerability measures [16]. Our previously published prospective observational study by Kagan et al. evaluated Mepilex dressings in patients with established post-RT MD in H&N cancer, with all 10 patients improving to Grade 1, although its findings were limited by the small sample size and absence of a control group [24].

Table 2. Comparison of healing and symptoms with Mepilex across studies.

Study	Population & Sample	Intervention/ Dressing	Healing Time	Symptom Outcomes
Current study ($n = 10$)	Patients with breast cancer and post-RT MD	Mepilex Lite and Mepilex Ag	Mean 10.4 days (median 10, range 7–19)	Reduction in pain/tenderness, burning hypersensitivity and blister/ulcer/discharge.
MacBride et al., 2008 ($n = 16$) [22]	Caucasian patients, 5 breast, 11 head & neck	Mepilex Lite, patients adapted dressings individually	Healing not explicitly quantified; observed faster-than-expected improvement in RISRAS scores	RISRAS showed consistent improvement in all skin reaction aspects; improved comfort, reduced pain, better sleep; some itch in 2 patients led to withdrawal.
Zhong et al., 2013 ($n = 88$) [16]	Chinese, nasopharyngeal carcinoma; post-RT prophylactic	Mepilex Lite vs. standard care	Median 16 days (95% CI 12–19) vs. control 23 days (95% CI 19–27), $p = 0.009$	Patients treated with Mepilex Lite reported significantly less wound pain (mean score 5.31 vs. 6.89, $p = 0.02$) and better sleep quality ($p = 0.005$) compared to controls. No significant differences were observed for neck mobility ($p = 0.56$) or appearance disturbance ($p = 0.12$).
Kagan et al., 2026 ($n = 10$) [24]	Patients with H&N cancer and post-RT MD	Mepilex Lite and Mepilex Ag	Mean 8.6 days (SD 3.9; median 7, range 2–17)	All patients improved to Grade 1 MD, with favorable wound and symptom trajectories following Mepilex application.
Diggelmann et al., 2010 ($n = 24$) [17]	Female breast cancer patients	Mepilex Lite vs. standard aqueous cream	Not specifically reported; emphasis on RD severity reduction	Mepilex Lite dressings significantly reduced patient-reported symptoms of pain, itching, burning, and interference with daily activities; 17 of 24 patients reported that the dressings were soothing and provided noticeable relief from pain and friction.
Paterson et al., 2012 ($n = 74$) [18]	Post-mastectomy breast cancer patients with radiation-induced erythema	Mepilex Lite vs. aqueous cream; randomized intra-patient trial	Time to healing 11 ± 2 days vs. 13 ± 2 days; total MD duration of all individual patches 18 weeks vs. 25 weeks	Mepilex Lite did not significantly reduce the incidence of moist desquamation (15% vs. 19%; $p = 0.55$) but decreased overall skin reaction severity by 41% ($p < 0.001$) and mean moist desquamation scores by 49% ($p = 0.043$). Most patients (80%) preferred Mepilex Lite, citing comfort and ease of use.

Across the studies reviewed, improvements in pain, tenderness, burning, and other patient-reported symptoms were reported following the use of Mepilex dressings [16–18,22]. Differences in population demographics, cancer type, radiotherapy dose, and endpoint

definitions likely explain variations in healing times and symptom trajectories. Although these findings suggest potential benefits of Mepilex dressings for patient comfort and skin protection, differences in study design, populations, and treatment protocols limit direct comparisons across studies [16–19]

Assessment of MD severity remains challenging, and there is currently no universally accepted tool for evaluating the severity and progression of these lesions [26–29]. In the present study, investigator-developed grading tools and symptom questionnaires were used to document MD severity, associated symptoms, and patient-reported outcomes over time (Appendices A–D). These instruments were not formally validated, and inter-rater reliability was not assessed. Future studies should evaluate their reliability, sensitivity to change, and agreement with established instruments such as RISRAS.

The parallel patient- and HCP-reported assessments provided complementary perspectives on symptom severity. Patient scores reflected participants' own experiences, whereas HCP scores reflected clinical observations and discussions with patients. Patients often reported ongoing discomfort, itching, or hypersensitivity that was not fully captured by clinical observation, highlighting the subjective nature of some symptoms. It is possible that part of this persistent itching could be related to the dressing itself, as even silicone-based or foam dressings may occasionally cause irritation, particularly with prolonged wear or in sensitive skin. Conversely, nurses and physicians sometimes noted objective changes, such as reduced exudation or erythema, that patients did not perceive as improvement. These findings underscore the importance of incorporating both patient-reported outcomes and clinical assessments in routine care [30], not only to evaluate MD severity and progression, but also to identify any dressing-related effects that might contribute to discomfort.

Patient feedback regarding dressing preferences further highlights the impact of treatment beyond objective wound healing. The comfort and reassurance associated with having affected skin covered appeared to be important aspects of the patient experience, alongside changes in wound appearance and symptoms. Patients in the present study described favourable experiences related to wound coverage, reduced friction, and comfort during Mepilex-based wound care. However, the uncontrolled study design does not allow these experiences to be attributed solely to the dressings.

Limitations

Several limitations of the present study should be acknowledged. First, the small sample size and absence of a comparator group limit the ability to determine whether observed changes in MD severity, symptoms, or healing time to Grade 1 were attributable to Mepilex dressings. Improvements may also have reflected natural wound healing, prior or concurrent treatments, or other aspects of supportive care. Patients were assessed at dressing changes, typically every 2–3 days, rather than daily. Consequently, the exact date of MD resolution could not be determined, and MD resolution was based on the first assessment documenting Grade 1 MD. The limited assessment frequency may also have resulted in new lesions developing between visits without being captured.

Information regarding the specific topical treatments used before enrolment was not consistently available at the patient level. Consequently, the potential influence of prior topical treatments on baseline MD severity and subsequent outcomes could not be reliably assessed. Dressing selection was based on clinical presentation rather than randomization, and different Mepilex products were used across patients. Therefore, the study cannot establish comparative differences between Mepilex Lite formats and Mepilex Ag.

The investigator-developed grading tools and symptom questionnaires were not formally validated, and inter-rater reliability was not assessed. In addition, patients with multiple lesions contributed correlated observations, limiting the interpretation of lesion-

level findings. Future studies with larger sample sizes, comparator groups, standardized co-interventions, validated assessment tools, and more frequent wound assessments are needed to better characterize MD progression and evaluate the contribution of advanced dressings to wound care.

5. Conclusions

This prospective observational study describes the clinical course of radiation-induced MD in breast cancer patients receiving Mepilex dressings as part of their wound care. Improvements in pain, burning, and hypersensitivity were observed during follow-up, while patients reported benefits related to comfort, skin coverage, and reduced friction. Although these findings provide preliminary insight into patient experiences and symptom changes during Mepilex-based wound care, the contribution of the dressings to healing and symptom improvement cannot be established. Larger comparative studies using standardized treatment protocols and validated assessment tools are warranted.

Author Contributions: Data curation was performed by S.K., Y.K., B.Z., C.Y., S.V., A.H.S., I.K. and E.C. Formal analysis was carried out by S.K. Investigation was conducted by S.K., Y.K., B.Z., C.Y., S.V., H.C.Y.W., A.H.S. and S.B. Methodology was developed by S.K., C.Y., I.K. and E.C. Supervision was provided by I.K. and E.C. Writing—original draft was completed by S.K., while writing—review and editing involved S.K., Y.K., B.Z., C.Y., S.V., H.C.Y.W., A.H.S., I.K., S.S.W.T., S.F.L., S.B. and E.C. Conceptualization was contributed by E.C. All authors have read and agreed to the published version of the manuscript.

Funding: Mepilex dressings were provided free of charge by Mölnlycke Health Care, which had no role in the study's design, data analysis, or reporting of results.

Institutional Review Board Statement: This study was approved by Sunnybrook Health Sciences Centre's Research Ethics Board (REB #: SUN-6680) on 7 July 2025.

Informed Consent Statement: Informed consent was obtained from all individual participants included in the study.

Data Availability Statement: The original contributions presented in this study are included in the article. Further inquiries can be directed to the corresponding author.

Conflicts of Interest: The authors declare no conflicts of interest.

Appendix A. Moist Desquamation Grading Tool for HCP

Study ID: _____ Date of assessment (dd/mm/yyyy): _____
Completed by: _____
Appointment Type (please circle): before/after RT review clinic follow-up
If during RT, what fraction of radiation completed: _____
If review clinic, what review appointment: 1 2 3 4 5 6 7
If follow-up, which follow-up (e.g., 1-week, 2-week): _____

Grade 0	No dry or moist desquamation
Grade 1	Dry desquamation
Grade 2	Moist desquamation with minimal exudate and/or with granulation tissue
Grade 3	Moist desquamation with moderate/copious exudate and no clinical signs of infection
Grade 4	Moist desquamation with clinical signs of infection and/or necrosis
Grade 5	Death

Subgroup Descriptions:

To capture other important clinical features, consider appending subgroup descriptor(s) to any grade:

- A (Blister);
- B (Bleeding);
- C (Ulceration).

Appendix B. Moist Desquamation Grading Tool for Patient

Study ID: _____ Date of assessment (dd/mm/yyyy): _____
Appointment Type (please circle): before/after RT review clinic follow-up
If during RT, what fraction of radiation completed: _____
If review clinic, what review appointment: 1 2 3 4 5 6 7
If follow-up, which follow-up (e.g., 1-week, 2-week): _____

Grade 0	No dry or moist desquamation
Grade 1	Dry desquamation
Grade 2	Moist desquamation with minimal discharge/secretions and/or with granulation tissue
Grade 3	Moist desquamation with moderate/severe discharge/secretions and no clinical signs of infection (i.e., pus)
Grade 4	Moist desquamation with clinical signs of infection (i.e., pus) and/or necrosis
Grade 5	Death

Subgroup Descriptions:

To capture other important clinical features, consider appending subgroup descriptor(s) to any grade:

- A (Blister);
- B (Bleeding);
- C (Ulceration).

Appendix C. 10-Item Patient Reported Outcomes for Moist Desquamation

Study ID: _____ Date of assessment (dd/mm/yyyy): _____
Appointment Type (please circle): before/after RT review clinic follow-up
If during RT, what fraction of radiation completed: _____
If review clinic, what review appointment: 1 2 3 4 5 6 7
If follow-up, which follow-up (e.g., 1-week, 2-week): _____

Please circle the word that best describes your symptoms in the area receiving radiation right now.

Pain, tenderness or discomfort			
None	Mild	Moderate	Severe
Itch			
None	Mild	Moderate	Severe
Burning sensation			
None	Mild	Moderate	Severe
Swelling or edema			
None	Mild	Moderate	Severe
Discharge or secretion			
None	Mild	Moderate	Severe

Bleeding			
None	Mild	Moderate	Severe
Blister or ulcer			
None	Mild	Moderate	Severe
Foul smelling			
None	Mild	Moderate	Severe
Hypersensitivity to touch, temperature, or light			
None	Mild	Moderate	Severe
Interference with daily activities			
None	Mild	Moderate	Severe

Appendix D. 10-Item HCP Reported Outcomes for Moist Desquamation

Study ID: _____ Date of assessment (dd/mm/yyyy): _____

Completed by: _____

Appointment Type (please circle): before/after RT review clinic follow-up

If during RT, what fraction of radiation completed: _____

If review clinic, what review appointment: 1 2 3 4 5 6 7

If follow-up, which follow-up (e.g., 1-week, 2-week): _____

Please circle the word that best describes your symptoms in the area receiving radiation right now.

Pain, tenderness or discomfort			
None	Mild	Moderate	Severe
Itch			
None	Mild	Moderate	Severe
Burning sensation			
None	Mild	Moderate	Severe
Swelling or edema			
None	Mild	Moderate	Severe
Discharge or secretion			
None	Mild	Moderate	Severe
Bleeding			
None	Mild	Moderate	Severe
Blister or ulcer			
None	Mild	Moderate	Severe
Foul smelling			
None	Mild	Moderate	Severe
Hypersensitivity to touch, temperature, or light			
None	Mild	Moderate	Severe
Interference with daily activities			
None	Mild	Moderate	Severe

References

1. Gruber, G. Escalation and De-Escalation of Adjuvant Radiotherapy in Early Breast Cancer: Strategies for Risk-Adapted Optimization. *Cancers* **2024**, *16*, 2946. [CrossRef] [PubMed]
2. Demircan, N.V.; Bese, N. New Approaches in Breast Cancer Radiotherapy. *Eur. J. Breast Health* **2023**, *20*, 1–7. [CrossRef] [PubMed]
3. Ramseier, J.Y.; Ferreira, M.N.; Leventhal, J.S. Dermatologic Toxicities Associated with Radiation Therapy in Women with Breast Cancer. *Int. J. Womens Dermatol.* **2020**, *6*, 349–356. [CrossRef] [PubMed]
4. Schnur, J.B.; Love, B.; Scheckner, B.L.; Green, S.; Wernicke, A.G.; Montgomery, G.H. A Systematic Review of Patient-Rated Measures of Radiodermatitis in Breast Cancer Radiotherapy. *Am. J. Clin. Oncol.* **2011**, *34*, 529–536. [CrossRef] [PubMed]
5. Salvo, N.; Barnes, E.; van Draanen, J.; Stacey, E.; Mitera, G.; Breen, D.; Giotis, A.; Czarnota, G.; Pang, J.; De Angelis, C. Prophylaxis and Management of Acute Radiation-Induced Skin Reactions: A Systematic Review of the Literature. *Curr. Oncol.* **2010**, *17*, 94–112. [CrossRef] [PubMed]
6. Kole, A.J.; Kole, L.; Moran, M.S. Acute Radiation Dermatitis in Breast Cancer Patients: Challenges and Solutions. *Breast Cancer* **2017**, *9*, 313–323. [CrossRef] [PubMed]

7. Bray, F.N.; Simmons, B.J.; Wolfson, A.H.; Nouri, K. Acute and Chronic Cutaneous Reactions to Ionizing Radiation Therapy. *Dermatol. Ther.* **2016**, *6*, 185–206. [CrossRef] [PubMed]
8. Rübe, C.E.; Freyter, B.M.; Tewary, G.; Roemer, K.; Hecht, M.; Rübe, C. Radiation Dermatitis: Radiation-Induced Effects on the Structural and Immunological Barrier Function of the Epidermis. *Int. J. Mol. Sci.* **2024**, *25*, 3320. [CrossRef] [PubMed]
9. Burke, G.; Faithfull, S.; Probst, H. Radiation Induced Skin Reactions during and Following Radiotherapy: A Systematic Review of Interventions. *Radiography* **2022**, *28*, 232–239. [CrossRef] [PubMed]
10. Suresh, R.; Raffi, J.; Yuen, F.; Murase, J.E. Treatment of Moist Desquamation for Patients Undergoing Radiotherapy. *Int. J. Womens Dermatol.* **2019**, *5*, 124–125. [CrossRef] [PubMed]
11. Zasadziński, K.; Spałek, M.J.; Rutkowski, P. Modern Dressings in Prevention and Therapy of Acute and Chronic Radiation Dermatitis—A Literature Review. *Pharmaceutics* **2022**, *14*, 1204. [CrossRef] [PubMed]
12. Iacovelli, N.A.; Torrente, Y.; Ciuffreda, A.; Guardamagna, V.A.; Gentili, M.; Giacomelli, L.; Sacerdote, P. Topical Treatment of Radiation-Induced Dermatitis: Current Issues and Potential Solutions. *Drugs Context* **2020**, *9*, 2020-4-7. [CrossRef] [PubMed]
13. Mölnlycke. Mepilex Foam Absorbent Dressing for Treating Chronic and Acute Wounds. Available online: http://www.molnlycke.ca/products-solutions/mepilex/ (accessed on 5 October 2025).
14. Nuutila, K.; Eriksson, E. Moist Wound Healing with Commonly Available Dressings. *Adv. Wound Care* **2021**, *10*, 685–698. [CrossRef] [PubMed]
15. Mölnlycke. Mepilex Ag Antimicrobial Foam Dressing with Silver and Soft Silicone. Available online: http://www.molnlycke.ca/products-solutions/mepilex-ag/ (accessed on 20 October 2025).
16. Zhong, W.H.; Tang, Q.F.; Hu, L.Y.; Feng, H.X. Mepilex Lite Dressings for Managing Acute Radiation Dermatitis in Nasopharyngeal Carcinoma Patients: A Systematic Controlled Clinical Trial. *Med. Oncol.* **2013**, *30*, 761. [CrossRef] [PubMed]
17. Diggelmann, K.V.; Zytkovicz, A.E.; Tuaine, J.M.; Bennett, N.C.; Kelly, L.E.; Herst, P.M. Mepilex Lite Dressings for the Management of Radiation-Induced Erythema: A Systematic Inpatient Controlled Clinical Trial. *Br. J. Radiol.* **2010**, *83*, 971–978. [CrossRef] [PubMed]
18. Paterson, D.; Poonam, P.; Bennett, N.C.; Peszynski, R.I.; Van Beekhuizen, M.J.; Jasperse, M.L.; Herst, P.M. Randomized Intra-Patient Controlled Trial of Mepilex Lite Dressings versus Aqueous Cream in Managing Radiation-Induced Skin Reactions Postmastectomy. *J. Cancer Sci. Ther.* **2012**, *4*, 347–356.
19. Finkelstein, S.; Kanee, L.; Behroozian, T.; Wolf, J.R.; van den Hurk, C.; Chow, E.; Bonomo, P. Comparison of Clinical Practice Guidelines on Radiation Dermatitis: A Narrative Review. *Support. Care Cancer* **2022**, *30*, 4663–4674. [CrossRef] [PubMed]
20. Cao, J.Q.; Yassa, M.; Avella Bolivar, C.H.; Dahn, H.; Kong, I.; Logie, N.; Théberge, V.; Wiebe, E.; Caudrelier, J.-M.; Bourque, J.-M.; et al. Modified Delphi Consensus on Interventions for Acute Radiation Dermatitis in Breast Cancer: A Canadian Expert Perspective. *Int. J. Radiat. Oncol. Biol. Phys.* **2025**, *122*, 267–274. [CrossRef] [PubMed]
21. Behroozian, T.; Bonomo, P.; Patel, P.; Kanee, L.; Finkelstein, S.; van den Hurk, C.; Chow, E.; Wolf, J.R. Multinational Association of Supportive Care in Cancer (MASCC) Oncodermatology Study Group Radiation Dermatitis Guidelines Working Group. Multinational Association of Supportive Care in Cancer (MASCC) Clinical Practice Guidelines for the Prevention and Management of Acute Radiation Dermatitis: International Delphi Consensus-Based Recommendations. *Lancet Oncol.* **2023**, *24*, e172–e185. [CrossRef] [PubMed]
22. MacBride, S.K.; Wells, M.E.; Hornsby, C.; Sharp, L.; Finnila, K.; Downie, L. A Case Study to Evaluate a New Soft Silicone Dressing, Mepilex Lite, for Patients with Radiation Skin Reactions. *Cancer Nurs.* **2008**, *31*, E8–E14. [CrossRef] [PubMed]
23. Wong, H.C.Y.; Zhang, B.; Kagan, S.; Yang, C.; Tse, S.S.W.; Tang, L.; Hircock, C.; Lee, S.F.; Hijal, T.; Safavi, A.H.; et al. Mepilex Lite Dressing in the Management of Radiation Dermatitis—A Systematic Review and Meta-Analysis of Randomized Controlled Trials. Support. *Care Cancer* **2026**, *34*, 625. [CrossRef] [PubMed]
24. Kagan, S.; Kagan, Y.; Yoganathan, T.; Galapin, M.; Yang, C.; Zhang, B.; Verma, S.; Wong, H.C.Y.; Safavi, A.H.; Tjong, M.C.; et al. Mepilex Dressings in Managing Radiation-Induced Moist Desquamation in Head and Neck Cancer. *Radiation* **2026**, *6*, 21. [CrossRef]
25. Rios-Ibacache, O.; Manalad, J.; O'Sullivan-Steben, K.; Poon, E.; Galarneau, L.; Khriguian, J.; Shenouda, G.; Kildea, J. Quantification of Head and Neck Cancer Patients' Anatomical Changes during Radiotherapy: Toward the Prediction of Replanning Need. *J. Appl. Clin. Med. Phys.* **2026**, *27*, e70465. [CrossRef] [PubMed]
26. Duzenli, C.; Chan, E.K.; Koulis, T.; Grahame, S.; Singer, J.; Morris, D.; Spence, J.; Lee, T.; Burns, L.; Olson, R.A. Validation of a Patient-Reported Outcome Measure for Moist Desquamation among Breast Radiotherapy Patients. *Curr. Oncol.* **2022**, *29*, 4734–4747. [CrossRef] [PubMed]
27. Bontempo, P.D.S.M.; Menêses, A.G.D.; Ciol, M.A.; Ferreira, E.B.; Dos Reis, P.E.D. Instruments and Scales for the Evaluation of Acute Radiation Dermatitis: A Systematic Review. *Crit. Rev. Oncol. Hematol.* **2023**, *191*, 104116. [CrossRef] [PubMed]
28. Lapen, K.; King, C.; Braunstein, L.Z.; Khan, A.J.; Kamrava, M.R.; Gillespie, E.F.; Cook, K.A. A Comparison of Patient- and Clinician-Reported Acute Toxic Effects During Radiation Therapy for Primary Breast Cancer. *Int. J. Radiat. Oncol. Biol. Phys.* **2022**, *114*, 301–309. [CrossRef] [PubMed]

29. Shumway, D.A.; Kapadia, N.; Walker, E.M.; Griffith, K.A.; Do, T.T.; Feng, M.; Boike, T.; Helfrich, Y.; DePalma, B.; Gillespie, E.F.; et al. Development of an Illustrated Scale for Acute Radiation Dermatitis in Breast Cancer Patients. *Pract. Radiat. Oncol.* **2021**, *11*, 168–176. [CrossRef] [PubMed]
30. Rotenstein, L.S.; Agarwal, A.; O'Neil, K.; Kelly, A.; Keaty, M.; Whitehouse, C.; Kalinowski, B.; Orio, P.F., III; Wagle, N.; Martin, N.E. Implementing Patient-Reported Outcome Surveys as Part of Routine Care: Lessons from an Academic Radiation Oncology Department. *J. Am. Med. Inform. Assoc.* **2017**, *24*, 964–968. [CrossRef] [PubMed]

Disclaimer/Publisher's Note: The statements, opinions and data contained in all publications are solely those of the individual author(s) and contributor(s) and not of MDPI and/or the editor(s). MDPI and/or the editor(s) disclaim responsibility for any injury to people or property resulting from any ideas, methods, instructions or products referred to in the content.