



Case Report

Intraoperative Flow Cytometry Upon and Beyond the Cell Cycle: A Case Study of the Characterization of a Bone Metastasis

Georgios S. Markopoulos ¹, Emiliós E. Pakos ², Vasilios Gavrielatos ², Dimitrios Kosmas ², Ioannis Gkiatas ², George A. Alexiou ³, Anna Batistatou ⁴, Evangelí Lampri ⁴ and George Vartholomatos ^{1,*}

¹ Haematology Laboratory, Unit of Molecular Biology and Translational Flow Cytometry, University Hospital of Ioannina, 45110 Ioannina, Greece; geomarkop@gmail.com

² Department of Orthopaedic Surgery, University of Ioannina, 45110 Ioannina, Greece; epakos@yahoo.gr (E.E.P.); vasiliosgavrielatos@gmail.com (V.G.); kosm.dmt@gmail.com (D.K.); john.gkiatas@gmail.com (I.G.)

³ Department of Neurosurgery, University Hospital of Ioannina, 45500 Ioannina, Greece; galexiou@uoi.gr

⁴ Department of Pathology, University Hospital of Ioannina, 45500 Ioannina, Greece; abatista@uoi.gr (A.B.); elampri@uoi.gr (E.L.)

* Correspondence: gvarthol@gmail.com

Abstract: The accurate assessment of malignancy and the precise characterization of cancer type are pivotal in guiding clinical decisions and ensuring optimal patient outcomes. The challenging task of identifying the primary site of carcinoma, especially during a surgical procedure, is not always possible and necessitates the exploration of novel, innovative diagnostic techniques. In this report, we detail a unique case of carcinoma of unknown primary origin encountered during an orthopedic surgical procedure. We introduce a novel intraoperative flow cytometry (iFC) methodology, distinctly different from traditional flow cytometry, which is tailored for real-time assessment during surgeries. This iFC technique, applied in a bone metastasis case of unknown primary origin, enabled DNA content analysis and the quantification of cytokeratin for rapid malignancy characterization, presenting an avenue for immediate surgical guidance and decision making. The case was distinctively characterized using iFC, shedding light on the potential of this emerging technique. iFC has been gaining traction because of its ability to facilitate cancer cell assessment and margin evaluation. It has been successfully applied across a wide spectrum of neoplastic conditions. Our innovative, two-step approach using iFC encompasses (1) DNA content analysis, which serves as a reliable indicator for the detection of cancer cells, and (2) the quantification of cytokeratin, a pivotal marker, which aids in the characterization and classification of a malignancy. In this case, the malignancy was classified as a carcinoma. The findings obtained from iFC were subsequently validated through pathology assessment, confirming the accuracy and reliability of our approach. This noteworthy case strengthens the potential of iFC as a novel tool in malignancy assessment, which is not just limited to cell cycle analysis but instead extends beyond this application. The promising results obtained from this case study serve as a testament to the need for more extensive research in clinical studies.

Keywords: cancer; surgical treatment; flow cytometry; bone metastasis; surgical oncology



Citation: Markopoulos, G.S.; Pakos, E.E.; Gavrielatos, V.; Kosmas, D.; Gkiatas, I.; Alexiou, G.A.; Batistatou, A.; Lampri, E.; Vartholomatos, G. Intraoperative Flow Cytometry Upon and Beyond the Cell Cycle: A Case Study of the Characterization of a Bone Metastasis. *J. Mol. Pathol.* **2023**, *4*, 225–233. <https://doi.org/10.3390/jmp4040020>

Academic Editor: Giancarlo Troncone

Received: 22 August 2023

Revised: 19 October 2023

Accepted: 23 October 2023

Published: 25 October 2023

Corrected: 20 March 2026



Copyright: © 2023 by the authors. Licensee MDPI, Basel, Switzerland. This article is an open access article distributed under the terms and conditions of the Creative Commons Attribution (CC BY) license (<https://creativecommons.org/licenses/by/4.0/>).

1. Introduction

Globally, cancer remains a predominant cause of human mortality worldwide, with its complex nature and diverse types posing significant challenges to medical professionals [1]. In most countries, cancer is among the two main causes of deaths, and surgical management is the first-line treatment for four out of five cancer cases since it has been estimated that more than 80% of the >15 million cancer cases in 2015 were candidates for surgical treatment [2]. The low mortality rate and morbidity following surgery and the prospective of complete tumor removal are among the main advantages, making surgery the method of choice, with a projection that by 2030, >45 million surgical procedures will be

performed regarding tumor removal [2]. The main objectives of surgical oncology are maximizing tumor removal as well as the characterization of a tumor to optimize subsequent clinical management.

Among the numerous cancer types, cancer of unknown primary site (CUP) stands out as a rare type of malignancy, accounting for <5% of cancers. However, because of its high mortality rate, its relative contribution to cancer deaths is higher than the average [3]. Diagnosing cancer of unknown primary site is challenging due to its unique nature. Typically, the origin of a tumor is identified through a combination of histopathological examination using specific markers and radiological assessment [4]. The diagnosis is made more complex by the morphological similarities between CUP and other types of epithelial tumors. Even with radiological assessments, identifying the primary site can be elusive, especially for early-stage or small-sized tumors, which may present a problem in the optimal clinical management of the patient.

Flow cytometry is among the most effective single-cell analysis techniques, with several applications in cancer analysis: immunophenotyping, the characterization of hematological malignancies, revealing measurable residual disease, ploidy, and cell cycle assessment. Intraoperative Flow Cytometry (iFC) is a recent advancement in cytometry that utilizes the analysis of DNA content/ploidy and cell cycle distribution during the surgical resection of tumors to characterize cancer cells and evaluate tumor margins, offering the potential for complete removal. iFC represents a modification of the traditional flow cytometry concept, designed to be employed during surgical procedures in order to provide near real-time data to surgeons. While the basic principles remain the same, iFC allows for the rapid assessment of tissue samples in the operating room, which can significantly aid in clinical decision making. iFC is currently applied in treating brain [5], head and neck [6], breast [7], liver [7], colorectal [8], gynecological [9], and bladder cancer, among others [10]. The aforementioned applications of iFC are all based solely on the DNA content analysis of cancer versus normal cells and represent methodologies with high accuracy that, in many cases, can be more than 90%.

This report presents an original application of iFC: its use in detecting cancer cells during orthopedic surgery. Additionally, this case study introduces a novel approach to the use of iFC, beyond DNA content and cell cycle analysis, for the intraoperative immunophenotyping of solid tumors via quantifying pancytokeratin, further expanding its potential applications. The innovative use of iFC in this case not only underscores its potential in enhancing surgical outcomes but also paves the way for its broader applications in the diagnosis and management of various cancer types.

2. Materials and Methods

2.1. Study Sample

The 77-year-old patient under study underwent resection at the Department of Orthopaedic Surgery, University Hospital of Ioannina (UHI). The operation was performed by experienced orthopaedic surgeons. Ethical approval was obtained from the University Hospital of Ioannina on 3 March 2020 (Protocol number: 1431/3-3-2020). Informed consent was obtained from the patient for participation in the current study.

2.2. Tissue Sampling

During the orthopedic surgery, a representative sample (approximately 5 mm² in volume) was excised from the tumor tissue. One portion was sent for flow cytometry analysis, while the other was reserved for pathology evaluation. The pathological assessment was conducted by an experienced pathologist.

2.3. DNA Content Analysis

The DNA analysis of the tumor was executed in line with the Ioannina Protocol, a methodology initially devised for intraoperative assessment of brain malignancies [5]. Briefly, the tissue sample was homogenized via mincing using a Medimachine System

(BD Bioscience, Franklin Lakes, NJ, USA) for a duration of one minute in a standard phosphate-buffered saline solution, resulting in a suspension containing single cells. This suspension was then diluted to achieve a final concentration of 10^6 cells/mL based on a count obtained using an automated hematology analyzer. Subsequently, the homogenized cell suspension was stained with a propidium iodide solution (125 $\mu\text{g/mL}$) for three minutes and promptly subjected to flow cytometric analysis. Control peripheral blood mononuclear cells (PBMCs) were prepared via isolation from whole blood using a Ficoll gradient (Ficoll–Paque separation, GE Healthcare, Chicago, IL, USA), and they were stained in the same manner as the tumor samples. The necessity of using PBMCs, although they are not of the same tissue origin as tumor cells, lies in the fact that PBMCs are characterized by a stable diploid population with a low proliferative potential; this population serves as a reliable reference for assessing both the DNA content of tumor cells as well as their cell cycle distribution.

The iFC analysis was conducted utilizing a FACSCalibur flow cytometer with the aid of CellQuest software V3.1 (Both by BD Bioscience). To establish a normal standard for identifying the diploid peak of cells in the G0/G1 phase, the mean fluorescence of PBMCs was used. Generally, 5000 gated events (stained cell nuclei) per sample were assessed. Post-acquisition analysis was undertaken to determine the DNA index and Tumor index. The DNA index, indicative of each cell's ploidy status, is computed as the ratio of the geometric mean corresponding to the G0/G1 peak of a sample to that of the PBMCs. A DNA index exceeding 1.1 signifies a hyperploid cell, while a DNA index below 0.9 indicates a hypoploid cell. A DNA index value of 1 corresponds to diploid cancer cells. The Tumor index, on the other hand, provides insights into the proliferation rate of cancer cells and is derived from the cumulative percentage of cells present in both the S and G2/M phases.

2.4. Immunostaining for Characterization and Classification of Cancer Cells

iFC Analysis of Cytokeratin Expression: For the characterization of cancer cells using iFC, cytokeratin expression was analyzed. The process was divided into three main steps: (1) Isotypic control analysis—an analysis of an isotypic control, specifically mouse IgG1-FITC, was initially performed to determine the autofluorescence signal, ensuring that any subsequent fluorescence observed was due to specific antibody binding and was not inherent to the cells; (2) cytokeratin-FITC analysis—an analysis of cytokeratin expression was performed using a pan cytokeratin-specific antibody (FITC Mouse Anti-Human Cytokeratin Clone CAM5.2, BD Bioscience) that was conjugated with fluorescein isothiocyanate (FITC), where a fluorescence signal beyond autofluorescence is indicative of the presence and level of cytokeratin expression in the sample; and (3) overlay analysis—this step consists of an overlay of the isotypic control and the cytokeratin-FITC signals that offers a comparative view, allowing for a clear differentiation between autofluorescence and specific cytokeratin expression.

Immunohistochemical staining: Post iFC analysis, the tumor cells were further subjected to immunohistochemical staining by an experienced pathologist to validate and expand upon the findings. The expression of pancytokeratin; keratins 5/6, 7, 8, 18, and 19; vimentin; EMA; p63; mesothelin; calretinin; HMB45; MelanA; S100; TTF1; keratin 20; CD117; GATA3; and PAX8 was analyzed (using specific antibodies) to provide insights into the tumor's cellular differentiation.

2.5. Statistical Analysis

The two-sample Kolmogorov–Smirnov Test was utilized to validate that the distribution of cytokeratin expression is significantly different from that of the autofluorescence signal. A *p*-value less than 0.05 was considered significant.

3. Results

3.1. Case Presentation

A 77-year-old male patient, with only a history of hypertension known, presented to our outpatient clinic with pain on his right scapula and right ulnar nerve palsy. The symptoms, cervicalgia, started 3 months before examination and progressively started to worsen. The patient was sent for a magnetic resonance imaging (MRI) full-body scan. The MRI and full-body scan revealed a primary malignant tumor of the scapula with multiple secondary metastases. The following day, the patient underwent surgery for an open mass biopsy. During the open mass biopsy procedure, a sample was sent for intraoperative flow cytometry, and the rest of the biopsied mass was sent for pathology assessment.

3.2. Intraoperative Analysis and Pathology Evaluation

DNA analysis according to the Ioannina Protocol was performed immediately after tumor excision, as previously described [5] (see Section 2 for a detailed description of the protocol). The results of the DNA content analysis are presented in Figure 1. Following analysis, two indices were calculated: first, the DNA index, based on the ratio of the geometric mean of the G0/G1 peak of cancer cells to that of normal cells, and, second, the Tumor index, which indicates the percentage of proliferating cancer cells and corresponds to the percentage of cells in the S and G2/M cell cycle phases. In our case, the cancer was hyperploid, with a DNA index of 1.7 as well as a highly proliferating neoplasia, with a Tumor index of 17%. The results of the DNA analysis were confirmed through pathological assessment (Figure 1B). Hematoxylin and eosin (H&E)-stained sections revealed central necrosis in tumor nests and nuclear polymorphism.

Next, we performed an immunophenotyping analysis of the marker cytokeratin and immediately analyzed the results using flow cytometry (Figure 2A). The cancer cells were found to express cytokeratin (Figure 2B).

According to the histopathologic report, pieces of neoplastic tissue were found within blood clots, presenting sites of infiltration of connective tissue. The neoplastic cells were mainly arranged perivascularly in thick bands and nests and in vague papillary structures. Areas with necrosis were identified. The neoplastic cells were large, with an ovoid, light-colored nucleus; small nucleoli; and eosinophilic or clear cytoplasm. The level of nuclear polymorphism was moderate, while multinucleated neoplastic forms were also recognized. There were many mitoses, some of them atypical. Hemorrhagic infiltration, hemosiderin deposits, scattered polynuclear giant cells of the osteoclastic type, and, rarely, bony trabecular were observed in the stroma.

Immunohistochemically, the neoplastic cells expressed pancytokeratin and keratins 8, 18, and 19, and 30% of them expressed vimentin. Only a few cells were positive for EMA and keratins 5/6 and 7. The immunostains for p63, mesothelin, calretinin, HMB45, MelanA, S100, TTF1, keratin 20, CD117, GATA3, and PAX8 were negative. The above findings are consistent with carcinoma, but it was not possible to identify the primary site.

Cytokeratin expression was found intraoperatively via iFC and confirmed using the gold standard, i.e., pathology immunostaining. Cytokeratin expression can assist in the differential diagnosis between carcinoma and mesenchymal-type neoplasms such as chondrosarcoma [11].

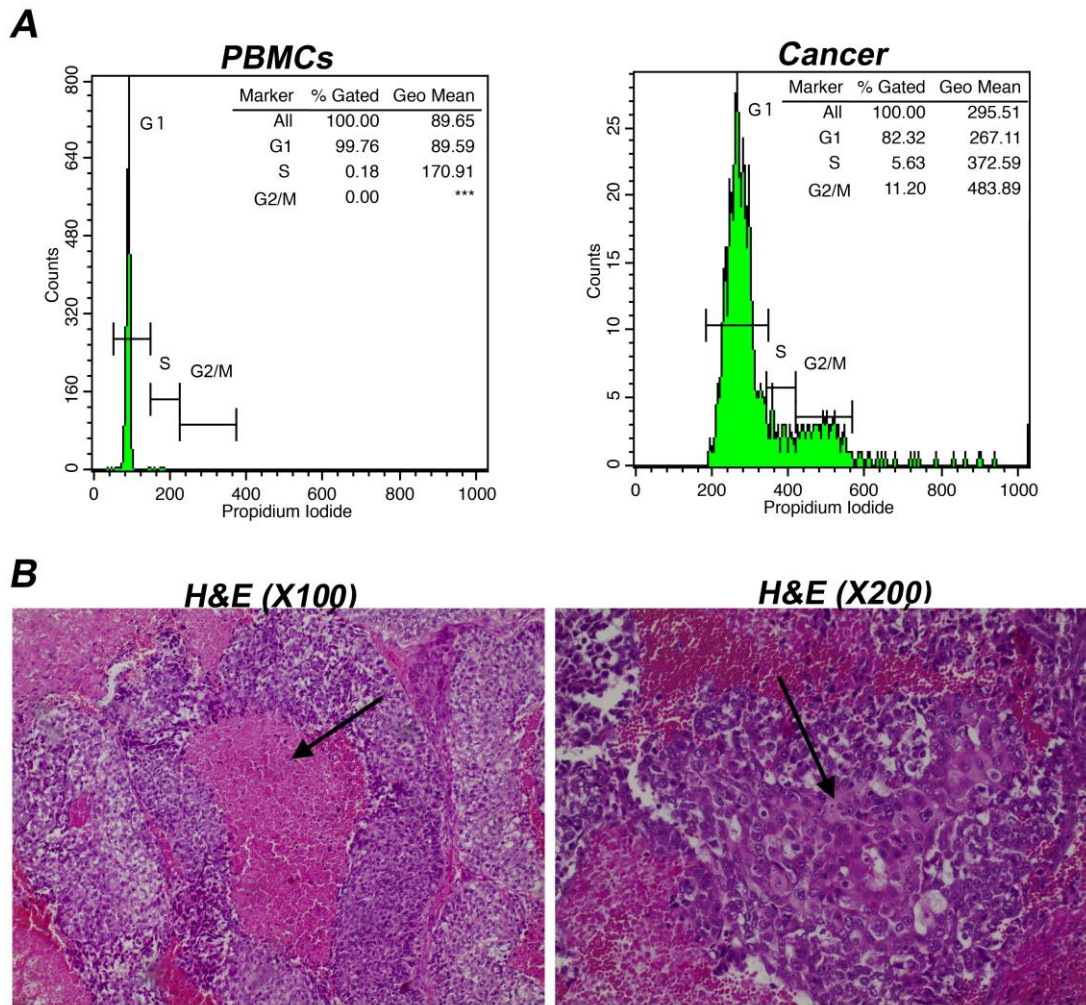


Figure 1. Detection of cancer cells via iFC and pathology assessment. **(A)** The preanalytical step requires staining with propidium iodide to bind nucleic acids. Left panel: Analysis of DNA content in peripheral blood mononuclear cells (PBMCs); right panel: analysis of DNA content in a sample derived from a tumor tissue. The presented histograms are separated into 3 different areas via the respective markers that correspond, based on the mean fluorescence, to cells in the G1, S, and G2/M phases, respectively. Cells in G2/M are characterized by a dual mean fluorescence intensity, which is not present for the cells in G1, due to the completion of DNA replication. Cells in S phase (undergoing DNA replication) are characterized by a mean fluorescence intensity between cells in G1 and G2/M phases. The percentage of cells in each phase (presented in the upper right in each histogram) was used to quantify markers that were used to determine malignancy. A total of 5000 gated nuclei were analyzed (cell counts are 4992 versus 4128 in G1, 9 versus 282 in S, and 0 versus 561 in G2/M between normal and cancer cell samples, respectively). *** stand as no cells present in the current gate **(B)** Representative images of hematoxylin and eosin (H&E)-stained sections in X100 and X200 magnification, respectively. Image taken in low-magnification view ($\times 100$) shows central necrosis (arrow) in tumor nests. Image taken in higher-magnification reveals nuclear polymorphism (arrow).



Figure 2. Immunostaining for the characterization and classification of cancer cells. **(A)** iFC analysis of cytokeratin expression. Left panel: analysis of isotypic control (distribution in green color), mouse IgG1-FITC (FITC Mouse IgG1, κ Isotype Control Clone MOPC-2, BD Pharmingen), conducted to determine autofluorescence signal; middle panel: analysis of the expression of cytokeratin-FITC, based on a cytokeratin-specific antibody (distribution in red color) conjugated with FITC (FITC Mouse Anti-Human Cytokeratin Clone CAM5.2, BD Pharmingen); right panel: overlay. The two distributions are significantly different based on the results of the two-sample Kolmogorov–Smirnov Test ($p < 0.01$). **(B)** Immunohistochemical staining showed that the tumor cells thoroughly expressed pancytokeratin (arrow) ((a), magnification $\times 200$) and partially expressed vimentin ((b), magnification $\times 200$).

4. Discussion

The challenge of accurately diagnosing and characterizing CUP lies in its inherent nature: the primary site of the malignancy remains elusive. In the presented case report, the histopathological findings provide a detailed picture of the tumor's characteristics, but the primary site remains unidentified, which is a hallmark of CUP. The presented case provides insights into a novel diagnostic algorithm that includes iFC, yielding results beyond the standard clinical evaluation. In the current report, we presented the first, to the best of our knowledge, utilization of iFC in orthopedic surgery, as well as its first application beyond the cell cycle, to characterize the phenotypic marker of cytokeratin to complement the information provided by pathology assessment and MRI analysis. The use of pancytokeratin in tumor immunophenotyping is an approach that has long been used in

cancer diagnosis. While we recognize the long-standing use of pancytokeratin in tumor immunophenotyping, the novelty of this method lies in the intraoperative application of flow cytometry for the rapid assessment of cytokeratin expression during orthopedic surgeries, which has not been documented before.

While this case report is the first in which our methodology has been used, there are some inherent limitations of our study, which may limit the generalizability of our findings. We believe that extending this method to a larger cohort would provide more comprehensive insights, allow for the potential of conducting future research with receiver operating characteristic (ROC) analysis across a larger patient group, and reveal the level of accuracy of our methodology. Another limitation is the use of a single marker quantified via iFC. Currently, we are working on improving this methodology by quantifying additional markers and proving their utility in the operating theater. However, there are several steps before such markers can be recognized as having potential diagnostic and/or prognostic significance. A potential candidate previously found by our group may be the marker CD56, quantified via flow cytometry, whose expression is reversely proportionate to tumor stage in pediatric brain malignancies [12]. Another possible limitation is the sample size, which might have limited the number of cells available for analysis. In previous studies, we observed that 5000 cells are sufficient for accurate analysis and tumor characterization [5]. However, we believe that improving sample preparation and analysis will enable us to analyze a larger number of cells, which may also increase the accuracy of our assay.

The symptoms presented in the current case indicated the need for diagnostic imaging, including MRI and a full-body scan, which was performed to ascertain the cause of the symptoms. The results of the MRI were concerning, revealing a primary malignant tumor situated in the scapula, accompanied by multiple secondary metastatic lesions dispersed throughout the body. Given the urgency and severity of the findings, the patient was promptly scheduled for a surgical intervention that included an open-mass biopsy. During the procedure, a portion of the tumor was earmarked for intraoperative flow cytometry analysis, while the remainder of the biopsied mass was dispatched for pathology assessment. The rapid progression of symptoms, from cervicgia to more localized pain and nerve palsy, underscored the aggressive nature of the described malignancy. The presence of multiple metastases further indicated an advanced stage of the disease, which can pose significant challenges in treatment and management [4].

The decision to utilize both intraoperative flow cytometry and a traditional pathology assessment reflects a comprehensive approach to diagnosis, ensuring both immediate insights during surgery and a more detailed histopathological evaluation post-operatively. Such an approach may be instrumental in guiding subsequent therapeutic decisions, offering a more complete understanding of a tumor's nature and behavior. This case also highlights the importance of timely medical consultation and intervention, especially when symptoms evolve or intensify. In the era of precision medicine, the proposed strategy falls in line with the combinatorial use of multiple techniques to assess malignancy since few data are available for CUP, mostly concerning the analysis of case reports and small case studies [13].

The histological examination revealed neoplastic tissue interspersed within blood clots and infiltrating connective tissue; thus, there were no additional samples collected from macroscopically healthy tissue. However, the revealed distribution of neoplastic cells, which were predominantly in the perivascular space in thick bands, nests, and unclear papillary structures, was indicative of an aggressive tumor [14]. The presence of necrotic areas, significant nuclear polymorphism, and numerous mitoses, including atypical ones, further underscores the malignancy's aggressive nature, and these traits are associated with several well-characterized hallmarks of cancer [15,16]. The stromal observations, such as hemorrhagic infiltration and hemosiderin deposits, provided additional context regarding the tumor's environment and its interactions with surrounding tissues.

Immunohistochemical staining is an invaluable tool that greatly contributes to our understanding of the intrinsic characteristics of a tumor, painting a precise picture of its

cellular and molecular composition. By examining the expression of specific markers, we are able to delve deeper into deciphering a tumor's origin and behavior. In this instance, the manifestation of pancytokeratin, along with keratins 8, 18, and 19, was notably observed. Concurrently, the presence of vimentin in a distinct subset of cells underscored the complex heterogeneity inherent within the tumor, leading us towards a strong inclination that we were confronted with a form of carcinoma. However, negative immunostains of markers such as p63, mesothelin and calretinin, which are often pivotal in illuminating the pathways to the roots of a tumor, led to uncertainty with respect to the identity of the tumor's primary site. This predicament is rather a common scenario encountered in the landscape of oncology, especially in cases pertaining to a cancer of unknown primary origin (CUP). Such instances underscore the intricate complexity of cancer diagnosis.

The results of the intraoperative flow cytometry analysis, which detected cytokeratin expression, align with the post-operative pathology immunostaining, reinforcing the reliability of iFC as a diagnostic tool. The expression of Pankeratin, in particular, can be instrumental in differentiating between carcinoma and other malignancies, such as mesenchymal-type neoplasms (e.g., chondrosarcoma) or lymphoma [11]. This differentiation is crucial, as the management and prognosis for these malignancies can differ significantly.

Determining tumor resection margins has emerged as a pivotal aspect of using iFC. This technology offers an unprecedented advantage by giving near real-time feedback, a crucial element in optimizing surgical outcomes. During a surgical procedure, iFC can be used to rapidly analyze the cellular composition of resected margins [5–10]. This instant analysis can guide a surgical team in assessing whether additional tissue needs to be removed, thus ensuring complete tumor excision, minimizing the risk of recurrence and potentially improving the overall prognosis for patients. We believe that the inclusion of immunostaining markers would further add to the utility of iFC in margin assessment in orthopedic surgeries, as has been shown in relation to other types of malignancies.

In conclusion, while the results provide a comprehensive characterization of the assessed tumor, they also highlight the challenges inherent in CUP diagnosis. The inability to identify the primary site, despite extensive histopathological and immunohistochemical analysis, underscores the need for novel innovative diagnostic approaches, such as iFC, to complement traditional methods. Such a multi-modal, systematic approach can enhance the accuracy of CUP diagnosis, guiding clinicians towards more targeted and effective therapeutic strategies.

5. Conclusions

The results of the current study provide novel insights into intraoperative tumor analysis. Based on DNA content analysis, we confirmed that iFC methodology can be expanded to assess malignancy during orthopedic surgeries. More importantly, we present a novel immunostaining-based iFC approach that can provide an immediate answer regarding the expression levels of histological markers at the cell population level. In our case, the expression of cytokeratin assisted diagnosis and tumor classification. Thus, our methodology could be applied as an adjunct to the standard histopathological evaluation of tumor samples in order to provide a rapid (intraoperative) characterization of tumors during surgery to guide clinical decision making. This result warrants further examination in a clinical study to evaluate the utility of our methodology during and beyond cell-cycle analysis in an orthopedic surgery setting.

Author Contributions: G.S.M.: Methodology, Investigation, Writing—Original draft preparation, Writing—Reviewing and Editing; E.E.P.: Visualization, Investigation, Writing—Original draft preparation; V.G.: Visualization, Investigation; D.K.: Visualization, Investigation; I.G.: Visualization, Investigation; G.A.A.: Visualization, Investigation; A.B.: Visualization, Investigation, and Writing—Original draft preparation; E.L.: Visualization, Investigation, and Writing—Original draft preparation; G.V.: Conceptualization, Methodology, Writing—Original draft preparation, Writing—Reviewing and Editing. All authors have read and agreed to the published version of the manuscript.

Funding: This research did not receive any specific grant from funding agencies in the public, commercial, or not-for-profit sectors.

Institutional Review Board Statement: The study was conducted in accordance with the Declaration of Helsinki and approved by the Institutional Review Board of the University Hospital of Ioannina (protocol code: 1431/3-3-2020; date of approval: 3 March 2020).

Informed Consent Statement: The authors of the study obtained the informed consent of the individual presented in the case report.

Data Availability Statement: The presented data are available upon request made to the corresponding authors.

Conflicts of Interest: The authors declare no conflict of interest.

References

1. Sung, H.; Ferlay, J.; Siegel, R.L.; Laversanne, M.; Soerjomataram, I.; Jemal, A.; Bray, F.; Bsc, M.F.B.; Me, J.F.; Soerjomataram, M.I.; et al. Global cancer statistics 2020: GLOBOCAN estimates of incidence and mortality worldwide for 36 cancers in 185 countries. *CA A Cancer J. Clin.* **2021**, *71*, 209–249. [[CrossRef](#)] [[PubMed](#)]
2. Sullivan, R.; Alatise, O.I.; Anderson, B.O.; Audisio, R.; Autier, P.; Aggarwal, A.; Balch, C.; Brennan, M.F.; Dare, A.; D’Cruz, A.; et al. Global cancer surgery: Delivering safe, affordable, and timely cancer surgery. *Lancet Oncol.* **2015**, *16*, 1193–1224. [[CrossRef](#)] [[PubMed](#)]
3. Krämer, A.; Bochtler, T.; Pauli, C.; Baciarello, G.; Delorme, S.; Hemminki, K.; Mileskin, L.; Moch, H.; Oien, K.; Olivier, T.; et al. Cancer of unknown primary: ESMO Clinical Practice Guideline for diagnosis, treatment and follow-up☆. *Ann. Oncol.* **2023**, *34*, 228–246. [[CrossRef](#)] [[PubMed](#)]
4. Pavlidis, N.; Pentheroudakis, G. Cancer of unknown primary site. *Lancet* **2012**, *379*, 1428–1435. [[CrossRef](#)] [[PubMed](#)]
5. Alexiou, G.A.; Vartholomatos, G.; Goussia, A.; Batistatou, A.; Tsamis, K.; Voulgaris, S.; Kyritsis, A.P. Fast cell cycle analysis for intraoperative characterization of brain tumor margins and malignancy. *J. Clin. Neurosci.* **2015**, *22*, 129–132. [[CrossRef](#)] [[PubMed](#)]
6. Vartholomatos, G.; Basiari, L.; Exarchakos, G.; Kastanioudakis, I.; Komnos, I.; Michali, M.; Markopoulos, G.S.; Batistatou, A.; Papoudou-Bai, A.; Alexiou, G.A. Intraoperative flow cytometry for head and neck lesions. Assessment of malignancy and tumour-free resection margins. *Oral. Oncol.* **2019**, *99*, 104344. [[CrossRef](#)] [[PubMed](#)]
7. Markopoulos, G.S.; Glantzounis, G.K.; Goussia, A.C.; Lianos, G.D.; Karampa, A.; Alexiou, G.A.; Vartholomatos, G. Touch imprint intraoperative flow cytometry as a complementary tool for detailed assessment of resection margins and tumor biology in liver surgery for primary and metastatic liver neoplasms. *Methods Protoc.* **2021**, *4*, 66. [[CrossRef](#)] [[PubMed](#)]
8. Georvasili, V.K.; Markopoulos, G.S.; Batistatou, A.; Mitsis, M.; Messinis, T.; Lianos, G.D.; Alexiou, G.; Vartholomatos, G.; Bali, C.D. Detection of cancer cells and tumor margins during colorectal cancer surgery by intraoperative flow cytometry. *Int. J. Surg.* **2022**, *104*, 106717. [[CrossRef](#)] [[PubMed](#)]
9. Anastasiadi, Z.; Mantziou, S.; Akrivis, C.; Paschopoulos, M.; Balasi, E.; Lianos, G.D.; Alexiou, G.A.; Mitsis, M.; Vartholomatos, G.; Markopoulos, G.S. Intraoperative Flow Cytometry for the Characterization of Gynecological Malignancies. *Biology* **2022**, *11*, 1339. [[CrossRef](#)] [[PubMed](#)]
10. Paliouras, A.; Markopoulos, G.S.; Tsampalas, S.; Mantziou, S.; Giannakis, I.; Baltogiannis, D.; Glantzounis, G.K.; Alexiou, G.A.; Lampri, E.; Sofikitis, N.; et al. Accurate Characterization of Bladder Cancer Cells with Intraoperative Flow Cytometry. *Cancers* **2022**, *14*, 5440. [[CrossRef](#)] [[PubMed](#)]
11. Kremenevski, N.; Schlaffer, S.-M.; Coras, R.; Kinfe, T.M.; Graillon, T.; Buchfelder, M. Skull base chordomas and chondrosarcomas. *Neuroendocrinology* **2020**, *110*, 836–847. [[CrossRef](#)] [[PubMed](#)]
12. Alexiou, G.; Vartholomatos, G.; Stefanaki, K.; Batistatou, A.; Markopoulos, G.S.; Tzoufi, M.; Sfakianos, G.; Prodromou, N. Pediatric brain tumor grading based on CD56 quantification. *J. Pediatr. Neurosci.* **2018**, *13*, 524. [[CrossRef](#)] [[PubMed](#)]
13. Rassy, E.; Pavlidis, N. Progress in refining the clinical management of cancer of unknown primary in the molecular era. *Nat. Rev. Clin. Oncol.* **2020**, *17*, 541–554. [[CrossRef](#)] [[PubMed](#)]
14. Liu, T.; Narra, K.K.; Stephenson, P.D.; Grossmann, A.H.; Downs-Kelly, E.; Albertson, D. Pathology of soft-tissue tumors. *Sarcoma Oncol. Multidiscip. Approach* **2019**, *15*, 15–40.
15. Caruso, R.; Parisi, A.; Bonanno, A.; Paparo, D.; Quattrocchi, E.; Branca, G.; Scardigno, M.; Fedele, F. Histologic coagulative tumour necrosis as a prognostic indicator of aggressiveness in renal, lung, thyroid and colorectal carcinomas: A brief review. *Oncol. Lett.* **2012**, *3*, 16–18. [[CrossRef](#)] [[PubMed](#)]
16. Hanahan, D.; Weinberg, R.A. Hallmarks of cancer: The next generation. *Cell* **2011**, *144*, 646–674. [[CrossRef](#)] [[PubMed](#)]

Disclaimer/Publisher’s Note: The statements, opinions and data contained in all publications are solely those of the individual author(s) and contributor(s) and not of MDPI and/or the editor(s). MDPI and/or the editor(s) disclaim responsibility for any injury to people or property resulting from any ideas, methods, instructions or products referred to in the content.