

Review

Optimal Assessment of Metastatic Breast Carcinoma: The Value of Cytopathology Combined with Molecular Analysis

Ricella Souza da Silva¹ and Fernando Schmitt^{1,2,3,*}¹ IPATIMUP Diagnostics, IPATIMUP—Institute of Molecular Pathology and Immunology of Porto University, 4200-135 Porto, Portugal² Faculty of Medicine of the University of Porto, 4200-319 Porto, Portugal³ CINTESIS@RISE (Health Research Network), 4200-450 Porto, Portugal

* Correspondence: fschmitt@ipatimup.pt

Abstract: Metastatic breast cancer (MBC) remains in most cases an incurable disease with genetic complexity and heterogeneity. Improvements in classification and management have been introduced, in addition to the development of endocrine and anti-HER2 targeted therapies. Currently, efforts are being made to delineate the best approach for the genomic landscape of MBC and, as result, molecular therapeutic targets. Here, we highlight the recent developments in the cytopathology of MBC, discussing cytological diagnostic approaches in the characterization of hallmarks, such as immunocytochemistry and genomic biomarkers. Cytological material can be processed for ancillary testing for diagnostic and therapeutic purposes. Reassessment of receptor status is indicated due to changes in tumor biology and metastatic presentation. PD-L1 expression is the only approved biomarker for predicting immune checkpoint inhibitor response in metastatic TNBC, evaluated by immunostaining. The feasibility of applying PD-L1 assays in MBC cytological samples can be recommended, with the adoption of a combined positive score. Non-formalin cytological samples provide higher purity, cellular yield, and better tumor fraction for single-multi gene assays. In MBC, molecular tests enable personalized therapy such as PIK3CA, NTRK fusion genes, and MSI. Cytopathology combined with molecular analysis must be performed effectively in routine clinical practice, through procedure standardization and experience dissemination.

Keywords: metastatic breast cancer; ancillary tests; fine needle aspiration; cytology; molecular biomarkers

Citation: Souza da Silva, R.; Schmitt, F. Optimal Assessment of Metastatic Breast Carcinoma: The Value of Cytopathology Combined with Molecular Analysis. *J. Mol. Pathol.* **2022**, *3*, 329–340. <https://doi.org/10.3390/jmp3040028>

Academic Editor: Alice Lytwyn

Received: 12 October 2022

Accepted: 18 November 2022

Published: 22 November 2022

Publisher's Note: MDPI stays neutral with regard to jurisdictional claims in published maps and institutional affiliations.



Copyright: © 2022 by the authors. Licensee MDPI, Basel, Switzerland. This article is an open access article distributed under the terms and conditions of the Creative Commons Attribution (CC BY) license (<https://creativecommons.org/licenses/by/4.0/>).

1. Introduction

Approximately 30% of female cancers are breast cancer (BC), which continues to be the most common disease in the world with a mortality-to-incidence ratio of 15% [1]. The vast majority of deaths due to breast cancer are attributed to metastasis and its associated relapse, which usually occurs in patients ~5–20 years after their first diagnosis [2]. Around 30% of breast cancer patients still relapse with distant metastasis [3]. Even they were reported as metastasis-free at the time of diagnosis, nearly 25% of patients with node-negative breast cancer develop metastases [4]. When metastatic breast cancer (MBC) is diagnosed, the 5-year survival rate is in the range of 38% [5].

The most common sites of breast carcinoma metastases are the bones, liver, lungs, and brain [2], but other secondary localizations have been described in the literature, including those of the peritoneal cavity [6]. Different patterns of metastatic sites in breast cancer are observed according to the hormone receptor, HER2 subtype, and histological type. The comprehension of primary and metastatic disease has advanced significantly, allowing the characterization of biomarkers and adequate follow-up for different groups of patients. However, the factors related to metastatic dissemination are multiple and add even greater complexity to an already intrinsically heterogeneous disease, with several

clinical, histological characteristics and molecular subtypes. A study that followed 60,227 patients with the diagnosis of breast cancer and 11,983 patients with metastases for three decades, illustrates this complexity connected to the cancer's biological progression. This work observed a change in the pattern of metastases. Systematic therapies have enabled the eradication of part of the initial metastases, the so-called prevalent micro-metastasis, resulting in delaying the appearance of subsequent metastases. Nevertheless, as an effect, there is an extension of the metastasis-free interval and a reduction in post-metastatic survival [7].

In the approach of metastatic disease, fine needle aspiration cytology (FNAC) can be the diagnostic technique of first choice for the documentation of suspected metastases [8]. The minimally invasive nature of cytological procedures facilitates tissue sampling, can be applied to several types of metastatic lesions, and is useful for patients in poor general conditions. The demands and implementation of cytology on metastatic breast cancer are increasing with the advances in radiological and endoscopic techniques for obtaining cytological material.

Furthermore, besides the confirmation of the primary breast site of metastasis, cytological material can be used for diagnostic and therapeutic purposes [9]. Currently, the classification of breast cancer includes the characterization of molecular biomarkers, which are critical for a properly targeted therapeutic. Recent guidelines from the College of American Pathologists (CAP) have endorsed the use of all cytological specimen preparations for molecular assays [10].

In this review, we outline the recent developments in the cytopathology of metastatic breast cancer, discussing cytological diagnostic approaches in the characterization of breast cancer hallmarks, such as immunocytochemistry (ICC) and genomic biomarkers, with an emphasis on molecular profiling.

2. Metastatic Breast Cancer: Molecular Cytological Approach

2.1. Immunocytochemistry Biomarkers: Receptor Status

ICC biomarker tests in MBC are recommended in the guidelines of the American Society of Clinical Oncology (ASCO)/American Pathology Association [11]. Three breast cancer subtypes were defined based on immunostaining estrogen receptor (ER), progesterone receptor (PR), and human epidermal growth factor receptor 2 (HER2) status: Hormone receptor (HR)+/HER2- subtype was defined by HR positive (either ER or PR positive) and HER2- status; HER2+ subtype by HER2 positivity as assessed by IHC and in situ hybridization in case of 2+ IHC score; and triple negative (TNBC) subtype by lack of expression of ER, PR and HER2 [12].

ER, PR, and HER2 status are critical predictive markers for most of the currently available targeted treatments. HR+ cancers are found to have increased metastasis to the bone. HER-2+ and TNBC subtypes are associated with brain metastasis. Metastases to the lung and bones are frequently seen in TNBC tumors, whereas there appears to be a higher rate of liver metastasis in HER2 positive breast cancer subtypes [5].

The use of cytology specimens for receptor analysis is a rapid, inexpensive, and less invasive alternative to biopsy at metastatic sites and in metastatic breast cancer patients [13]. Following specific validation, immunostaining can be performed on any cytological preparation, including cellblocks (CBs), cytospins, smears, and liquid-based cytology (LBC) [14], particularly in cellblocks and LBC sediments.

Cellblocks have technical advantages over other cytological preparations; they can produce a greater number of sections, which is appropriate for an immunostaining panel. Additionally, samples are embedded in paraffin, and antigen retrieval techniques are identical to those used in histology; therefore, marker validation is not necessary. Studies have been reported in which the results of analysis for receptors in fine-needle aspiration CBs fixed in 10% buffered formalin showed excellent agreement with those in the corresponding tissue blocks, including solid tumors at metastatic sites [15].

Aspiration cytology is particularly useful in the assessment of breast cancers, allowing a sampling that frames the spatial heterogeneity common to this neoplasm. Discordance in the receptor status between primary breast carcinomas and corresponding metastases is well documented in the literature (Table 1). There are several potential explanations for these changes reported in the literature, including variability in assay performance, clonal and phenotypic heterogeneity, and biologic evolution of the tumor [16]. Multiple studies have shown that tumors evolve over time, and metastatic tumors show enrichment of mutations, as well as de novo molecular aberrations, absent in the primary site. Treatment history, which might lead to clonal selection, should also be taken into consideration [17].

MBC after therapy for early breast cancer (EBC) tends to have more aggressive tumor biology and a worse outcome compared with de novo MBC [7,18]. Thus, improvements in EBC therapies seem to have led to an alteration in tumor biology and metastasis presentation in subsequent MBC, presumably resulting from a molecular selection process [5]. The discrepancies are responsible for a therapy regimen change in 14–20% of patients [19].

Table 1. Studies on the discordance of immunochemical biomarkers between primary breast carcinomas and corresponding metastases.

| Study (Author, Year; Type of Study) | Number (Articles or Cases; Period) | Discordance Rates PBC vs. MBC |
|---|---|---------------------------------------|
| Aurilio et al. 2014 [20] Meta-analysis | 48 articles From 1983 to 2011 | ER: 20% PR: 33% HER2: 8% |
| Yeung et al. 2016 [17] Review | 47 articles From 1988 to 2012 | ER: 14% PR: 21% HER2: 10% |
| Nakayama et al. 2016 [21] Prospective | 20 paired cytology cases From 2015 | ER: 24% PR: 24% HER2: 5% |
| Pareja et al. 2017 [22] Prospective | 65 paired cytology cases From 2007 to 2009 | ER: 21.5% PR: 41.5% HER2: 3.1% |
| Schrijver et al. 2018 [23] Systematic review and meta-analysis | 39 articles From 1989 to 2016 | ER: 19.3% PR: 30.9% HER2: 10.3% |
| Matsui et al. 2019 [24] Prospective | 62 paired cytology cases From 2015 to 2016 | ER: 18.2% PR: 36.4% HER2: 8.2% |
| Sperduto et al. 2020 [25] Retrospective | 316 paired cases From 2006 and 2017 | ER: 22% PR: 26% HER2: 10% |
| Kotecha et al. 2021 [16] Systematic review and meta-analysis | 15 articles From 2007 to 2020 | ER: 17% PR: 23% HER2: 12% |

ER: estrogen receptor; PR: progesterone receptor; HER2: human epidermal growth factor receptor 2; MBC: metastatic breast cancer; PBC: primary breast cancer.

In different studies, the criteria for evaluating these markers in cytological material was similar [13,21,22,24,26–30]. For evaluating the results of HR staining, it was recommended to report the results as positive or negative according to the following criteria: any nuclear staining of tumor cells should be classified as positive, and a complete

lack of staining of tumor cells as negative. For HER 2, the recommendation is to apply the same ASCO/CAP histological criteria and analysis in cellblocks. Only strongly stained cells should be categorized as 3+, and cases where it is difficult to decide between 2+ and 1+ should be labeled as 2+. To avoid missing HER2-positive cases, strict scoring criteria must be used to categorize samples as 2+ or 3+. Nakayama et al. [21] advised utilizing only positive/negative judgment for both HR and HER2 in cases with cytology material containing a small number of cancer cells.

Beca and Schmitt [31] highlight the immunocytochemistry of these markers in cytology samples, including FNAC and fluids, for metastatic breast cancer. In the presence of a limited sample, which is frequent in a metastatic setting, they recommended testing only ER, since PR assessment adds little predictive information and ER priority as these carcinomas benefit from endocrine therapy. Regarding HER2, the work reinforces the test in cellblocks because these allow for standardized protocols for formalin-fixed, paraffin-embedded (FFPE) tissue. Moreover, it emphasizes the availability of various methods (fluorescence, silver, or chromogenic) for testing the HER2 status, using FNAC. Although improvements have been made in the classification and management of breast cancer, as well as the development of status-receptor targeted therapies, MBC remains in the majority of cases an incurable disease [32].

2.2. Immunocytochemistry Biomarkers: Program Death Ligand-1 (PD-L1)

PD-L1 expression, as assessed by immunohistochemistry, is the only established biomarker for predicting the response to immune checkpoint inhibitors in metastatic TNBC. PD-L1 positivity predicted the efficacy of pembrolizumab (Clone 22C3) in combination with first-line chemotherapy for advanced TNBC [12].

According to recent NCCN guidelines [12], PD-L1 expression in TNBC is determined by using Combined Positive Score (CPS), which is the number of PD-L1 staining cells (tumor cells, lymphocytes, macrophages) divided by the total number of viable tumor cells, multiplied by 100, with a cut-off $\geq 10\%$.

A minimum of 100 viable tumor cells must be present for the specimen to be considered adequate for PD-L1 evaluation. Any perceptible and convincing partial or complete linear membrane staining ($\geq 1+$) of viable tumor cells, lymphocytes, and macrophages that are perceived as distinct from cytoplasmic staining is considered PD-L1 staining and should be included in the scoring [33].

In this context, the feasibility of applying PD-L1 assays to MBC cytological samples can be recommended with better performance. Adoption of CPS facilitates PD-L1 evaluation for cytological samples, as the differentiation between inflammatory cells (mainly macrophages) and tumor cells can be challenging in immunocytochemical staining.

Although specific recommendations for PD-L1 testing in cytology are yet to be established and validated, PD-L1 evaluation has been performed on cytological samples of lung cancer [34]. The studies demonstrate good agreement in PD-L1 expression between FFPE samples, FFPE cell blocks, and alcohol-fixed Papanicolaou stained smears (85.2% adequacy rate; 81–85% median concordance) [33,35].

2.3. Genomic Biomarkers

For metastatic breast cancer, the goal of molecular testing is to find tumor-specific mutations and then target therapy already approved or under study in clinical trials to increase survival and quality of life [36]. The European Society of Medical Oncology (ESMO) recommends including MBC patients in molecular screening programs to assess targeted therapies [37], either in the framework of multigene panels or to test specific genes that allow for personalized therapy.

Studies have revealed that cytological specimens produce adequate substrates for molecular analysis and can provide clinically reliable genomic profiling [10,38]. Cytological samples have been reported to be feasible for collecting sufficient tumor

samples for DNA and RNA analysis, in single-multiplex genomic assays, including polymerase chain reaction (PCR), Sanger sequencing, and next generation sequencing (NGS) [39].

Lee et al. [40], evaluating the sensitivity of FNAC compared with gross surgical sampling in the detection of somatic mutations in breast cancer (using whole-exome sequencing), concluded that there was no difference in the total amount of DNA extracted for both sampling methods. Roy-Chowdhuri et al. [41] reviewed solid tumors concurrently sampled by FNAC and core needle biopsy (CNB) and compared overall cellularity, tumor fraction, and the results of NGS. FNAC samples provided better cellularity, a higher tumor fraction, and superior sequencing metrics than concurrently performed CNB. Dupain et al. [38], analyzing 61 metastatic samples (CNB and FNAC), mainly MBC, concluded that FNA can be used in routine diagnostic workflow and clinical trials for tumor molecular profiling with the advantages of being minimally invasive and preserving tissue material needed for diagnostic, prognostic, or therapeutic purposes.

The viability is related to the higher purity of the samples, as in smears and touch preparations. The adoption of non-cross-linking alcoholic reagents may yield superior results in terms of quality and quantity of extracted nucleic acids with respect to formalin [42]. Molecular tests are significantly influenced by pre-analytical and analytical tissue management [43]. The analytical sensitivity of each molecular assay varies according to the amount and quality of DNA/RNA extracted from the sample tumor.

Molecular platforms require approximately a range from 1 ng to 200 ng input nucleic acid masses (10 ng usual minimum input for most NGS assays). A fraction of malignant cells greater than 10% to 20% is generally considered a lower acceptable limit for these methods [41]. Most NGS assays demand approximately between 1000–5000 cells [43]. About three to fourfold more cells are required from an FFPE sample from ethanol-fixed material to isolate 10 ng of nucleic acids [44].

Among the different cytological preparations, recent researches have validated the viability of adopting supernatant fluids for NGS analysis [45,46], while CBs and smears have shown to be appropriate for more complex NGS analysis, such as tumor mutational burden profiling [47]. To prevent medico-legal problems, whole slide scanning and digital storage are required when only one diagnostic slide is available for testing [48].

The genomic alterations in MBC include ERBB2 amplifications, PIK3CA mutations, germline BRCA 1/2 mutations, somatic BRCA 1/2 mutations, NTRK fusions, ESR1 mutations (mechanism of resistance), PTEN mutations, AKT1^{E17K} mutations, NF1 mutations (resistance biomarker), MDM2 amplifications, ERBB3 mutations, and microsatellite instability (MSI) [37]. According to the ESMO Scale for Clinical Actionability of Molecular Targets (ESCAT), only five molecular alterations are associated with breast cancer treatment efficacy with the highest level of evidence (ESCAT I): ERBB2 amplification, germline BRCA1/2 mutations, PIK3CA mutations, MSI, and NTRK fusion [37].

In the context of daily practice, there is currently no need to perform tumor multi-gene NGS for patients with MBC [37]. ERBB2 amplifications are usually assessed by immunochemistry or in situ hybridization; BRCA1/2 mutations by germline testing; and PIK3CA status can be determined by PCR on the three hotspots. When performed, multi-gene NGS in MBC is based on the following gene panel: BRCA1/2, PALB2, ATM, CHEK2, RAD51C, BARD1, and TP53 genes [3].

Therapeutically relevant genomic biomarkers to be assessed concerning immunochemistry classification include: germline BRCA1/2 mutations in HER2-negative MBC; somatic BRCA mutations in HER2-low MBC; PIK3CA, germline BRCA1/2 mutations, PALB2 mutations (optional), and ESR1 (optional) in ER positive, HER2-negative MBC; PD-L1, germline BRCA1/2 mutations, and PALB2 mutations (optional) in TNBC tumors; and in all patients MSI, TMB, and NTRK only if corresponding therapies are available [5,49].

Research by Bertucci et al. [50] on 617 metastatic breast cancer patients exhibited that some driver alterations, in TP53, ESR1, GATA3, KMT2C, NCOR1, AKT1, NF1, RIC8A, and RB1, were more frequently detected in HR-positive/HER2-negative MBC if compared to EBC. Additionally, mutations in TP53, RB1, and NF1 were associated with worse outcomes, and MBC showed an increase in mutational burden compared to EBC.

Systemic therapies in this setting include endocrine therapy with targeted agents, such as CDK4/6 inhibitors and PIK3CA inhibitors for HR positive disease, anti-HER2 targeted therapy for HER2-positive disease, poly ADP ribose polymerase inhibitors (PARP) for BRCA1/2 mutation carriers, and immunotherapy currently for part of triple-negative disease [12,51].

In Table 2, a summary of the genomic changes in MBC associated with the respective breast cancer subtypes, detection tests, prevalence, rating scales, and targeted therapies [5,12,37,49,52,53].

Table 2. Summary of genomic alterations in metastatic breast cancer.

| Biomarker/Alteration | BC Subtypes | Detection | Prevalence | ESCAT/NCCN Category | FDA-Approved Agents [12] |
|---|------------------|----------------|------------|---------------------|--|
| HER2 Amplification | HER2 + | IHC, FISH | 15%-20% | IA/1 | Trastuzumab, T-DM1, lapatinib, trastuzumab + pertuzumab, neratinib |
| BRCA 1, BRCA 2 Germline Mutation | All | NGS | 4% | IA/1 | Olaparib Talazoparib |
| BRCA 1, BRCA 2 Somatic Mutation | HER 2 low status | IHC | 3% | IIA/2A | Trastuzumab deruxtecan |
| PIK3CA Hotspot mutation | HR+/HER2– | PCR,NGS | 30–40% | IA/1 | Alpelisib + fulvestrant |
| MSI-H dMMR | All | IHC, PCR | 1% | IC/2A | Pembrolizumab Dostarlimab-gxly |
| NTRK Fusion | All | FISH, PCR, NGS | 1% | IC/2A | Larotrectinib Entrectinib |
| PD-L1 | TNBC | IHC | 20% | IA/1 | Pembrolizumab + chemotherapy |
| TMB-High (≥10 mut/mb) | All | NGS | 8–11% | IA/2A | Pembrolizumab |
| ESR1 Mutation (mechanism of resistance) | HER + | NGS | 10% | IIA/1 | Fulvestrant |
| PTEN Mutation | NA | NGS | 7% | IIA/NA | NA |
| AKT1 Mutation | NA | NGS | 5% | IIB/NA | NA |
| NF1 Mutation (resistance biomarker) | NA | NGS | 6% | NA | NA |
| MDM2 Amplification | NA | NGS | ~1% | IIIA/NA | NA |
| ERBB3 Mutation | NA | NGS | 2% | IIIB/NA | NA |

BC: breast cancer; ESCAT: ESMO Scale Clinical Actionability of Molecular Targets; FDA Food and Drug Administration; FISH: fluorescence in situ hybridization; HR: hormone receptor; IHC: Immunohistochemistry; NA: Not applicable; NCCN: Clinical Practice Guidelines in Oncology; NGS: next generation sequencing; PCR: polymerase chain reaction; TNBC: triple negative breast cancer.

3. Discussion

The genomic scenery of metastatic breast cancer is enriched in druggable genomic drivers and is more complex than early breast cancer [50]. Identifying these genomic alterations and consequently targeted treatments is the goal of personalized medicine. To that end, we outline a framework for a practical approach in the characterization of MBC hallmarks, with information on standardization for cytological processing and diagnosis (Figure 1). It is important to emphasize that molecular diagnosis from small cytological and/or tissue samples has been working for patients with advanced lung cancer [54], with encouraging effects in reducing mortality and increasing survival [55].

The exploration of cytological specimens seems closer and more connected with current precision oncology, in which cancer characterization, in both the diagnostic and therapeutic fields, focuses on the “smallest” level: the molecular. For this purpose, the cytopathological method has inherent advantages related to its minimally invasive nature, which may allow an easier approach, greater sampling, and greater tumor representativeness, which are essential in the heterogeneous landscape common to the tumor biology and evolution of MBC.

For ancillary testing in advanced breast cancer, the use of cytological specimens can offer two advantages. The variety of cytological preparations available from FNAC enables the selection of certain preparations for each type of test based on its performance and sensitivity. Second, non-FFPE FNA samples provide higher purity, higher cellular yield, and a better tumor fraction for molecular testing. The benefits of cytological processing for ancillary tests extend particularly to the most common metastatic site of breast cancer. Bone FNA samples do not require exposure to decalcifying agents, which are well known to have a marked effect on hormone receptor tests and molecular assays.

Although, in the last decade, we have validated cytology for molecular tests [10] and we have been observing a significant increase in the number of FNA cases and ancillary studies, especi

ally related to lung cancer [39], cytology still needs to be better integrated into routine molecular diagnostics workflow.

What is necessary for the perception that cytology is naturally connected with precision medicine? First, it must be performed effectively in clinical practice. Work on the standardization of cytological pre-analytical and analytical processing and specific guidelines for assay validation for ancillary tests on cytology samples are required. Second, it is necessary to demonstrate the experience and disseminate it through scientific publication for the cytopathological community. Finally, disseminate this knowledge during the academic education of young pathologists and through training, mainly aimed at anatomical pathologists.

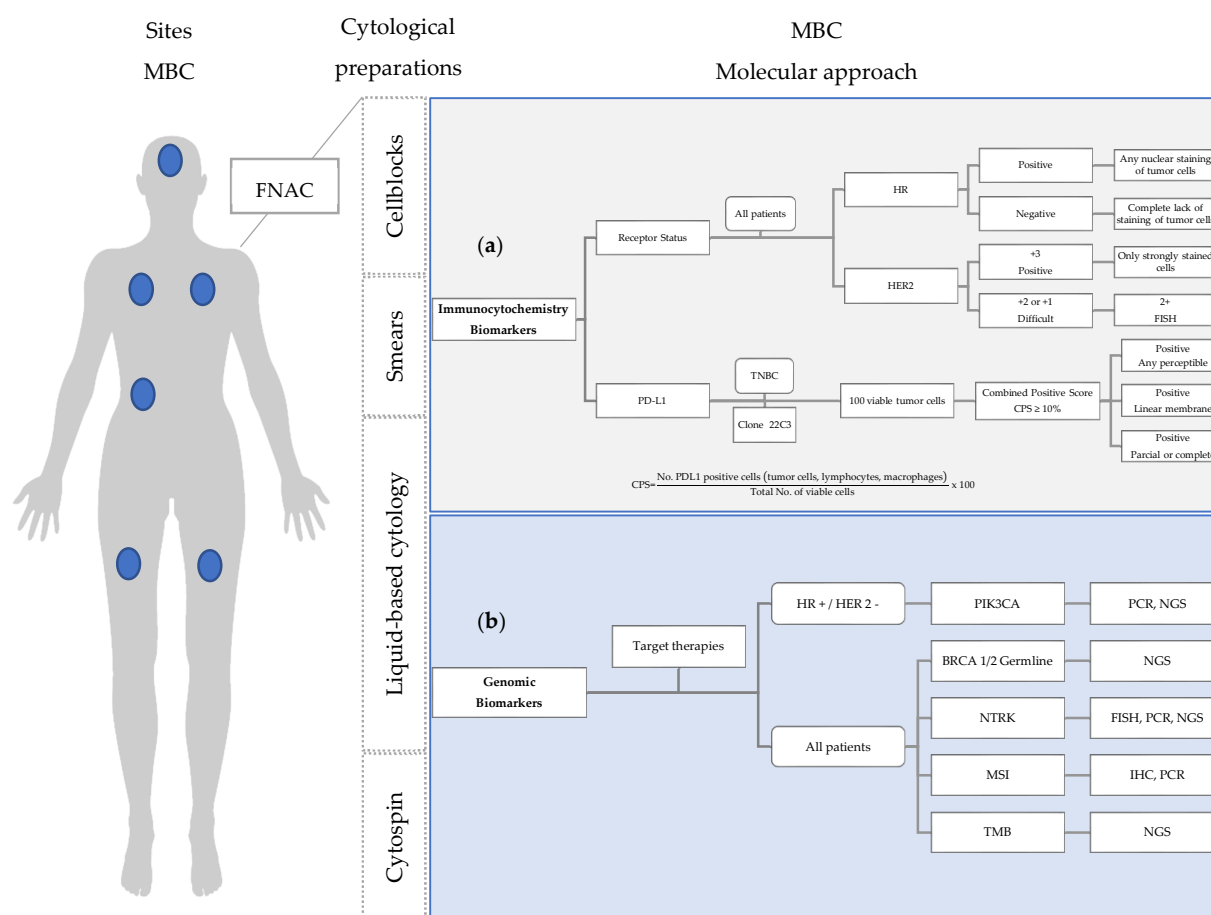


Figure 1. Molecular approach in the characterization of MBC hallmarks, using cytological preparations: **(a)** Immunocytochemistry biomarkers: Criteria for assessing HR and HER2 receptor status and PD-L1 expression in cytological material; **(b)** Genomic biomarkers: therapeutically relevant molecular changes in MBC and detection methods. FISH: fluorescence in situ hybridization; HR: hormone receptor; FNAC: fine needle aspiration cytology; MBC: metastatic breast cancer; NGS: next generation sequencing; PCR: polymerase chain reaction; TNBC: triple negative breast cancer.

Author Contributions: Conceptualization, F.S.; methodology, F.S. and R.S.d.S.; resources, F.S. and R.S.d.S.; writing—original draft preparation, R.S.d.S.; writing—review and editing, F.S. and R.S.d.S.; supervision, F.S. All authors have read and agreed to the published version of the manuscript.

Funding: This research received no external funding.

Institutional Review Board Statement: Not applicable.

Informed Consent Statement: Not applicable.

Data Availability Statement: Not applicable.

Acknowledgments: The authors acknowledge the support of Fundação para a Ciência e a Tecnologia, I.P., within the scope of the project “RISE—LA/P/0053/2020”.

Conflicts of Interest: The authors declare no conflict of interest.

References

1. Siegel, R.L.; Miller, K.D.; Fuchs, H.E.; Jemal, A. Cancer Statistics. *CA Cancer J. Clin.* **2022**, *72*, 7–33. <https://doi.org/10.3322/caac.21708>.
2. Schieman, W.P. Introduction to This Special Issue “Breast Cancer Metastasis. *J. Cancer Metastasis Treat.* **2020**, *6*, 3. <https://doi.org/10.20517/2394-4722.2020.01>.

3. Loibl, S.; Poortmans, P.; Morrow, M.; Denkert, C.; Curigliano, G. Breast Cancer. *Lancet* **2021**, *397*, 1750–1769. [https://doi.org/10.1016/S0140-6736\(20\)32381-3](https://doi.org/10.1016/S0140-6736(20)32381-3).
4. Martins, D.; Beca, F.; Schmitt, F. Metastatic Breast Cancer: Mechanisms and Opportunities for Cytology. *Cytopathol. Off. J. Br. Soc. Clin. Cytol.* **2014**, *25*, 225–230. <https://doi.org/10.1111/cyt.12158>.
5. Gennari, A.; André, F.; Barrios, C.H.; Cortés, J.; de Azambuja, E.; DeMichele, A.; Dent, R.; Fenlon, D.; Gligorov, J.; Hurvitz, S.A.; et al. ESMO Clinical Practice Guideline for the Diagnosis, Staging and Treatment of Patients with Metastatic Breast Cancer. *Ann. Oncol. Off. J. Eur. Soc. Med. Oncol.* **2021**, *32*, 1475–1495. <https://doi.org/10.1016/j.annonc.2021.09.019>.
6. Na, K.; Lee, J.-Y.; Sung, J.-Y.; Kim, G.M.; Koo, J.S.; Kim, H.-S. Comparative Clinicopathological and Cytomorphological Analyses of Peritoneal Carcinomatosis Associated with Metastatic Breast Carcinoma and Primary Peritoneal/Ovarian Carcinoma in Patients with a History of Breast Carcinoma. *Virchows Arch. Int. J. Pathol.* **2018**, *473*, 165–175. <https://doi.org/10.1007/s00428-018-2390-5>.
7. Hölzel, D.; Eckel, R.; Bauerfeind, I.; Baier, B.; Beck, T.; Braun, M.; Ettl, J.; Hamann, U.; Kiechle, M.; Mahner, S.; et al. Improved Systemic Treatment for Early Breast Cancer Improves Cure Rates, Modifies Metastatic Pattern and Shortens Post-Metastatic Survival: 35-Year Results from the Munich Cancer Registry. *J. Cancer Res. Clin. Oncol.* **2017**, *143*, 1701–1712. <https://doi.org/10.1007/s00432-017-2428-0>.
8. Cramer, H. Cytopathology of Metastatic Breast Cancer. *Clin. Breast Cancer* **2000**, *1*, 243–244. <https://doi.org/10.3816/CBC.2000.n.021>.
9. Pinto, D.; Schmitt, F.C. Immunohistochemistry Applied to Breast Cytological Material. *Pathobiology* **2022**, *89*, 343–358. <https://doi.org/10.1159/000522542>.
10. Roy-Chowdhuri, S.; Dacic, S.; Ghofrani, M.; Illei, P.B.; Layfield, L.J.; Lee, C.; Michael, C.W.; Miller, R.A.; Mitchell, J.W.; Nikolic, B.; et al. Collection and Handling of Thoracic Small Biopsy and Cytology Specimens for Ancillary Studies: Guideline From the College of American Pathologists in Collaboration With the American College of Chest Physicians, Association for Molecular Pathology, American Society of Cytopathology, American Thoracic Society, Pulmonary Pathology Society, Papanicolaou Society of Cytopathology, Society of Interventional Radiology, and Society of Thoracic Radiology. *Arch. Pathol. Lab. Med.* **2020**, *144*, 933–958. <https://doi.org/10.5858/arpa.2020-0119-CP>.
11. Van Poznak, C.; Somerfield, M.R.; Bast, R.C.; Cristofanilli, M.; Goetz, M.P.; Gonzalez-Angulo, A.M.; Hicks, D.G.; Hill, E.G.; Liu, M.C.; Lucas, W.; et al. Use of Biomarkers to Guide Decisions on Systemic Therapy for Women With Metastatic Breast Cancer: American Society of Clinical Oncology Clinical Practice Guideline. *J. Clin. Oncol. Off. J. Am. Soc. Clin. Oncol.* **2015**, *33*, 2695–2704. <https://doi.org/10.1200/JCO.2015.61.1459>.
12. Gradishar, W.J.; Moran, M.S.; Abraham, J.; Aft, R.; Agnese, D.; Allison, K.H.; Anderson, B.; Burstein, H.J.; Chew, H.; Dang, C.; et al. Breast Cancer, Version 3.2022, NCCN Clinical Practice Guidelines in Oncology. *J. Natl. Compr. Cancer Netw. JNCCN* **2022**, *20*, 691–722. <https://doi.org/10.6004/jnccn.2022.0030>.
13. Nishimura, R.; Murata, Y.; Mori, K.; Yamashiro, K.; Kuraoka, K.; Ichihara, S.; Taguchi, K.; Suzuki, H.; Ito, M.; Yamashita, N. Evaluation of the HER2 and Hormone Receptor Status in Metastatic Breast Cancer Using Cell Blocks: A Multi-Institutional Study. *Acta Cytol.* **2018**, *62*, 288–294. <https://doi.org/10.1159/000488382>.
14. Kanber, Y.; Pustaszeri, M.; Auger, M. Immunocytochemistry for Diagnostic Cytopathology-A Practical Guide. *Cytopathol. Off. J. Br. Soc. Clin. Cytol.* **2021**, *32*, 562–587. <https://doi.org/10.1111/cyt.12993>.
15. Monaco, S.E.; Wu, Y.; Teot, L.A.; Cai, G. Assessment of Estrogen Receptor (ER), Progesterone Receptor (PR), and Human Epidermal Growth Factor Receptor 2 (HER2) Status in the Fine Needle Aspirates of Metastatic Breast Carcinomas. *Diagn. Cytopathol.* **2013**, *41*, 308–315. <https://doi.org/10.1002/dc.21841>.
16. Kotecha, R.; Tonse, R.; Rubens, M.; McDermott, M.W.; Odia, Y.; Appel, H.; Mehta, M.P. Systematic Review and Meta-Analysis of Breast Cancer Brain Metastasis and Primary Tumor Receptor Expression Discordance. *Neuro-Oncol. Adv.* **2021**, *3*, vdab010. <https://doi.org/10.1093/oaajnl/vdab010>.
17. Yeung, C.; Hilton, J.; Clemons, M.; Mazzarello, S.; Hutton, B.; Haggard, F.; Addison, C.L.; Kuchuk, I.; Zhu, X.; Gelmon, K.; et al. Estrogen, Progesterone, and HER2/Neu Receptor Discordance between Primary and Metastatic Breast Tumours—a Review. *Cancer Metastasis Rev.* **2016**, *35*, 427–437. <https://doi.org/10.1007/s10555-016-9631-3>.
18. Malmgren, J.A.; Mayer, M.; Atwood, M.K.; Kaplan, H.G. Differential Presentation and Survival of de Novo and Recurrent Metastatic Breast Cancer over Time: 1990–2010. *Breast Cancer Res. Treat.* **2018**, *167*, 579–590. <https://doi.org/10.1007/s10549-017-4529-5>.
19. Amir, E.; Miller, N.; Geddie, W.; Freedman, O.; Kassam, F.; Simmons, C.; Oldfield, M.; Dranitsaris, G.; Tomlinson, G.; Laupacis, A.; et al. Prospective Study Evaluating the Impact of Tissue Confirmation of Metastatic Disease in Patients with Breast Cancer. *J. Clin. Oncol. Off. J. Am. Soc. Clin. Oncol.* **2012**, *30*, 587–592. <https://doi.org/10.1200/JCO.2010.33.5232>.
20. Aurilio, G.; Disalvatore, D.; Pruneri, G.; Bagnardi, V.; Viale, G.; Curigliano, G.; Adamoli, L.; Munzone, E.; Sciandivasci, A.; De Vita, F.; et al. A Meta-Analysis of Oestrogen Receptor, Progesterone Receptor and Human Epidermal Growth Factor Receptor 2 Discordance between Primary Breast Cancer and Metastases. *Eur. J. Cancer* **2014**, *50*, 277–289. <https://doi.org/10.1016/j.ejca.2013.10.004>.
21. Nakayama, Y.; Nakagomi, H.; Omori, M.; Inoue, M.; Takahashi, K.; Maruyama, M.; Takano, A.; Furuya, K.; Amemiya, K.; Ishii, E.; et al. Benefits of Using the Cell Block Method to Determine the Discordance of the HR/HER2 Expression in Patients with Metastatic Breast Cancer. *Breast Cancer* **2016**, *23*, 633–639. <https://doi.org/10.1007/s12282-015-0615-x>.

22. Pareja, F.; Murray, M.P.; Des Jean, R.; Konno, F.; Friedlander, M.; Lin, O.; Edelweiss, M. Cytologic Assessment of Estrogen Receptor, Progesterone Receptor, and HER2 Status in Metastatic Breast Carcinoma. *J. Am. Soc. Cytopathol.* **2017**, *6*, 33–40. <https://doi.org/10.1016/j.jasc.2016.10.001>.
23. Schrijver, W.A. M. E.; Suijkerbuijk, K.P. M.; van Gils, C.H.; van der Wall, E.; Moelans, C.B.; van Diest, P.J. Receptor Conversion in Distant Breast Cancer Metastases: A Systematic Review and Meta-Analysis. *J. Natl. Cancer Inst.* **2018**, *110*, 568–580. <https://doi.org/10.1093/jnci/djx273>.
24. Matsui, A.; Murata, Y.; Masuda, N.; Mori, K.; Takahashi, M.; Yamashiro, K.; Aogi, K.; Maeda, S.; Itou, M.; Ozaki, S.; et al. Clinical Significance of Evaluating Hormone Receptor and HER2 Protein Using Cell Block against Metastatic Breast Cancer: A Multi-Institutional Study. *Oncotarget* **2019**, *10*, 5680–5689. <https://doi.org/10.18632/oncotarget.27163>.
25. Sperduto, P.W.; Mesko, S.; Li, J.; Cagney, D.; Aizer, A.; Lin, N.U.; Nesbit, E.; Kruser, T.J.; Chan, J.; Braunstein, S.; et al. Estrogen/Progesterone Receptor and HER2 Discordance between Primary Tumor and Brain Metastases in Breast Cancer and Its Effect on Treatment and Survival. *Neuro-Oncology* **2020**, *22*, 1359–1367. <https://doi.org/10.1093/neuonc/noaa025>.
26. Shabaik, A.; Lin, G.; Peterson, M.; Hasteh, F.; Tipps, A.; Datnow, B.; Weidner, N. Reliability of Her2/Neu, Estrogen Receptor, and Progesterone Receptor Testing by Immunohistochemistry on Cell Block of FNA and Serous Effusions from Patients with Primary and Metastatic Breast Carcinoma. *Diagn. Cytopathol.* **2011**, *39*, 328–332. <https://doi.org/10.1002/dc.21389>.
27. Kumar, S.K.; Gupta, N.; Rajwanshi, A.; Joshi, K.; Singh, G. Immunochemistry for Oestrogen Receptor, Progesterone Receptor and HER2 on Cell Blocks in Primary Breast Carcinoma. *Cytopathol. Off. J. Br. Soc. Clin. Cytol.* **2012**, *23*, 181–186. <https://doi.org/10.1111/j.1365-2303.2011.00853.x>.
28. Bueno Angela, S.P.; Viero, R.M.; Soares, C.T. Fine Needle Aspirate Cell Blocks Are Reliable for Detection of Hormone Receptors and HER-2 by Immunohistochemistry in Breast Carcinoma. *Cytopathol. Off. J. Br. Soc. Clin. Cytol.* **2013**, *24*, 26–32. <https://doi.org/10.1111/j.1365-2303.2011.00934.x>.
29. Ferguson, J.; Chamberlain, P.; Cramer, H.M.; Wu, H.H. ER, PR, and Her2 Immunocytochemistry on Cell-Transferred Cytologic Smears of Primary and Metastatic Breast Carcinomas: A Comparison Study with Formalin-Fixed Cell Blocks and Surgical Biopsies. *Diagn. Cytopathol.* **2013**, *41*, 575–581. <https://doi.org/10.1002/dc.22897>.
30. Francis, I.M.; Altemaimi, R.A.; Al-Ayadhy, B.; Alath, P.; Jaragh, M.; Mothafar, F.J.; Kapila, K. Hormone Receptors and Human Epidermal Growth Factor (HER2) Expression in Fine-Needle Aspirates from Metastatic Breast Carcinoma—Role in Patient Management. *J. Cytol.* **2019**, *36*, 94–100. https://doi.org/10.4103/JOC.JOC_117_18.
31. Beca, F.; Schmitt, F.C. Ancillary Tests in Breast Cytology: A Practical Guide. *Acta Cytol.* **2019**, *63*, 302–313. <https://doi.org/10.1159/000499697>.
32. Verret, B.; Bottosso, M.; Hervais, S.; Pistilli, B. The Molecular Predictive and Prognostic Biomarkers in Metastatic Breast Cancer: The Contribution of Molecular Profiling. *Cancers* **2022**, *14*, 4203. <https://doi.org/10.3390/cancers14174203>.
33. Iaccarino, A.; Salatiello, M.; Migliat�o, I.; De Luca, C.; Gagnano, G.; Russo, M.; Bellevicene, C.; Malapelle, U.; Troncone, G.; Vigliar, E. PD-L1 and beyond: Immuno-Oncology in Cytopathology. *Cytopathol. Off. J. Br. Soc. Clin. Cytol.* **2021**, *32*, 596–603. <https://doi.org/10.1111/cyt.12982>.
34. Satturwar, S.; Girolami, I.; Munari, E.; Ciompi, F.; Eccher, A.; Pantanowitz, L. Program Death Ligand-1 Immunocytochemistry in Lung Cancer Cytological Samples: A Systematic Review. *Diagn. Cytopathol.* **2022**, *50*, 313–323. <https://doi.org/10.1002/dc.24955>.
35. Mansour, M.S.I.; Lindquist, K.E.; Seidal, T.; Mager, U.; Mohlin, R.; Tran, L.; Hejny, K.; Holmgren, B.; Violidaki, D.; Dobra, K.; et al. PD-L1 Testing in Cytological Non-Small Cell Lung Cancer Specimens: A Comparison with Biopsies and Review of the Literature. *Acta Cytol.* **2021**, *65*, 501–509. <https://doi.org/10.1159/000517078>.
36. Zhang, X. Molecular Classification of Breast Cancer. *Arch. Pathol. Lab. Med.* **2022**. <https://doi.org/10.5858/arpa.2022-0070-RA>.
37. Mosele, F.; Remon, J.; Mateo, J.; Westphalen, C.B.; Barlesi, F.; Lolkema, M.P.; Normanno, N.; Scarpa, A.; Robson, M.; Meric-Bernstam, F.; et al. Recommendations for the Use of Next-Generation Sequencing (NGS) for Patients with Metastatic Cancers: A Report from the ESMO Precision Medicine Working Group. *Ann. Oncol. Off. J. Eur. Soc. Med. Oncol.* **2020**, *31*, 1491–1505. <https://doi.org/10.1016/j.annonc.2020.07.014>.
38. Dupain, C.; Masliah-Planchon, J.; Gu, C.; Girard, E.; Gestraud, P.; Du Rusquec, P.; Borcoman, E.; Bello, D.; Ricci, F.; Hescot, S.; et al. Fine-Needle Aspiration as an Alternative to Core Needle Biopsy for Tumour Molecular Profiling in Precision Oncology: Prospective Comparative Study of next-Generation Sequencing in Cancer Patients Included in the SHIVA02 Trial. *Mol. Oncol.* **2021**, *15*, 104–115. <https://doi.org/10.1002/1878-0261.12776>.
39. Dinarvand, P.; Liu, C.; Roy-Chowdhuri, S. A Decade of Change: Trends in the Practice of Cytopathology at a Tertiary Care Cancer Centre. *Cytopathology* **2021**, *32*, 604–610. <https://doi.org/10.1111/cyt.12972>.
40. Lee, H.-B.; Joung, J.-G.; Kim, J.; Lee, K.-M.; Ryu, H.S.; Lee, H.-O.; Moon, H.-G.; Park, W.-Y.; Noh, D.-Y.; Han, W. The Use of FNA Samples for Whole-Exome Sequencing and Detection of Somatic Mutations in Breast Cancer Surgical Specimens. *Cancer Cytopathol.* **2015**, *123*, 669–677. <https://doi.org/10.1002/cncy.21599>.
41. Roy-Chowdhuri, S.; Chen, H.; Singh, R.R.; Krishnamurthy, S.; Patel, K.P.; Routbort, M.J.; Manekia, J.; Barkoh, B.A.; Yao, H.; Sabir, S.; et al. Concurrent Fine Needle Aspirations and Core Needle Biopsies: A Comparative Study of Substrates for next-Generation Sequencing in Solid Organ Malignancies. *Mod. Pathol.* **2017**, *30*, 499–508. <https://doi.org/10.1038/modpathol.2016.228>.

42. Pisapia, P.; Pepe, F.; Sgariglia, R.; Nacchio, M.; Russo, G.; Conticelli, F.; Girolami, I.; Eccher, A.; Bellevicine, C.; Vigliar, E.; et al. Next Generation Sequencing in Cytology. *Cytopathol. Off. J. Br. Soc. Clin. Cytol.* **2021**, *32*, 588–595. <https://doi.org/10.1111/cyt.12974>.
43. Souza da Silva, R.; Pinto, R.; Cirnes, L.; Schmitt, F. Tissue Management in Precision Medicine: What the Pathologist Needs to Know in the Molecular Era. *Front. Mol. Biosci.* **2022**, *9*, 983102. <https://doi.org/10.3389/fmolb.2022.983102>.
44. Penault-Llorca, F.; Kerr, K.M.; Garrido, P.; Thunnissen, E.; Dequeker, E.; Normanno, N.; Patton, S.J.; Fairley, J.; Kapp, J.; de Ridder, D.; et al. Expert Opinion on NSCLC Small Specimen Biomarker Testing—Part 1: Tissue Collection and Management. *Virchows Arch.* **2022**, *481*, 335–350. <https://doi.org/10.1007/s00428-022-03343-2>.
45. Janaki, N.; Harbhajanka, A.; Michael, C.W.; Bomeisl, P.; Wasman, J.; Atchley, M.; Miskiewicz, K.; Alouani, D.; Sadri, N. Comparison of Cytocentrifugation Supernatant Fluid and Formalin-Fixed Paraffin-Embedded Tissue for Targeted next-Generation Sequencing. *Cancer Cytopathol.* **2019**, *127*, 297–305. <https://doi.org/10.1002/cncy.22126>.
46. Ruff, H.M.; Lou, S.K.; Hahn, E.; Grenier, S.; Stockley, T.L.; Boerner, S.L. Molecular Yield and Cytomorphologic Assessment of Fine Needle Aspiration Specimen Supernatants. *J. Am. Soc. Cytopathol.* **2022**, *11*, 142–153. <https://doi.org/10.1016/j.jasc.2022.02.004>.
47. Pepe, F.; Pisapia, P.; Gristina, V.; Rocco, D.; Micheli, M.; Micheli, P.; Iaccarino, A.; Tufano, R.; Gragnano, G.; Russo, G.; et al. Tumor Mutational Burden on Cytological Samples: A Pilot Study. *Cancer Cytopathol.* **2021**, *129*, 460–467. <https://doi.org/10.1002/cncy.22400>.
48. Bellevicine, C.; Malapelle, U.; Vigliar, E.; Pisapia, P.; Vita, G.; Troncone, G. How to Prepare Cytological Samples for Molecular Testing. *J. Clin. Pathol.* **2017**, *70*, 819–826. <https://doi.org/10.1136/jclinpath-2017-204561>.
49. Hong, R.; Xu, B. Breast Cancer: An up-to-Date Review and Future Perspectives. *Cancer Commun.* **2022**, *42*, 913–936. <https://doi.org/10.1002/cac2.12358>.
50. Bertucci, F.; Ng, C.K.Y.; Patsouris, A.; Droin, N.; Piscuoglio, S.; Carbuccion, N.; Soria, J.C.; Dien, A.T.; Adnani, Y.; Kamal, M.; et al. Genomic Characterization of Metastatic Breast Cancers. *Nature* **2019**, *569*, 560–564. <https://doi.org/10.1038/s41586-019-1056-z>.
51. Henry, N.L.; Somerfield, M.R.; Dayao, Z.; Elias, A.; Kalinsky, K.; McShane, L.M.; Moy, B.; Park, B.H.; Shanahan, K.M.; Sharma, P.; et al. Biomarkers for Systemic Therapy in Metastatic Breast Cancer: ASCO Guideline Update. *J. Clin. Oncol. Off. J. Am. Soc. Clin. Oncol.* **2022**, *40*, 3205–3221. <https://doi.org/10.1200/JCO.22.01063>.
52. Danesi, R.; Fogli, S.; Indraccolo, S.; Del Re, M.; Dei Tos, A.P.; Leoncini, L.; Antonuzzo, L.; Bonanno, L.; Guarneri, V.; Pierini, A.; et al. Druggable Targets Meet Oncogenic Drivers: Opportunities and Limitations of Target-Based Classification of Tumors and the Role of Molecular Tumor Boards. *ESMO Open* **2021**, *6*, 100040. <https://doi.org/10.1016/j.esmoop.2020.100040>.
53. Arora, S.; Narayan, P.; Osgood, C.L.; Wedam, S.; Prowell, T.M.; Gao, J.J.; Shah, M.; Krol, D.; Wahby, S.; Royce, M.; et al. U.S. FDA Drug Approvals for Breast Cancer: A Decade in Review. *Clin. Cancer Res.* **2022**, *28*, 1072–1086. <https://doi.org/10.1158/1078-0432.CCR-21-2600>.
54. Schmitt, F.; Lozano, M.D. Molecular/Biomarker Testing in Lung Cytology: A Practical Approach. *Diagn. Cytopathol.* **2022**. <https://doi.org/10.1002/dc.25054>.
55. Nicholson, A.G.; Tsao, M.S.; Beasley, M.B.; Borczuk, A.C.; Brambilla, E.; Cooper, W.A.; Dacic, S.; Jain, D.; Kerr, K.M.; Lantuejoul, S.; et al. The 2021 WHO Classification of Lung Tumors: Impact of Advances Since 2015. *J. Thorac. Oncol. Off. Publ. Int. Assoc. Study Lung Cancer* **2022**, *17*, 362–387. <https://doi.org/10.1016/j.jtho.2021.11.003>.