uro

MDPI

Case Report

Concomitant Radical Cystectomy and Infrarenal Aortic Aneurysm Repair with Cryopreserved Aortic Allograft: A Case Report

Francesco Cianflone [1,*], Alberto Bianchi [1], Giovanni Novella [1], Alessandro Tafuri [1], Maria Angela Cerruto [1], Andrea Zivi [2], Gian Franco Veraldi [3] and Alessandro Antonelli [1,*]

[1] Department of Urology, Azienda Ospedaliera Universitaria Integrata Verona, University of Verona, 37126 Verona, Italy; alberto.bianchimd@gmail.com (A.B.); giovanni.novella@aovr.veneto.it (G.N.); aletaf@hotmail.it (A.T.); mariaangela.cerruto@univr.it (M.A.C.)

[2] Department of Oncology, Azienda Ospedaliera Universitaria Integrata Verona, University of Verona, 37126 Verona, Italy; andrea.zivi@aovr.veneto.it

[3] Department of Vascular Surgery, Azienda Ospedaliera Universitaria Integrata Verona, University of Verona, 37126 Verona, Italy; gianfranco.veraldi@aovr.veneto.it

* Correspondence: francesco.cianflone@studenti.univr.it (F.C.); alessandro.antonelli@aovr.veneto.it (A.A.); Tel.: +39-04-5812-7701 (F.C. & A.A.); Fax: +39-04-5812-7715 (F.C. & A.A.)

Abstract: In localized muscle invasive bladder cancer (MIBC), the gold standard treatment is radical cystectomy (RC) with bilateral pelvic lymph node dissection (PLND), associated with cisplatin-based neoadjuvant chemotherapy, whereas first-line treatment for metastatic patients is cisplatin-based chemotherapy. In men with an abdominal aortic aneurysm (AAA), elective repair is recommended when its diameter is >5.5 cm, while cryopreserved arterial allografts (CAA) offer resistance to infection. A patient with simultaneous metastatic MIBC, associated with left hydronephrosis, and infrarenal AAA of 49 mm diameter was evaluated in an interdisciplinary study. Concomitant surgery was opted for; first, the AAA repair with CAA implantation was practiced, followed by retroperitoneal and common iliac lymphadenectomy. Thereafter, RC and PLND were conducted, and a Wallace-1 ileal conduit and a stoma were constructed. Chest and abdomen contrast-enhanced CT at 2 months showed the onset of two osteolytic lesions on the left ilium. At oncological re-evaluation the patient was deemed cisplatin-fit.

Keywords: muscle invasive bladder cancer; urothelial cancer; infrarenal aortic aneurysm; cryopreserved aortic allograft

check for updates

Citation: Cianflone, F.; Bianchi, A.; Novella, G.; Tafuri, A.; Cerruto, M.A.; Zivi, A.; Veraldi, G.F.; Antonelli, A. Concomitant Radical Cystectomy and Infrarenal Aortic Aneurysm Repair with Cryopreserved Aortic Allograft: A Case Report. *Uro* **2022**, *2*, 6–12. https://doi.org/10.3390/uro2010002

Academic Editor: Tommaso Cai

Received: 7 December 2021
Accepted: 22 December 2021
Published: 11 January 2022

Publisher's Note: MDPI stays neutral with regard to jurisdictional claims in published maps and institutional affiliations.

Copyright: © 2022 by the authors. Licensee MDPI, Basel, Switzerland. This article is an open access article distributed under the terms and conditions of the Creative Commons Attribution (CC BY) license (https://creativecommons.org/licenses/by/4.0/).

1. Introduction

Bladder cancer (BCa) is the second most common genitourinary malignancy, with 81,190 estimated new diagnoses in 2018 in the United States [1]. The contemporary gold standard treatment for muscle invasive BCa (MIBC) is radical cystectomy (RC) with pelvic lymph node dissection (PLND), preceded by cisplatin-based neoadjuvant chemotherapy.

Abdominal aortic aneurysm (AAA) affects 1.5–3.3% of European men after 65 years of age, with a prevalence steadily increasing from the sixth decade [2]. AAA can be defined either as an abdominal aortic diameter larger than 3.0 cm, or a maximum aortic diameter exceeding 50% of the suprarenal diameter [2]. Elective repair should be considered at 5.5 cm and 5.0 cm, in men and women, respectively. Open and endovascular repair techniques are available and should be indicated on an individual basis, according to the anatomy of the AAA, the patient's comorbidities, and the anticipated durability of the repair [2].

Moreover, in order to perform open vascular reconstruction, nowadays a wide variety of synthetic materials are available, such as Dacron or expanded polytetrafluoroethylene, and allografts [2]. The latter have been used for more than a century. Fresh aortic allografts,

stored at 4 °C for 48 h, were the first implemented, with the major drawback of the preservation technique limiting their use. With the advent of cryopreservation, standardized conservation processes and tissues banks were created. Cryopreserved arterial allografts offer the advantages of experimental and clinical high resistance to infection, and the bonus of leaving the patient anticoagulant-free [2,3].

Although BCa and AAA share several risk factors—such as hypertension, dyslipidemia and, smoking [1,3–5]—only sparse reports deal with the simultaneous management of these two conditions [6,7]. All reports are mainly focused on the surgical technique of a combined approach to AAA and BCa, and on perioperative morbidity. However, there is an additional issue to date that is still neglected; that is, how neoadjuvant chemotherapy in candidates to RC bearing an AAA should be managed. Platinum-based chemotherapy indeed exposes the patient to a significant risk of major events, such as aortic dissection and thrombosis, due to cisplatin-related hypertension and cancer-related hypercoagulability [8,9] and, accordingly, it cannot be administered in the presence of a significant AAA. For these reasons, the diagnosis of MIBC in patients with concomitant AAA is a unique challenge needing for a multidisciplinary team to establish the priorities and sequence of treatments.

Herein, we present an original solution adopted in a case observed at our institution.

2. Case Report

A 59-year-old male smoker, affected by hypertension, came to the urology clinic after gross hematuria. Ultrasound found a 3-cm solid mass on the right posterolateral bladder wall, and a concomitant 49-mm diameter infrarenal AAA. Thoraco-abdominal CT staging confirmed a left bladder wall mass, infiltrating the perivescical fat and the prostate (cT4a) with left hydroureteronephrosis; multiple lymphadenopathies were shown along the iliac vessels and retroperitoneally, up to a maximum diameter of 11 mm. No secondary localizations were found. The CT also confirmed the presence of the infrarenal AAA with diameters of 47 × 49 × 65 mm, with a significant thrombotic apposition, with no aneurysmal dilation of its significant branches (Figure 1). A further PET-CT showed that the pelvic nodes were metabolically active, whereas the retroperitoneal ones had only a mild activity, without a clearly pathological uptake (Figure 2).

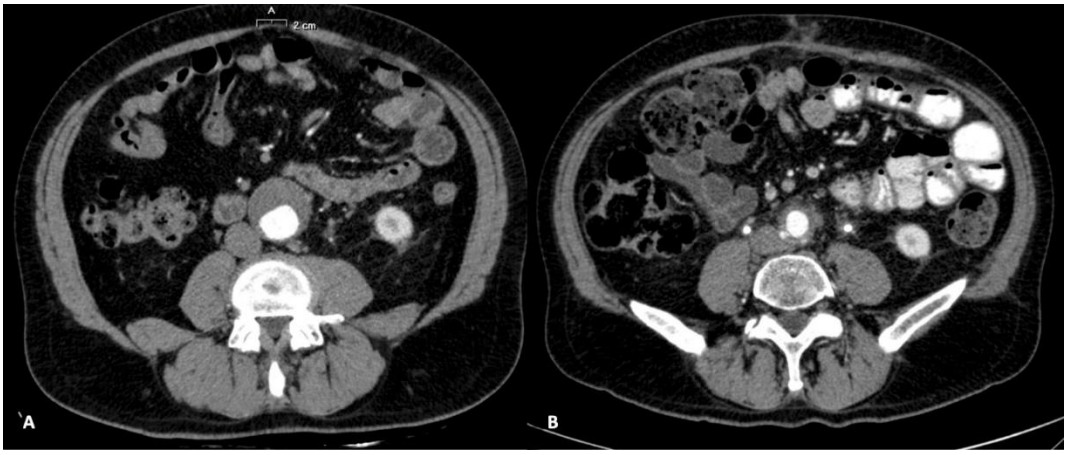

Figure 1. Contrast-enhanced arterial-phase CT scan of the aortic aneurysm before (Panel **A**) and after surgical correction (Panel **B**).

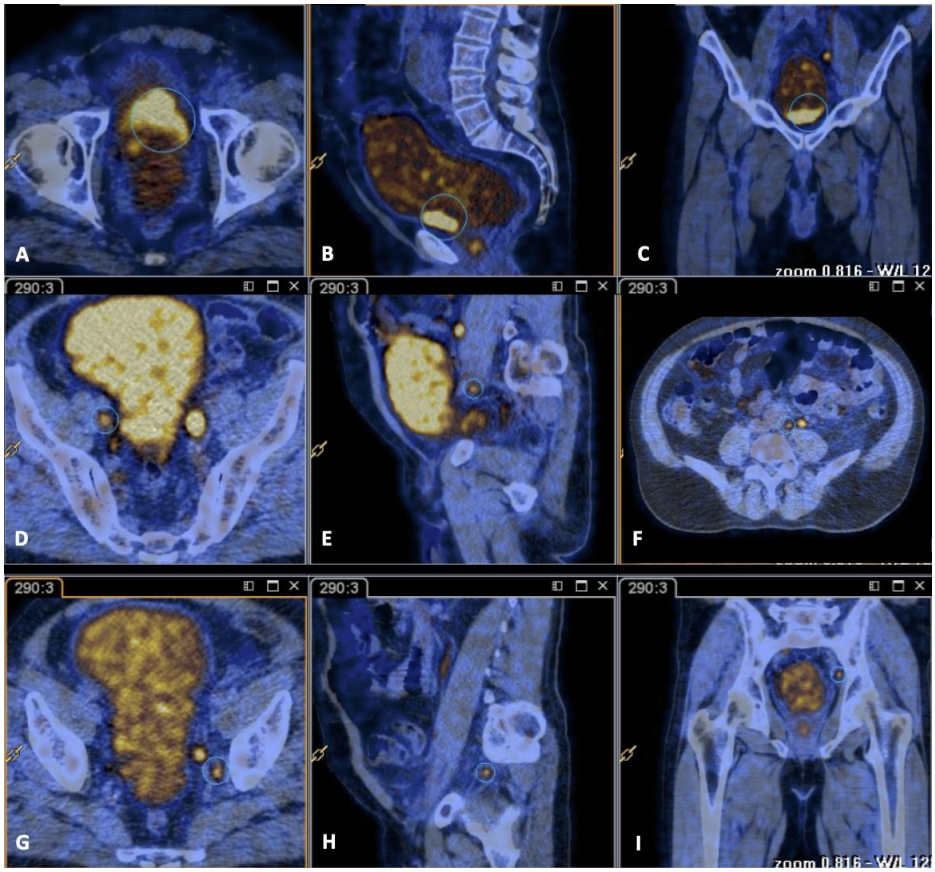

Figure 2. FDG-PET/CT showing significant metabolic activity in bilateral pelvic lymph nodes and mild metabolic activity in the femoral and retroperitoneal LN. (**A**) Transverse low-pelvic slice showing significant metabolic activity in the anterior aspect of the bladder (circled in green). (**B**) Sagittal pelvic slice showing significant metabolic activity in the anterior aspect of the bladder (circled in green). (**C**) Coronal anterior pelvic slice showing significant metabolic activity in the anterior aspect of the bladder (circled in green). (**D**) Transverse high-pelvic slice showing significant metabolic activity in the right pelvic lymph nodes (circled in green). (**E**) Right parasagittal slice showing significant metabolic activity in the right pelvic lymph nodes (circled in green). (**F**) Mid-abdominal slice showing mild metabolic activity in retroperitoneal lymph nodes (circled in green). (**G**) Transverse mid-pelvic slice showing significant metabolic activity in the left pelvic lymph nodes (circled in green). (**H**) Left parasagittal slice showing significant metabolic activity in the left pelvic lymph nodes (circled in green). (**I**) Coronal posterior pelvic slice showing significant metabolic activity in the left pelvic lymph nodes (circled in green).

At transurethral resection, a high-grade MIBC, solid and papillary urothelial cancer, with focal clear cell aspects and necrotic areas, was found.

After multidisciplinary consultation, cisplatin-based chemotherapy was contraindicated due to the prohibitive risk of AAA rupture. Moreover, a preliminary endovascular repair was excluded, because of the anatomy and volume of the AAA impairing the correct graft placement.

Accordingly, a combined procedure of open RC with extended PLND and AAA repair was planned.

After placing the patient in a supine position, general anesthesia was induced. A median xipho-pubic laparotomy was performed. As the first step, the proximal infrarenal aneurysmatic neck and the common iliac arteries were isolated distally. Under systemic heparinization, the aneurysm was clamped and incised, the thrombus was removed, and an aorto-aortic cadaveric allograft was put in place (Figures 3 and 4). After declamping, a regular blood arterial flow was found along the iliac vessels. Then retroperitoneal

and pelvic lymphadenectomy was done and the aneurysmatic sac closed over the graft (Figure 4). After ending the vascular steps, an antegrade radical cysto-prostatectomy with uretero-ileocutaneostomy according to the Wallace 2 technique was performed. Intraoperative vital parameters were maintained as stable throughout the procedure; the estimated blood loss was 3200 mL, and 5 packs of concentrated blood cells and 1200 mL of plasma were transfused.

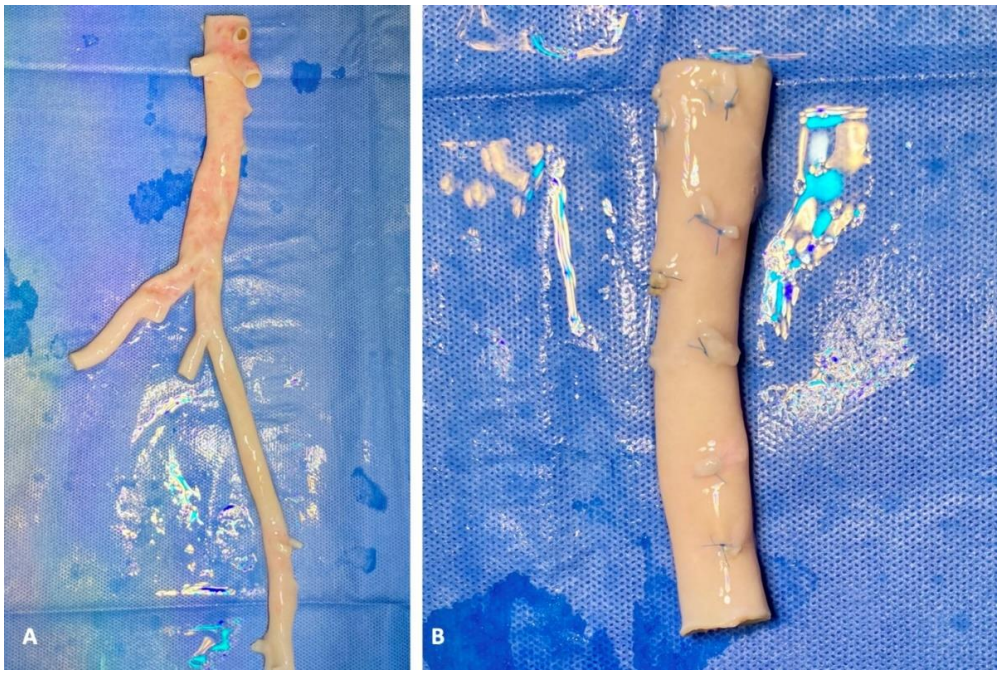

Figure 3. Cryopreserved aortic allograft before (Panel **A**) and after (Panel **B**) preparation.

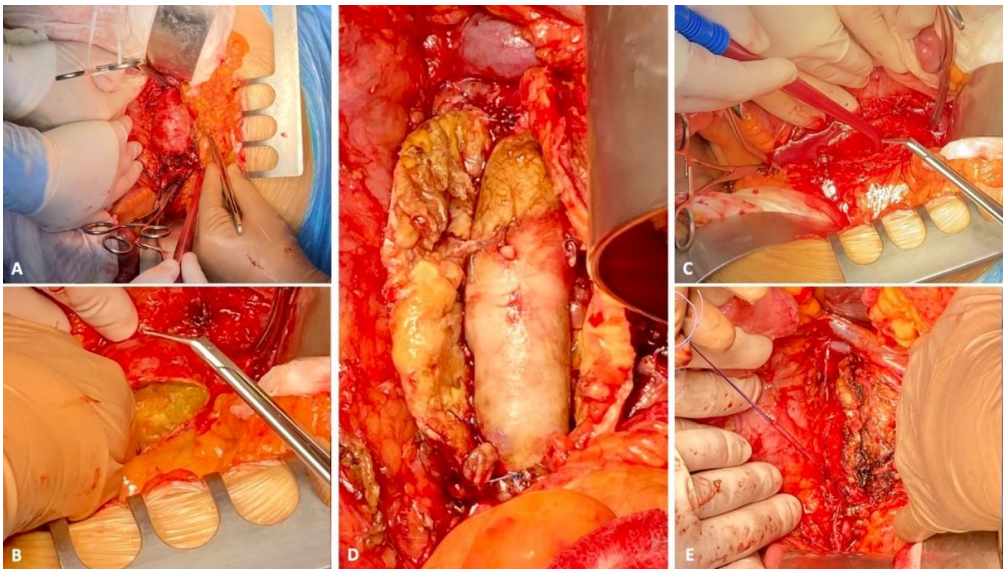

Figure 4. Infrarenal aortic aneurysm repair with cryopreserved aortic allograft surgical steps: (Panel **A**): the aneurysm is clamped at the proximal infrarenal neck and the iliac arteries are also clamped. (Panel **B**): incision of the aneurysm. (Panel **C**): Thrombus excision. (Panel **D**): aorto-aortic allograft using a beforehand prepared cryopreserved segment of abdominal aorta. (Panel **E**): aneurysmatic sack closure.

The patient was monitored in an intensive care unit for one night. Post-operative course was complicated by fever on the 2° post-operative day (POD), which was treated with antibiotic therapy (Clavien-Dindo II). During POD 5, transitory diarrhea occurred (Clavien-Dindo I), and a CT scan evidenced a 92 × 88 × 110 mm fluid collection in the small pelvis, which was drained with transurethral catheterization on POD 9 (Clavien-Dindo I). The patient was discharged on POD 19, with the indication to complete the 28-day course of thromboprophylaxis with low molecular weight heparin, as per the guidelines [1], which was started on POD 1. Moreover, indication for a life-time anti-platelet therapy with low-dose acetylsalicylic acid was given. No early uretero-ileocutaneostomy complications, such as urinary leakage, ileal conduit retraction and ileal conduit ischemia, were reported.

The final pathological report was consistent with a pT4a N3 M1a (TNM 2017 version) high-grade urothelial papillary cancer with perineural and vascular invasion, infiltrating the perivescical fat, the prostate, and the right seminal vesicle, with a positive urethral margin, and 16/31 positive nodes (eight left iliac-obturator, two right iliac-obturator, two right common iliac, three paraaortic, one interaortocaval). Two months later, a re-staging CT scan showed a bony metastasis with an 18 mm osteolytic lesion of the left ilium. The patient was then enrolled in the open-label NILE protocol (ClinicalTrials.gov Identifier: NCT03682068; https://clinicaltrials.gov/ct2/show/NCT03682068 (accessed on 10 January 2022)), which comprises treatment with cisplatin, gemcitabine and Durvalumab vs. cisplatin and gemcitabine only. The patient is currently undergoing the second cycle of chemotherapy, with only minor or mild side effects reported, such as dysgeusia, mild pain under adequate analgesic control, and mild neutropenia, while maintaining an ECOG 1 performance status. Moreover, no late uretero-ileocutaneostomy complications, such as uretero-ileal anastomosis stenosis and parastomal hernia, were reported. In consideration of the need to perform a restaging contrast-enhanced CT, vascular follow-up at 6 months with the aforementioned imaging was indicated.

3. Discussion

The concomitant occurrence of MIBC and AAA is uncommon but possible, considering the risk factors shared by these two conditions [6,7,10,11]. In the presence of critical AAA, the administration of platinum-based chemotherapy is impaired by the risk of aneurysm leakage and thrombosis [8,9]. Accordingly, surgery remains the only viable option, although burdened by the additive risk of complications from multiple surgical procedures. Both elective open aortic replacement and cystectomy had a high rate of peri-operative mortality (ranging from 1% to 8% [12]) and severe complications (up to 58% [1,13]). Considering that several points mutually influence these risks—heparinization required by aortic replacement with inherent risk of massive bleeding during cystectomy, and spillage of ileal or urinary contents that could contaminate the vascular graft—it becomes clear that the indication to RC and AAA repair represents a unique challenge.

The case here reported present a combined solution taken in a young patient with symptomatic bladder cancer, without other effective treatment options. The cryopreserved aortic allograft (CAA) for aortic replacement was chosen counting on its higher resistance to infections, compared with synthetic materials, such as Dacron or expanded polytetrafluoroethylene [14]. This option has been increasingly adopted in AAA repair with concomitant surgeries for complex gastrointestinal procedures with high infectious risk (fistula of rectal stump after left colic resection; bowel resection for perforated sigmoid diverticulitis [3]). Moreover, CAA reduces the need of anticoagulants with respect to synthetic prosthesis [14]. The improvement of cryopreservation techniques with better preservation of human tissue, has recently improved [15] the risks of early graft rupture and late development of aneurysmal change or wall calcification [16].

As of today, there are few reports in the literature of MIBC with concomitant AAA. Lierz et al., in 1993, first described eight cases [9], managed by a sequential treatment of the two conditions. Ginsberg et al. described the first report of simultaneous treatment in 1996, performing first RC and then the vascular steps [17]. Thereafter, Grego et al. compared

patients undergoing simultaneous surgical treatment of abdominal aneurysm and bladder carcinoma with control patients undergoing surgery for either one of the two diseases alone, showing no survival difference between the groups [7].

In the case here presented, the post-operative course was complicated by an infectious event, that fortunately did not involve the aortic graft. A histological examination confirmed a locally advanced bladder cancer involving the pelvic and lymph nodes. As expected, an early metastatic bone progression occurred, and systemic treatment could be prescribed due to the solution of previous AAA. To date, the patient is currently enrolled in the open-label NILE trial, undergoing cisplatin and gemcitabine chemotherapy without any major adverse effects.

4. Conclusions

The present case report depicts concomitant treatment of simultaneous metastatic MIBC and infrarenal AAA which, alone, did not justify surgical treatment; however, after interdisciplinary assessment surgical intervention was deemed as the only course of action.

Author Contributions: Conceptualization, F.C., A.B. and A.A.; methodology: A.A., A.T.; investigation, G.N., G.F.V.; resources, A.Z., G.F.V., M.A.C. and A.A.; writing—original draft preparation, F.C. and A.B.; writing—review and editing, F.C., A.B. and A.A.; supervision, A.Z. and G.F.V.; project administration, A.A., M.A.C. All authors have read and agreed to the published version of the manuscript.

Funding: This research received no external funding.

Institutional Review Board Statement: Not applicable.

Informed Consent Statement: Not applicable.

Data Availability Statement: Not applicable.

Conflicts of Interest: The authors declare no conflict of interest.

References

1. Witjes, J.A.; Bruins, H.M.; Cathomas, R.; Compérat, E.M.; Cowan, N.C.; Gakis, G.; Hernández, V.; Linares Espinós, E.; Lorch, A.; Neuzillet, Y.; et al. European Association of Urology Guidelines on Muscle-invasive and Metastatic Bladder Cancer: Summary of the 2020 Guidelines. *Eur. Urol.* **2021**, *79*, 82–104. [CrossRef] [PubMed]
2. Wanhainen, A.; Verzini, F.; Van Herzeele, I.; Allaire, E.; Bown, M.; Cohnert, T.; Dick, F.; van Herwaarden, J.; Karkos, C.; Koelemay, M.; et al. Editor's Choice—European Society for Vascular Surgery (ESVS) 2019 Clinical Practice Guidelines on the Management of Abdominal Aorto-iliac Artery Aneurysms. *Eur. J. Vasc. Endovasc. Surg.* **2019**, *57*, 8–93. [CrossRef] [PubMed]
3. Harlander-Locke, M.P.; Harmon, L.K.; Lawrence, P.F.; Oderich, G.S.; McCready, R.A.; Morasch, M.D.; Feezor, R.J. The use of cryopreserved aortoiliac allograft for aortic reconstruction in the United States. *J. Vasc. Surg.* **2014**, *59*, 669–674. [CrossRef] [PubMed]
4. Kong, J.; Diao, X.; Diao, F.; Fan, X.; Zheng, J.; Yan, D.; Huang, J.; Qin, H.; Lin, T. Causes of death in long-term bladder cancer survivors: A population-based study. *Asia-Pacific J. Clin. Oncol.* **2019**, *15*, e167–e174. [CrossRef] [PubMed]
5. Sturgeon, K.M.; Deng, L.; Bluethmann, S.M.; Zhou, S.; Trifiletti, D.M.; Jiang, C.; Kelly, S.; Zaorsky, N.G. A population-based study of cardiovascular disease mortality risk in US cancer patients. *Eur. Heart J.* **2019**, *40*, 3889–3897. [CrossRef] [PubMed]
6. Barbalias, G.A.; Liatsikos, E.N.; Yarmenitis, S.; Maroulis, I.; Tsolakis, I. Simultaneously occurring abdominal aortic aneurysm and invasive transitional cell carcinoma of the bladder and their synchronous management. *Urol. Int.* **1998**, *60*, 66–68. [CrossRef] [PubMed]
7. Grego, F.; Lepidi, S.; Bassi, P.; Tavolini, I.M.; Noventa, F.; Pagano, F.; Deriu, G.P. Simultaneous surgical treatment of abdominal aortic aneurysm and carcinoma of the bladder. *J. Vasc. Surg.* **2003**, *37*, 607–614. [CrossRef] [PubMed]
8. Ito, S.; Nakamura, Y.; Noumi, T.; Sasaki, Y. Acute aortic thrombosis during cisplatin based chemotherapy for gastric cancer. *Intern. Med.* **2013**, *52*, 973–975. [CrossRef] [PubMed]
9. Madden, G.W.; Ishaq, M.K.; Gupta, R. Acute aortic dissection in a patient receiving gemcitabine and cisplatin. *Am. J. Ther.* **2014**, *21*, e21–e25. [CrossRef] [PubMed]
10. Lierz, M.F.; Davis, B.E.; Noble, M.J.; Wattenhofer, S.P.; Thomas, J.H. Management of Abdominal Aortic Aneurysm and Invasive Transitional Cell Carcinoma of Bladder. *J. Urol.* **1993**, *149*, 476–479. [CrossRef]
11. Mearini, L.; Zucchi, A.; Pizzirusso, G.; Vivacqua, C.; Mearini, E. Incidence and evolution of aortic aneurysm in patients with bladder cancer. *Arch. Ital. di Urol. e Androl.* **2004**, *76*, 80–82.

12. Members, T.F.; Erbel, R.; Aboyans, V.; Boileau, C.; Bossone, E.; di Bartolomeo, R.; Eggebrecht, H.; Evangelista, A.; Falk, V.; Frank, H.; et al. 2014 ESC Guidelines on the diagnosis and treatment of aortic diseases. *Eur. Hear. J.* **2014**, *35*, 2873–2926.
13. Hautmann, R.E.; de Petriconi, R.C.; Volkmer, B.G. Lessons Learned from 1000 Neobladders: The 90-Day Complication Rate. *J. Urol.* **2010**, *184*, 990–994. [CrossRef] [PubMed]
14. Vogt, P.R. Arterial Allografts in Treating Aortic Graft Infections: Something Old, Something New. *Semin. Vasc. Surg.* **2011**, *24*, 227–233. [CrossRef] [PubMed]
15. Heo, S.-H.; Kim, Y.-W.; Woo, S.-Y.; Park, Y.-J.; Kim, D.-K.; Chung, D.-R. Recent Results of In Situ Abdominal Aortic Reconstruction with Cryopreserved Arterial Allograft. *Eur. J. Vasc. Endovasc. Surg.* **2016**, *53*, 158–167. [CrossRef] [PubMed]
16. Lejay, A.; Delay, C.; Girsowicz, E.; Chenesseau, B.; Bonnin, E.; Ghariani, M.-Z.; Thaveau, F.; Georg, Y.; Geny, B.; Chakfe, N. Cryopreserved Cadaveric Arterial Allograft for Arterial Reconstruction in Patients with Prosthetic Infection. *Eur. J. Vasc. Endovasc. Surg.* **2017**, *54*, 636–644. [CrossRef] [PubMed]
17. Ginsberg, D.A.; Esrig, D.; Grossfeld, G.D.; Stein, J.P.; Freeman, J.A.; Yellin, A.E.; Lieskovsky, G.; Weaver, F.A.; Skinner, D.G. Technique of radical cystectomy and simultaneous repair of an abdominal aortic aneurysm. *Urology* **1996**, *47*, 120–122. [CrossRef]