livers

MDPI

Review

Clinical Presentation and Therapeutic Approach of Hepatic Sarcoidosis

Vittoria Benintende [1,2], Luca Bettazzoni [1,2], Nicola Reggidori [3], Chiara Ambrosi [1,2], Monica Patrignani [1,2] and Luca Ielasi [3,*]

[1] Department of Primary Health Care, Internal Medicine Unit Addressed to Frailty and Aging, AUSL Romagna, 48100 Ravenna, Italy
[2] Department of Medical and Surgical Sciences, University of Bologna, 40138 Bologna, Italy
[3] Department of Internal Medicine, Ospedale Degli Infermi di Faenza, 48018 Faenza, Italy
* Correspondence: luca.ielasi@auslromagna.it

Abstract

Sarcoidosis is a multisystemic inflammatory disease defined by non-caseating granuloma formation in involved organs. The liver is the third most implicated organ after the lungs and lymph nodes. Due to its frequently asymptomatic presentation, the true prevalence of hepatic sarcoidosis may be understated. Increased levels of alkaline phosphatase and gamma-glutamyl transferase are the most frequent biochemical abnormalities. The liver biopsy is still the gold standard and reveals non-caseating granulomas in almost all cases. The use of corticosteroids and ursodeoxycholic acid results in a significant decrease in biochemical parameters. However, the clinical course of hepatic sarcoidosis is diverse and requires individualized management strategies, especially to prevent hepatic complications. This review aims to synthesize the current evidence on epidemiology, pathogenesis, diagnostic approaches, and therapeutic strategies for this disease.

Keywords: hepatic sarcoidosis; sarcoidosis; liver involvement

1. Introduction

Sarcoidosis is a multisystemic inflammatory disease of unknown origin characterized by the formation of non-necrotizing epithelioid cell granulomas in the affected organs. The disease has a worldwide distribution, and pulmonary involvement is the most frequent manifestation, accounting for approximately 90% of all cases. Among patients with extra-thoracic sarcoidosis, the liver is the most affected organ, after lymph nodes [1]. The pathogenesis is still not totally understood, but it is believed that organic and inorganic environmental agents generate a dysregulated CD4+ Th1 cell-driven response in predisposed individuals, leading to the formation of granulomas [2]. Studies conducted on autopsies and liver biopsies have shown that the damage to the hepatic parenchyma caused by granuloma formation is mainly cholestatic and, to a lesser extent, affects the vascular structures [3,4].

In most cases, liver localization is asymptomatic or pauci-symptomatic, and it is often underdiagnosed. However, a minority of patients progress to advanced liver disease.

Therefore, diagnosis is critical but challenging because of the variability in clinical presentation, the absence of specific laboratory markers, and the lack of characteristic imaging findings. For this reason, a biopsy is often performed to validate the diagnosis and exclude other causes [5,6].

Check for updates

Received: 7 January 2026
Revised: 4 March 2026
Accepted: 29 April 2026
Published: 18 May 2026

Copyright: © 2026 by the authors. Licensee MDPI, Basel, Switzerland. This article is an open access article distributed under the terms and conditions of the Creative Commons Attribution (CC BY) license.

About half of patients have a benign course with remission of liver disease. However, there are no clear guidelines indicating when it is appropriate to start treatment. Corticosteroids are generally the most used drugs for symptomatic patients or those with evidence of organ damage. However, since patients who develop such complications remain a minority, the literature provides limited evidence regarding treatment choice and response monitoring methods [7].

In this review, we summarize the literature on the etiology, risk factors, pathogenesis, diagnosis, and treatment of hepatic sarcoidosis.

2. Epidemiology and Pathogenesis

The prevalence of sarcoidosis varies depending on ethnic group, sex, and age. Some data highlight a 3-fold higher prevalence among Afro-Americans (140 per 100,000) than Caucasians (50 per 100,000) [8], and this trend may be correlated not only with genetic factors but also with environmental and socioeconomic determinants [9]. Sarcoidosis generally affects adults between 25 and 40 years old, with a second peak of incidence in women over 50 years old. Female gender is associated with a slightly higher disease rate (6.3 per 100,000 person–years for women vs. 5.9 per 100,000 person–years for men) [10].

According to ante-mortem studies, in patients with systemic involvement, the presence of hepatic granuloma has been documented as between 3.6 and 20%, and as up to 80% in post-mortem research [5]. Due to its asymptomatic or pauci-symptomatic course, hepatic sarcoidosis is generally underdiagnosed; consequently, its actual prevalence is probably underestimated.

The etiology of sarcoidosis remains unknown, while the pathophysiological mechanisms underlying granuloma formation suggest a multifactorial interplay among environmental, genetic, and immunological factors [5,6,11].

A putative antigen in genetically predisposed individuals may trigger an immune-mediated response leading to granulomatous inflammation. Both transmissible and non-infectious environmental agents are probably involved in sarcoidosis pathogenesis: (1) evidence of *Mycobacteria* and *Propionibacterium acnes* in sarcoidosis granuloma was reported; (2) the inhalation of organic bio-aerosol may explain the flare in sarcoidosis diagnosis during the spring season; (3) occupational exposures to non-organic aerosol inhalation may create an inflammatory state that promotes granulomatous response, as observed in occupations such as naval service, firefighting and construction-related work [4]. The main workplaces at risk for sarcoidosis are the metal industry and agricultural settings (moldy environments and insecticides) [4,12].

The higher risk of sarcoidosis between co-twins, the presence of familial clusters, and differences in incidence among ethnic groups strongly suggest a genetic predisposition [10]. Genome-wide association studies identified polymorphic variations in Major Histocompatibility Complex (MHC) genes, supposed to represent genetic factors of susceptibility to sarcoidosis [13]. Next-generation sequencing and whole-exome sequencing analyses, then, permit the study of familiar forms of sarcoidosis, providing a series of recessive and de novo variants in genes related mainly to autophagy, intracellular trafficking, and T cell activation. Pathways involved in the immunological dysregulation, such as mTOR and Rac1, can alter both macrophages and T cell responses and hamper the clearance of pathogens or non-organic particles [13,14].

Both innate and adaptive immune responses have shown to play a role in the development and progression of granulomas [15,16].

The leading theory regarding sarcoidosis' pathogenesis posits that the interaction between an unknown antigen and antigen-presenting cells (APCs) in predisposed individuals leads to an abnormal immune response and the formation of the characteristic lesion of the

disease, the non-necrotizing epithelioid granuloma [11]. This is characterized by a central collection of activated macrophages called epithelioid cells, which usually fuse into giant cells, and a small number of CD4+ T lymphocytes. This structure is surrounded by B cells, CD8+ T cells, Treg, and fibroblasts [2,17].

Following interaction with an unknown stimulus, macrophages and dendritic cells activate CD4+ cells and generate a cytokine environment that promotes differentiation into a specific subtype of T helper cells [4]. The production of interleukin (IL)-12, tumor necrosis factor-α (TNF-α), and interferon-γ (INF-γ) by APCs stimulates the differentiation of circulating naïve T cell in helper-type 1 T cells (Th1), while IL-23, IL-6, and transforming growth factor-β (TGF-β) into helper-type 17 T cells (Th17). Activated T cells produced IFN-γ, IL-2, and IL-17, which stimulate granuloma formation [2]. Studies on bronchoalveolar lavage of patients with sarcoidosis have shown a predominantly Th1 cytokine environment [18] with upregulated IFN-γ production [15,19]. Recent research has also shown a role of Th17 in granuloma formation; notably, the presence of a high level of the Th 17.1 subtype, which produces mainly IFN-γ, appears to be linked to the development of chronic disease [20]. Other authors have instead observed a switch to a helper-type 2 T cells (Th2)-mediated immune response in patients who developed pulmonary fibrosis [2,21].

Innate immunity is also involved in this process. In the early stages, the inflammatory state drives macrophage activation with M1 polarization and the production of TNF-α and IL-1β. That leads to aggregation of epithelial cells and further induction of multinucleated giant cells [2,15].

It is believed that there is a dynamic balance and complex interaction between different immune cells during the disease [15], and a dysregulation of the Th1/Th2/Th17 balance and B-cell compartment contributes to creating a conducive environment for granuloma formation and progression [5]. However, the progression to fibrosis and end-stage organ damage is still not fully understood (Figure 1).

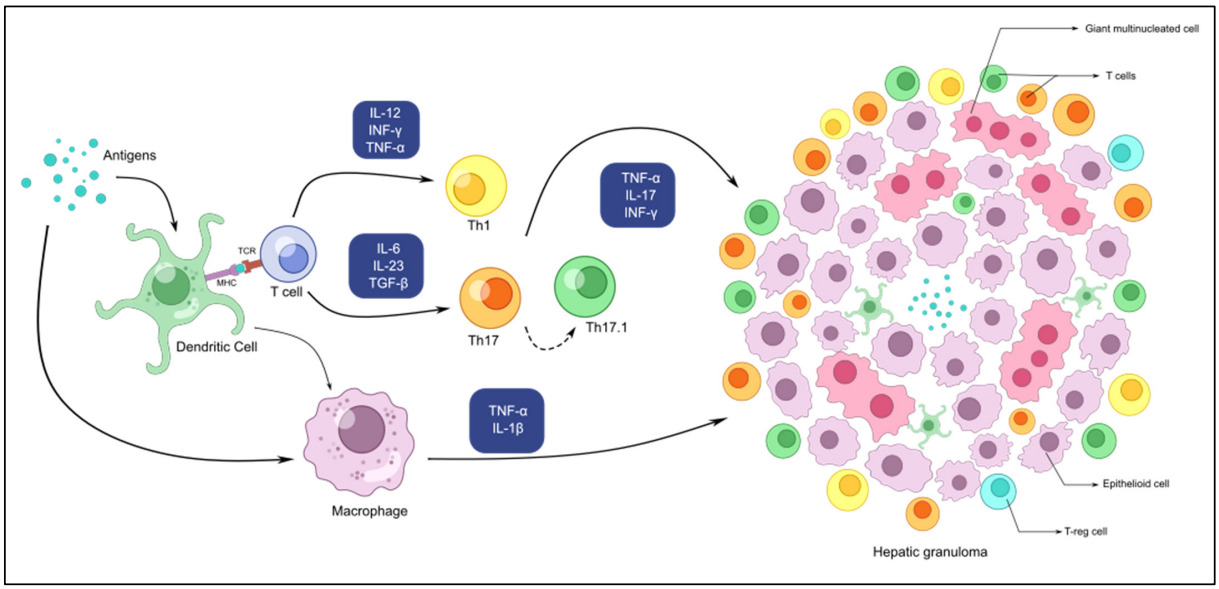

Figure 1. Molecular mechanism of granuloma formation. After exposure to an unknown external stimulus, the antigen-presenting cells (APCs) start to release cytokines that drive the differentiation of the circulating naïve T cell. The production of interleukin-12 (IL-12), tumor necrosis factor-α (TNF-α), and interferon-γ (INF-γ) stimulates the differentiation of helper-type 1 T cells (Th1), whereas interleukin-23 (IL-23), interleukin-6 (IL-6), and transforming growth factor-β (TGF-β) stimulate the differentiation of helper-type 17 T cells (Th17). Activated T cells than secrete IFN-γ, interleukin-2 (IL-2), and interleukin-17 (IL-17), ultimately leading to granuloma formation. The Th17 population

that secretes IFN-γ is called Th17.1. The granuloma is characterized by the presence of a center formed by activated macrophages called epithelioid cells, which usually fuse into giant cells, and a small number of CD4+ T lymphocytes. This structure is surrounded by B cells, CD8+ T cells, Treg, and fibroblasts.

The process of granuloma formation in the liver probably starts with the interaction between Kupffer cells and an exogenous stimulus that cannot be cleared, generating the dysregulated immune response that leads to granuloma formation [5]. Lesions can be found in any site, but they are most often present in the portal and peri-portal regions. In fact, different patterns of granuloma distribution and parenchyma damage have been observed in liver biopsy and autopsy studies of symptomatic patients [6]. Intrahepatic cholestasis is the most frequent finding, presenting in up to half of cases [22]. The damage observed is characterized by the progressive destruction of interlobular bile ducts, leading to ductopenia and periductal and portal region fibrosis. These are, however, non-specific patterns that could also be found in primary biliary cholangitis and primary sclerosing cholangitis [3,6,17].

Portal hypertension is uncommon in hepatic sarcoidosis and can occur in non-cirrhotic patients through different mechanisms [3]. Portal and periportal involvement create extrinsic venous compression with arteriovenous shunt and sinusoidal block, leading to granulomatous phlebitis and ischemia of both hepatic and portal veins. Those vascular changes progressively increase portal hypertension with further scarring and destruction of portal venules, leading to parenchymal distortion [3,6,17,23]. The compression and invasion of the hepatic veins have also been associated with some rare cases of sarcoidosis complicated by Budd–Chiari syndrome [24].

Consequently, progression to cirrhosis involves the predominance or interaction of one or more of the above mechanisms: cholestatic damage, granulomatous phlebitis, and hepatic vein thrombosis. This is also reflected in the varying clinical phenotypes of presentation of this condition [5,17,22].

3. Diagnosis

The diagnosis of systemic sarcoidosis is based on three elements: a suitable clinical and imaging presentation, the demonstration of non-necrotizing granulomatous inflammation in one or more tissue samples, and the exclusion of an alternative cause [25]. Consequently, the evidence of extrapulmonary sarcoid often requires a multidisciplinary team.

The demonstration of hepatic sarcoidosis involvement is based on a combination of clinical, laboratory, imaging, and histopathological assessment [26].

The illness is often asymptomatic, with hepatic affection occasionally identified through laboratory abnormalities or radiological findings. Nonspecific symptoms such as fatigue, fever, weight loss, abdominal discomfort, hepatomegaly, or splenomegaly may be part of the clinical presentation. Pruritus, jaundice, and right upper quadrant pain, due to the stretching of the Glisson's capsule, often occur in more advanced disease [5].

Laboratory exams can show a cholestatic pattern with elevated alkaline phosphatase (ALP) and gamma-glutamyl transferase (GGT), while transaminase elevations are less frequent. ALP levels are increased in 90% of cases and may reach values up to 5–10 times the upper normal limit. The extent of granulomatous inflammation correlates with the severity of liver test alterations [27]. Augmented bilirubin levels and hypoalbuminemia are rare and could be an expression of a more advanced liver involvement. To this day, there is no single test that provides a definitive diagnosis of sarcoidosis [1]. The most studied biomarker is the angiotensin-converting enzyme (ACE), which can be produced by epithelioid and giant cells, leading to increased circulating levels [28]. Elevated serum ACE levels have been reported in approximately 60% of patients with systemic sarcoidosis; however, due to its low sensitivity and specificity, its diagnostic value is limited [29].

Nevertheless, increased serum ACE levels are considered a laboratory indicator of systemic sarcoidosis and do not correlate with hepatic involvement.

Radiological findings are not pathognomonic, and normal imaging may be compatible with hepatic sarcoidosis. Ultrasound, computed tomography and magnetic resonance imaging could reveal organomegaly of the liver or the spleen, hypodense nodular lesions, and, in more severe cases, features of portal hypertension (such as ascites, esophageal varices, and portal hypertensive gastropathy) and cirrhosis. The most observed finding (5–35%) is hypodense nodules localized to the portal and periportal spaces of hepatic sinusoids; the second most frequent is hepatomegaly (8–18%). Contrast-enhanced ultrasound may reveal subtle focal lesions not visible on conventional ultrasound and may guide targeted biopsies [30,31].

Some authors have suggested that non-invasive markers of liver fibrosis, such as the fibrosis-4 (FIB-4) index or elastography, still require further evaluation and validation to reliably assess disease stage in hepatic sarcoidosis [29].

18F-Fluorodeoxyglucose positron emission tomography scan could help define the disease activity or search for multisystem involvement. It has also been used to guide biopsies to the most metabolically active sites [32,33]. The downsides are that the radiological findings are not pathognomonic and may overlap with other illnesses [34,35].

The gold standard for diagnosis is liver biopsy, as imaging alone cannot reliably distinguish hepatic sarcoidosis from malignancies or other conditions. There is no consensus in the literature regarding the optimal timing of biopsy [6]; however, it is generally recommended in patients with moderate or severe liver test abnormalities, when the diagnosis remains uncertain, when imaging suggests possible liver damage, or when treatment is being considered [36]. Most studies report a sensitivity of approximately 88% for diagnosing hepatic sarcoidosis [37].

Several liver biopsy techniques are available, including percutaneous needle biopsy (the most widely used) as well as trans-jugular, laparoscopic, mini-laparoscopic, and endoscopic ultrasound-guided approaches, all of which have been described in the literature. Some authors have reported an advantage of the mini-laparoscopy approach, as it allows sampling from both liver lobes. Therefore, more recent reports have noted the susceptibility to errors when using a single liver biopsy [38].

The biopsy shows non-caseating granulomas and giant cell granulomas multifocally distributed with possible lobular involvement, a preferred localization in the portal and periportal area or in the biliary ducts, and varying degrees of fibrosis or micronodular cirrhosis [29].

It is mandatory to eliminate other causes of granulomatosis, such as infection (e.g., tuberculosis or non-tubercular mycobacterial infections, aspergillosis, actinomycosis, and nocardiosis), autoimmune disease (e.g., primary biliary cholangitis), lymphoma, IgG4-related diseases, drug-induced liver injury, and other granulomatous diseases (e.g., granulomatous reactions to malignancy) [39–41] (Table 1).

Table 1. Different causes of granulomatous hepatitis.

Category	Etiology
Bacterial	Brucella, Coxiella, Bartonella, Nocardia, Actinomyces, Tuberculosis, non-tubercular mycobacteria
Parasitic	Schistosoma, Toxoplasma, Leishmania
Fungal	Histoplasma, Cryptococcus, Aspergillus
Viral (rare)	Epstein–Barr Virus, Cytmegalovirus
Autoimmune	Sarcoidosis, primary biliary cholangitis, Crohn disease, IgG4-related disease
Neoplastic	Lymphoma, sarcoid-like reaction
Drug-induced	Allopurinol, isoniazid, sulfonamides, carbamazepine, sexual hormones (potentially all drugs)

4. Treatment

The treatment of hepatic sarcoidosis is a medical challenge due to the different clinical manifestations of the disease and the lack of guidelines and a validated algorithm. The quality of evidence regarding therapeutic approaches for these patients is low and comes from case reports and observational and retrospective studies [6,7,42,43].

The decision to initiate a treatment must consider several factors: the level of LT abnormalities, the presence of symptoms, the stage of liver disease, concomitant extrahepatic manifestation and drug side effects [5]. The challenge is to identify those patients with a reduced quality of life and/or with a potentially progressive disease leading to end-stage organ damage in whom the expected benefits of treatment outweigh the risks [5,6].

Spontaneous resolution of hepatic sarcoidosis is observed in half of patients [5]. A wait-and-see approach could be reasonable in those who are asymptomatic or those who present with mild symptoms, without organomegaly at imaging investigation, with a mild alteration in LT, and without cholestasis [6,36]. In this case, Cremers et al. propose a laboratory follow-up every 3–6 months, but there is no consensus in the literature on specific LT cut-off values that require treatment initiation [36].

In most studies, corticosteroids are used as first-line therapy, typically prednisone at 20–40 mg/day. In the literature, there is no consensus on treatment duration, which is generally prolonged for at least 6 months, with tapering every 4–8 weeks, but also depends on laboratory and clinical response [7]. The aim is to taper corticosteroids gradually and discontinue them once adequate disease control has been achieved. This is reached in most patients (up to two-thirds), but in the remaining cases, lack of response, treatment intolerance, or inability to withdraw corticosteroids necessitates the introduction of a second-line therapy. Treatment failure is usually defined as the absence of improvement in laboratory parameters, evidence of disease progression on imaging or biopsy, and/or persistent symptoms [5–7,42,44].

Because hepatic sarcoidosis is predominantly a cholestatic condition, several authors have proposed ursodeoxycholic acid (UDCA) as a therapeutic option, particularly for patients with elevated GGT and ALP levels, and/or a cholestatic pattern upon liver biopsy. The dosage varies in the literature (10 to 15 mg/kg/day), and some studies suggested it as a first-line therapy due to the reduced side effects profile compared to corticosteroids [6,37,45]. It improves symptoms such as fatigue and itching and reduces the level of liver aminotransferases by simulating immune response modulation, with a success rate similar to the corticosteroid regimen [7,44]. Nevertheless, UDCA has not been demonstrated to reverse liver damage [36].

Immunomodulators such as azathioprine (AZA), methotrexate (MTX), and mycophenolate mofetil (MMF) have been studied as second-line strategies for patients who fail to respond to corticosteroids or as corticosteroid-sparing agents [6] (Figure 2 and Table 2).

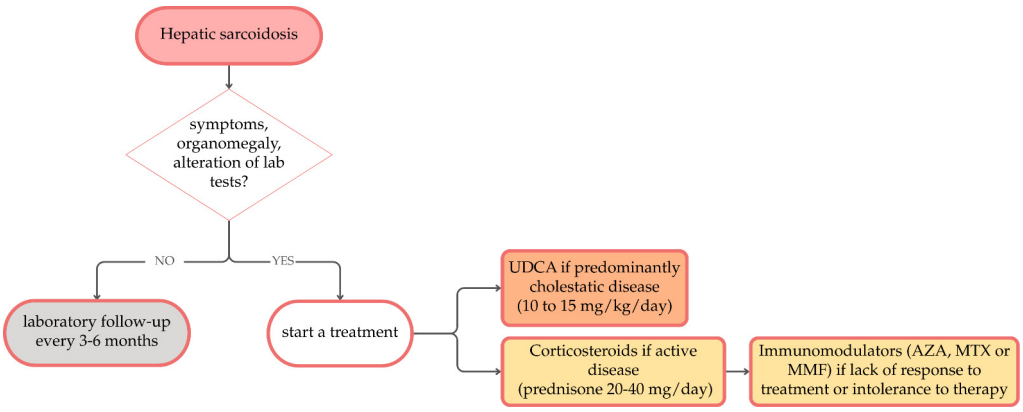

Figure 2. Therapeutic algorithm of hepatic sarcoidosis. AZA: azathioprine; MMF: mycophenolate mofetil; MTX: methotrexate; UDCA: ursodeoxycholic acid.

Table 2. Second-line and corticosteroid-sparing agents.

Drugs	Mechanism	Main Side Effects	Contraindications
Methotrexate (MTX)	Inhibition of the dihydrofolate reductase, blocking the conversion of folic acid to tetrahydrofolic acid affecting DNA synthesis. It reduces lymphocyte proliferation and modulates immune responses.	Myelosuppression Hepatotoxicity Gastrointestinal disorders Pulmonary and renal toxicity Pericarditis Thromboembolic events Retinopathy Rash, erythema, itching Stevens–Johnson syndrome	Hypersensitivity to MTX Severe hepatic impairment Severe renal impairment Active blood disorders Clinically active infection Pregnancy Breastfeeding Recurrent oral ulcers Alcohol abuse
Azathioprine (AZA)	Prodrug of 6-mercapopurine that acts as a purine antagonist. It inhibits de novo purine synthesis and suppresses the proliferation of T and B lymphocytes, leading to immunosuppressive effects.	Myelosuppression Bacterial, viral, fungal infections Gastrointestinal disorders Hepatotoxicity Pancreatitis Neoplasm (mainly skin) Stevens-Johnson syndrome	Hypersensitivity to AZA Active malignancy Deficit in TPMT activity Pregnancy Clinically active infection
Mycophenolate mofetil (MMF)	Selective, non-competitive and reversible inhibitor of inosine monophosphate dehydrogenase. It inhibits the de novo guanosine synthesis and suppresses the proliferation of T and B lymphocytes, leading to immunosuppressive effects.	Myelosuppression Bacterial, viral, fungal infections Nausea, vomiting Diarrhea Headache, dizziness Nephrotoxicity Dyslipidemia Skin tumors	Hypersensitivity to MMF Pregnancy Breastfeeding Clinically active infection

AZA is an inhibitor of purine metabolism and conveys its effect by lowering the level of circulating T and B cells. Is the most used second-line agent, and about two-thirds of patients reach a clinical or biochemical response [7]. The usual dosage is 50–150 mg/day, and its utilization is generally limited by the side effects: myelosuppression and hepatotoxicity. The risk is greater in patients with a genetic deficiency of thiopurine S-methyltransferase (TPMT) activity, so measuring enzyme activity is advised before starting treatment [46].

MTX acts by competitively inhibiting the enzyme dihydrofolate reductase and inhibiting DNA synthesis. The dosage used for hepatic sarcoidosis reported in the literature is 10–15 mg/week and has been shown to lead to a significant reduction in LT. A systematic review reported a slightly lesser clinical and laboratory response rate of the MTX with respect to AZA, but due to the small sample of patients treated with these drugs, more data are needed to establish if one of these two is superior. Suspension of MTX is associated with relapse of the disease, so treatment duration is not currently established [7,47].

One of the limitations of the use of AZA and MTX is the risk of hepatoxicity, with the potential development of drug-induced liver injury (DILI), especially in patients with already chronic liver disease [5]. A relapse or persistently elevated LT upon serial examination could be due to sarcoid or medication side effects, and this could lead to immunosuppressant discontinuation or repeated liver biopsy. Regarding MTX, the coadministration of folate could reduce toxic effects [36].

Another immunomodulator used in hepatic sarcoidosis is MMF, which showed a clinical response and a significant reduction in LT, but data regarding its utilization are scarce [6,36].

TNF-α is fundamental in the granuloma formation process, and for this reason, TNF inhibitors, particularly Infliximab and Adalimumab, have been used in systemic sarcoidosis. For hepatic involvement, they represent a third line of therapy, especially for long-term illnesses, as corticosteroid-sparing agents. Infliximab, given every 4–6 weeks, has been shown to be promising, with a high rate of response, but interruption has led to relapse, so treatment duration is currently unclear [48]. However, due to the lack of randomized controlled trials or prospective studies in this area, more data are needed to formulate specific indications [5,7,36,49].

The various cytokines involved in the granuloma formation (IFN-γ, IL-2, IL-6, IL-12, and IL-23) relay to the JAK-STAT pathway to transmit their signal. So, based on the pathogenesis of the disease, the utilization of JAK inhibitors has been proposed. To our knowledge, the clinical use of this class is very limited in systemic sarcoidosis [47].

Patients who do not respond to the treatment options and develop advanced liver disease should be considered for liver transplantation. The survival rate is similar to that of other hepatic conditions. Recurrence of the disease post-transplantation has been reported in small case reports and case series. The disease recurrence is probably related to the persistence of active systemic disease, but the actual pathobiological mechanisms remain unclear. Current evidence suggests that recurrence does not affect overall survival. Further studies are needed to clarify the underlying processes and their potential clinical implications [6,50–52].

5. Conclusions

Hepatic sarcoidosis is a manifestation of systemic sarcoidosis, and it is characterized by non-caseating granulomatous inflammation within the liver. The disease is a combination of diverse genetic elements and triggering factors, with several exposure routes. Ultimately, the illness has a variable clinical impact, and it is not yet completely understood. It should be suspected in patients with systemic sarcoidosis and unexplained cholestatic liver enzyme elevations [27]. Most patients experience a benign course and are not subjected to treatment; a minority will develop progressive liver disease, which may lead to substantial morbidity or, rarely, to end-stage disease [53].

Non-invasive imaging provides guidance for diagnosis, but biopsy is still the gold standard for confirmation; however, there are no recommendations for specific liver biopsy techniques.

Treatment regimens for systemic sarcoidosis are generally effective, but for refractory cases, the use of a second-line therapy that carries a risk of hepatotoxicity may complicate the interpretation of laboratory tests and the assessment of the actual response to therapy.

6. Future Directions

Despite decades of research on sarcoidosis, specific diagnostic and therapeutic algorithms for hepatic involvement are still lacking. Further studies are needed to stratify the risk of advanced liver disease using non-invasive methods, helping to determine when an invasive diagnostic approach is warranted. Several promising biomarkers for diagnosis have emerged in recent years, but they require additional validation before they can be integrated into clinical practice [54]. Randomized controlled trials are also necessary to clarify the role of the various drugs used in hepatic sarcoidosis. Given the more favorable safety profile of UDCA compared with corticosteroids, studies evaluating its potential therapeutic benefits are particularly desirable. Moreover, no guidelines currently define

when to initiate second-line therapy or which agent to choose; decisions are still based on low-quality evidence and center-specific experience. TNF-α inhibitors and JAK inhibitors appear to be promising medications for refractory cases, and further investigation may help establish their role in managing the most challenging presentations.

Author Contributions: Conceptualization, L.I.; writing—original draft preparation, V.B., L.B., M.P. and C.A.; writing—review and editing, L.I. and N.R.; supervision, L.I. All authors have read and agreed to the published version of the manuscript.

Funding: This research received no external funding.

Institutional Review Board Statement: Not applicable.

Informed Consent Statement: Not applicable.

Data Availability Statement: No new data were created or analyzed in this study.

Conflicts of Interest: The authors declare no conflicts of interest.

References

1. Judson, M.A. The Clinical Features of Sarcoidosis: A Comprehensive Review. *Clin. Rev. Allergy Immunol.* **2015**, *49*, 63–78. [CrossRef]
2. Miedema, J.; Cinetto, F.; Smed-Sörensen, A.; Spagnolo, P. The immunopathogenesis of sarcoidosis. *J. Autoimmun.* **2024**, *149*, 103247. [CrossRef] [PubMed]
3. Moreno-Merlo, F.; Wanless, I.R.; Shimamatsu, K.; Sherman, M.; Greig, P.; Chiasson, D. The role of granulomatous phlebitis and thrombosis in the pathogenesis of cirrhosis and portal hypertension in sarcoidosis. *Hepatology* **1997**, *26*, 554–560. [CrossRef]
4. Iannuzzi, M.C.; Rybicki, B.A.; Teirstein, A.S. Sarcoidosis. *N. Engl. J. Med.* **2007**, *357*, 2153–2165. [CrossRef] [PubMed]
5. Weinberg, E.M.; Aghayeva, S.; Reddy, R.K. Sarcoid liver disease—A review article. *Hepatology* **2025**. [CrossRef]
6. Belfeki, N.; Kammoun, S.; Ghriss, N.; Eldirani, C.; Mekinian, A. Current concepts on pathogenesis, diagnosis and management of hepatic sarcoidosis. *Rheumatol. Int.* **2025**, *45*, 130. [CrossRef]
7. Sinnanaidu, R.P.; Kumar, V.C.; Shunmugam, R.H.; Mahadeva, S. The clinical management of hepatic sarcoidosis: A systematic review. *JGH Open* **2024**, *8*, e13076. [CrossRef] [PubMed]
8. Arkema, E.V.; Cozier, Y.C. Sarcoidosis epidemiology: Recent estimates of incidence, prevalence and risk factors. *Curr. Opin. Pulm. Med.* **2020**, *26*, 527–534. [CrossRef]
9. Baughman, R.P.; Field, S.; Costabel, U.; Crystal, R.G.; Culver, D.A.; Drent, M.; Judson, M.A.; Wolff, G. Sarcoidosis in America. Analysis Based on Health Care Use. *Ann. Am. Thorac. Soc.* **2016**, *13*, 1244–1252. [CrossRef]
10. American Thoracic Society (ATS); European Respiratory Society (ERS); World Association of Sarcoidosis and Other Granulomatous Disorders (WASOG). Statement on Sarcoidosis. *Am. J. Respir. Crit. Care Med.* **1999**, *160*, 736–755. [CrossRef]
11. Sakthivel, P.; Bruder, D. Mechanism of granuloma formation in sarcoidosis. *Curr. Opin. Hematol.* **2017**, *24*, 59–65. [CrossRef] [PubMed]
12. Newman, K.L.; Newman, L.S. Occupational causes of sarcoidosis. *Curr. Opin. Allergy Clin. Immunol.* **2012**, *12*, 145–150. [CrossRef]
13. Calender, A.; Weichhart, T.; Valeyre, D.; Pacheco, Y. Current Insights in Genetics of Sarcoidosis: Functional and Clinical Impacts. *J. Clin. Med.* **2020**, *9*, 2633. [CrossRef] [PubMed]
14. Pacheco, Y.; Lim, C.X.; Weichhart, T.; Valeyre, D.; Bentaher, A.; Calender, A. Sarcoidosis and the mTOR, Rac1, and Autophagy Triad. *Trends Immunol.* **2020**, *41*, 286–299. [CrossRef]
15. Lee, S.; Birnie, D.; Dwivedi, G. Current perspectives on the immunopathogenesis of sarcoidosis. *Respir. Med.* **2020**, *173*, 106161. [CrossRef]
16. Linke, M.; Pham, H.T.T.; Katholnig, K.; Schnöller, T.; Miller, A.; Demel, F.; Schütz, B.; Rosner, M.; Kovacic, B.; Sukhbaatar, N.; et al. Chronic signaling via the metabolic checkpoint kinase mTORC1 induces macrophage granuloma formation and marks sarcoidosis progression. *Nat. Immunol.* **2017**, *18*, 293–302. [CrossRef]
17. Valla, D.-C.; Benhamou, J.-P. Hepatic granulomas and hepatic sarcoidosis. *Clin. Liver Dis.* **2000**, *4*, 269–285. [CrossRef]
18. Ragusa, F. Sarcoidosis and the Th1 chemokine MIG. *Clin. Ter.* **2018**, *169*, E308–E313. [CrossRef] [PubMed]
19. Kriegova, E.; Fillerova, R.; Tomankova, T.; Hutyrova, B.; Mrazek, F.; Tichy, T.; Kolek, V.; du Bois, R.; Petrek, M. T-helper cell type-1 transcription factor T-bet is upregulated in pulmonary sarcoidosis. *Eur. Respir. J.* **2011**, *38*, 1136–1144. [CrossRef]
20. Miedema, J.R.; Kaiser, Y.; Broos, C.E.; Wijsenbeek, M.S.; Grunewald, J.; Kool, M. Th17-lineage cells in pulmonary sarcoidosis and Löfgren's syndrome: Friend or foe? *J. Autoimmun.* **2018**, *87*, 82–96. [CrossRef]
21. Asif, H.; Ribeiro Neto, M.; Culver, D. Pulmonary fibrosis in sarcoidosis. *Sarcoidosis Vasc. Diffus. Lung Dis.* **2023**, *40*, e2023027.

22. Devaney, K.; Goodman, Z.D.; Epstein, M.S.; Zimmerman, H.J.; Ishak, K.G. Hepatic sarcoidosis. Clinicopathologic features in 100 patients. *Am. J. Surg. Pathol.* **1993**, *17*, 1272–1280. [CrossRef] [PubMed]
23. Dasani, D.B.; Fiel, M.I.; Simoes, C.C.; Morgenthau, A.S.; Schiano, T.D. The Varying Histology of Hepatic Sarcoidosis and the Relation of Bile Duct Damage and Loss to the Presence of Portal Hypertension and Cirrhosis. *Gastro Hep Adv.* **2025**, *4*, 100561. [CrossRef]
24. Odah, T.; Al-Khazraji, A.; Idriss, R.; Morrow, M.; Curry, M.P. Budd-Chiari Syndrome in a Patient with Simultaneous Diagnosis of Hepatic Sarcoidosis and Nodular Regenerative Hyperplasia. *ACG Case Rep. J.* **2019**, *6*, e00200. [CrossRef]
25. Jeny, F.; Vucinic, V.; Zhou, Y.; Valeyre, D.; Bhattacharyya, P.; Bickett, A.N.; Judson, M.A.; Obi, O.N.; Denis, J.E.; Talwar, D.; et al. Validation of the Sarcoidosis Diagnostic Score in a Multicontinental Study. *Ann. Am. Thorac. Soc.* **2023**, *20*, 371–380. [CrossRef]
26. Ungprasert, P.; Ryu, J.H.; Matteson, E.L. Clinical Manifestations, Diagnosis, and Treatment of Sarcoidosis. *Mayo Clin. Proc. Innov. Qual. Outcomes* **2019**, *3*, 358–375. [CrossRef]
27. Tadros, M.; Forouhar, F.; Wu, G.Y. Hepatic Sarcoidosis. *J. Clin. Transl. Hepatol.* **2013**, *1*, 87–93.
28. Zheng, S.-Y.; Du, X.; Dong, J.-Z. Re-evaluating serum angiotensin-converting enzyme in sarcoidosis. *Front. Immunol.* **2023**, *14*, 950095. [CrossRef] [PubMed]
29. Horst, L.J.; Zimmermann, K.; Lutz, J.; Weidemann, S.; Lüth, S.; Lohse, A.W.; Wiesch, J.S.Z.; Schramm, C.; Wehmeyer, M.H.; Müller, M.; et al. Insights into Hepatic Sarcoidosis: Analysis of Histological Patterns, Hepatic Complications and Therapeutic Approaches. *Liver Int. Off. J. Int. Assoc. Study Liver* **2025**, *45*, e70037. [CrossRef]
30. Uehara, K.; Kanda, T.; Arima, S.; Totsuka, M.; Honda, M.; Masuzaki, R.; Sasaki-Tanaka, R.; Matsumoto, N.; Ogawa, M.; Kogure, H. Liver biopsy as a useful diagnostic tool for hepatic sarcoidosis: A case report. *Med. Int.* **2024**, *4*, 38. [CrossRef]
31. Zardi, E.M. A case of hepatic sarcoidosis: What can ultrasound, colour, power, and pulsed Doppler do? *Ultrasound* **2025**, *10*, 1742271X251390783. [CrossRef]
32. Kaira, K.; Oriuchi, N.; Otani, Y.; Yanagitani, N.; Sunaga, N.; Hisada, T.; Ishizuka, T.; Endo, K.; Mori, M. Diagnostic usefulness of fluorine–18-α–methyltyrosine positron emission tomography in combination with 18F-fluorodeoxyglucose in sarcoidosis patients. *Chest* **2007**, *131*, 1019–1027. [CrossRef]
33. Watanabe, T.; Jodo, S. Hepatic sarcoidosis. *CMAJ Can. Med. Assoc. J.* **2018**, *190*, E988. [CrossRef]
34. Scott, G.C.; Berman, J.M.; Higgins, J.L. CT Patterns of Nodular Hepatic and Splenic Sarcoidosis: A Review of the Literature. *J. Comput. Assist. Tomogr.* **1997**, *21*, 369–372. [CrossRef] [PubMed]
35. Warshauer, D.M.; Molina, P.L.; Hamman, S.M.; Koehler, R.E.; Paulson, E.K.; Bechtold, R.E.; Perlmutter, M.L.; Hiken, J.N.; Francis, I.R.; Cooper, C.J. Nodular sarcoidosis of the liver and spleen: Analysis of 32 cases. *Radiology* **1995**, *195*, 757–762. [CrossRef]
36. Cremers, J.P.; Drent, M.; Baughman, R.P.; Wijnen, P.A.; Koek, G.H. Therapeutic approach of hepatic sarcoidosis. *Curr. Opin. Pulm. Med.* **2012**, *18*, 472–482. [CrossRef]
37. Ungprasert, P.; Crowson, C.S.; Simonetto, D.A.; Matteson, E.L. Clinical Characteristics and Outcome of Hepatic Sarcoidosis: A Population-Based Study 1976–2013. *Am. J. Gastroenterol.* **2017**, *112*, 1556–1563. [CrossRef] [PubMed]
38. Bains, L.; Paswan, N.; Khan, S.A.; Mandal, S. Abdominal Sarcoidosis: A Mystery Revisited. *Clin. Case Rep.* **2025**, *13*, e71557. [CrossRef] [PubMed]
39. Lagana, S.M.; Moreira, R.K.; Lefkowitch, J.H. Hepatic Granulomas: Pathogenesis and Differential Diagnosis. *Clin. Liver Dis.* **2010**, *14*, 605–617. [CrossRef]
40. Ielasi, L.; Fulco, E.; Reggidori, N.; Domenicali, M.; Foschi, F.G. Anabolic Androgenic Steroids and Hepatocellular Adenoma and Carcinoma: Molecular Mechanisms and Clinical Implications. *Gastroenterol. Insights* **2024**, *15*, 599–613. [CrossRef]
41. Zaghi, I.; Ielasi, L.; Stagni, B.; Cascavilla, A.; Ferri, S.; Ambrosini, V.; Riefolo, M.; Varani, S. A case of *Leishmania* infection with focal splanchnic involvement without systemic symptoms: A potential anti-inflammatory role for vitamin D. *Acta Clin. Belg.* **2023**, *78*, 321–324. [CrossRef]
42. Ryland, K.L. Hepatic Sarcoidosis: Incidence, Monitoring, and Treatment. *Clin. Liver Dis.* **2020**, *16*, 208–211. [CrossRef]
43. Della Corte, C.; D'AMato, D.; Rocchetti, A.; Martini, A.; Morelli, M.C.; Terracciani, F.; Campigotto, M.; Pugliese, N.; Pieri, G.; Simone, L.; et al. Clinical Features, Management and Prognosis of Hepatic Sarcoidosis: Insights from a Nationwide Italian Study. *Liver Int. Off. J. Int. Assoc. Study Liver* **2026**, *46*, e70459. [CrossRef]
44. Graf, C.; Arncken, J.; Lange, C.M.; Willuweit, K.; Schattenberg, J.M.; Seessle, J.; Julia, L.; Tobias, B.; Julia, D.; Nils, W.; et al. Hepatic sarcoidosis: Clinical characteristics and outcome. *JHEP Rep. Innov. Hepatol.* **2021**, *3*, 100360. [CrossRef] [PubMed]
45. Weinberg, E.; Stonelake, A.; Borges, K.; Toal, E.; Aghayeva, S.; Rossman, M.; Ligon, C.; Reddy, K.R. Ursodeoxycholic acid for the treatment of hepatic sarcoid: A pre-post pilot study. *Clin. Exp. Hepatol.* **2024**, *10*, 194–196. [CrossRef] [PubMed]
46. Zur, R.M.; Roy, L.M.; Ito, S.; Beyene, J.; Carew, C.; Ungar, W.J. Thiopurine S-methyltransferase testing for averting drug toxicity: A meta-analysis of diagnostic test accuracy. *Pharmacogenomics J.* **2016**, *16*, 305–311. [CrossRef] [PubMed]
47. Wang, A.; Singh, K.; Ibrahim, W.; King, B.; Damsky, W. The Promise of JAK Inhibitors for Treatment of Sarcoidosis and Other Inflammatory Disorders with Macrophage Activation: A Review of the Literature. *Yale J. Biol. Med.* **2020**, *93*, 187–195.

48. Sondhi, M.; Hasan, S.; Vadlamudi, K.; Bhuiyan, M.A.N.; Ali, A.; Muutu, T.; Hayat, S.; Umer, S.; Muzaffar, K. Management of Hepatic Sarcoidosis: A Retrospective Analysis of Patients at a University Hospital. *Mediterr. J. Rheumatol.* **2025**, *36*, 423–427. [CrossRef]
49. Crommelin, H.A.; Vorselaars, A.D.M.; van Moorsel, C.H.M.; Korenromp, I.H.E.; Deneer, V.H.M.; Grutters, J.C. Anti-TNF therapeutics for the treatment of sarcoidosis. *Immunotherapy* **2014**, *6*, 1127–1143. [CrossRef]
50. Vanatta, J.M.; Modanlou, K.A.; Dean, A.G.; Nezakatgoo, N.; Campos, L.; Nair, S.; Eason, J.D. Outcomes of orthotopic liver transplantation for hepatic sarcoidosis: An analysis of the United Network for Organ Sharing/Organ Procurement and Transplantation Network data files for a comparative study with cholestatic liver diseases. *Liver Transplant.* **2011**, *17*, 1027–1034. [CrossRef]
51. Kennedy, P.T.; Zakaria, N.; Modawi, S.B.; Papadopoulou, A.M.; Murray-Lyon, I.; du Bois, R.M.; Andreyev, H.J.N.; Devlin, J. Natural history of hepatic sarcoidosis and its response to treatment. *Eur. J. Gastroenterol. Hepatol.* **2006**, *18*, 721–726. [CrossRef]
52. Bilal, M.; Satapathy, S.K.; Ismail, M.K.; Vanatta, J.M. Long-Term Outcomes of Liver Transplantation for Hepatic Sarcoidosis: A Single Center Experience. *J. Clin. Exp. Hepatol.* **2016**, *6*, 94–99. [CrossRef]
53. Ibrahim, A.M.; Bhandari, B.; Soriano, P.K.; Quader, Z.; Gao, J.Z.; Shuster, D.; Mamillapalli, C.K. Hepatic Involvement in Systemic Sarcoidosis. *Am. J. Case Rep.* **2018**, *19*, 1212–1215. [CrossRef]
54. Della Zoppa, M.; Bertuccio, F.R.; Campo, I.; Tousa, F.; Crescenzi, M.; Lettieri, S.; Mariani, F.; Corsico, A.G.; Piloni, D.; Stella, G.M. Phenotypes and Serum Biomarkers in Sarcoidosis. *Diagnostics* **2024**, *14*, 709. [CrossRef]

Disclaimer/Publisher's Note: The statements, opinions and data contained in all publications are solely those of the individual author(s) and contributor(s) and not of MDPI and/or the editor(s). MDPI and/or the editor(s) disclaim responsibility for any injury to people or property resulting from any ideas, methods, instructions or products referred to in the content.