livers

MDPI

Review

The Liver in Pediatric Rheumatology: A Comprehensive Review

Mehul Jariwala [1], Tristan Kerr [1] and Mohit Kehar [2,*]

[1] Division of Pediatric Rheumatology, Department of Pediatrics, University of Saskatchewan, 103 Hospital Dr, Saskatoon, SK S7N 0W8, Canada
[2] Division of Pediatric Gastroenterology, Hepatology and Nutrition, Children's Hospital of Eastern Ontario, 401 Smyth Rd, Ottawa, ON K1H 8L1, Canada
* Correspondence: mkehar@cheo.on.ca

Abstract

Liver involvement in pediatric rheumatologic diseases is an increasingly recognized but often underappreciated clinical issue. Systemic autoimmune and autoinflammatory disorders including juvenile idiopathic arthritis, systemic lupus erythematosus, juvenile dermatomyositis, systemic vasculitis, and mixed connective tissue disease can all affect hepatic structure and function. The mechanisms of injury are multifactorial, encompassing immune-mediated inflammation, macrophage activation, drug-induced toxicity, and metabolic alterations. Hepatic manifestations range from asymptomatic transaminase elevations to fulminant liver failure, frequently influenced by immunosuppressive therapy and comorbid infections. Early recognition through routine biochemical monitoring, imaging, and targeted autoantibody testing is essential for differentiating primary disease activity from treatment-related injury. Timely, multidisciplinary management involving pediatric rheumatology and hepatology teams can prevent progression to chronic liver disease and optimize outcomes. This review summarizes the current understanding of hepatic pathology in pediatric rheumatology, highlighting diagnostic algorithms, monitoring strategies, and emerging therapeutic considerations.

Keywords: pediatric rheumatology; liver involvement; autoimmune hepatitis; macrophage activation syndrome; drug-induced liver injury; lupus hepatitis; juvenile idiopathic arthritis; connective tissue disease; pediatric hepatology

1. Introduction

Hepatic involvement in pediatric rheumatic diseases represents a complex and underrecognized clinical entity. Immune dysregulation, systemic inflammation, infectious triggers, and the expanding use of conventional and advanced immunomodulatory therapies all contribute to a wide spectrum of liver abnormalities. Although many children exhibit only mild, transient enzyme elevations, others can develop significant hepatocellular or cholestatic injury, granulomatous disease, vascular complications, or acute hepatic dysfunction in macrophage activation syndrome [MAS]. Distinguishing primary hepatic involvement of rheumatic disease from secondary causes, particularly drug-induced liver injury [DILI] or viral infection, poses significant challenges, given the overlapping biochemical and immunologic patterns. Given this diversity, a structured, clinically oriented approach is essential to differentiate benign inflammatory changes from serious hepatic disease and to guide timely management. This review synthesizes current knowledge on the mechanisms, clinical manifestations, and histopathology of hepatic involvement across pediatric rheumatic disorders and summarizes available evidence on the hepatotoxic

Check for updates

Academic Editor: Yankai Wen

Received: 11 December 2025
Revised: 3 February 2026
Accepted: 27 March 2026
Published: 8 May 2026

Copyright: © 2026 by the authors. Licensee MDPI, Basel, Switzerland. This article is an open access article distributed under the terms and conditions of the Creative Commons Attribution (CC BY) license.

potential of contemporary therapeutic agents, with the aim of guiding safer prescribing practices and timely recognition of liver disease.

2. Methods

This narrative review was conducted through a comprehensive literature search of PubMed, MEDLINE, and Embase databases. Search terms included combinations of 'pediatric rheumatology', 'liver disease', 'hepatotoxicity', 'autoimmune hepatitis', 'macrophage activation syndrome', 'systemic lupus erythematosus', and individual antirheumatic medications. Articles published in English up to December 2024 were considered. Priority was given to pediatric studies; however, relevant adult literature was included when pediatric data were limited. Case reports, case series, observational studies, clinical trials, and high-quality reviews were included.

2.1. Pediatric Rheumatic Disease and the Liver

Liver involvement in rheumatic disease remains poorly characterized in the literature to date, with a wide range of incidence and degree of hepatic involvement described [1–4]. Liver involvement appears to be common in a wide range of rheumatic diseases and ranges from asymptomatic mild elevation in transaminases to fulminant liver failure [2]. We describe the current understanding of the frequency, degree and etiology of hepatic involvement in various rheumatic disorders below, summarized in Table 1.

Table 1. Summary of liver manifestations, causes/mechanisms, and histopathology in various pediatric rheumatic diseases.

Rheumatic Disease	Liver Manifestations	Key Pattern	Causes/Mechanisms	Histopathology
Systemic Juvenile Idiopathic Arthritis [sJIA]	- Common: Hepatomegaly; elevated ALT, AST [5,6]. - MAS: acute liver failure; coagulopathy; significantly elevated ALT, AST [7]	Mild Hepatocellular Severe Hepatocellular/Synthetic dysfunction in MAS	- Unclear mechanism - Drugs: MTX [chronic toxicity, fibrosis risk], NSAIDs/aspirin [transaminase elevation, Reye syndrome]	- sJIA: Periportal inflammatory infiltrates and Kupffer cell activation [8] - MAS: Lobular and periportal hepatitis and hepatocellular apoptosis, and varying degrees of bile duct lesions [9,10].
Systemic Lupus Erythematosus [SLE]	- Uncommon: lupus hepatitis [LH] with elevated AST, ALT [11] - Rare: Coexistent AIH [12–14]	Mild–moderate hepatocellular; mixed	- Unclear mechanism - Drugs: MMF, AZA, NSAIDs, MTX	- Lobular and periportal inflammation, interface hepatitis, focal necrosis, chronic active or persistent hepatitis, granulomatous hepatitis, nodular regenerative hyperplasia, small vessel vasculitis, cholangitis, cholestasis and non-alcoholic steatosis [13,15,16]
Antiphospholipid Antibody Syndrome [APS]	- Very rare: Budd–Chiari Syndrome, hepatic veno-occlusive disease, hepatic infarction [17]	Vascular	- Venous and arterial thrombosis resulting from prothrombotic circulating antiphospholipid antibodies [18]	- n/a

Table 1. *Cont.*

Rheumatic Disease	Liver Manifestations	Key Pattern	Causes/Mechanisms	Histopathology
Sjogren's Syndrome [SS]	- Uncommon: Elevated ALT, AST [19] - Rare/Uncertain: Coexistent PBC [20]	Cholestatic	- Unclear mechanism	- n/a
Sarcoidosis	- Common: Hepatomegaly; elevated ALP, GGT; cholestasis; granulomatous hepatitis [21,22] - Uncommon: Elevated ALT, AST [23]	Cholestatic or mixed	- Noncaseating granulomas in portal tracts and lobules lead to cholestasis, portal hypertension from fibrosis/portal granulomas [21,22,24]	- Sarcoidosis granulomas composed of aggregates of epithelioid histiocytic and multinucleated giant cells with peripheral lymphocytes and fibrin deposits [21,24,25] - Intrahepatic cholestasis, ductopenia, and fibrosis of portal tracts [21,26]
Juvenile Dermatomyositis [JDM]	- Common: Elevated ALT, AST [from muscle breakdown] [2,27] - Rare: non-specific liver enzyme elevation [28,29]	AST/ALT elevation possible with normal CK, Muscle vs liver differentiation needed	- Unclear mechanism, associated with anti-MDA-5 positivity [30,31] - Drugs: MTX, cyclophosphamide, tacrolimus [potential hepatotoxic effects] - Muscle breakdown: AST, ALT from myositis can mimic hepatitis [2,27]	- Few reports; non-specific findings [28,30]
Vasculitides	- PAN: rare—cholestasis, hepatitis [32] - AAV: mild-moderate elevated ALT, AST [33,34] - BD: Budd–Chiari Syndrome, portal vein thrombosis [35,36] - KD: mild elevation in ALT, AST, GGT, ALP; hepatomegaly; gallbladder hydrops [37] - HSP: mild elevation in ALT, AST; rare—acute cholecystitis [37]	Hepatocellular	- PAN: Immune complex deposition in vessel walls leading to necrotizing inflammation, resulting in stenosis, thrombosis, dilatation and rupture [38] - BD: Vasculitis and hyper-coagulable/inflammatory state leading to thrombosis [39] - Drugs: immunosuppressive agents	- PAN: Necrotizing arteritis of medium sized vessels with fibrinoid necrosis and polymorphonuclear leukocytes [38] - AAV: Non-necrotizing granulomas [33]
IgG4-Related Disease [IgG4-RD]	- Uncommon: jaundice; biliary strictures; cholestasis [40,41]	Cholestatic	- IgG4-related systemic fibroinflammatory disease of intrahepatic, extrahepatic and periportal bile ducts [41]	- Storiform fibrosis, obliterative phlebitis, IgG4 positive staining plasma cells [41,42]

Abbreviations: ALT, alanine aminotransferase; AST, aspartate aminotransferase; MAS, macrophage activation syndrome; MTX, methotrexate; NSAID, non-steroidal anti-inflammatory drug; MMF, mycophenolate mofetil; AZA, azathioprine; AIH, autoimmune hepatitis; PBC, primary biliary cholangitis; ALP, alkaline phosphatase; GGT, gamma glutamyl transferase.

2.2. Juvenile Idiopathic Arthritis

The International League Against Rheumatism [ILAR] criteria define seven subtypes of Juvenile Idiopathic Arthritis [JIA] [43]. Primary hepatic involvement in most subtypes of JIA is thought to be rare, most frequently encountered as secondary to medications. The major exception to this is systemic JIA [sJIA], where hepatic involvement is part of its classification criteria [43]. sJIA commonly presents with hepatomegaly, and liver dysfunction, if present, is typically mild [5,6,44]. Liver involvement in Adult-Onset Still's

Disease [AOSD] is usually mild to moderate, and most liver enzyme abnormalities resolve with treatment [45,46]. Liver biopsy is not routinely performed, but case reports describe nonspecific periportal inflammatory cells and hyperplasia of Kupffer cells [8]. Adequate treatment of sJIA results in resolution of liver derangement [5,6].

MAS most commonly complicates sJIA and represents a hyperinflammatory state driven by activated macrophages, monocytes, and T-lymphocytes with excessive cytokine production [47]. Liver biopsies of patients with MAS reveal lobular and periportal hepatitis, hepatocellular apoptosis, and varying degrees of bile duct lesions [9,10]. Infiltrating CD8+ lymphocytes and macrophages are common, with expression of IFN-gamma, IL-6 and TNF-alpha [7]. Clinically, this results in hepatomegaly, liver dysfunction and coagulopathy [7,48]. With successful treatment, liver involvement usually resolves, though rare cases of liver failure requiring transplantation have been reported in AOSD [49,50].

2.3. Systemic Lupus Erythematosus

Systemic lupus erythematosus [SLE] is a multisystemic, autoimmune connective tissue disease, classified per the ACR/EULAR [American College of Rheumatology/European Alliance of Associations for Rheumatology] 2019 criteria [51]. Liver involvement in both adult and pediatric SLE is reported in up to 50% of patients over the course of their disease in some studies [11,12] but is generally mild in the majority of instances, typically presenting with subclinical elevation of liver enzymes [13]. Hepatic abnormalities may arise from infection, medications, coexisting autoimmune liver disease, or from primary lupus hepatitis [LH] [11]. While typically asymptomatic, clinical symptoms of LH are similar to other forms of hepatitis, and include fatigue, anorexia, and jaundice.

Although some reviews report an LH prevalence of 3–8% [13], most studies are retrospective and inconsistently account for confounding factors [52]. The recent literature suggests that LH may be more prevalent than previously appreciated, likely due to under-recognition of milder cases [14,15,52]. Although no diagnostic test is both sensitive and specific for differentiating LH from other causes of hepatitis, several adult studies report a higher frequency of anti–ribosomal P antibody positivity in LH compared with autoimmune hepatitis [AIH] [12–14]. If no etiology is identified following appropriate investigations and medication withdrawal, liver biopsy may be warranted. The pathophysiology of LH remains unclear and may be multifactorial [14]. This is supported by the diverse range of findings on histopathology, which may include lobular and periportal inflammation, interface hepatitis [also known as piecemeal necrosis], focal necrosis [hepatocyte punctate necrosis], chronic active or persistent hepatitis, granulomatous hepatitis, nodular regenerative hyperplasia, small vessel vasculitis, cholangitis, cholestasis and non-alcoholic steatosis [13,15,16]. Biopsy is important in uncertain cases to rule out other causes, which have different prognosis and treatment. The prognosis of LH is generally favorable, as it typically responds to appropriate SLE-directed therapy, and progression to cirrhosis in isolated LH is rare [12,15].

2.4. Antiphospholipid Syndrome

Antiphospholipid syndrome [APS] is characterized by arterial or venous thromboembolism, pregnancy morbidity and non-thrombotic manifestations in the presence of persistent antiphospholipid antibodies [APLs] [53]. Antiphospholipid syndrome may be primary or secondary to another autoimmune disease, such as SLE. Liver manifestations of APS include Budd –Chiari Syndrome [hepatic vein thrombosis], portal vein thrombosis, hepatic infarction, and hepatic veno-occlusive disease [17]. Budd–Chiari Syndrome is the most commonly reported hepatic complication of APS and may represent the initial presenting manifestation in some patients [2,54–56]. Portal vein thrombosis has been identified in

pediatric patients as well [57,58]. Clinical manifestations include abdominal pain, ascites and hepatomegaly, with diagnosis established through vascular imaging such as Doppler ultrasound or CT/MRI angiography [54]. Hepatic infarction is rare and described in the context of APS and pregnancy [59,60]. Hepatic veno-occlusive disease is very rare in cases with positive APLs [61,62], and no cases have been reported in the pediatric population.

2.5. Sjogren's Syndrome

Sjogren's syndrome [SS] is a systemic autoimmune disease primarily affecting the exocrine glands [63]. Similar to SLE patients, SS is associated with mild, typically clinically asymptomatic elevation in liver enzymes [19]. Reported incidence varies widely, but hepatic enzyme elevations may occur in up to 50% of patients over the course of the disease [3,19], with one pediatric SS review identifying hepatitis or transaminase elevation in 37% [64]. Notably, adult Sjögren's syndrome is associated with an increased risk of PBC, with prevalence ranging from 1 to 35% [20,65–67]. However, PBC is extremely rare in pediatrics, and no cases associated with pediatric SS have been reported.

2.6. Sarcoidosis

Sarcoidosis is an inflammatory, multisystemic disease characterized by non-caseating granuloma formation [21,68]. Liver involvement has been reported in 30–50% of pediatric sarcoidosis patients, presenting as hepatomegaly clinically or on imaging [69]. The liver is not a common site of biopsy in pediatric sarcoidosis, but patients with hepatomegaly or elevated transaminases will often have granulomas on biopsy [70]. In adults, up to 70% of patients on autopsy were found to have lesions, suggesting subclinical hepatic involvement is under-recognized [26].

On biopsy, sarcoidosis granulomas are composed of aggregates of epithelioid histiocytic and multinucleated giant cells with peripheral lymphocytes and fibrin deposits [22]. These granulomas can be seen throughout the liver parenchyma but have a predilection to portal/periportal regions [21,22]. Hepatic sarcoidosis may also demonstrate evidence of intrahepatic cholestasis, ductopenia, and fibrosis of portal tracts [21,26], and enzyme abnormalities are typically a cholestatic pattern in sarcoidosis with elevations in ALP and GGT [21,26,71].

Aside from the sarcoidosis seen in adults, pediatric patients may also present with early-onset sarcoidosis, also known as Blau syndrome, a condition caused by gain-of-function mutations in the NOD2 gene [25,68]. Blau syndrome often presents with some combination of uveitis, rash and arthritis [68,72]. Visceral manifestations have been increasingly recognized as well, affecting a third of patients in an international registry [72,73]. Cases of granulomatous liver involvement are uncommon in Blau but have been described, with one individual requiring transplantation [25,71,73–75].

2.7. Systemic Vasculitis

Systemic vasculitis is categorized by the predominant size of vessel involved, being either small, medium or large vessel vasculitis. Further, definitions of the most common vasculitis were agreed upon at the International Chapel Hill Consensus conference, held in 1994 and again in 2012 to further update nomenclature [76]. Liver involvement in vasculitis is uncommon and tends to be subclinical [77].

Polyarteritis nodosa [PAN] is a necrotizing vasculitis of the medium sized vessels. Hepatic involvement in adult PAN is rare and typically subclinical [38,78]. Jaundice and hepatomegaly have been reported as clinical manifestations [78–81]; however, these are from case series decades old and may have been related to infection, as PAN may be associated with hepatitis B [38]. There are case reports of liver infarction [82–84], liver rupture [85,86] and liver lobe atrophy [87] in adult patients. In pediatrics, case series to date

do not focus on hepatic involvement [88], but there are rare case reports of hepatobiliary system manifestations [89].

ANCA (Anti-Neutrophil Cytoplasmic Antibody)-associated vasculitis [AAV] is a group of small vessel vasculitis that includes Granulomatosis with Polyangiitis [GPA], Microscopic Polyangiitis [MPA] and Eosinophilic Granulomatosis with Polyangiitis [EGPA] [33]. Hepatic involvement is not well-described in pediatric literature to date. Elevated liver enzymes can occur at diagnosis in adults, present in up to 49.4%, and resolve with therapy [33,34].

Behcet's Disease [BD] is a vasculitis that can affect any size artery, as well as veins [39]. It can present with a wide range of symptoms, including recurrent oral and genital ulcers, skin manifestations, vascular lesions, thrombosis, ocular disease and neurological disease [39]. Hepatic involvement is very rare, with the most reported hepatic manifestation of BD being Budd–Chiari Syndrome following hepatic vein thrombosis [35,36,90].

Kawasaki Disease [KD] is a medium-vessel vasculitis that affects multiple organs, with coronary artery aneurysms as the most serious potential sequela. Hepatobiliary manifestations are common and include elevations in transaminases, hepatomegaly and gallbladder hydrops. These manifestations resolve with treatment of KD [37,91].

Henoch-Schonlein Purpura [HSP], also known as IgA vasculitis, presents with a combination of skin, GI, joint and renal manifestations and is typically a self-limited illness. Hepatic involvement may be seen in approximately 10% of patients as mild elevations in ALT and AST, which resolve with the HSP [92]. There are rare reports of pediatric patients with cholecystitis [93].

2.8. IgG4 Related Disease

IgG4-Related Disease [IgG4-RD] is a multifocal, fibroinflammatory condition that can affect a variety of organs and tissues, including the liver [40]. Cholangitis is the most common hepatobiliary involvement in IgG4-RD and can involve the extrahepatic, intrahepatic and perihilar bile ducts [41,94,95]. Clinically, patients present with abdominal pain, weight loss and jaundice [40,41]. Hepatobiliary involvement is relatively common, but estimates in cohorts vary widely, likely in part to the difficulty in diagnosing IgG4-RD [96,97].

The diagnosis of IgG4-RD relies on biopsy findings, elevation in serum IgG4 or IgG4/IgG1 ratio, and exclusion of alternative diagnoses [40]. Serum IgG4 level can be normal in 10–40% of IgG4-RD patients, and an elevation in serum IgG4 can be seen in autoimmunity, malignancy and infection [40,42,98]. Histologic features suggestive of IgG4-RD include obliterative phlebitis, IgG4+ staining plasma cells, and storiform fibrosis [41,42].

2.9. Systemic Sclerosis

Systemic sclerosis [SSc] is an autoimmune disease characterized by vasculopathy and fibrosis of the skin and internal organs [99]. Although there is an increased association between SSc and PBC, primary liver involvement is rare [100]. A study in adult patients with SSc looking at fibrosis and steatosis in the liver found no significant difference in rates of significant fibrosis or steatosis compared to the general population [101], suggesting liver involvement is not typically clinically significant.

2.10. Juvenile Dermatomyositis

Juvenile dermatomyositis [JDM] is a systemic autoimmune vasculopathy that presents with symmetrical proximal muscle weakness and typical skin findings [102]. In addition, extra-muscular manifestations can occur, including articular, pulmonary and cardiac involvement [27]. Due to muscle injury, ALT and AST can be mild to modestly elevated, and it is important to not mistake this for liver involvement [2,27]. However, there is increasing

evidence that liver disease can occur in patients with dermatomyositis, and a degree of suspicion is required especially in patients who have an ALT elevation disproportionate to other markers of muscle injury [28]. In adult dermatomyositis, patients positive for the myositis-specific antibody anti-MDA5 have been found to have hepatic disease [28,29]. There are also case reports of JDM patients, also positive for anti-MDA5, with liver abnormalities as well [30,31]. The few biopsies reported demonstrated non-specific liver inflammation [28,30].

2.11. Overlap Syndromes

Patients may present features of more than one rheumatic disease, such as a combination of SLE, JDM, SSc or JIA, termed overlap syndromes [103]. Overlap syndromes are a heterogeneous group with no classification criteria in pediatrics, resulting in a paucity of literature [104]. It is important to consider an overlap syndrome in the evaluation of liver involvement in rheumatic disease, as the hepatic involvement may resemble that of another disease entity, such as SS or APS in a patient with SLE. The most clearly defined overlap syndrome is Mixed Connective Tissue Disease [MCTD] [104]. Liver involvement in MCTD appears to be rare; in a systematic review of childhood onset MCTD, only 2.3% of patients had hepatitis at presentation, of which 60% was AIH [105].

Lastly, whilst autoimmune liver disease is not the primary focus of this review, it is important to highlight that an overlap between autoimmune liver disease and rheumatic disease can occur, as alluded to in earlier sections. While a rare occurrence overall [106], it is important to consider in addition to rheumatic disease activity, infection and iatrogenic causes.

Having outlined the spectrum of liver involvement across key pediatric rheumatic diseases, we now turn to a frequent iatrogenic contributor: hepatotoxicity from antirheumatic therapies.

2.12. Hepatotoxicity Related to Antirheumatic Drugs

The expanding therapeutic landscape in pediatric rheumatology has dramatically improved outcomes for children with chronic autoimmune and autoinflammatory diseases. Antirheumatic agents including conventional synthetic disease-modifying antirheumatic drugs [DMARDs], biologic agents, and small molecules are widely used in the management of pediatric rheumatic conditions. Although these medications are effective, they are associated with a spectrum of hepatotoxicity mediated by both direct and idiosyncratic mechanisms ranging from mild, transient aminotransferase elevations to severe DILI, drug-induced autoimmune hepatitis and, rarely, acute liver failure [ALF]. Pediatric patients also represent a uniquely vulnerable population due to differences in liver development, disease-associated immune dysregulation, concurrent infections, and the frequent use of combination therapies. Early recognition and proactive monitoring are crucial to prevent progression to fibrosis, steatohepatitis, or acute liver failure.

DILI is the leading cause of acute liver failure in North America and Europe, a major barrier to drug approval, and a common reason for regulatory restrictions or market withdrawal after approval [12,107]. Because DILI can replicate virtually any pattern of liver disease, it is difficult to anticipate during drug development. Several forms of DILI exist, with idiosyncratic DILI, an unexpected reaction not explained by the drug's pharmacologic properties, being the most widely recognized [108]. The clinical phenotype of a DILI episode is typically classified in adults as hepatocellular, cholestatic, or mixed, based on the R-value [109], which represents the ratio of serum alanine aminotransferase [ALT] to alkaline phosphatase levels [ALP] [both expressed as multiples of the upper limit of normal] at the onset of injury [108]. The use of R-values or scores like Roussel Uclaf Causality Assessment Method [RUCAM] [110] score in children is limited due to lack of evidence and use of

ALP levels which can be normally high in children due to growing age. Chronic drug-associated liver injury is generally defined by sustained biochemical and imaging hepatic abnormalities lasting more than one year after the onset [111]. Drug-induced autoimmune hepatitis is suspected when autoimmune hepatitis-like clinical, serologic, and histologic features appear in temporal association with a drug. Improvement after drug withdrawal and absence of relapse for 12–18 months support the diagnosis [112].

2.13. Liver Injury Related to NSAID

Nonsteroidal anti-inflammatory agents [NSAIDs] represent some of the most frequently utilized drugs globally. NSAIDs are considered relatively safe for long-term use in children; however, they are also included among the medications most frequently reported to cause idiosyncratic hepatotoxicity [113]. They are recommended for most patients with JIA and are also widely used in other pediatric rheumatic disorders. Commonly used NSAIDs in pediatric rheumatology include ibuprofen, naproxen, indomethacin, meloxicam, and celecoxib. They provide rapid analgesic effects, whereas their anti-inflammatory benefits take longer to manifest and may require doses up to twice those used solely for pain relief [114].

NSAID toxicity is mediated by elevated hepatobiliary drug concentrations, resulting in reactive metabolite formation, oxidative stress, and mitochondrial injury. Ibuprofen and naproxen, both propionic acid derivatives, are among the least hepatotoxic NSAIDs [115,116]. When hepatotoxicity does occur, they most often produce an acute hepatocellular or cholestatic pattern. The mechanism of injury is primarily metabolic and idiosyncratic in nature. NSAIDs within this class have also been associated with microvesicular steatosis, attributed to inhibition of mitochondrial function by the carboxylic radical. Importantly, such micro vesicular steatosis is often not associated with acute hepatic failure [117–119]. Within the acetic acid derivative class, diclofenac is the agent most strongly associated with hepatotoxicity, which is almost exclusively hepatocellular in pattern. The mechanism of injury is predominantly idiosyncratic [120]. Cyclooxygenase-2 inhibitors, such as celecoxib, appear to have a lower hepatotoxic potential compared with non-selective NSAIDs; however, pediatric data remain limited [121,122].

Salicylates can produce liver injury in a dose-dependent manner; however, hepatotoxicity is uncommon at routine therapeutic doses [113,118,123]. Aspirin, the earliest and most widely used NSAID, is metabolized in the liver to salicylate and several downstream compounds. Liver injury is most often described after prolonged or repeated exposure. Management consists primarily of discontinuing the drug, and hepatic injury generally resolves even when the presentation is severe. High-dose salicylate therapy and hypoalbuminemia have been identified as risk factors for toxicity [124]. A distinct and serious form of salicylate-related hepatic injury is Reye's syndrome [125]. This syndrome occurs predominantly in children who receive aspirin during viral infections such as varicella or influenza and is characterized by acute hepatic dysfunction with marked microvesicular steatosis [118]. The strong association between Reye's syndrome and aspirin use in febrile pediatric patients has led to clear recommendations against aspirin administration during viral illnesses in children [126]. Concomitant use of NSAIDs with other antirheumatic medications may further increase the overall risk of hepatotoxicity.

3. Non-Biologic [Synthetic] Disease-Modifying Antirheumatic Drugs [DMARDs]

3.1. Methotrexate

Low-dose methotrexate [MTX] is one of the most widely used DMARDs in pediatric rheumatology and is commonly employed as first-line therapy across multiple conditions,

including JIA, localized scleroderma, Takayasu arteritis, sarcoidosis, Behçet disease, chronic uveitis, and systemic lupus erythematosus [127]. MTX can affect the liver along a broad spectrum, from asymptomatic transaminase elevation to steatosis, hepatic fibrosis, and, rarely, acute hepatic necrosis. In children with JIA, however, clinically significant MTX-related hepatotoxicity appears to be uncommon.

Mild acute liver toxicity characterized by elevated transaminases is the most frequent abnormality and occurs in approximately 9–17% of children with JIA receiving MTX [128]. Most elevations are transient and resolve spontaneously with dose adjustment, or after a brief drug interruption [129,130]. Although MTX has the potential to cause both acute and chronic liver injury, cirrhosis has not been reported in children with rheumatic diseases treated with low-dose MTX [131–134].

Histologic liver injury associated with methotrexate exposure has traditionally been assessed using the Roenigk histological grading system, a semi-quantitative scoring method. This system categorizes liver injury from grade I [mild steatosis or portal inflammation] through grade III [periportal fibrosis] to grade IV [cirrhosis], allowing standardized assessment of methotrexate-associated hepatic injury and fibrosis risk across studies [135]. Lahdenne et al. [136] evaluated percutaneous liver biopsies from 34 children with JIA treated with MTX for more than 2.4 years and reported predominantly mild histologic changes. Among patients receiving $\geq$20 mg/m^2, four had Roenigk grade II changes and five had grade I findings; one biopsy showed extensive steatosis without other abnormalities. Importantly, **none** of the specimens demonstrated fibrosis or cirrhosis. Similarly, Haskes and colleagues found that 27 biopsy specimens [82%] were Roenigk grade I, 4 [12%] were grade II, and 2 [6%] were grade IIIA, again with no evidence of significant fibrosis. Elevated liver enzymes and increased body mass index were the only variables associated with higher Roenigk scores [132]. Kocharla et al. [130] reported that liver enzyme elevations > 2 $\times$ ULN are rare in JIA, regardless of MTX exposure.

More recent non-invasive studies support these findings. A study examining the prevalence of hepatic steatosis and fibrosis using transient elastography found that steatosis is relatively common in MTX-treated JIA patients, particularly in adolescents who are overweight/obese or have received higher cumulative MTX doses, yet none of the participants demonstrated elastography-defined hepatic fibrosis [137]. Similarly, Gungorer et al. [138] observed reduced liver elasticity in MTX-treated patients compared with controls; however, this change did not correlate with cumulative MTX dose, and no significant fibrosis was identified. Interestingly, the study by Sümeyra Özdemir Çiçek et al. [139], which evaluated liver elasticity using shear-wave elastography in methotrexate-treated patients with JIA, did not demonstrate increased liver stiffness. Elastography measurements in children receiving methotrexate were comparable to those of age-matched healthy controls, suggesting that long-term therapy was not associated with subclinical hepatic fibrosis in this cohort.

3.2. Sulfasalazine

Sulfasalazine is widely utilized in the management of mild to moderate inflammatory bowel disease and has also demonstrated therapeutic benefit in childhood inflammatory arthritis, particularly oligoarticular subtypes and spondyloarthritis with peripheral joint involvement [140]. Reports from adult cohorts indicate that sulfasalazine-associated hepatitis is uncommon, with an estimated incidence of approximately 0.4%, and most cases present within the first month of treatment initiation [141].

In pediatric populations, elevations in liver enzymes represent the most frequently observed hepatic adverse effect [141–143]. Children with systemic-onset juvenile idiopathic arthritis appear to respond less favorably and exhibit higher rates of drug intolerance, occasionally manifesting as serum sickness-like reactions [141]. Although uncommon,

fulminant hepatitis has been described in patients receiving sulfasalazine for Crohn's disease [144]. Additional serious hypersensitivity phenomena have been reported, including sulfasalazine-induced Stevens–Johnson syndrome and toxic epidermal necrolysis accompanied by hepatic involvement [145]. Sulfasalazine hypersensitivity reactions consistent with DRESS [Drug Reaction with Eosinophilia and Systemic Symptoms] and leading to elevated transaminases have also been described [146,147]. These reactions are thought to reflect sulfonamide sensitivity related to the sulfapyridine component of the drug, with a particular predisposition in individuals who are slow acetylators [148].

3.3. Leflunomide

Leflunomide has demonstrated safety and efficacy comparable to methotrexate [MTX] in patients with polyarticular-course juvenile idiopathic arthritis [JIA] [149]. In published cohorts, elevations in serum transaminases were generally mild, with one study reporting that only 3 of 43 children required permanent discontinuation due to hepatic abnormalities. Other pediatric series similarly describe a relatively low frequency of leflunomide-associated transaminase elevation, typically ranging from 4% to 15% [150,151]. Such abnormalities are thought to reflect direct hepatocellular injury and often improve with temporary treatment interruption. Acute liver failure associated with leflunomide remains rare in children. Despite the U.S. Food and Drug Administration's boxed warning for severe hepatotoxicity with leflunomide, reports of clinically significant liver injury in the pediatric population are uncommon [152]. In an adult analysis of 17 cases of leflunomide-related hepatotoxicity drawn from two large drug-induced liver injury registries, notable demographic and clinical differences were observed: 89% of Indian cases occurred in women and were uniformly associated with severe cutaneous adverse reactions, with a median drug latency of 49 days. In contrast, only 37.5% of cases from the US Drug-Induced Liver Injury Network [DILIN] registry were female, none demonstrated cutaneous involvement, and the median latency period was substantially longer at 166 days.

3.4. Azathioprine

Azathioprine is a thiopurine pro-drug that undergoes non-enzymatic conversion to its active metabolite, 6-mercaptopurine [6-MP], primarily within hepatocytes and erythrocytes. It remains a commonly utilized immunosuppressive agent across several pediatric and adult autoimmune disorders, including systemic lupus erythematosus, cutaneous vasculitides, dermatomyositis, ANCA-associated vasculitis, and Behçet disease.

Reported hepatic adverse effects range from acute drug-induced liver injury to vascular disorders such as nodular regenerative hyperplasia, hepatic veno-occlusive disease, and peliosis hepatis [112]. In inflammatory bowel disease cohorts, the estimated prevalence of azathioprine-related hepatotoxicity is low, averaging approximately 3%, with an annual incidence of clinically relevant liver injury around 1.4% [153]. Comparable prevalence data in pediatric rheumatology remain limited. In one series assessing adverse drug reactions among children with chronic rheumatic disease, azathioprine was associated with elevated liver enzymes in 5 of 115 patients [154]. Although uncommon, azathioprine has been implicated in severe cholestatic injury, including protracted cholestasis and vanishing bile duct syndrome [155].

Overall, hepatotoxicity from azathioprine appears to be largely idiosyncratic and multifactorial rather than strictly dose dependent [153,156,157]. Given this potential for uncommon but serious hepatic complications, regular monitoring of liver enzymes is recommended throughout treatment.

4. Corticosteroids

Corticosteroids are among the most used immunosuppressive agents in pediatric rheumatology and are frequently employed in the treatment of immune-mediated liver disease, including autoimmune hepatitis and severe inflammatory flares. Although they are often used to treat DILI, corticosteroids themselves can, in rare circumstances, contribute to hepatic injury through several indirect and direct mechanisms [158]. The hepatic effects of corticosteroids are most related to metabolic and immunologic consequences rather than intrinsic hepatotoxicity. Prolonged exposure or supraphysiologic dosing may lead to hepatomegaly, hepatic steatosis, or hepatic glycogenosis, particularly in children, with associated elevations in aminotransferases. Corticosteroids may also exacerbate underlying metabolic dysfunction-associated steatotic liver disease [MASLD], largely through their effects on insulin resistance, weight gain, and lipid metabolism. In most cases, these changes are clinically mild and reversible with dose reduction or discontinuation [159]. Corticosteroid therapy can also worsen pre-existing chronic viral hepatitis. In patients with chronic hepatitis B, immunosuppression may increase viral replication, with clinically significant hepatic flares occurring most commonly during dose reduction or withdrawal as immune function recovers [160]. These risks underscore the importance of viral hepatitis screening and prophylaxis prior to initiation of prolonged or high-dose corticosteroid therapy. Rarely, high-dose intravenous corticosteroids, particularly pulse methylprednisolone, have been associated with acute hepatocellular injury that may present weeks after exposure and can be severe [161]. In such cases, alternative causes including viral reactivation and autoimmune hepatitis must be carefully excluded, as corticosteroids may act as a trigger for immune-mediated liver injury rather than as direct hepatotoxin. Overall, clinically significant liver injury attributable solely to corticosteroids is uncommon, and most reported hepatic complications reflect exacerbation or unmasking of underlying liver disease.

4.1. Other Synthetic DMARDs

Hepatotoxicity associated with hydroxychloroquine [HCQ] is considered exceedingly rare; however, DILI attributable to HCQ has been described, including isolated cases of fulminant hepatic failure occurring shortly after treatment initiation [162,163]. Pediatric reports remain sparse, reflecting both infrequent use at high-risk doses and the overall low incidence of clinically significant liver injury in children. HCQ undergoes extensive hepatic metabolism through the cytochrome P450 system, which has been postulated to contribute either directly or indirectly to the development of hepatocellular injury in susceptible individuals [164]. Cyclosporine A-related increases in liver enzymes or bilirubin are uncommon at the lower doses typically used in rheumatology [165]. Mycophenolate mofetil is widely used across multiple rheumatic conditions and is considered among the safer synthetic DMARDs in pediatric practice. To date, acute liver injury has not been reported in children, although isolated cases have been described in older adults with polyarteritis nodosa and in non-rheumatologic settings.

4.2. Biological Therapy and Hepatoxicity

4.2.1. TNF Inhibitor Hepatotoxicity

Tumor necrosis factor inhibitors [TNFi] are widely used as second-line therapy for children with juvenile idiopathic arthritis [JIA] who respond inadequately to conventional synthetic DMARDs. Agents currently employed include the TNF receptor fusion protein etanercept and monoclonal anti-TNF antibodies such as adalimumab, certolizumab pegol, golimumab, and infliximab, along with related biosimilars [166]. Transient, mild elevations in serum liver enzymes have been commonly reported during TNFi therapy in children [167]. More clinically significant hepatic involvement, although uncommon,

has also been described, including cases of autoimmune hepatitis in children treated with anti-TNF agents [168].

Severe hepatic reactions have been documented following infliximab exposure, with onset ranging from two weeks to more than one year after treatment commencement, most often presenting with hepatocellular injury, though cholestatic patterns have also been reported [112]. Observational data suggest variability in hepatotoxicity reporting: a pediatric retrospective cohort that included multiple inflammatory conditions noted no liver enzyme abnormalities attributed to anti-TNF therapy [167], whereas analysis of the U.S. DILI Network database identified 34 cases of DILI in adults attributed to TNF-α antagonists, with infliximab associated with the highest risk compared with etanercept and adalimumab [169]. Rare instances of fulminant hepatic failure have been described in older individuals [170]. Available data indicate that liver injury from TNF-α antagonists may represent a class effect, with immune-mediated mechanisms frequently implicated and hepatocellular injury being the dominant phenotype, though mixed injury patterns and cholestasis have also been reported [169]. In a large pediatric safety evaluation of adalimumab involving patients with JIA, psoriasis, and Crohn's disease, liver-related adverse events were identified in approximately 1.5% of exposed children, including hepatitis, hepatocellular injury, hepatotoxicity, and nonspecific liver disorders [166]. TNF inhibitors have also been associated with hepatitis B reactivation among chronic carriers, a concern that is less pronounced in children yet still warrants routine screening prior to treatment initiation [171]. Baseline viral hepatitis screening, routine biochemical monitoring, and early evaluation of unexplained aminotransferase elevation are recommended to ensure safe and timely management in children receiving these agents.

4.2.2. IL-1 Inhibitors

Reports in the pediatric rheumatology literature indicate that anakinra can rarely be associated with liver test abnormalities or clinically apparent hepatic injury [172]. Most descriptions come from individual case reports or small case series involving children treated for conditions such as systemic juvenile idiopathic arthritis and Kawasaki Disease [173]. Similar observations have been published in adults receiving anakinra for autoinflammatory diseases, including rheumatoid arthritis and Still's disease, suggesting that this reaction is not confined to the pediatric population. Although uncommon, suspected anakinra-related hepatotoxicity is clinically relevant, particularly when liver enzyme elevations arise after treatment initiation. In several published examples, withdrawal of the drug was followed by normalization of liver tests, and in select cases, therapy was safely reintroduced due to ongoing disease activity without subsequent recurrence of liver injury [174]. Recently, additional pediatric cases have been documented, further supporting that hepatotoxicity can occur in association with anakinra, even though its overall frequency remains low [173–175].

Canakinumab appears to have a favorable hepatic safety profile, with a lower likelihood of affecting liver metabolism than anakinra and no published cases of clinically evident acute liver injury directly attributed to its use [176]. Across multiple large trial programs, asymptomatic increases in alanine aminotransferase have been reported in a small minority of treated patients, typically within the range of 1–3%, and on occasion classified as hepatobiliary adverse events or hepatitis [172,177,178]. Although these abnormalities have been infrequent and generally mild, the potential for liver enzyme elevation supports routine monitoring of hepatic function during therapy, particularly in children and adolescents. Notably, to date there are no documented instances of clinically apparent liver injury with jaundice associated with canakinumab, reinforcing its overall hepatic tolerability among IL-1 targeted agents [176].

4.2.3. IL-6 Inhibitors

Tocilizumab, a recombinant humanized monoclonal antibody targeting the interleukin-6 receptor, is approved for systemic and polyarticular categories of JIA. In clinical experience, transient elevations in liver enzymes occur more often among children with systemic JIA, with transaminase abnormalities documented in approximately 24% of patients [179]. Isolated histopathological descriptions of liver injury in the absence of biochemical abnormalities have also appeared, including focal hemorrhagic necrosis, steatosis, and perisinusoidal fibrosis [180]. In a long-term extension study evaluating two-year efficacy and safety of tocilizumab in polyarticular-course JIA, no events met the criteria for Hy's law, and liver enzyme elevations that did occur were attributed to intercurrent Epstein–Barr virus or other causes; by week 104, ALT values < 2.5 × ULN were observed in 35% of patients and >5 × ULN in 2%, both considered secondary to other etiologies [181]. A separate retrospective cohort of 104 children treated for various pediatric rheumatic diagnoses reported only a single case of liver enzyme elevation in a patient with JIA, who was also receiving concurrent methotrexate; the injury emerged after several months, displayed a predominantly hepatocellular pattern, and lacked features of hypersensitivity or autoimmunity [45]. Clinically apparent liver injury with jaundice has been reported, although such cases are uncommon, generally self-resolving, and recovery typically occurs within two to three months. Tocilizumab has also been linked to rare instances of hepatitis B reactivation, underscoring the need for screening but suggesting overall low risk [180,182]. Modification of tocilizumab therapy is conditionally recommended based on liver function monitoring. In the presence of elevated aminotransferases, a dose reduction or interval extension is advised for levels 1–3× the upper limit of normal [ULN], temporary interruption for levels ≥ 3 × ULN, and permanent discontinuation for levels ≥ 5 × ULN [183].

4.2.4. JAK Inhibitors

Tofacitinib has demonstrated a favorable hepatic safety profile in pediatric rheumatology, with rare mild elevation of transaminases. In a large phase 3, double-blind, placebo-controlled withdrawal trial, the drug was reported to be well tolerated, with only mild transaminase elevations occurring in approximately 11% of treated patients, and no signal suggestive of significant hepatotoxicity [181]. Comparable findings have been reported when tofacitinib was used for other pediatric rheumatic conditions [184]. Published evidence of drug-induced liver injury associated with tofacitinib remains extremely limited, with only a single case described in a child with alopecia areata. Data regarding hepatic effects of baricitinib in pediatric populations are similarly scarce. In the phase 3, randomized, double-blind, placebo-controlled JIA trial, elevated liver enzymes were noted in roughly 3% of participants [185] and were generally mild. Baricitinib has been used in cases of Still's disease complicated by severe hepatic injury and has been explored as a therapeutic option to control systemic inflammation and facilitate recovery of liver function [186]. Baricitinib has been used in patients with interferon-mediated autoinflammatory diseases, with no reported adverse hepatic outcomes [187].

4.2.5. Other Biological Therapies

Rituximab is a chimeric mouse–human monoclonal antibody directed against CD20. It has been widely employed across multiple autoimmune and inflammatory conditions, including systemic lupus erythematosus, ANCA-associated vasculitis, and juvenile dermatomyositis, among others [188]. In addition, rituximab has demonstrated therapeutic benefit in refractory autoimmune hepatitis [189]. Drug-induced liver injury [DILI] attributed to rituximab has been reported in adult literature, although such cases remain rare [190,191]. Importantly, no significant hepatic safety signals were identified across

two large pediatric case series evaluating rituximab use in children with rheumatic diseases [192–194]. A large-scale pediatric clinical trial evaluating the safety and efficacy of intravenous belimumab in pediatric SLE found that elevations in serum aminotransferase levels were uncommon, and no additional hepatic surveillance is required beyond that indicated for the underlying disease [195].

4.3. Hepatic Response in Infection

Children with rheumatic diseases, especially those on immunosuppressive therapy, are at increased risk of infections that may involve the liver and mimic or exacerbate autoimmune disease. The most relevant infections and their hepatic/rheumatologic manifestations are summarized in Table 2.

Table 2. Key infections associated with liver involvement and rheumatic manifestations in pediatric rheumatology.

Infection	Virus/ Bacterium	Prevalence	Liver Involvement	Key Rheumatic Autoimmune Manifestations [May Mimic or Trigger]	Strength of Association
Hepatitis B [HBV]	Enveloped dsDNA virus	Rare in children in vaccinated populations	Acute hepatitis [mild → fulminant]; ↑ ALT/AST, jaundice Chronic hepatitis more common	Polyarteritis nodosa [PAN], arthralgia/myalgia	Strong [7–50% of PAN cases HBV+] [196–199]
Hepatitis C [HCV]	Enveloped ssRNA virus	Uncommon in children	Usually mild or asymptomatic in acute phase. Chronic hepatitis more common	Mixed cryoglobulinemia vasculitis [rare in peds], non-erosive arthritis, sicca symptoms, ±low-titre ANA/RF [mimics Sjögren's or SLE]	Established for cryoglobulinemia [adults]; extremely rare in children [200–203]
Epstein–Barr Virus [EBV]	dsDNA herpesvirus	>90% seropositive by adulthood; primary IM more symptomatic in adolescents	Mild ↑ transaminases common; rarely severe hepatitis [primary infection or reactivation]	Overlap with SLE symptoms, ↑ reactivation in SLE → flares, arthritis, secondary Sjögren's	Strong temporal & molecular mimicry evidence in SLE; common differential [204–206]
Cytomegalovirus [CMV]	dsDNA herpesvirus	Up to 90% seroprevalence	Common mild hepatitis in symptomatic infection	Possible trigger of SSc; less clear for SLE/RA; reactivation → apparent "flare" in immunosuppressed rheumatic patients	Reactivation well-documented with glucocorticoids/immunosuppressants [15,207,208]
Tuberculosis [TB]	Mycobacterium tuberculosis	Higher risk in endemic areas & immunosuppressed	Hepatic involvement in up to 68% [granulomas, KC hyperplasia, fibrosis]; often subclinical	Granulomatous vasculitis [mimics GPA/TAK/sarcoidosis], septic arthritis, Poncet's reactive arthritis	Important mimic; no proven causal link with TAK [209–212]
Lyme disease [Borrelia burgdorferi]	Spirochete	Depends on geographic exposure	Early disseminated phase: mild ↑ transaminases	Late Lyme arthritis [oligoarticular, knee predominant]	Well-established late complication; liver involvement mild [213,214]
Reactive arthritis-associated GI pathogens	Yersinia, Salmonella, Campylobacter, Shigella	Common triggers of ReA in children/adolescents	Rare hepatitis reported	Classic reactive arthritis [oligo/polyarticular, lower limb]	Temporal association; liver involvement uncommon [215,216]

ALT: alanine aminotransferase, ANA: antinuclear antibody, AST: aspartate aminotransferase, CMV: cytomegalovirus, dsDNA: double-stranded DNA, EBV: Epstein–Barr virus, GI: gastrointestinal, GPA: granulomatosis with polyangiitis, HBV: hepatitis B virus, HCV: hepatitis C virus, IM: infectious mononucleosis, KC: Kupffer cells, PAN: polyarteritis nodosa, RA: rheumatoid arthritis, ReA: reactive arthritis, RF: rheumatoid factor, SLE: systemic lupus erythematosus, ssRNA: single-stranded RNA, SSc: systemic sclerosis, TAK: Takayasu arteritis, TB: tuberculosis.

5. Approach to Liver Enzyme Elevation in Pediatric Rheumatology

Evaluation of liver abnormalities in children with rheumatic disease begins with clarifying the clinical context in which the abnormalities were detected [Figure 1]. Mild, asymptomatic elevations in aminotransferases are common during systemic inflammation, particularly in sJIA and SLE, and often normalize with disease control. In contrast, jaundice, hepatomegaly, abdominal pain, or rapidly rising enzymes should prompt consideration of MAS, viral infection, medication toxicity, vascular complications, or cholestatic and granulomatous disorders. A focused history and physical examination can help refine the differential.

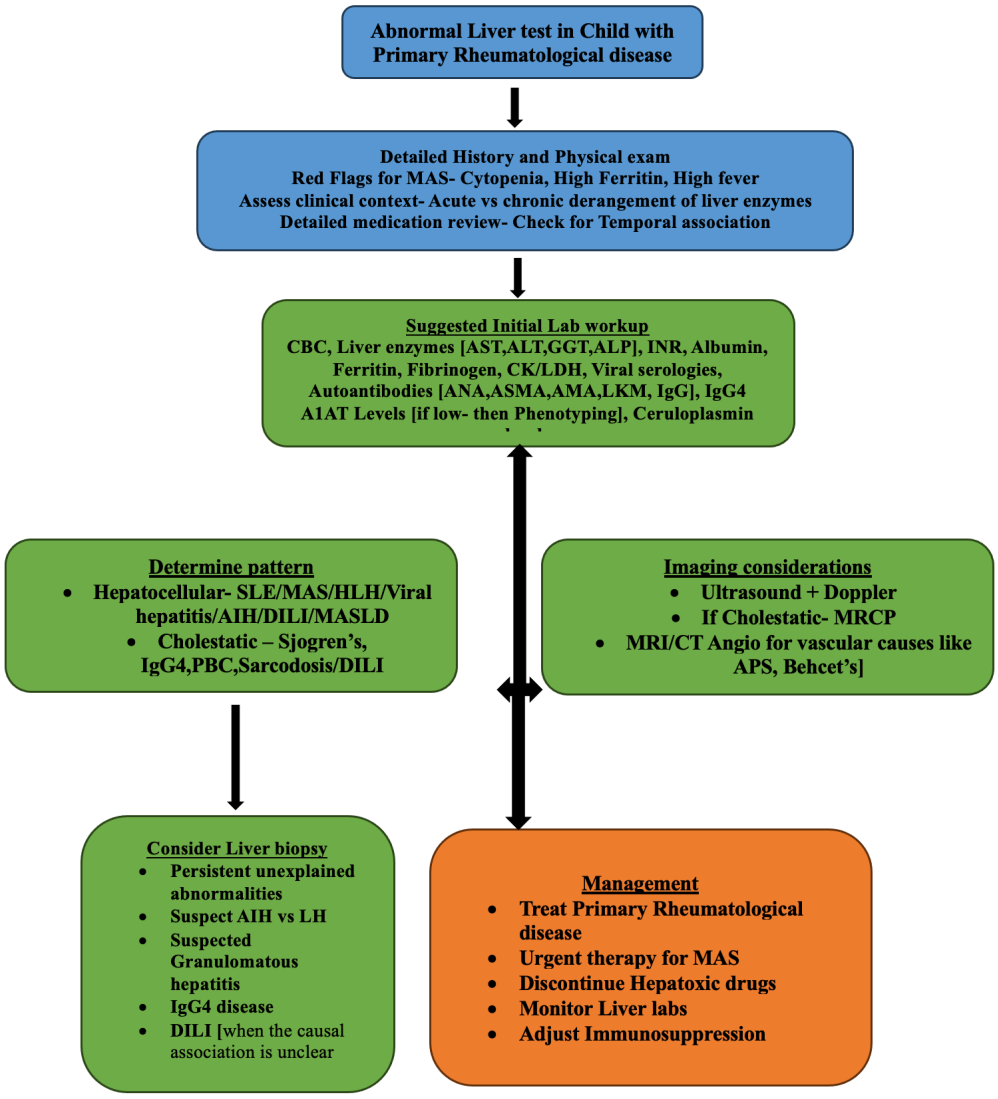

Figure 1. Diagnostic Approach to Liver Abnormalities in Pediatric Rheumatology. A1AT—alpha-1 antitrypsin; AIH—autoimmune hepatitis; ALP—alkaline phosphatase; ALT—alanine aminotransferase; AMA—anti-mitochondrial antibody; ANA—antinuclear antibody; APS—antiphospholipid syndrome; ASMA—anti-smooth muscle antibody; AST—aspartate aminotransferase; CBC—complete blood count; CK—creatine kinase; CT—computed tomography; DILI—drug-induced liver injury; GGT—gamma-glutamyl transferase; HLH—hemophagocytic lymphohistiocytosis; IgG—immunoglobulin G; IgG4—immunoglobulin G subclass 4; INR—international normalized ratio; LDH—lactate dehydrogenase; LH—lupus hepatitis; LKM—liver-kidney microsomal antibody; MAS—macrophage activation syndrome; MRCP—magnetic resonance cholangiopancreatography; MASLD-Metabolic Dysfunction-Associated Steatotic Liver Disease. MRI—magnetic resonance imaging; PBC—primary biliary cholangitis; SLE—systemic lupus erythematosus.

The timing of liver test abnormalities in relation to rheumatic disease activity or medication initiation is crucial. While a temporal link between drug exposure and enzyme elevation is a helpful clue, the most reliable diagnostic step is withdrawal of the suspected drug, followed by improvement in liver tests. When clinically appropriate and safe, cautious reintroduction with close monitoring may further confirm the diagnosis if abnormalities recur.

Hepatomegaly or splenomegaly may occur in sJIA, MAS, or sarcoidosis, while vascular findings such as livedo, thrombosis, or abdominal distension raise concern for APS or Behçet-related Budd–Chiari Syndrome/hepatic vein obstruction. Myositis may falsely elevate AST and ALT; thus, CK and LDH should be obtained when muscle involvement is suspected. In this scenario, measurement of GGT can sometimes help. An isolated elevation of AST and ALT with normal GGT but elevated CK favors a muscular origin, while concomitant elevation of GGT could support a hepatic source in appropriate clinical contexts [GGT can also be high in metabolic conditions like MASLD and can also be released from kidneys, intestines, heart, brain and pancreas]. Initial laboratory evaluation should determine whether the pattern is hepatocellular or cholestatic. A hepatocellular pattern suggests MAS, lupus hepatitis, viral infection, or drug-induced injury. A cholestatic pattern is more consistent with sarcoidosis, IgG4-related disease, or Sjögren's-associated biliary pathology. Viral studies [hepatitis A–E, EBV, CMV], autoantibodies, coagulation profile, ferritin, fibrinogen, and inflammatory markers are also warranted. It is also important to rule out other primary liver diseases when evaluating these children [e.g., Wilsons disease, A1AT deficiency, etc.].

MASLD represents the most common chronic liver disease in children and adolescents and is an increasingly important confounding factor when evaluating liver enzyme abnormalities in pediatric rheumatology [217]. This is particularly relevant in adolescents with obesity, those exposed to prolonged or repeated courses of corticosteroids, and patients receiving therapies such as methotrexate, all of which are independently associated with metabolic risk. In children with rheumatic disease, distinguishing MASLD-related liver injury from immune-mediated hepatitis or drug-induced liver injury can be challenging, as these entities may coexist and produce overlapping biochemical and histologic features. Mild to moderate elevations in aminotransferases are common in MASLD and may be erroneously attributed to medication toxicity or disease activity, particularly when baseline metabolic risk factors are not systematically assessed. In such cases, liver enzyme abnormalities may reflect a multifactorial process rather than a single dominant etiology. Non-invasive assessment tools, including ultrasound and elastography, can support the evaluation of hepatic steatosis and fibrosis; however, their ability to distinguish MASLD from inflammatory or drug-related liver injury is limited. In selected cases with persistent or progressive abnormalities, liver biopsy may be required to clarify the relative contributions of metabolic, inflammatory, and drug-related injury. Such decisions should be individualized and made in collaboration with pediatric hepatology.

As DILI is common, a detailed medication review is essential because methotrexate, leflunomide, azathioprine, TNF inhibitors, IL-6 blockade, and JAK inhibitors can all cause liver enzyme elevation. Identifying temporal relationships often distinguishes treatment toxicity from disease flare. Ultrasound with Doppler is the first-line imaging modality to assess hepatomegaly, biliary dilation, or vascular thrombosis. MRCP is useful when cholangitis or sclerosing features are suspected [218]. Liver biopsy is reserved for persistent unexplained abnormalities, suspected autoimmune hepatitis, granulomatous disease, IgG4-related disease, or uncertain DILI [219].

Management of hepatic abnormalities hinges on treating the underlying rheumatic condition while simultaneously addressing hepatic pathology. Control of systemic inflam-

mation in sJIA and SLE typically leads to normalization of liver enzymes, whereas MAS requires urgent, aggressive immunomodulation. Vascular complications in APS or Behçet's disease require prompt anticoagulation. Cholestatic diseases associated with Sjögren's or IgG4-related disease respond to ursodeoxycholic acid [220] and corticosteroid-based regimens [221], respectively. Drug-induced liver injury necessitates withdrawal of the offending agent, with gradual reintroduction of alternative immunomodulatory therapies when necessary. Collaboration with pediatric hepatology is often invaluable, especially in children with severe or unclear hepatic involvement.

6. Limitations

This review has limitations. Pediatric-specific data are limited for many rheumatic conditions, and much of the available evidence is derived from adult cohorts or small pediatric case series. Diagnostic criteria and monitoring strategies are heterogeneous across studies, limiting direct comparison. Additionally, the evolving therapeutic landscape means that long-term hepatic safety data for newer biologic and targeted agents remain incomplete.

7. Conclusions

In summary, hepatic complications in pediatric rheumatology demand vigilant monitoring and a nuanced differential diagnosis to optimize outcomes, balancing therapeutic efficacy with the minimization of iatrogenic and infectious risks in this evolving field. A structured approach that integrates clinical context, biochemical pattern recognition, imaging, and selective use of liver biopsy enables clinicians to differentiate benign or transient abnormalities from severe disease requiring urgent intervention. Early identification of MAS, hepatic vein thrombosis, and worsening disease is especially critical for improving outcomes. In most children, prompt management of the underlying rheumatic condition results in resolution of hepatic injury, and long-term prognosis is favorable. Continued interdisciplinary collaboration and research are needed to refine diagnostic strategies, clarify disease mechanisms, and optimize care for children in whom rheumatic diseases and liver pathology intersect.

Author Contributions: Conceptualization, M.J. and M.K.; literature review and data curation, M.J., M.K. and T.K.; writing—review and editing, M.J., T.K. and M.K.; supervision, M.K. All authors have read and agreed to the published version of the manuscript.

Funding: This research received no external funding.

Institutional Review Board Statement: Not applicable.

Informed Consent Statement: Not applicable.

Data Availability Statement: No new data were created or analyzed in this study.

Conflicts of Interest: The authors declare no conflicts of interest.

Abbreviations

A1AT, Alpha-1 antitrypsin; AID, Autoinflammatory disease; AIH, Autoimmune hepatitis; ALP, Alkaline phosphatase; ALT, Alanine aminotransferase; AMA, Antimitochondrial antibody; ANA, Antinuclear antibody; APS, Antiphospholipid syndrome; ASMA, Anti-smooth muscle antibody; AST, Aspartate aminotransferase; CBC, Complete blood count; CK, Creatine kinase; DILI, Drug-induced liver injury; GGT, Gamma-glutamyl transferase; HLH, Hemophagocytic lymphohistiocytosis; IgG, Immunoglobulin G; IgG4, Immunoglobulin G subclass 4; INR, International normalized ratio; JIA, Juvenile idiopathic arthritis; LFTs, Liver function tests; LKM, Liver–kidney microsomal antibody; MAS, Macrophage activation syndrome; MCTD, Mixed connective tissue disease MRCP, Magnetic

resonance cholangiopancreatography; MASLD, Metabolic dysfunction-associated steatotic liver disease; PBC, Primary biliary cholangitis; SLE, Systemic lupus erythematosus.

References

1. Ohira, H.; Abe, K.; Takahashi, A. Involvement of the liver in rheumatic diseases. *Clin. J. Gastroenterol.* **2012**, *5*, 9–14. [CrossRef]
2. Podgórska, J.; Werel, P.; Klapaczyński, J.; Orzechowska, D.; Wudarski, M.; Gietka, A. Liver involvement in rheumatic diseases. *Reumatologia* **2020**, *58*, 289–296. [CrossRef]
3. Schlenker, C.; Halterman, T.; Kowdley, K.V. Rheumatologic disease and the liver. *Clin. Liver Dis.* **2011**, *15*, 153–164. [CrossRef]
4. Selmi, C.; De Santis, M.; Gershwin, M.E. Liver involvement in subjects with rheumatic disease. *Arthritis Res. Ther.* **2011**, *13*, 226. [CrossRef] [PubMed]
5. Minoia, F.; Davì, S.; Horne, A.; Demirkaya, E.; Bovis, F.; Li, C.; Lehmberg, K.; Weitzman, S.; Insalaco, A.; Wouters, C.; et al. Clinical features, treatment, and outcome of macrophage activation syndrome complicating systemic juvenile idiopathic arthritis: A multinational, multicenter study of 362 patients. *Arthritis Rheumatol.* **2014**, *66*, 3160–3169. [CrossRef]
6. Woo, P. Systemic juvenile idiopathic arthritis: Diagnosis, management, and outcome. *Nat. Clin. Pract. Rheumatol.* **2006**, *2*, 28–34. [CrossRef]
7. Billiau, A.D.; Roskams, T.; Van Damme-Lombaerts, R.; Matthys, P.; Wouters, C. Macrophage activation syndrome: Characteristic findings on liver biopsy illustrating the key role of activated, IFN-gamma-producing lymphocytes and IL-6- and TNF-alpha-producing macrophages. *Blood* **2005**, *105*, 1648–1651. [CrossRef]
8. Schaller, J.; Beckwith, B.; Wedgwood, R.J. Hepatic involvement in juvenile rheumatoid arthritis. *J. Pediatr.* **1970**, *77*, 203–210. [CrossRef]
9. Bihl, F.; Emmenegger, U.; Reichen, J.; Neftel, K.A.; Zimmermann, A.; Cerny, A. Macrophage activating syndrome is associated with lobular hepatitis and severe bile duct injury with cholestasis. *J. Hepatol.* **2006**, *44*, 1208–1212. [CrossRef] [PubMed]
10. Favara, B.E. Histopathology of the liver in histiocytosis syndromes. *Pediatr. Pathol. Lab. Med.* **1996**, *16*, 413–433. [CrossRef] [PubMed]
11. Tahernia, L.; Alimadadi, H.; Tahghighi, F.; Amini, Z.; Ziaee, V. Frequency and Type of Hepatic and Gastrointestinal Involvement in Juvenile Systemic Lupus Erythematosus. *Autoimmune Dis.* **2017**, *2017*, 8097273. [CrossRef]
12. Adiga, A.; Nugent, K. Lupus Hepatitis and Autoimmune Hepatitis (Lupoid Hepatitis). *Am. J. Med. Sci.* **2017**, *353*, 329–335. [CrossRef]
13. Afzal, W.; Haghi, M.; Hasni, S.; Newman, K. Lupus hepatitis, more than just elevated liver enzymes. *Scand. J. Rheumatol.* **2020**, *49*, 427–433. [CrossRef]
14. González-Regueiro, J.A.; Cruz-Contreras, M.; Merayo-Chalico, J.; Barrera-Vargas, A.; Ruiz-Margáin, A.; Campos-Murguía, A.; Espin-Nasser, M.; Martínez-Benítez, B.; Méndez-Cano, V.H.; Macías-Rodríguez, R.U. Hepatic manifestations in systemic lupus erythematosus. *Lupus* **2020**, *29*, 813–824. [CrossRef]
15. Yin, X.; He, Z.; Mo, H.; Luo, X.; Xiao, Y. Lupus hepatitis as the primary cause: A retrospective analysis of liver biopsy in systemic lupus erythematosus with unexplained liver function abnormalities from two centers in Southern China. *Clin. Rheumatol.* **2025**, *44*, 3899–3908. [CrossRef]
16. Zheng, R.-H.; Wang, J.-H.; Wang, S.-B.; Chen, J.; Guan, W.-M.; Chen, M.-H. Clinical and immunopathological features of patients with lupus hepatitis. *Chin. Med. J.* **2013**, *126*, 260–266. [CrossRef]
17. Uthman, I.; Khamashta, M. The abdominal manifestations of the antiphospholipid syndrome. *Rheumatology* **2007**, *46*, 1641–1647. [CrossRef]
18. Knight, J.S.; Branch, D.W.; Ortel, T.L. Antiphospholipid syndrome: Advances in diagnosis, pathogenesis, and management. *BMJ* **2023**, *380*, e069717. [CrossRef]
19. Kaplan, M.J.; Ike, R.W. The liver is a common non-exocrine target in primary Sjogren's syndrome: A retrospective review. *BMC Gastroenterol.* **2002**, *2*, 21. [CrossRef]
20. Hatzis, G.S.; Fragoulis, G.E.; Karatzaferis, A.; Delladetsima, I.; Barbatis, C.; Moutsopoulos, H.M. Prevalence and longterm course of primary biliary cirrhosis in primary Sjogren's syndrome. *J. Rheumatol.* **2008**, *35*, 2012–2016.
21. Sedki, M.; Fonseca, N.; Santiago, P.; Diaz, L.; Garcia-Buitrago, M.; Mirsaeidi, M.; Levy, C. Hepatic Sarcoidosis: Natural History and Management Implications. *Front. Med.* **2019**, *6*, 232. [CrossRef]
22. Kumar, M.; Herrera, J.L. Sarcoidosis and the Liver. *Clin. Liver Dis.* **2019**, *23*, 331–343. [CrossRef] [PubMed]
23. Nawfal, G.; Budin, C.; Bouvier, R.; Lachaux, A. Elevated aminotransaminases as the first manifestation of sarcoidosis. *Case Rep. Med.* **2009**, *2009*, 193785. [CrossRef]
24. Devaney, K.; Goodman, Z.D.; Epstein, M.S.; Zimmerman, H.J.; Ishak, K.G. Hepatic sarcoidosis. Clinicopathologic features in 100 patients. *Am. J. Surg. Pathol.* **1993**, *17*, 1272–1280. [CrossRef]

25. Jindal, A.K.; Pilania, R.K.; Suri, D.; Gupta, A.; Gattorno, M.; Ceccherini, I.; Kumar, N.; Bansal, R.; Nada, R.; Singh, S. A young female with early onset arthritis, uveitis, hepatic, and renal granulomas: A clinical tryst with Blau syndrome over 20 years and case-based review. *Rheumatol. Int.* **2021**, *41*, 173–181. [CrossRef]
26. Karagiannidis, A.; Karavalaki, M.; Koulaouzidis, A. Hepatic sarcoidosis. *Ann. Hepatol.* **2006**, *5*, 251–256. [CrossRef]
27. Feldman, B.M.; Rider, L.G.; Reed, A.M.; Pachman, L.M. Juvenile dermatomyositis and other idiopathic inflammatory myopathies of childhood. *Lancet* **2008**, *371*, 2201–2212. [CrossRef]
28. Nagashima, T.; Kamata, Y.; Iwamoto, M.; Okazaki, H.; Fukushima, N.; Minota, S. Liver dysfunction in anti-melanoma differentiation-associated gene 5 antibody-positive patients with dermatomyositis. *Rheumatol. Int.* **2019**, *39*, 901–909. [CrossRef]
29. Yang, X.; Cui, X.; Yang, X.; Ren, B.; Cheng, X.; Zhao, X.; Liu, S.; Tian, T.; Zhao, H.; Qu, L.; et al. Liver Involvement is Associated with Higher Risk of Rapidly Progressive Interstitial Lung Disease and Mortality in Anti-Melanoma Differentiation-Associated Gene 5 Antibody- Positive Dermatomyositis. *J. Inflamm. Res.* **2024**, *17*, 3101–3113. [CrossRef] [PubMed]
30. Kinkor, M.; Hameed, S.; Kats, A.; Slowik, V.; Fox, E.; Ibarra, M. 14-month-old female with anti-MDA5 juvenile dermatomyositis complicated by liver disease: A case report. *Pediatr. Rheumatol. Online J.* **2024**, *22*, 86. [CrossRef]
31. Yi, B.Y.; Marrs, J.; Schenker, R.; Suddock, J.; Cotter, J.A.; Cidon, M. Elevated liver enzymes: Unusual presentation of anti-MDA5 antibody-associated juvenile dermatomyositis. *Clin. Exp. Rheumatol.* **2024**, *42*, 456–457. [CrossRef]
32. Oğuzkurt, P.; Akçören, Z.; Kale, G.; Tanyel, F. Polyarteritis nodosa involving the hepatobiliary system in an eight-year-old girl with a previous diagnosis of familial Mediterranean fever. *Eur. J. Pediatr. Surg.* **2000**, *10*, 145–147. [CrossRef]
33. Willeke, P.; Schlüter, B.; Limani, A.; Becker, H.; Schotte, H. Liver involvement in ANCA-associated vasculitis. *Clin. Rheumatol.* **2016**, *35*, 387–394. [CrossRef]
34. Pavone, L.; Grasselli, C.; Chierici, E.; Maggiore, U.; Garini, G.; Ronda, N.; Manganelli, P.; Pesci, A.; Rioda, W.T.; Tumiati, B.; et al. Outcome and prognostic factors during the course of primary small-vessel vasculitides. *J. Rheumatol.* **2006**, *33*, 1299–1306.
35. Cansu, D.U.; Temel, T.; Erturk, A.; Kasifoglu, T.; Acu, B.; Korkmaz, C. The Long-Term Outcomes for Patients with Budd-Chiari Syndrome Caused by Behcet's Disease: A Case Series on the Results, from Cirrhosis to Death. *Hepat. Mon.* **2016**, *16*, e32457. [CrossRef] [PubMed]
36. Allaoui, A.; Echchilali, K.; Fares, M.; Belabbes, F.Z.; Jabbouri, R.; Naitlho, A.; Moudatir, M.; Alaoui, F.Z.; Elkabli, H. Budd-Chiari syndrome associated to Behcet disease: An observational retrospective multicenter study in Morocco. *Medicine* **2022**, *101*, e31308. [CrossRef]
37. Suhaini, S.A.; Azidin, A.H.; Cheah, C.S.; Lee Wei Li, W.; Khoo, M.S.; Ismail, N.A.S.; Ali, A. Kawasaki Disease with Hepatobiliary Manifestations. *Medicina* **2022**, *58*, 1833. [CrossRef] [PubMed]
38. Ebert, E.C.; Hagspiel, K.D.; Nagar, M.; Schlesinger, N. Gastrointestinal involvement in polyarteritis nodosa. *Clin. Gastroenterol. Hepatol.* **2008**, *6*, 960–966. [CrossRef] [PubMed]
39. Davatchi, F. Diagnosis/Classification Criteria for Behcet's Disease. *Pathol. Res. Int.* **2012**, *2012*, 607921. [CrossRef]
40. Culver, E.L.; Chapman, R.W. IgG4-related hepatobiliary disease: An overview. *Nat. Rev. Gastroenterol. Hepatol.* **2016**, *13*, 601–612. [CrossRef] [PubMed]
41. Löhr, J.-M.; Vujasinovic, M.; Rosendahl, J.; Stone, J.H.; Beuers, U. IgG4-related diseases of the digestive tract. *Nat. Rev. Gastroenterol. Hepatol.* **2022**, *19*, 185–197. [CrossRef] [PubMed]
42. Chen, J.H.; Deshpande, V. IgG4-related Disease and the Liver. *Gastroenterol. Clin. N. Am.* **2017**, *46*, 195–216. [CrossRef]
43. Petty, R.E.; Southwood, T.R.; Manners, P.; Baum, J.; Glass, D.N.; Goldenberg, J.; He, X.; Maldonado-Cocco, J.; Orozco-Alcala, J.; Prieur, A.M.; et al. International League of Associations for Rheumatology classification of juvenile idiopathic arthritis: Second revision, Edmonton, 2001. *J. Rheumatol.* **2004**, *31*, 390–392. [PubMed]
44. Tsai, H.-Y.; Lee, J.-H.; Yu, H.-H.; Wang, L.-C.; Yang, Y.-H.; Chiang, B.-L. Initial manifestations and clinical course of systemic onset juvenile idiopathic arthritis: A ten-year retrospective study. *J. Formos. Med. Assoc.* **2012**, *111*, 542–549. [CrossRef]
45. Aeschlimann, F.A.; Dumaine, C.; Wörner, A.; Mouy, R.; Wouters, C.; Melki, I.; Uettwiller, F.; Job-Deslandre, C.; Quartier, P.; Bader-Meunier, B. Serious adverse events in children with juvenile idiopathic arthritis and other rheumatic diseases on tocilizumab—A real-world experience. *Semin. Arthritis Rheum.* **2020**, *50*, 744–748. [CrossRef]
46. Zhu, G.; Liu, G.; Liu, Y.; Xie, Q.; Shi, G. Liver abnormalities in adult onset Still's disease: A retrospective study of 77 Chinese patients. *J. Clin. Rheumatol.* **2009**, *15*, 284–288. [CrossRef]
47. Crayne, C.B.; Albeituni, S.; Nichols, K.E.; Cron, R.Q. The Immunology of Macrophage Activation Syndrome. *Front. Immunol.* **2019**, *10*, 119. [CrossRef]
48. Boom, V.; Anton, J.; Lahdenne, P.; Quartier, P.; Ravelli, A.; Wulffraat, N.M.; Vastert, S.J. Evidence-based diagnosis and treatment of macrophage activation syndrome in systemic juvenile idiopathic arthritis. *Pediatr. Rheumatol. Online J.* **2015**, *13*, 55. [CrossRef]
49. Ogasawara, Y.; Kogiso, T.; Kotera, Y.; Omori, A.; Konda, N.; Sugano, E.; Sagawa, T.; Taniai, M.; Harigai, M.; Egawa, H.; et al. The utility of liver transplantation to treat acute liver failure caused by adult-onset Still's disease: Case reports. *Clin. J. Gastroenterol.* **2021**, *14*, 866–875. [CrossRef] [PubMed]

50. Orr, J.; Bury, Y.; Hudson, M.; Masson, S. Liver transplantation for acute liver failure caused by macrophage activation syndrome. *Transpl. Int.* **2013**, *26*, e105–e108. [CrossRef]
51. Aringer, M.; Costenbader, K.; Daikh, D.; Brinks, R.; Mosca, M.; Ramsey-Goldman, R.; Smolen, J.S.; Wofsy, D.; Boumpas, D.T.; Kamen, D.L.; et al. 2019 European League Against Rheumatism/American College of Rheumatology Classification Criteria for Systemic Lupus Erythematosus. *Arthritis Rheumatol.* **2019**, *71*, 1400–1412. [CrossRef]
52. Liu, Y.; Yu, J.; Oaks, Z.; Marchena-Mendez, I.; Francis, L.; Bonilla, E.; Aleksiejuk, P.; Patel, J.; Banki, K.; Landas, S.K.; et al. Liver injury correlates with biomarkers of autoimmunity and disease activity and represents an organ system involvement in patients with systemic lupus erythematosus. *Clin. Immunol.* **2015**, *160*, 319–327. [CrossRef]
53. Barbhaiya, M.; Zuily, S.; Naden, R.; Hendry, A.; Manneville, F.; Amigo, M.C.; Amoura, Z.; Andrade, D.; Andreoli, L.; Artim-Esen, B.; et al. 2023 ACR/EULAR antiphospholipid syndrome classification criteria. *Ann. Rheum. Dis.* **2023**, *82*, 1258–1270. [CrossRef]
54. Espinosa, G.; Font, J.; García-Pagan, J.C.; Tàssies, D.; Reverter, J.C.; Gaig, C.; Cervantes, F.; Cervera, R.; Bosch, J.; Ingelmo, M. Budd-Chiari syndrome secondary to antiphospholipid syndrome: Clinical and immunologic characteristics of 43 patients. *Medicine* **2001**, *80*, 345–354. [CrossRef]
55. Pandiaraja, J.; Sathyaseelan, A. Budd- Chiari Syndrome as an Initial Manifestation of Systemic Lupus Erythematosus. *J. Clin. Diagn. Res.* **2016**, *10*, OD01–OD02. [CrossRef] [PubMed]
56. Ravelli, A.; Martini, A. Antiphospholipid antibody syndrome in pediatric patients. *Rheum. Dis. Clin. N. Am.* **1997**, *23*, 657–676. [CrossRef]
57. Ma, J.; Song, H.; Wei, M.; He, Y. Clinical characteristics and thrombosis outcomes of paediatric antiphospholipid syndrome: Analysis of 58 patients. *Clin. Rheumatol.* **2018**, *37*, 1295–1303. [CrossRef]
58. Pati, H.P.; Srivastava, A.; Sahni, P. Extra hepatic portal vein thrombosis in a child associated with lupus anticoagulant. *J. Trop. Pediatr.* **2003**, *49*, 191–192. [CrossRef] [PubMed]
59. Kim, J.H.; Ha, H.K.; Yoon, K.H.; Lee, Y.S.; Park, K.B.; Lee, I.J.; Kim, P.N.; Lee, M.G.; Auh, Y.H. CT features of abdominal manifestations of primary antiphospholipid syndrome. *J. Comput. Assist. Tomogr.* **1999**, *23*, 678–683. [CrossRef] [PubMed]
60. Alsulyman, O.M.; Castro, M.A.; Zuckerman, E.; McGehee, W.; Goodwin, T.M. Preeclampsia and liver infarction in early pregnancy associated with the antiphospholipid syndrome. *Obstet. Gynecol.* **1996**, *88*, 644–646. [CrossRef]
61. Morio, S.; Oh, H.; Hirasawa, A.; Aotsuka, N.; Nakamura, H.; Asai, T.; Yoshida, S.; Ito, M. Hepatic veno-occlusive disease in a patient with lupus anticoagulant after allogeneic bone marrow transplantation. *Bone Marrow Transplant.* **1991**, *8*, 147–149.
62. Nakamura, H.; Uehara, H.; Okada, T.; Kambe, H.; Kimura, Y.; Ito, H.; Hayashi, E.; Yamamoto, H.; Kishimoto, S. Occlusion of small hepatic veins associated with systemic lupus erythematosus with the lupus anticoagulant and anti-cardiolipin antibody. *Hepatogastroenterology* **1989**, *36*, 393–397.
63. Franceschini, F.; Cavazzana, I.; Andreoli, L.; Tincani, A. The 2016 classification criteria for primary Sjogren's syndrome: What's new? *BMC Med.* **2017**, *15*, 69. [CrossRef]
64. Marino, A.; Romano, M.; Giani, T.; Gaggiano, C.; Costi, S.; Singh, R.; Mehta, J.J.; Lieberman, S.M.; Cimaz, R. Childhood Sjogren's syndrome: An Italian case series and a literature review-based cohort. *Semin. Arthritis Rheum.* **2021**, *51*, 903–910. [CrossRef]
65. Montaño-Loza, A.J.; Crispín-Acuña, J.C.; Remes-Troche, J.M.; Uribe, M. Abnormal hepatic biochemistries and clinical liver disease in patients with primary Sjogren's syndrome. *Ann. Hepatol.* **2007**, *6*, 150–155. [CrossRef]
66. Skopouli, F.N.; Barbatis, C.; Moutsopoulos, H.M. Liver involvement in primary Sjogren's syndrome. *Br. J. Rheumatol.* **1994**, *33*, 745–748. [CrossRef]
67. Karp, J.K.; Akpek, E.K.; Anders, R.A. Autoimmune hepatitis in patients with primary Sjogren's syndrome: A series of two-hundred and two patients. *Int. J. Clin. Exp. Pathol.* **2010**, *3*, 582–586.
68. Chiu, B.; Chan, J.; Das, S.; Alshamma, Z.; Sergi, C. Pediatric Sarcoidosis: A Review with Emphasis on Early Onset and High-Risk Sarcoidosis and Diagnostic Challenges. *Diagnostics* **2019**, *9*, 160. [CrossRef]
69. Nott, K.; Nott, V.; Lever, E.; Deakin, C.; Galloway, J.; Fisher, C. Compeyrot-Lacassagne S Pediatric Sarcoidosis: Retrospective Analysis of Biopsy-Proven Patients. *J. Rheumatol.* **2023**, *50*, 924–933. [CrossRef]
70. Fauroux, B.; Clement, A. Paediatric sarcoidosis. *Paediatr. Respir. Rev.* **2005**, *6*, 128–133. [CrossRef]
71. Sinharay, R.; McKeown, L.; Phillips, C.; Li, A.; Duckworth, A.; Hall, F.; Griffiths, W.J.H. First report of liver transplantation in Blau syndrome: The challenges faced in this rare granulomatous liver disease. *Transpl. Immunol.* **2021**, *65*, 101378. [CrossRef]
72. Wouters, C.H.; Maes, A.; Foley, K.P.; Bertin, J.; Rose, C.D. Blau syndrome, the prototypic auto-inflammatory granulomatous disease. *Pediatr. Rheumatol. Online J.* **2014**, *12*, 33. [CrossRef]
73. Rosé, C.D.; Aróstegui, J.I.; Martin, T.M.; Espada, G.; Scalzi, L.; Yagüe, J.; Rosenbaum, J.T.; Modesto, C.; Cristina Arnal, M.; Merino, R.; et al. NOD2-associated pediatric granulomatous arthritis, an expanding phenotype: Study of an international registry and a national cohort in Spain. *Arthritis Rheum.* **2009**, *60*, 1797–1803. [CrossRef]
74. Yao, F.; Tan, B.; Wu, D.; Shen, M. Blau syndrome with hypertension and hepatic granulomas: A case report and literature review. *Front. Pediatr.* **2023**, *11*, 1063222. [CrossRef]

75. PaÇ Kisaarslan, A.; SÖzerİ, B.; Şahİn, N.; Özdemİr ÇİÇek, S.; GÜndÜz, Z.; DemİrkayA, E.; Berdelİ, A.; Sadet Özcan, S.; PorazoĞlu, H.; DÜŞÜnsel, R. Blau Syndrome and Early-Onset Sarcoidosis: A Six Case Series and Review of the Literature. *Arch. Rheumatol.* **2020**, *35*, 117–127. [CrossRef]
76. Jennette, J.C. Overview of the 2012 revised International Chapel Hill Consensus Conference nomenclature of vasculitides. *Clin. Exp. Nephrol.* **2013**, *17*, 603–606. [CrossRef]
77. Anderson, E.; Gakhar, N.; Stull, C.; Caplan, L. Gastrointestinal and Hepatic Disease in Vasculitis. *Rheum. Dis. Clin. N. Am.* **2018**, *44*, 1–14. [CrossRef]
78. Gumà, M.; Lorenzo-Zúñiga, V.; Olivé, A.; Perendreu, J.; Bechini, J.; Doménech, E.; Planas, R. Occult liver involvement by polyarteritis nodosa. *Clin. Rheumatol.* **2002**, *21*, 184–186. [CrossRef]
79. Becker, N. Polyarteritis nodosa: Two cases and a review. *S. Afr. Med. J.* **1959**, *33*, 690–691.
80. Mowrey, F.H.; Lundberg, E.A. The clinical manifestations of essential polyanglitis (periarteritis nodosa), with emphasis on the hepatic manifestations. *Ann. Intern. Med.* **1954**, *40*, 1145–1164. [CrossRef]
81. Travers, R.L.; Allison, D.J.; Brettle, R.P.; Hughes, G.R. Polyarteritis nodosa: A clinical and angiographic analysis of 17 cases. *Semin. Arthritis Rheum.* **1979**, *8*, 184–199. [CrossRef]
82. Jee, K.N.; Ha, H.K.; Lee, I.J.; Kim, J.K.; Sung, K.B.; Cho, K.S.; Kim, P.N.; Lee, M.G.; Lim, H.K.; Choi, C.S.; et al. Radiologic findings of abdominal polyarteritis nodosa. *AJR Am. J. Roentgenol.* **2000**, *174*, 1675–1679. [CrossRef]
83. Iuliano, L.; Gurgo, A.; Gualdi, G.; Bonavita, M.S. Succeeding onset of hepatic, splenic, and renal infarction in polyarteritis nodosa. *Am. J. Gastroenterol.* **2000**, *95*, 1837–1838. [CrossRef]
84. Kawakami, T. A review of pediatric vasculitis with a focus on juvenile polyarteritis nodosa. *Am. J. Clin. Dermatol.* **2012**, *13*, 389–398. [CrossRef]
85. Gómez-Luque, I.; Alconchel, F.; Ciria, R.; Ayllón, M.D.; Luque, A.; Sánchez, M.; López-Cillero, P.; Briceño, J. Spontaneous liver rupture as first sign of polyarteritis nodosa. *World J. Hepatol.* **2016**, *8*, 1414–1418. [CrossRef]
86. Battula, N.; Tsapralis, D.; Morgan, M.; Mirza, D. Spontaneous liver haemorrhage and haemobilia as initial presentation of undiagnosed polyarteritis nodosa. *Ann. R. Coll. Surg. Engl.* **2012**, *94*, e163–e165. [CrossRef]
87. Nakazawa, K.; Itoh, N.; Duan, H.; Komiyama, Y.; Shigematsu, H. Polyarteritis nodosa with atrophy of the left hepatic lobe. *Acta Pathol. Jpn.* **1992**, *42*, 662–666. [CrossRef]
88. Sönmez, H.E.; Armağan, B.; Ayan, G.; Barut, K.; Batu, E.D.; Erden, A.; Uğurlu, S.; Bilginer, Y.; Kasapçopur, Ö.; Karadağ, Ö.; et al. Polyarteritis nodosa: Lessons from 25 years of experience. *Clin. Exp. Rheumatol.* **2019**, *37*, 52–56.
89. Park, H.-J.; Choi, Y.-J.; Kim, J.-E.; Ye, Y.-M.; Park, H.-S.; Suh, C.-H. Successful treatment of pediatric systemic polyarteritis nodosa with cholestatic hepatitis. *Clin. Rheumatol.* **2007**, *26*, 122–124. [CrossRef]
90. Hu, Y.-C.; Chiang, B.-L.; Yang, Y.-H. Clinical Manifestations and Management of Pediatric Behcet's Disease. *Clin. Rev. Allergy Immunol.* **2021**, *61*, 171–180. [CrossRef]
91. ElAdawy, M.; Dominguez, S.R.; Anderson, M.S.; Glodé, M.P. Abnormal liver panel in acute kawasaki disease. *Pediatr. Infect. Dis. J.* **2011**, *30*, 141–144. [CrossRef]
92. Rosti, G.; Milani, G.P.; Laicini, E.A.; Fossali, E.F.; Bianchetti, M.G. Liver chemistry in new-onset Henoch-Schonlein syndrome. *Ital. J. Pediatr.* **2017**, *43*, 85. [CrossRef]
93. Özkaya, A.K.; Güler, E.; Çetinkaya, A.; Karakaya, A.E.; Göksügür, Y.; Katı, Ö.; Güler, A.G.; Davutoğlu, M. Henoch-Schonlein purpura complicated by acalculous cholecystitis and intussusception, and following recurrence with appendicitis. *Paediatr. Int. Child Health* **2016**, *36*, 157–159. [CrossRef]
94. Karim, F.; Loeffen, J.; Bramer, W.; Westenberg, L.; Verdijk, R.; van Hagen, M.; van Laar, J. IgG4-related disease: A systematic review of this unrecognized disease in pediatrics. *Pediatr. Rheumatol. Online J.* **2016**, *14*, 18. [CrossRef]
95. Kaya Akca, U.; Kose, H.; Kurt, T.; Ulu, K.; Guliyeva, V.; Kılbas, G.; Arslanoglu, C.; Yildirim, D.G.; Demir, S.; Sahin, S.; et al. A rare disease with many faces: A multicentre registry of IgG4-related disease in children. *Rheumatology* **2025**, *64*, 2185–2192. [CrossRef]
96. Peng, L.; Zhang, X.; Zhou, J.; Li, J.; Liu, Z.; Lu, H.; Peng, Y.; Fei, Y.; Zhao, Y.; Zeng, X.; et al. Comparison of clinical features and outcomes of proliferative, fibrotic, and mixed subtypes of IgG4-related disease: A retrospective cohort study. *Chin. Med. J.* **2024**, *137*, 303–311. [CrossRef]
97. Wallace, Z.S.; Zhang, Y.; Perugino, C.A.; Naden, R.; Choi, H.K.; Stone, J.H. Clinical phenotypes of IgG4-related disease: An analysis of two international cross-sectional cohorts. *Ann. Rheum. Dis.* **2019**, *78*, 406–412. [CrossRef]
98. Capurso, G.; Pedica, F.; Palumbo, D.; Della-Torre, E. IgG4-related autoimmune liver disease. *Minerva Gastroenterol.* **2023**, *69*, 23–49. [CrossRef]
99. Colaci, M.; Aprile, M.L.; Sambataro, D.; Sambataro, G.; Malatino, L. Systemic Sclerosis and Idiopathic Portal Hypertension: Report of a Case and Review of the Literature. *Life* **2022**, *12*, 1781. [CrossRef]
100. Green, E.W.; Kahl, L.; Jou, J.H. Systemic Sclerosis and the Liver. *Clin. Liver Dis.* **2021**, *18*, 76–80. [CrossRef]

101. Cuomo, G.; Iandoli, C.; Galiero, R.; Caturano, A.; Di Vico, C.; Perretta, D.; Adamo, P.V.; Ferrara, R.; Rinaldi, L.; Romano, C.; et al. Liver Involvement in Patients with Systemic Sclerosis: Role of Transient Elastography in the Assessment of Hepatic Fibrosis and Steatosis. *Diagnostics* **2023**, *13*, 1766. [CrossRef]
102. Pachman, L.M.; Khojah, A.M. Advances in Juvenile Dermatomyositis: Myositis Specific Antibodies Aid in Understanding Disease Heterogeneity. *J. Pediatr.* **2018**, *195*, 16–27. [CrossRef]
103. Pepmueller, P.H. Undifferentiated Connective Tissue Disease, Mixed Connective Tissue Disease, and Overlap Syndromes in Rheumatology. *Mo. Med.* **2016**, *113*, 136–140.
104. Berard, R.A.; Laxer, R.M. Pediatric Mixed Connective Tissue Disease. *Curr. Rheumatol. Rep.* **2016**, *18*, 28. [CrossRef]
105. Terminiello, A.; Marrani, E.; Pagnini, I.; Maccora, I.; Maniscalco, V.; Rumeileh, S.A.; Mastrolia, M.V.; Simonini, G. Childhood mixed connective tissue disease at disease onset: Evidence from a systematic review. *Autoimmun. Rev.* **2024**, *23*, 103513. [CrossRef]
106. Wang, C.-R.; Tsai, H.-W. Autoimmune liver diseases in systemic rheumatic diseases. *World J. Gastroenterol.* **2022**, *28*, 2527–2545. [CrossRef]
107. Stevens, J.L.; Baker, T.K. The future of drug safety testing: Expanding the view and narrowing the focus. *Drug Discov. Today* **2009**, *14*, 162–167. [CrossRef]
108. Danan, G.; Benichou, C. Causality assessment of adverse reactions to drugs—I. A novel method based on the conclusions of international consensus meetings: Application to drug-induced liver injuries. *J. Clin. Epidemiol.* **1993**, *46*, 1323–1330. [CrossRef]
109. Kozielewicz, D.M.; Stalke, P.; Skrzypek, J. Drug-induced liver injury. Part I: Classification, diagnosis and treatment. *Clin. Exp. Hepatol.* **2025**, *11*, 25–33. [CrossRef]
110. Danan, G.; Teschke, R. Roussel Uclaf Causality Assessment Method for Drug-Induced Liver Injury: Present and Future. *Front. Pharmacol.* **2019**, *10*, 853. [CrossRef]
111. European Association for the Study of the Liver. EASL Clinical Practice Guidelines: Drug-induced liver injury. *J. Hepatol.* **2019**, *70*, 1222–1261. [CrossRef]
112. Aithal, G.P. Hepatotoxicity related to antirheumatic drugs. *Nat. Rev. Rheumatol.* **2011**, *7*, 139–150. [CrossRef]
113. Aithal, G.P.; Day, C.P. Nonsteroidal anti-inflammatory drug-induced hepatotoxicity. *Clin. Liver Dis.* **2007**, *11*, 563–575. [CrossRef]
114. Lindsley, C.B. Uses of nonsteroidal anti-inflammatory drugs in pediatrics. *Am. J. Dis. Child.* **1993**, *147*, 229–236. [CrossRef]
115. Gebreselassie, A.; Aduli, F.; Howell, C.D. Rheumatologic Diseases and the Liver. *Clin. Liver Dis.* **2019**, *23*, 247–261. [CrossRef]
116. Ohana, O.; Marmor, I.; Ferguson, R.; Levinsky, Y.; Rubin, S.; Baszis, K.; Tal, R.; Harel, L.; Peled, O.; Amarilyo, G. Efficacy and safety of ibuprofen and naproxen in the treatment of oligoarticular juvenile idiopathic arthritis: Bi-national cohort study. *Immunopharmacol. Immunotoxicol.* **2025**, *47*, 141–146. [CrossRef]
117. Björnsson, E.S. Hepatotoxicity by Drugs: The Most Common Implicated Agents. *Int. J. Mol. Sci.* **2016**, *17*, 224. [CrossRef]
118. Larrey, D.; Ursic-Bedoya, J.; Meunier, L. Drug-Induced Hepatotoxicity. In *Schiff's Diseases of the Liver*, 12th ed.; Schiff, E.R., Ed.; Wiley-Blackwell: New York, NY, USA, 2018; pp. 740–773.
119. Schmeltzer, P.A.; Kosinski, A.S.; Kleiner, D.E.; Hoofnagle, J.H.; Stolz, A.; Fontana, R.J.; Russo, M.W. Drug-Induced Liver Injury Network (DILIN). Liver injury from nonsteroidal anti-inflammatory drugs in the United States. *Liver Int.* **2016**, *36*, 603–609. [CrossRef]
120. Aithal, G.P. Diclofenac-induced liver injury: A paradigm of idiosyncratic drug toxicity. *Expert Opin. Drug Saf.* **2004**, *3*, 519–523. [CrossRef]
121. Bessone, F.; Hernandez, N.; Roma, M.G.; Ridruejo, E.; Mendizabal, M.; Medina-Cáliz, I.; Robles-Díaz, M.; Lucena, M.I.; Andrade, R.J. Hepatotoxicity induced by coxibs: How concerned should we be? *Expert Opin. Drug Saf.* **2016**, *15*, 1463–1475. [CrossRef]
122. Soni, P.; Shell, B.; Cawkwell, G.; Li, C.; Ma, H. The hepatic safety and tolerability of the cyclooxygenase-2 selective NSAID celecoxib: Pooled analysis of 41 randomized controlled trials. *Curr. Med. Res. Opin.* **2009**, *25*, 1841–1851. [CrossRef]
123. Teoh, N.C.; Farrell, G.C. Hepatotoxicity associated with non-steroidal anti-inflammatory drugs. *Clin. Liver Dis.* **2003**, *7*, 401–413. [CrossRef]
124. Gitlin, N. Salicylate hepatotoxicity: The potential role of hypoalbuminemia. *J. Clin. Gastroenterol.* **1980**, *2*, 281–285. [CrossRef]
125. Schror, K. Aspirin and Reye syndrome: A review of the evidence. *Paediatr. Drugs* **2007**, *9*, 195–204. [CrossRef]
126. Centers for Disease Control and Prevention. Reye Syndrome—Ohio, Michigan. *MMWR* **1997**, *46*, 741–744.
127. Gutierrez-Suarez, R.; Burgos-Vargas, R. The use of methotrexate in children with rheumatic diseases. *Clin. Exp. Rheumatol.* **2010**, *28*, S122–S127.
128. Singsen, B.H.; Goldbach-Mansky, R. Methotrexate in the treatment of juvenile rheumatoid arthritis and other pediatric rheumatoid and nonrheumatic disorders. *Rheum. Dis. Clin. N. Am.* **1997**, *23*, 811–840. [CrossRef]
129. Graham, L.D.; Myones, B.L.; Rivas-Chacon, R.F.; Pachman, L.M. Morbidity associated with long-term methotrexate therapy in juvenile rheumatoid arthritis. *J. Pediatr.* **1992**, *120*, 468–473. [CrossRef]
130. Kocharla, L.; Taylor, J.; Weiler, T.; Ting, T.V.; Luggen, M.; Brunner, H.I. Monitoring methotrexate toxicity in juvenile idiopathic arthritis. *J. Rheumatol.* **2009**, *36*, 2813–2818. [CrossRef]

131. Bichenapally, S.; Khachatryan, V.; Muazzam, A.; Hamal, C.; Velugoti, L.S.D.R.; Tabowei, G.; Gaddipati, G.N.; Mukhtar, M.; Alzubaidee, M.J.; Dwarampudi, R.S.; et al. Risk of Liver Fibrosis in Methotrexate-Treated Patients: A Systematic Review. *Cureus* **2022**, *14*, e30910. [CrossRef]
132. Hashkes, P.J.; Balistreri, W.F.; Bove, K.E.; Ballard, E.T.; Passo, M.H. The relationship of hepatotoxic risk factors and liver histology in methotrexate therapy for juvenile rheumatoid arthritis. *J. Pediatr.* **1999**, *134*, 47–52. [CrossRef]
133. Keim, D.; Ragsdale, C.; Heidelberger, K.; Sullivan, D. Hepatic fibrosis with the use of methotrexate for juvenile rheumatoid arthritis. *J. Rheumatol.* **1990**, *17*, 846–848.
134. Kugathasan, S.; Newman, A.J.; Dahms, B.B.; Boyle, J. Liver biopsy findings in patients with juvenile rheumatoid arthritis receiving long-term, weekly methotrexate therapy. *J. Pediatr.* **1996**, *128*, 149–151. [CrossRef]
135. Richard, S.; Guerret, S.; Gerard, F.; Tebib, J.G.; Vignon, E. Hepatic fibrosis in rheumatoid arthritis patients treated with methotrexate: Application of a new semi-quantitative scoring system. *Rheumatology* **2000**, *39*, 50–54. [CrossRef]
136. Lahdenne, P.; Rapola, J.; Ylijoki, H.; Haapasaari, J. Hepatotoxicity in patients with juvenile idiopathic arthritis receiving longterm methotrexate therapy. *J. Rheumatol.* **2002**, *29*, 2442–2445.
137. Niyasom, C.; Soponkanaporn, S.; Vilaiyuk, S.; Lertudomphonwanit, C.; Getsuwan, S.; Tanpawpong, P.; Kaewduang, P.; Sobhonslidsuk, A. Use of transient elastography to assess hepatic steatosis and fibrosis in patients with juvenile idiopathic arthritis during methotrexate treatment. *Clin. Rheumatol.* **2024**, *43*, 423–433. [CrossRef]
138. Güngörer, V.; Öztürk, M.; Özlü, M.Y.; Arslan, Ş. What is the impact of methotrexate on liver in patients with juvenile idiopathic arthritis? Results of liver SWE performed in a single centre. *Mod. Rheumatol.* **2022**, *32*, 776–782. [CrossRef]
139. Çiçek, S.Ö.; Karaman, Z.F.; Şahin, N.; Kısaarslan, A.P.; Poyrazoğlu, M.H.; Düşünsel, R. Evaluation of liver elasticity with shear-wave elastography in juvenile idiopathic arthritis patients receiving methotrexate. *Pediatr. Int.* **2022**, *64*, e15239. [CrossRef]
140. Shenoi, S.; Horneff, G.; Aggarwal, A.; Ravelli, A. Treatment of non-systemic juvenile idiopathic arthritis. *Nat. Rev. Rheumatol.* **2024**, *20*, 170–181. [CrossRef]
141. Jobanputra, P.; Amarasena, R.; Maggs, F.; Homer, D.; Bowman, S.; Rankin, E.; Filer, A.; Raza, K.; Jubb, R. Hepatotoxicity associated with sulfasalazine in inflammatory arthritis: A case series from a local surveillance of serious adverse events. *BMC Musculoskelet. Disord.* **2008**, *9*, 48. [CrossRef]
142. Brooks, C.D. Sulfasalazine for the management of juvenile rheumatoid arthritis. *J. Rheumatol.* **2001**, *28*, 845–853.
143. Caspi, D.; Fuchs, D.; Yaron, M. Sulphasalazine induced hepatitis in juvenile rheumatoid arthritis. *Ann. Rheum. Dis.* **1992**, *51*, 275–276. [CrossRef]
144. Besnard, M.; Debray, D.; Durand, P.; Fabre, M.; Chardot, C.; Cezard, J.P. [Fulminant hepatitis in two children treated with sulfasalazine for Crohn disease]. *Arch. Pediatr.* **1999**, *6*, 643–646. [CrossRef]
145. Wang, L.; Varghese, S.; Bassir, F.; Lo, Y.C.; Ortega, C.A.; Shah, S.; Blumenthal, K.G.; Phillips, E.J.; Zhou, L. Stevens-Johnson syndrome and toxic epidermal necrolysis: A systematic review of PubMed/MEDLINE case reports from 1980 to 2020. *Front. Med.* **2022**, *9*, 949520. [CrossRef]
146. Kuchinskaya, E.M.; Chikova, I.A.; Kostik, M.M. Case report: Sulfasalazine-induced hypersensitivity. *Front. Med.* **2023**, *10*, 1140339. [CrossRef]
147. Piñana, E.; Lei, S.H.; Merino, R.; Melgosa, M.; De La Vega, R.; Gonzales-Obeso, E.; Ramírez, E.; Borobia, A.; Carcas, A. DRESS-syndrome on sulfasalazine and naproxen treatment for juvenile idiopathic arthritis and reactivation of human herpevirus 6 in an 11-year-old Caucasian boy. *J. Clin. Pharm. Ther.* **2010**, *35*, 365–370. [CrossRef]
148. Kitas, G.D.; Farr, M.; Waterhouse, L.; Bacon, P.A. Influence of acetylator status on sulphasalazine efficacy and toxicity in patients with rheumatoid arthritis. *Scand. J. Rheumatol.* **1992**, *21*, 220–225. [CrossRef]
149. Silverman, E.; Mouy, R.; Spiegel, L.; Jung, L.K.; Saurenmann, R.K.; Lahdenne, P.; Horneff, G.; Calvo, I.; Szer, I.S.; Simpson, K.; et al. Leflunomide or methotrexate for juvenile rheumatoid arthritis. *N. Engl. J. Med.* **2005**, *352*, 1655–1666. [CrossRef]
150. Alcântara, A.C.d.C.; Leite, C.A.C.; Leite, A.C.R.M.; Sidrim, J.J.C.; Silva, F.S.; Rocha, F.A.C. A longterm prospective real-life experience with leflunomide in juvenile idiopathic arthritis. *J. Rheumatol.* **2014**, *41*, 338–344. [CrossRef]
151. Chickermane, P.R.; Khubchandani, R.P. Evaluation of the benefits of sequential addition of leflunomide in patients with polyarticular course juvenile idiopathic arthritis failing standard dose methotrexate. *Clin. Exp. Rheumatol.* **2015**, *33*, 287–292.
152. New Boxed Warning for Severe Liver Injury with Arthritis Drug Arava [Leflunomide]. 2010. Available online: https://wayback.archive-it.org/7993/20170111234020/http:/www.fda.gov/Drugs/DrugSafety/DrugSafetyPodcasts/ucm219584.htm (accessed on 23 January 2026).
153. Gisbert, J.P.; González-Lama, Y.; Maté, J. Thiopurine-induced liver injury in patients with inflammatory bowel disease: A systematic review. *Am. J. Gastroenterol.* **2007**, *102*, 1518–1527. [CrossRef]
154. Said, M.A.; Silva, L.S.T.E.; de Oliveira Rocha, A.M.; Alves, G.G.B.; Piotto, D.G.P.; Len, C.A.; Terreri, M.T. Adverse drug reactions associated with treatment in patients with chronic rheumatic diseases in childhood: A retrospective real life review of a single center cohort. *Adv. Rheumatol.* **2020**, *60*, 53. [CrossRef]

155. Chouchana, L.; Terris, B.; Sogni, P.; Treluyer, J.; Costedoat-Chalumeau, N.; Loriot, M. Azathioprine-induced vanishing bile duct syndrome: The value of early thiopurine metabolism assessment. *Br. J. Clin. Pharmacol.* **2023**, *89*, 2625–2630. [CrossRef]
156. Behairy, B.; El-Said, H.; Konswa, H.; El-Deen, A.; Adawy, N.; Sira, A. Predictors of azathioprine toxicity in children with autoimmune hepatitis. *Clin. Exp. Hepatol.* **2021**, *7*, 47–54. [CrossRef]
157. Horning, K.; Schmidt, C. Azathioprine-Induced Rapid Hepatotoxicity. *J. Pharm. Technol.* **2014**, *30*, 18–20. [CrossRef]
158. Ahmad, J.; Li, Y.J.; Phillips, E.; Dellinger, A.; Hayashi, P.H.; Chalasani, N.; Fontana, R.J.; Kleiner, D.E.; Barnhart, H.X.; Hoofnagle, J.H. Liver Injury due to Intravenous Methylprednisolone in the Drug-Induced Liver Injury Network. *Liver Int.* **2025**, *45*, e16242. [CrossRef]
159. Jarmakiewicz-Czaja, S.; Sokal, A.; Pardak, P.; Filip, R. Glucocorticosteroids and the Risk of NAFLD in Inflammatory Bowel Disease. *Can. J. Gastroenterol. Hepatol.* **2022**, *2022*, 4344905. [CrossRef]
160. Hammond, A.; Ramersdorfer, C.; Palitzsch, K.D.; Scholmerich, J.; Lock, G. Fatal liver failure after corticosteroid treatment of a hepatitis B virus carrier. *Dtsch. Med. Wochenschr.* **1999**, *124*, 687–690. [CrossRef]
161. Monteserín, L.; Jiménez, M.; Linares, P.; Rodríguez-Martín, L.; Álvarez-Cuenllas, B.; Álvarez-Cañas, C.; Jorquera, F. Acute hepatitis secondary to high-dose intravenous methylprednisolone. *Gastroenterol. Hepatol.* **2018**, *41*, 508–509. [CrossRef]
162. Chen, D.; Pham, C.; Kaur, M.; Yip, K. Hydroxychloroquine-Induced Hepatotoxicity in Systemic Lupus Erythematous: A Case Report and Literature Review. *Cureus* **2025**, *17*, e81664. [CrossRef]
163. Makin, A.J.; Wendon, J.; Fitt, S.; Portmann, B.C.; Williams, R. Fulminant hepatic failure secondary to hydroxychloroquine. *Gut* **1994**, *35*, 569–570. [CrossRef]
164. Schrezenmeier, E.; Dörner, T. Mechanisms of action of hydroxychloroquine and chloroquine: Implications for rheumatology. *Nat. Rev. Rheumatol.* **2020**, *16*, 155–166. [CrossRef]
165. Chighizola, C.B.; Ong, V.H.; Meroni, P.L. The Use of Cyclosporine A in Rheumatology: A 2016 Comprehensive Review. *Clin. Rev. Allergy Immunol.* **2017**, *52*, 401–423. [CrossRef]
166. Horneff, G.; Minden, K.; Rolland, C.; Daly, A.C.H.; Borlenghi, C.; Ruperto, N. Efficacy and safety of TNF inhibitors in the treatment of juvenile idiopathic arthritis: A systematic literature review. *Pediatr. Rheumatol. Online J.* **2023**, *21*, 20. [CrossRef]
167. French, J.B.; Bonacini, M.; Ghabril, M.; Foureau, D.; Bonkovsky, H.L. Hepatotoxicity Associated with the Use of Anti-TNF-alpha Agents. *Drug Saf.* **2016**, *39*, 199–208. [CrossRef]
168. Lurz, E.; Patel, H.; Frimpong, R.G.; Ricciuto, A.; Kehar, M.; Wales, P.W.; Towbin, A.J.; Chavhan, G.B.; Kamath, B.M.; Ng, V.L. Sarcopenia in Children with End-Stage Liver Disease. *J. Pediatr. Gastroenterol. Nutr.* **2018**, *66*, 222–226. [CrossRef]
169. Ghabril, M.; Bonkovsky, H.L.; Kum, C.; Davern, T.; Hayashi, P.H.; Kleiner, D.E.; Serrano, J.; Rochon, J.; Fontana, R.J.; Bonacini, M. US Drug-Induced Liver Injury Network. Liver injury from tumor necrosis factor-alpha antagonists: Analysis of thirty-four cases. *Clin. Gastroenterol. Hepatol.* **2013**, *11*, 558–564.e3. [CrossRef]
170. Tobon, G.J.; Cañas, C.; Jaller, J.-J.; Restrepo, J.-C.; Anaya, J.-M. Serious liver disease induced by infliximab. *Clin. Rheumatol.* **2007**, *26*, 578–581. [CrossRef]
171. McCluggage, L.K. Safety of TNF inhibitors in adolescents and children. *Adolesc. Health Med. Ther.* **2011**, *2*, 1–8. [CrossRef]
172. Giancane, G.; Papa, R.; Vastert, S.; Bagnasco, F.; Swart, J.F.; Quartier, P.; Antón, J.; Kamphuis, S.; Sanner, H.; Glerup, M.; et al. Anakinra in Patients with Systemic Juvenile Idiopathic Arthritis: Long-term Safety from the Pharmachild Registry. *J. Rheumatol.* **2022**, *49*, 398–407. [CrossRef]
173. Martins, F.R.; Azevedo, A.C.; Ganhão, S.; Aguiar, F.; Rodrigues, M.; Brito, I. Anakinra and hepatotoxicity in pediatric rheumatology: A case series. *Pediatr. Rheumatol. Online J.* **2023**, *21*, 112. [CrossRef]
174. Canna, S.; Frankovich, J.; Higgins, G.; Narkewicz, M.R.; Nash, S.R.; Hollister, J.R.; Soep, J.B.; Dragone, L.L. Acute hepatitis in three patients with systemic juvenile idiopathic arthritis taking interleukin-1 receptor antagonist. *Pediatr. Rheumatol. Online J.* **2009**, *7*, 21. [CrossRef]
175. Mannala, S.; Kehar, M.; Samson, L.; Poulin, A.; Kerr, T.; Jariwala, M.P. Drug-induced liver injury secondary to anakinra in a patient with systemic juvenile idiopathic arthritis—Case report and literature overview. *Can. Liver J.* **2025**, *8*, 591–596. [CrossRef]
176. National Institute of Diabetes and Digestive and Kidney Diseases. Canakinumab. In *LiverTox: Clinical and Research Information on Drug-Induced Liver Injury [Internet]*; National Institute of Diabetes and Digestive and Kidney Diseases: Bethesda, MD, USA, 2012.
177. Gülez, N.; Makay, B.; Sözeri, B. Long-term effectiveness and safety of canakinumab in pediatric familial Mediterranean fever patients. *Mod. Rheumatol.* **2020**, *30*, 166–171. [CrossRef]
178. Lachmann, H.J.; Kone-Paut, I.; Kuemmerle-Deschner, J.B.; Leslie, K.S.; Hachulla, E.; Quartier, P.; Gitton, X.; Widmer, A.; Patel, N.; Hawkins, P.N. Use of canakinumab in the cryopyrin-associated periodic syndrome. *N. Engl. J. Med.* **2009**, *360*, 2416–2425. [CrossRef]
179. Gazda, A.; Naishtetik, I.; Kołodziejczyk, B.; Rybak, K.; Mańczak, M.; Wójtowicz, J.; Krasowicz-Towalska, O.; Gietka, P. Clinical outcomes of tocilizumab therapy in polyarticular and systemic juvenile idiopathic arthritis: A single-center analysis [2018–2022]. *Rheumatol. Int.* **2024**, *44*, 2949–2959. [CrossRef]

180. National Institute of Diabetes and Digestive and Kidney Diseases. Tocilizumab. In *LiverTox: Clinical and Research Information on Drug-Induced Liver Injury [Internet]*; National Institute of Diabetes and Digestive and Kidney Diseases: Bethesda, MD, USA, 2012.
181. Brunner, H.I.; Ruperto, N.; Zuber, Z.; Cuttica, R.; Keltsev, V.; Xavier, R.M.; Burgos-Vargas, R.; Penades, I.C.; Silverman, E.D.; Espada, G.; et al. Efficacy and Safety of Tocilizumab for Polyarticular-Course Juvenile Idiopathic Arthritis in the Open-Label Two-Year Extension of a Phase III Trial. *Arthritis Rheumatol.* **2021**, *73*, 530–541. [CrossRef]
182. Nakamura, J.; Nagashima, T.; Nagatani, K.; Yoshio, T.; Iwamoto, M.; Minota, S. Reactivation of hepatitis B virus in rheumatoid arthritis patients treated with biological disease-modifying antirheumatic drugs. *Int. J. Rheum. Dis.* **2016**, *19*, 470–475. [CrossRef]
183. Onel, K.B.; Horton, D.B.; Lovell, D.J.; Shenoi, S.; Cuello, C.A.; Angeles-Han, S.T.; Becker, M.L.; Cron, R.Q.; Feldman, B.M.; Ferguson, P.J.; et al. 2021 American College of Rheumatology Guideline for the Treatment of Juvenile Idiopathic Arthritis: Recommendations for Nonpharmacologic Therapies, Medication Monitoring, Immunizations, and Imaging. *Arthritis Care Res.* **2022**, *74*, 505–520. [CrossRef]
184. Kostik, M.M.; Raupov, R.K.; Suspitsin, E.N.; Isupova, E.A.; Gaidar, E.V.; Gabrusskaya, T.V.; Kaneva, M.A.; Snegireva, L.S.; Likhacheva, T.S.; Miulkidzhan, R.S.; et al. The Safety and Efficacy of Tofacitinib in 24 Cases of Pediatric Rheumatic Diseases: Single Centre Experience. *Front. Pediatr.* **2022**, *10*, 820586. [CrossRef]
185. Ramanan, A.V.; Quartier, P.; Okamoto, N.; Foeldvari, I.; Spindler, A.; Fingerhutová, Š.; Antón, J.; Wang, Z.; Meszaros, G.; Araújo, J.; et al. Baricitinib in juvenile idiopathic arthritis: An international, phase 3, randomised, double-blind, placebo-controlled, withdrawal, efficacy, and safety trial. *Lancet* **2023**, *402*, 555–570. [CrossRef]
186. Tang, D.; Jiang, Y.; Zhang, Y.; Xie, J.; Zhang, J. Successful management of Still's disease with severe liver injury through the administration of baricitinib: A case report. *Front. Med.* **2025**, *12*, 1591431. [CrossRef]
187. Sanchez, G.A.M.; Reinhardt, A.; Ramsey, S.; Wittkowski, H.; Hashkes, P.J.; Berkun, Y.; Schalm, S.; Murias, S.; Dare, J.A.; Brown, D.; et al. JAK1/2 inhibition with baricitinib in the treatment of autoinflammatory interferonopathies. *J. Clin. Investig.* **2018**, *128*, 3041–3052. [CrossRef]
188. McAtee, C.L.; Lubega, J.; Underbrink, K.; Curry, K.; Msaouel, P.; Barrow, M.; Muscal, E.; Lotze, T.; Srivaths, P.; Forbes, L.R.; et al. Association of Rituximab Use with Adverse Events in Children, Adolescents, and Young Adults. *JAMA Netw. Open.* **2021**, *4*, e2036321. [CrossRef]
189. Asrani, S.K.; Devarbhavi, H.; Eaton, J.; Kamath, P.S. Burden of liver diseases in the world. *J. Hepatol.* **2019**, *70*, 151–171. [CrossRef]
190. Armendariz-Pineda, S.M.; Vargas-Beltran, A.M.; Corredor-Nassar, M.J.; Gamboa-Domínguez, A.; Santos-Reyes, D.A.; Cordova-Gallardo, J. Drug-induced liver injury secondary to rituximab use. *Oxf. Med. Case Rep.* **2025**, *2025*, omaf003. [CrossRef]
191. Huda, T.; Hussain, F.; Mani, H.; Gheith, S.M.; Skandan, S. Rituximab-Associated Liver Toxicity Without Known Viral Reactivation. *Cureus* **2024**, *16*, e64331. [CrossRef]
192. Sawhney, S.; Agarwal, M. Rituximab use in pediatric systemic lupus erythematosus: Indications, efficacy and safety in an Indian cohort. *Lupus* **2021**, *30*, 1829–1836. [CrossRef]
193. Tambralli, A.; Beukelman, T.; Cron, R.Q.; Stoll, M.L. Safety and efficacy of rituximab in childhood-onset systemic lupus erythematosus and other rheumatic diseases. *J. Rheumatol.* **2015**, *42*, 541–546. [CrossRef]
194. Cognard, J.; Pietrement, C.; Laurent, A.; Fouillet-Desjonquères, M.; Moran-Alvarez, P.; Reumaux, H.; Leguevaques, D.; Hatchuel, Y.; Felix, A.; Pillet, P.; et al. Indications, efficacy and safety of rituximab in childhood-onset systemic lupus erythematosus: A retrospective study of the JIR cohort. *Rheumatology* **2025**, *64*, 4921–4929. [CrossRef]
195. Brunner, H.I.; Abud-Mendoza, C.; Viola, D.O.; Penades, I.C.; Levy, D.; Anton, J.; Calderon, J.E.; Chasnyk, V.G.; Ferrandiz, M.A.; Keltsev, V.; et al. Safety and efficacy of intravenous belimumab in children with systemic lupus erythematosus: Results from a randomised, placebo-controlled trial. *Ann. Rheum. Dis.* **2020**, *79*, 1340–1348. [CrossRef]
196. Cacoub, P.; Terrier, B. Hepatitis B-related autoimmune manifestations. *Rheum. Dis. Clin. N. Am.* **2009**, *35*, 125–137. [CrossRef]
197. Fernandes, B.; Dias, E.; Mascarenhas-Saraiva, M.; Bernardes, M.; Costa, L.; Cardoso, H.; Macedo, G. Rheumatologic manifestations of hepatic diseases. *Ann. Gastroenterol.* **2019**, *32*, 352–360. [CrossRef]
198. Graf, C.; Arncken, J.; Lange, C.M.; Willuweit, K.; Schattenberg, J.M.; Seessle, J.; Lang-Meli, J.; Böttler, T.; Dietz, J.; Wetzstein, N.; et al. Hepatic sarcoidosis: Clinical characteristics and outcome. *JHEP Rep.* **2021**, *3*, 100360. [CrossRef]
199. Guillevin, L.; Mahr, A.; Callard, P.; Godmer, P.; Pagnoux, C.; Leray, E.; Cohen, P. Hepatitis B virus-associated polyarteritis nodosa: Clinical characteristics, outcome, and impact of treatment in 115 patients. *Medicine* **2005**, *84*, 313–322. [CrossRef] [PubMed]
200. Cacoub, P.; Vieira, M.; Saadoun, D. Cryoglobulinemia—One Name for Two Diseases. *N. Engl. J. Med.* **2024**, *391*, 1426–1439. [CrossRef]
201. Ferri, C. Mixed cryoglobulinemia. *Orphanet J. Rare Dis.* **2008**, *3*, 25. [CrossRef] [PubMed]
202. Rao, A.G. Cryoglobulinemia in a child. *Indian J. Dermatol.* **2010**, *55*, 381–383. [CrossRef]
203. Palazzi, C.; D'ANgelo, S.; Olivieri, I. Hepatitis C virus-related arthritis. *Autoimmun. Rev.* **2008**, *8*, 48–51. [CrossRef]
204. Jog, N.R.; James, J.A. Epstein Barr Virus and Autoimmune Responses in Systemic Lupus Erythematosus. *Front. Immunol.* **2020**, *11*, 623944. [CrossRef]

205. Robinson, W.H.; Younis, S.; Love, Z.Z.; Steinman, L.; Lanz, T.V. Epstein-Barr virus as a potentiator of autoimmune diseases. *Nat. Rev. Rheumatol.* **2024**, *20*, 729–740. [CrossRef]
206. Draborg, A.H.; Duus, K.; Houen, G. Epstein-Barr virus and systemic lupus erythematosus. *Clin. Dev. Immunol.* **2012**, *2012*, 370516. [CrossRef]
207. Wu, J.; Wang, L.; Ming, B.; Cai, S.; Dong, L. The clinical and immunological features of CMV infection in rheumatic patients: A nested case-control study. *Clin. Rheumatol.* **2025**, *44*, 3033–3047. [CrossRef]
208. Sebastiani, G.; Iuliano, A.; Canofari, C.; Bracci, M. Cytomegalovirus infection in Systemic Lupus Erythematosus: Report of four cases challenging the management of the disease, and literature review. *Lupus* **2019**, *28*, 432–437. [CrossRef]
209. Jain, A.; Misra, D.P.; Ramesh, A.; Basu, D.; Jain, V.K.; Negi, V.S. Tuberculosis mimicking primary systemic vasculitis: Not to be missed! *Trop. Doct.* **2017**, *47*, 158–164. [CrossRef]
210. Lim, A.Y.; Lee, G.Y.; Jang, S.Y.; Gwag, H.B.; Choi, S.H.; Jeon, E.-S.; Cha, H.-S.; Sung, K.; Kim, Y.-W.; Kim, S.M.; et al. Comparison of clinical characteristics in patients with Takayasu arteritis with and without concomitant tuberculosis. *Heart Vessel.* **2016**, *31*, 1277–1284. [CrossRef]
211. Ali, G.A.; Goravey, W. Tuberculosis and Takayasu's arteritis: An enigmatic association. *IDCases* **2024**, *36*, e01938. [CrossRef]
212. Higashiguchi, M.; Matsumoto, T.; Kitamura, T.; Nakajima, T.; Nishioka, K.; Kimura, H.; Yamamoto, T.; Komuta, K. Poncet's Disease (Reactive Arthritis Associated with Tuberculosis). *Intern. Med.* **2022**, *61*, 3245–3249. [CrossRef]
213. Horowitz, H.W.; Dworkin, B.; Forseter, G.; Nadelman, R.B.; Connolly, C.; Luciano, B.B.; Nowakowski, J.; O'Brien, T.A.; Calmann, M.; Wormser, G.P. Liver function in early Lyme disease. *Hepatology* **1996**, *23*, 1412–1417. [CrossRef]
214. Puius, Y.A.; Kalish, R.A. Lyme arthritis: Pathogenesis, clinical presentation, and management. *Infect. Dis. Clin. N. Am.* **2008**, *22*, 289–300. [CrossRef] [PubMed]
215. Korman, T.M.; Varley, C.C.; Spelman, D.W. Acute hepatitis associated with Campylobacter jejuni bacteraemia. *Eur. J. Clin. Microbiol. Infect. Dis.* **1997**, *16*, 678–681. [CrossRef]
216. Schmitt, S.K. Reactive Arthritis. *Infect. Dis. Clin. N. Am.* **2017**, *31*, 265–277. [CrossRef]
217. Xanthakos, S.A.; Ibrahim, S.H.; Adams, K.; Kohli, R.; Sathya, P.; Sundaram, S.; Vos, M.B.; Dhawan, A.; Caprio, S.; Behling, C.A.; et al. AASLD Practice Statement on the evaluation and management of metabolic dysfunction-associated steatotic liver disease in children. *Hepatology* **2025**, *82*, 1352–1394. [CrossRef] [PubMed]
218. Drazilova, S.; Veseliny, E.; Lenartova, P.D.; Drazilova, D.; Gazda, J.; Grgurevic, I.; Janicko, M.; Jarcuska, P. IgG4-Related Sclerosing Cholangitis: Rarely Diagnosed, but not a Rare Disease. *Can. J. Gastroenterol. Hepatol.* **2021**, *2021*, 1959832. [CrossRef] [PubMed]
219. Ahmad, J.; Barnhart, H.X.; Bonacini, M.; Ghabril, M.; Hayashi, P.H.; Odin, J.A.; Rockey, D.C.; Rossi, S.; Serrano, J.; Tillmann, H.L.; et al. Value of liver biopsy in the diagnosis of drug-induced liver injury. *J. Hepatol.* **2022**, *76*, 1070–1078. [CrossRef]
220. Poupon, R.; Lindor, K.; Cauch-Dudek, K.; Dickson, E.; Poupon, R.; Heathcote, E. Combined analysis of randomized controlled trials of ursodeoxycholic acid in primary biliary cirrhosis. *Gastroenterology* **1997**, *113*, 884–890. [CrossRef] [PubMed]
221. Sapountzi, E.; Kotanidou, E.P.; Tsinopoulou, V.-R.; Fotis, L.; Fidani, L.; Galli-Tsinopoulou, A. The Management of IgG4-Related Disease in Children: A Systematic Review. *Children* **2025**, *12*, 213. [CrossRef]

Disclaimer/Publisher's Note: The statements, opinions and data contained in all publications are solely those of the individual author(s) and contributor(s) and not of MDPI and/or the editor(s). MDPI and/or the editor(s) disclaim responsibility for any injury to people or property resulting from any ideas, methods, instructions or products referred to in the content.