surgeries

Case Report

Double Microsurgical Corticoperiosteal Free Flap from Bilateral Medial Femoral Condyles for the Treatment of Forearm Nonunions: A Case Report

Matteo Guzzini [1], Alice Patrignani [1,*] and Susanna Pagnotta [2]

[1] Departmental Faculty of Medicine and Surgery, Unicamillus-Saint Camillus International University of Health Sciences, Via di Sant'Alessandro 8, 00131 Rome, Italy; matteo.guzzini@unicamillus.org
[2] Department of Orthopaedics and Traumatology, Aurelia Hospital, Via Aurelia 860, 00165 Rome, Italy; susannapagnotta@gmail.com
* Correspondence: alice.patrignani@unicamillus.org; Tel.: +39-3466709836

Abstract

Background: Forearm nonunions represent a challenging clinical condition that significantly impairs upper limb function. Various surgical techniques have been proposed, including vascularized bone grafts. Although these procedures are not considered first-line treatment, they play a crucial role in complex or recalcitrant cases, particularly after failure of conventional methods, where their superior biological potential can significantly enhance bone healing. Despite the widespread use of the medial femoral condyle corticoperiosteal flap, simultaneous bilateral harvest has not been previously described in the literature. Case Presentation: We report the case of a 50-year-old male presenting with persistent nonunions of both the radius and ulna following previous osteosynthesis and revision surgery with iliac crest bone graft. The patient was successfully treated using bilateral vascularized corticoperiosteal free flaps harvested from both medial femoral condyles. Conclusions: Double vascularized corticoperiosteal free flaps may represent an effective and reliable option for the treatment of complex forearm nonunions, especially in cases with multiple previous surgical failures. To the best of our knowledge, this case represents the first report of simultaneous bilateral medial femoral condyle corticoperiosteal flap harvest.

Keywords: forearm nonunion; corticoperiosteal flap; medial femoral condyle; vascularized bone graft; microsurgery; upper limb reconstruction; bone healing; complex nonunion; free flap surgery

Check for updates

Academic Editor: Francesco De Francesco

Received: 17 May 2026
Revised: 11 June 2026
Accepted: 15 June 2026
Published: 18 June 2026

Copyright: © 2026 by the authors. Licensee MDPI, Basel, Switzerland. This article is an open access article distributed under the terms and conditions of the Creative Commons Attribution (CC BY) license.

1. Introduction

Forearm nonunions are disabling conditions that compromise both wrist and elbow function. Several treatment strategies have been described to enhance bone healing, including biological stimulation techniques and surgical reconstruction.

Among surgical options, vascularized bone grafts play a key role due to their superior biological potential. The vascularized fibular graft is typically indicated in bone defects larger than 5 cm [1], whereas corticoperiosteal flaps are preferred for smaller defects [2,3]. The advantage of microsurgical flaps is to guarantee an improved healing of nonunions, given their high biological potential associated with vascularized bone. First introduced by Sakai in 1991 [4], vascularized corticoperiosteal flaps are commonly harvested from the medial femoral condyle. Their blood supply arises from the descending genicular artery in approximately 80% of cases and from the superomedial genicular artery in the remaining

cases. These flaps can be used as either pedicled or free grafts, depending on the defect location [3]. Corticoperiosteal flaps can be harvested as free or pedicled flaps [5]; the former is generally involved in upper extremity bone defects [2], with the latter in lower extremity ones. To the best of our knowledge, this is the first report describing the use of bilateral corticoperiosteal free flaps harvested from both medial femoral condyles in a single-stage procedure to treat simultaneous radius and ulna nonunions.

2. Case Report

2.1. Case Presentation

A 50-year-old male manual worker sustained a high-energy open fracture of the left forearm (AO classification: 2R2C3 and 2U2C3) in July 2019. Initial management at another institution consisted of temporary external fixation, followed by definitive open reduction and internal fixation (ORIF) with plates and screws after 15 days. Postoperatively, the limb was immobilized for 30 days. At 4 months postoperatively, radiographic evaluation showed no signs of bone healing. Despite two months of adjunctive extracorporeal shock wave therapy, the patient remained symptomatic, and a diagnosis of nonunion of both the radius and ulna was established. In April 2020, revision surgery was performed with repeat osteosynthesis and autologous iliac crest bone grafting. The postoperative protocol included cast immobilization for 30 days followed by an intensive rehabilitation program. However, clinical and radiological improvement was not achieved. In December 2020, the patient was referred to our institution due to persistent forearm pain, significant reduction in grip strength, and marked limitation in both wrist and elbow range of motion. Radiographic assessment confirmed established nonunion of both radius and ulna, with no evidence of hardware failure but clear signs of impaired biological healing. Given the history of multiple failed surgical attempts and the compromised biological environment of the bone, a reconstructive strategy based on vascularized bone transfer was considered. In January 2021, we elected to perform a one-stage reconstruction using bilateral vascularized corticoperiosteal free flaps harvested from both medial femoral condyles. Due to the poor bone quality resulting from repeated surgical procedures, the previously implanted plates were preserved to maintain mechanical stability. Only the screws located within the nonunion sites and interfering with the osteogenic environment were removed (Figure 1). The bone defects were then filled and biologically enhanced using the harvested corticoperiosteal flaps.

2.2. Surgical Technique

The patient was placed in the supine position under general anesthesia. Preoperative planning included bilateral skin marking of the medial femoral condyles to identify the flap harvest sites and guide surgical exposure (Figure 2).

The left upper limb was prepared and draped in a sterile fashion. Tourniquets were applied at the root of both thighs. Both lower limbs were positioned in slight flexion and external rotation to allow optimal access to the medial femoral condyles. The corticoperiosteal free flaps were harvested from both medial femoral condyles according to the technique described by Doi et al. [6]. Bilateral flap harvest was performed sequentially, first on the right side and subsequently on the left. A longitudinal incision was made over the medial aspect of the distal thigh, centered over the adductor magnus tendon, proximal to the knee joint line. After skin and subcutaneous dissection, the fascia was incised and the vastus medialis muscle was elevated and retracted anteriorly, exposing the medial femoral condyle.



Figure 1. Preoperative radiographic evaluation showing nonunion of both the radius and ulna, with retained fixation hardware. Screws located within the nonunion sites were identified and subsequently removed to optimize the biological environment while preserving plate stability.



Figure 2. Preoperative surgical planning showing bilateral skin markings over the medial femoral condyles to identify the corticoperiosteal flap harvest sites.

Careful dissection was performed to identify the vascular pedicle. The descending genicular artery and the superomedial genicular vessels were identified, and the descending genicular artery was selected bilaterally as the main vascular pedicle due to its caliber and reliability. The pedicle was meticulously dissected, and its muscular and saphenous branches were coagulated or ligated to allow adequate mobilization (Figure 3).

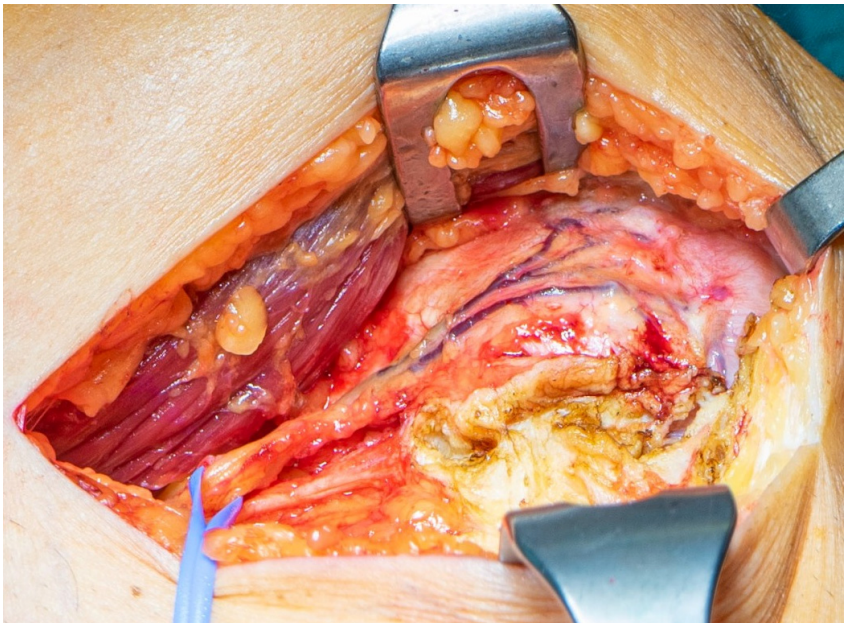

Figure 3. Intraoperative view of the medial femoral condyle during flap harvest. The vastus medialis muscle is retracted anteriorly, exposing the vascular pedicle. The descending genicular vessels are identified and dissected to allow mobilization of the corticoperiosteal flap.

The donor site was selected based on the area with the highest density of periosteal perforators. Bone harvesting was performed using a piezosurgical device in order to minimize thermal injury and preserve the integrity of the periosteum and surrounding soft tissues [7]. A thin cortico-cancellous corticoperiosteal flap was then elevated using a small osteotome, taking care to preserve the cambium layer (Figures 4 and 5).

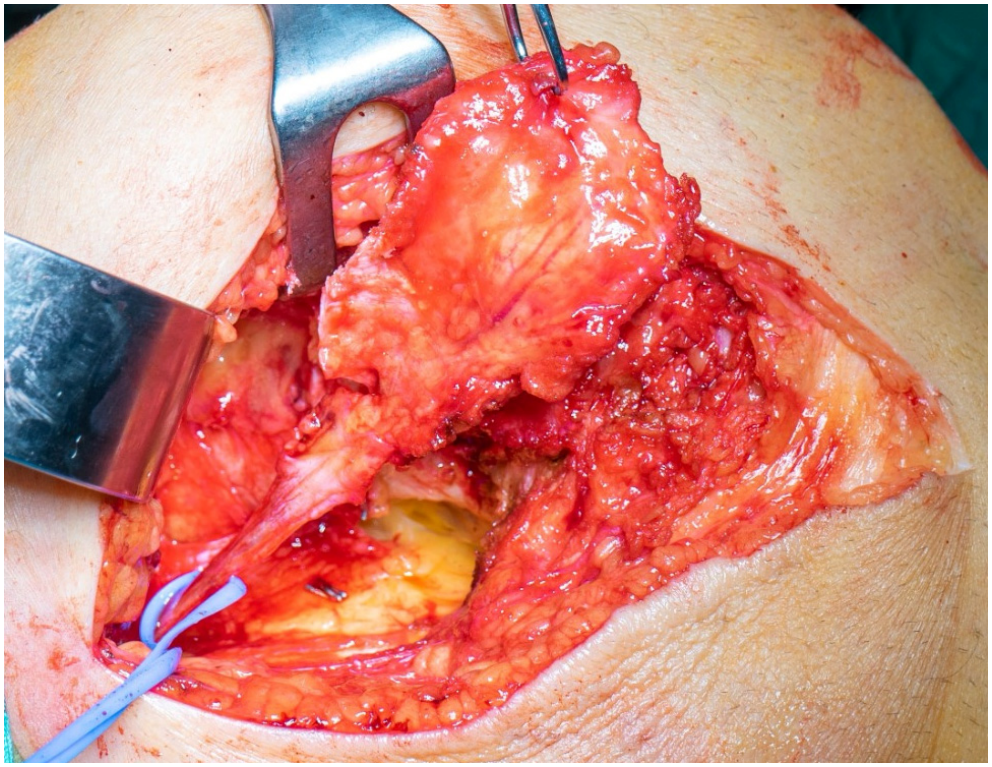

Figure 4. Intraoperative view of the corticoperiosteal flap harvested from the medial femoral condyle.

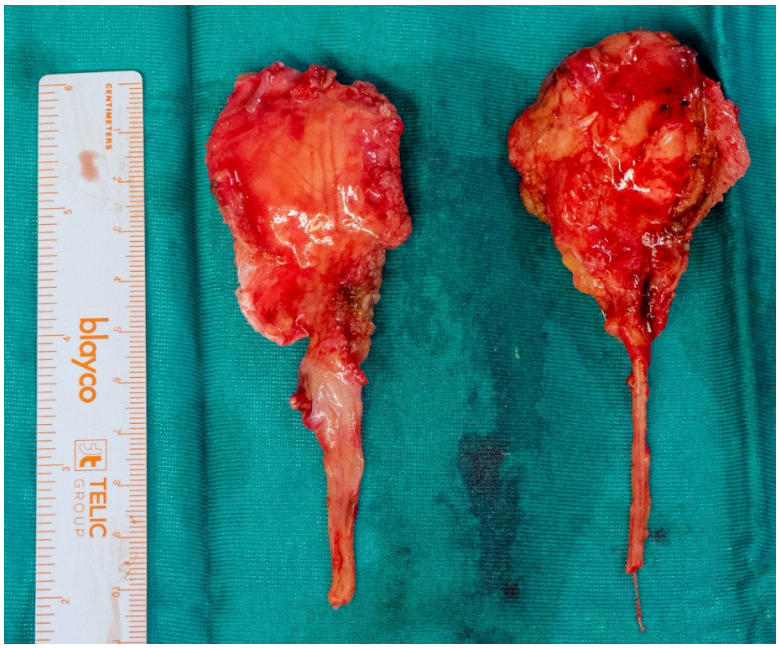

Figure 5. Harvested corticoperiosteal free flaps from both medial femoral condyles. Each flap is based on an independent vascular pedicle. The grafts are displayed with the periosteal surface facing the operating table and the cortical component exposed. A ruler is shown for scale.

In parallel, preparation of the recipient site was carried out by a second surgical team. After removal of the screws located within the nonunion sites of both the radius and ulna, thorough debridement of fibrous tissue and necrotic bone was performed until viable bleeding bone was obtained. The harvested corticoperiosteal flaps were then transferred to the forearm and carefully wrapped around the nonunion sites of both the radius and ulna, ensuring intimate contact with the recipient bone. Microsurgical reconstruction was subsequently performed. For the radius, an end-to-side arterial anastomosis was performed between the genicular artery and the radial artery (Figure 6).

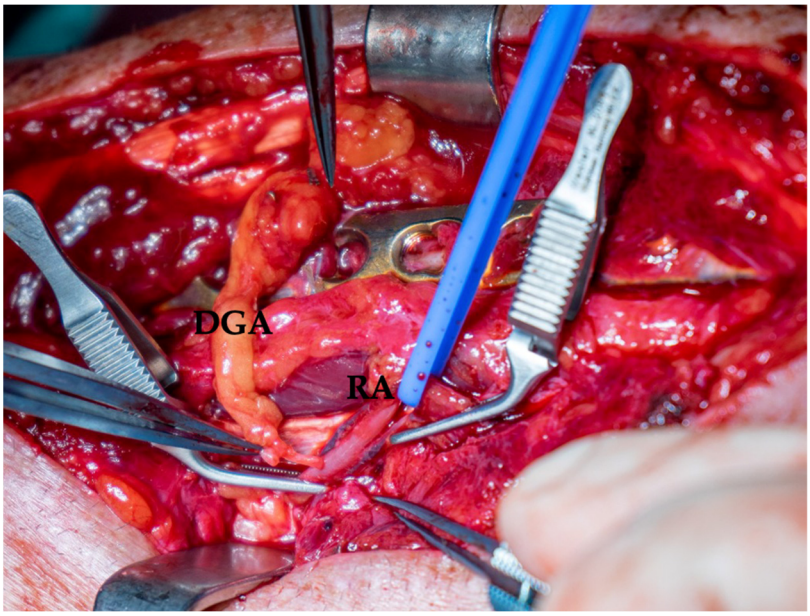

Figure 6. Intraoperative view of the end-to-side arterial microvascular anastomosis between the descending genicular artery (DGA) of the medial femoral condyle corticoperiosteal flap and the radial artery (RA). The donor and recipient vessels are labeled for clarity.

For the ulna, an end-to-side arterial anastomosis was carried out between the genicular artery on the ulnar artery (Figure 7).

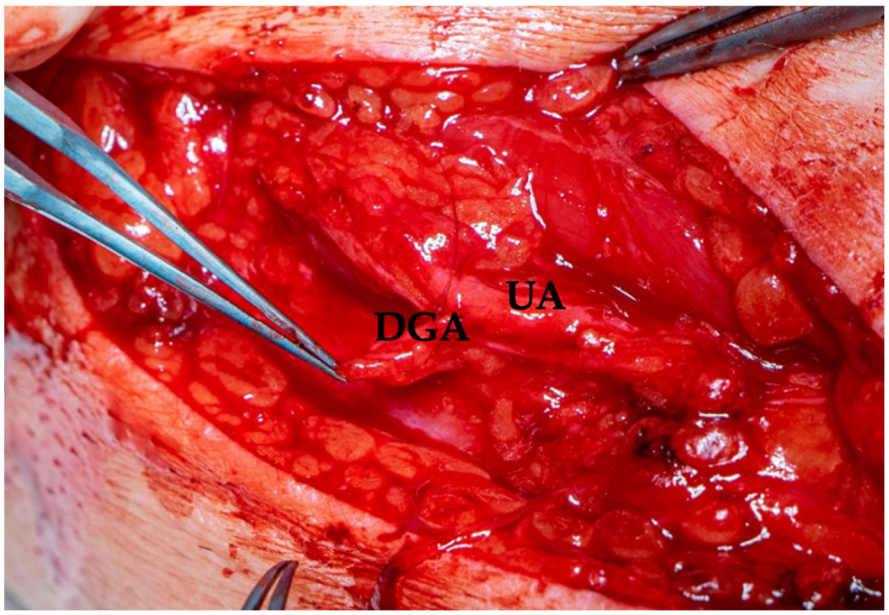

Figure 7. Intraoperative view of the end-to-side arterial microvascular anastomosis between the descending genicular artery (DGA) of the medial femoral condyle corticoperiosteal flap and the ulnar artery (UA). The donor and recipient vessels are labeled for clarity.

At the end of the procedure, patency of all microvascular anastomoses was carefully assessed using standard intraoperative methods, confirming adequate blood flow in both flaps. Immediate postoperative radiographs confirmed satisfactory hardware positioning and restoration of forearm alignment (Figure 8).

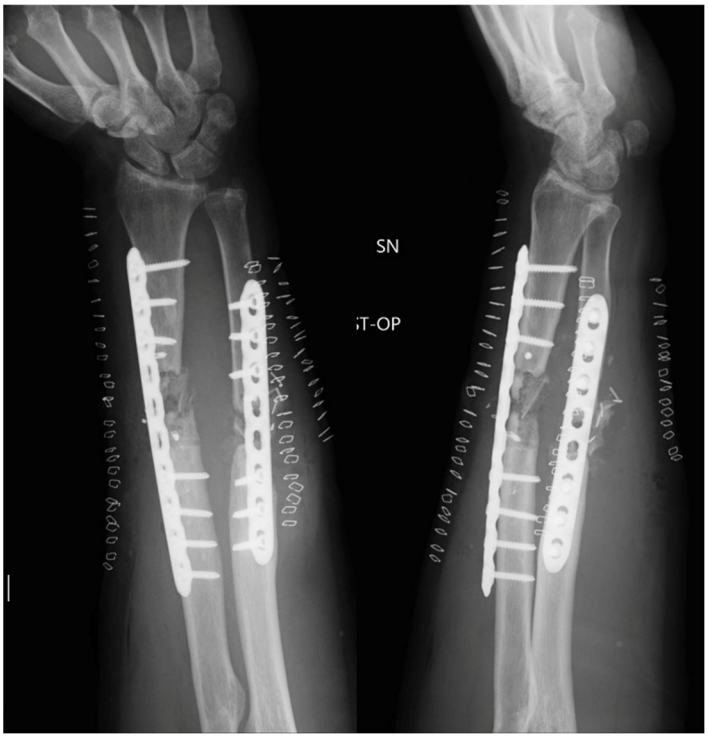

Figure 8. Immediate postoperative anteroposterior and lateral radiographs showing fixation of the radius and ulna following bilateral vascularized corticoperiosteal free flap reconstruction.

2.3. Post—Operative Protocol

Postoperatively, the left upper limb was immobilized in a brachio-metacarpal cast for 30 days, while both lower limbs were managed with compressive bandaging. The patient was maintained on bed rest for the first 48 h, after which gradual mobilization with crutches was allowed. Antithrombotic prophylaxis was administered for 2 weeks. Sutures were removed at 2 weeks postoperatively. A structured rehabilitation program was initiated at 5 weeks, focusing on progressive recovery of range of motion without weight-bearing until the third postoperative month. Clinical and radiological follow-up evaluations were performed at 1, 3, 6, 9, and 12 months. Clinical assessment included pain evaluation using the Visual Analog Scale (VAS), measurement of range of motion of the forearm (elbow and wrist) and both knees, and functional evaluation of the donor sites using the International Knee Documentation Committee (IKDC) score. Radiological assessment was carried out at regular intervals to monitor bone healing at the recipient site and regeneration at the donor sites.

3. Outcomes

At the final follow-up, the patient reported no complications and complete resolution of pain. A full range of motion of the elbow and wrist was achieved in flexion–extension and forearm supination–pronation. The patient had returned to his previous occupation as a manual worker by 12 months after surgery. He reported high satisfaction with the procedure and substantial improvement in daily activities and quality of life. Additionally, both knees demonstrated full range of motion without pain or functional limitation. Radiographic evaluation of the recipient site showed complete bone union of both radius and ulna at 12 months postoperatively (Figure 9). Radiographic evaluation of the donor sites demonstrated complete bone regeneration at both medial femoral condyles within 12 months (Figure 10). No donor-site complaints were reported throughout the follow-up period. Both knees demonstrated full range of motion without pain or functional limitation, and radiographs confirmed complete regeneration of the donor sites.

At final follow-up at 12 months, complete restoration of upper limb function and preserved donor-site knee function were clinically confirmed (Figure 11).

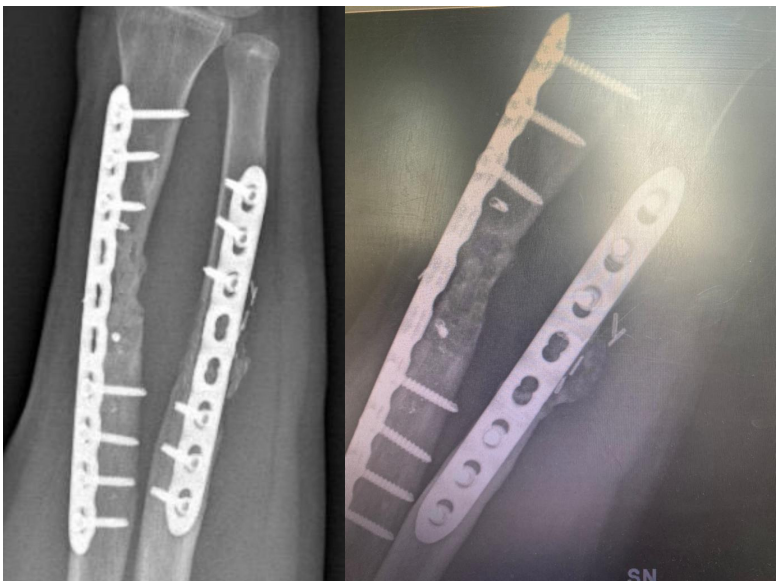

Figure 9. Radiographic evaluation at 12 months postoperatively demonstrating complete bone union of both the radius and ulna. (**Left**) Anteroposterior view of the forearm. (**Right**) Lateral/oblique radiographic view confirming consolidation at both nonunion sites.



Figure 10. Anteroposterior radiograph of both knees obtained 12 months postoperatively demonstrating complete regeneration of the medial femoral condyle donor sites.



Figure 11. Clinical evaluation at final follow-up at 12 months demonstrating satisfactory functional recovery, showing full forearm supination (**top**), full forearm pronation (**middle**), and preserved bilateral knee function without functional limitation at the donor sites (**bottom**).

4. Discussion

Forearm nonunions are particularly challenging due to the need to restore both mechanical stability and precise rotational function, with reported rates of persistent nonunion and functional impairment despite standard surgical treatments. Different conservative

treatments have been described for the treatment of nonunions, including extracorporeal shock waves [8], pulsed electromagnetic fields and low-intensity ultrasound [9]. However, these modalities are generally reserved for selected cases and show limited effectiveness in established or biologically compromised nonunions. Surgical treatment represents a valid option in cases of failed conservative management. Available surgical strategies include internal fixation, external fixation, and biological reconstruction using autologous bone grafts, such as iliac crest grafts, vascularized fibular grafts, and corticoperiosteal flaps from the medial femoral condyle [10]. Vascularized corticoperiosteal free flap from the medial femoral condyle is gaining consensus as a valid treatment given its biological properties, flexibility and low morbidity at the donor site. The peculiarity of this flap is the capacity for complete restoration (both vascular and bone) of the donor site [11]: Their effectiveness relies on the preservation of the cambium layer, which provides a rich source of osteogenic progenitor cells and promotes rapid revascularization and bone regeneration. Compared to vascularized fibular grafts, corticoperiosteal flaps offer a less invasive option with lower donor site morbidity and are particularly suitable for small to moderate bone defects without the need for structural support. Jones et al. [12] reported the use of medial femoral condyle flap to manage scaphoid [13], phalanx, metacarpal, clavicle, humerus and forearm nonunions. Corticoperiosteal graft consists of cancellous bone, periosteum and outer cortical bone; Doi and Sakai protected the vital cambium layer by elevating the periosteum along with a strip of cortex.

To the best of our knowledge, this is the first report describing the simultaneous use of bilateral corticoperiosteal free flaps to treat both radius and ulna nonunions in a single-stage procedure. In the present case, the patient had already undergone two previous surgical procedures, including initial osteosynthesis with plates and screws followed by revision osteosynthesis with autologous iliac crest bone grafting. Despite these interventions, persistent nonunions of both the radius and ulna were observed, associated with forearm pain, reduced strength, and significant limitation in range of motion.

In this complex clinical scenario, several surgical options were considered, including the use of a vascularized fibular graft with reconstruction of a single-bone forearm, a further revision with compression plating, or the use of a single corticoperiosteal flap. However, each of these options presented potential limitations, particularly in the context of a biologically compromised environment due to multiple previous surgeries.

Given the poor bone quality and the need to preserve forearm anatomy and function, we opted to maintain the existing fixation hardware in order to ensure mechanical stability, removing only the screws interfering with the nonunion sites. This strategy allowed us to avoid further destabilization while focusing on enhancing the biological environment.

The decision to use bilateral vascularized corticoperiosteal free flaps harvested from both medial femoral condyles was based on the high osteogenic potential of these grafts and their low donor site morbidity. Furthermore, the use of two independent flaps enabled targeted biological stimulation of both nonunion sites, without the need for more invasive reconstructive procedures.

At 1-year follow-up, the patient demonstrated complete clinical recovery, with full restoration of range of motion and strength, and no evidence of complications. These findings are consistent with our previous experience with corticoperiosteal flaps, which have shown reliable outcomes in the treatment of challenging nonunions.

5. Conclusions

Based on these considerations, bilateral vascularized corticoperiosteal free flaps harvested from the medial femoral condyles may represent a valuable and reliable treatment option for complex forearm nonunions, particularly in patients with multiple previous sur-

gical failures and compromised biological conditions. This technique allows simultaneous restoration of the biological environment and preservation of mechanical stability, leading to satisfactory clinical and radiological outcomes.

Author Contributions: Conceptualization, M.G.; methodology, A.P.; software, A.P.; validation, S.P.; formal analysis, S.P.; investigation, A.P.; resources, A.P.; data curation, S.P.; writing—original draft preparation, S.P.; writing—review and editing, A.P.; visualization, M.G.; supervision, M.G.; project administration, M.G.; All authors have read and agreed to the published version of the manuscript.

Funding: This research received no external funding.

Institutional Review Board Statement: Ethical review and approval were waived for this study, in accordance with Italian regulations and Regulation (EU) No 536/2014, as this work represents a retrospective single case report describing a standard-of-care surgical procedure and does not constitute a clinical trial or experimental study.

Informed Consent Statement: Written informed consent was obtained from the patient for the publication of this case report and any accompanying images.

Data Availability Statement: The data presented in this study are available on request from the corresponding author due to patient privacy and ethical restrictions.

Conflicts of Interest: The authors declare no conflict of interest.

References

1. Cáffee, H.; Gilbert, A. Vascularized transfer of the fibular shaft. *Plast. Reconstr. Surg.* **1983**, *71*, 743. [CrossRef]
2. Guzzini, M.; Lanzetti, R.M.; Perugia, D.; Lupariello, D.; Vadalà, A.; Guidi, M.; Civitenga, C.; Ferretti, A.T. The treatment of long bones nonunions of upper limb with microsurgical cortico-periosteal free flap. *Injury* **2017**, *48*, S66–S70. [CrossRef] [PubMed]
3. Iorio, M.L.; Masden, D.L.; Higgins, J.P. The limits of medial femoral condyle corticoperiosteal flaps. *J. Hand Surg. Am.* **2011**, *36*, 1592–1596. [CrossRef] [PubMed]
4. Sakai, K.; Doi, K.; Kawai, S. Free vascularized thin corticoperiosteal graft. *Plast. Reconstr. Surg.* **1991**, *87*, 290–298. [CrossRef] [PubMed]
5. Guzzini, M.; Calderaro, C.; Guidi, M.; Civitenga, C.; Ferri, G.; Ferretti, A. Treatment of a Femur Nonunion with Microsurgical Corticoperiosteal Pedicled Flap from the Medial Femoral Condyle. *Case Rep. Orthop.* **2016**, *2016*, 5125861. [CrossRef] [PubMed]
6. Doi, K.; Hattori, Y. Vascularized bone graft from the supracondylar region of the femur. *Microsurgery* **2009**, *29*, 379–384. [CrossRef] [PubMed]
7. Ciclamini, D.; Tos, P.; Guzzini, M.; Soldati, A.; Crosio, A.; Battiston, B. The medial femoral condyle free corticoperiosteal flap versus traditional bone graft for treatment of nonunions of long bones: A retrospective comparative cohort study. *Injury* **2019**, *50*, S54–S58. [CrossRef] [PubMed]
8. Biedermann, R.; Martin, A.; Handle, G.; Auckenthaler, T.; Bach, C.; Krismer, M. Extracorporeal shock waves in the treatment of nonunions. *J. Trauma Acute Care Surg.* **2003**, *54*, 936–942. [CrossRef] [PubMed]
9. Rubin, C.; Bolander, M.; Ryaby, J.P.; Hadjiargyrou, M. The use of low-intensity ultrasound to accelerate the healing of fractures. *J. Bone Jt. Surg. Am.* **2001**, *83*, 259–270. [CrossRef] [PubMed]
10. Srinivasan, R.C.; Hutson, R.L.; Richard, M.J. Forearm Nonunion: Characterization and Management. *J. Hand Surg. Am.* **2020**, *45*, 1055–1064. [CrossRef] [PubMed]
11. Guzzini, M.; Lupariello, D.; Argento, G.; Arioli, L.; Ferretti, A. Vascular and Bone Regeneration of the Donor Site After Corticoperiosteal Flap From the Medial Femoral Condyle. *Hand* **2022**, *17*, 366–372. [CrossRef] [PubMed]
12. Jones, D.B.; Rhee, P.C.; Bishop, A.T.; Bishop, A.T.; Shin, A.Y. Free vascularized medial femoral condyle autograft for challenging upper extremity nonunions. *Hand Clin.* **2012**, *28*, 493–501. [CrossRef] [PubMed]
13. Guzzini, M.; Lanzetti, R.M.; Proietti, L.; Lupariello, D.; Iorio, R.; Ferretti, A. The role of vascularized flaps in the treatment of proximal pole avascular necrosis in scaphoid non-unions. *Acta Biomed.* **2019**, *90*, 64–68. [CrossRef] [PubMed]

Disclaimer/Publisher's Note: The statements, opinions and data contained in all publications are solely those of the individual author(s) and contributor(s) and not of MDPI and/or the editor(s). MDPI and/or the editor(s) disclaim responsibility for any injury to people or property resulting from any ideas, methods, instructions or products referred to in the content.