surgeries

MDPI

Case Report

Isolated Prostatic Anterior Fat Pad Nodal Metastasis in High-Grade Anterior Prostate Cancer: A Case Report and Focused Narrative Review

Pietro Pepe [1], Ludovica Pepe [2,*], Mara Curduman [3] and Vincenzo Fiorentino [2,*]

[1] Urology Unit, Cannizzaro Hospital, Via Messina 829, 95126 Catania, Italy
[2] Department of Human Pathology in Adult and Developmental Age "Gaetano Barresi", University of Messina, Via Consolare Valeria 1, 98125 Messina, Italy
[3] Pathology Unit, Cannizzaro Hospital, Via Messina 829, 95126 Catania, Italy
* Correspondence: ludopepe97@gmail.com (L.P.); vincenzo.fiorentino@unime.it (V.F.)

Abstract

Background/Objectives: Lymph node metastasis within the prostatic anterior fat pad (PAFP) is uncommon but may refine nodal staging when pelvic lymph node dissection and PSMA PET/CT are negative. **Case Presentation:** A 58-year-old man with PSA 59 ng/mL, negative digital rectal examination, and a PI-RADS 5 anterior lesion underwent transperineal MRI/US fusion biopsy, showing an acinar adenocarcinoma (Gleason score 5 + 5 = 10, ISUP grade group 5) confined to anterior cores. 18F-PSMA-1007 PET/CT showed intense intraprostatic uptake (SUVmax 55.2) without nodal or distant disease. Retropubic radical prostatectomy, bilateral extended pelvic lymph node dissection (ePLND), and separate PAFP submission were performed. Final pathology showed a 38 mm bilateral anterior tumor involving 35% of the prostate, focal anterior extraprostatic extension, negative margins, absent seminal vesicle and bladder neck invasion, perineural and lymphovascular invasion, and no cribriform or intraductal carcinoma. All 15 pelvic nodes were negative. One of two PAFP nodes contained a 3 mm PSA-positive metastasis without extranodal extension, resulting in pT3aN1 staging. Postoperative PSA persistence prompted radiotherapy plus androgen deprivation therapy; PSA was 0.01 ng/mL at 6 months. **Conclusions:** In very-high-risk anterior prostate cancer, separate PAFP evaluation may provide clinically relevant staging information when PSMA PET/CT and pelvic lymph nodes are negative. This case highlights the PAFP as a potential site of occult regional nodal disease.

Keywords: prostate cancer; prostatic anterior fat pad; periprostatic fat; lymph node metastasis; radical prostatectomy; extended pelvic lymph node dissection; PSMA PET/CT; case report; focused narrative review

Check for updates

Academic Editor: Salomone Di Saverio

Received: 10 May 2026
Revised: 3 June 2026
Accepted: 16 June 2026
Published: 17 June 2026

Copyright: © 2026 by the authors. Licensee MDPI, Basel, Switzerland. This article is an open access article distributed under the terms and conditions of the Creative Commons Attribution (CC BY) license.

1. Introduction

Prostate cancer (PCa) is one of the most common malignancies in men and remains a major oncological burden [1]. Although screening and contemporary diagnostic pathways have increased detection of indolent tumors, a clinically relevant subset of men still presents with high-risk or metastatic disease, making accurate staging essential for treatment planning [2]. From a pathology perspective, this issue is reinforced by the imperfect concordance between biopsy grading and final radical prostatectomy findings, including Gleason score upgrading or downgrading and histopathological parameters associated with biopsy-radical prostatectomy agreement [3,4].

In this setting, prostate-specific membrane antigen positron emission tomography/computed tomography (PSMA PET/CT) has improved staging in high-risk PCa and has shown higher accuracy than conventional imaging for nodal and distant disease assessment [5–7]. Multiparametric magnetic resonance imaging (mpMRI) and magnetic resonance imaging/ultrasound (MRI/US) fusion-guided biopsy have also improved the detection of clinically significant tumors, including lesions located in the anterior gland, which may be missed by conventional posteriorly oriented sampling [8–10].

Pure anterior PCas are located anterior to the urethra and account for approximately 10% of all PCas. A substantial proportion of anterior tumors arise in the transition zone or are exclusively anterior, and aggressive anterior tumors may show adverse pathological features, including higher grade, extracapsular extension, and positive surgical margins [10]. Lymph nodes within the PAFP have been reported in radical prostatectomy specimens, and metastatic involvement, although infrequent, has been described across several cohorts [11–22].

We report a case of high-grade PCa arising predominantly in the anterior gland and associated with an isolated lymph node metastasis in the PAFP, despite negative pelvic lymph nodes and negative preoperative PSMA PET/CT for nodal disease. This case supports a risk-adapted approach in which PAFP tissue removed during anterior surgical exposure is submitted separately for pathological assessment in selected patients with very-high-risk anterior PCa.

2. Case Presentation

2.1. Diagnostic Workup and Biopsy Findings

A 58-year-old man with no palpable lesion on digital rectal examination was referred for diagnostic evaluation because of a PSA value of 59 ng/mL. The mpMRI showed a Prostate Imaging Reporting and Data System (PI-RADS) 5 lesion located in the anterior zone of the prostate [23].

The patient underwent transperineal MRI/US fusion-guided biopsy, with five targeted cores, combined with extended systematic transperineal sampling, for a total of 18 biopsy cores. Histological examination showed an acinar prostatic adenocarcinoma (Gleason score 5 + 5 = 10, International Society of Urological Pathology (ISUP) grade group 5) located exclusively in anterior cores. Overall, 5 of 18 cores were involved, all corresponding to the anterior lesion, with a maximum cancer involvement of 90% in the most affected core.

2.2. Staging, Surgical Strategy, and Pathological Processing

For staging purposes, the 18F-PSMA-1007 PET/CT was performed after intravenous administration of 4 MBq/kg of tracer, with image acquisition 120 min after injection from the skull base to the mid-thigh. The examination demonstrated intense uptake corresponding to the intraprostatic anterior lesion, with a maximum standardized uptake value (SUVmax) of 55.2, and showed no radiological evidence of pelvic lymph node or systemic metastases (Figures 1 and 2) [5–7,24–26]. Retrospective review of the available PET/CT images confirmed the absence of a discrete PSMA-avid pelvic nodal lesion and did not identify a clearly separable PAFP nodal focus adjacent to the avid anterior primary tumor.

After multidisciplinary evaluation, the patient underwent retropubic radical prostatectomy (RP) plus bilateral extended pelvic lymph node dissection (ePLND) as the first step of a planned multimodal treatment strategy. The dissection was bilateral and extended from the distal common iliac/internal iliac origin region to the node of Cloquet, including external iliac, obturator, and internal iliac nodal tissue. Nodal packets were submitted separately and yielded 15 negative pelvic lymph nodes: 6 external iliac nodes, 7 obturator nodes, and 2 internal iliac nodes. By side, the yield was 3 right and 3 left external iliac nodes, 4 right and 3 left obturator nodes, and 1 right and 1 left internal iliac node. During the retropubic

anterior approach, anterior fat overlying the prostate was removed to expose the dorsal venous complex, bladder neck, and anterior prostatic surface. Because of the very-high-risk biopsy profile and predominantly anterior tumor location, this tissue was deliberately labeled and submitted as a separate PAFP specimen rather than being incorporated into the prostate specimen or considered an extension of the pelvic lymphadenectomy template.

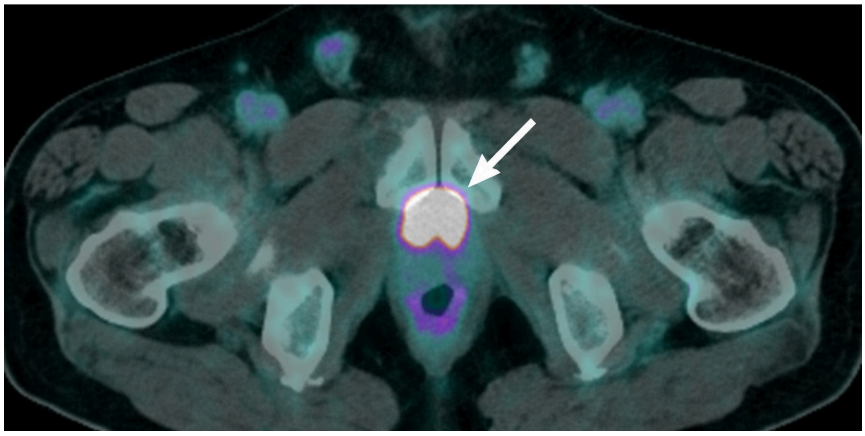

Figure 1. 18F-PSMA-1007 PET/CT demonstrating intense uptake in the anterior zone prostate cancer (arrow), with SUVmax 55.2. No discrete PAFP lymph node is distinguishable from the adjacent avid anterior primary tumor on this representative axial image.



Figure 2. 18F-PSMA-1007 PET/CT maximum-intensity projection showing anterior prostate cancer (arrow) without radiological evidence of systemic metastases.

The surgical rationale for separate PAFP labeling and pathological submission was based on the combination of very-high-risk biopsy features, exclusive anterior tumor location, high tumor volume in the sampled anterior cores, and the need for more accurate pathological staging before postoperative treatment planning. The PAFP was dissected from the prostatic apex cranially toward the bladder neck, with bilateral extension to the junction between the prostate and the endopelvic fascia.

2.3. Final Pathology and Postoperative Course

Definitive histological examination confirmed a high-grade acinar prostatic adenocarcinoma (Gleason score 5 + 5 = 10, ISUP grade group 5), located predominantly in the anterior gland and involving both lobes. The dominant anterior tumor measured 38 mm and involved 35% of the prostate. Focal extraprostatic extension was present in the anterior periprostatic tissue, most evident at the anterior mid-gland/apical region. Surgical margins were negative, seminal vesicle invasion and bladder neck invasion were absent, and the final local pathological stage was pT3a. Perineural and lymphovascular invasion were present. Cribriform architecture and intraductal carcinoma were not identified.

The most clinically relevant finding was the nodal discordance between the standard pelvic lymphadenectomy specimen and the separately submitted PAFP. All 15 pelvic lymph nodes from the external iliac, obturator, and internal iliac regions were negative. By contrast, the PAFP specimen was serially sectioned and entirely submitted for histological examination. Two lymph nodes were identified; one lymph node, measuring 4 mm, harbored metastatic acinar PCa. The maximum diameter of the metastatic deposit was 3 mm. Residual nodal architecture and lymphoid tissue supported the interpretation as an intranodal metastasis rather than a soft-tissue tumor deposit in fat. Extranodal extension was not identified. Immunohistochemistry showed PSA positivity in the metastatic cells, supporting prostatic origin. The histological correlation between the anterior primary tumor and the PAFP nodal metastasis is shown in Figure 3.

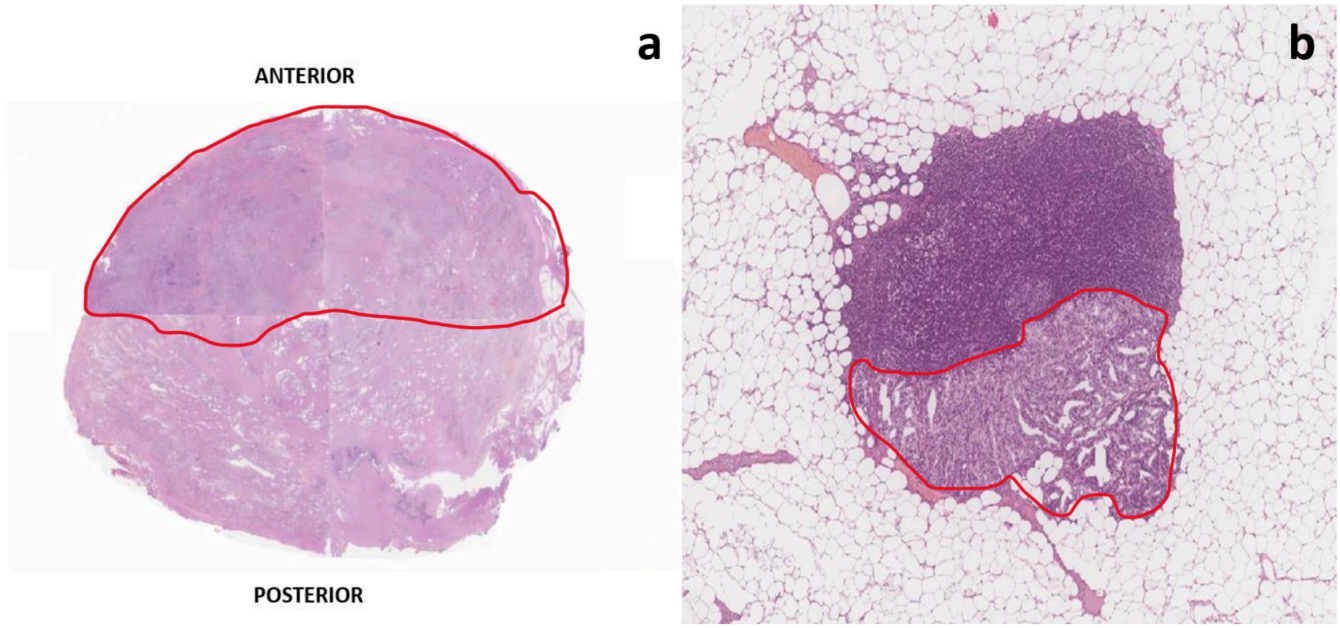

Figure 3. Histological correlation of the anterior primary tumor and the PAFP nodal metastasis. (**a**) Panoramic view of a whole-mount prostate section showing high-grade acinar prostatic adenocarcinoma arising in the anterior gland and involving both lobes (hematoxylin and eosin, ×25). The anterior neoplastic area is outlined in red. (**b**) Metastatic lymph node within the anterior periprostatic fat pad (hematoxylin and eosin, ×50). The metastatic focus is outlined in red.

Although the PAFP lies outside the conventional pelvic lymph node dissection field, the involved lymph node was interpreted as regional nodal disease rather than distant metastasis because it represented periprostatic nodal tissue within the pelvis, associated with the prostate specimen, and not common iliac, para-aortic, inguinal, or other distant nodal disease. The final pathological stage was therefore pT3aN1 according to TNM principles [27]. Without separate histological evaluation of the PAFP specimen, the patient would have been classified as node negative.

One month after surgery, PSA was 0.23 ng/mL, consistent with PSA persistence. The patient underwent postoperative radiotherapy combined with luteinizing hormone-releasing hormone (LHRH) therapy. The treatment decision was based on the overall adverse postoperative profile, including PSA persistence, very-high-risk tumor biology, pT3a disease, lymphovascular invasion, and pN1 status. Therefore, the PAFP-positive node strengthened postoperative risk stratification but should not be interpreted as the sole driver of postoperative treatment. Somatic testing for *BRCA* alterations was negative [28]. No additional exploratory immunomolecular markers, beyond diagnostic PSA immunohistochemistry on the PAFP nodal metastasis, were used to guide management in this patient, although recent literature has linked PD-L1 expression, epigenetic regulation, and cell-adhesion pathways to adverse clinicopathological features and metastatic progression in PCa [29–31]. No surgical complications were reported. After 6 months of follow-up, PSA was 0.01 ng/mL. Functional recovery was satisfactory, with one pad per day reported for urinary continence. Erectile dysfunction was managed with a vacuum erectile device combined with intracavernosal prostaglandin E1 injection.

2.4. Case Timeline

A concise chronological summary of the diagnostic, therapeutic, pathological, and follow-up milestones is provided in Table 1.

Table 1. Case timeline.

Time Point	Clinical Event	Key Findings and Management
Initial diagnostic evaluation	Referral for suspected prostate cancer	Negative digital rectal examination; PSA 59 ng/mL; mpMRI showing a PI-RADS 5 anterior lesion.
Biopsy	Transperineal MRI/US fusion-guided biopsy plus systematic sampling	Acinar adenocarcinoma, Gleason score 5 + 5 = 10, ISUP grade group 5; 5/18 cores involved, all corresponding to the anterior lesion; maximum cancer involvement 90%.
Preoperative staging	18F-PSMA-1007 PET/CT	4 MBq/kg, acquisition 120 min after injection; intense anterior intraprostatic uptake (SUVmax 55.2); no pelvic nodal or systemic metastases; retrospective review showed no separate PAFP focus.
Surgery	Radical prostatectomy, bilateral ePLND, and separate PAFP submission	Bilateral ePLND from the distal common iliac/internal iliac origin region to the node of Cloquet; 15 negative pelvic nodes (6 external iliac, 7 obturator, 2 internal iliac). PAFP tissue removed during anterior exposure was submitted separately, not as an expanded pelvic lymphadenectomy field.

Table 1. *Cont.*

Time Point	Clinical Event	Key Findings and Management
Final pathology	Pathological staging	High-grade anterior acinar adenocarcinoma, Gleason score 5 + 5 = 10, ISUP grade group 5; dominant tumor 38 mm, involving 35% of the prostate; focal anterior extraprostatic extension; negative margins; no seminal vesicle or bladder neck invasion; perineural and lymphovascular invasion present; no cribriform architecture or intraductal carcinoma; 15 pelvic nodes negative; 1/2 PAFP nodes positive, with a 3 mm PSA-positive intranodal metastasis and no extranodal extension; final stage pT3aN1.
One month after surgery	Early postoperative assessment and postoperative treatment	PSA 0.23 ng/mL, consistent with PSA persistence; postoperative radiotherapy plus LHRH therapy because of PSA persistence and adverse pathological features, including pT3a disease, lymphovascular invasion, and pN1 status.
Six months after surgery	Follow-up	PSA 0.01 ng/mL; no surgical complications; urinary continence one pad/day; erectile dysfunction managed with vacuum device and intracavernosal prostaglandin E1.

2.5. Focused Literature Review Strategy

A focused narrative literature review was performed using PubMed up to 6 May 2026. The search terms included "prostatic anterior fat pad", "anterior prostatic fat pad", "periprostatic fat pad", "prostate cancer", "lymph node", "metastasis", and "radical prostatectomy". Additional articles were identified through reference lists of relevant papers. Studies were retained for tabulation when they reported denominator-based data on PAFP lymph nodes and/or PAFP lymph node metastases in patients undergoing RP, with or without pelvic lymph node dissection. This review was intended as a focused narrative review rather than a systematic review; therefore, no PRISMA-based selection workflow, formal risk-of-bias assessment, or meta-analysis was performed. Potentially overlapping cohorts were interpreted descriptively.

3. Discussion

The present case illustrates the staging value of dedicated PAFP assessment in very-high-risk anterior PCa. Although lymph nodes and occasional metastatic involvement within the PAFP have been reported previously, their clinical relevance becomes most apparent when they represent the only documented site of nodal disease after negative PSMA PET/CT and negative bilateral ePLND. In this patient, the concurrence of a high-volume anterior Gleason score 5 + 5 tumor, focal anterior extraprostatic extension, perineural and lymphovascular invasion, 15 negative pelvic lymph nodes, and a small PSA-positive intranodal PAFP metastasis without extranodal extension provides a well-documented example of occult regional nodal disease outside the conventional pelvic dissection field. These findings support a risk-adapted approach in which PAFP tissue removed during anterior surgical exposure is submitted separately for pathological assessment in selected patients with very-high-risk anterior PCa.

Anterior tumors are more likely to be missed at initial biopsy when sampling does not adequately cover the anterior gland. They are also less likely to be palpable on digital rectal examination and may show apparently lower disease volume when assessed by conventional posteriorly oriented sampling strategies [8–10]. Nevertheless, aggressive anterior PCa is well documented, and anterior location does not imply indolent biology [11]. In this case, the combination of a negative digital rectal examination, very high PSA, PI-RADS 5 anterior lesion, and a Gleason score 5 + 5 = 10 emphasized the need for both accurate local diagnosis and careful nodal staging.

The available literature suggests that lymph nodes are identified in the PAFP in a minority of RP specimens, with reported frequencies ranging from approximately 5% to 17% in denominator-based series. Metastatic involvement is less frequent, generally ranging from 0% to 3.8% of patients or assessed specimens, but it may be clinically relevant whenever it leads to nodal upstaging [11–22]. Table 2 summarizes denominator-based rates from the main studies reporting PAFP lymph nodes and metastatic involvement, with the specific denominator clarified when it differs from the total RP cohort.

Table 2. Denominator-based frequency of PAFP lymph node identification and PAFP nodal metastasis in radical prostatectomy series.

Author	Study Denominator, N	Cases/Specimens with PAFP Lymph Nodes, n/N (%)	Cases/Specimens with PAFP Nodal Metastasis, n/N (%)
Hansen et al. [11]	356	19/356 (5.3%)	4/356 (1.1%)
Yuh et al. [12]	120	20/120 (16.7%)	3/120 (2.5%)
Zhao et al. [13]	287	23/287 (8.0%)	11/287 (3.8%)
Ozkan et al. [14]	100	9/100 (9.0%)	0/100 (0%)
Yu et al. [15]	4028	295/4028 (7.3%)	70/4028 (1.74%)
Hu et al. [16]	255	19/255 (7.45%)	3/255 (1.18%)
Weng et al. [17]	849	76/849 (9.0%)	11/849 (1.3%)
Shimizu et al. [18]	215	20/215 (9.3%)	2/215 (0.9%)
Kim et al. [19]	4261	NR	40/4261 (0.94%)
Jeong et al. [20]	258	30/258 (11.6%)	3/258 (1.16%)
Hosny et al. [21]	629	46/629 (7.3%)	2/629 (0.3%)
Guy et al. [22]	358 assessed (657 RP)	38/358 (10.6%)	1/358 (0.3%)

NR: not reported; PAFP: prostatic anterior fat pad; RP: radical prostatectomy. Values are n/N (%) and refer to patients or specimens with at least one PAFP lymph node or at least one PAFP nodal metastasis, not to total lymph node counts. Unless otherwise specified, N refers to patients or RP specimens assessed for PAFP lymph nodes. For Guy et al., only 358 of 657 robot-assisted RP patients had anterior fat samples reviewed; therefore, rates are reported using the specimen denominator.

The interpretation of these data should be cautious. The absolute incidence of PAFP metastasis is low, and the available studies differ in surgical approach, pathological processing, pelvic lymph node dissection extent, risk distribution, and whether the PAFP was routinely submitted for histology. Consequently, the literature does not justify the indiscriminate expansion of the lymphadenectomy concept for every patient undergoing RP. However, the data support selective PAFP removal or, more precisely, selective separate labeling and pathological submission of PAFP tissue in men with high-risk features, particularly when tumors are high-grade, high-volume, and predominantly anterior [16,17,19].

A further relevant point is the interaction between imaging and pathology. PSMA PET/CT is highly valuable in the staging of high-risk PCa [5–7,24–26], but the present case shows that a small nodal metastasis may remain radiologically occult when it is immediately adjacent to a strongly avid anterior primary lesion. In this patient, retrospective review confirmed intense anterior intraprostatic uptake but did not identify a discrete PSMA-avid PAFP nodal focus separable from the primary tumor. The 3 mm intranodal metastasis may

therefore have been below the effective spatial resolution of PET/CT or obscured by the adjacent highly avid anterior tumor.

The oncological meaning of PAFP metastasis is still evolving. Large multi-institutional outcome data suggest that PAFP lymph node metastasis identifies biologically aggressive disease and may function as an anatomically distinct nodal landing zone, with recurrence outcomes broadly comparable to those observed in pelvic nodal involvement when managed with appropriate multimodal therapy [32]. The present case is consistent with this concept, but cannot prove an oncological benefit from PAFP assessment.

The surgical and pathological implication is practical and should be stated narrowly. The PAFP should not be considered automatically equivalent to an additional pelvic lymphadenectomy field. It is tissue encountered during anterior exposure of the prostate and may be removed, at least in part, to improve visualization of the dorsal venous complex, bladder neck, and anterior prostatic surface. In selected very-high-risk anterior tumors, separate orientation, labeling, and pathological submission of that tissue may allow the pathologist to identify lymph nodes that would otherwise be overlooked or incorporated into the prostate specimen without specific nodal assessment.

From a surgical standpoint, this distinction is important. PAFP management differs from widening the pelvic lymph node dissection field. The key issue is not routine enlargement of ePLND, but communication between the surgeon and pathologist when PAFP tissue is removed during anterior exposure. If submitted separately, the specimen can be handled as a dedicated staging specimen; if not, small lymph nodes may be missed or interpreted only as nonspecific periprostatic fibroadipose tissue.

The most reasonable selection criteria are not yet standardized, but the present case suggests practical triggers for considering separate PAFP submission. These include a predominantly anterior or exclusively anterior lesion, a high PSA value, PI-RADS 5 imaging, ISUP grade group 4 or 5 disease on biopsy, high cancer involvement in targeted anterior cores, and a planned multimodal strategy in which refined nodal staging may influence postoperative risk discussion. In this setting, the potential staging benefit appears greater than in low-volume or favorable intermediate-risk tumors, where the probability of clinically meaningful PAFP involvement is expected to be very low.

The pathological workflow is equally important. PAFP specimens are often composed mainly of fibroadipose tissue, and lymph nodes may be small, fragmented, or grossly inconspicuous. When PAFP assessment is requested, the specimen should therefore be handled as a dedicated nodal staging specimen rather than as redundant periprostatic tissue. Complete embedding, when feasible, or careful macroscopic search for nodal tissue may increase the likelihood of detecting small metastatic deposits. This point is particularly relevant because a single involved node, as in the present patient, may be sufficient to change pathological nodal status.

The finding also has multidisciplinary consequences, but these should not be overstated. In the present patient, postoperative treatment would have been considered even without the PAFP-positive node because of persistent postoperative PSA (0.23 ng/mL at one month), high PSA at presentation (59 ng/mL), Gleason score 5 + 5 = 10, pT3a disease, and lymphovascular invasion. The PAFP metastasis nevertheless provided additional pN1 staging information and strengthened the rationale for postoperative multimodal treatment. This distinction is important because a single case cannot establish a management-changing indication for routine PAFP dissection.

Finally, this case is relevant for the modern imaging era. The availability of PSMA PET/CT has substantially improved preoperative staging, but imaging and histology answer different questions. PSMA PET/CT can identify clinically suspicious disease before treatment, whereas microscopic pathological assessment can detect small nodal

metastases below the spatial resolution of imaging or hidden by the intense signal of an adjacent primary tumor. The practical message is therefore not that PSMA PET/CT is insufficient, but that negative imaging should not preclude targeted pathological scrutiny when anatomical location and biopsy phenotype indicate a high risk of occult nodal disease.

This report has limitations. It describes a single patient, and therefore no generalized recommendation can be made. Follow-up is short, and longer observation is required to assess oncological outcome. In addition, the imaging review was retrospective and not a prospective blinded central imaging review, so the negative PAFP imaging finding should be interpreted descriptively. Although the available records allowed detailed clinicopathological and imaging correlation, this remains a single case and cannot establish whether separate PAFP submission improves oncological outcomes. Its value is mainly educational and staging-related, because it documents a rare isolated PAFP nodal metastasis in a very-high-risk anterior prostate cancer and supports a selective, risk-adapted approach to PAFP assessment. Its main value is not to propose routine PAFP dissection for all RP patients, but to emphasize a rational, risk-adapted approach to separate PAFP labeling and pathological examination in aggressive anterior PCa.

4. Conclusions

In selected men with aggressive, high-volume anterior PCa, separate pathological evaluation of PAFP tissue may refine regional nodal staging when preoperative imaging and standard pelvic lymph node dissection are negative. This case supports considering PAFP assessment only in carefully selected high-risk anterior tumors, particularly when tissue is already removed during anterior exposure and when refined nodal staging may influence postoperative risk discussion. It does not prove oncological benefit and does not establish a routine indication for PAFP dissection.

Author Contributions: Conceptualization, P.P. and V.F.; methodology, P.P., L.P., V.F. and M.C.; investigation, P.P., L.P., V.F. and M.C.; resources, P.P. and M.C.; data curation, P.P., L.P., V.F. and M.C.; writing—original draft preparation, P.P. and V.F.; writing—review and editing, P.P., L.P., V.F. and M.C.; visualization, L.P., V.F. and M.C.; supervision, P.P. and V.F. All authors have read and agreed to the published version of the manuscript.

Funding: This research received no external funding.

Institutional Review Board Statement: Ethical review and approval were waived for this study because it is a single-patient case report based exclusively on routine diagnostic and therapeutic procedures, with no experimental intervention performed for research purposes, in accordance with local institutional policy. The study was conducted in accordance with the Declaration of Helsinki.

Informed Consent Statement: Written informed consent has been obtained from the patient to publish this paper.

Data Availability Statement: The data presented in this case report are contained within the article. Additional de-identified clinical information may be available from the corresponding authors upon reasonable request, subject to privacy and ethical restrictions.

Conflicts of Interest: The authors declare no conflicts of interest.

Abbreviations

ISUP, International Society of Urological Pathology; LHRH, luteinizing hormone-releasing hormone; mpMRI, multiparametric magnetic resonance imaging; MRI/US, magnetic resonance imaging/ultrasound; NR, not reported; PAFP, prostatic anterior fat pad; PCa, prostate cancer; PET/CT, positron emission tomography/computed tomography; PI-RADS, Prostate Imaging Reporting and

Data System; PSA, prostate-specific antigen; PSMA, prostate-specific membrane antigen; RP, radical prostatectomy; SUVmax, maximum standardized uptake value.

References

1. Kratzer, T.B.; Mazzitelli, N.; Star, J.; Dahut, W.L.; Jemal, A.; Siegel, R.L. Prostate cancer statistics, 2025. *CA Cancer J. Clin.* **2025**, *75*, 485–497. [CrossRef] [PubMed]
2. de Vos, I.I.; Rosenstand, C.; Hogenhout, R.; van den Bergh, R.C.N.; Remmers, S.; Roobol, M.J.; ERSPC Rotterdam Study Group. Reducing overtreatment of prostate cancer patients: Revisiting the European Association of Urology pretreatment risk group classification using long-term follow-up data from the European Randomized Study of Screening for Prostate Cancer Rotterdam. *Eur. Urol. Oncol.* **2025**, *8*, 747–754. [CrossRef] [PubMed]
3. Fiorentino, V.; Pepe, L.; Zuccalà, V.; Pizzimenti, C.; Ieni, A.; Martini, M.; Curduman, M.; Pepe, P. Gleason score down and upgrading at radical prostatectomy in targeted vs. systematic prostate biopsy: Findings from an institutional cohort. *Pathol. Res. Pract.* **2025**, *271*, 156040. [CrossRef] [PubMed]
4. Fiorentino, V.; Martini, M.; Dell'Aquila, M.; Musarra, T.; Orticelli, E.; Larocca, L.M.; Rossi, E.; Totaro, A.; Pinto, F.; Lenci, N.; et al. Histopathological ratios to predict Gleason score agreement between biopsy and radical prostatectomy. *Diagnostics* **2021**, *11*, 10. [CrossRef] [PubMed]
5. Herrmann, K.; Walz, J.; MacLennan, S.; Briganti, A.; Cornford, P.; Czernin, J.; Eiber, M.; Fanti, S.; Fendler, W.P.; Fizazi, K.; et al. SPARC: The Standardised Prostate-specific Membrane Antigen Positron Emission Tomography/Computed Tomography Analysis and Reporting Consensus: A Delphi Analysis. *Eur. Urol.* **2026**, *89*, 260–274. [CrossRef] [PubMed]
6. Mazzone, E.; Cannoletta, D.; Quarta, L.; Chen, D.C.; Thomson, A.; Barletta, F.; Stabile, A.; Moon, D.; Eapen, R.; Lawrentschuk, N.; et al. A comprehensive systematic review and meta-analysis of the role of prostate-specific membrane antigen positron emission tomography for prostate cancer diagnosis and primary staging before definitive treatment. *Eur. Urol.* **2025**, *87*, 654–671. [CrossRef] [PubMed]
7. Pepe, P.; Pepe, L.; Cignoli, D.; Roscigno, M. PSMA PET/CT in the diagnosis of prostate cancer: Why and when? *Arch. Ital. Urol. Androl.* **2025**, *97*, 13746. [CrossRef] [PubMed]
8. Pepe, P.; Pepe, L.; Fiorentino, V.; Curduman, M.; Fraggetta, F. Multiparametric MRI targeted prostate biopsy: When omit systematic biopsy? *Arch. Ital. Urol. Androl.* **2024**, *96*, 12992. [CrossRef] [PubMed]
9. Pepe, P.; Pepe, L.; Panella, P.; Pennisi, M. Can multiparametric ultrasound improve cognitive MRI/TRUS fusion prostate biopsy? *Arch. Ital. Urol. Androl.* **2020**, *92*, 89–92. [CrossRef] [PubMed]
10. Samaratunga, H.; Egevad, L.; Yaxley, J.W.; Johannsen, S.; Le Fevre, I.K.; Perry-Keene, J.L.; Gianduzzo, T.; Chabert, C.; Coughlin, G.; Parkinson, R.; et al. Clinicopathologic significance of anterior prostate cancer: Comparison with posterior prostate cancer in the era of multiparametric magnetic resonance imaging. *Am. J. Surg. Pathol.* **2023**, *47*, 701–708. [CrossRef] [PubMed]
11. Hansen, J.; Budäus, L.; Spethmann, J.; Schlomm, T.; Salomon, G.; Rink, M.; Haese, A.; Steuber, T.; Heinzer, H.; Huland, H.; et al. Assessment of rates of lymph nodes and lymph node metastases in periprostatic fat pads in a consecutive cohort treated with retropubic radical prostatectomy. *Urology* **2012**, *80*, 877–882. [CrossRef] [PubMed]
12. Yuh, B.; Wu, H.; Ruel, N.; Wilson, T. Analysis of regional lymph nodes in periprostatic fat following robot-assisted radical prostatectomy. *BJU Int.* **2012**, *109*, 603–607. [CrossRef] [PubMed]
13. Zhao, D.W.; Zhou, Z.H.; Zhao, J.L.; Chen, D.; Yang, Z.Y.; Wang, J.; Long, X.B.; Zhang, Y.J.; Yang, P.; Cao, Y.; et al. Landscape and metastases of the lymph nodes in prostatic anterior fat pad at radical prostatectomy. *Zhonghua Wai Ke Za Zhi* **2022**, *60*, 999–1003. [CrossRef] [PubMed]
14. Ozkan, B.; Tunc, B.; Coskuner, E.R.; Saglican, Y.; Yalçın, V. Role of anterior prostatic fat pad dissection for extended lymphadenectomy in prostate cancer: A non-randomized study of 100 patients. *Int. Urol. Nephrol.* **2015**, *47*, 959–964. [CrossRef] [PubMed]
15. Yu, B.; Zhou, X.; Bian, F.; Yan, F.; Franz, F. Long-term outcomes of prostate cancer patients with metastases in the anterior fat pad and pelvic lymph nodes: Nodal upstaging without worse long-term outcomes. *Hum. Pathol.* **2026**, *170*, 106033. [CrossRef] [PubMed]
16. Hu, M.; Liao, J.; Cai, W.; Ling, H.; Wu, D.; Xu, X.; Zhu, Q.; Ye, L. Presence of lymph nodes and metastasis within prostatic anterior fat pad in radical prostatectomy patients: A single Chinese institution experience and literature review. *Eur. J. Surg. Oncol.* **2023**, *49*, 107112. [CrossRef] [PubMed]
17. Weng, W.C.; Huang, L.H.; Hsu, C.Y.; Tung, M.-C.; Yang, C.-K.; Jin, J.-S.; Ou, Y.-C.; Yang, S.-F. Impact of prostatic anterior fat pads with lymph node staging in prostate cancer. *J. Cancer* **2018**, *9*, 3361–3365. [CrossRef] [PubMed]
18. Shimizu, Y.; Ogawa, K.; Kida, K.; Tsuchihashi, K.; Kanamaru, S.; Ishihara, M.; Hashimoto, K.; Ito, N. Lymph node metastasis to the prostatic anterior fat pad in the patients treated with prostatectomy. *Hinyokika Kiyo* **2018**, *64*, 359–363. [CrossRef] [PubMed]

19. Kim, I.Y.; Modi, P.K.; Sadimin, E.; Ha, Y.-S.; Kim, J.H.; Skarecky, D.; Cha, D.Y.; Wambi, C.O.; Ou, Y.-C.; Yuh, B.; et al. Detailed analysis of patients with metastasis to the prostatic anterior fat pad lymph nodes: A multi-institutional study. *J. Urol.* **2013**, *190*, 527–534. [CrossRef] [PubMed]
20. Jeong, J.; Choi, E.Y.; Kang, D.I.; Ercolani, M.; Lee, D.H.; Kim, W.-J.; Kim, I.Y. Pathologic implications of prostatic anterior fat pad. *Urol. Oncol.* **2013**, *31*, 63–67. [CrossRef] [PubMed]
21. Hosny, M.; Rai, B.; Aljaafari, F.; Agarwal, S.; McNicholas, T.; Boustead, G.; Lane, T.; Adshead, J.; Vasdev, N. Can anterior prostatic fat harbor prostate cancer metastasis? A prospective cohort study. *Curr. Urol.* **2017**, *10*, 182–185. [CrossRef] [PubMed]
22. Guy, A.M.; Kavanagh, L.E.; Hart, E.; Haagsma, B.; Perry, M.J.A. Anterior prostate fat resection during prostatectomy: A histopathologic review. *J. Robot. Surg.* **2021**, *15*, 769–772. [CrossRef] [PubMed]
23. Turkbey, B.; Rosenkrantz, A.B.; Haider, M.A.; Padhani, A.R.; Villeirs, G.; Macura, K.J.; Tempany, C.M.; Choyke, P.L.; Cornud, F.; Margolis, D.J.; et al. Prostate Imaging Reporting and Data System Version 2.1: 2019 update of Prostate Imaging Reporting and Data System Version 2. *Eur. Urol.* **2019**, *76*, 340–351. [CrossRef] [PubMed]
24. Pepe, P.; Pepe, L.; Fiorentino, V.; Curduman, M.; Pennisi, M.; Fraggetta, F. PSMA PET/CT accuracy in diagnosing prostate cancer nodes metastases. *In Vivo* **2024**, *38*, 2880–2885. [CrossRef] [PubMed]
25. Tamburo, M.; Buffettino, E.; Pepe, P.; Marletta, G.; Pepe, L.; Cosentino, S.; Ippolito, M.; Pennisi, M.; Marletta, F. Salvage radiotherapy PSMA PET/CT-guided in men with PSA recurrence. *Anticancer Res.* **2024**, *44*, 2205–2210. [CrossRef] [PubMed]
26. Pepe, P.; Pepe, L.; Tamburo, M.; Marletta, G.; Savoca, F.; Pennisi, M.; Fraggetta, F. 68Ga-PSMA PET/CT evaluation in men enrolled in prostate cancer active surveillance. *Arch. Ital. Urol. Androl.* **2023**, *95*, 11322. [CrossRef] [PubMed]
27. Amin, M.B.; Edge, S.B.; Greene, F.L.; Byrd, D.R.; Brookland, R.K.; Washington, M.K.; Gershenwald, J.E.; Compton, C.C.; Hess, K.R.; Sullivan, D.C. (Eds.) *AJCC Cancer Staging Manual*, 8th ed.; Springer: Cham, Switzerland, 2017.
28. Vatrano, S.; Pepe, P.; Pepe, L.; Vella, N.; Alario, C.; Chiarandà, A.; Taranto, C.; Scillieri, R.; Mauceri, C.; Fraggetta, F. BRCA mutations and prostate cancer: Should urologist improve daily clinical practice? *Arch. Ital. Urol. Androl.* **2025**, *97*, 13635. [CrossRef] [PubMed]
29. Fiorentino, V.; Pepe, L.; Pizzimenti, C.; Zuccalà, V.; Pepe, P.; Cianci, V.; Mondello, C.; Tuccari, G.; Fadda, G.; Giuffrè, G.; et al. PD-L1 expression in prostate cancer and Gleason Grade Group: Is there any relationship? Findings from a multi-institutional cohort. *Pathol. Res. Pract.* **2025**, *269*, 155916. [CrossRef] [PubMed]
30. Fiorentino, V.; Germanà, E.; Ricciardi, G.; Capodimonti, S.; Cenci, T.; Orlandi, A.; Zuccalà, V.; Guida, E.; Ficarra, V.; Pizzimenti, C.; et al. SPOP and MMR/MSI alterations in prostate cancer: Relationship with PD-L1, TILs and AR expression. *Pathologica* **2025**, *117*, 338–347. [CrossRef] [PubMed]
31. Pecci, V.; Troisi, F.; Aiello, A.; De Martino, S.; Carlino, A.; Fiorentino, V.; Ripoli, C.; Rotili, D.; Pierconti, F.; Martini, M.; et al. Targeting of H19/cell adhesion molecules circuitry by GSK-J4 epidrug inhibits metastatic progression in prostate cancer. *Cancer Cell Int.* **2024**, *24*, 56. [CrossRef] [PubMed]
32. Kwon, Y.S.; Ha, Y.S.; Modi, P.K.; Salmasi, A.; Parihar, J.S.; Patel, N.; Faiena, I.; May, M.; Lee, D.I.; Llukani, E.; et al. Oncologic outcomes in men with metastasis to the prostatic anterior fat pad lymph nodes: A multi-institution international study. *BMC Urol.* **2015**, *15*, 79. [CrossRef] [PubMed]

Disclaimer/Publisher's Note: The statements, opinions and data contained in all publications are solely those of the individual author(s) and contributor(s) and not of MDPI and/or the editor(s). MDPI and/or the editor(s) disclaim responsibility for any injury to people or property resulting from any ideas, methods, instructions or products referred to in the content.