surgeries

Case Report

Total Reconstruction of the Donor Site After Toe-to-Thumb Transfer: Introducing a Novel Technique

Pierfrancesco Pugliese *, Serafina Pepe, Mara Franza and Adriana Cordova

Plastic and Reconstructive Surgery Unit, Department of Precision Medicine in Medical, Surgical and Critical Care, University of Palermo, Via del Vespro 129, 90127 Palermo, Italy
* Correspondence: p.pugliese@villasofia.it

Abstract

Traumatic thumb loss causes severe functional impairment, as the thumb provides approximately 40% of total hand function. Toe-to-thumb transfer remains the gold standard for thumb reconstruction, yet donor site morbidity represents a significant functional and aesthetic limitation. A total thumb reconstruction using a "trimmed" right great toe transfer, combined with immediate donor site reconstruction using a free SCIP (superficial circumflex iliac perforator) flap and iliac crest bone graft. The flap was designed as a tubular skin island to create a neo-hallux with optimal contour and volume, minimizing visible scarring and avoiding microcirculatory compression. The patient, a 33-year-old man with post-traumatic thumb avulsion, underwent delayed reconstruction three months after injury. The postoperative course was uneventful, with no vascular or wound complications. At 12 months, he resumed full ambulation and manual activities, including motorcycle driving and work tasks. Baropodometric analysis demonstrated symmetric load distribution and gait dynamics. Thumb opposition was satisfactory (Kapandji score: seven); the patient rated the aesthetic results as excellent. This case demonstrates that SCIP flap reconstruction with iliac crest bone graft enables complete functional and aesthetic restoration of the great toe donor site after total toe transfer. Compared to previous techniques using cross-flaps, skin grafts, or peroneal flaps, this approach minimizes morbidity, optimizes cosmetic outcomes, and preserves gait. Although representing a single case, this constitutes the first documented instance of total hallux reconstruction following toe-to-thumb transfer, emphasizing the importance of the foot as a functional and aesthetic unit and the need for donor-site preservation in microsurgical reconstructive planning.

Keywords: toe-to-thumb transfer; SCIP flap; hallux reconstruction; donor site morbidity; microsurgery; iliac crest graft

Check for updates

Academic Editor: Francesco De Francesco

Received: 15 March 2026
Revised: 26 April 2026
Accepted: 6 May 2026
Published: 8 May 2026

Copyright: © 2026 by the authors. Licensee MDPI, Basel, Switzerland. This article is an open access article distributed under the terms and conditions of the Creative Commons Attribution (CC BY) license.

1. Introduction

Traumatic thumb loss results in significant functional impairment, as the first digit contributes approximately 40% of total hand function [1]. These injuries occur predominantly in working-age men and are most frequently caused by machinery-related accidents. Compared to the absence of reconstruction, any reconstructive procedure provides a clear functional benefit. Several techniques have been proposed to address such deficits, each with specific advantages and limitations that make them more or less suitable depending on individual circumstances.

Thumb reconstruction may also be required in non-traumatic cases such as congenital anomalies or oncological amputations. The main goals of thumb reconstruction are to

obtain a sensate, stable, and functional digit with an adequate first web space, capable of opposition and grasp. Furthermore, reconstruction should minimize donor-site morbidity while providing satisfactory aesthetic results. Lister classified thumb defects into four groups [2]: (1) acceptable length but poor soft-tissue coverage, (2) subtotal amputation with doubtful residual length, (3) total amputation with preservation of the basal joint, and (4) total amputation with loss of the basal joint.

For group three defects, transfer of the great toe or the second toe represents a valid reconstructive option. The latter is associated with reduced donor-site morbidity while still providing functional outcomes comparable to great toe transfer. The second toe [3] is not essential for ambulation and allows harvest of the entire metatarsophalangeal joint to reconstruct the metacarpophalangeal joint. Limitations include reduced strength of the reconstructed digit, less satisfactory aesthetics due to a shorter nail, and a tendency toward claw deformity, which may be corrected secondarily.

Toe transfer therefore remains a reliable option. Although immediate transfers have been reported with comparable outcomes, the procedure is most often performed in a delayed fashion [4], allowing the patient to fully understand the severity of the injury, make an informed decision, and adequately plan surgery before using a critical donor site.

The great toe flap is an innervated onycho-osteocutaneous flap based on the dorsal or plantar metatarsal artery, harvested together with the dorsal venous network and the deep peroneal and digital nerves. This method provides a sensate, robust, stable, and mobile tissue of good aesthetic quality, with adjustable length and position. However, the procedure is lengthy, technically demanding and entails the loss of a significant portion of the donor site. The two major challenges are the 20% size discrepancy between the thumb and great toe, and the potential morbidity of the donor site.

To address the first issue, various alternatives have been proposed. Wei et al. [5] described the Trimmed Toe Transfer, which involves a longitudinal osteotomy to reduce bony and soft-tissue bulk, creating a slimmer reconstructed thumb. This technique, developed in response to aesthetic concerns about excessive thumb size, provides good stability and pinch strength, though with somewhat reduced joint motion compared with complete great toe transfer.

The Wraparound Toe Transfer, first described by Morrison et al. [6], utilizes the pulp and nail of the great toe along with a segment of the distal phalanx, combined with an iliac crest bone graft. This approach is particularly advantageous in patients with high functional demands or significant aesthetic concerns, as it preserves most of the great toe and provides greater flexibility of transferred tissues. It yields favorable aesthetic results at both donor and recipient sites but is limited by possible graft resorption and the absence of a transferred joint. It is therefore most suitable for distal injuries with preserved skeletal elements or for aesthetic reconstructions.

In cases where toe harvest is contraindicated or unacceptable, alternatives such as metacarpal lengthening or pollicization may be considered.

As mentioned, the second major issue with toe transfer is donor-site morbidity. Although overall functional results and patient satisfaction are good, the literature reports a morbidity rate of approximately 20.2% [7]. This is due to the important biomechanical role of the great toe in weight-bearing and gait. Several studies [8,9] have shown that about 40% of body weight is supported by the great toe during ambulation. Normally, load distribution proceeds from the heel to the lateral border of the foot, then medially across the metatarsal heads to the toes. During the push-off phase, the metatarsal heads and great toe share the load, contributing to propulsion and medial stability of the foot. Adernoqlu et al. [10] demonstrated that great toe removal alters plantar pressure distribution. Therefore, following great toe transfer, changes in gait dynamics are expected due to

the abrupt alteration in anatomy and load distribution [11]. Patients may adapt over time, but such changes can increase the risk of ulceration, callosity, pain, and delayed healing.

Restoration of the integrity of the first toe is therefore not only an aesthetic goal but also a functional necessity. Although toe-to-hand transfer remains a valuable reconstructive option for thumb loss, donor-site morbidity continues to be a significant challenge. The present study reviews various techniques for donor-site reconstruction and introduces a new method for total great toe reconstruction.

2. Case Report and Surgical Technique

A 33-year-old man was admitted to the emergency department following a road traffic accident resulting in a traumatic avulsion of the right thumb at the base of the proximal phalanx (P1), with disruption of the neurovascular bundles and flexor pollicis longus tendon up to the musculotendinous junction. Due to the poor condition of the amputated segment and the patient's overall status, replantation was not attempted. Prior to surgery, the patient underwent a physiotherapy protocol focused on optimization of the residual first ray and preparation of the hand for reconstruction. This phase included: Management of pre-existing scar tissue through scar mobilization techniques, soft-tissue massage, and, when indicated, silicone or pressure therapy to improve pliability and reduce adhesions. Active range-of-motion exercises of the long fingers, emphasizing full flexion and extension, interphalangeal joint mobilization, and intrinsic muscle strengthening to maintain hand function and prevent stiffness. Sensory and proprioceptive re-education of the residual first ray, including recognition tasks and integration into coordinated hand movements, to promote cortical representation and functional use of the remaining thumb segment. This preparatory phase aimed to restore soft-tissue mobility, preserve grip and dexterity of the uninjured structures, and enhance the patient's awareness and control of the residual first ray before surgical reconstruction.

Three months later, the patient underwent digital transfer from the right great toe to the thumb (Figure 1a,b). Reconstruction was performed using a trimmed toe transfer with plantar predominance, including neurorrhaphy of the collateral nerves and osteosynthesis at the base of P1, preserving the integrity of the metacarpophalangeal joint (Figure 2).

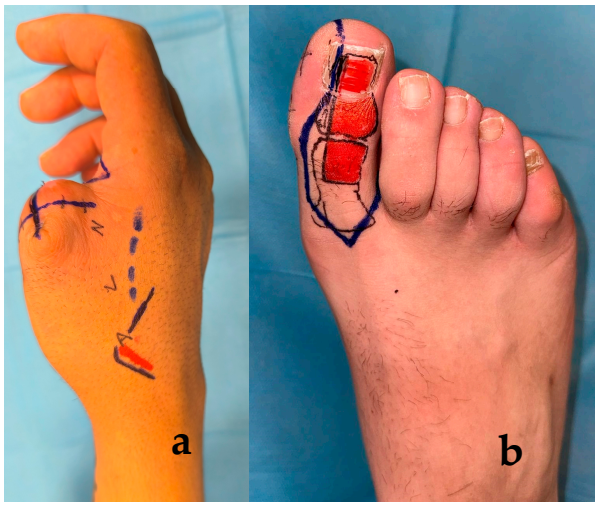

Figure 1. (**a**,**b**) Preoperative planning.

Immediate reconstruction of the flexor pollicis longus was deferred for a potential secondary tendon transfer. Simultaneously, the right great toe was reconstructed using a left SCIP (superficial circumflex iliac perforator) flap combined with a 3 × 1 cm iliac crest bone graft harvested from the left side. The bone graft was fixed to the residual base of P1

of the great toe using a Kirschner wire. Following osteosynthesis, the graft was contoured using piezo surgery to complement the surface geometry of the proximal phalanx stump.



Figure 2. Harvest of neo-thumb.

The SCIP flap was tubularized before pedicle division to verify vascular reliability and was shaped into a neo-toe based on the dimensions of the contralateral first toe (Figure 3). It was inset over the iliac crest graft (neo-phalanx) using the Kirschner wire as a guide and revascularized by anastomosis to the vessels previously divided during toe harvest (Figures 4 and 5). The SCIP donor site was closed primarily over a drain, without the need for a local flap or skin graft. Postoperatively, no major or minor complications occurred at any surgical site. The patient did not experience significant postoperative pain, which was adequately controlled with paracetamol. Clinical and radiological follow-up was regular (Figures 6a,b and 7a,b), with removal of Kirschner wires from both hand and foot at 45 days and full weight-bearing allowed at 60 days. Active mobilization of the free fingers was started immediately after surgery. Ten days later, a custom splint was applied to position the reconstructed thumb and to centralize the pinch grip within the motor pattern, facilitating proper pinch development. At three weeks post-op, scar management was introduced, including scar mobilization and soft-tissue techniques, combined with active mobilization of the thumb metacarpophalangeal (TM) joint to further stimulate pinch grip. Abduction, adduction, and opposition were guided with K-wires in place, using gentle active-assisted exercises to maintain joint mobility while protecting the fixation. The splint was downsized, leaving the wrist free while retaining night splinting and daytime splinting only to maintain the thumb in a functional position. After K-wire removal, a neoprene "strap" splint was fabricated for the thumb, providing joint stability, slight elastic resistance during movement, and compression of the scar in the first web space. For the donor hallux, a neoprene cap was applied at night to control edema and support scar maturation. This second phase of the rehabilitation protocol emphasizes early functional use, progressive strengthening, edema and scar control, and the integration of the reconstructed thumb into daily and occupational tasks. After three months, once scar maturation and edema reduction were achieved, a secondary procedure under local anesthesia was performed to widen the first web space of the hand and reduce the circumference and apical redundancy of the neo-toe. Twenty days later, the patient resumed unrestricted ambulation, wearing a neoprene anti-edema sleeve over the reconstructed toe and a hand splint to maintain web space width.



Figure 3. Tubularization of the neo-toe.



Figure 4. Neo-toe bony framework reconstruction with iliac crest graft.



Figure 5. Immediate post-operative picture.

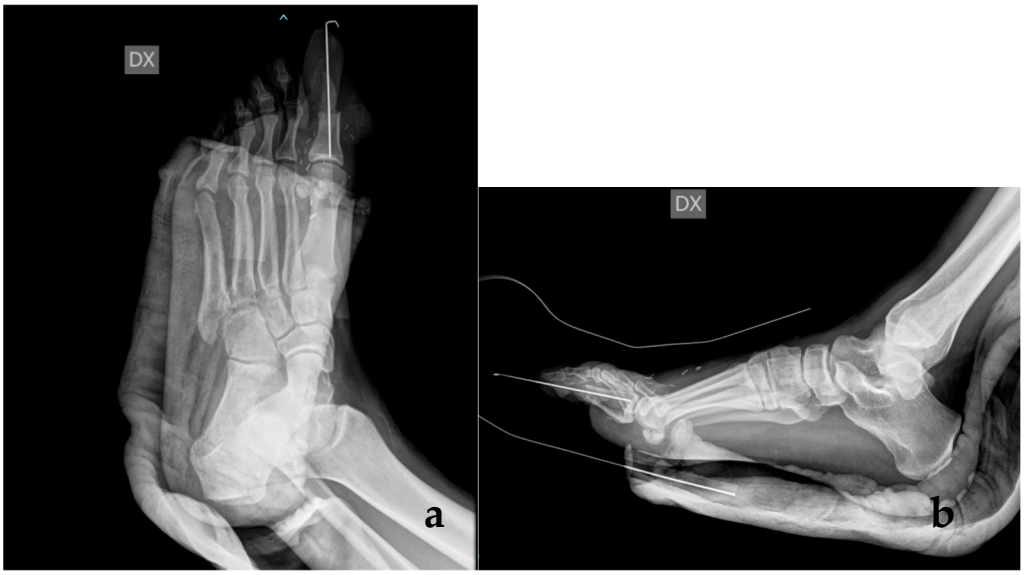

Figure 6. (**a**,**b**) Immediate post-op X-ray.



Figure 7. (**a**,**b**) Follow-up X-ray.

3. Results

Functionally, the patient resumed normal daily activities, including motorcycle riding and manual work. Thumb opposition was satisfactory, with a Kapandji score of seven, despite the absence of tendon transfer for flexion of the distal phalanx; flexion was achieved mainly through the flexor pollicis brevis (Figure 8a,b).

The neo-toe flap showed no vascular compromise or cutaneous breakdown from ambulation, except for mild plantar hyperpigmentation along the surgical scar. The bone callus between the iliac crest graft and the residual phalanx was stable. At 12-month follow-up, the patient exhibited complete recovery of gait without orthotic support or modification of footwear, including open-toe shoes. Static and dynamic baropodometric analysis revealed no gait asymmetry or abnormalities related to the procedure. Functional testing confirmed symmetrical ability to rise on tiptoe, bearing full weight on the neo-toe.

Subjectively, the patient reported high satisfaction and no social discomfort, even when wearing summer footwear (Figure 9a,b).

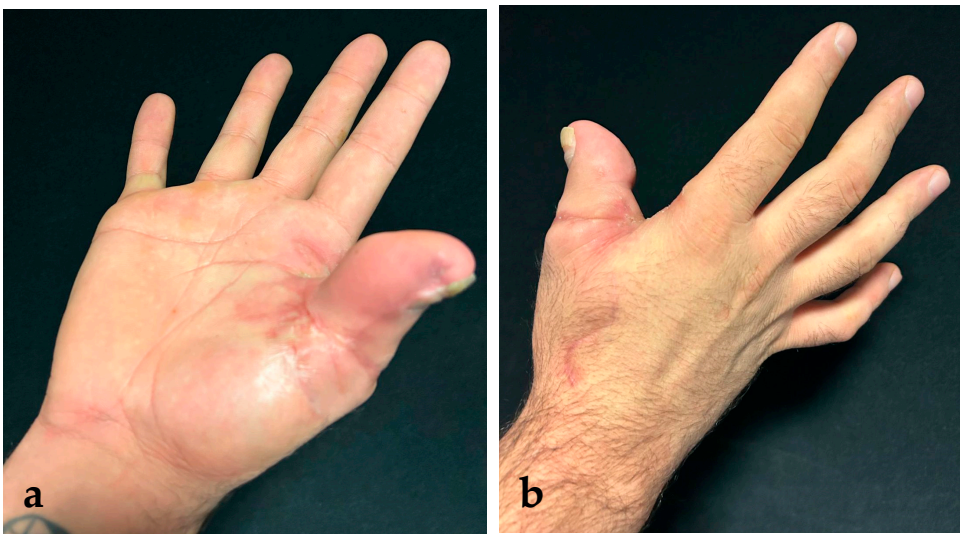

Figure 8. (**a**,**b**) New thumb at 6 months.



Figure 9. (**a**,**b**) New toe at 6 months.

4. Discussion

Digital transfer remains the best reconstructive option for restoring a missing digit, especially the thumb, offering excellent aesthetic and functional results. However, these procedures carry significant donor-site morbidity due to partial or total loss of a toe. Over the years, several authors have refined surgical techniques to minimize the amount of tissue harvested from the foot. Initially, Morrison et al. [6], following the wraparound technique, proposed covering the dorsal aspect of the great toe with a cross-toe flap from the plantar side of the second toe and the remaining plantar surface with a split-thickness skin graft. The flap was divided after three weeks [12]. However, this method provided insufficient soft tissue padding, predisposing to chronic injury, ulceration, and delayed healing. Later, Morrison and colleagues [13] recommended using a dorsal cross-toe flap from the second toe to cover the plantar surface, delaying flap division to one month, further prolonging recovery. Hashimoto et al. [14] addressed these limitations by reconstructing the donor site using a free peroneal flap with subcutaneous fat for protection. This achieved rapid healing (within one month) and good aesthetic results, though mild discomfort was noted

during prolonged walking or running. Disadvantages included longer operative time and the frequent need for secondary flap thinning. Kawamura et al. [14,15] utilized a free soleus perforator flap for immediate reconstruction following wraparound transfer. Compared to the peroneal flap, the procedure was faster, did not require secondary debulking, and allowed primary closure with lower morbidity due to the pliability of the proximal lateral leg. No major arteries were sacrificed. However, the small perforator diameter and hair-bearing skin were drawbacks. Inoue et al. [16] reported 16 cases using a free arterialized venous flap, achieving good results in seven cases with healing times between seven weeks and three months. St-Laurent and Lanzetta [17] employed a free lateral forearm flap in five cases, achieving satisfactory outcomes owing to its thin, pliable skin and potential inclusion of the posterior cutaneous nerve to restore sensibility. The procedure, however, was long, technically complex, and the transferred skin could be hairy, particularly in men. Yamamoto et al. [18] were the first to describe the use of the SCIP flap for great toe donor-site reconstruction, reporting excellent aesthetic and functional results, fast healing, early gait recovery, and a concealed scar beneath the underwear line. Most published studies have focused on partial toe-harvest techniques, combining elements from multiple toes to avoid total amputation of one [19]. This approach yields smaller digital gaps that are easier to reconstruct. However, when a complete great toe harvest is required for functional or aesthetic reasons, the resulting anatomical defect leads to functional gait alteration and a conspicuous aesthetic deformity. While thumb reconstruction justifies this level of donor-site sacrifice, total neglect of the resulting foot defect is no longer acceptable. Patients undergoing thumb reconstruction are typically young, active, and socially engaged; thus, the aesthetic appearance of the foot can significantly affect psychological well-being, particularly when wearing open footwear. Modern microsurgical techniques enable the design of thin, low-profile flaps with minimal donor-site visibility. The SCIP flap, with its thinness and pliability, allows tubularization to create a three-dimensional shape without compromising perfusion. For this reason, it was chosen for neo-toe reconstruction, with the skin island designed according to the dimensions of the contralateral healthy toe. The incision was planned obliquely to minimize the risk of scar contracture and avoid dorsal visibility. The vascular anatomy of the SCIP flap allows its harvest with an iliac crest bone segment on a single pedicle, creating an osteocutaneous flap. Even though a composite flap including vascularized bone had some potential advantages, particularly in terms of enhanced circulation and possibly improved long-term bone viability, in the present case, the size of the bony fragment was considered sufficient to allow adequate consolidation even as an isolated bone graft. Moreover, after a careful risk-benefit assessment, a composite flap was not considered the preferred option because it could have reduced joint mobility and imposed greater limitations during subsequent cutaneous remodeling due to the need to preserve the vascular connections. In particular, any further trimming of the cutaneous component would have been constrained by the need to maintain the vascular pedicle, thereby limiting the amount of skin that could be safely removed. For these reasons, the choice was oriented toward a separate iliac crest bone graft rather than a composite flap. This approach provided greater flexibility in shaping the neo-phalanx and positioning the flap without compromising vascularity. At follow-up, baropodometric analysis revealed no gross asymmetries or functional impairment, and the ability to rise on tiptoe confirmed structural stability. The final aesthetic result was excellent according to the patient, despite the absence of a nail plate (which could be simulated later with medical tattooing). Functionally, he resumed motorcycle riding and full daily activity, including wearing open-toe footwear.

5. Conclusions

To our knowledge, no previous reports describe total great toe reconstruction following digital transfer. This case illustrates a feasible approach to restoring foot integrity after total toe harvest.

The goal of this report is not to propose the SCIP flap with iliac crest bone graft as the new gold standard for neo-toe creation, but rather to emphasize the importance of respecting the foot as a donor site. Iatrogenic mutilation of the great toe—though functionally less critical than hand loss—constitutes a significant aesthetic handicap, particularly in young and active patients.

With modern microsurgical techniques allowing thin, tailored flaps and minimal donor-site visibility, surgeons should adopt a new mindset toward digital transfer: the foot must no longer be regarded merely as a source of spare parts for the hand, but as a structure worthy of functional and aesthetic preservation.

Author Contributions: Conceptualization, P.P. and M.F.; methodology, P.P.; validation, A.C., P.P. and M.F.; data curation, P.P.; writing—original draft preparation, S.P.; writing—review and editing, P.P.; visualization, P.P.; supervision, A.C.; project administration, P.P. All authors have read and agreed to the published version of the manuscript.

Funding: This research received no external funding.

Institutional Review Board Statement: Given the retrospective design of this study, being a case report, the use of fully anonymised routinely collected data and the absence of any experimental intervention or deviation from standard clinical care, formal ethical committee review was not required.

Informed Consent Statement: Written informed consent has been obtained from the patient to publish this paper.

Data Availability Statement: No new data were created.

Acknowledgments: During the preparation of this manuscript, the authors used Dall-E for the purposes of creating their Graphical Abstract. The authors have reviewed and edited the output and take full responsibility for the content of this publication.

Conflicts of Interest: The authors declare no conflicts of interest.

Abbreviations

The following abbreviations are used in this manuscript

SCIP	Superficial circumflex iliac perforator flap
P1	Proximal Phalanx

References

1. Shale, C.M.; Tidwell, J.E.; Mulligan, R.P.; Jupiter, D.C.; Mahabir, R.C. A nationwide review of the treatment patterns of traumatic thumb amputations. *Ann. Plast. Surg.* **2013**, *70*, 647–651. [CrossRef] [PubMed]
2. Graham, D.J.; Venkatramani, H.; Sabapathy, S.R. Current Reconstruction Options for Traumatic Thumb Loss. *J. Hand Surg.* **2016**, *41*, 1159–1169. [CrossRef] [PubMed]
3. Pet, M.A.; Ko, J.H.; Vedder, N.B. Reconstruction of the traumatized thumb. *Plast. Reconstr. Surg.* **2014**, *134*, 1235–1245. [CrossRef] [PubMed]
4. Yim, K.K.; Wei, F.C.; Lin, C.H. A comparison between primary and secondary toe-to-hand transplantation. *Plast. Reconstr. Surg.* **2004**, *114*, 107–112. [CrossRef] [PubMed]
5. Wei, F.-C.; Chen, H.-C.; Chuang, C.-C.; Noordhoff, M.S. Reconstruction of the thumb with a Trimmed- Toe transfer Technique. *Plast. Reconstr. Surg.* **1987**, *82*, 506–513. [CrossRef] [PubMed]
6. Morrison, W.A.; O'Brien, B.M.C.; MacLeod, A.M. Thumb reconstruction with a free neurovascular wrap-around flap from the big toe. *J. Hand Surg.* **1980**, *5*, 575–583. [CrossRef] [PubMed]

7. Sosin, M.; Lin, C.-H.; Steinberg, J.; Hammond, E.R.; Poysophon, P.; Iorio, M.L.; Patel, K.M. Functional donor site morbidity after vascularized toe transfer procedures a review of the literature and biomechanical consideration for surgical site selection. *Ann. Plast. Surg.* **2016**, *76*, 735–742. [CrossRef] [PubMed]
8. Lin, C.H.; Lin, C.H.; Sassu, P.; Hsu, C.C.; Lin, Y.T.; Wei, F.C. Replantation of the great toe: Review of 20 cases. *Plast. Reconstr. Surg.* **2008**, *122*, 806–812. [CrossRef] [PubMed]
9. Cui, Y.; Wang, J.; Lin, J.; Pei, Y.; Zhu, L.; Xu, Q. Long-term outcomes of toe replantation: A review of ten cases. *J. Plast. Reconstr. Aesthetic Surg.* **2022**, *75*, 4042–4047. [CrossRef] [PubMed]
10. Ademoglu, Y.; Ada, S.; Kaplan, I. Should the Amputations of the Great Toe Be Replanted? *Foot Ankle Int.* **2000**, *21*, 673–679. [CrossRef] [PubMed]
11. Kotkansalo, T.; Elo, P.; Luukkaala, T.; Vilkki, S.K. Long-term effects of toe transfers on the donor feet. *J. Hand Surg. Eur.* **2014**, *39*, 966–976. [CrossRef] [PubMed]
12. Hamilton, R.B.; O'brien, B.M.; Morrison, W.A. The cross toe flap. *Br. J. Plast. Surg.* **1979**, *32*, 213–216. [CrossRef] [PubMed]
13. Morrison, W.A.; O'brien, B.M.; Macleod, A.M. Experience with Thumb Reconstruction. *J. Hand Surg.* **1983**, *9*, 223–233. [CrossRef] [PubMed]
14. Hashimoto, F.; Nomura, S.; Yamauchi, S.; Shimamura, K.; Yoshimura, M. Free peroneal flap coverage of the great toe defect resulting from a wrap-around flap transfer. *Microsurgery* **1986**, *7*, 199–202. [CrossRef] [PubMed]
15. Kawamura, K.; Yajima, H.; Kobata, Y.; Shigematsu, K.; Maegawa, N.; Takakura, Y. Coverage of Big Toe Defects After Wrap-Around Flap Transfer with a Free Soleus Perforator Flap. *J. Reconstr. Microsurg.* **2005**, *21*, 225–229. [CrossRef] [PubMed]
16. Inoue, G.; Maeda, N.; Suzuki, K. Closure of big toe defects after wrap-around flap transfer. using the arterialized venous flap. *J. Reconstr. Microsurg.* **1991**, *7*, 1–8. [CrossRef] [PubMed]
17. St-Laurent, J.-Y.; Lanzetta, M. Resurfacing of the Donor Defect After Wrap-Around Toe Transfer with a Free Lateral Forearm Flap. *J. Hand Surg.* **1997**, *22*, 913–917. [CrossRef] [PubMed]
18. Fuse, Y.; Yamamoto, T.; Kageyama, T.; Sakai, H.; Tsukuura, R.; Yoshimatsu, H.; Yamamoto, N. Domino Free Flap Transfer Using a Superficial Circumflex Iliac Artery Perforator Flap for the Toe Flap Donor Site. *Ann. Plast. Surg.* **2022**, *88*, 293–297. [CrossRef] [PubMed]
19. Kempny, T.; Paroulek, J.; Marik, V.; Kurial, P.; Lipovy, B.; Huemer, G.M. Further developments in the twisted-toe technique for isolated thumb reconstruction: Our method of choice. *Plast. Reconstr. Surg.* **2013**, *131*, 871e–879e. [CrossRef] [PubMed]

Disclaimer/Publisher's Note: The statements, opinions and data contained in all publications are solely those of the individual author(s) and contributor(s) and not of MDPI and/or the editor(s). MDPI and/or the editor(s) disclaim responsibility for any injury to people or property resulting from any ideas, methods, instructions or products referred to in the content.