surgeries

MDPI

Systematic Review

Robotic Surgery Conservative Approaches for Uterine Adenomyosis: A Systematic Review

Mario Ardovino [1], Davide Pisani [2], Pasquale De Franciscis [2], Ester Picone [1], Antonio Conte [1], Fatima Cherifi [3], Maria Izzo [2], Emanuele Amabile [2] and Marco La Verde [2,*]

[1] Department of Obstetrics and Gynecology, Ospedale S.G. Moscati, 83100 Avellino, Italy; mario.ardovino@aornmoscati.it (M.A.); ester.picone@aornmoscati.it (E.P.); antonio.conte@aornmoscati.it (A.C.)

[2] Obstetrics and Gynecology Unit, Department of Woman, Child and General and Specialized Surgery, University of Campania "Luigi Vanvitelli", 80138 Naples, Italy; davidepisani94@gmail.com (D.P.); pasquale.defranciscis@unicampania.it (P.D.F.); maria.izzo23688@gmail.com (M.I.); amabilema93@gmail.com (E.A.)

[3] Dubai Academic Health Corporation, Dubai 505054, United Arab Emirates; fcherifi@dubaihealth.ae

* Correspondence: marco.laverde@unicampania.it

Abstract

Background/Objectives: Adenomyosis is a common disorder of the uterus in those of reproductive age. Robotic-assisted surgery has been adopted to address the technical challenges of adenomyomectomy. This systematic review evaluated the current evidence regarding the feasibility, safety, and clinical outcomes of robotic-assisted conservative surgery for uterine adenomyosis. **Methods**: A systematic review of literature was performed on five databases, from the beginning to 21 December 2025, to identify studies reporting robotic-assisted uterus-sparing surgical approaches to adenomyosis. Data were collected on patient characteristics, surgical techniques used, pre- and post-operative pain, fertility outcomes, and complications. Risk of bias was evaluated using the ROBINS-I framework. **Results**: A total of 514 articles were found; six studies met the inclusion criteria. Most included studies were small and retrospective. The operative time ranged from 279 to 147 min. Mean blood loss ranged between 25 and 296 mL with a low rate of conversion and perioperative complications. Dysmenorrhea improved after surgery as reflected by the post operative visual analog scale pain score and serum CA-125 level. Few reproductive data were collected about successive spontaneous pregnancies. Risk of bias was serious or moderate in all studies included. **Conclusions**: Robotic-assisted conservative surgery for adenomyosis may represent a feasible and safe option for women with symptomatic adenomyosis who wish preserve the uterus, with a positive impact on patients' symptoms. Large prospective, multicenter studies with standardized protocols and long-term follow-up are needed to clarify the real impact of robotic surgery in adenomyosis management.

Keywords: adenomyosis; uterine diseases; robotic surgical procedures; conservative treatment; fertility preservation

Check for updates

Academic Editors: Nir Horesh and Salomone Di Saverio

Received: 2 March 2026
Revised: 19 March 2026
Accepted: 15 April 2026
Published: 23 April 2026

Copyright: © 2026 by the authors. Licensee MDPI, Basel, Switzerland. This article is an open access article distributed under the terms and conditions of the Creative Commons Attribution (CC BY) license.

1. Introduction

Adenomyosis is a common disorder of the uterus and is associated with uterine alterations, heavy menstrual bleeding, pelvic pain, and infertility [1]. It is characterized by endometrial epithelial cells and stromal fibroblasts abnormally found in the myometrium [1]. Transvaginal ultrasonography and magnetic resonance imaging are used to establish the

diagnosis before hysterectomy [2]. Several authors linked adenomyosis to an increased risk of infertility [3,4]. Adenomyosis can cause severe, progressive, and even sexual and daily lifestyle impairment [5,6]. Adenomyosis frequently coexists with leiomyomas and endometriosis, suggesting a shared pathogenic mechanism including hyperestrogenism and inflammatory, environmental, and genetic alterations that may complicate management [7–9]. Different studies have found an explanation for the decreased fertility that might be linked to uterine peristalsis, decreasing endometrial receptivity and chronic inflammation in the uterine microenvironment [10,11]. Management options focus on fertility preservation and symptom control [12]. Historically, hysterectomy used to be the only treatment strategy for symptomatic adenomyosis in those of non-reproductive age [13]. Women of reproductive age who want to preserve the uterus can opt for different therapeutic options. The most common drugs taken as first-line treatments are hormonal contraceptives, progestins, gonadotropin-releasing hormone agonists, and levonorgestrel-releasing intrauterine systems [14]. These therapies often provide temporary symptomatic relief but are not commonly effective in the long term and are commonly associated with symptom re-emergence following discontinuation [15]. On the other hand, side effects and contraindications can restrict long-term medical treatment [16]. In this scenario, for patients who are refractory or unsuitable for long-term medical treatment or those with focal adenomyoma, conservative surgeries could be offered [17]. Adenomyomectomy, that is, removing adenomyotic tissue and reconstructing the wall of the uterine cavity, is an alternative treatment option for selected patients with treatment-resistant symptoms or infertility [18]. Adenomyomectomy is an exceedingly technically challenging procedure, with no distinction between diseased and normal myometrium, as well as grave intraoperative bleeding and demanding multilayer uterine reconstruction, being key considerations [19]. Complete adenomyosis excision is difficult to achieve [20]. These challenges are particularly pronounced in diffuse disease. Meanwhile, minimally invasive surgery has transformed gynecologic practice, improving patient outcomes and satisfaction [21]. Laparoscopic adenomyomectomy is possible with acceptable outcomes in some cases; however, it is among the most complex surgeries in benign gynecology [22]. Instrument rigidity, limited degrees of freedom, and the two-dimensional visibility of the surgical site limit accurate dissection and proper myometrial reconstruction of uterine integrity [23]. Robotic-assisted surgery was developed to reduce these limitations [24]. Robotic platforms provide three-dimensional, high-definition visualization, tremor-filtered instruments, and wristed instruments of higher dexterity for dissection and complex suturing [25]. Technological innovations are important in conservative surgery for adenomyosis, where the aim is to balance between the removal of pathological tissue and functional myometrium. Conservative adenomyosis operations have been reported to have better results in the past 10 years, with more information about their feasibility, symptom improvement, and perioperative outcome. Clinical evidence for robotic-assisted conservative surgery for uterine adenomyosis remains limited [26]. This review summarizes the available evidence on robotic surgery in the conservative management of adenomyosis, using novel data to provide a critique, and identifies priorities for future studies.

2. Materials and Methods

2.1. Eligibility Criteria, Information Sources, and Search Strategy

This systematic review was conducted using the following databases: PubMed, Scopus, EMBASE, CENTRAL, and ClinicalTrials.gov. Database search was conducted from inception to 21 December 2025, with the terms “robotic surgical procedures” and “adenomyosis”. The complete search strategy for the different databases is reported in Appendix A, Table A1. We included only studies that reported robotic conservative surgery for adeno-

myosis. Articles without robotic surgery or without a conservative approach (e.g., those that include hysterectomy) were excluded. Our focus was on the conservative and minimally invasive management of a common condition, such as uterine adenomyosis. We included only studies that involve human subjects. Date, language, geographical, or small sample size restrictions were not applied to our research. Case reports and case series were included, while reviews, meta-analyses, editorial letters, and abstracts were excluded from our research. The systematic review was performed using the PRISMA guidelines (Supplementary Table S1) and was registered with the following code CRD420251239958 in the International Prospective Register of Systematic Reviews (PROSPERO). Given the small number of available studies, we also included small case series ($n < 5$) to avoid potential bias, and no language limitation was applied.

2.2. Study Selection

Two independent reviewers (M.I. and E.A.) performed the study selection to identify articles. Duplicates were removed. During the screening, two authors independently screened all the papers following the inclusion criteria (M.I. and E.A.). If the articles selected did not report on conservative robotic conservative surgery or if adenomyosis was not reported, articles were excluded by these two independent reviewers (M.I. and E.A.). If the two reviewers (M.I. and E.A.) did not reach a consensus or in case of disagreement, a third reviewer (M.L.V.) was referred. Due to the heterogeneous data obtained, a quantitative analysis and a pooled quantitative analysis were not available, and detailed stratification according to adenomyosis phenotype or adjuvant therapy was not consistently reported across studies.

2.3. Data Extraction

Two reviewers (M.I. and E.A.) independently extracted data from each included study using a standardized data-collection form. Disagreements about data extraction were resolved by discussion with a senior reviewer (M.L.V.). We extracted data about: (a) study information (researcher, year of publication date, country, study design, and sample size); (b) surgery information (patient age, surgical technique, follow-up, operative time, blood loss, conversion rate, complication rate, and hospital stay days); (c) clinical and reproductive outcomes (visual analog scale scores of pre- and post operative pain, CA-125 pre- and post operative, symptom recurrence, and pregnancy); (d) technique and instrumentation data (uterine closure, energy source, adhesion prevention, and robotic platform).

2.4. Assessment of Risk of Bias

The Cochrane risk of bias in non-randomized studies of interventions (ROBINS-I) tool for observational studies [27] was adopted for the risk of bias evaluation by two independent reviewers (M.I. and E.A.) with a third reviewer consultation in case of disagreement (M.L.V).

3. Results

3.1. Study Selection and Characteristics

A total of 514 studies were identified on the database, and 208 duplicates were removed (Figure 1). After the record screening, 13 were assessed, and only six met the criteria. All the included papers reported a uterus-sparing conservative robotic surgical approach for confirmed uterine adenomyosis [19,28–32].

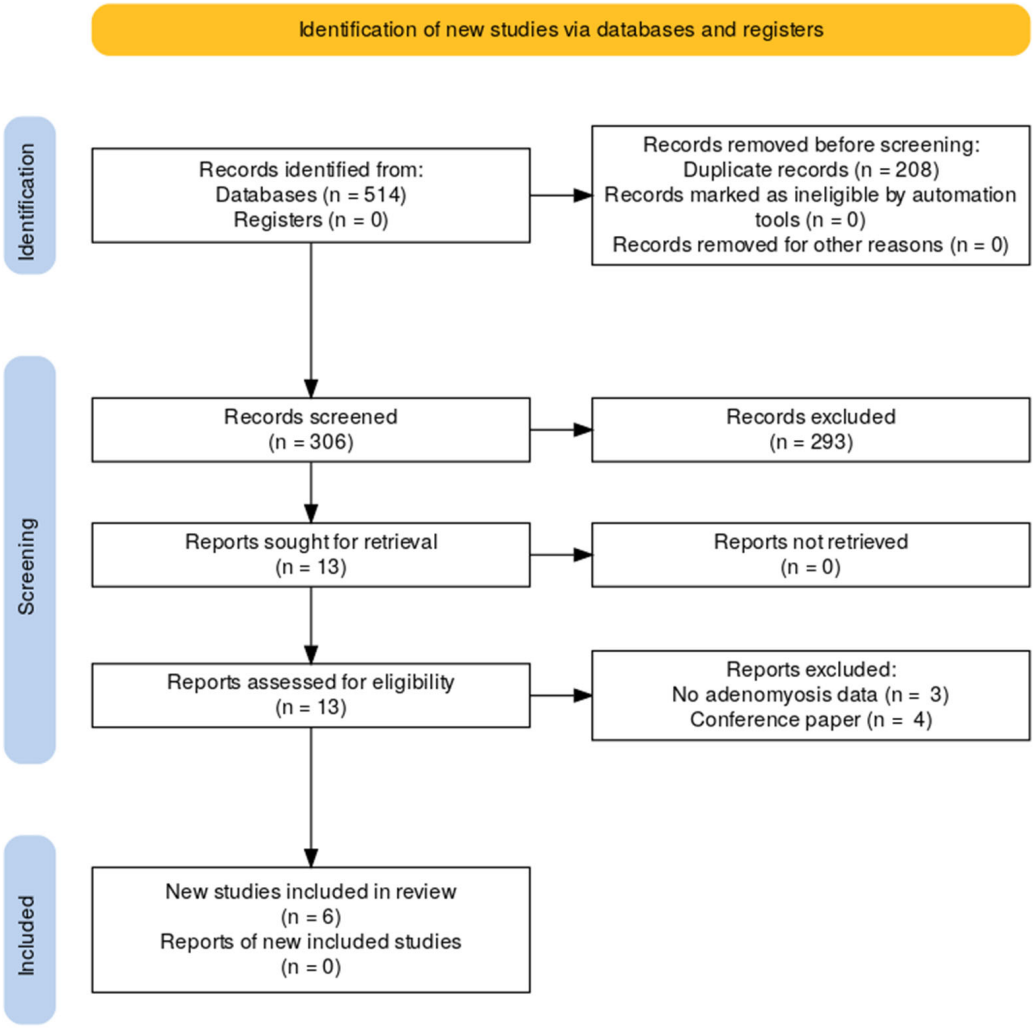

Figure 1. The PRISMA flow diagram of the studies included.

The majority of the studies included [28–32] are small retrospective series (less than 50 patients included) or single-center studies; only one study was a prospective study (Table 1) [19]. One study had a considerable number of patients included [32]. The age of the included patients was in the reproductive period and ranged from 25 to 50 years (Table 1). The follow-up varied from 1 w to 76 months [19,28–30]. Five studies originated from East Asia (Korea and China) [19,28–30,32] and one from the United States of America [31]. All studies investigated uterus-conservative robotic-assisted adenomyomectomy. Three studies compared robotic techniques versus laparoscopy or transumbilical laparoendoscopic single-site surgery (LESS) [19,30,32]. Due to the limited number of studies and heterogeneity of reporting, a structured narrative synthesis was performed considering surgical technique, follow-up duration, and reported clinical outcomes. Several clinically relevant data, such as abnormal uterine bleeding, quality-of-life measures, and fertility outcomes were not reported in the included studies.

Table 1. Characteristics of included studies.

Study (Year)	Country	Design	n.	Mean Age (y)	Surgical Technique	Follow-Up (mo)
Hijazi et al., [28]	Korea	Retrospective cohort	34	35.6 ± 5.3	Robot-assisted adenomyomectomy	1 w and 3 mo
Chung et al., [29]	Korea	Case series	4	33 ± 3	Robot-assisted adenomyomectomy	25
Chong et al., [19]	Korea	Prospective	33	39 ± 5	Laparoscopic/Robotic ± GnRH	38–76
Shim et al., [30]	Korea	Retrospective comparative	43	41 (25–50)	Laparoscopic vs. Robotic	4.5 (1–24)
Barton et al., [31]	USA	Case series	13	41.9 ± 4.9	Robotic + flexible CO_2 laser	NR
Zhao et al., [32]	China	Retrospective comparative	1573	50–52	R-LESS vs. TU-LESS	NR

3.2. Intraoperative and Perioperative Outcomes

Five studies reported that the operative time ranged from a mean of 147.4 to 279.8 min, and the estimated intraoperative blood loss varied largely across studies from 25 mL to 300 mL (Table 2). Perioperative complications were uncommon in the available studies [30,31]. Three studies did not report the complication rate [26,28,32]. Only Chong et al. reported five cases of fever, ileus, and pelvic abscess [19] (Table 2). Length of hospital stay ranged from outpatient management to 5.1 days. Conversion rate was zero and was reported only by Shim et al. [30].

Table 2. Intraoperative and perioperative outcomes.

Study	Operative Time (min)	Blood Loss (mL)	Conversion (%)	Complications (%)	Hospital Stay (Days)
Hijazi et al., [28]	279.82 ± 69.02	296.47 ± 160.77	NR	NR	2.71 ± 0.68
Chung et al., [29]	159.25 ± 93.06	117.5 ± 56.78	NR	NR	2.5 ± 0.5
Chong et al., [19]	147 ± 52	36 ± 37	NR	5 (15%)	5.1 ± 2.2
Shim et al., [30]	160	300	0	0	6.0
Barton et al., [31]	169	25	NR	0	0
Zhao et al., [32]	NR	NR	NR	NR	NR

3.3. Clinical and Reproductive Outcomes

Three studies reported pre- and post-visual analog scale (VAS) scores for pain evaluation, with better pain control after surgery [19,28,29]. Preoperative VAS ranged from 7.5 to 9.0, with postoperative scores near to zero (Table 3). CA125 levels followed the same trend: preoperative values 85 to 125 U/mL, and postoperative levels ranging from 6 to 13 U/mL. Symptom recurrence was evaluated in two studies, with a range of 7–12% [19,30]. Pregnancies were reported only by one study, with three pregnancies [28].

Table 3. Clinical and reproductive outcomes.

Study	VAS Pain (Pre)	VAS Pain (Post)	CA-125 Pre (U/mL)	CA-125 Post	Symptom Recurrence (%)	Pregnancies
Hijazi [28]	8.6 ± 1.12	0.06 ± 0.3	121.7 ± 117	6.95 ± 2.60	NR	3
Chung [29]	9.0 ± 1.41	0	104.09 ± 125.39	6.17 ± 1.97	NR	NR
Chong [19]	7.8 ± 2.5	0.3 ± 0.9 (12 mo)	85.4 ± 88.2	13.9 ± 13.0 (12 mo)	12	NR
Shim [30]	7.5	NR	106.3	NR	7	NR
Barton [31]	NR	NR	NR	NR	NR	NR
Zhao [32]	NR	NR	NR	NR	NR	NR

3.4. Surgical Technique and Instrumentation

The robotic procedures include uterine reconstruction using layered closure techniques. Different energy sources were reported: monopolar and bipolar electrosurgery, harmonic scalpel devices, and CO_2 lasers. Adhesion prevention strategies were reported in three studies: anti-adhesive barriers and peritoneal lavage [19,28,31]. Robotic platforms were described in three studies and included the da Vinci S, Si, and Xi systems [28,30,32]. All the data about the surgical technique details are shown in Table 4.

Table 4. Operative technique and instrumentation.

Study	Uterine Closure	Energy Source	Adhesion Prevention	Robotic Platform
Hijazi [28]	Layered, Stratafix + PDS	Monopolar + bipolar	Anti-adhesive barrier	da Vinci S or Xi
Chung [29]	Layered	curved monopolar scissors + PK bipolar forceps	NR	NR
Chong [19]	Layered	Monopolar/Harmonic	Barrier + lavage	NR
Shim [30]	2–3 layers	Monopolar	NR	da Vinci Si
Barton [31]	Multilayer, barbed sutures	CO_2 laser	Interceed	NR
Zhao [32]	NR	NR	NR	Vinci Xi

3.5. Risk of Bias Assessment

Four studies, assessed using the ROBINS-I framework, showed a serious or critical risk of bias, and two studies had a moderate overall risk. This was due to the study design of the studies included (case series), the small sample sizes (only one study had adequate sample sizes), limited comparability between the studies, or incomplete outcome assessment (especially the pregnancy outcomes). The risk of bias is reported in Table 5.

Table 5. Risk of Bias Assessment (ROBINS-I).

Study	D1	D2	D3	D4	D5	D6	D7	Overall
Hijazi [28]	Serious	Moderate	Low	Moderate	Moderate	Moderate	Moderate	Serious
Chung [29]	Serious	Serious	Low	Low	Low	Moderate	Moderate	Serious
Chong [19]	Moderate	Moderate	Low	Low	Moderate	Moderate	Moderate	Moderate
Shim [30]	Serious	Moderate	Low	Moderate	Moderate	Moderate	Moderate	Serious
Barton [31]	Serious	Serious	Low	Low	Low	Moderate	Moderate	Serious
Zhao [32]	Moderate	Moderate	Low	Low	Low	Moderate	Moderate	Moderate

Legend: D1: confounding; D2: selection of participants; D3: classification of interventions; D4: deviations from intended interventions; D5: missing data; D6: measurement of outcomes; D7: selection of the reported result.

4. Discussion

This systematic review provides a review of the current evidence regarding conservative robotic conservative surgery for uterine adenomyosis. The main conclusion of this review is the evidence for robotic surgery as a minimally invasive method in certain women with symptomatic adenomyosis who need uterine conservation, which provides acceptable surgical feasibility and clinically significant relief from symptoms such as dysmenorrhea and menorrhagia. The studies included in the review showed a low incidence of intraoperative complications, low conversion requirements, and good short- and long-term follow-up outcomes for robotic adenomyomectomy. These findings suggest a potential role for robotic-assisted conservative surgery in this challenging clinical scenario; however, several outcomes (complications and reproductive outcomes) were reported across the included studies, and our conclusions are not generalizable. The clinical benefit appeared

adequate for conservative clinical management of adenomyosis. By removing specific uterine adenomyotic tissue and reconstructing myometrial architecture, robotic conservative surgery could relieve the symptoms of myometrial hyperplasia, inflammation, and improper uterine peristalsis while maintaining uterine integrity [33]. Robotic platforms provide enhanced dexterity, three-dimensional visualization, and tremor filtration, which may be particularly advantageous in adenomyomectomy, where precise dissection and multilayer myometrial closure are critical in order to minimize bleeding, preserve uterine integrity, and prevent postoperative morbidity. The reduction in pain scores and serum CA-125 scores found in different studies indicates not only mechanical decompression of the diseased tissue, but also a reduction of the inflammatory milieu commonly associated with adenomyosis [34]. When placed in a larger literature review context, the results of this review found a solid correlation with previous studies where laparoscopic conservative surgery has been described as an effective but challenging modality [35,36]. Conventional laparoscopy has been shown to improve symptoms and have acceptable reproductive outcomes in selected cases [37,38]. Robotic assistance provides support for suturing in deep myometrial defects and permits more radical yet effective excision of adenomyotic lesions with a reassuring, feasible profile. This review has several limitations that limit the generalizability of these findings. First, the heterogeneity of surgical techniques and selection criteria for patients across different studies. In addition, there was an elevated variability in the disease phenotypes, from focal adenomyomas to diffuse myometrial lesions. The absence of a uniform outcome and preoperative classification system, imaging criteria, and surgical algorithms limits a direct comparison between outcomes. At least four studies add evidence that reduces our outcomes analysis: surgical treatment was combined with adjuvant medical therapy (GnRH agonists, oral contraceptives, progestins, or intrauterine devices) [19,26,29,30]. Conversely, different strengths are present. We performed an extensive review of the literature regarding a growing surgical practice, and we focused on robotic approaches tailored to uterine preservation. Different data were integrated to explore the potential benefits and limitations of robotic surgery in adenomyosis in the context of actual clinical practice. Moreover, the inclusion of perioperative, symptomatic, and technical outcomes provides a complex evaluation of feasibility beyond mere operative techniques. We aim to perform this review to support future research on this topic. Additional studies are necessary to obtain data on subsequent pregnancy rates, uterine rupture, and obstetric outcomes after robotic conservative surgery for adenomyosis [39]. Additionally, data are necessary to explore different subgroup populations, such as women with extensive diffuse disease, severe comorbidities, or advanced age. All these efforts are necessary to acquire robust evidence to support valid counseling in adenomyosis strategies.

5. Conclusions

This systematic review suggests that robotic-assisted conservative surgery may be an acceptable and feasible option for selected women with symptomatic uterine adenomyosis, who wish to preserve the uterus. Although further multicenter, large prospective studies including standard diagnosis, surgical protocol, and long-term follow-up are needed to establish the necessary role of robotic surgery in the treatment algorithm of adenomyosis.

Supplementary Materials: The following supporting information can be downloaded at https://www.mdpi.com/article/10.3390/surgeries7020052/s1, Supplementary Table S1: PRISMA 2020 Checklist.

Author Contributions: Conceptualization, M.L.V. and M.A.; methodology, P.D.F. and F.C.; validation, A.C. and E.P.; formal analysis, E.A.; investigation, E.A. and M.I.; data curation, E.A. and M.I.; writing—original draft preparation, D.P.; writing—review and editing, M.L.V.; visualization, A.C.

and E.P.; supervision, P.D.F. and F.C. All authors have read and agreed to the published version of the manuscript.

Funding: This research received no external funding.

Institutional Review Board Statement: Not applicable.

Informed Consent Statement: Not applicable.

Data Availability Statement: The original contributions presented in this study are included in the article. Further inquiries can be directed to the corresponding author.

Conflicts of Interest: Author Dr. Fatima Cherifi was employed by the company Dubai Academic Health Corporation. The remaining authors declare that the research was conducted in the absence of any commercial or financial relationships that could be construed as a potential conflict of interest.

Abbreviations

The following abbreviations are used in this manuscript:

VAS	visual analog scale scores
LESS	transumbilical laparoendoscopic single-site surgery

Appendix A

Table A1. Detailed search strategy for the systematic review.

Variable	Search Strategy
Database searched	Cochrane Central Register of Controlled Trials (CENTRAL) and ClinicalTrials.gov, PubMed, Scopus, and EMBASE from inception of each database until 21 December 2025.
Search strategy for Pubmed	(“Robotics”[Mesh] OR “Robotic Surgical Procedures”[Mesh] OR (“robot*”[tiab] AND (surg*[tiab] OR operat*[tiab] OR proced*[tiab])) OR “robot-assisted”[tiab] OR “robot assisted”[tiab] OR “robotic-assisted”[tiab] OR “robotically assisted”[tiab] OR “telerobot*”[tiab] OR “tele-robot*”[tiab] OR “computer-assisted surg*”[tiab] OR “computer assisted surg*”[tiab] OR “da vinci”[tiab]) AND (“Adenomyosis”[Mesh] OR adenomyo*[tiab] OR “uterine adenomyo*”[tiab] OR (“adenomyo*”[tiab] AND uterus[tiab]) OR (“adenomyo*”[tiab] AND uterine[tiab]))
Cochrane Central Register of Controlled Trials (CENTRAL)	(robotics OR “robotic surgical procedures” OR (robot* AND (surg* OR operat* OR proced*)) OR “robot-assisted” OR “robot assisted” OR “robotic-assisted” OR “robotically assisted” OR telerobot* OR “tele-robot*” OR “computer-assisted surg*” OR “computer assisted surg*” OR “da vinci”) AND (adenomyosis OR adenomyo* OR “uterine adenomyo*” OR (adenomyo* AND uterus) OR (adenomyo* AND uterine))
Scopus	(robotics OR “robot-assisted” OR “robot assisted” OR “robotic-assisted” OR (robot* W/3 (surg* OR operat* OR proced*)) OR telerobot* OR (“computer assisted” W/3 surg*) OR “da vinci”) AND (adenomyo* OR “uterine adenomyo*” OR (adenomyo* W/3 (uterus OR uterine)))

Table A1. *Cont.*

Variable	Search Strategy
EMBASE	('robot'/exp OR 'robot assisted surgery'/exp OR (robot* NEAR/3 (surg* OR operat* OR proced*)):ti,ab,kw OR 'robot-assisted':ti,ab,kw OR 'robot assisted':ti,ab,kw OR 'robotic-assisted':ti,ab,kw OR telerobot*:ti,ab,kw OR ('computer assisted' NEAR/3 surg*):ti,ab,kw OR 'da vinci':ti,ab,kw) AND ('adenomyosis uteri'/exp OR adenomyo*:ti,ab,kw OR 'uterine adenomyo*':ti,ab,kw OR (adenomyo* NEAR/3 (uterus OR uterine)):ti,ab,kw)
Clinical Trial	(robotics OR "robotic surgical procedures" OR (robot* AND (surg* OR operat* OR proced*)) OR "robot-assisted" OR "robot assisted" OR "robotic-assisted" OR "robotically assisted" OR telerobot* OR "tele-robot*" OR "computer-assisted surg*" OR "computer assisted surg*" OR "da vinci") AND (adenomyosis OR adenomyo* OR "uterine adenomyo*" OR (adenomyo* AND uterus) OR (adenomyo* AND uterine))
Other sources	The reference lists of selected articles were hand-searched to identify any relevant articles.

References

1. Zhai, J.; Vannuccini, S.; Petraglia, F.; Giudice, L.C. Adenomyosis: Mechanisms and Pathogenesis. *Semin. Reprod. Med.* **2020**, *38*, 129–143. [CrossRef]
2. Reinhold, C.; Tafazoli, F.; Mehio, A.; Wang, L.; Atri, M.; Siegelman, E.S.; Rohoman, L. Uterine Adenomyosis: Endovaginal US and MR Imaging Features with Histopathologic Correlation. *RadioGraphics* **1999**, *19*, S147–S160. [CrossRef]
3. Moawad, G.; Kheil, M.H.; Ayoubi, J.M.; Klebanoff, J.S.; Rahman, S.; Sharara, F.I. Adenomyosis and infertility. *J. Assist. Reprod. Genet.* **2022**, *39*, 1027–1031. [CrossRef]
4. Harada, T.; Khine, Y.M.; Kaponis, A.; Nikellis, T.; Decavalas, G.; Taniguchi, F. The Impact of Adenomyosis on Women's Fertility. *Obstet. Gynecol. Surv.* **2016**, *71*, 557–568. [CrossRef]
5. Alcalde, A.M.; Martínez-Zamora, M.Á.; Gracia, M.; Ros, C.; Rius, M.; Nicolás, I.; Carmona, F. Impact of Adenomyosis on Women's Psychological Health and Work Productivity: A Comparative Cross-Sectional Study. *J. Women's Health* **2021**, *30*, 1653–1659. [CrossRef] [PubMed]
6. Ekin, M.; Cengiz, H.; Öztürk, E.; Kaya, C.; Yaşar, L. Genitourinary symptoms in patients with adenomyosis. *Int. Urogynecol. J.* **2013**, *24*, 509–512. [CrossRef] [PubMed]
7. Matalliotakis, M.; Tsakiridis, I.; Matalliotaki, C.; Krithinakis, K.; Spandidos, D.; Dagklis, T.; Mamopoulos, A.; Kalogiannidis, I. Coexistence of gynecological pathology with endometriosis and adenomyosis. *Mol. Clin. Oncol.* **2025**, *24*, 12. [CrossRef] [PubMed]
8. Bulun, S.E.; Yildiz, S.; Adli, M.; Chakravarti, D.; Parker, J.B.; Milad, M.; Yang, L.; Chaudhari, A.; Tsai, S.; Wei, J.J.; et al. Endometriosis and adenomyosis: Shared pathophysiology. *Fertil. Steril.* **2023**, *119*, 746–750. [CrossRef]
9. Verit, F.F.; Yucel, O. Endometriosis, Leiomyoma and Adenomyosis: The Risk of Gynecologic Malignancy. *Asian Pac. J. Cancer Prev.* **2013**, *14*, 5589–5597. [CrossRef]
10. Pathare, A.D.S.; Loid, M.; Saare, M.; Gidlöf, S.B.; Zamani Esteki, M.; Acharya, G.; Yang, L.; Chaudhari, A.; Tsai, S.; Wei, J.J.; et al. Endometrial receptivity in women of advanced age: An underrated factor in infertility. *Hum. Reprod. Update* **2023**, *29*, 773–793. [CrossRef]
11. Sun, P.; Zhang, C.; Wang, W.; Ma, H. Mechanism of Endometrial Receptivity Affected by Fibroids. *Am. J. Reprod. Immunol.* **2024**, *92*, e70022. [CrossRef] [PubMed]

12. Vannuccini, S.; Luisi, S.; Tosti, C.; Sorbi, F.; Petraglia, F. Role of medical therapy in the management of uterine adenomyosis. *Fertil. Steril.* **2018**, *109*, 398–405. [CrossRef] [PubMed]
13. Moldassarina, R.S. Modern view on the diagnostics and treatment of adenomyosis. *Arch. Gynecol. Obstet.* **2023**, *308*, 171–181. [CrossRef] [PubMed]
14. Tosti, C.; Troìa, L.; Vannuccini, S.; Lazzeri, L.; Luisi, S.; Petraglia, F. Current and Future Medical Treatment of Adenomyosis. *J. Endometr. Pelvic Pain Disord.* **2016**, *8*, 127–135. [CrossRef]
15. Etrusco, A.; Barra, F.; Chiantera, V.; Ferrero, S.; Bogliolo, S.; Evangelisti, G.; Oral, E.; Pastore, M.; Izzotti, A.; Venezia, R.; et al. Current Medical Therapy for Adenomyosis: From Bench to Bedside. *Drugs* **2023**, *83*, 1595–1611. [CrossRef]
16. Pontis, A.; D'Alterio, M.N.; Pirarba, S.; de Angelis, C.; Tinelli, R.; Angioni, S. Adenomyosis: A systematic review of medical treatment. *Gynecol. Endocrinol.* **2016**, *32*, 696–700. [CrossRef]
17. Younes, G.; Tulandi, T. Conservative Surgery for Adenomyosis and Results: A Systematic Review. *J. Minim. Invasive Gynecol.* **2018**, *25*, 265–276. [CrossRef]
18. Osada, H. Uterine adenomyosis and adenomyoma: The surgical approach. *Fertil. Steril.* **2018**, *109*, 406–417. [CrossRef]
19. Chong, G.O.; Lee, Y.H.; Hong, D.G.; Cho, Y.L.; Lee, Y.S. Long-Term Efficacy of Laparoscopic or Robotic Adenomyomectomy with or without Medical Treatment for Severely Symptomatic Adenomyosis. *Gynecol. Obstet. Investig.* **2016**, *81*, 346–352. [CrossRef]
20. Thain, S.; Tan, H.H. Approaches to adenomyomectomy. *Gynecol. Minim. Invasive Ther.* **2015**, *4*, 49–54. [CrossRef]
21. Peters, A.; Siripong, N.; Wang, L.; Donnellan, N.M. Enhanced recovery after surgery outcomes in minimally invasive nonhysterectomy gynecologic procedures. *Am. J. Obstet. Gynecol.* **2020**, *223*, 234.e1–234.e8. [CrossRef]
22. Huang, X.; Huang, Q.; Chen, S.; Zhang, J.; Lin, K.; Zhang, X. Efficacy of laparoscopic adenomyomectomy using double-flap method for diffuse uterine adenomyosis. *BMC Women's Health* **2015**, *15*, 24. [CrossRef]
23. Takeuchi, H.; Kitade, M.; Kikuchi, I.; Shimanuki, H.; Kumakiri, J.; Kitano, T.; Kinoshita, K. Laparoscopic adenomyomectomy and hysteroplasty: A novel method. *J. Minim. Invasive Gynecol.* **2006**, *13*, 150–154. [CrossRef] [PubMed]
24. Cianci, S.; Arcieri, M.; Vizzielli, G.; Martinelli, C.; Granese, R.; La Verde, M.; Fagotti, A.; Fanfani, F.; Scambia, G.; Ercoli, A. Robotic Pelvic Exenteration for Gynecologic Malignancies, Anatomic Landmarks, and Surgical Steps: A Systematic Review. *Front. Surg.* **2021**, *8*, 790152. [CrossRef] [PubMed]
25. Alkatout, I.; O'Sullivan, O.; Peters, G.; Maass, N. Expanding Robotic-Assisted Surgery in Gynecology Using the Potential of an Advanced Robotic System. *Medicina* **2023**, *60*, 53. [CrossRef] [PubMed]
26. Hijazi, A.; Chung, Y.J.; Song, J.Y.; Kim, M.R. Robot-assisted laparoscopic adenomyomectomy: A review of literature. *Gynecol. Robot. Surg.* **2021**, *2*, 9–13. [CrossRef]
27. Sterne, J.A.; Hernán, M.A.; Reeves, B.C.; Savović, J.; Berkman, N.D.; Viswanathan, M.; Henry, D.; Altman, D.G.; Ansari, M.T.; Boutron, I.; et al. ROBINS-I: A tool for assessing risk of bias in non-randomised studies of interventions. *BMJ* **2016**, *355*, i4919. [CrossRef]
28. Hijazi, A.; Chung, Y.J.; Sinan, N.; Kang, H.; Ko, M.; Lee, S.; Song, J.Y.; Kim, M.-R. A novel technique for myometrial defect closure after robot-assisted laparoscopic adenomyomectomy: A retrospective cohort study. *Taiwan. J. Obstet. Gynecol.* **2022**, *61*, 75–79. [CrossRef]
29. Chung, Y.J.; Kang, S.Y.; Choi, M.R.; Cho, H.H.; Kim, J.H.; Kim, M.R. Robot-Assisted Laparoscopic Adenomyomectomy for Patients Who Want to Preserve Fertility. *Yonsei Med. J.* **2016**, *57*, 1531. [CrossRef]
30. Shim, J.I.; Jo Ehye Kim, M.; Kim, M.K.; Kim, M.L.; Yun, B.S.; Seong, S.J.; Jung, Y.W. A comparison of surgical outcomes between robot and laparoscopy-assisted adenomyomectomy. *Medicine* **2019**, *98*, e15466. [CrossRef]
31. Barton, S.E.; Gargiulo, A.R. Robot-assisted laparoscopic myomectomy and adenomyomectomy with a flexible CO_2 laser device. *J. Robot. Surg.* **2013**, *7*, 157–162. [CrossRef] [PubMed]
32. Zhao, J.; Liao, Y.; Huang, J.; Cheng, J.; Xiong, J.; Liao, J.; Zhang, W. Robot-assisted versus transumbilical laparoendoscopic single-site surgery in gynecological procedures: A retrospective comparative analysis of efficacy. *Intell. Surg.* **2025**, *8*, 76–83. [CrossRef]
33. Kuijsters, N.P.M.; Methorst, W.G.; Kortenhorst, M.S.Q.; Rabotti, C.; Mischi, M.; Schoot, B.C. Uterine peristalsis and fertility: Current knowledge and future perspectives: A review and meta-analysis. *Reprod. Biomed. Online* **2017**, *35*, 50–71. [CrossRef] [PubMed]
34. Bourdon, M.; Santulli, P.; Jeljeli, M.; Vannuccini, S.; Marcellin, L.; Doridot, L.; Petraglia, F.; Batteux, F.; Chapron, C. Immunological changes associated with adenomyosis: A systematic review. *Hum. Reprod. Update* **2021**, *27*, 108–129. [CrossRef]
35. Kwack, J.Y.; Im, K.S.; Kwon, Y. Conservative surgery of uterine adenomyosis via laparoscopic versus laparotomic approach in a single institution. *J. Obstet. Gynaecol. Res.* **2018**, *44*, 1268–1273. [CrossRef]
36. Raffone, A.; Raimondo, D.; Oliviero, A.; Raspollini, A.; Travaglino, A.; Torella, M.; Riemma, G.; La Verde, M.; De Franciscis, P.; Casadio, P.; et al. The Use of near Infra-Red Radiation Imaging after Injection of Indocyanine Green (NIR–ICG) during Laparoscopic Treatment of Benign Gynecologic Conditions: Towards Minimalized Surgery. A Systematic Review of Literature. *Medicina* **2022**, *58*, 792. [CrossRef]

37. Kwack, J.Y.; Kwon, Y.S. Laparoscopic Surgery for Focal Adenomyosis. *JSLS J. Soc. Laparosc. Robot. Surg.* **2017**, *21*, e2017.00014. [CrossRef]
38. Surico, D.; Aquino, C.I.; Vigone, A.; Ferrante, D.; Baldi, S.; Bracci, B.; Libretti, A.; Remorgida, V. Robot-assisted hysterectomy for endometrial cancer: Is there a correlation between uterine diameters, pelvic volume, and surgical outcomes? *J. Robot. Surg.* **2025**, *19*, 661. [CrossRef]
39. Parker, W.H.; Einarsson, J.; Istre, O.; Dubuisson, J.B. Risk Factors for Uterine Rupture after Laparoscopic Myomectomy. *J. Minim. Invasive Gynecol.* **2010**, *17*, 551–554. [CrossRef]

Disclaimer/Publisher's Note: The statements, opinions and data contained in all publications are solely those of the individual author(s) and contributor(s) and not of MDPI and/or the editor(s). MDPI and/or the editor(s) disclaim responsibility for any injury to people or property resulting from any ideas, methods, instructions or products referred to in the content.