surgeries

MDPI

Article

Massive Pulmonary Hemorrhage After Pulmonary Endarterectomy: Updated Outcomes of a Standardized Management Protocol over 14 Years

Cagatay Cetinkaya [1,*], Sehnaz Olgun Yildizeli [2], Altug Sagir [3], Mustafa Emre Kavlak [4] and Bedrettin Yildizeli [5]

[1] Department of Thoracic Surgery, School of Medicine, Üsküdar University, Istanbul 34768, Turkey
[2] Department of Pulmonology, School of Medicine, Marmara University, Istanbul 34854, Turkey
[3] Department of Cardiovascular Surgery, School of Medicine, Üsküdar University, Istanbul 34768, Turkey
[4] Deparment of Anesthesia, School of Medicine, Üsküdar University, Istanbul 34768, Turkey
[5] Department of Thoracic Surgery, School of Medicine, Marmara University, Istanbul 34854, Turkey
* Correspondence: drcagataycet@gmail.com

Abstract

Background: Massive pulmonary hemorrhage is a life-threatening complication of pulmonary endarterectomy (PEA) with limited evidence to guide standardized management. Methods: We retrospectively evaluated consecutive PEA procedures performed at a high-volume center and analyzed the incidence, perioperative characteristics, management strategies, and early outcomes of patients who developed massive pulmonary hemorrhage. Results: Among 1123 patients who underwent PEA, massive pulmonary hemorrhage occurred in 51 (4.54%) and developed intraoperatively after completion of PEA and separation from total circulatory arrest. Primary suturing achieved hemostasis in 12 patients (23.5%), and bronchial isolation was applied in 18 (35.3%). Local adjuncts included intraoperative bronchial clamping in 1 patient (2.0%) and biological glue occlusion in 2 (3.9%). Extracorporeal membrane oxygenation (ECMO) was required in 25 patients (49.0%), initiated intraoperatively in 22 and postoperatively in 3. Overall in-hospital mortality was 41.2%, while 30 patients (58.8%) survived to hospital discharge; among survivors, mean hospital length of stay was 16.1 $\pm$ 6.8 days. Conclusions: Massive pulmonary hemorrhage after PEA remains associated with substantial early mortality and resource utilization; a stepwise institutional algorithm combining bronchoscopy-guided localization, targeted airway/surgical control, and timely ECMO support may help standardize management in this critical setting.

Keywords: pulmonary endarterectomy; chronic thromboembolic pulmonary hypertension; extracorporeal membrane oxygenation; massive pulmonary hemorrhage; perioperative complications

Check for updates

Academic Editor: Paul Quax

Received: 18 February 2026
Revised: 20 March 2026
Accepted: 30 March 2026
Published: 30 March 2026

Copyright: © 2026 by the authors. Licensee MDPI, Basel, Switzerland. This article is an open access article distributed under the terms and conditions of the Creative Commons Attribution (CC BY) license.

1. Introduction

Pulmonary endarterectomy (PEA) remains the definitive and potentially curative treatment for patients with chronic thromboembolic pulmonary hypertension (CTEPH). Recent data from expert centers show that PEA markedly improves hemodynamics, functional capacity, and survival, reinforcing its central role as first-line therapy for operable disease [1,2]. The success of the procedure depends on meticulous endarterectomy of the

intima and organized thromboembolic material, extending into the media of the affected pulmonary arteries.

Despite advances in surgical technique and perioperative care, pulmonary or airway hemorrhage remains one of the most serious complications of PEA. The reported incidence of pulmonary hemorrhage after PEA ranges from approximately 1% to 7% in contemporary series [3,4]. This complication is consistently associated with high postoperative mortality.

Given its acute and often life-threatening nature, early recognition and structured management of pulmonary hemorrhage are critical for optimizing outcomes. Initial management priorities include hemodynamic stabilization, maintenance of gas exchange, and rapid identification of the bleeding source. Over the past decade, high-volume PEA centers have underscored the importance of standardized protocols incorporating bronchoscopy, selective airway isolation, and timely escalation to extracorporeal support.

Our center has accumulated substantial experience in this domain, having reported one of the earliest case descriptions of massive pulmonary hemorrhage after PEA in 2014 [5] and later presenting an expanded cohort describing management principles and outcomes in 2018 [6]. These publications highlighted a multimodal strategy combining early bronchoscopy, bronchial isolation, optimization of ventilation parameters, and selective use of extracorporeal membrane oxygenation (ECMO). Despite these contributions, contemporary literature still offers limited systematic data on standardized management protocols and their real-world outcomes in larger surgical populations.

With expanding institutional experience and a growing PEA volume, our unchanged management protocol has now been applied to a much larger population. This study presents 14-year updated outcomes, evaluating the effectiveness of this standardized approach in massive pulmonary hemorrhage after PEA.

2. Patients and Methods

2.1. Study Design and Patient Selection

This study was conducted using a prospectively maintained database of all patients who underwent pulmonary endarterectomy (PEA) performed by the same surgical team at two high-volume centers between March 2011 and December 2025. A total of 1123 patients underwent PEA during the study period, of whom 51 (4.54%) developed massive pulmonary hemorrhage and were included in the analysis. Demographic characteristics, preoperative clinical data, and perioperative outcomes were evaluated retrospectively.

2.2. Diagnosis and Operability Assessment

The diagnosis of chronic thromboembolic pulmonary hypertension (CTEPH) was established using ventilation–perfusion scintigraphy demonstrating mismatched perfusion defects, computed tomography pulmonary angiography (CTPA), and right heart catheterization (RHC). All patients had echocardiographic evidence of pulmonary hypertension despite at least three months of anticoagulation. Operability was determined by the multidisciplinary CTEPH team based on New York Heart Association functional class > II, absence of prohibitive comorbidities, and imaging evidence of surgically accessible thromboembolic obstruction.

2.3. Definition of Massive Pulmonary Hemorrhage

Massive pulmonary hemorrhage was defined as significant intrabronchial bleeding compromising oxygenation or ventilation, observed either intraoperatively during separation from cardiopulmonary bypass (CPB) or postoperatively, and requiring bronchoscopic evaluation, bronchial blockade, cessation of anticoagulation, correction of coagulopathy, and/or extracorporeal membrane oxygenation (ECMO) support, consistent with defini-

tions used in previous pulmonary endarterectomy series and major airway hemorrhage reports [1,4].

2.4. Surgical Technique

All PEA procedures were performed under deep hypothermia (20 °C) and intermittent circulatory arrest, following previously described operative principles [7]. A true endarterectomy plane was established bilaterally, and circulation was gradually restored with rewarming. Particular care was taken during CPB weaning to detect early signs of airway bleeding. Intraoperative assessment for potential arterial wall injury included selective use of the bubbling technique described by Morsolini et al. [8].

2.5. Management Protocol for Pulmonary Hemorrhage

The management of massive pulmonary hemorrhage followed a standardized algorithm applied throughout the study period:

1. Intraoperative assessment for pulmonary hemorrhage was routinely performed using a combination of the bubble technique and fiberoptic bronchoscopy (FOB) immediately after completion of pulmonary endarterectomy and during reperfusion. The bubble technique, as described by Morsolini et al., was used to detect and localize active pulmonary arterial bleeding, while FOB was simultaneously performed to assess the airway, characterize the appearance of hemorrhage, and evaluate its impact on ventilation.
2. Conservative measures included airway suctioning, hyperventilation, lung-protective ventilation adjustments, temporary cessation or reversal of anticoagulation, and correction of coagulopathy as needed. These measures were initiated immediately upon identification of pulmonary hemorrhage, either intraoperatively during separation from cardiopulmonary bypass or postoperatively, and were continued as part of the initial stabilization phase prior to escalation to surgical repair, bronchial isolation, or extracorporeal support. Coagulation correction was guided by institutional transfusion targets, including platelet count > 100,000/μL, fibrinogen level > 150–200 mg/dL, and normalization of INR and activated partial thromboplastin time where feasible, particularly in patients requiring ongoing ECMO support.
3. When bleeding was associated with a pulmonary arterial tear, the lesion was evaluated for surgical repairability.
    - If repairable, primary suturing of the tear was performed under circulatory arrest.
    - If the lesion was not suitable for suturing, biological glue was applied to achieve local hemostasis, followed by reassessment.
4. In cases of focal airway bleeding or persistent hemorrhage affecting gas exchange, bronchial isolation was achieved using an endobronchial blocker to protect the contralateral lung and maintain ventilation.
5. Venoarterial ECMO was instituted in cases of persistent hypoxemia, hemodynamic instability, or refractory hemorrhage despite initial interventions.
6. Bronchial blocker removal and ECMO weaning were considered after 24–48 h, provided there was no ongoing bleeding and gas exchange had adequately improved.

The stepwise algorithm used for the management of pulmonary hemorrhage during or after separation from CPB is illustrated in Figure 1.

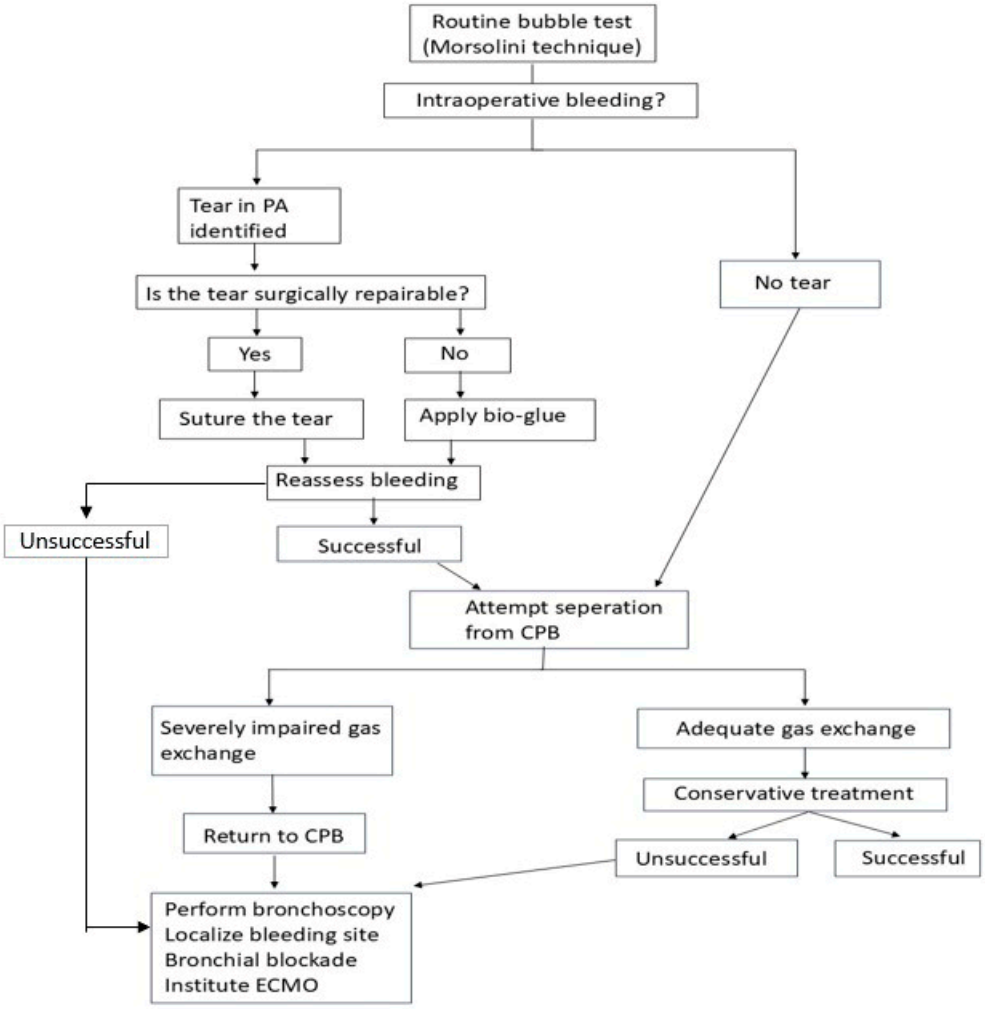

Figure 1. Institutional algorithm for the management of intraoperative and early postoperative pulmonary hemorrhage during pulmonary endarterectomy. Abbreviations: CPB = cardiopulmonary bypass; PA = pulmonary artery; ECMO = extracorporeal membrane oxygenation.

2.6. Collected Variables

Preoperative variables included patient age, sex, World Health Organization (WHO) functional class, six-minute walk distance, duration of symptoms until PEA, comorbidities, smoking history, and baseline hemodynamic measurements obtained by right heart catheterization, including mean pulmonary arterial pressure (mPAP), pulmonary vascular resistance (PVR), and cardiac output.

Intraoperative data encompassed cardiopulmonary bypass duration, aortic cross-clamp time, total circulatory arrest time, predominant side of disease, surgical level of endarterectomy, and detailed descriptions of any intraoperative bleeding events.

Hemorrhage-related parameters included the timing of hemorrhage (intraoperative or postoperative), estimated severity, use of bronchial blockade, requirement for extracorporeal membrane oxygenation (ECMO) with specification of VA or VV configuration, ECMO duration, and transfusion needs.

Postoperative outcome measures included duration of mechanical ventilation, intensive care unit and hospital length of stay, need for reintervention, major complications, in-hospital and 30-day mortality, and follow-up hemodynamic improvement.

No generative artificial intelligence tools were used for data generation, analysis, interpretation, or study design. AI-assisted tools were used solely for language editing and grammatical refinement.

2.7. Statistical Analysis

Continuous variables are presented as mean ± standard deviation or median (range), as appropriate. Categorical variables are expressed as frequencies and percentages. In-hospital and 30-day mortality rates were compared between patients with and without massive pulmonary hemorrhage using the χ^2 test or Fisher's exact test when expected cell counts were small. All statistical analyses were performed using SPSS software (version 25.0).

2.8. Ethical Approval

The study protocol was approved by the institutional ethics committee(s), and all procedures were conducted in accordance with the Declaration of Helsinki.

3. Results

3.1. Study Population

Between March 2011 and December 2025, a total of 1123 patients underwent pulmonary endarterectomy (PEA) performed by the same surgical team across two centers. Massive pulmonary hemorrhage developed in 51 patients (4.54%), who constituted the study cohort.

The mean age of patients with pulmonary hemorrhage was 51.3 ± 16.5 years. The cohort included 25 males (49.0%) and 26 females (51.0%). One patient (2.0%) was in the pediatric age group (16 months old). Baseline demographic characteristics of the hemorrhage cohort are summarized in Table 1.

Table 1. Demographic and preoperative clinical characteristics of patients with massive pulmonary hemorrhage after PEA.

Characteristics	*n* (%)	Mean ± SD	Min–Max
Age (year)		51.3 ± 16.5	1.3–75
Gender			
Male	25 (49%)		
Female	26 (51%)		
Body mass index		26.3 ± 4.9 kg/m^2	14.9–38.2 kg/m^2
6 min walking test (meters)		197.9 ± 152.7	0–495
WHO Classification			
Class II	2 (3.9%)		
Class III	31 (60.8%)		
Class IV	18 (35.3%)		
mPAP (mm Hg)		71.1 ± 27.4	19–159
TAPSE (mm)		16.7 ± 4.5	7–27
Preoperative PVR (dyn·s·cm^{-5})		725.6 ± 359.3	264–1692
Cardiopulmonary bypass (min)		257.8 ± 83.7	150–560
Aortic cross-clamp (min)		39.9 ± 30.9	2–109
Total circulatory arrest (min)		25.6 ± 10.0	1–45

Abbreviations: PEA: pulmonary endarterectomy; WHO: World Health Organization; mPAP: mean pulmonary artery pressure; TAPSE: Tricuspid annular plane systolic excursion; PVR: Pulmonary vascular resistance.

3.2. Preoperative Clinical Characteristics and Risk Factors

Preoperatively, the majority of patients were in an advanced functional stage, with 31 patients (60.8%) classified as WHO functional class III and 18 patients (35.3%) as class IV, resulting in 96.1% of the cohort being in WHO class III–IV. A history of non-massive hemoptysis prior to surgery was present in 4 patients (7.8%).

A history of thromboembolic disease was present in all patients, consistent with the diagnosis of chronic thromboembolic pulmonary hypertension. Isolated pulmonary embolism without associated systemic disease was documented in 34 patients (66.7%). In the remaining patients, pulmonary embolism was associated with underlying systemic or predisposing conditions, including Behçet disease in 4 patients (7.8%), systemic lupus erythematosus in 3 patients (5.9%), and antiphospholipid syndrome in 1 patient (2.0%). Deep vein thrombosis without a clearly documented episode of pulmonary embolism was present in 3 patients (5.9%), although the diagnosis of CTEPH confirmed prior thromboembolic involvement.

Additional predisposing conditions included inherited thrombophilia (Factor V Leiden and prothrombin gene mutation) in 1 patient (2.0%), prior splenectomy in 2 patients (3.9%), trauma-related risk factors in 1 patient (2.0%), and chronic renal failure requiring dialysis in 1 patient (2.0%). Laboratory-based autoimmune markers without a definitive systemic diagnosis were noted in 1 patient (2.0%). Some patients had more than one identified risk factor.

Preoperative echocardiographic evaluation showed a mean systolic pulmonary artery pressure of 71.1 ± 27.4 mmHg. Mean left ventricular ejection fraction was 61.7 ± 4.7%, and mean tricuspid annular plane systolic excursion (TAPSE) was 16.7 ± 4.5 mm. Functional capacity assessment revealed a mean six-minute walk distance of 197.9 ± 152.7 m.

3.3. Intraoperative Characteristics

The mean aortic cross-clamp time was 39.9 ± 30.9 min (range, 2–109 min). The mean cardiopulmonary bypass duration was 257.8 ± 83.7 min (range, 150–560 min), and the mean total circulatory arrest time was 25.6 ± 10.0 min (range, 1–45 min).

Pulmonary hemorrhage developed intraoperatively in all patients following completion of pulmonary endarterectomy and after separation from total circulatory arrest.

3.4. Perioperative Management and Early Postoperative Outcomes

Primary suturing alone achieved hemostasis in 12 patients (23.5%). Bronchial isolation was employed in 18 patients (35.3%), either as a standalone strategy or in combination with ECMO support. Extracorporeal membrane oxygenation (ECMO) support was required in 25 patients (49.0%). ECMO was instituted intraoperatively in 22 patients to facilitate separation from cardiopulmonary bypass, including 19 patients who received venoarterial (VA) ECMO and 3 patients who received venovenous (VV) ECMO. In the postoperative period, ECMO support was initiated in 3 additional patients, including 2 managed with VA ECMO and 1 with VV ECMO. Overall, a total of 21 patients received VA ECMO and 4 patients received VV ECMO. Among patients receiving ECMO support, 16 patients were managed with ECMO alone, 5 patients received combined ECMO and bronchial blockade, and 1 patient underwent ECMO support in conjunction with intraoperative bronchial clamping. One patient required postoperative ECMO following bronchial stapling. Successful weaning from ECMO and hospital discharge were achieved in 9 of the 25 patients (36.0%) who required ECMO support.

Among patients managed with bronchial blockade alone, 11 of 12 patients survived to hospital discharge, while 1 patient died due to sepsis-related complications. Both patients treated with biological glue occlusion (one combined with bronchial blockade and one as a standalone intervention) survived and were discharged. Management strategies and early postoperative outcomes, including the need for ECMO support and survival to hospital discharge, are summarized in Table 2.

Table 2. Management strategies and early outcomes in patients with massive pulmonary hemorrhage after PEA.

Management Strategy	*n* (%)	ECMO Required	Survival to Discharge
Suture only	12 (23.5%)	No	8/12 (66.6%)
Bronchial blocker only	12 (23.5%)	No	11/12 (91.7%)
Bronchial blocker + BioGlue	1 (2.0%)	No	1/1 (100%)
BioGlue only	1 (2.0%)	No	1/1 (100%)
ECMO only	16 (31.4%)	Yes	7/16 (43.75%)
ECMO + bronchial blocker	5 (9.8%)	Yes	1/5 (20%)
ECMO + surgical clamping	1 (2.0%)	Yes	0/1 (0%)
Postoperative ECMO	3 (5.9%)	Yes	1/3 (33.3%)
Total	51 (100%)	25 (49.0%)	30/51 (58.8%)

Abbreviations: ECMO: extracorporeal membrane oxygenation; PEA: pulmonary endarterectomy.

Overall in-hospital mortality in the cohort was 21 patients (41.2%). Among the 30 patients who survived to hospital discharge, the mean length of hospital stay was 16.1 ± 6.8 days (range, 8–34 days).

4. Discussion

This study reports updated outcomes of a standardized management approach for massive pulmonary hemorrhage following pulmonary endarterectomy over a 14-year period. Among 1123 patients undergoing PEA, massive pulmonary hemorrhage occurred in 51 patients, indicating that although uncommon, this complication remains clinically relevant and associated with substantial morbidity and mortality. The present analysis builds on our previously published experience by including a larger and more recent cohort and provides updated data on perioperative characteristics, management strategies, and early outcomes [5,6]. Our findings reflect the real-world use of a structured treatment algorithm within an experienced PEA program and place current management practices into a contemporary clinical context.

The reported incidence of airway or pulmonary hemorrhage following pulmonary endarterectomy in the literature ranges between approximately 1% and 7%, depending on case definitions and institutional experience. In a large contemporary series by Kabadi et al., postoperative airway hemorrhage occurred in 6.6% of patients undergoing PEA and was associated with a significantly higher early mortality compared with patients without hemorrhage [4]. Similarly, Guth et al. reported that massive endobronchial hemorrhage represents a rare but particularly severe complication that frequently necessitates advanced supportive measures, including extracorporeal membrane oxygenation [3]. In the present study, massive pulmonary hemorrhage occurred in 4.54% of patients, which is consistent with previously reported ranges. Despite its relatively low incidence, the observed mortality rate underscores the substantial clinical impact of this complication and supports prior observations that pulmonary hemorrhage remains one of the most critical determinants of early outcome after PEA.

Management of massive pulmonary hemorrhage after pulmonary endarterectomy requires rapid identification of the bleeding source and timely escalation of supportive measures. In our cohort, all hemorrhagic events occurred intraoperatively after completion of endarterectomy and separation from total circulatory arrest, emphasizing the need for immediate intraoperative decision-making. A structured, stepwise strategy based on early bronchoscopic evaluation, selective airway isolation, and escalation to extracorporeal support was applied.

In cases of massive pulmonary hemorrhage after PEA, bronchial isolation represents an important initial management strategy when bleeding is focal and anatomically localized. In our cohort, bronchial blockade was utilized in 18 of 51 patients (35.3%), either as a standalone intervention or in combination with other local measures. Among patients managed with bronchial blockade alone, survival to hospital discharge was achieved in 11 of 12 cases. The use of endobronchial blockers for focal airway bleeding after PEA has also been described in previous reports, including the series by Kabadi et al. and the case-based experience reported by Bonta et al., supporting its role as an effective first-line intervention in selected patients [4,9].

When bronchial isolation alone was insufficient or not feasible, additional local surgical measures were employed to control hemorrhage. In our series, intraoperative surgical bronchial clamping was performed in 1 patient, and bronchial occlusion using biological glue was applied in 2 patients. All patients managed with biological glue, either alone or in combination with bronchial blockade, achieved successful hemorrhage control and survived to hospital discharge. Although data on biological sealants for post-PEA pulmonary hemorrhage are limited, glue-based hemostatic techniques have been reported as effective adjunctive measures in the control of severe hemoptysis, supporting their potential role in selected cases with focal airway bleeding. Our findings suggest that targeted local interventions may be effective in carefully selected cases with focal bleeding and preserved respiratory stability [10].

These outcomes are comparable with larger contemporary series. In the UK national cohort reported by Chia et al., perioperative ECMO was required in 4.7% of PEA patients, including 31 cases for endobronchial bleeding, with 56.4% successfully weaned and 51.8% surviving to hospital discharge [11]. Similarly, Kelava et al. reported an in-hospital survival rate of 43% among PEA patients requiring ECMO support, highlighting the substantial mortality associated with this intervention despite its life-saving potential [12].

Taken together, these findings support ECMO as a critical rescue therapy rather than a definitive treatment, reflecting disease severity rather than treatment failure. Our relatively high ECMO utilization likely reflects a low threshold for early deployment in the setting of massive hemorrhage, aiming to stabilize gas exchange and hemodynamics while definitive hemorrhage control is achieved.

Antifibrinolytic agents such as tranexamic acid (TXA) are widely used in cardiac and thoracic surgery to reduce perioperative bleeding and transfusion requirements [13]. However, in pulmonary endarterectomy, massive pulmonary hemorrhage is typically related to mechanical disruption of pulmonary arterial branches rather than fibrinolysis-driven bleeding, and management strategies primarily focus on mechanical hemorrhage control, including bronchial isolation, surgical repair, and extracorporeal support [3,4]. Consequently, antifibrinolytic therapy was not routinely included in our institutional management protocol. Nevertheless, TXA may serve as an adjunctive therapy in selected cases, and its potential role in this setting warrants further investigation.

In addition, point-of-care coagulation monitoring using viscoelastic assays such as thromboelastography (TEG) or rotational thromboelastometry (ROTEM) has been increasingly utilized in cardiac surgery to guide transfusion strategies and improve perioperative hemostatic management. These modalities may provide a more comprehensive assessment of coagulation status in complex cases, including those undergoing prolonged cardiopulmonary bypass. Although such techniques were not routinely incorporated into our institutional protocol during the study period, their potential role in optimizing coagulation management in patients with massive pulmonary hemorrhage after PEA warrants further investigation [14].

Massive pulmonary hemorrhage after PEA was associated with high mortality in our cohort, with an overall mortality rate of 41.2%. This reflects the severity of hemorrhage in patients requiring advanced rescue therapies rather than failure of a single management strategy.

In the literature, mortality varies according to hemorrhage severity and the need for advanced support. Kabadi et al. reported a mortality rate of 13.8% in patients with postoperative airway hemorrhage, most of whom were managed without ECMO [4]. In contrast, ECMO-based series report substantially higher mortality. Chia et al. demonstrated a hospital survival rate of 51.8% in patients supported with ECMO for severe perioperative complications, including endobronchial bleeding [11], while Kelava et al. reported an in-hospital mortality of 57% in ECMO-supported PEA patients [12]. In this context, the mortality observed in our study is consistent with cohorts characterized by severe hemorrhage requiring aggressive intervention.

The structured management algorithm applied in this study emphasizes early localization of bleeding, stepwise escalation from bronchial isolation to surgical or extracorporeal support, and timely multidisciplinary decision-making. This approach allowed individualized management based on hemorrhage severity and physiological compromise, facilitating rapid transition to advanced support when conservative measures were insufficient.

This study has several limitations. First, the retrospective design may introduce selection and information bias, despite the use of a prospectively maintained database. Second, management decisions—including the choice and timing of bronchial blockade, surgical interventions, and ECMO support—were individualized and influenced by clinical judgment, precluding standardized comparative analysis between treatment modalities. Third, this study was specifically designed to evaluate the incidence, management, and early outcomes of massive pulmonary hemorrhage, and a formal comparative analysis with patients who did not develop pulmonary hemorrhage was beyond the scope of the current investigation. Such comparative analyses may provide additional insights into risk factors and outcome differences. Finally, long-term functional and hemodynamic outcomes were not systematically evaluated, limiting conclusions to early postoperative results.

5. Conclusions

Massive pulmonary hemorrhage after pulmonary endarterectomy remains a rare but highly lethal complication, requiring prompt recognition and decisive management. In this large single-team experience, a stepwise treatment strategy incorporating bronchial isolation, selective local surgical interventions, and timely use of extracorporeal membrane oxygenation enabled individualized management according to hemorrhage severity and physiological deterioration. Bronchial blockade proved effective in selected patients with focal bleeding, while ECMO served as a crucial rescue modality in cases with refractory hypoxemia or hemodynamic instability. These findings support the use of a structured, escalation-based management algorithm and highlight the importance of multidisciplinary expertise in high-volume PEA programs to improve early outcomes in this life-threatening complication.

Author Contributions: Conceptualization, C.C. and S.O.Y.; Methodology, C.C.; Data curation, C.C., A.S., and B.Y.; Formal analysis, C.C. and M.E.K.; Investigation, C.C., A.S. and M.E.K.; Writing—original draft preparation, C.C.; Writing—review and editing, B.Y., S.O.Y., and M.E.K.; Supervision, B.Y. All authors have read and agreed to the published version of the manuscript.

Funding: This research received no external funding.

Institutional Review Board Statement: The study was conducted in accordance with the Declaration of Helsinki and approved by the Ethics Committee of Marmara University Faculty of Medicine (approval code: 09.2026.608; date of approval: 22 January 2026).

Informed Consent Statement: Patient consent was waived due to the retrospective nature of the study. All data were anonymized, and no identifiable personal information was included.

Data Availability Statement: The data presented in this study are available on request from the corresponding author. The data are not publicly available due to institutional and ethical restrictions regarding patient confidentiality.

Conflicts of Interest: The authors declare no conflicts of interest.

References

1. Madani, M.M.; Wiedenroth, C.B.; Jenkins, D.P.; Fadel, E.; de Perrot, M. Pulmonary Thromboendarterectomy: The Potentially Curative Treatment of Choice for Chronic Thromboembolic Pulmonary Hypertension. *Ann. Thorac. Surg.* **2025**, *119*, 756–767. [CrossRef] [PubMed]
2. Kim, N.H.; D'Armini, A.M.; Delcroix, M.; Jaïs, X.; Jevnikar, M.; Madani, M.M.; Matsubara, H.; Palazzini, M.; Wiedenroth, C.B.; Simonneau, G.; et al. Chronic thromboembolic pulmonary disease. *Eur. Respir. J.* **2024**, *64*, 2401294. [CrossRef] [PubMed] [PubMed Central]
3. Guth, S.; Wiedenroth, C.B.; Wollenschläger, M.; Richter, M.J.; Ghofrani, H.A.; Arlt, M.; Mayer, E. Short-term venoarterial extracorporeal membrane oxygenation for massive endobronchial hemorrhage after pulmonary endarterectomy. *J. Thorac. Cardiovasc. Surg.* **2018**, *155*, 643–649. [CrossRef] [PubMed]
4. Kabadi, A.A.; Fernandes, T.M.; Papamatheakis, D.G.; Poch, D.S.; Kim, N.H.; Yang, J.Z.; Bautista, A.; Pretorius, V.G.; Madani, M.M.; Kerr, K.M. Airway Hemorrhage Complicating Pulmonary Thromboendarterectomy: Risk Factors and Outcomes. *Ann. Thorac. Surg.* **2023**, *116*, 121–128. [CrossRef] [PubMed]
5. Yıldızeli, B.; Arslan, Ö.; Taş, S.; Eldem, B.; Aksoy, E.; Koçak, T.; Sunar, H. Management of massive pulmonary hemorrhage following pulmonary endarterectomy. *Thorac. Cardiovasc. Surg.* **2014**, *62*, 89–91. [PubMed]
6. Yıldızeli, Ş.O.; Erkılınç, A.; Yanartaş, M.; Taş, S.; Sunar, H.; Gürcü, E.; Yıldızeli, B. Perioperative management of massive pulmonary hemorrhage after pulmonary endarterectomy. *Turk. J. Thorac. Cardiovasc. Surg.* **2018**, *26*, 429–435. [CrossRef] [PubMed] [PubMed Central]
7. Yıldızeli, B.; Taş, S.; Yanartaş, M.; Kaymaz, C.; Mutlu, B.; Karakurt, S.; Altınay, E.; Eldem, B.; Ermerak, N.O.; Batırel, H.F.; et al. Pulmonary endarterectomy for chronic thrombo-embolic pulmonary hypertension: An institutional experience. *Eur. J. Cardiothorac. Surg.* **2013**, *44*, 219–227. [CrossRef] [PubMed]
8. Morsolini, M.; Azzaretti, A.; Orlandoni, G.; D'Armini, A.M. Airway bleeding during pulmonary endarterectomy: The "bubbles" technique. *J. Thorac. Cardiovasc. Surg.* **2013**, *145*, 1409–1410. [CrossRef] [PubMed]
9. Bonta, P.I.; Tramper, J.; Eberl, S.; Tepaske, R.; Nossent, E.J.; Vonk-Noordgraaf, A.; Bogaard, H.J.; Symersky, P. Endobronchial blocker use for massive, focal pulmonary hemorrhage during pulmonary endarterectomy for CTEPH. *J. Heart Lung Transplant.* **2022**, *41*, 1130–1133. [CrossRef] [PubMed]
10. Shamseldin, M.; Kluge, J.; Bauer, J.U.; Puls, R. Efficacy and safety of treating acute haemoptysis using glue embolization: A retrospective observational study and comparison to the literature. *J. Med. Imaging Radiat. Oncol.* **2024**, *68*, 177–184. [CrossRef] [PubMed]
11. Chia, A.X.F.; Valchanov, K.; Ng, C.; Tsui, S.; Taghavi, J.; Vuylsteke, A.; Fowles, J.A.; Jenkins, D.P. Perioperative extracorporeal membrane oxygenation support for pulmonary endarterectomy: A 17-year experience from the UK national cohort. *J. Heart Lung Transplant.* **2024**, *43*, 241–250. [CrossRef] [PubMed]
12. Kelava, M.; Koprivanac, M.; Smedira, N.; Mihaljevic, T.; Alfirevic, A. Extracorporeal Membrane Oxygenation in Pulmonary Endarterectomy Patients. *J. Cardiothorac. Vasc. Anesth.* **2019**, *33*, 60–69. [CrossRef] [PubMed]
13. Ker, K.; Edwards, P.; Perel, P.; Shakur, H.; Roberts, I. Effect of tranexamic acid on surgical bleeding: Systematic review and cumulative meta-analysis. *BMJ* **2012**, *344*, e3054. [CrossRef] [PubMed] [PubMed Central]
14. Whiting, D.; DiNardo, J.A. TEG and ROTEM: Technology and clinical applications. *Am. J. Hematol.* **2014**, *89*, 228–232. [CrossRef] [PubMed]

Disclaimer/Publisher's Note: The statements, opinions and data contained in all publications are solely those of the individual author(s) and contributor(s) and not of MDPI and/or the editor(s). MDPI and/or the editor(s) disclaim responsibility for any injury to people or property resulting from any ideas, methods, instructions or products referred to in the content.