osteology

MDPI

Systematic Review

Comparative Analysis of Latarjet Procedure and Free Bone Block Techniques in the Management of Anterior Shoulder Instability: An Updated Systematic Review and Meta-Analysis

Umile Giuseppe Longo [1,2,*], Sergio De Salvatore [2,3], Beniamino Macaluso [2], Francesco Bellomi [2], Ara Nazarian [4], Diana Giannarelli [5], Pieter D'Hooghe [6] and Vincenzo Denaro [1,2]

1 Fondazione Policlinico Universitario Campus Bio-Medico, Via Alvaro del Portillo, 200, Trigoria, 00128 Rome, Italy; denaro.cbm@gmail.com
2 Research Unit of Orthopaedic and Trauma Surgery, Department of Medicine and Surgery, Università Campus Bio-Medico di Roma, 00128 Roma, Italy; s.desalvatore@unicampus.it (S.D.S.); beniamino.macaluso@alcampus.it (B.M.); francesco.bellomi@alcampus.it (F.B.)
3 Department of Orthopedics, Children's Hospital Bambino Gesù, Palidoro, 00165 Rome, Italy
4 Musculoskeletal Translational Innovation Initiative, Carl J. Shapiro Department of Orthopaedic Surgery and Center for Advanced Orthopaedic Studies, Beth Israel Deaconess Medical Center, Harvard Medical School, Boston, MA 20115, USA; anazaria@bidmc.harvard.edu
5 Department of Statistics, Fondazione Policlinico Universitario A. Gemelli IRCCS, Largo A. Gemelli 8, 00168 Rome, Italy; diana.giannarelli@gmail.com
6 Aspetar Orthopedic and Sports Medicine Hospital, Doha P.O. Box 29222, Qatar; pieter.dhooghe@aspetar.com
* Correspondence: g.longo@policlinicocampus.it; Tel.: +39-06-225411613

Abstract

Background/Objectives: This updated systematic review and meta-analysis provide a focused synthesis of contemporary evidence on clinical outcomes reported after the Latarjet procedure and Free Bone Block (FBB) techniques for anterior shoulder instability, focusing on recurrence, patient-reported outcome measures (PROMs), return to sport, complications, and osteoarthritis progression. Given that most available studies report single-procedure cohorts, between-technique comparisons were interpreted in the context of indirect evidence and study-level heterogeneity. **Methods**: A systematic review and meta-analysis were conducted according to PRISMA 2020 guidelines. The updated search included studies published from 2019 to May 2024 and was integrated with 70 studies from the previous review that were re-screened according to the same eligibility criteria. Eligible studies reported outcomes for the Latarjet or FBB procedure, with a minimum 2-year follow-up and at least five patients in the relevant treatment cohort. Risk of bias was assessed using the RoB 2 and MINORS tools. Outcomes were synthesized using random-effects meta-analysis. Pooled estimates were calculated separately for each procedure, and between-technique contrasts were treated as exploratory and descriptive when appropriate. Heterogeneity was assessed using I^2. **Results**: Ninety-eight studies with 6043 patients and 6071 shoulders were included: 72 on Latarjet, 23 on FBB, and 3 direct comparative studies. Both procedures were associated with low recurrence rates, improved PROMs, and comparable return-to-sport rates. Recurrence was 7% for Latarjet and 5% for FBB. Return to sport was 66% after Latarjet and 65% after FBB. Complication rates were 5% for Latarjet and 8% for FBB, while osteoarthritis progression was 12% and 9%, respectively. PROMs improved after both techniques, although differences between procedures should be interpreted cautiously because of the indirect nature of most comparisons and substantial heterogeneity across studies. **Conclusions**: Both Latarjet and FBB procedures were associated with generally favorable outcomes for anterior shoulder instability with bone loss in the included studies. The available evidence suggests broadly comparable clinical outcomes, with possible

Check for updates

Academic Editor: Yuta Tachibana

Received: 20 November 2025
Revised: 8 June 2026
Accepted: 12 June 2026
Published: 17 June 2026

Copyright: © 2026 by the authors. Licensee MDPI, Basel, Switzerland. This article is an open access article distributed under the terms and conditions of the Creative Commons Attribution (CC BY) license.

differences in complication profile, recurrence pattern, and osteoarthritis progression. However, these findings should be interpreted considering differences in patient characteristics, follow-up duration, surgical technique, graft type, and outcome definitions across studies. Current evidence does not allow definitive conclusions regarding the superiority of one technique over the other, but it provides useful descriptive outcome profiles to inform clinical decision-making and guide future direct comparative research.

Keywords: anterior shoulder instability; Latarjet procedure; bone block; glenoid bone loss

1. Introduction

Anterior shoulder instability represents a frequent clinical issue, particularly in young and active individuals, and is often characterized by a high recurrence rate following traumatic dislocation events [1,2]. Shoulder dislocation occurs at an incidence of 10 per 100,000 person-years, with similar data reported across Western Europe and North America [1,3]. In athletic populations, anterior shoulder instability represents more than 85% of all traumatic dislocations, particularly among individuals engaged in contact or overhead sports such as rugby, football, and handball.

The first dislocation often marks the beginning of a pathological course characterized by recurrent instability and subsequent injuries [4,5]. The most common sequelae following an initial shoulder dislocation include Bankart lesions and Hill-Sachs injuries, which may contribute to ongoing instability.

Various surgical approaches, both arthroscopic and open, have been proposed to restore anatomical and functional integrity when post-traumatic recurrent instability is associated with bone loss [5–7].

Among these, the Latarjet and Free Bone Block (FBB) procedures are widely used. The Latarjet procedure, first described by Michel Latarjet in 1954, involves transferring the coracoid process with its attached musculature to the anteroinferior glenoid. This technique has gained widespread acceptance for cases with significant glenoid bone loss and Hill-Sachs lesions because of its ability to reduce recurrence rates. However, it has been associated with a higher risk of postoperative complications, including nerve injuries and osteoarthritis [8,9].

Conversely, the FBB technique, initially described by Hybinette in 1932, has emerged as an alternative approach for glenoid reconstruction. Unlike the Latarjet procedure, FBB allows for customized graft size and positioning. The graft, often harvested from the iliac crest or an allograft, aims to restore glenoid bone stock while minimizing complications related to nerve injury [10]. A prior systematic review and meta-analysis by Gilat et al. [11], which synthesized literature published up to 2019, provided initial comparisons between the Latarjet and FBB techniques. Since then, however, a substantial volume of new research has emerged. Our systematic search identified 1319 studies published between 2019 and 2024, reflecting a growing body of literature in this field. These recent studies are not only more numerous, but also more advanced in terms of methodology, imaging techniques, surgical precision, and outcome reporting. Notably, several of them include modern arthroscopic approaches, more accurate definitions of graft morphology, and standardized patient-reported outcome measures (PROMs), which were largely absent or inconsistently reported in older studies.

This marked evolution in clinical practice and research methodology justifies the need for an updated synthesis. Our aim was to determine whether the updated evidence base provides greater clarity on the reported outcome profiles of the Latarjet and Free Bone Block (FBB) techniques in managing anterior shoulder instability, without implying definitive comparative superiority.

In this review, the term 'FBB' refers to autologous or allograft bone grafts harvested from anatomical sites such as the iliac crest or distal tibia, used without capsuloligamentous or muscular attachments.

2. Materials and Methods

2.1. Information Sources and Search Strategy

A comprehensive literature search was performed between August 2023 and May 2024 using PubMed (National Library of Medicine, Bethesda, MD, USA), Embase (Elsevier B.V., Amsterdam, the Netherlands), CINAHL (EBSCO Information Services, Ipswich, MA, USA), Scopus (Elsevier B.V., Amsterdam, the Netherlands), Web of Science (Clarivate, London, UK), and the Cochrane Library (The Cochrane Collaboration, London, UK; published by John Wiley & Sons, Hoboken, NJ, USA). Only articles published in English, Spanish, or Italian were considered. The search focused on studies published from January 2019 to May 2024, as this review was designed as an update of the previous evidence base. The newly identified studies from the 2019–2024 search were then integrated with the 70 studies included in the previous systematic review, which were re-screened and retained only if they fulfilled the eligibility criteria of the present review. The complete PubMed search strategy is reported in Supplementary Table S1. Equivalent search strategies were adapted for Embase, CINAHL, Scopus, Web of Science, and the Cochrane Library according to the syntax of each database. The selection process was managed using CADIMA software, version 2.2.4.2 (Julius Kühn-Institut, Quedlinburg, Germany), to ensure systematic identification and screening of eligible studies.

2.2. PICOS Framework and Research Question

The aim of this updated systematic review and meta-analysis was to provide a current synthesis of clinical outcomes following the Latarjet and Free Bone Block (FBB) procedures for anterior shoulder instability, based on newly identified evidence published between 2019 and 2024, integrated with eligible studies from the previous review after re-screening. Given the predominance of single-procedure cohorts in the available literature, no formal hypothesis of superiority between the two techniques was tested. Between-procedure comparisons were therefore considered exploratory and interpreted in the context of indirect evidence and study-level heterogeneity.

The research question was formulated according to the PICOS framework. The population (P) included patients with anterior shoulder instability treated with bone-block stabilization procedures. The intervention (I) of interest was the Latarjet procedure, and the comparator (C) was FBB techniques, including iliac crest, distal tibial, or other free graft reconstructions. The outcomes (O) of interest were recurrent instability, redislocation, subluxation, reoperation, PROMs, return to sport, postoperative complications, and progression of glenohumeral osteoarthritis. Eligible study designs (S) included randomized controlled trials, prospective and retrospective cohort studies, comparative studies, and case series meeting the predefined inclusion criteria.

2.3. Eligibility Criteria

Studies were considered eligible if they reported clinical outcomes following anterior shoulder stabilization using the Latarjet procedure and/or bone block techniques. The inclusion criteria required prospective studies, case series, cohort studies, or randomized controlled trials (RCTs) published since 2019 as an update to the previous meta-analysis. Studies were required to include at least five patients in the relevant treatment cohort and a minimum follow-up of two years.

Studies were excluded if they were case reports, technical notes without clinical outcome data, conference abstracts, review articles, cadaveric or biomechanical studies, or studies focused primarily on Bankart repair or posterior shoulder instability. Studies were also excluded if the surgical procedure or the diagnosis of traumatic anterior shoulder instability was not clearly reported. When multiple studies reported overlapping cohorts, the most complete or most recent dataset was selected.

2.4. Selection and Data Collection Processes

The literature search and data extraction were independently performed by two authors (B.M. and F.E.B.). Disagreements were resolved through discussion with a third reviewer (S.D.S.). The study selection process was performed in two phases. Initially, titles and abstracts were screened to identify potentially relevant studies that met the inclusion criteria. Full-text articles were then retrieved and assessed for final inclusion. Data extraction included the year of publication, study design, level of evidence, sample size, patient demographics such as age and number of shoulders treated, type of surgical intervention involving the Latarjet and/or bone block procedure, recurrence rate, follow-up duration, patient-reported outcome measures (PROMs), range of motion (ROM), return to sport, and postoperative complications. PROMs and ROM values were collected both preoperatively and postoperatively to facilitate comparative analysis. The PROMs assessed included the ROWE Score, Constant–Murley Score, Western Ontario Shoulder Instability Index (WOSI), Oxford Shoulder Instability Score (OSIS), Visual Analogue Scale (VAS), Simple Shoulder Test (SST), American Shoulder and Elbow Surgeons Shoulder Score (ASES), Japan Shoulder Society Shoulder Instability Score (JSS-SIS), and University of California at Los Angeles (UCLA) Score. Among the outcomes, PROMs such as ASES, WOSI, and Rowe were the most consistently reported and therefore prioritized in the meta-analysis. PROMs reported by only one study were described narratively. This structured approach ensured a comprehensive evaluation of the literature and standardized data extraction, facilitating an objective and reproducible meta-analysis. The 70 studies included in the previous meta-analysis were re-assessed against the same eligibility criteria used for the present update and were retained if they fulfilled the predefined inclusion criteria.

2.5. Study Risk of Bias Assessment

A total of 98 studies were subjected to a risk of bias analysis. This assessment was independently conducted by two authors (B.M. and F.E.B.), followed by a comparative review to resolve any discrepancies. For the three randomized trials included, the risk of bias was evaluated using the RoB 2 checklist, a tool developed by Cochrane. This checklist assesses five domains: the randomization process, deviations from intended interventions, missing outcome data, measurement of the outcome, and selection of the reported result, plus an overall risk-of-bias judgement. Each domain was rated as "high risk," "low risk," or "some concerns," based on responses to predefined questions. For the 95 non-randomized studies, the MINORS checklist was used to evaluate the risk of bias. This assessment involved assigning a score ranging from zero to two for each of the following study characteristics: clearly stated aim, inclusion of consecutive patients,

prospective data collection, endpoints appropriate to the study aim, unbiased assessment of study endpoint, follow-up period appropriate to the study aim, loss to follow-up below 5%, prospective calculation of study size, presence of an adequate control group, use of contemporary groups, baseline equivalence of groups, and application of adequate statistical analyses.

2.6. Statistical Analysis

Because most included studies reported outcomes for only one procedure, the primary analyses consisted of pooled estimates calculated separately for the Latarjet and FBB groups. Comparisons between procedures were therefore mainly based on indirect comparisons of pooled single-arm estimates, rather than on direct treatment effects from head-to-head comparative studies. Accordingly, between-procedure *p*-values were considered exploratory and were not interpreted as definitive evidence of superiority of one procedure over the other.

The analysis of binomial outcomes, including recurrent instability, return to sport, postoperative complications, and progression of glenohumeral osteoarthritis, was performed using a random-effects meta-analysis. Statistical analyses were conducted using RStudio, Version 2024.04.0 (Posit Software, PBC, Boston, MA, USA), R, Version 4.4.0 (R Foundation for Statistical Computing, Vienna, Austria), and meta package, Version 7.0-0 (R Foundation for Statistical Computing, Vienna, Austria). For patient-reported outcome measures (PROMs) such as VAS, Rowe, ASES, WOSI, SSV, Constant score, UCLA shoulder score, Walch-Duplay score, SST, OSS, and SANE, continuous data were analyzed through a random-effects meta-analysis of pooled means or mean changes, when available. Given the variability among studies, heterogeneity was assessed using Cochran's Q statistic and I^2 estimation. Exploratory comparisons between pooled estimates for the Latarjet and FBB groups were performed using t-tests or z-tests, as appropriate. Any between-procedure *p*-values, when presented, were considered exploratory descriptive statistics and were not used to infer comparative treatment effects. The results of the meta-analysis were visually represented using forest plots to facilitate interpretation of within-procedure pooled outcomes and exploratory descriptive between-procedure contrasts.

3. Results

3.1. Study Selection

After the removal of duplicates, 1319 studies were initially considered. Based on title and abstract screening, 29 full-text articles were assessed for eligibility. Twenty-eight were included in the updated systematic review, while one full-text article was excluded because it focused on recurrent posterior shoulder instability, which did not meet the predefined eligibility criteria. Of the 28 newly included studies, 19 were Latarjet studies, 8 were FBB studies, and 1 was a comparative study contributing data to both procedure-specific analyses. These newly identified studies were integrated with the 70 studies included in the 2019 meta-analysis, leading to a final dataset of 98 studies. The selection process is illustrated in Figure 1.

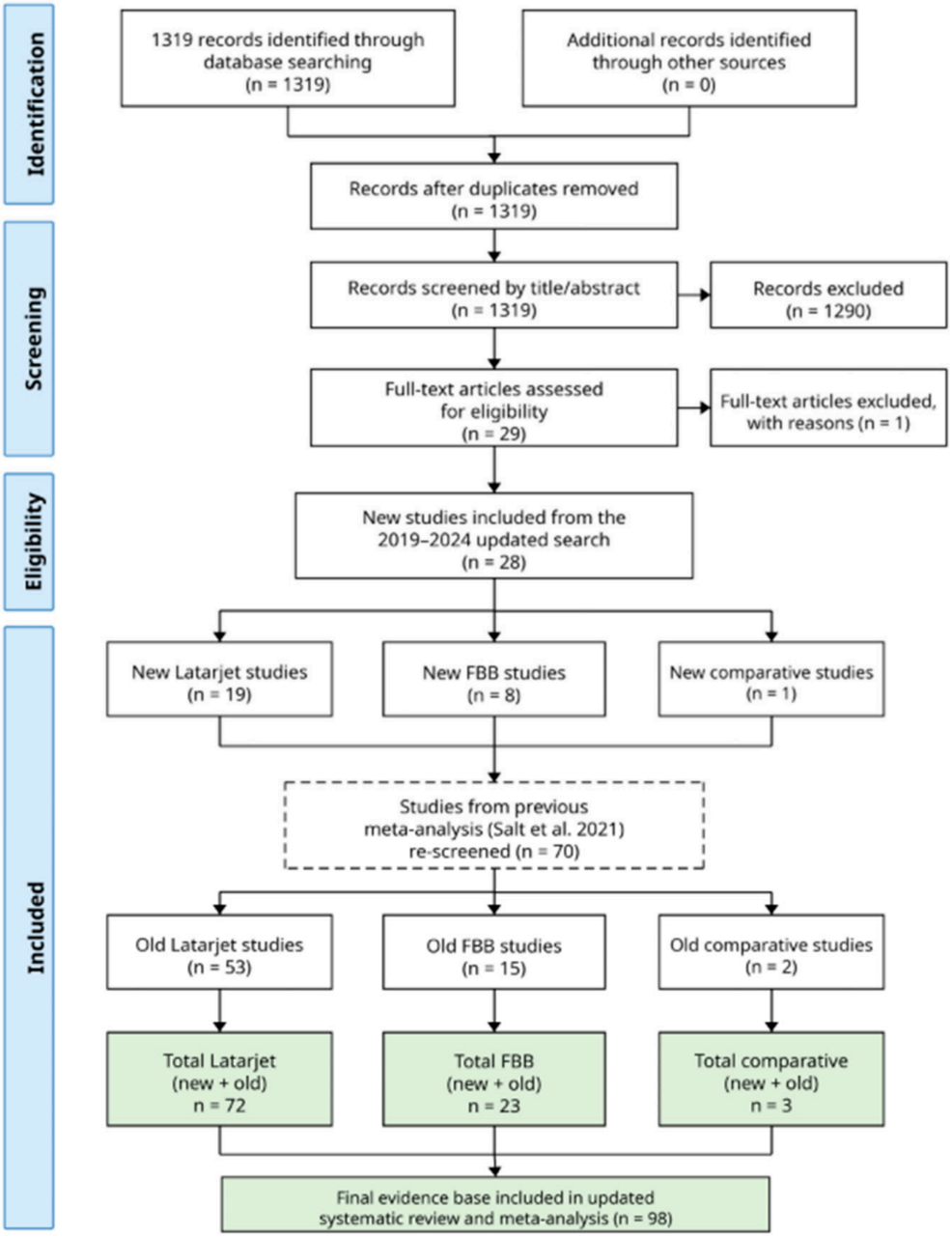

Figure 1. PRISMA flow diagram showing the updated search process, exclusion of the posterior shoulder instability study, and integration of re-screened studies from the previous meta-analysis into the final evidence base.

3.2. Study Characteristics

Among the 98 selected studies, 72 investigated the Latarjet procedure, 23 focused on the Bone Block technique, and 3 compared both surgical approaches. The total number of patients was 6043, with 6071 shoulders undergoing surgery. Women constituted 15.2% of the study population. Study characteristics are summarized in Table 1, and patient demographics are detailed in Table 2.

Table 1. Studies characteristics.

		Paper (n)	Shoulder (n)	Patient (n)	Loe I–II	Loe III	Loe IV	Studies with Open Procedures	Studies with Arthroscopic Procedures
New articles	Latarjet	19	1205	1205	2	7	9	14	7
	FBB	8	220	222	0	1	7	1	7
	Comparison	1	174	174	1	0	0	0	1
Old articles	Latarjet	53	3813	3786	2	28	23	46	9
	FBB	15	499	496	0	6	9	6	9
	Comparison	2	160	160	1	1	0	2	0
Total	Latarjet	72	5018	4991	4	35	32	60	16
	FBB	23	719	718	0	7	16	7	16
	Comparison	3	334	334	2	1	0	2	1

Loe I–II, Loe III; Loe IV; FBB Abbreviations: Loe, level of evidence; FBB, free bone block.

Table 2. Patients characteristics.

		Mean Age (Min-Max) (Years)	Mean Follow Up (Min-Max) (Months)	Females Involved (%)	Right Shoulder Involved (%)	Dominant Shoulder Involved (%)	Precedent Operation	Pre-Op Glenoid Bone Defect	Pre-Op Hills-Sachs Lesion	Pre-Op Hyperlaxity
New articles	Latarjet	27.3 (16–60)	40.4 (24–193)	12.7	57.5	57.9	355	1022	569	152
	FBB	28.6 (16–74)	48.7 (24–240)	16.5	49.2	63.8	48	123	72	20
	Comparison	29.5 (18–57)	44.1 (41–46)	17.3	-	-	70	-	-	-
Old articles	Latarjet	27.3 (14–85)	74.9 (24–420)	16.6	56.0	62.5	388	1543	938	293
	FBB	35.9 (16–63)	195 (24–228)	14.9	53.3	60.5	195	99	9	11
	Comparison	27.3 (18–57)	24 (24–24)	5.0	-	-	92	160	-	-
Total	Latarjet	27.3 (14–85)	66.6 (24–420)	15.7	56.4	61.4	743	2565	1507	445
	FBB	33.5 (16–74)	147.8 (24–240)	15.4	52.0	61.6	243	222	81	31
	Comparison	28.4 (18–57)	34.5 (24–46)	11.4	-	-	162	160	0	0

3.3. Latarjet Studies

A total of 72 studies examined the Latarjet procedure [12–83], encompassing 5018 shoulders from 4991 patients, with evidence levels ranging from LoE I to IV. Open procedures were analyzed in 56 studies, arthroscopic techniques in 12 studies, and 4 studies included both approaches. The mean patient age was 27.3 years (range 14–85), with an average follow-up period of 66.6 months (range 24–420). Women represented 15.7% of the cohort.

Shoulder laterality was reported in 61 studies, with the right shoulder involved in 56.4% of cases (20 studies) and the dominant shoulder in 61.4% (49 studies). A total of 743 shoulders had undergone previous surgery. Preoperative imaging identified a glenoid bone defect in 2565 shoulders, a Hill-Sachs lesion in 1507 shoulders, and hyperlaxity in 445 shoulders.

3.4. Bone Block Studies

The Bone Block technique was assessed in 23 studies [84–106], including 719 shoulders from 718 patients, with evidence levels ranging from LoE III to IV. Open procedures were examined in 7 studies, while 16 focused on arthroscopic techniques. Iliac crest grafts were the most frequently used (14 studies), while distal tibial, glenoid, and allograft bone blocks were also reported in selected studies. Fixation methods varied across studies and included screw fixation, button-based fixation, and other fixation constructs according to graft type and surgical approach.

The mean patient age was 33.5 years (range 16–74), with an average follow-up of 147.8 months (range 24–240). Women comprised 15.4% of the study population. Laterality was documented in 18 studies, identifying the right shoulder in 52.0% of cases (9 studies)

and the dominant shoulder in 61.6% (13 studies). A total of 243 shoulders had undergone previous surgery. Preoperative assessment revealed a glenoid bone defect in 222 shoulders, a Hill-Sachs lesion in 81 shoulders, and hyperlaxity in 31 shoulders.

3.5. Comparative Studies

Three studies compared the Latarjet and Bone Block procedures [107–109], including 334 shoulders (334 patients). Among these, 188 shoulders underwent the Latarjet procedure, while 146 received the Bone Block technique. The included studies featured a Level II multicenter trial.

The mean patient age was 27.5 years in the Latarjet group and 29.5 years in the Bone Block group. The follow-up period was 30 months for both groups, ranging from 24 to 46 months. The proportion of female patients was 12.7% in the Latarjet group and 8.6% in the Bone Block group. Shoulder laterality was not specified in these comparative studies. In terms of surgical history, 83 shoulders in the Latarjet group had undergone previous surgery, while 77 shoulders in the Bone Block group had a prior surgical history.

3.6. Risk of Bias in Studies

Of the 98 included studies, 3 were randomized controlled trials and were assessed using the Cochrane Risk of Bias 2 (RoB 2) tool, while the remaining 95 non-randomized studies were evaluated using the Methodological Index for Non-Randomized Studies (MINORS) checklist.

Among the randomized trials, one study was judged to have a low overall risk of bias, whereas the remaining two studies showed some concerns or high risk of bias in at least one domain. The RoB 2 assessment is reported in Figure 2.

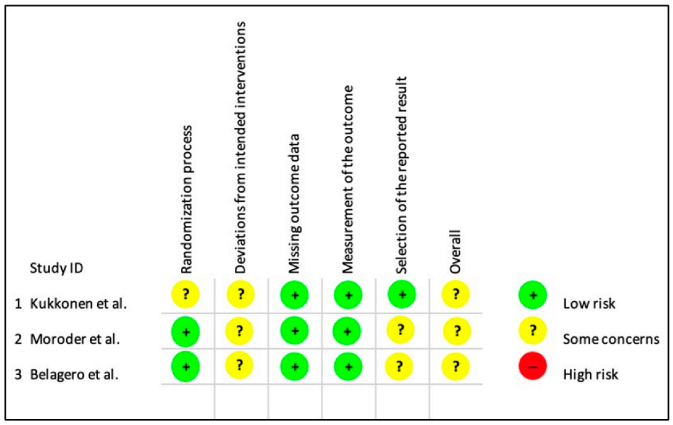

Figure 2. RoB 2 track list results for randomized trials included in the meta-analysis. Kukkonen et al. [24], Moroder et al. [108], and Belangero et al. [16]. The references mentioned in the figure have been cited in the caption.

Among the 95 non-randomized studies, MINORS scores ranged from 9 to 16, with most studies scoring between 9 and 12, indicating moderate methodological quality. The highest score was observed in the comparative study by Dos Santos et al. (2015), which received a score of 16 [42]. Study-level MINORS scores for the non-randomized studies assessed are provided in Supplementary Table S2, while summary descriptive statistics are presented in Table 3.

Table 3. Summary descriptive statistics of MINORS scores.

	Mean	Median	Mode	Min.	Max.	s.d.
95 studies	11.04	11	12	9	16	1.29

3.7. Outcomes

Recurrent Instability

The pooled recurrence rate was 0.07 (95% CI 0.06–0.07, I^2 = 85%) after the Latarjet procedure and 0.05 (95% CI 0.04–0.07, I^2 = 67%) after FBB. A small numerical difference was observed between pooled estimates. However, because these estimates were derived mainly from separate single-arm cohorts, this finding should be interpreted as an exploratory descriptive contrast and should not be considered a direct comparative treatment effect. The outcomes of recurrent instability are detailed in Figure 3A,B.

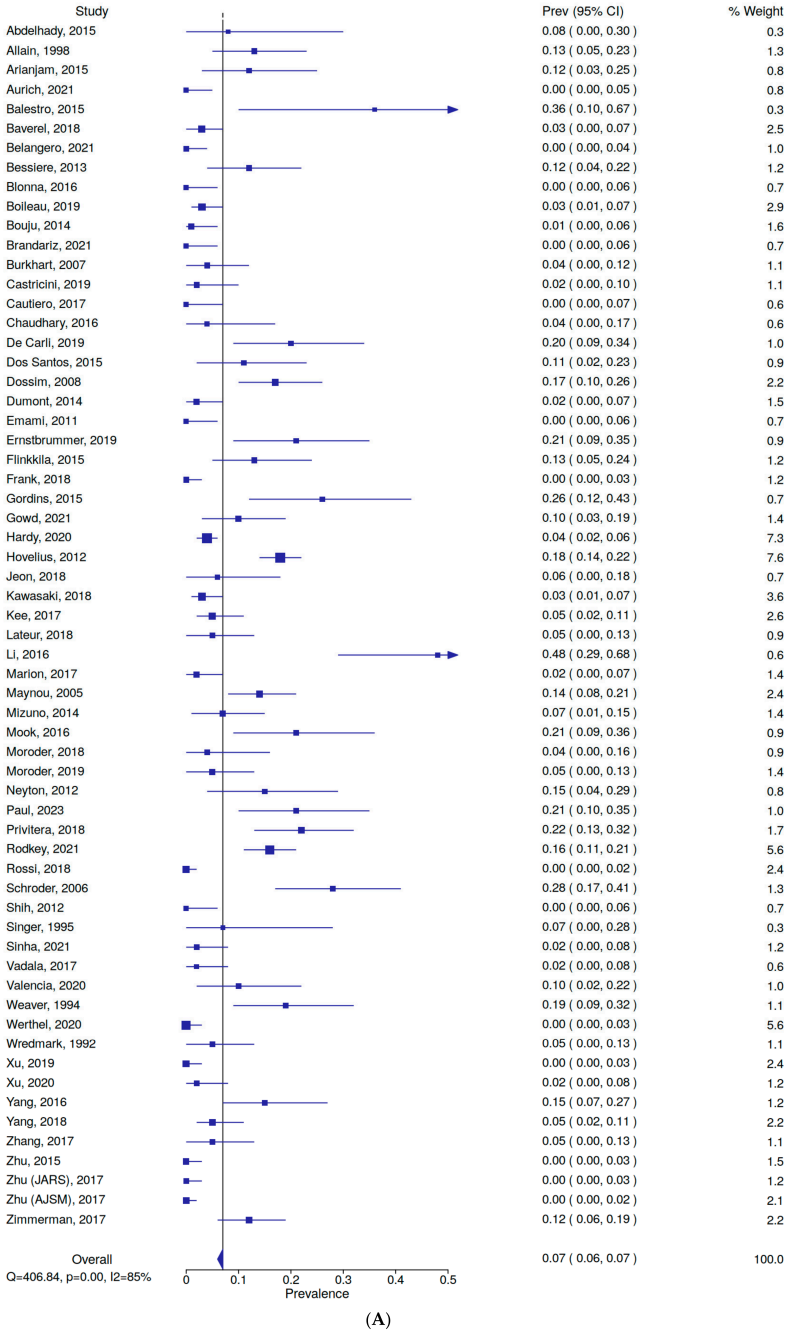

Figure 3. *Cont.*

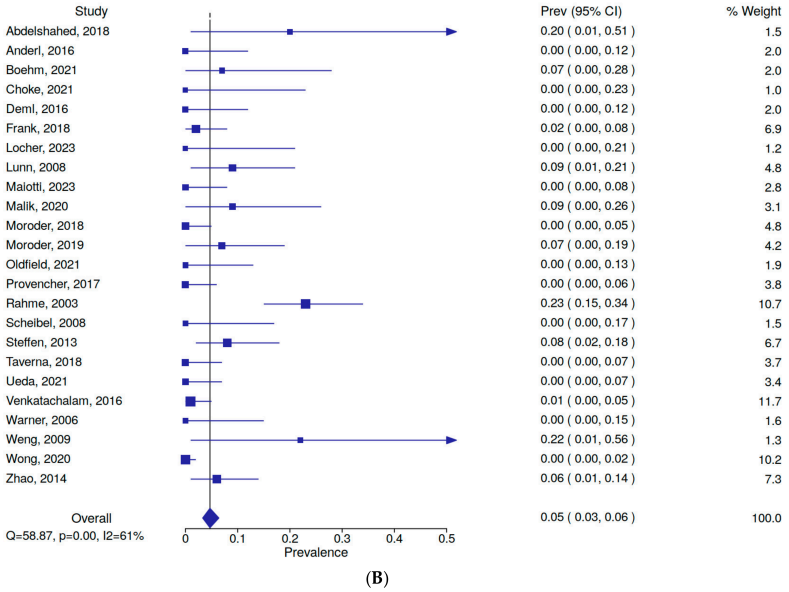

(**B**)

Figure 3. (**A**): Forest plot of recurrent instability after the Latarjet procedure [12–83,107–109]. Pooled prevalence: 0.07 (95% CI: 0.06–0.07); Heterogeneity: Q = 406.84, $p < 0.001$, $I^2 = 85\%$. (**B**): Forest plot of recurrent instability after the Free Bone Block (FBB) procedure [84–109]. Pooled prevalence: 0.05 (95% CI: 0.04–0.07); Heterogeneity: Q = 58.87, $p < 0.001$, $I^2 = 61\%$.

3.8. PROMs

Postoperative PROMs showed significant improvement across all reviewed studies. For the ASES score, the pooled mean change was 22.69 (95% CI 13.79–31.58, $I^2 = 97\%$) after the Latarjet procedure and 34.10 (95% CI 16.82–51.39, $I^2 = 98\%$) after FBB. Although the pooled improvement appeared numerically greater in the FBB group, PROM comparisons were based mainly on indirect pooled estimates from heterogeneous cohorts and should therefore be interpreted descriptively. Similar caution applies to other PROMs, including Rowe, WOSI, SSV, and VAS, because baseline values, follow-up duration, and reporting methods varied across studies. The ASES outcomes are presented in Figure 4A,B.

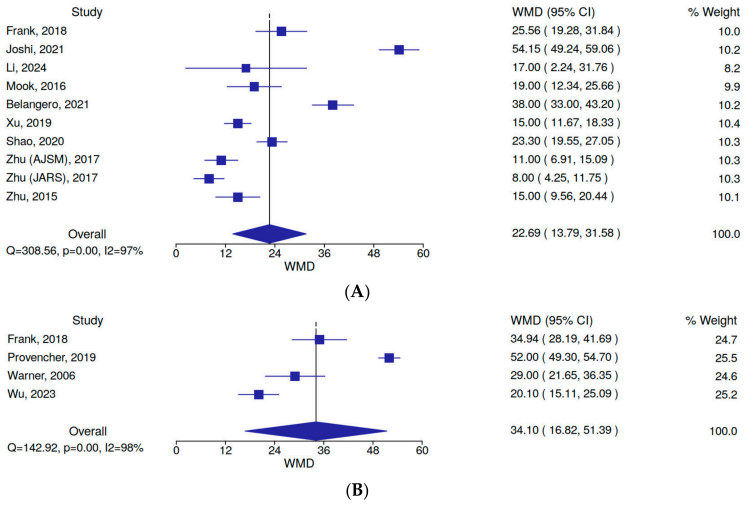

(**A**)

(**B**)

Figure 4. (**A**): Forest plot of changes in ASES score after the Latarjet procedure [13,16,18,39,41,63,68,76,77,107]. Pooled weighted mean difference (WMD): 22.69 (95% CI: 13.79–31.58); Heterogeneity: Q = 308.56, $p < 0.001$, $I^2 = 97\%$. (**B**): Forest plot of changes in ASES score after the Free Bone Block (FBB) procedure [84–109]. Pooled weighted mean difference (WMD): 34.10 (95% CI: 16.82–51.39); Heterogeneity: Q = 142.92, $p < 0.001$, $I^2 = 98\%$.

3.9. Return to Sport

The pooled proportion of patients returning to sport at the same level was 0.66 (95% CI 0.64–0.68, I^2 = 97%) after the Latarjet procedure and 0.65 (95% CI 0.61–0.70, I^2 = 97%) after FBB. The pooled estimates were numerically similar. However, substantial heterogeneity was observed for both procedures, and these findings should be interpreted as descriptive outcome patterns rather than precise comparative effects. The outcomes are illustrated in Figure 5A,B.

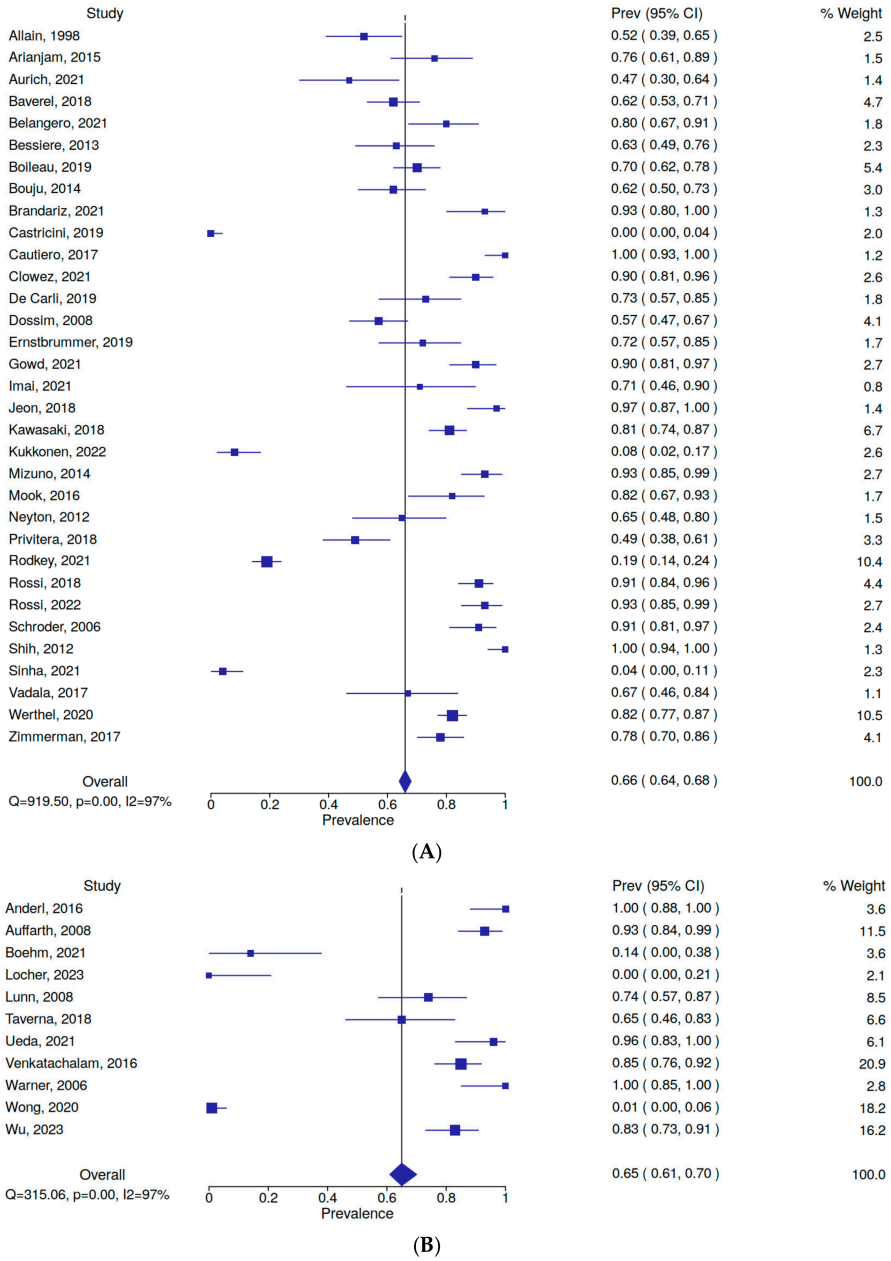

Figure 5. (**A**): Forest plot of return to sport following the Latarjet procedure [12–83,107–109]. Pooled prevalence: 0.66 (95% CI: 0.64–0.68); Heterogeneity: Q = 919.50, $p < 0.001$, I^2 = 97%. (**B**): Forest plot of return to sport following the Free Bone Block (FBB) procedure [84–109]. Pooled prevalence: 0.65 (95% CI: 0.61–0.70); Heterogeneity: Q = 315.06, $p < 0.001$, I^2 = 97%.

3.10. Postoperative Complications

Complications unrelated to instability included postoperative hematoma, infection, arm paresthesia, sensory alterations, nerve palsy, neuropraxia, subscapularis weakness, pain, and weakness. The pooled rate of complications unrelated to instability was 0.05

(95% CI 0.04–0.06, I^2 = 82%) after the Latarjet procedure and 0.08 (95% CI 0.06–0.10, I^2 = 58%) after FBB. A higher numerical pooled rate of non-instability-related complications was observed in the FBB group. This finding should be interpreted cautiously because complication definitions and reporting varied across studies, and because FBB studies differed in graft source, fixation method, and surgical approach. The outcomes are depicted in Figure 6A,B.

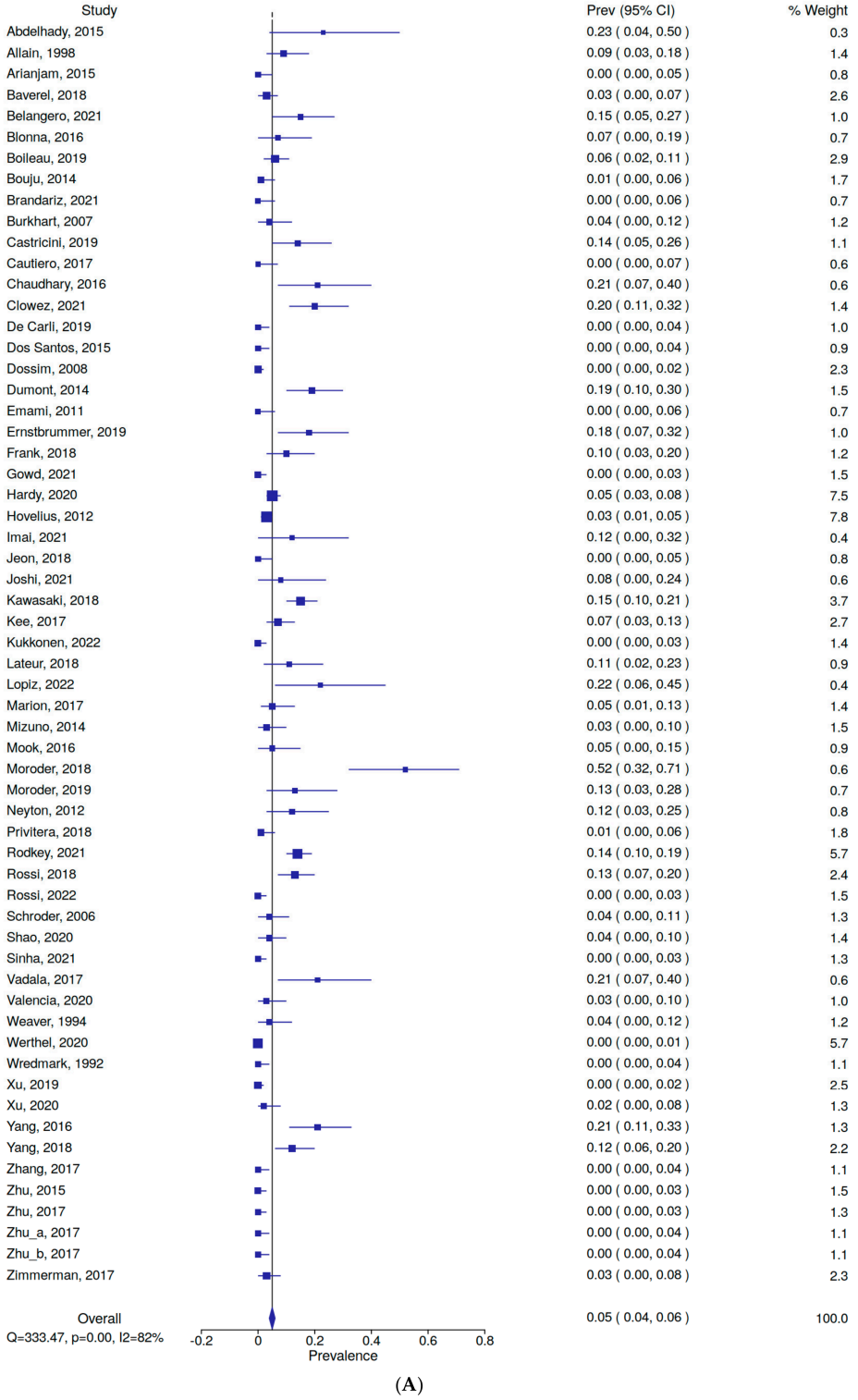

Figure 6. *Cont.*

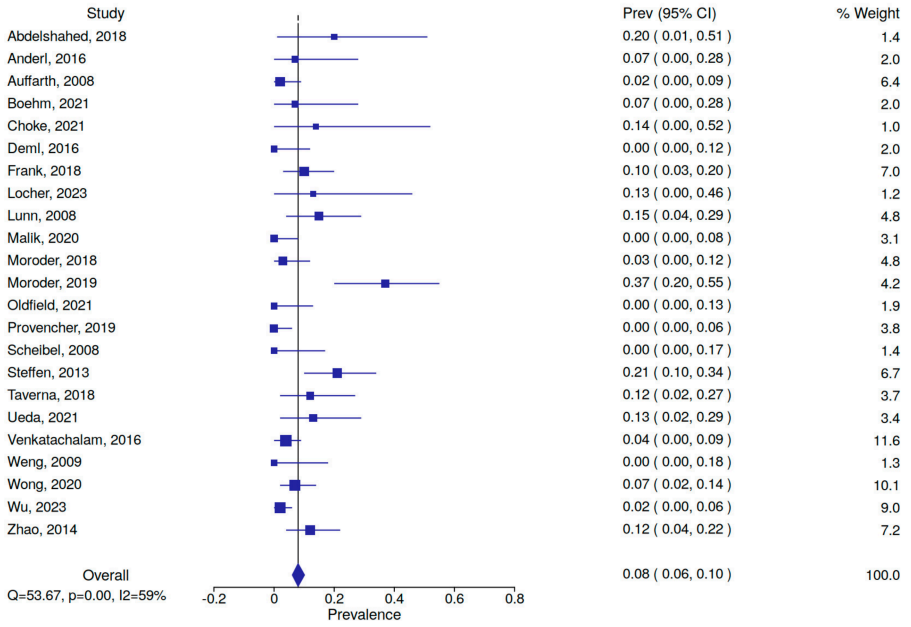

(**B**)

Figure 6. (**A**): Forest plot of postoperative complications not instability related after the Latarjet procedure [12–14,16,18–25,27,32,35–45,47–55,57–62,64,66–70,72–81,107,108]. Pooled prevalence: 0.05 (95% CI: 0.04–0.06); Heterogeneity: Q = 333.47, $p < 0.001$, $I^2 = 82\%$. (**B**): Forest plot of postoperative complications not instability related after the Free Bone Block (FBB) procedure. Pooled prevalence: 0.08 (95% CI: 0.06–0.10); Heterogeneity: Q = 53.67, $p < 0.001$, $I^2 = 59\%$.

3.11. Progression of Glenohumeral Osteoarthritis

The pooled rate of postoperative glenohumeral osteoarthritis progression was 0.12 (95% CI 0.10–0.14, $I^2 = 91\%$) after the Latarjet procedure and 0.09 (95% CI 0.06–0.13, $I^2 = 77\%$) after FBB. The numerical difference between pooled estimates should be interpreted descriptively because osteoarthritis definitions, radiographic classifications, and follow-up duration varied substantially across studies. The outcomes are detailed in Figure 7A,B.

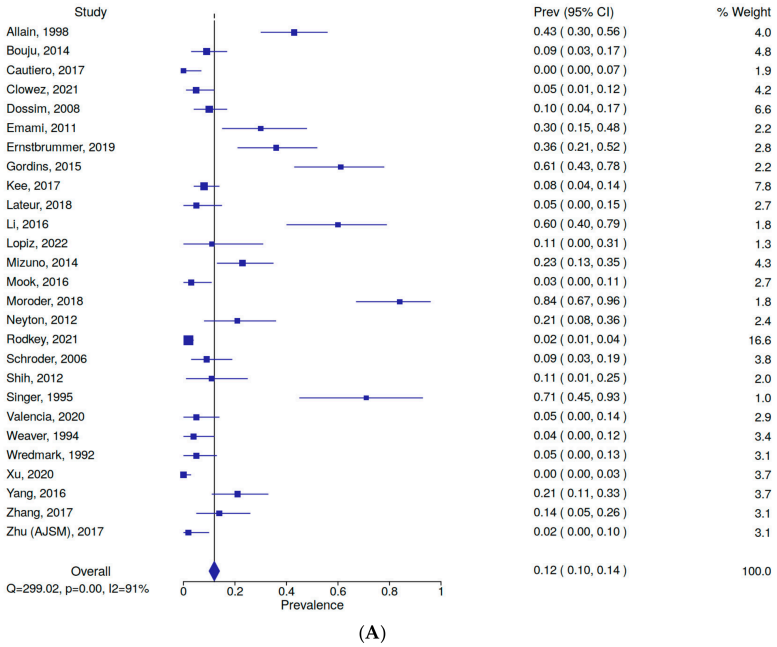

(**A**)

Figure 7. *Cont.*

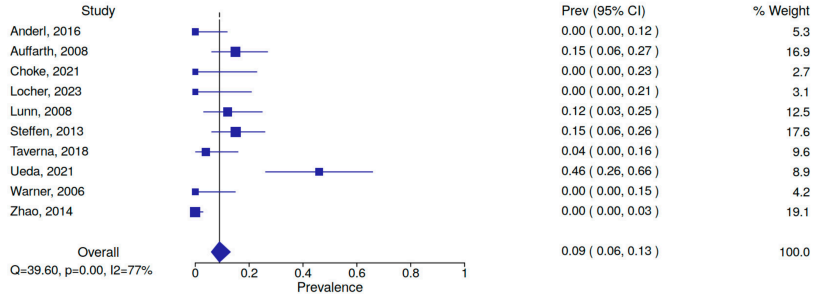

(**B**)

Figure 7. (**A**): Forest plot of postoperative glenohumeral osteoarthritis after the Latarjet procedure [19,21,23,32,34,40,43,44,51,53–56,60,62,63,67–70,73,74,77,78,80–82]. Pooled prevalence: 0.12 (95% CI: 0.10–0.14); Heterogeneity: Q = 299.02, $p < 0.001$, I^2 = 91%. (**B**): Forest plot of postoperative glenohumeral osteoarthritis after the Free Bone Block (FBB) procedure. Pooled prevalence: 0.09 (95% CI: 0.06–0.13); Heterogeneity: Q = 39.60, $p < 0.001$, I^2 = 77%.

3.12. Recurrence

Recurrence-related events were analyzed separately. The Latarjet procedure resulted in 122 dislocations (2.34%), 154 subluxations (2.95%), and 207 reoperations (3.97%). FBB studies reported 39 dislocations (4.39%), 8 subluxations (0.90%), and 31 reoperations (3.49%). These recurrence-related events are reported descriptively because definitions and reporting of redislocation, subluxation, subjective instability, and reoperation were not uniform across studies.

4. Discussion

The present study summarizes clinical outcomes reported after the Latarjet and FBB procedures for anterior shoulder instability. Across the included studies, both procedures were associated with generally favorable postoperative stability and functional outcomes. However, because the evidence base was dominated by observational single-arm studies and substantial heterogeneity was present across several outcomes, these findings should be interpreted as descriptive outcome patterns rather than confirmation of comparative efficacy, safety, or reliability.

Recurrent instability rates were generally low for both techniques, with pooled recurrence rates of 7% after Latarjet and 5% after FBB. Although most studies reported recurrence rates below 25% at the final follow-up, some outliers were identified for both FBB [109] and Latarjet [46,56,63,73]. The small numerical difference in pooled recurrence rates should be interpreted cautiously and may reflect differences in study populations, indications, follow-up duration, or outcome definitions rather than a true procedural effect. From a clinical perspective, recurrence risk alone should not determine surgical decision-making. Instead, surgical decisions should be guided by patient-specific anatomical and functional factors, especially given the higher subluxation rate observed in the Latarjet group despite its lower redislocation prevalence. Latarjet studies showed a lower redislocation rate, but a higher subluxation rate compared with FBB studies. This pattern may reflect the stabilizing effect of glenoid augmentation and the dynamic sling mechanism in preventing complete redislocation. However, it should be interpreted cautiously because definitions of subluxation, subjective instability, and redislocation were not uniform across the included studies.

Patient-reported outcome measures (PROMs), including the ASES score, improved after both procedures in the included studies. Several studies reported improvements exceeding 50% from baseline [61,99], suggesting favorable postoperative functional recovery in the included cohorts. These findings should be interpreted descriptively because baseline characteristics, follow-up duration, rehabilitation protocols, and reporting methods varied across studies.

Return to sport is a key factor in surgical planning, particularly for athletic patients. Both procedures showed similar return-to-sport rates at pre-injury intensity levels, with pooled estimates of 66% for Latarjet and 65% for FBB. Although informative, these rates should be interpreted with caution, as return to sport is influenced by multiple factors such as patient age, sport type, rehabilitation adherence, and psychological readiness. Therefore, patient counseling should include a broader discussion that goes beyond recurrence rates alone.

Regarding postoperative complications unrelated to instability, both procedures showed relatively low pooled incidence rates. Inflammatory reactions, infections, and nerve-related complications were reported, with Latarjet showing a slightly lower complication rate (5%) compared with FBB (8%) [23,45,61,74]. This numerical difference should not be interpreted as definitive comparative safety evidence because complication definitions and reporting intensity varied across studies. The higher pooled rate in the FBB group may also reflect variability in graft type, harvest site, fixation method, and surgical approach rather than intrinsic procedural risk.

Progression of glenohumeral osteoarthritis remains a key concern during long-term follow-up. The pooled rate of osteoarthritis progression was 12% after Latarjet and 9% after FBB. Although this numerical difference may suggest a potential trend toward lower osteoarthritis progression after FBB, it should be interpreted in the context of differences in radiographic classifications, follow-up duration, baseline joint status, graft position, instability history, and patient-specific risk factors. Overall, postoperative osteoarthritis appears to be influenced by multiple clinical and technical variables rather than by the surgical technique alone, reinforcing the need for individualized surgical planning.

Importantly, clinical outcome patterns showed that Latarjet patients experienced slightly higher rates of subluxation (2.95%) and reoperation (3.97%) compared with FBB patients (0.90% and 3.49%, respectively), while showing a lower redislocation rate (2.34% vs. 4.39%). The Latarjet procedure may provide greater resistance to complete redislocation through bone-block stability and the dynamic sling effect, whereas FBB techniques may offer an anatomical reconstruction of glenoid bone stock without transfer of the coracoid and its attached musculature. These differences can help surgeons frame the expected outcome profile of each procedure, while recognizing that definitions of subluxation, redislocation, and recurrence were not uniform across studies.

These findings suggest that both techniques can be considered within the surgical treatment algorithm, but surgical choice should be guided by the clinical context rather than by indirect pooled comparisons alone. Patient age, activity level, degree of glenoid bone loss, previous surgery, graft availability, surgeon experience, risk of osteoarthritis progression, and patient expectations should all be considered when selecting the most appropriate procedure. In this context, FBB may be considered when anatomical restoration of glenoid bone stock is prioritized, whereas Latarjet remains a well-established option in high-demand patients and revision settings because of its reproducibility, bone-block effect, and dynamic sling mechanism.

The high heterogeneity observed across several outcomes should also be considered when interpreting the pooled estimates. Differences in patient selection, surgical approach, graft type, fixation method, follow-up duration, rehabilitation protocols, and outcome definitions likely contributed to variability among studies. Therefore, pooled results should be viewed as estimates of overall outcome patterns rather than precise comparative measures.

Limitations

The main limitation of this review is that most between-procedure comparisons were indirect. Only a limited number of included studies directly compared the Latarjet and FBB

procedures, whereas most reported outcomes for a single surgical technique. Therefore, differences in pooled estimates may reflect variability in study populations, surgical indications, follow-up duration, previous surgery, graft type, fixation method, rehabilitation protocols, and outcome definitions rather than true differences in treatment effect. For this reason, the comparative findings of the present review should be considered exploratory and hypothesis-generating.

Substantial clinical and methodological heterogeneity was observed across the included studies. Variability in patient demographics, glenoid bone loss, Hill-Sachs lesions, hyperlaxity, previous surgery, surgical approach, graft source, fixation method, follow-up duration, and outcome definitions may have influenced the pooled estimates. This heterogeneity was particularly relevant for outcomes such as return to sport, PROMs, complications, and osteoarthritis progression, which were not uniformly defined or reported across studies. Subgroup and sensitivity analyses were considered but were not feasible: cross-stratifying studies by surgical approach (open vs. arthroscopic), graft source, fixation method, follow-up duration, and outcome definitions left fewer than 8–10 studies per subgroup for most outcomes, a threshold below which pooled estimates become unstable. Heterogeneity was therefore reported descriptively through the I^2 statistic and contextualized in the Discussion rather than explored through formal subgroup analysis. The synthesis of continuous outcomes also has intrinsic limitations. PROM improvements were frequently derived from preoperative and postoperative values reported in uncontrolled cohorts. As a result, pooled changes may be influenced by baseline differences, follow-up duration, rehabilitation protocols, and regression to the mean. Therefore, between-procedure differences in PROM improvement should be interpreted descriptively rather than as direct comparative effects.

In addition, the protocol for this updated systematic review was not prospectively registered in PROSPERO; therefore, no PROSPERO registration ID is available. This should be considered when interpreting the methodological transparency of the review, and future updates will be prospectively registered.

5. Conclusions

This updated systematic review and meta-analysis found that both Latarjet and FBB procedures were associated with generally favorable clinical outcomes for the treatment of anterior shoulder instability with bone loss in the included studies. Both techniques were associated with low recurrence rates, improved functional outcomes, and satisfactory return-to-sport rates. However, because most between-procedure comparisons were based on indirect pooled estimates from heterogeneous observational studies, no definitive conclusion can be drawn regarding the superiority, relative safety, or comparative reliability of one technique over the other. These findings support consideration of an individualized surgical approach based on patient characteristics, bone loss pattern, graft availability, and surgeon expertise. Further high-quality direct comparative studies are needed to better define procedure-specific indications and long-term outcomes.

Certainty of Evidence

The extracted data aimed to provide a comprehensive assessment of postoperative outcomes in a large patient population, encompassing 6071 cases. This large dataset provides a broad overview of postoperative outcomes after Latarjet and FBB procedures and strengthens the descriptive value of the present synthesis. However, sample size alone does not determine the certainty of evidence. The certainty of evidence was therefore interpreted by considering study design, risk of bias, inconsistency, indirectness, and imprecision. Overall, the available evidence suggests that both procedures are associated with gener-

ally favorable reported outcomes for recurrent instability, functional improvement, and return to sport. Nevertheless, the certainty of evidence for direct between-procedure differences remains limited because most comparisons were based on indirect pooled estimates from predominantly observational studies, with substantial heterogeneity across several outcomes. Further high-quality direct comparative studies with standardized outcome definitions and longer follow-up are needed to strengthen the certainty of evidence regarding procedure-specific differences. The outcome-level GRADE-informed certainty-of-evidence assessment is provided as a dedicated Supplementary Table S3.

Supplementary Materials: The following supporting information can be downloaded at: https://www.mdpi.com/article/10.3390/osteology6020012/s1, Supplementary File S1: Supplementary Table S1. Complete PubMed search strategy, Supplementary Table S2 and Table 3 of the main manuscript, Supplementary Table S3. Certainty of Evidence (GRADE approach); Supplementary File S2: PRISMA 2020 checklist [110].

Author Contributions: Conceptualization, U.G.L., S.D.S. and A.N.; methodology, S.D.S., F.B. and B.M.; formal analysis, D.G.; investigation, B.M., F.B. and S.D.S.; data curation, B.M., F.B. and D.G.; writing—original draft preparation, B.M. and F.B.; writing—review and editing, U.G.L., S.D.S., A.N., P.D. and V.D.; visualization, B.M., F.B. and D.G.; supervision, U.G.L., S.D.S., A.N., P.D. and V.D.; project administration, U.G.L. and S.D.S. All authors have read and agreed to the published version of the manuscript.

Funding: This research received no external funding.

Institutional Review Board Statement: Not applicable.

Informed Consent Statement: Not applicable.

Data Availability Statement: No new data were created in this study. Data analyzed in this study were obtained from previously published articles included in the review; the extracted datasets are available from the corresponding author upon reasonable request.

Conflicts of Interest: The authors declare no conflicts of interest.

Abbreviations

ASES	American Shoulder and Elbow Surgeons Shoulder Score
CI	Confidence interval
CINAHL	Cumulative Index to Nursing and Allied Health Literature
FBB	Free bone block
JSS-SIS	Japan Shoulder Society Shoulder Instability Score
LoE	Level of evidence
MINORS	Methodological Index for Non-Randomized Studies
OSS	Oxford Shoulder Score
OSIS	Oxford Shoulder Instability Score
PROMs	Patient-reported outcome measures
PRISMA	Preferred Reporting Items for Systematic Reviews and Meta-Analyses
ROM	Range of motion
ROWE	Rowe Shoulder Score
SANE	Single Assessment Numeric Evaluation
SST	Simple shoulder test
SSV	Subjective shoulder value
UCLA	University of California at Los Angeles Shoulder Score
VAS	Visual analogue scale
WOSI	Western Ontario Shoulder Instability Index

References

1. Cameron, K.L.; Mauntel, T.C.; Owens, B.D. The Epidemiology of Glenohumeral Joint Instability: Incidence, Burden, and Long-term Consequences. *Sports Med. Arthrosc. Rev.* **2017**, *25*, 144–149. [CrossRef] [PubMed]
2. Longo, U.G.; Huijsmans, P.E.; Maffulli, N.; Denaro, V.; De Beer, J.F. Video analysis of the mechanisms of shoulder dislocation in four elite rugby players. *J. Orthop. Sci.* **2011**, *16*, 389–397. [CrossRef] [PubMed]
3. Longo, U.G.; Candela, V.; Berton, A.; Naro, C.D.; Migliorini, F.; Schena, E.; Denaro, V. Epidemiology of shoulder instability in Italy: A 14-years nationwide registry study. *Injury* **2021**, *52*, 862–868. [CrossRef] [PubMed]
4. Callanan, M.; Tzannes, A.; Hayes, K.; Paxinos, A.; Walton, J.; Murrell, G.A. Shoulder instability. Diagnosis and management. *Aust. Fam. Physician* **2001**, *30*, 655–661. [PubMed]
5. Longo, U.G.; Loppini, M.; Rizzello, G.; Romeo, G.; Huijsmans, P.E.; Denaro, V. Glenoid and humeral head bone loss in traumatic anterior glenohumeral instability: A systematic review. *Knee Surg. Sports Traumatol. Arthrosc.* **2014**, *22*, 392–414. [CrossRef] [PubMed]
6. Chillemi, C.; Guerrisi, M.; Paglialunga, C.; Salate Santone, F.; Osimani, M. Latarjet procedure for anterior shoulder instability: A 24-year follow-up study. *Arch. Orthop. Trauma Surg.* **2021**, *141*, 189–196. [CrossRef] [PubMed]
7. Taverna, E.; Longo, U.G.; Guarrella, V.; Garavaglia, G.; Perfetti, C.; Sconfienza, L.M.; Broffoni, L.; Denaro, V. A new mini-open technique of arthroscopically assisted Latarjet. *BMC Musculoskelet. Disord.* **2020**, *21*, 285. [CrossRef] [PubMed]
8. Nzeako, O.; Bakti, N.; Bawale, R.; Singh, B. Bone block procedures for glenohumeral joint instability. *J. Clin. Orthop. Trauma* **2019**, *10*, 231–235. [CrossRef] [PubMed]
9. Longo, U.G.; Loppini, M.; Rizzello, G.; Ciuffreda, M.; Maffulli, N.; Denaro, V. Latarjet, Bristow, and Eden-Hybinette procedures for anterior shoulder dislocation: Systematic review and quantitative synthesis of the literature. *Arthroscopy* **2014**, *30*, 1184–1211. [CrossRef] [PubMed]
10. Bradley, K.E.; Jansson, H.L.; Lansdown, D.A.; Zhang, A.L. Arthroscopic Glenoid Reconstruction with Iliac Crest Bone Block Transfer in the Beach Chair Position. *Arthrosc. Tech.* **2021**, *10*, e1155–e1164. [CrossRef] [PubMed]
11. Gilat, R.; Haunschild, E.D.; Lavoie-Gagne, O.Z.; Tauro, T.M.; Knapik, D.M.; Fu, M.C.; Cole, B.J. Outcomes of the Latarjet Procedure Versus Free Bone Block Procedures for Anterior Shoulder Instability: A Systematic Review and Meta-analysis. *Am. J. Sports Med.* **2021**, *49*, 805–816. [CrossRef] [PubMed]
12. Werthel, J.D.; Sabatier, V.; Schoch, B.; Amsallem, L.; Nourissat, G.; Valenti, P.; Kany, J.; Deranlot, J.; Solignac, N.; Hardy, P.; et al. Outcomes of the Latarjet Procedure for the Treatment of Chronic Anterior Shoulder Instability: Patients With Prior Arthroscopic Bankart Repair Versus Primary Cases. *Am. J. Sports Med.* **2020**, *48*, 27–32. [CrossRef] [PubMed]
13. Shao, Z.; Song, Q.; Cheng, X.; Luo, H.; Lin, L.; Zhao, Y.; Cui, G. An Arthroscopic "Inlay" Bristow Procedure With Suture Button Fixation for the Treatment of Recurrent Anterior Glenohumeral Instability: 3-Year Follow-up. *Am. J. Sports Med.* **2020**, *48*, 2638–2649. [CrossRef] [PubMed]
14. Imai, S. A New Guide for the Arthroscopically Assisted Latarjet Procedure. *JBJS Open Access* **2021**, *6*, e20.00141-9. [CrossRef] [PubMed]
15. Aurich, M.; Hofmann, G.O.; Best, N. Clinical outcome and return to sports activity after surgical treatment for recurrent shoulder instability with a modified Latarjet procedure. *Orthop. Traumatol. Surg. Res.* **2021**, *107*, 102977. [CrossRef] [PubMed]
16. Belangero, P.S.; Lara, P.H.S.; Figueiredo, E.A.; Andreoli, C.V.; de Castro Pochini, A.; Ejnisman, B.; Smith, R.L. Bristow versus Latarjet in high-demand athletes with anterior shoulder instability: A prospective randomized comparison. *JSES Int.* **2021**, *5*, 165–170. [CrossRef] [PubMed]
17. Malavolta, E.A.; Cruz, D.G.; Gracitelli, M.E.C.; Assunção, J.H.; Andrade-Silva, F.B.; Andrusaitis, F.R.; Ferreira Neto, A.A. Isokinetic evaluation of the shoulder and elbow after Latarjet procedure. *Orthop. Traumatol. Surg. Res.* **2020**, *106*, 1079–1082. [CrossRef] [PubMed]
18. Joshi, S.; Rao, V.; Shetty, U.C.; Rai, S.; Arora, S.; Kumar, S.R. Functional Outcome of Open Latarjet Procedure in Non-Athletic Middle-Aged Patients. *Malays. Orthop. J.* **2021**, *15*, 151–158. [CrossRef] [PubMed]
19. Rodkey, D.L.; Colantonio, D.F.; LeClere, L.E.; Kilcoyne, K.G.; Dickens, J.F. Latarjet After Failed Arthroscopic Bankart Repair Results in Twice the Rate of Recurrent Instability Compared With Primary Latarjet. *Arthroscopy* **2021**, *37*, 3248–3252. [CrossRef] [PubMed]
20. Gowd, A.K.; Liu, J.N.; Polce, E.M.; Agarwalla, A.; Garcia, G.H.; Nicholson, G.P.; Cole, B.J.; Romeo, A.A.; Verma, N.N. Return to sport following Latarjet glenoid reconstruction for anterior shoulder instability. *J. Shoulder Elb. Surg.* **2021**, *30*, 2549–2559. [CrossRef] [PubMed]
21. Clowez, G.; Gendre, P.; Boileau, P. The Bristow-Latarjet procedure for revision of failed arthroscopic Bankart: A retrospective case series of 59 consecutive patients. *J. Shoulder Elb. Surg.* **2021**, *30*, e724–e731. [CrossRef] [PubMed]
22. Sinha, S.; Kar, S.; Naik, A.K.; Kumar, J.; Goyal, R.; Jain, V.K.; Arya, R.K. Decreased motion with normal strength after Latarjet procedure has minimal impact on return to activity. *Knee Surg. Sports Traumatol. Arthrosc.* **2021**, *29*, 2579–2586. [CrossRef] [PubMed]

23. Lópiz, Y.; Checa, P.; García-Fernández, C.; Martín Albarrán, S.; López de Ramón, R.; Marco, F. Complications after open Latarjet procedure: Influence of arm positioning on musculocutaneous and axillary nerve function. *Eur. J. Orthop. Surg. Traumatol.* **2022**, *32*, 243–248. [CrossRef] [PubMed]
24. Kukkonen, J.; Elamo, S.; Flinkkilä, T.; Paloneva, J.; Mäntysaari, M.; Joukainen, A.; Lehtinen, J.; Lepola, V.; Holstila, M.; Kauko, T.; et al. Arthroscopic Bankart versus open Latarjet as a primary operative treatment for traumatic anteroinferior instability in young males: A randomised controlled trial with 2-year follow-up. *Br. J. Sports Med.* **2022**, *56*, 327–332. [CrossRef] [PubMed]
25. Rossi, L.A.; Tanoira, I.; Bruchmann, M.G.; Pasqualini, I.; Ranalletta, M. The Latarjet procedure in competitive athletes younger than 20 years old with a significant glenoid bone loss. *Shoulder Elb.* **2022**, *14*, 21–28. [CrossRef]
26. Ueda, Y.; Sugaya, H.; Takahashi, N.; Matsuki, K.; Tokai, M.; Morioka, T.; Hoshika, S. Arthroscopic Iliac Bone Grafting for Traumatic Anterior Shoulder Instability with Significant Glenoid Bone Loss Yields Low Recurrence and Good Outcome at a Minimum of Five-Year Follow-Up. *Arthroscopy* **2021**, *37*, 2399–2408. [CrossRef] [PubMed]
27. Brandariz, R.N.; Gorodischer, T.D.; Pasqualini, I.; Rossi, L.A.; Tanoira, I.; Ranalletta, M. The Latarjet Procedure Without Remplissage Is Effective to Restore Stability in Athletes With Glenoid Bone Defects Greater Than 25% and Off-Track Hill-Sachs Lesions. *Arthroscopy* **2021**, *37*, 2455–2461. [CrossRef] [PubMed]
28. Maiotti, M.; De Vita, A.; De Benedetto, M.; Cerciello, S.; Massoni, C.; Di Giunta, A.; Raffelini, F.; Lo Cascio, R.; Pirani, P.; Castricini, R. Clinical outcomes and recurrence rate of 4 procedures for recurrent anterior shoulder instability: ASA, remplissage, open, and arthroscopic Latarjet: A multicenter study. *J. Shoulder Elb. Surg.* **2023**, *32*, 931–938. [CrossRef] [PubMed]
29. Paul, R.W.; Reddy, M.P.; Sonnier, J.H.; Onor, G.; Spada, J.M.; Clements, A.; Bishop, M.E.; Erickson, B.J. Increased rates of subjective shoulder instability after Bankart repair with remplissage compared to Latarjet surgery. *J. Shoulder Elb. Surg.* **2023**, *32*, 939–946. [CrossRef] [PubMed]
30. Malavolta, E.A.; Souza, J.A.B.; Assunção, J.H.; Gracitelli, M.E.C.; Silva, F.B.A.E.; Ferreira, A.A. treatment of recurrent anterior shoulder dislocation using the Latarjet technique. *Acta Ortop. Bras.* **2023**, *31*, e261896. [CrossRef] [PubMed]
31. Bessiere, C.; Trojani, C.; Pélégri, C.; Carles, M.; Boileau, P. Coracoid bone block versus arthroscopic Bankart repair: A comparative paired study with 5-year follow-up. *Orthop. Traumatol. Surg. Res.* **2013**, *99*, 123–130. [CrossRef] [PubMed]
32. Bouju, Y.; Gadéa, F.; Stanovici, J.; Moubarak, H.; Favard, L. Shoulder stabilization by modified Latarjet-Patte procedure: Results at a minimum 10 years' follow-up, and role in the prevention of osteoarthritis. *Orthop. Traumatol. Surg. Res.* **2014**, *100*, S213–S218. [CrossRef] [PubMed]
33. Flinkkilä, T.; Sirniö, K. Open Latarjet procedure for failed arthroscopic Bankart repair. *Orthop. Traumatol. Surg. Res.* **2015**, *101*, 35–38. [CrossRef] [PubMed]
34. Singer, G.C.; Kirkland, P.M.; Emery, R.J. Coracoid transposition for recurrent anterior instability of the shoulder. A 20-year follow-up study. *J. Bone Jt. Surg. Br.* **1995**, *77*, 73–76. [CrossRef]
35. Boileau, P.; Saliken, D.; Gendre, P.; Seeto, B.L.; d'Ollonne, T.; Gonzalez, J.F.; Bronsard, N. Arthroscopic Latarjet: Suture-Button Fixation Is a Safe and Reliable Alternative to Screw Fixation. *Arthroscopy* **2019**, *35*, 1050–1061. [CrossRef] [PubMed]
36. Hardy, A.; Sabatier, V.; Laboudie, P.; Schoch, B.; Nourissat, G.; Valenti, P.; Kany, J.; Deranlot, J.; Solignac, N.; Hardy, P.; et al. Outcomes After Latarjet Procedure: Patients With First-Time Versus Recurrent Dislocations. *Am. J. Sports Med.* **2020**, *48*, 21–26. [CrossRef] [PubMed]
37. Arianjam, A.; Bell, S.N.; Coghlan, J.; Old, J.; Sloan, R. Outcomes for intra-substance free coracoid graft in patients with antero-inferior instability and glenoid bone loss in a population of high-risk athletes at a minimum follow-up of 2 years. *Shoulder Elb.* **2015**, *7*, 36–43. [CrossRef]
38. Rossi, L.A.; Bertona, A.; Tanoira, I.; Maignon, G.D.; Bongiovanni, S.L.; Ranalletta, M. Comparison Between Modified Latarjet Performed as a Primary or Revision Procedure in Competitive Athletes: A Comparative Study of 100 Patients With a Minimum 2-Year Follow-up. *Orthop. J. Sports Med.* **2018**, *6*, 2325967118817233. [CrossRef] [PubMed]
39. Zhu, Y.M.; Jiang, C.; Song, G.; Lu, Y.; Li, F. Arthroscopic Latarjet Procedure With Anterior Capsular Reconstruction: Clinical Outcome and Radiologic Evaluation With a Minimum 2-Year Follow-Up. *Arthroscopy* **2017**, *33*, 2128–2135. [CrossRef] [PubMed]
40. Ernstbrunner, L.; Wartmann, L.; Zimmermann, S.M.; Schenk, P.; Gerber, C.; Wieser, K. Long-term Results of the Open Latarjet Procedure for Recurrent Anterior Shoulder Instability in Patients Older Than 40 Years. *Am. J. Sports Med.* **2019**, *47*, 3057–3064. [CrossRef] [PubMed]
41. Xu, Y.; Wu, K.; Ma, Q.; Zhang, L.; Zhang, Y.; Xu, W.; Guo, J.J. Comparison of clinical and patient-reported outcomes of three procedures for recurrent anterior shoulder instability: Arthroscopic Bankart repair, capsular shift, and open Latarjet. *J. Orthop. Surg. Res.* **2019**, *14*, 326. [CrossRef] [PubMed]
42. Dos Santos, R.B.; Kauffman, F.N.; de Lima, G.P.; Ferreira, A.M.; Dos Santos, S.M.; Aguiar, J.L. Evaluation of isometric strength and fatty infiltration of the subscapularis in latarjet surgery. *Acta Ortop. Bras.* **2015**, *23*, 129–133. [CrossRef] [PubMed]

43. Zhang, H.; Gong, J.; Xie, M.; Tang, K. Individualized coracoid osteotomy and 3D congruent arc reconstruction of glenoid for the treatment of recurrent anterior shoulder dislocation. *J. Orthop. Surg. Res.* **2017**, *12*, 193. [CrossRef] [PubMed]
44. Xu, J.; Liu, H.; Lu, W.; Deng, Z.; Zhu, W.; Peng, L.; Ouyang, K.; Li, H.; Wang, D. Modified Arthroscopic Latarjet Procedure: Suture-Button Fixation Achieves Excellent Remodeling at 3-Year Follow-up. *Am. J. Sports Med.* **2020**, *48*, 39–47. [CrossRef] [PubMed]
45. Abdelhady, A.; Abouelsoud, M.; Eid, M. Latarjet procedure in patients with multiple recurrent anterior shoulder dislocation and generalized ligamentous laxity. *Eur. J. Orthop. Surg. Traumatol.* **2015**, *25*, 705–708. [CrossRef] [PubMed]
46. Balestro, J.C.; Young, A.; Maccioni, C.; Walch, G. Graft osteolysis and recurrent instability after the Latarjet procedure performed with bioabsorbable screw fixation. *J. Shoulder Elb. Surg.* **2015**, *24*, 711–718. [CrossRef] [PubMed]
47. Baverel, L.; Colle, P.E.; Saffarini, M.; Anthony Odri, G.; Barth, J. Open Latarjet Procedures Produce Better Outcomes in Competitive Athletes Compared With Recreational Athletes: A Clinical Comparative Study of 106 Athletes Aged Under 30 Years. *Am. J. Sports Med.* **2018**, *46*, 1408–1415. [CrossRef] [PubMed]
48. Blonna, D.; Bellato, E.; Caranzano, F.; Assom, M.; Rossi, R.; Castoldi, F. Arthroscopic Bankart Repair Versus Open Bristow-Latarjet for Shoulder Instability: A Matched-Pair Multicenter Study Focused on Return to Sport. *Am. J. Sports Med.* **2016**, *44*, 3198–3205. [CrossRef] [PubMed]
49. Burkhart, S.S.; De Beer, J.F.; Barth, J.R.; Cresswell, T.; Roberts, C.; Richards, D.P. Results of modified Latarjet reconstruction in patients with anteroinferior instability and significant bone loss. *Arthroscopy* **2007**, *23*, 1033–1041. [CrossRef] [PubMed]
50. De Carli, A.; Vadalà, A.; Proietti, L.; Ponzo, A.; Desideri, D.; Ferretti, A. Latarjet procedure versus open capsuloplasty in traumatic anterior shoulder dislocation: Long-term clinical and functional results. *Int. Orthop.* **2019**, *43*, 237–242. [CrossRef] [PubMed]
51. Dossim, A.; Abalo, A.; Dosseh, E.; Songne, B.; Ayite, A.; Gnandi-Pio, F. Bristow-Latarjet repairs for anterior instability of the shoulder: Clinical and radiographic results at mean 8.2 years follow-up. *Chir. Main* **2008**, *27*, 26–30. [CrossRef] [PubMed]
52. Dumont, G.D.; Fogerty, S.; Rosso, C.; Lafosse, L. The arthroscopic latarjet procedure for anterior shoulder instability: 5-year minimum follow-up. *Am. J. Sports Med.* **2014**, *42*, 2560–2566. [CrossRef] [PubMed]
53. Emami, M.J.; Solooki, S.; Meshksari, Z.; Vosoughi, A.R. The effect of open Bristow-Latarjet procedure for anterior shoulder instability: A 10-year study. *Musculoskelet. Surg.* **2011**, *95*, 231–235. [CrossRef] [PubMed]
54. Allain, J.; Goutallier, D.; Glorion, C. Long-term results of the Latarjet procedure for the treatment of anterior instability of the shoulder. *J. Bone Jt. Surg. Am.* **1998**, *80*, 841–852. [CrossRef] [PubMed]
55. Weaver, J.K.; Derkash, R.S. Don't forget the Bristow-Latarjet procedure. *Clin. Orthop. Relat. Res.* **1994**, *308*, 102–110. [CrossRef]
56. Gordins, V.; Hovelius, L.; Sandström, B.; Rahme, H.; Bergström, U. Risk of arthropathy after the Bristow-Latarjet repair: A radiologic and clinical thirty-three to thirty-five years of follow-up of thirty-one shoulders. *J. Shoulder Elb. Surg.* **2015**, *24*, 691–699. [CrossRef] [PubMed]
57. Hovelius, L.; Sandström, B.; Olofsson, A.; Svensson, O.; Rahme, H. The effect of capsular repair, bone block healing, and position on the results of the Bristow-Latarjet procedure (study III): Long-term follow-up in 319 shoulders. *J. Shoulder Elb. Surg.* **2012**, *21*, 647–660. [CrossRef] [PubMed]
58. Jeon, Y.S.; Jeong, H.Y.; Lee, D.K.; Rhee, Y.G. Borderline Glenoid Bone Defect in Anterior Shoulder Instability: Latarjet Procedure Versus Bankart Repair. *Am. J. Sports Med.* **2018**, *46*, 2170–2176. [CrossRef] [PubMed]
59. Kawasaki, T.; Hasegawa, Y.; Kaketa, T.; Shiota, Y.; Gonda, Y.; Sobue, S.; Kobayashi, H.; Yamakawa, J.; Itoigawa, Y.; Kaneko, K. Midterm Clinical Results in Rugby Players Treated With the Bristow Procedure. *Am. J. Sports Med.* **2018**, *46*, 656–662. [CrossRef] [PubMed]
60. Kee, Y.M.; Kim, H.J.; Kim, J.Y.; Rhee, Y.G. Glenohumeral arthritis after Latarjet procedure: Progression and it's clinical significance. *J. Orthop. Sci.* **2017**, *22*, 846–851. [CrossRef] [PubMed]
61. Chaudhary, D.; Goyal, A.; Joshi, D.; Jain, V.; Mohindra, M.; Mehta, N. Clinical and radiological outcome after mini-open Latarjet technique with fixation of coracoid with Arthrex wedge mini-plate. *J. Clin. Orthop. Trauma* **2016**, *7*, 23–29. [CrossRef] [PubMed]
62. Lateur, G.; Pailhe, R.; Refaie, R.; Chedal Bornu, B.J.; Boudissa, M.; Saragaglia, D. Results of the Latarjet coracoid bone block procedure performed by mini invasive approach. *Int. Orthop.* **2018**, *42*, 2397–2402. [CrossRef] [PubMed]
63. Li, Y.; Jiang, C. The Effectiveness of the Latarjet Procedure in Patients with Chronic Locked Anterior Shoulder Dislocation: A Retrospective Study. *J. Bone Jt. Surg. Am.* **2016**, *98*, 813–823. [CrossRef] [PubMed]
64. Marion, B.; Klouche, S.; Deranlot, J.; Bauer, T.; Nourissat, G.; Hardy, P. A Prospective Comparative Study of Arthroscopic Versus Mini-Open Latarjet Procedure With a Minimum 2-Year Follow-up. *Arthroscopy* **2017**, *33*, 269–277. [CrossRef] [PubMed]
65. Maynou, C.; Cassagnaud, X.; Mestdagh, H. Function of subscapularis after surgical treatment for recurrent instability of the shoulder using a bone-block procedure. *J. Bone Jt. Surg. Br.* **2005**, *87*, 1096–1101. [CrossRef] [PubMed]
66. Castricini, R.; Longo, U.G.; Petrillo, S.; Candela, V.; De Benedetto, M.; Maffulli, N.; Denaro, V. Arthroscopic Latarjet for Recurrent Shoulder Instability. *Medicina* **2019**, *55*, 582. [CrossRef] [PubMed]

67. Mizuno, N.; Denard, P.J.; Raiss, P.; Melis, B.; Walch, G. Long-term results of the Latarjet procedure for anterior instability of the shoulder. *J. Shoulder Elb. Surg.* **2014**, *23*, 1691–1699. [CrossRef] [PubMed]
68. Mook, W.R.; Petri, M.; Greenspoon, J.A.; Horan, M.P.; Dornan, G.J.; Millett, P.J. Clinical and Anatomic Predictors of Outcomes After the Latarjet Procedure for the Treatment of Anterior Glenohumeral Instability With Combined Glenoid and Humeral Bone Defects. *Am. J. Sports Med.* **2016**, *44*, 1407–1416. [CrossRef] [PubMed]
69. Moroder, P.; Stefanitsch, V.; Auffarth, A.; Matis, N.; Resch, H.; Plachel, F. Treatment of recurrent anterior shoulder instability with the Latarjet or Bristow procedure in older patients. *J. Shoulder Elb. Surg.* **2018**, *27*, 824–830. [CrossRef] [PubMed]
70. Neyton, L.; Young, A.; Dawidziak, B.; Visona, E.; Hager, J.P.; Fournier, Y.; Walch, G. Surgical treatment of anterior instability in rugby union players: Clinical and radiographic results of the Latarjet-Patte procedure with minimum 5-year follow-up. *J. Shoulder Elb. Surg.* **2012**, *21*, 1721–1727. [CrossRef] [PubMed]
71. Paladini, P.; Merolla, G.; De Santis, E.; Campi, F.; Porcellini, G. Long-term subscapularis strength assessment after Bristow-Latarjet procedure: Isometric study. *J. Shoulder Elb. Surg.* **2012**, *21*, 42–47. [CrossRef] [PubMed]
72. Privitera, D.M.; Sinz, N.J.; Miller, L.R.; Siegel, E.J.; Solberg, M.J.; Daniels, S.D.; Higgins, L.D. Clinical Outcomes Following the Latarjet Procedure in Contact and Collision Athletes. *J. Bone Jt. Surg. Am.* **2018**, *100*, 459–465. [CrossRef] [PubMed]
73. Schroder, D.T.; Provencher, M.T.; Mologne, T.S.; Muldoon, M.P.; Cox, J.S. The modified Bristow procedure for anterior shoulder instability: 26-year outcomes in Naval Academy midshipmen. *Am. J. Sports Med.* **2006**, *34*, 778–786. [CrossRef] [PubMed]
74. Yang, J.S.; Mazzocca, A.D.; Cote, M.P.; Edgar, C.M.; Arciero, R.A. Recurrent Anterior Shoulder Instability With Combined Bone Loss: Treatment and Results With the Modified Latarjet Procedure. *Am. J. Sports Med.* **2016**, *44*, 922–932. [CrossRef] [PubMed]
75. Yang, J.S.; Mehran, N.; Mazzocca, A.D.; Pearl, M.L.; Chen, V.W.; Arciero, R.A. Remplissage Versus Modified Latarjet for Off-Track Hill-Sachs Lesions With Subcritical Glenoid Bone Loss. *Am. J. Sports Med.* **2018**, *46*, 1885–1891. [CrossRef] [PubMed]
76. Zhu, Y.M.; Jiang, C.Y.; Lu, Y.; Li, F.L.; Wu, G. Coracoid bone graft resorption after Latarjet procedure is underestimated: A new classification system and a clinical review with computed tomography evaluation. *J. Shoulder Elb. Surg.* **2015**, *24*, 1782–1788. [CrossRef] [PubMed]
77. Zhu, Y.; Jiang, C.; Song, G. Arthroscopic Versus Open Latarjet in the Treatment of Recurrent Anterior Shoulder Dislocation With Marked Glenoid Bone Loss: A Prospective Comparative Study. *Am. J. Sports Med.* **2017**, *45*, 1645–1653. [CrossRef] [PubMed]
78. Wredmark, T.; Törnkvist, H.; Johansson, C.; Brobert, B. Long-term functional results of the modified Bristow procedure for recurrent dislocations of the shoulder. *Am. J. Sports Med.* **1992**, *20*, 157–161. [CrossRef] [PubMed]
79. Vadalà, A.; Lanzetti, R.M.; De Carli, A.; Lupariello, D.; Guzzini, M.; Desideri, D.; Ferretti, A. Latarjet procedure: Evolution of the bone block and correspondent clinical relevance-a clinical and radiological study. *Musculoskelet. Surg.* **2017**, *101*, 113–120. [CrossRef] [PubMed]
80. Valencia, M.; Fernández-Bermejo, G.; Martín-Ríos, M.D.; Fernández-Jara, J.; Morcillo-Barrenechea, D.; Coifman-Lucena, I.; Foruria, A.M.; Calvo, E. Subscapularis structural integrity and function after arthroscopic Latarjet procedure at a minimum 2-year follow-up. *J. Shoulder Elb. Surg.* **2020**, *29*, 104–112. [CrossRef] [PubMed]
81. Cautiero, F.; Russo, R.; Di Pietto, F.; Sabino, G. Computerized tomographic assessment and clinical evaluation in shoulder instability treated with the Latarjet-Patte procedure using one screw and washer. *Muscles Ligaments Tendons J.* **2017**, *7*, 26–33. [CrossRef] [PubMed]
82. Shih, W.-Y.; Cheng, K.-C.; Hung, S.-T.; Lee, H.-M.; Shih, J.-T. Clinical results of shoulder arthroscopy combined with an open modified Latarjet procedure for chronic anterior shoulder instability with glenoid bony loss. *Formos. J. Musculoskelet. Disord.* **2012**, *4*, 126–131. [CrossRef]
83. Zimmermann, S.M.; Scheyerer, M.J.; Farshad, M.; Catanzaro, S.; Rahm, S.; Gerber, C. Long-Term Restoration of Anterior Shoulder Stability: A Retrospective Analysis of Arthroscopic Bankart Repair Versus Open Latarjet Procedure. *J. Bone Jt. Surg. Am.* **2016**, *98*, 1954–1961. [CrossRef] [PubMed]
84. Venkatachalam, S.; Storey, P.; Macinnes, S.J.; Ali, A.; Potter, D. The Sheffield bone block procedure: A new operation for the treatment of glenoid bone loss in patients with anterior traumatic shoulder instability. *Shoulder Elb.* **2016**, *8*, 106–110. [CrossRef]
85. Anderl, W.; Pauzenberger, L.; Laky, B.; Kriegleder, B.; Heuberer, P.R. Arthroscopic Implant-Free Bone Grafting for Shoulder Instability With Glenoid Bone Loss: Clinical and Radiological Outcome at a Minimum 2-Year Follow-up. *Am. J. Sports Med.* **2016**, *44*, 1137–1145. [CrossRef] [PubMed]
86. Deml, C.; Kaiser, P.; van Leeuwen, W.F.; Zitterl, M.; Euler, S.A. The J-Shaped Bone Graft for Anatomic Glenoid Reconstruction: A 10-Year Clinical Follow-up and Computed Tomography-Osteoabsorptiometry Study. *Am. J. Sports Med.* **2016**, *44*, 2778–2783. [CrossRef] [PubMed]
87. Rahme, H.; Wikblad, L.; Nowak, J.; Larsson, S. Long-term clinical and radiologic results after Eden-Hybbinette operation for anterior instability of the shoulder. *J. Shoulder Elb. Surg.* **2003**, *12*, 15–19. [CrossRef] [PubMed]
88. Lunn, J.V.; Castellano-Rosa, J.; Walch, G. Recurrent anterior dislocation after the Latarjet procedure: Outcome after revision using a modified Eden-Hybinette operation. *J. Shoulder Elb. Surg.* **2008**, *17*, 744–750. [CrossRef] [PubMed]

89. Provencher, M.T.; Frank, R.M.; Golijanin, P.; Gross, D.; Cole, B.J.; Verma, N.N.; Romeo, A.A. Distal Tibia Allograft Glenoid Reconstruction in Recurrent Anterior Shoulder Instability: Clinical and Radiographic Outcomes. *Arthroscopy* **2017**, *33*, 891–897. [CrossRef]
90. Scheibel, M.; Nikulka, C.; Dick, A.; Schroeder, R.J.; Gerber Popp, A.; Haas, N.P. Autogenous bone grafting for chronic anteroinferior glenoid defects via a complete subscapularis tenotomy approach. *Arch. Orthop. Trauma Surg.* **2008**, *128*, 1317–1325. [CrossRef] [PubMed]
91. Taverna, E.; Garavaglia, G.; Perfetti, C.; Ufenast, H.; Sconfienza, L.M.; Guarrella, V. An arthroscopic bone block procedure is effective in restoring stability, allowing return to sports in cases of glenohumeral instability with glenoid bone deficiency. *Knee Surg. Sports Traumatol. Arthrosc.* **2018**, *26*, 3780–3787. [CrossRef] [PubMed]
92. Abdelshahed, M.M.; Shamah, S.D.; Mahure, S.A.; Mollon, B.; Kwon, Y.W. Cryopreserved bone allograft for the treatment of shoulder instability with glenoid defect. *J. Orthop.* **2018**, *15*, 248–252. [CrossRef] [PubMed]
93. Warner, J.J.; Gill, T.J.; O'hollerhan, J.D.; Pathare, N.; Millett, P.J. Anatomical glenoid reconstruction for recurrent anterior glenohumeral instability with glenoid deficiency using an autogenous tricortical iliac crest bone graft. *Am. J. Sports Med.* **2006**, *34*, 205–212. [CrossRef] [PubMed]
94. Steffen, V.; Hertel, R. Rim reconstruction with autogenous iliac crest for anterior glenoid deficiency: Forty-three instability cases followed for 5–19 years. *J. Shoulder Elb. Surg.* **2013**, *22*, 550–559. [CrossRef] [PubMed]
95. Moroder, P.; Plachel, F.; Becker, J.; Schulz, E.; Abdic, S.; Haas, M.; Resch, H.; Auffarth, A. Clinical and Radiological Long-term Results After Implant-Free, Autologous, Iliac Crest Bone Graft Procedure for the Treatment of Anterior Shoulder Instability. *Am. J. Sports Med.* **2018**, *46*, 2975–2980. [CrossRef] [PubMed]
96. Zhao, J.; Huangfu, X.; Yang, X.; Xie, G.; Xu, C. Arthroscopic glenoid bone grafting with nonrigid fixation for anterior shoulder instability: 52 patients with 2- to 5-year follow-up. *Am. J. Sports Med.* **2014**, *42*, 831–839. [CrossRef] [PubMed]
97. Weng, P.W.; Shen, H.C.; Lee, H.H.; Wu, S.S.; Lee, C.H. Open reconstruction of large bony glenoid erosion with allogeneic bone graft for recurrent anterior shoulder dislocation. *Am. J. Sports Med.* **2009**, *37*, 1792–1797. [CrossRef] [PubMed]
98. Auffarth, A.; Schauer, J.; Matis, N.; Kofler, B.; Hitzl, W.; Resch, H. The J-bone graft for anatomical glenoid reconstruction in recurrent posttraumatic anterior shoulder dislocation. *Am. J. Sports Med.* **2008**, *36*, 638–647. [CrossRef] [PubMed]
99. Provencher, M.T.; Peebles, L.A.; Aman, Z.S.; Bernhardson, A.S.; Murphy, C.P.; Sanchez, A.; Dekker, T.J.; LaPrade, R.F.; Di Giacomo, G. Management of the Failed Latarjet Procedure: Outcomes of Revision Surgery With Fresh Distal Tibial Allograft. *Am. J. Sports Med.* **2019**, *47*, 2795–2802. [CrossRef] [PubMed]
100. Malik, S.S.; Elashry, S.; Jordan, R.W.; Choudhary, S.; Kalogrianitis, S. Is there a difference in outcome of arthroscopic iliac crest autograft and allograft in recurrent anterior shoulder instability? *Eur. J. Orthop. Surg. Traumatol.* **2020**, *30*, 1453–1461. [CrossRef] [PubMed]
101. Choke, A.; Wonggokusuma, E.; Lai, M.C.; Lie, D.T.T. Clinical outcomes of an all-arthroscopic glenoid reconstruction using iliac crest bone graft with a double cannulated screw fixation technique. *Asia Pac. J. Sports Med. Arthrosc. Rehabil. Technol.* **2021**, *24*, 41–48. [CrossRef] [PubMed]
102. Oldfield, M.; Burns, J.; Wong, I. Arthroscopic Glenoid Bone Augmentation Using Iliac Crest Autograft Is Safe and Effective for Anterior Shoulder Instability With Bone Loss. *Arthrosc. Sports Med. Rehabil.* **2021**, *3*, e1671–e1677. [CrossRef] [PubMed]
103. Boehm, E.; Minkus, M.; Moroder, P.; Scheibel, M. Arthroscopic iliac crest bone grafting in recurrent anterior shoulder instability: Minimum 5-year clinical and radiologic follow-up. *Knee Surg. Sports Traumatol. Arthrosc.* **2021**, *29*, 266–274. [CrossRef] [PubMed]
104. Wong, I.; John, R.; Ma, J.; Coady, C.M. Arthroscopic Anatomic Glenoid Reconstruction Using Distal Tibial Allograft for Recurrent Anterior Shoulder Instability: Clinical and Radiographic Outcomes. *Am. J. Sports Med.* **2020**, *48*, 3316–3321. [CrossRef] [PubMed]
105. Locher, J.; Longo, U.G.; Pirato, F.; Susdorf, R.; Henninger, H.B.; Suter, T. Open anatomical glenoid reconstruction with an iliac crest bone autograft effectively resolves off-track Hill-Sachs lesions to on-track lesions. *Arch. Orthop. Trauma Surg.* **2023**, *143*, 203–211. [CrossRef] [PubMed]
106. Wu, C.; Xu, J.; Fang, Z.; Chen, J.; Ye, Z.; Wu, X.; Li, Z.; Wang, L.; Kang, Y.; Zhao, S.; et al. Clinical and Radiological Outcomes in Patients With Anterior Shoulder Instability and Glenoid Bone Loss after Arthroscopic Free Bone Block Combined With Dynamic Anterior Stabilization. *Am. J. Sports Med.* **2023**, *51*, 187–197. [CrossRef] [PubMed]
107. Frank, R.M.; Romeo, A.A.; Richardson, C.; Sumner, S.; Verma, N.N.; Cole, B.J.; Nicholson, G.P.; Provencher, M.T. Outcomes of Latarjet Versus Distal Tibia Allograft for Anterior Shoulder Instability Repair: A Matched Cohort Analysis. *Am. J. Sports Med.* **2018**, *46*, 1030–1038. [CrossRef]
108. Moroder, P.; Schulz, E.; Wierer, G.; Auffarth, A.; Habermeyer, P.; Resch, H.; Tauber, M. Neer Award 2019: Latarjet procedure vs. iliac crest bone graft transfer for treatment of anterior shoulder instability with glenoid bone loss: A prospective randomized trial. *J. Shoulder Elb. Surg.* **2019**, *28*, 1298–1307. [CrossRef] [PubMed]

109. Bockmann, B.; Nebelung, W.; Gröger, F.; Leuzinger, J.; Agneskirchner, J.; Brunner, U.; Seybold, D.; Streich, J.; Bartsch, S.; Schicktanz, K.; et al. The arthroscopic treatment of anterior shoulder instability with glenoid bone loss shows similar clinical results after Latarjet procedure and iliac crest autograft transfer. *Knee Surg. Sports Traumatol. Arthrosc.* **2023**, *31*, 4566–4574. [CrossRef] [PubMed]
110. Page, M.J.; McKenzie, J.E.; Bossuyt, P.M.; Boutron, I.; Hoffmann, T.C.; Mulrow, C.D.; Shamseer, L.; Tetzlaff, J.M.; Akl, E.A.; Brennan, S.E.; et al. The PRISMA 2020 statement: An updated guideline for reporting systematic reviews. *BMJ* **2021**, *372*, n71. [CrossRef] [PubMed]

Disclaimer/Publisher's Note: The statements, opinions and data contained in all publications are solely those of the individual author(s) and contributor(s) and not of MDPI and/or the editor(s). MDPI and/or the editor(s) disclaim responsibility for any injury to people or property resulting from any ideas, methods, instructions or products referred to in the content.