transplantology

MDPI

Case Report

Kidney Re-Transplantation after Simultaneous Heart and Kidney Transplant: Case Study and Literature Review

Antonina Przybył [1], Zbigniew Heleniak [1,*], Jarosław Kobiela [2], Iwona Stopczyńska [3], Marian Zembala [4,†], Michał Zakliczyński [5], Leszek Domański [6], Jacek Różański [6] and Alicja Dębska-Ślizień [1]

1 Department of Nephrology, Transplantology and Internal Medicine, Medical University of Gdansk, 80-952 Gdańsk, Poland; tosia.przybyl@gmail.com (A.P.); adeb@gumed.edu.pl (A.D.-Ś.)
2 Department of General, Endocrine and Transplant Surgery, Medical University of Gdansk, 80-952 Gdańsk, Poland; jaroslaw.kobiela@gumed.edu.pl
3 1st Department of Cardiology, Medical University of Gdansk, 80-952 Gdańsk, Poland; iwona.stopczynska@gumed.edu.pl
4 Department of Cardiac Surgery, Transplantology and Vascular Surgery, Medical University of Silesia, 41-800 Zabrze, Poland; m.zembala@sccs.pl
5 Cardiac Transplantation and Mechanical Circulatory Support Unit, Institute of Heart Diseases, Faculty of Medicine, Wroclaw Medical University, 50-558 Wrocław, Poland; michal.zakliczynski@umw.edu.pl
6 Department of Nephrology, Transplantology and Internal Medicine, Pomeranian Medical University, 70-111 Szczecin, Poland; leszek.domanski@pum.edu.pl (L.D.); jacek.rozanski@pum.edu.pl (J.R.)
* Correspondence: zbigniew.heleniak@gumed.edu.pl; Tel.: +48-58-584-47-00
† Deceased author.

check for updates

Citation: Przybył, A.; Heleniak, Z.; Kobiela, J.; Stopczyńska, I.; Zembala, M.; Zakliczyński, M.; Domański, L.; Różański, J.; Dębska-Ślizień, A. Kidney Re-Transplantation after Simultaneous Heart and Kidney Transplant: Case Study and Literature Review. *Transplantology* **2022**, *3*, 124–129. https://doi.org/10.3390/transplantology3020013

Academic Editor: Wisit Cheungpasitporn

Received: 23 January 2022
Accepted: 12 April 2022
Published: 14 April 2022

Publisher's Note: MDPI stays neutral with regard to jurisdictional claims in published maps and institutional affiliations.

Correction Statement: This article has been republished with a minor change. The change does not affect the scientific content of the article and further details are available within the backmatter of the website version of this article.

Copyright: © 2022 by the authors. Licensee MDPI, Basel, Switzerland. This article is an open access article distributed under the terms and conditions of the Creative Commons Attribution (CC BY) license (https://creativecommons.org/licenses/by/4.0/).

Abstract: The kidney is one of most frequent transplants to be performed in multi-organ transplantation. A simultaneous heart and kidney transplant (SHKT) is the best-known treatment method in patients with severe heart failure and end-stage renal disease (ESRD). Here, the authors describe the case of a kidney re-transplantation after SHKT, which is in accordance with the majority of studies, and proves the safety of simultaneous procedures. The article highlights the complex care required after the transplant, followed by the multi-factor qualification for re-transplantation. In conclusion, the case shows that SHKT provides long-term favorable outcomes and enables a repeated kidney transplantation with satisfactory one-year follow-up results.

Keywords: heart transplantation; kidney transplantation; cardiovascular risk

1. Introduction

Through the years, the kidney has remained the most commonly transplanted organ. According to the Polish association Poltransplant's statistics, in the first six months of 2021 alone, 306 kidney transplantations were performed [1]. In Poland, the number of transplanted patients at the end of 2020 was 332 patients per million (ppm) [2]. For many years, transplantation has enabled a dialysis-free life, allowing patients to live more simply and independently. Nevertheless, the graft survival time is finite, leading, in many cases, to the failure of the transplanted organ. The number of such cases increases yearly. Many patients are then eligible for re-transplantation. The Polish Transplant Waiting List reports that as of 2019, there were 854 patients awaiting a first kidney transplantation and 311 patients awaiting a re-transplantation (regardless of whether it was a second, third or fourth re-transplantation). Similarly, in 2018 there were 872 potential first kidney recipients and 324 potential re-transplant recipients. In comparison, in 2015, the numbers were 730 and 243, respectively [1]. The kidney is also one of most frequent transplants to be performed in multi-organ transplantation. Simultaneous heart and kidney transplant (SHKT) is the best-known treatment method in patients with severe heart failure and end-stage renal disease (ESRD) [3]. SHKT in Poland is still extremely rare. Thus far (as of 2021) only two such procedures have taken place (the first in 2002, in Zabrze, Silesia; the second in 2018,

in Gdańsk, Pomerania) [4,5]. Worldwide, an increase in such procedures can be noted. According to Shaw from Duke University, South Carolina, in the USA, from 2004 to 2008, the number of SHKT increased nearly five-fold (from 44 to 202) [6]. Following SHKT, the patients in question require complex care.

When facing two organ failures, it is crucial to thoroughly assess the indications for transplantation. Patients who should be considered for cardiac transplantation are those presenting severe symptoms of heart failure, intractable angina or rhythm disturbances, are on optimal medical therapy, and have limited alternatives for treatment. Other indications for cardiac transplantation are deteriorating renal function or the inability to clear congestion without adversely affecting renal function, and worsening right ventricular function or rising pulmonary artery pressure [7,8] As for renal transplantation, according to KDIGO, it is recommended to educate and inform all patients with chronic kidney disease (CKD) G4-G5 (glomerular filtration rate (GFR) < 30 mL/min/1.73 m^2) who are expected to reach ESRD, about kidney transplantation.

In some patients, the kidney graft function may gradually deteriorate. It is unknown how many patients with a failed kidney allograft need dialysis. A retrospective study conducted among 73 SHKT recipients, including 16 postoperative deaths, demonstrated that in a 5-year follow-up, seven (9.6%) returned to dialysis. The most favorable option to avoid dialysis is preemptive kidney re-transplantation.

The aim of this study is to present the case of a kidney re-transplantation after SHKT.

2. Case Study

The 61-year-old patient was diagnosed with ESRD caused by glomerulonephritis, accompanied by heart failure caused by dilated cardiomyopathy developed after myocarditis as a complication of influenza. The CKD lasted approximately 4 years prior to the heart failure. The ESRD required RRT (hemodialysis), which lasted 9 months before the initial transplantation. The patient underwent SHKT on 30 August 2002 in Zabrze, Poland. The original transplantation was performed as a single procedure. Both organs were collected from the same donor. The initial immunosuppression was based on basiliximab, sirolimus, mycophenolate mofetil and glucocorticosteroids. Since then, the heart function remained stable. According to the collected data, during the observation period, the patient did not require hospitalization due to heart failure decompensation. Additionally, the patient did not present symptoms during routine check-ups. This was confirmed by the regularly performed echocardiography. The patient underwent regular diagnostic evaluations, including thorough cardiology diagnostics. Simultaneously, the kidney function was also being monitored. The creatinine level after SHKT was 1.6 mg/dL. An increase was observed in 2017 and a creatinine level above 3 mg/dL was noted in June 2019. The most possible cause of the initial graft failure was its chronic rejection/chronic glomerulopathy of the kidney transplant, but a biopsy was not performed. Subsequently, several comorbidities were diagnosed (Table 1). However, the patient did not present any critical cardiovascular symptoms. The echocardiography showed normal ventricle and atrial dimensions, with an estimated left ventricle ejection fraction (LVEF) of 55–60%. On 28 May 2020, coronarography was performed, which ruled out any coronary vessel abnormalities, including stenosis. After a thorough evaluation the patient was accepted for preemptive re-transplantation and placed on a transplant waiting list in May 2020. The renal replacement therapy (hemodialysis with a vascular access provided with a catheter) started in July 2020, when the creatinine level was 5.7 mg/dL (eGFR CKD-EPI 11 mL/min/1.73 m^2) (Figure 1). After 4.5 months of hemodialysis, the kidney re-transplantation from a deceased donor was performed on 2 December 2020. The warm ischemic time was 29 min, and the cold ischemic time was 5 h 58 min. Immunosuppression according to the protocol (tacrolimus, mycophenolate mofetil (MMF), steroids, basiliximab (Simulect)) was introduced. Additionally, the patient received an antibacterial, antifungal and antiviral prophylaxis including trimethoprim/sulfamethoxazole, ceftriaxone, nystatin and acyclovir. Post-operation, a delayed graft function was observed, seen as a high serum creatinine level 11.1 mg/dL

and overhydration due to inadequate urine output. The patient needed five hemodialysis procedures. Subsequently, the diuresis increased, beginning on the sixth day after the operation, followed by an improvement in renal function parameters. The serum creatinine level was 1.9 mg/dL on discharge. In the follow-up, problems with urination began and prostate gland hypertrophy was diagnosed, and in June 2021 the patient underwent a transurethral prostatic resection. Currently (as of February 2022), the function of both the heart and kidney remains stable with a serum creatinine level of 1.4–1.6 mg/dL. The immunosuppression medications are tacrolimus, mycophenolate mofetil and steroids. Shortly after the transplantation, the diabetes accelerated, resulting in the need for insulin therapy.

Table 1. Comorbidities.

Disease	Year of Diagnosis	Treatment
Prostate gland hypertrophy	2020	Administration of alfa-antagonist and 5 alfa inhibitor, TURP qualification, performed 12 August 2021
Post-transplant non-insulin dependent diabetes mellitus	2008	Acceptable glycemic profile, feasting glucose 110, beginning of insulin therapy
Arterial hypertension	2002	Good control, SBP 120–125, DBP 80–85, combined therapy (B-blocker, diuretic)
Supraventricular arrhythmia	2002	Regular sinus rhythm, treatment with metoprolol

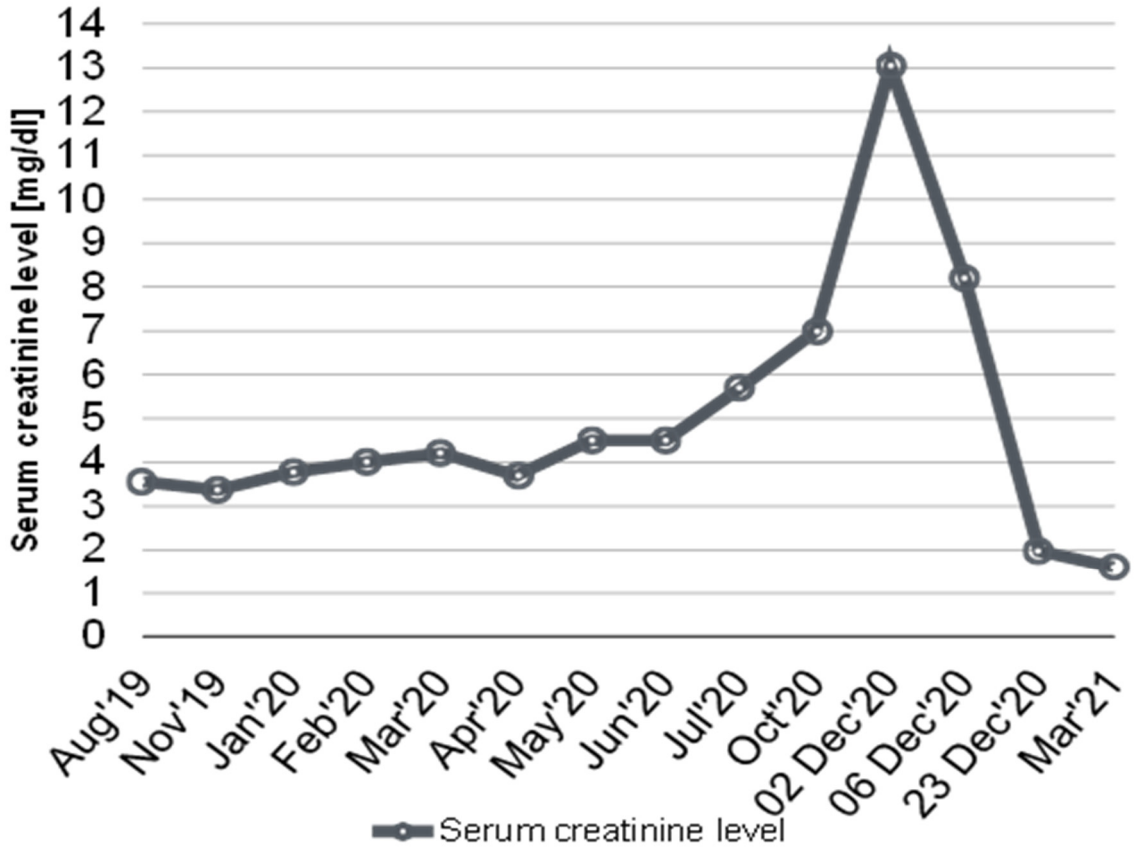

Figure 1. Serum creatinine level throughout the re-transplantation process.

3. Discussion

The presented case shows a history of long-term satisfactory function of both the kidney and heart. Possibilities for data comparisons are limited due to the scarcity of available studies. Nevertheless, the results are consistent with the collected data, proving the safety of SHKT. The studies usually include a 5-year follow-up, which shows acceptable kidney

graft function with a serum creatinine level of 1.5 mg/dL and below 2 mg/dL after the first year and five years, respectively [3,9]. Multiple analyses speak in favor of SHKT from one donor, showing that the kidney graft has a better outcome compared to two donors [10,11]. In comparison with staged kidney-after-heart transplantation, SHKT has some advantages. These include the absence of the potential immunologic risk from receiving organs from two donors; a single procedure requiring one induction therapy and one recovery; and possibly, a lesser need for dialysis after HTx. The advantages of a staged transplantation include the avoidance of peri- and immediate postoperative hemodynamic instability; the improved chance of a heart transplant in a highly sensitized and difficult-to-match patient; and the avoidance of unnecessary kidney transplants and their complications [12]. Often, as a result of multiple organ insufficiency, further disorders may occur, namely, diabetes, obesity, hypertension, hyperlipidaemia, nicotine dependence or alcohol consumption [3]. Several of the mentioned comorbidities were observed in the described case (diabetes, hypertension, overweight, hyperlipidemia), although they were well controlled (SBP < 140 mmHg, diabetes: initially impaired fasting glucose, followed by satisfactory glycemic levels achieved through oral medication, HbA1c 6.5%). In the presence of a preceding multiple organ transplantation and its complexity, it is reasonable to make a comparison with other solid organ transplantations such as simultaneous heart and lung (SHL), heart transplant (HTx), lung transplant (LTx). Calcineurin inhibitor nephrotoxicity and pre-transplantation renal disease (diabetes, hypertensive nephrosclerosis, glomerulonephritis and polycystic kidney disease) are the most common factors that contribute to developing ESRD [13].

According to the literature, ESRD develops faster after SHL than HTx (115.4 vs. 145.7 months) [14,15]. In the presented case, the time between SHKT and repeated KTx was 216 months, which was clearly longer compared to the above data. Additionally, patients after LTx, HTx and SHLTx with post-transplant kidney failure remained on dialysis for an average of 12.5 months. In our case, the hemodialysis was carried out for 4.5 months only. In spite of a previous multiple organ transplantation, the preparation for the re-transplantation is similar to a primary qualification. The cardiological assessment is vital. Cardiovascular events (CVE) are the most common cause of mortality in patients with kidney failure, such as ESRD, hemodialysis, and even after successful KTx. The American Heart Association and the American College of Cardiology Foundation (AHA/ACC Foundation) name eight risk factors that should be monitored in potential kidney recipients (age > 60 years, smoking, dyslipidemia, hypertension, diabetes mellitus, known coronary artery disease (CAD), left ventricular hypertrophy, and being in ESRD for >12 months). Invasive diagnostics might be omitted when the CVE risk is low. In the presence of symptoms or a past history of cardiac disease, both leading to an elevated risk of CVE, invasive strategies (coronarography) should be performed, allowing the risk level to be set, and if needed, to react accordingly. The described patient underwent echocardiography and coronarography that showed no abnormalities (LVEF ca. 55–60%, valves—good function and structure) [16]. Another aspect is the difference in immunosuppression. An organ transplantation in a patient's medical history may lead to high-level immunization; therefore, highly-sensitized patients are at risk of longer waiting times, more graft rejection, and poorer graft outcomes. The immunosuppressive regimen in our case included induction therapy with basiliximab. Nowadays, patients usually receive modern immunosuppression that may still cause long-term side-effects, among which the most common are infections and an elevated risk of malignancy. Kidney recipients show a three-fold higher risk of developing post-transplant malignancy (PTM). Hence, oncological screening is performed, especially for the most frequent types: renal cell carcinoma, skin cancer and post-transplant lymphoproliferative disorders (PTLD). Some studies report the clear benefits of screening, which results in lower mortality rates associated with gastric and colorectal cancers in kidney transplant recipients [17,18]. A suspicion of malignancy or a precancerous condition requires a reduction in immunosuppression. However, there are examples of re-transplantation after PTLD as well as squamous cell carcinoma (SCC) [19,20]. In the presented case, the oncological assessment did not show any abnormalities.

4. Conclusions

The described case of a re-transplantation after SHKT is in accordance with the majority of studies, proving the safety of simultaneous procedures. In this case, kidney graft failure developed after 18 years, which, compared to the collected data, is an extraordinarily long time [3,9]. Such a success may be a result of proper pre-transplantation education, regular control and patient compliance, as well as the cooperation between the cardiologist, nephrologist and transplantologist. The repeated transplant did not deteriorate the function of the heart, and the kidney function remained stable. The authors aimed to highlight the complex care required after transplant, as well as the multi-factor qualification required for re-transplantation. They would also like to highlight that when considering repeated transplant after multi-organ transplantation, the approach should be individualized, and thoroughly discussed with the patient. When comparing solutions for a failed allograft, a few issues should be taken into consideration. These include, on one hand, the risk of CVD due to hemodialysis used as a life-prolonging procedure, and on the other hand, re-transplantation, with the side-effects of a complex procedure including early complications. However, kidney transplantation in heart recipients who require dialysis is of vital importance, since their life expectancy is significantly longer than in those remaining on dialysis and other maintenance dialysis patients [21]. The patient's qualification for the transplant waiting list in the pre-dialysis period in the absence of a living donor does not guarantee a transplantation before dialysis; however, it shortens the waiting time.

In conclusion, the case shows that SHKT provides long-term favorable outcomes and enables a repeated kidney transplantation with satisfactory one-year follow-up results.

Author Contributions: Conceptualization, A.P., Z.H. and A.D.-Ś.; methodology, A.P. and Z.H.; software, A.P. and Z.H.; validation, Z.H., J.K., I.S. and A.D.-Ś.; formal analysis, A.P. and Z.H.; investigation, A.P., Z.H., M.Z. (Marian Zembala), M.Z. (Michał Zakliczyński), L.D., J.R. and A.D.-Ś.; resources, A.P. and Z.H.; data curation, J.K., I.S. and A.D.-Ś.; writing—original draft preparation, A.P. and Z.H.; writing—review and editing, Z.H., J.K., I.S. and A.D.-Ś.; visualization, J.K., I.S. and A.D.-Ś. supervision, A.D.-Ś.; project administration, A.P. and Z.H.; funding acquisition, A.P. and Z.H. All authors have read and agreed to the published version of the manuscript.

Funding: This research received no external funding.

Institutional Review Board Statement: Ethical review and approval was not required for this study as per national legislation (https://isap.sejm.gov.pl/isap.nsf/DocDetails.xsp?id=WDU20240000581) due to its retrospective nature.

Informed Consent Statement: Written informed consent has been obtained from the patient to publish this paper.

Data Availability Statement: Not applicable.

Conflicts of Interest: The authors declare no conflict of interest.

References

1. Centrum Organizacyjno-Koordynacyjne. *"Poltransplant Biuletyn Informacyjny" Nr 1 (29)*; Centrum Organizacyjno-Koordynacyjne: Warszawa, Poland, 2020; ISSN 1428-0825.
2. Debska-Slizien, A.; Rutkowski, B.; Rutkowski, P.; Jagodziński, P.; Korejwo, G.; Przygoda, J.; Gellert, R. Current status of renal replacement therapy in Poland in 2020. *Nephrol. Dial. Pol.* **2020**, *25*, 7–20.
3. Awad, M.; Czer, L.; Esmailian, F.; Jordan, S.; De Robertis, M.; Mirocha, J.; Patel, J.; Chang, D.; Kittleson, M.; Ramzy, D.; et al. Combined Heart and Kidney Transplantation: A 23-Year Experience. *Transpl. Proc.* **2017**, *49*, 348–353. [CrossRef] [PubMed]
4. Centrum Organizacyjno-Koordynacyjne. *"Poltransplant Biuletyn Informacyjny" Nr 1 (11)*; Centrum Organizacyjno-Koordynacyjne: Warszawa, Poland, 2003; ISSN 1428-0825.
5. Centrum Organizacyjno-Koordynacyjne. *"Poltransplant Biuletyn Informacyjny" Nr 1 (26)*; Centrum Organizacyjno-Koordynacyjne: Warszawa, Poland, 2018; ISSN 1428-0825.
6. Shaw, B.I.; Sudan, D.L.; Boulware, L.E.; McElroy, L.M. Striking a Balance in Simultaneous Heart Kidney Transplant: Optimizing Outcomes for All Wait-Listed Patients. *J. Am. Soc. Nephrol.* **2020**, *31*, 1661–1664. [CrossRef] [PubMed]
7. de Jonge, N.; Kirkels, J.H.; Klöpping, C.; Lahpor, J.R.; Caliskan, K.; Maat, A.P.W.M.; Brügemann, J.; Erasmus, M.E.; Klautz, R.J.M.; Verwey, H.F.; et al. Guidelines for heart transplantation. *Neth. Heart J.* **2008**, *16*, 79–87. [CrossRef] [PubMed]

8. Bhagra, S.K.; Pettit, S.; Parameshwar, J. Cardiac transplantation: Indications, eligibility and current outcomes. *Heart* **2019**, *105*, 252–260. [CrossRef] [PubMed]
9. Czer, L.S.C.; Ruzza, A.; Vespignani, R.; Jordan, S.; De Robertis, M.A.; Mirocha, J.; Gallagher, S.P.; Patel, K.; Schwarz, E.R.; Kass, R.M.; et al. Survival and Allograft Rejection Rates after Com-bined Heart and Kidney Transplantation in Comparison with Heart Transplantation Alone. *Transpl. Proc.* **2011**, *43*, 3869–3876. [CrossRef] [PubMed]
10. Awad, M.A.; Czer, L.S.C.; Emerson, D.; Jordan, S.; De Robertis, M.A.; Mirocha, J.; Kransdorf, E.; Chang, D.H.; Patel, J.; Kittleson, M.; et al. Combined Heart and Kidney Transplantation: Clinical Experience in 100 Consecutive Patients. *J. Am. Heart Assoc.* **2019**, *8*, e010570. [CrossRef] [PubMed]
11. Toinet, T.; Dominique, I.; Cholley, I.; Vanalderwerelt, V.; Goujon, A.; Paret, F.; Bessede, T.; Delaporte, V.; Salomon, L.; Badet, L.; et al. Renal outcome after simultaneous heart and kidney transplantation. *Clin. Transpl.* **2019**, *33*, e13615. [CrossRef] [PubMed]
12. Cheng, X.S.; Khush, K.K.; Wiseman, A.; Teuteberg, J.; Tan, J.C. To kidney or not to kidney: Applying lessons learned from the simultaneous liver-kidney transplant policy to simultaneous heart-kidney transplantation. *Clin. Transpl.* **2020**, *34*, e13878. [CrossRef] [PubMed]
13. Cassuto, J.R.; Reese, P.P.; Sonnad, S.; Bloom, R.D.; Levine, M.H.; Olthoff, K.M.; Shaked, A.; Naji, A.; Abt, P. Wait list death and survival benefit of kidney transplantation among non-renal transplant recipients. *Am. J. Transpl.* **2010**, *10*, 2502–2511. [CrossRef] [PubMed]
14. González-Vílchez, F.; Vázquez de Prada, J.A. Chronic Renal Insufficiency in Heart Transplant Recipients: Risk Factors and Management Options. *Drugs* **2014**, *74*, 1481–1494. [CrossRef] [PubMed]
15. Roest, S.; Hesselink, D.A.; Klimczak-Tomaniak, D.; Kardys, I.; Caliskan, K.; Brugts, J.J.; Maat, A.P.; Ciszek, M.; Constantinescu, A.A.; Manintveld, O.C. Incidence of end-stage renal disease after heart transplantation and effect of its treatment on survival. *ESC Heart Fail.* **2020**, *7*, 533–541. [CrossRef] [PubMed]
16. Herzog, A.L.; Kalogirou, C.H.; Wanner, C.H.; Lopau, K. Comparison of different algorithms for the assessment of cardiovascular risk after kidney transplantation by the time of entering the waiting list. *Clin Kidney J.* **2019**, *13*, 150–158. [CrossRef] [PubMed]
17. Wong, G.; Li, M.W.; Howard, K.; Hua, D.K.; Chapman, J.R.; Bourke, M.; Turner, R.; Tong, A.; Tong, J.C. Health benefits and costs of screening for colorectal cancer in people on dialysis or who have received a kidney transplant. *Nephrol. Dial. Transpl.* **2013**, *28*, 917–926. [CrossRef] [PubMed]
18. Lee, I.S.; Kim, T.H.; Kim, Y.H. Clinical significance of gastric cancer surveillance in renal transplant recipients. *World J. Surg.* **2012**, *36*, 1806–1810. [CrossRef] [PubMed]
19. Leeaphorn, N.; Thongprayoon, C.; Chewcharat, A.; Hansrivijit, P.; Jadlowiec, C.C.; Cummings, L.S.; Katari, S.; Mao, S.A.; Cheungpasitporn, W. Outcomes of kidney retransplantation in recipients with prior posttransplant lymphoproliferative disorders: An analysis of the 2000–2019 UN-OS/OPTN database. *Am. J. Transpl.* **2021**, *21*, 846–853. [CrossRef] [PubMed]
20. Ducroux, E.; Martin, C.; Bavinck JN, B.; Decullier, E.; Brocard, A.; Westhuis-van Elsäcker, M.E.; Lebbé, C.; Francès, C.; Morelon, E.; Legendre, C.; et al. Risk of Aggressive Skin Cancers after Kidney Retransplantation in Patients with Previous Posttransplant Cutaneous Squamous Cell Carcinomas: A Ret-rospective Study of 53 Cases. *Transplant* **2017**, *101*, e133–e141. [CrossRef] [PubMed]
21. Alam, A.; Badovinac, K.; Ivis, F.; Trpeski, L.; Cantarovich, M. The outcome of heart transplant recipients following the development of end-stage renal disease: Analysis of the Canadian Organ Replacement Register (CORR). *Am. J. Transpl.* **2007**, *7*, 461–465. [CrossRef] [PubMed]