reproductive medicine

MDPI

*Case Report*

# A Rare Case of a Large Composite Endometrioma–Mature Cystic Teratoma: The Importance of Surgical Treatment and Pathologic Diagnosis

**Jun Song * and Caitlin Martin**

Department of OBGYN, University of Texas Health Science Center at San Antonio, San Antonio, TX 78229, USA
* Correspondence: junsongmd@gmail.com; Tel.: +1-615-686-9648

**Abstract:** Endometriosis is a common benign gynecologic disorder associated with infertility and pelvic pain, affecting 6–11% of reproductive-age females, and can frequently lead to the formation of ovarian endometriomas. Mature cystic teratomas are benign ovarian tumors comprising 10–25% of ovarian tumors. Both pathologies are common individually but rarely coexist. The case presented here describes a 49-year-old female presenting with a large composite endometrioma–mature cystic teratoma, a rare occurrence with few documented cases. The patient had a 24 cm × 17 cm × 15 cm adnexal mass identified via imaging, which was surgically removed. Pathology confirmed a composite tumor, with the teratoma encased within the endometrioma. This case underscores the importance of surgical management in complex adnexal masses to obtain tissue for definitive diagnosis and to exclude malignancy. Given the rarity of such coexistence and the challenges in preoperative diagnosis, surgical intervention is crucial for accurate diagnosis and effective management.

**Keywords:** endometriosis; endometrioma; teratoma; adnexal mass

check for updates

**Citation:** Song, J.; Martin, C. A Rare Case of a Large Composite Endometrioma–Mature Cystic Teratoma: The Importance of Surgical Treatment and Pathologic Diagnosis. *Reprod. Med.* **2024**, *5*, 280–287. https://doi.org/10.3390/reprodmed5040024

Academic Editor: Jan Tesarik

Received: 26 August 2024
Revised: 3 November 2024
Accepted: 22 November 2024
Published: 29 November 2024

**Copyright:** © 2024 by the authors. Licensee MDPI, Basel, Switzerland. This article is an open access article distributed under the terms and conditions of the Creative Commons Attribution (CC BY) license (https://creativecommons.org/licenses/by/4.0/).

## 1. Introduction

Endometriosis is a benign gynecologic disorder commonly associated with infertility and pelvic pain that affects 6 to 11 percent of all reproductive-age females [1,2]. Ovarian endometriomas are benign ovarian tumors frequently found in patients with endometriosis. Mature cystic teratomas are also commonly found in reproductive-aged women that account for nearly 10 to 25 percent of all ovarian tumors and up to 60 percent of benign ovarian tumors [3,4]. While endometriosis and mature cystic teratomas are in themselves common, the coexistence of both conditions is rare [5].

In a review of existing literature, there have been very few reported cases of coexisting endometriosis with teratoma in the same ovary [6–10]. In most of these cases, endometriosis was diagnosed by endometrial cells on histology, without the existence of a discrete endometrioma. One of these reported cases did contain a teratoma with coexisting endometrioma, though of a much smaller size [10]. Here, we present a unique case of a large composite endometrioma–mature teratoma, which we feel is important for its rareness in presentation, its size, and the age of the patient. This case highlights the importance of surgical excision in the management of these kinds of adnexal masses to obtain tissue for pathologic diagnosis.

## 2. Case Presentation

A 49-year-old gravida 5 para 5 female without any significant medical, surgical, obstetric, or gynecologic history presented to the emergency room at our hospital with a chief complaint of lower abdominal pain with associated nausea. She reported progressively increasing abdominal pain over a period of 4 months. She described weight loss and increasingly heavier menstrual cycles over the same timeframe with associated dysmenorrhea. She also reported that her family had observed that since she has lost weight, she now

"looked pregnant." She was from a nearby city and had previously been evaluated at a local health center, where computed tomography (CT) imaging had revealed a 30 cm × 18 cm ovarian mass. At that time, her gynecologist obtained a cancer antigen 125 (CA 125) level which was "very elevated" (this was per patient report, as we were unable to obtain outside records), and the patient was told she needed to seek care with specialists at our facility for a higher level of care. On physical exam, she was noted to have a visible and palpable abdominal mass filling the abdomen and extending up to her xyphoid process. She was mildly tender to palpation without any peritonitic signs.

Laboratory testing revealed a microcytic anemia with hemoglobin level of 8.1 g/dL, hematocrit of 28.7%, mean corpuscular volume (MCV) of 72.7 fL, with otherwise normal white blood cell count and platelet count. A complete metabolic profile (CMP) was unremarkable, and her pregnancy test was negative. Tumor markers were sent and were notable for an elevated CA 125 level of 40.4 ng/mL (normal <20.1 ng/mL) and elevated carcinoembryonic antigen (CEA) level of 3.6 ng/mL (normal <3.1 ng/mL); inhibin-B and CA 19-9 levels were within normal limits.

Imaging with a transvaginal ultrasound revealed a complex-appearing mass measuring 21 cm × 14.5 cm with internal layering. Due to the mass, the sonographer was unable to visualize the patient's uterus or ovaries. A repeat CT performed at our hospital revealed a 24 cm × 17 cm × 15 cm hypodense lesion likely arising from the left ovary with intralesional calcifications and fat, most likely representing a teratoma.

After appropriate counseling including counseling regarding possible malignancy, the patient was admitted to the hospital and surgery was planned for the next day to ensure oncology backup was available in light of her elevated tumor markers. Due to the patient's age, perimenopausal status, satisfied parity, and worsening menorrhagia and dysmenorrhea, the patient was also counseled on her treatment options, and she elected for a concurrent hysterectomy. At the time of surgery, a midline incision was chosen due to the size of the mass. Intraoperatively, a smooth, multilobed left adnexal mass measuring 27 cm × 22 cm × 14 cm was encountered (Figure 1), and a left salpingo-oophorectomy was performed to remove the mass in its entirety without rupture of its contents. The mass was sent for frozen section. The uterus, right fallopian tube, and right ovary were found to be normal in appearance. A close inspection of the abdomen and pelvis revealed normal upper abdominal organs. No endometriotic implants or pelvic adhesions were seen. After the frozen section confirmed that the mass was benign, we then proceeded to perform an abdominal hysterectomy and opportunistic right salpingectomy in a routine fashion without any operative complications. The patient had an uncomplicated surgical course and recovered well postoperatively; she was discharged home on postoperative day number 2.

On pathologic assessment, the specimen was found to be a multiloculated cystic mass weighing 4390 g. Upon opening the mass, a cystic lesion filled with brown endometriotic fluid was noted and was found to contain a firm tan-yellow solid component along with 6 intact adult teeth (Figure 2).

Histologic sections from the ovarian mass revealed an ossified and teeth-baring mature teratoma that was contained within a larger endometriotic cyst in which it appeared to be encased. The pathology report described the mass as a "composite endometrioma–mature teratoma". The endometriotic cyst was lined by endometrial glands and stroma containing hemosiderin (Figure 3). The teratoma was composed mostly of mature bone and a small amount of cartilage (Figure 4), with six teeth seen. The outer soft tissue layer was found to be composed of respiratory and squamous epithelium, minor salivary gland tissue, and a small amount of thyroid tissue and fat (Figure 5). No evidence of malignancy was noted. The uterus was found to be 10 cm × 6 cm × 3 cm with intramural and submucosal leiomyomas as well as adenomyosis. Bilateral fallopian tubes were unremarkable.

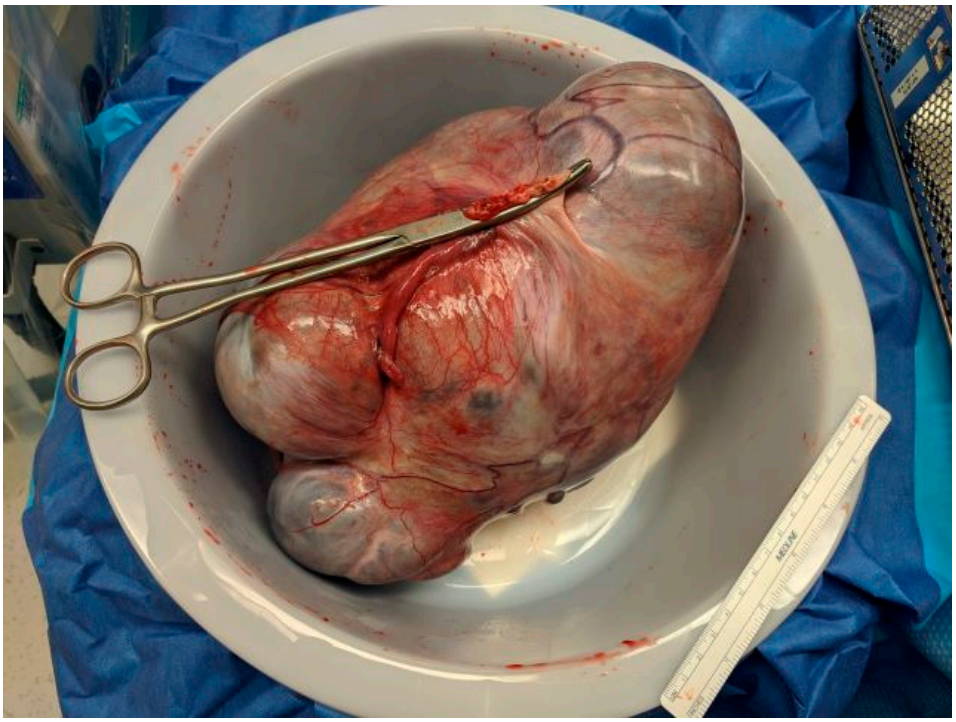

**Figure 1.** The left ovarian cyst (4390 g and 27 cm in greatest dimension) was removed intact and sent for intraoperative frozen section.




**Figure 2.** Upon opening, the endometriotic cyst contained a 5.5 cm calcified mass with well-formed teeth.

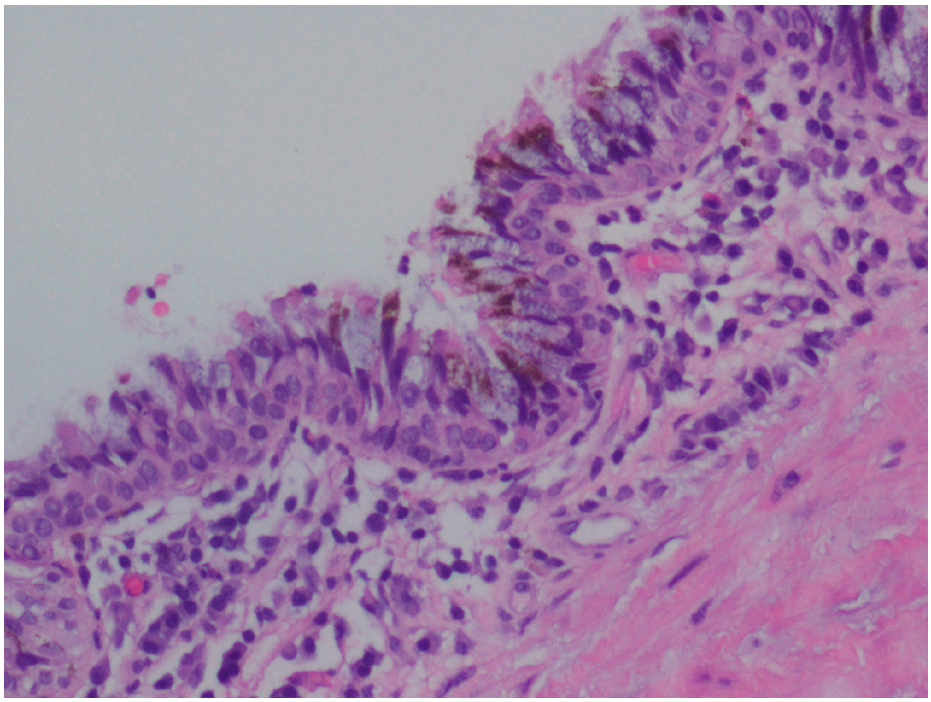

**Figure 3.** The endometriotic cyst is lined by endometrial glands and stroma containing hemosiderin (200×).

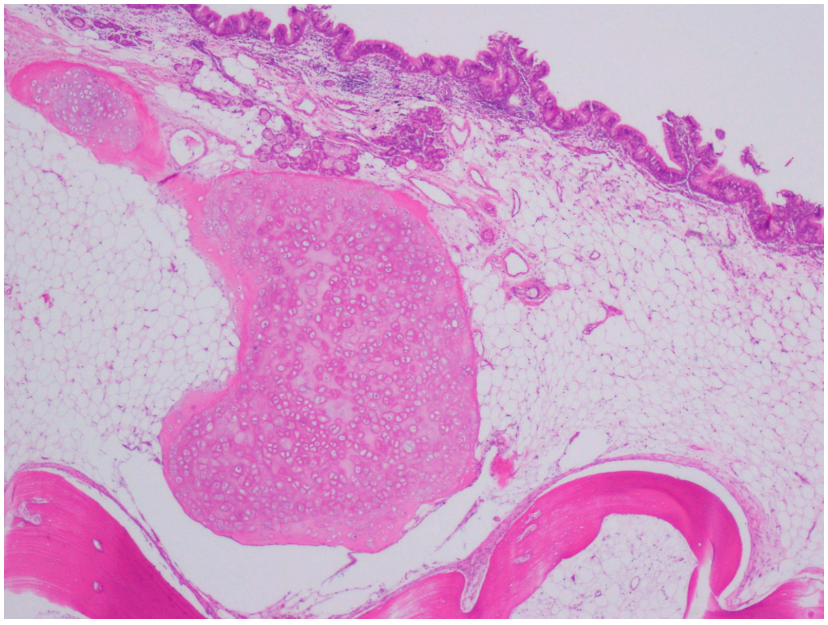

**Figure 4.** The calcified nodule contains bone and some cartilage (100×).

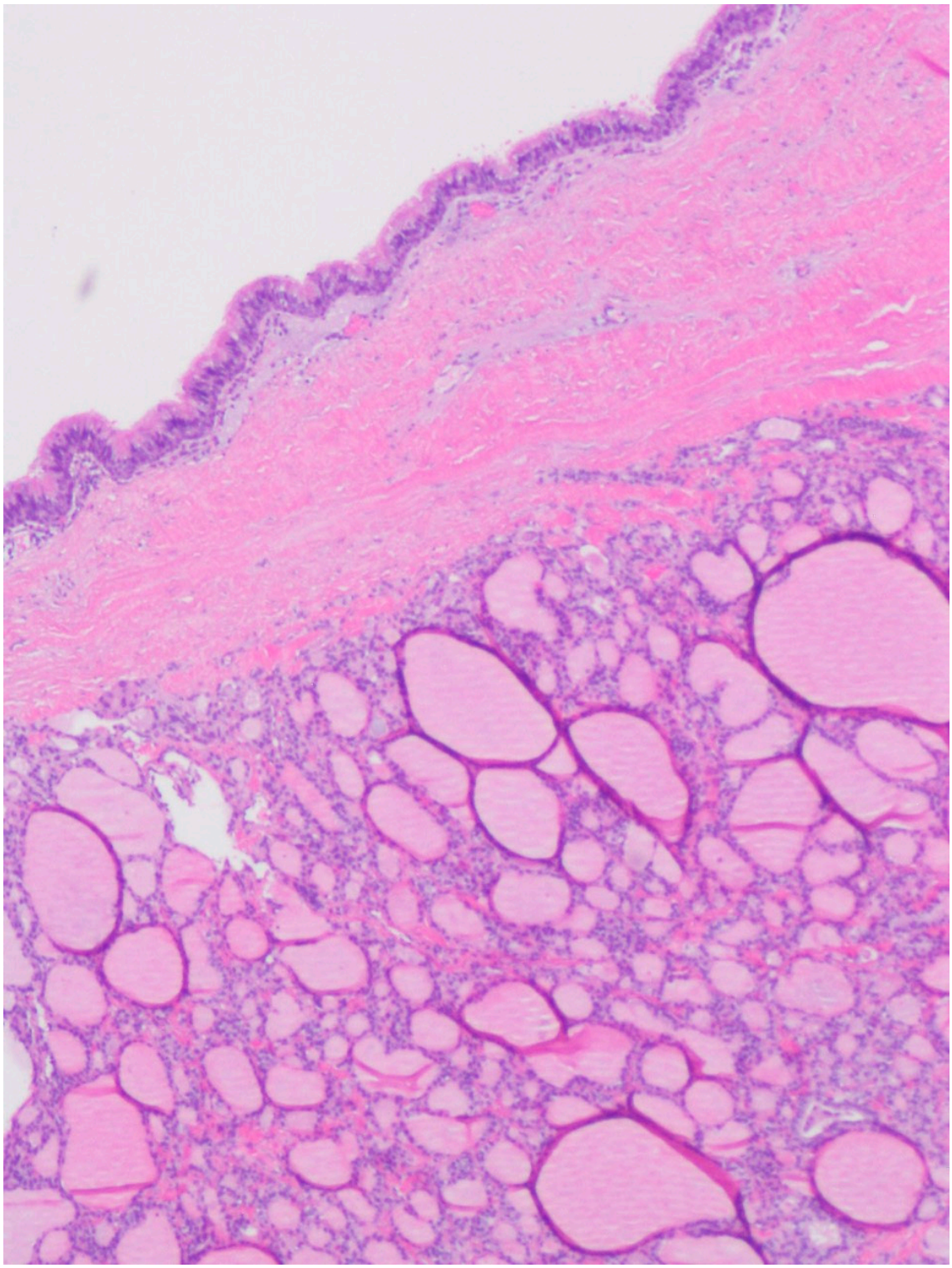

**Figure 5.** A small amount of thyroid tissue is seen underlying ciliated glandular epithelium (100×).

The patient was subsequently seen in our clinic at 2 and 6 weeks postoperatively for her standard postoperative care without any complications noted. She did not report any recurrence of symptoms at her 1-year follow-up, and she was therefore released to her primary gynecologist for the remainder of her routine gynecologic care.

## 3. Discussion

This case report describes a rare case of a mature cystic teratoma contained within a larger endometrioma. A review of the current literature shows only a few case reports of coexisting teratoma within patients with endometriosis, typically characterized by endometrial deposits [6–10]. To our knowledge, there is only one other reported case of a teratoma with an endometrioma found simultaneously in the same ovary; Hwang et al. report a case of struma ovarii coexisting with endometrioma and bilateral teratomas [10]. Table 1 contains a summary of the case reports with characteristics including age, country of origin, gravidity, parity, teratoma size and location, the method of endometriosis diagnosis, and the treatment received.

**Table 1.** Summary of case reports. NR = not reported.

| Author | Country | Age | Gravidity | Parity | Teratoma Size | Teratoma Location | Endometriosis Diagnosis | Treatment |
|---|---|---|---|---|---|---|---|---|
| Van der Merwe (2010) | South Africa | 30 | NR | NR | 40 × 23 × 20 cm | Right ovary | Peritoneal deposits | Open right oophorectomy |
| Chen (2011) | China | 35 | 0 | 0 | 7 × 6 × 6 cm | Right adnexa | Endometrial cells on histology | Laparoscopic ovarian cystectomy |
| Prorocic (2013) | NR | 33 | 0 | 0 | NR | Left adnexa | Endometrial cells on histology | Laparoscopic ovarian cystectomy |
| Chae (2015) | NR | 28 | 1 | 0 | 6 cm | Bilateral | Endometrial tissue in left ovary on histology | Laparoscopic ovarian cystectomy |
| Hwang (2018) | South Korea | 22 | 0 | 0 | 3 cm | Bilateral | Endometrioma in left ovary | Laparoscopic ovarian cystectomy |

The case presented here is unique for its size, as well as for the existence of the teratoma within the endometrioma, hence the diagnosis of a composite endometrioma–mature cystic teratoma. In contrast, the other cases reported in the literature all feature distinct lesions even if they exist within the same adenxa. For our patient, her age, perimenopausal status, satisfied parity status, symptoms of dysmenorrhea and menorrhagia, and elevated tumor markers all factored into her counseling regarding her treatment options and ultimately resulted in her desiring a hysterectomy in addition to the removal of her adnexal mass. While efforts should be made to perform surgeries in a minimally invasive approach, an open approach is appropriate in cases of larger masses or masses with concern for possible malignancy. In younger women or those who still desire childbearing potential, attempts should be made to perform fertility-sparing surgeries.

Endometriosis is a common, benign gynecologic disorder defined by the presence of endometrial tissue outside of its normal location. Its prevalence ranges from 6 to 11 percent of all reproductive-age females [1,2], though up to 25 percent of those with endometriosis may be asymptomatic [11]. However, endometriosis is commonly associated with infertility and pelvic pain and is more prevalent in women with such symptoms. Various studies have shown the incidence of endometriosis to be between 20 and 50 percent in women with infertility and between 40 and 50 percent in those with pelvic pain [12–14].

Ovarian endometriomas are benign ovarian tumors frequently found in patients with endometriosis. Endometriomas are characteristically dark-brown ovarian cysts filled with chocolate-appearing fluid. Endometriomas are typically treated with surgical resection to exclude malignancy, treat associated pelvic pain, or improve future fertility. Despite

cystectomy, endometriomas may still recur. Liu et al. [15] found a recurrence rate of approximately 15 percent at 2 years after initial surgery.

Mature cystic teratomas, commonly referred to as dermoid cysts, also occur frequently in reproductive-aged women. Mature teratomas are benign ovarian germ cell tumors arising from any of the three germ cell layers—ectoderm, mesoderm, or endoderm. These cysts can contain sebaceous and sweat glands, hair, fatty secretions, thyroid tissue, and at times even bone or teeth. Mature cystic teratomas comprise nearly 10 to 25 percent of all ovarian tumors and up to 60 percent of benign ovarian tumors [3,4]. They occur bilaterally in approximately 10 percent of cases. Rarely, malignant transformation of mature teratomas can develop in 0.06 to 2 percent of cases, typically in older or postmenopausal females [16,17]. Due to their size, mature cystic teratomas can often undergo torsion, but cyst rupture is rare. However, if cysts do spill, acute peritonitis can occur. Because symptoms of teratomas are similar to those of other ovarian cysts, and due to the risk of malignant transformation, many women with mature cystic teratomas are managed surgically to obtain a definitive diagnosis, provide symptomatic relief, and prevent torsion, rupture, and malignant degeneration.

## 4. Conclusions

This case highlights the complexity and difficulty of preoperative radiologic diagnosis of complex adnexal masses, especially when features are suggestive of mature cystic teratomas. The management of such tumors can also be challenging due to the low risk of possible malignancy. Although the coexistence of multiple pathologies within the same ovary is an overall rare occurrence, it can be particularly difficult to rule out cancer in a complex mass of this large size. In challenging cases such as this, we feel that it is essential to counsel patients regarding the importance of surgical excision to obtain a pathologic evaluation of such masses, in order to confirm the diagnosis with tissue pathology and to exclude malignancy.

**Author Contributions:** Conceptualization, J.S. and C.M.; data curation, J.S.; writing—original draft preparation, J.S.; writing—review and editing, C.M. All authors have read and agreed to the published version of the manuscript.

**Funding:** This research received no external funding.

**Institutional Review Board Statement:** This study was IRB exempt.

**Informed Consent Statement:** Informed consent was obtained from the patient to publish this paper.

**Data Availability Statement:** Data is contained within the article.

**Conflicts of Interest:** The authors declare no conflicts of interest.

## References

1. Buck Louis, G.M.; Hediger, M.L.; Peterson, C.M.; Croughan, M.; Sundaram, R.; Stanford, J.; Chen, Z.; Fujimoto, V.Y.; Varner, M.W.; Trumble, A.; et al. Incidence of endometriosis by study population and diagnostic method: The ENDO study. *Fertil. Steril.* **2011**, *96*, 360–365. [CrossRef] [PubMed]
2. Mahmood, T.A.; Templeton, A. Prevalence and genesis of endometriosis. *Hum. Reprod.* **1991**, *6*, 544–549. [CrossRef] [PubMed]
3. Koonings, P.P.; Campbell, K.; Mishell, D.R.J.; Grimes, D.A. Relative frequency of primary ovarian neoplasms: A 10-year review. *Obstet. Gynecol.* **1989**, *74*, 921–926. [CrossRef] [PubMed]
4. Peterson, W.F.; Prevost, E.C.; Edmunds, F.T.; Hundley, J.M.J.; Morris, F.K. Benign cystic teratomas of the ovary; a clinico-statistical study of 1,007 cases with a review of the literature. *Am. J. Obstet. Gynecol.* **1955**, *70*, 368–382. [CrossRef] [PubMed]
5. Matalliotakis, M.; Matalliotaki, C.; Zervou, M.I.; Krithinakis, K.; Goulielmos, G.N.; Kalogiannidis, I.; Arici, A.; Spandidos, D.A.; Matalliotakis, I. Retrospective evaluation of pathological results among women with ovarian endometriomas versus teratomas. *Mol. Clin. Oncol.* **2019**, *10*, 592–596. [CrossRef] [PubMed]
6. van der Merwe, J.L.; Siebert, I.; van Wyk, A.C. Rare case of perplexing ovarian endometriosis. *Fertil. Steril.* **2010**, *94*, 1910.e17–1910.e19. [CrossRef] [PubMed]
7. Chen, T.; Kuo, H.; Shyu, S.; Chu, C.; Chang, T. Endometriosis coexisting with dermoid cyst in a single ovary: A case report. *Chin. Med. J.* **2011**, *124*, 627–630. [PubMed]

8. Prorocic, M.; Tasic, L.; Vasiljevic, M.; Jurisic, A.; Smiljkovic, O.D.; Raznatovic, S.; Saranovic, M. Simultaneous dermoid cyst and endometriosis in the same ovary: A case report. *Clin. Exp. Obstet. Gynecol.* **2013**, *40*, 457–459.
9. Chae, H.; Rheu, C. Endometriosis coexisting with mature cystic teratoma in the same ovary and ectopic pregnancy of left fallopian tube: A rare coexistence. *Clin. Case Rep.* **2015**, *3*, 315–318. [CrossRef] [PubMed]
10. Hwang, J.Y.; Lee, M.H.; Lee, J.H.; Kim, D.H.; Song, S.H. A Case of Unilateral Endometriosis Coexisting with Struma Ovarii in Bilateral Ovarian Teratoma. *J. Minim. Invasive Gynecol.* **2018**, *25*, 941–943. [CrossRef]
11. Bulletti, C.; Coccia, M.E.; Battistoni, S.; Borini, A. Endometriosis and infertility. *J. Assist. Reprod. Genet.* **2010**, *27*, 441–447. [CrossRef]
12. Balasch, J.; Creus, M.; Fabregues, F.; Carmona, F.; Ordi, J.; Martinez-Roman, S.; Vanrell, J.A. Visible and non-visible endometriosis at laparoscopy in fertile and infertile women and in patients with chronic pelvic pain: A prospective study. *Hum. Reprod.* **1996**, *11*, 387–391. [CrossRef] [PubMed]
13. Eskenazi, B.; Warner, M.; Bonsignore, L.; Olive, D.; Samuels, S.; Vercellini, P. Validation study of nonsurgical diagnosis of endometriosis. *Fertil. Steril.* **2001**, *76*, 929–935. [CrossRef]
14. Meuleman, C.; Vandenabeele, B.; Fieuws, S.; Spiessens, C.; Timmerman, D.; D'Hooghe, T. High prevalence of endometriosis in infertile women with normal ovulation and normospermic partners. *Fertil. Steril.* **2009**, *92*, 68–74. [CrossRef] [PubMed]
15. Liu, X.; Yuan, L.; Shen, F.; Zhu, Z.; Jiang, H.; Guo, S.-W. Patterns of and risk factors for recurrence in women with ovarian endometriomas. *Obstet. Gynecol.* **2007**, *109*, 1411–1420. [CrossRef] [PubMed]
16. Choi, E.-J.; Koo, Y.-J.; Jeon, J.-H.; Kim, T.-J.; Lee, K.-H.; Lim, K.-T. Clinical experience in ovarian squamous cell carcinoma arising from mature cystic teratoma: A rare entity. *Obstet. Gynecol. Sci.* **2014**, *57*, 274–280. [CrossRef] [PubMed]
17. Rim, S.-Y.; Kim, S.-M.; Choi, H.-S. Malignant transformation of ovarian mature cystic teratoma. *Int. J. Gynecol. Cancer* **2006**, *16*, 140–144. [CrossRef] [PubMed]


**Disclaimer/Publisher's Note:** The statements, opinions and data contained in all publications are solely those of the individual author(s) and contributor(s) and not of MDPI and/or the editor(s). MDPI and/or the editor(s) disclaim responsibility for any injury to people or property resulting from any ideas, methods, instructions or products referred to in the content.