heritage

MDPI

Article

A Multidisciplinary Approach and Technical–Scientific Contribution to the Ecclesiastical Evaluation of Sacred Remains Attributed to Saint Hipolystus and the Martyrs Crescentius and Irenaeus (3rd Century A.D.) from the *Specus Martyrum* of Atripalda (Ancient *Abellinum*)

Chantal Milani [1], Francesca Motta [2], Elena de Laurentiis [1], Cristina Elia [1], Raffaele Cirillo [1], Nicoletta Pomposo [1], Sergio Brogna [3], Francesco La Sala [4], Fabio Marzaioli [5], Domenico Volino [6], Carmen Sementa [7], Francesca Consalvo [1,8,*] and Alessandro Santurro [1,8]

1 Department of Medicine, Surgery and Dentistry, University of Salerno, 84081 Baronissi, Italy; c.milani@identificazionepersonale.it (C.M.); asanturro@unisa.it (A.S.)
2 Pontifical Institute for Christian Archaeology, 00185 Rome, Italy; info@identificazionepersonale.it
3 INPS Medico-Legal Centre of Avellino, 83100 Avellino, Italy
4 San Pio Hospital, 82100 Benevento, Italy
5 CIRCE Laboratory—Center for Isotopic Research on Cultural and Environmental Heritage, University of Campania Luigi Vanvitelli, 81020 San Nicola la Strada, Italy
6 Volino Radiology Center, 83100 Avellino, Italy
7 San Giuseppe Moscati Hospital, 83100 Avellino, Italy
8 University Hospital San Giovanni di Dio e Ruggi d'Aragona, 84081 Salerno, Italy
* Correspondence: fconsalvo@unisa.it

Abstract

Relics and mortal remains attributed to saints and martyrs, long venerated within Christian tradition, represent a unique area of scientific inquiry conducted under canonical procedures aimed at verifying authenticity, ensuring preservation, and promoting public devotion. This study focuses on the canonical recognition of the bone remains preserved in the *Specus Martyrum* of Atripalda (ancient *Abellinum*), attributed to Saint Hipolystus and the martyrs Crescentius and Irenaeus. The investigation was promoted by the Diocese of Avellino in preparation for the Hipolystian Jubilee commemorating 1720 years since their martyrdom (1 May 303 A.D.). A multidisciplinary approach was applied, combining historical analysis of sources such as the *Martyrologium Hieronymianum* (5th century), the *Passio Sancti Hipolysti* (9th century, edited in the *Acta Sanctorum*) and another *Passio* written by the Bishop Ruggero (13th century), with anthropological, radiographic, and radiocarbon (^{14}C) analyses. The skeletal remains were examined through recognition, lateralization, cataloging, and evaluation of morphological and anthropometric features. The results identified elements compatible with an elderly male and two subadult individuals, consistent with the traditional identities of the martyrs. Despite the challenges posed by commingling, fragmentation, and environmental degradation, the investigation demonstrated how scientific rigor can effectively support canonical processes, offering a methodological framework for the verification of relics and contributing to the preservation of religious and cultural heritage.

Keywords: forensic anthropology; canonical recognition; radiocarbon dating; human remains; paleopathology

Check for updates

Academic Editor: Carme Rissech and Lluís Lloveras

Received: 25 December 2025
Revised: 6 March 2026
Accepted: 10 March 2026
Published: 26 March 2026

Copyright: © 2026 by the authors. Licensee MDPI, Basel, Switzerland. This article is an open access article distributed under the terms and conditions of the Creative Commons Attribution (CC BY) license.

1. Introduction

Canonical recognition refers to the process—authorized by Ecclesiastical Authority and governed by Canon Law—that permits the study of saints through direct examination of their physical remains, or relics, with the support of scientific methods. This process increasingly benefits from advanced medical, investigative, and conservation techniques [1–11].

Three types of canonical recognition are typically distinguished: historical, inspective, and conservative [12].

The historical recognition involves a committee of experts analyzing all available documentary sources, including those found in canonical or Vatican archives, and researching minor texts. This investigation aims to confirm the historical data concerning the saint and the preservation of their remains.

The inspective recognition is aimed at verifying the integrity of reliquaries and authenticating the enclosed remains. During this phase, a visual and descriptive examination may be performed. If anomalies or contamination by external biological or chemical agents are identified, a further and more invasive intervention—conservative recognition—may be proposed.

All recognition procedures are regulated by Canon Law, specifically in the document *Sanctorum Mater—Instruction for Conducting Diocesan or Eparchial Inquiries in the Causes of Saints* [13]. This document specifies that the Bishop determines the appropriate moment for recognition and is responsible for overseeing the entire process. Before opening any reliquaries (if present), the notary must read documentation from the most recent recognition to verify that the described contents match the current state. The remains are then removed from the reliquary and laid out for analysis and documentation.

At the end of the procedure, an updated official report is sealed with wax and stamped with the Bishop's seal.

Within this framework, the present study applies a multidisciplinary analytical approach to the examination of skeletal remains traditionally attributed to Saint Hipolystus and the child martyrs Crescentius and Irenaeus, with the aim of defining biologically and chronologically plausible parameters consistent with historical and hagiographic sources, in consideration of the limitations related to the fragmentary condition of the remains and the complexity of their preservation history.

2. Materials and Methods

2.1. Source Analysis

The historical investigation was based on primary medieval sources: the *Martyrologium Hieronymianum ad fidem codicum adiectis prolegomenis* (5th century), the *Passio Sancti Hipolysti* dated back to the 9th century as re-edited in the 1776 edition of the *Acta Sanctorum* compiled by the Bollandists, and another *Passio* quite similar to the first mentioned and reported in a manuscript written by the Bishop Ruggero (13th century) titled *Vita Sancti Hipolysti ac aliquorum martyrum in Abellinensi cimiterio quiescentium* (The life of Saint Hipolystus and some martyrs who rest in the cemetery of *Abellinum*).

2.2. Morphological Anthropological Analysis

The anthropological analysis focused on a group of bones originating from a larger reliquary (Figure 1), selected on the basis of historical sources, with the aim of identifying the morphological features of the bone segments and, as far as possible, the anthropological profile of the individuals—specifically, sex, age at death, and ancestry.

The first diagnostic step was aimed to separate adult and subadults. This distinction is crucial because age estimation from bone and dental fragments is significantly more

accurate in subadults (infants, children, and adolescents), whose growth and development follow relatively predictable stages. In contrast, once skeletal maturity is reached, age-at-death estimates in adults rely primarily on degenerative changes, which yield broader and less precise age ranges [14]. Additionally, sex estimation relies on the presence of sexual dimorphism.



Figure 1. *Cont.*



Figure 1. Reliquaries and skeletal remains from the *Specus Martyrum* of Atripalda (Avellino, Italy), subjected to canonical recognition and anthropological analysis.

According to the recommendations of the Study Group on Forensic Age Diagnostics [15], the age estimation of a living individual for judicial purposes should involve a combination of:

- A physical examination including anthropometric measurements, signs of sexual maturation, and identification of developmental disorders;
- An X-ray of the left hand;
- A dental assessment that documents the state of dentition and includes an orthopantomogram.

Although these protocols are designed for living subjects, the combined application of these criteria also enhances the accuracy of postmortem age estimations and facilitates the detection of age-related biological patterns [16–18].

The biological–anthropological profiles obtained should be associated with morphometric documentation, measurements, or statistical indices. However, despite the integration of these different approaches, due to the extreme fragmentation and intermingling of skeletal remains, it is sometimes not possible to obtain systematic morphometric measurements and statistical indices in a consistent manner.

Sex determination is also dependent on skeletal development and becomes significantly more reliable only after puberty. In subadult remains, the absence of sexual dimorphism makes differentiation between males and females highly unreliable [19–21]. The most commonly used diagnostic features are summarized in Table 1.

Table 1. Morphological traits commonly used in forensic sex determination based on cranial and pelvic features in adult skeletal remains.

Anatomical Region	Trait	Male	Female
Skull	Mandibular angle	Everted, muscular	Smooth, less pronounced
	Shape of the orbits	Rectangular	Rounded
	Forehead	Sloping	Vertical, with step
Pelvis	Subpubic angle	Less than 90°	Greater than 90°
	Greater sciatic notch	Narrow	Wide
	Obturator foramen	Rounded	Broad and triangular
	Acetabulum	Larger	Smaller
	Preauricular sulcus	Rarely present	Often present

In this context, any reliable sex estimation for adult individuals should be considered in a context of a probabilistic evaluation based on the integrated assessment of all available skeletal elements, including pelvic fragments and long bones where preserved, as fragmentary facial bones alone are not sufficient and carry a high error rate.

In ancestry and population affinity evaluation, classification of individuals from different groups can be complex and challenging, due to the diversity within this group. Recurring skeletal features should be noted and analyzed. In particular, standard anatomical craniofacial landmarks of particular interest in forensic anthropology (asterion, bregma, dacryon, ectoconchion, frontomalar temporal, lambda, nasion, subspinal, zygomaxillary, zygoorbital) and dental traits like shovel-shaped incisors, Carabelli's cusp, and other morphological features should be considered. Craniometric measurements obtained from the remains can be compared with standardized reference data to enhance the accuracy of ancestry estimation [22–26].

2.3. Radiographic Investigations

Following the morphological analysis of the bone segments contained within the reliquaries, standard radiographic imaging (X-ray) was conducted on a few bones to supplement the assessment (Figure 2).



Figure 2. Standard radiographic imaging (X-ray) conducted by portable machine inside the *Specus Martyrum* of Atripalda (Avellino, Italy).

In forensic anthropology, radiology is a valuable tool that can assist in various aspects of skeletal analysis. It is particularly useful for estimating age at death, identifying trauma and injury patterns, and aiding in the recognition of unknown deceased individuals [27].

With respect to age estimation, radiographic images enable the detection of biological changes across the human life cycle—from growth-related markers in juveniles to degenerative alterations associated with senescence [28]. For instance, X-rays are frequently applied in subadult skeletons to evaluate the degree of dental mineralization and the ossification status of epiphyseal plates, both of which are critical indicators in age assessment [29]. Obviously, X-rays are also involved in many other processes for the study of skeletal remains for identification, medico-legal/forensic, and paleopathological purposes. Radiographic techniques are routinely employed to assess trauma, detect foreign objects, document pathological changes, and compare antemortem and postmortem records for identification, as well as to investigate ancient diseases and non-invasively analyze archeological human remains.

2.4. Radiocarbon Dating of Bone Fragments

Radiocarbon (^{14}C) is an unstable isotope of carbon that continuously decays over time. As part of the global carbon cycle, ^{14}C is constantly generated in the Earth's upper atmosphere when cosmic-ray neutrons collide with nitrogen (^{14}N) atoms [30]. The resulting

radiocarbon is oxidized into carbon dioxide (CO_2) and absorbed by living organisms through photosynthesis, respiration, and nutrition.

When an organism dies, the exchange of carbon with the environment ceases, and the radiocarbon content in its tissues begins to decrease through a process known as radioactive decay. This decay is governed by the isotope's half-life—the time required for half of the ^{14}C atoms in a sample to disintegrate. For radiocarbon, the conventional half-life is 5730 years [31].

Accelerator Mass Spectrometry (AMS) is currently the most widely, effective and sensitive method for radiocarbon dating of bone remains. It directly measures the isotopic ratio of ^{14}C to ^{12}C and ^{13}C in type I bone collagen extracted from the organic fraction of the bone and, in particular, measures $^{14}C/^{12}C$ isotopic ratios corrected for isotopic fractionation processes (measured as $^{13}C/^{12}C$ isotopic ratios) that occur in nature, in sample preparation and measurement [32–36].

Despite various attempts to obtain accurate radiocarbon determinations from the inorganic component of bone, collagen is still the preferable fraction for collection and radiocarbon dating. However, the preservation state, the content, and the quality of collagen are all of crucial importance when radiocarbon dating bones, and can vary significantly, depending mainly on bone preservation and diagenesis. In particular, the more deteriorated the collagen, the more relevant is its loss, and the larger the probability for the residual collagen to be contaminated.

In general, radiocarbon dating of bone fragments allows accurate dating even from very small or degraded samples, making it particularly suitable for archeological applications. Radiocarbon is also widely applied in forensic contexts, although it requires careful interpretation of laboratory results.

In this study, bone samples were processed following standard protocols employed by the CIRCE Laboratory—Center for Isotopic Research on Cultural and Environmental heritage, University of Campania Luigi Vanvitelli [37]. The isotopic ratios ($^{14}C/^{12}C$) were measured using ultrasensitive accelerator measurement, and calibrated calendrical ages were obtained using the OxCal (v4.4) calibration software.

3. Results

3.1. Source Analysis: Historical and Hagiographic Context

The results of the historical research led to the conclusion that the present Church of Saint Hipolystus in Atripalda (Avellino, Italy) incorporates the *Specus Martyrum*, a paleochristian burial site identified with the pagan necropolis of ancient *Abellinum*. Developed around the graves of early christian martyrs, the site lies outside the ancient residential center, on the eastern bank of the Sabato River, and evolved over time into a true place of worship.

Historical sources report that the body of Saint Hipolystus, martyred in 304 A.D. during the Diocletian persecutions, was retrieved and buried by two noblewomen, Massimilla and Lucretia, in a pagan subterranean necropolis in *Abellinum*, later consecrated by christian veneration.

According to the *Passio Sancti Hipolysti*, dated back to the 9th century, and other hagiographic sources, Saint Hipolystus was born in the mid-3rd century A.D. in Antioch, though some accounts suggest he was born in *Abellinum* (modern-day Atripalda) to parents of Antiochian origin. He belonged to a noble family and was entrusted to a Christian minister during childhood.

Educated in both classical literature and the christian faith, Hipolystus became a priest and traveled extensively before settling in *Abellinum*, a city known to host a community of Orientals relocated by the emperor Alexander Severus.

In 303 A.D., during the Feast of Jupiter on 1 May—an event traditionally marked by the ritual sacrifice of a bull with gilded horns—Hipolystus publicly declared his Christian faith before the local priests and senators. When compelled to venerate the pagan deity, he defied the order by hurling the incense censer at the idol, shattering it.

This act of blasphemy led to his condemnation. He was spat upon and sentenced to death: he was bound to the tail of the sacrificial bull, which was then incited with torches. The animal ran wild down a rugged hillside, dragging Hipolystus over brambles and stones. Once the mutilated body reached the banks of the Sabato River, the executioners decapitated him and left the remains unburied (Figure 3).

Two days later, the noblewomen Massimilla and Lucretia, recently converted to Christianity and later martyred themselves, recovered his body under the cover of night and buried it in a nearby cave—later known as the *Specus Martyrum*.

This martyrdom was soon followed by that of Senator Quinzianus, a convert of Hipolystus, who was executed for refusing to condemn the saint. His sons, Irenaeus (aged about ten) and Crescentius (aged about seven), attempted to shield their father from execution, but were themselves pierced by lances.



Figure 3. *Cont.*



Figure 3. Interior of the *Specus Martyrum*. Detail from the fresco depicting "*the martyrdom of Saint Hipolystus and his companions*", "*removed from the back of the ancient altar of Saint Romulus*" and "*placed by Baron Francesco De Donato*" in the *Specus Martyrum* of Atripalda (Avellino, Italy), as stated in the original caption text at the bottom right of the mural painting.

3.2. Anthropological Analysis

The remains appeared commingled and extremely incomplete and fragmented; even from the initial analysis, it was evident that they had belonged to multiple individuals (it should be noted that the analysis focused on remains from a section of the reliquary that had already been preliminarily separated from the others—albeit approximately—on the basis of historical sources). The reconnaissance investigation allowed for the identification of at least three distinct anthropological profiles. Given the state of preservation, the analysis was necessarily limited to a compatibility-based assessment, including probabilistic evaluations of age at death and biological sex.

A bundle of ancient fabric found within the commingled remains contained the fragmented remains of a skull embedded in brick and sedimentary material. Based on the identified anthropomorphic and anthropometric features, two group were created: adult (A) and subadults (B and C). The adult individual exhibited skeletal features compatible with an advanced adult or senile age and degenerative changes consistent with osteoarthritic pathology. The two subadult individuals showed developmental characteristics compatible with approximate age ranges of 4–6 years and 14–16 years, respectively.

Overall, the anthropological findings contributed to delineating parameters of plausibility consistent with the biological profiles traditionally attributed to Saint Hipolystus and the martyrs Crescentius and Irenaeus. However, these results should be interpreted with caution, particularly in light of the fragmentary nature of the remains and the potential inaccuracies of historical sources regarding age (Figures 4 and 5).

Necessarily, in fact, in such cases, any reference to biological sex or individual identity therefore derives primarily from historical and liturgical tradition, adequately compared with available osteological evidence.

3.2.1. Focus on Adult Remains (A)—Looking for Saint Hipolystus

Morphological analysis of the skeletal remains included:

- Skull: Partial calvarium including portions of the parietal, temporal, and occipital bones; fragmented facial bones.
- Mandible: Fragmented with retained teeth showing wear compatible with upper maxilla remnants.
- Right humerus: Proximal epiphysis revealed arthritic degeneration (osteophytic beaking), consistent with a senile individual.

- Pelvic brim/Os coxae (left and right): Support both male sex and advanced age determination.
- Left femur (diaphyseal fragment), distal femur, left tibia: Morphologically compatible and attributable to an adult male.

Taken together, the available skeletal elements support a probabilistic attribution to an advanced adult individual (estimated age at death > 60 years, ±10 years), with features compatible with male biological sex. However, given the incomplete and commingled nature of the remains, these assessments should be regarded as compatibility-based rather than definitive.

No cervical vertebrae were recovered, precluding the evaluation of skeletal trauma potentially associated with the beheading described in hagiographic sources. No perimortem traumatic lesions were observed on the preserved rib fragments; nevertheless, this absence must be interpreted in light of preservation limitations and does not constitute evidence contradicting hagiographical and historical accounts [38–40].



Figure 4. Analysis and cataloging of the bone remains (group A, adult remains), some of which possibly attributed to Saint Hipolystus.



Figure 5. Analysis and cataloging of the bone remains of subadult individuals (group B–C), some of which can possibly be attributed to Crescentius and Irenaeus.

3.2.2. Focus on Subadult Individuals (B–C)—Looking for Saints Irenaeus and Crescentius

The anthropological analysis of the subadult remains allowed for the reconstruction of two distinct biological profiles, attributable to young individuals whose characteristics could plausibly coincide with those attributed to the martyrs Irenaeus and Crescentius, according to hagiographic tradition.

As before, the remains are partially preserved and highly fragmented, preventing a rapid assessment of the minimum number of individuals. However, the absence of duplication in the major skeletal elements, combined with overall morphological consistency, supports—cautiously—the presence of two separate subadult individuals of different developmental stages.

The estimation of age at death was based on the assessment of epiphyseal fusion, vertebral development, and dental eruption, in accordance with standard parameters used in forensic and physical anthropology. One individual was estimated to be between 4 and 6 years old (±2 years), as detailed in Table 2, based on unfused vertebral arches, ongoing sacral and iliac fusion. The second individual presented more advanced skeletal development, including nearly fused metatarsals and phalanges, permanent dentition, and the fused thoracic vertebrae that lacked intervertebral disks. These features suggest a most probable age-at-death range of 14–16 years (±3 years). However, due to variability among individual skeletal indicators and preservation limitations, a wider developmental interval of 6–20 years cannot be excluded and is reported in Table 3.

Table 2. Fusion status for age estimation for the younger individual attributed to the remains of Irenaeus.

Skeletal Element	Fusion Status
Iliac wings	Complete, isolated
Cervical vertebra 1	Ongoing fusion of anterior arch
Cervical vertebra 2	Ongoing apical fusion
Cervical vertebra 4	Not fused
Thoracic vertebra	Fused body, unfused arch
Thoracic and lumbar vertebrae	Ongoing fusion
Sacral vertebra	Ongoing fusion

Table 3. Fusion status for age estimation for the older individual attributed to the remains of Crescentius.

Skeletal Element	Fusion Status
Proximal epiphysis right humerus	Non-fused epiphysis
Talus	Complete
Right cuboid	Complete
Thoracic vertebra 1	Complete but absent vertebral disk
Thoracic vertebra 8	Complete but absent vertebral disk
Right metatarsus I	Complete with visible fusion lines
Left metatarsus I	Complete with visible fusion lines
Left metatarsus II	Complete distal epiphysis; ongoing fusion of the proximal epiphysis.
Left metatarsus III	Complete distal epiphysis; ongoing fusion of the proximal epiphysis.
Left metatarsus V	Complete distal epiphysis; ongoing fusion of the proximal epiphysis.
Right metatarsus V	Complete distal epiphysis; ongoing fusion of the proximal epiphysis.
Right proximal phalanx III	Complete
Left lower lateral incisor	Permanent
Right lower canine	Permanent

In both cases, sex determination was not possible due to the young age and the skeletal development of the individuals, and in particular due to the absence of sufficiently developed sexual markers. In this context, biological sex estimation and determination of the bone remains—which could plausibly belong to individuals of male sex—are principally based on historical and ecclesiastical presumption derived from hagiographic sources.

No traumatic lesions compatible with sharp force or penetrating injuries were identified on the preserved skeletal elements. Nevertheless, the absence of key anatomical regions—such as the thoracic cage and cervical spine—prevents a definitive exclusion

of lesions consistent with the modes of martyrdom described in the sources, specifically piercing by lances and decapitation.

Overall, the morphological and osteometric characteristics recorded are not entirely inconsistent with the ages attributed to the martyrs Crescentius and Irenaeus, estimated at approximately seven and ten years old, respectively, according to local liturgical tradition and considering some inaccuracies in the sources. The preservation of some anatomical regions allowed for a detailed assessment of skeletal maturity, providing objective evidence to support the plausibility—though not the confirmation—of the proposed attribution. Finally, the identification of two right cuboids, together with comparative epiphyseal analysis of the metatarsals and phalanges, revealed a non-overlapping duplication, supporting the presence of at least two biologically distinct individuals, consistent with the hypothesis of two subadult martyrs.

3.3. Radiographic Analysis

Standard radiographic imaging (X-ray) was conducted on selected skeletal elements to support the anthropological assessment, particularly in estimating age at death and identifying possible pathological or traumatic alterations (Figure 6).

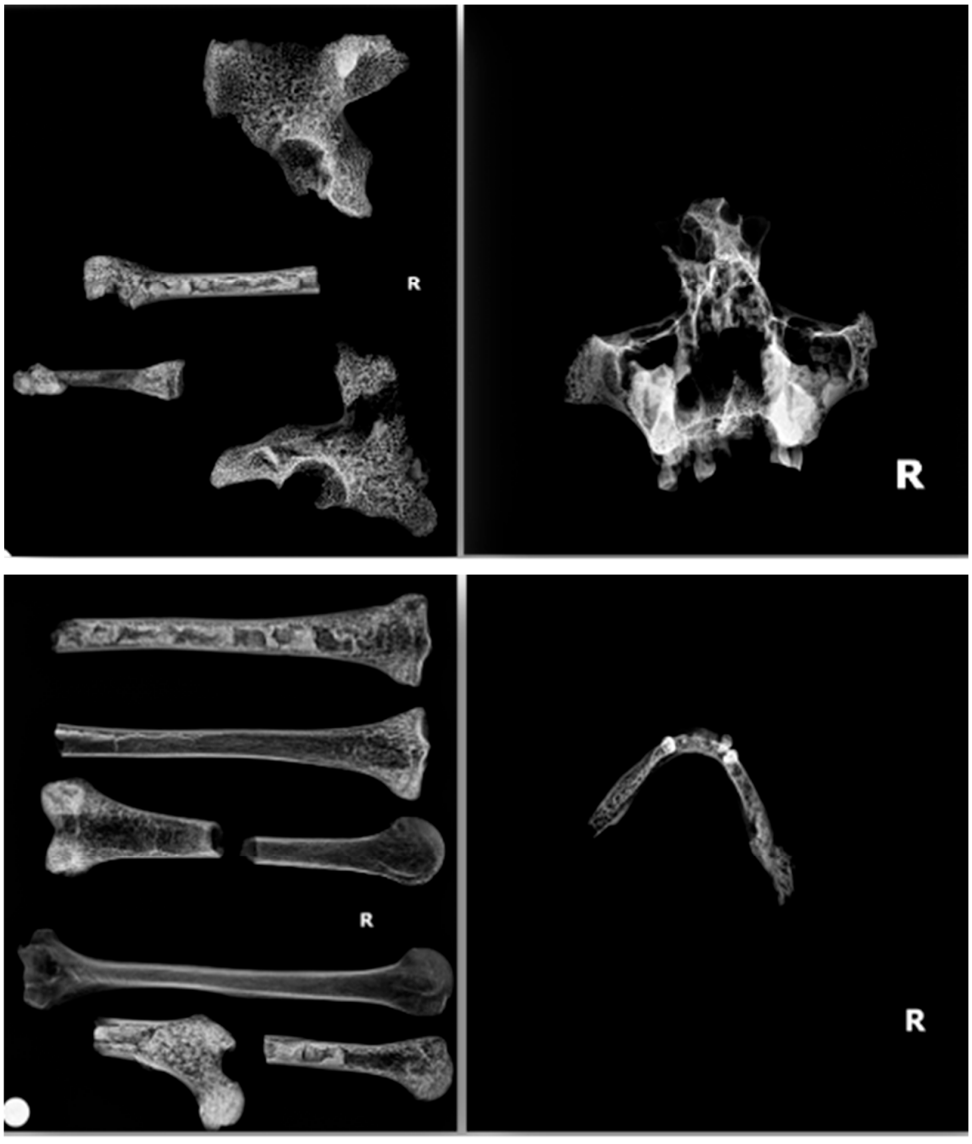

Figure 6. Radiographic images of the main skeletal segments attributed to the adult individuals (included in group A), including Saint Hipolystus.

The radiographic findings confirm the anthropological age estimations and do not reveal evidence of blunt force trauma or defensive injuries. However, the absence of key anatomical regions in the adult individual (such as the cervical spine and thoracic cage) prevents a full assessment of potential injuries described in hagiographic sources. Thus, the lack of visible trauma on the available remains does not contradict historical accounts but rather reflects the preservation limitations of the skeletal material examined.

3.4. Dating of Bone Fragments by ^{14}C Analysis

Bone samples from three individuals, two from the adult male (from tibia and skull) and one sample each from subadult "1" and subadult "2", were selected for radiocarbon (^{14}C) analysis to verify the chronological compatibility between the biological remains and the hagiographic timeline. The samples were analyzed by the CIRCE Laboratory—Center for Isotopic Research on Cultural and Environmental heritage, University of Campania Luigi Vanvitelli, where they underwent Accelerator Mass Spectrometry (AMS), currently considered the gold standard in high-precision radiocarbon dating of archeological and forensic samples.

Prior to analysis, each bone fragment was subjected to rigorous pre-treatment procedures to eliminate potential contamination and to isolate the collagen fraction necessary for dating. The $^{14}C/^{12}C$ isotopic ratios were measured directly, and the results were subsequently calibrated using the OxCal software (v4.4), referencing the latest internationally accepted calibration curves (IntCal20).

The calibrated 2σ age ranges (with 95.4% probability) obtained were as follows:

- Adult individual from group A (from tibia of the presumed Saint Hipolystus): 1308–1047 B.C.;
- Adult individual from group A (from skull of the presumed Saint Hipolystus): n.d.;
- Subadult 1 from group B (presumed Crescentius): 275–345 A.D. (Figure 7);
- Subadult 2 from group C (presumed Irenaeus): n.d.

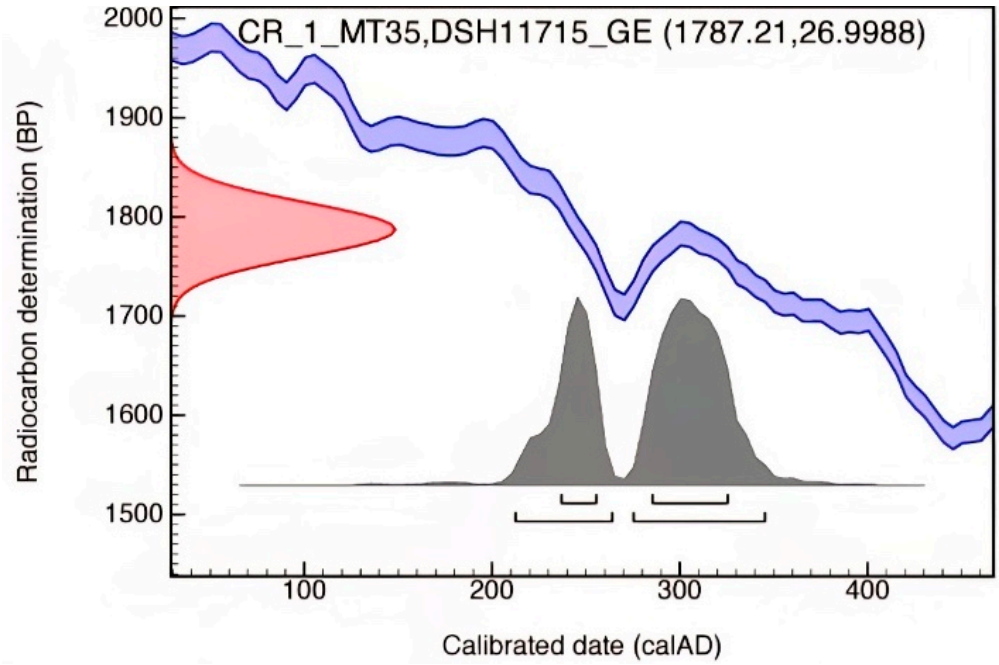

Figure 7. Calibrated radiocarbon dating result of the presumed Crescentius sample obtained via AMS. The calibrated 2σ (95.4%) probability range is 275–345 A.D. (63%) and 212–264 A.D. (37%). The main probability peak (63%) is chronologically compatible with the traditional date of martyrdom (303 A.D.) of Saint Hipolystus and the child martyrs Crescentius and Irenaeus.

Unfortunately, some of the samples returned no result due too poor collagen preservation, in particular the fragment from the skull in the ancient envelope.

The dating of the sample taken from the tibia of the elder individual yielded a result of 1000 B.C. This anomalously early radiocarbon age must be interpreted with extreme caution. The very low collagen yield required microsample pre-treatment, a condition known to increase susceptibility to contamination and diagenetic alteration. Consequently, this measurement is considered chronologically unreliable and is not informative for historical or interpretative purposes.

By contrast, the radiocarbon results of the subadult individual (presumed Crescentius) are compatible with the historical date of martyrdom traditionally associated with these saints—namely, 1 May 303 A.D., during the Diocletian persecution.

Overall, the radiocarbon results do not indicate the presence of later intrusive material or post-antique replacement. Within the limitations imposed by collagen preservation and sample availability, the ^{14}C analysis provides independent chronological support for the plausibility of continuity between the preserved relics and the individuals venerated within the local cult.

These findings also highlight both the potential and the methodological limitations of radiocarbon dating in canonical contexts, emphasizing the importance of collagen preservation, cautious interpretation, and integration with other lines of evidence in the scientific study of sacred remains.

4. Discussion

The aim of this study was to reconstruct the anthropological, chronological, and pathological profile of the skeletal remains attributed to Saint Hipolystus and the child martyrs Crescentius and Irenaeus through a coordinated and multidisciplinary approach. The procedures followed a gradual and systematic methodology, based on available scientific evidence, which included canonical reconnaissance, morphological inspection, anthropological analysis, radiological imaging, and radiocarbon dating [41–50].

The results made it possible to identify at least three distinct biological and anthropological profiles: an adult, senile male individual and two subadults, consistent with the ages traditionally attributed to Saint Hipolystus, Irenaeus, and Crescentius. The morphological and metric-structural analyses provided data that are coherent with what is handed down in hagiographic sources, albeit within the limits imposed by the preservation state and commingled nature of the remains [51].

In particular, the adult individual (from group A) showed marked signs of osteoarthritic degeneration, typical of advanced age, supporting a probabilistic compatibility with an age over 60 years (±10 years). The subadult individuals (from groups B and C) returned estimated age-at-death ranges of 4–6 years (±2 years) and 14–16 years (±3 years), respectively. The age of the older of the two is slightly higher than that reported in the historical sources; this discrepancy may reflect either biological variability and methodological uncertainty in a fragmented context or inaccuracies in the sources themselves. By contrast, the younger individual falls within an age range compatible with the traditional account of the child martyrs. The identification of two right cuboids and the absence of overlap among key skeletal elements further support the presence of at least two biologically distinct subadult individuals [52].

Age-at-death estimation was derived from the integration of multiple skeletal indicators (including degenerative changes in the adult individual and developmental markers in the subadults) and was therefore intentionally reported as a probabilistic range rather than as a single-point value. This choice reflects the well-recognized methodological uncertainty of skeletal age estimation—particularly in older adults, where age indicators tend to plateau

and inter-individual variability increases, and in assemblages affected by fragmentation and commingling, where the number and quality of observable markers are inevitably reduced [53,54].

Radiological investigations confirmed the anthropological age estimates and did not reveal any macroscopic traumatic lesions on the preserved elements. However, the absence of certain key anatomical regions (i.e., the cervical spine and thoracic cage) precludes definitive assessment of lesions potentially consistent with the forms of martyrdom described in historical sources (e.g., decapitation and piercing). The observed bone alterations were interpreted as taphonomic and postmortem in origin. Therefore, the absence of macroscopic trauma should not be interpreted as evidence contradicting the hagiographic narrative, but rather as a reflection of the preservation limitations and anatomical incompleteness of the analyzed remains [55].

One relevant aspect of the study concerns the results of the radiocarbon dating analyses. The calibrated 2σ ranges obtained for one of the subadult individuals (presumed Crescentius) fall between the 2nd and 4th centuries AD, with overlapping margins corresponding to the Diocletian persecution and the traditionally accepted date of martyrdom (1 May 303 A.D.). These data provide independent support for the chronological plausibility of the traditional attribution of at least part of the examined remains [56]. Unfortunately, some of the remains were very poor in collagen and returned no result. The radiocarbon dation of the elder individual resulted in 1300–1000 B.C.; due to the very low collagen yield and the need for microsample pre-treatment, this measurement is considered chronologically unreliable and is not informative for historical interpretation. The low collagen yield, significant organic deterioration, and taphonomic alterations linked to the preservation history of the remains are well documented in the scientific literature for their potential to significantly distort radiocarbon results.

It is important to note that all activities were conducted in accordance with Articles 15–17 of the Instruction of the Congregation for the Causes of Saints, Relics in the Church: Authenticity and Preservation. The process led to the establishment of a curated collection of bone remains, currently preserved in a glass case inside the *Specus Martyrum* under the custody of the Ecclesiastical Authority (Figure 8). All operations were documented through notarial acts and were followed by a critical reassessment of the analyses conducted.

Radiocarbon dating, first introduced by Libby in the 1950s, allows the estimation of the age of organic materials (e.g., bone, textile, wood) by measuring residual ^{14}C content. The initial result, expressed as conventional radiocarbon age (CRA), is later calibrated through standard reference curves to obtain a calendar age in B.C./A.D. [57]. However, in the presence of collagen degradation and taphonomic interference—as observed in the present case—significant deviations can occur, requiring careful critical evaluation [58]. Collagen preservation and ^{14}C pre-treatment protocols are known to strongly influence the reliability and comparability of radiocarbon dates in bone, highlighting the need for cautious interpretation in poorly preserved contexts [59,60].

From a methodological standpoint, this study has demonstrated the effectiveness of an integrated approach that combines investigative techniques from forensic medicine, skeletal anthropology, forensic radiology, and archeometry. This interdisciplinary framework proved particularly suitable for the analysis of human remains that had undergone multiple relocations, biological degradation, and environmental deterioration. Moreover, the sacred context in which this investigation was conducted required the incorporation of canonical and documentary elements into the overall analytical process [61].

The findings of this study are consistent with recent interdisciplinary research in forensic and archeological science that highlights the value of integrating scientific methodologies with historical and devotional frameworks in the analysis of ancient human remains.

In particular, radiocarbon dating has proven to be a decisive tool in the verification of relics of presumed religious significance, as demonstrated in the study of the relics of Cardinal Jacques de Vitry, where anthropological, isotopic, and genetic data converged to support historical attribution [62]. Similarly, the scientific investigation of the skull relic from Turku Cathedral revealed how material analysis can enrich the interpretation of medieval devotional practices and the relics associated with them [63]. This study therefore proposes an operational model that merges methodological rigor with cultural sensitivity—an approach increasingly endorsed in both secular and ecclesiastical forensic contexts.



Figure 8. Overview of the skeletal remains attributed to Saint Hipolystus, Irenaeus and Crescentius, arranged for public veneration within the *Specus Martyrum*. The central panel displays the segment of the elder individual; lateral panel shows subadult individuals. The bones are displayed on red fabric, following canonical guidelines for the exposition of sacred relics.

Despite the compatibility of some results with historical and hagiographic sources, several objective limitations remain. The fragmentation of the skeletal remains restricted the ability to identify trauma that might be consistent with martyrdom. An alternative explanation—namely that the analyzed subadult remains may belong to individuals unrelated to the traditionally venerated martyrs—cannot be excluded.

Additionally, radiocarbon dating was performed on a limited number of samples, reducing the chronological interpretability. The anomalous date obtained for the adult sample further illustrates the constraints of radiocarbon analysis in contexts characterized by severe collagen degradation, taphonomic alteration, and complex preservation histories. Furthermore, advanced molecular techniques such as ancient DNA analysis have not yet been applied, though they may be useful for determining biological sex or exploring potential kinship links [64].

Considering these points, we suggest expanding the investigation to the entire osteological collection preserved in the *Specus Martyrum*. This would ideally include the execution of multiple radiocarbon samples, comparative analysis across different urns, the implementation of molecular methodologies (e.g., DNA extraction and sequencing), and the systematic integration of archival and liturgical sources [65–69].

In conclusion, the data gathered support an overall anthropological and chronological compatibility between the analyzed remains and the historical profiles traditionally attributed to Crescentius and, more cautiously, to Saints Hipolystus and Irenaeus. These

findings reinforce the scientific plausibility of the traditional attribution, defining plausibly reliable parameters that align with historical and ecclesiastical tradition, and offering a replicable methodological model for future canonical investigations.

Beyond the verification of authenticity, this work also carries a deeper significance: it aims to reconstruct a lost identity and restore dignity to the physical memory of the martyrs, in a gesture that interweaves faith, science, and historical responsibility.

5. Conclusions

The preliminary morphological and anthropological analysis of the adult individual revealed no clear incompatibilities with the historical figure of Saint Hipolystus. Although definitive identification remains unattainable, the biological profile obtained aligns closely with the attributes traditionally ascribed to him, making his identification plausible. Likewise, the remains of the two subadults have been attributed to individuals estimated to be approximately 4–6 ($\pm$2) years and 14–16 ($\pm$3) years old, respectively. Considering both the fragmentary condition of the remains and the potential inconsistencies or interpretative limits of the historical sources, the attribution of these remains to Saints Irenaeus and Crescentius can be regarded as plausible and not contradictory to the available evidence. From a strictly scientific standpoint, the present analyses can establish only compatibility or plausibility and cannot confirm the specific identity of the relics, which remains grounded in historical and devotional tradition.

Overall, the work undertaken has enabled a more rational and scientifically grounded definition of the skeletal elements selected for public veneration among those officially recognized by the Ecclesiastical Authority as belonging to Saint Hipolystus and the child martyrs. At the same time, this research opens the door to more in-depth interdisciplinary studies on what can be considered both a human and spiritual legacy preserved within the *Specus Martyrum*. The presence of ancient bone remains has been confirmed; however, their chronological definition would benefit from further analytical precision and independent replication.

In conclusion, the present findings suggest a plausible attribution of the remains and that future analytical investigations may further substantiate and refine these results.

The recognition of the relics attributed to the Martyred Saints of *Abellinum* has highlighted the multifaceted complexity involved in the scientific study of ancient human remains. In particular, it has underscored the challenges posed by bone segments that have undergone repeated relocations, periodic canonical recognitions, and long-term preservation in environments affected by fluctuating conditions and natural events. Within this framework, the multidisciplinary approach applied—combining medico-legal, anthropological, odontological, and bioarcheological expertise—proves to be an indispensable scientific and technical resource. It offers a valuable contribution to canonical investigations, helping to define robust, shared methodological, operational, and interpretative criteria.

Author Contributions: Conceptualization, A.S., F.C., C.S. and C.M.; methodology, A.S.; investigation, C.M., F.M. (Francesca Motta), E.d.L., C.E., S.B., F.L.S., F.M. (Fabio Marzaioli), D.V., C.S. and A.S.; data curation, C.M., F.L.S., C.S., F.C. and A.S.; writing—original draft preparation, F.C.; writing—review and editing, C.M., F.M. (Francesca Motta), R.C., N.P., F.L.S., C.S. and A.S.; supervision, A.S. All authors have read and agreed to the published version of the manuscript.

Funding: This research received no external funding.

Data Availability Statement: The data presented in this study are available on request from the corresponding author.

Acknowledgments: The authors extend their acknowledgments to the ecclesiastical authorities, in particular to Mons. Arturo Aiello, Bishop of Avellino, to Don Luca Monti, Parish Priest of Saint Hipolystus Church in Atripalda, and to the community of Atripalda (Avellino, Italy).

Conflicts of Interest: The authors declare no conflicts of interest.

References

1. Fulcheri, E. Canonic recognitions and scientific investigations on the Mummies of Saints. *Med. Nei Secoli* **2013**, *25*, 139–165.
2. Piombino-Mascali, D. Incorruptibles. In *Mummies Around the World: An Encyclopedia of Mummies in History, Religion, and Popular Culture*; Cardin, M., Ed.; Bloomsbury Publishing: New York, NY, USA, 2015; pp. 179–182.
3. Dedouit, F.; Guglielmi, G.; Perilli, G.; Nasuto, M.; Telmon, N.; Fineschi, V.; Pomara, C. Virtual anthropological study of the skeletal remains of San Fortunato (Italy, third century AD) with multislice computed tomography. *J. Forensic Radiol. Imaging* **2014**, *2*, 9–16. [CrossRef]
4. Alterauge, A.; Becker, T.; Berndt, B.; Jackowski, C.; Lösch, S. Testing "saintly" authenticity: Investigations on two catacomb saints. *RadioGraphics* **2016**, *36*, 573–579. [CrossRef]
5. Biehler-Gomez, L.; Porta, D.; Mattia, M.; De Angelis, D.; Poppa, P.; Cattaneo, C. 'Ye must have faith'-how anthropology can contribute to religious heritage: The osteobiography of Italian martyr Saint Nazarius. *Int. J. Osteoarchaeol.* **2021**, *31*, 506–512. [CrossRef]
6. Piombino-Mascali, D.; Zink, A.; Maixner, F. The Blessed Antonio (Patrizi) from Monticiano, Sienna (Italy): Bioanthropological and palaeohistological considerations. *Acta Medica Litu.* **2022**, *29*, 159–166. [CrossRef] [PubMed]
7. Minozzi, S.; Gatti, G.; Ricci, S.; Giuffra, V.; Lunardini, A. Bioarchaeological study of the skeletal remains attributed to Saint Ceccardo from Luni, patron of Carrara (Tuscany). *J. Bioarchaeological Res.* **2023**, *1*, e2023012.
8. Charlier, P.; Poupon, J.; Eb, A.; De Mazancourt, P.; Gilbert, T.; Huynh-Charlier, I.; Loublier, Y.; Verhille, A.M.; Moulheirat, C.; Patou-Mathis, M.; et al. The 'relics of Joan of arc': A forensic multidisciplinary analysis. *Forensic Sci. Int.* **2010**, *194*, e9–e15. [CrossRef]
9. Kristóf, L.A.; Kovács, M.; Baksa, G.; Bereczki, Z.; Szatmári, F.; Patonay, L.; Pálfi, G.; Pohárnok, L. Condition assessment of two early Christian martyrs', St. Christine's and St. Augustine's relics with paleoradiological methods in Hungary. *J. Cult. Herit.* **2015**, *16*, 249–253. [CrossRef]
10. Mihanović, F.; Jerković, I.; Kružić, I.; Anđelinović, Š.; Janković, S.; Bašić, Ž. From biography to osteobiography: An example of anthropological historical identification of the remains of St. Paul. *Anat. Rec.* **2017**, *300*, 1535–1546. [CrossRef]
11. Nilsson, M.; Possnert, G.; Edlund, H.; Budowle, B.; Kjellström, A.; Allen, M. Analysis of the putative remains of a European patron saint—St Birgitta. *PLoS ONE* **2010**, *5*, e8986. [CrossRef]
12. Tagliaferri, M. The cult of relics. In *The Causes of the Saints*; Libreria Editrice Vaticana: Rome, Italy, 2018.
13. Congregation for the Causes of Saints. Sanctorum Mater: Instruction for Conducting Diocesan or Eparchial Inquiries in the Causes of Saints. Vatican City. 2007. Available online: https://www.vatican.va/roman_curia/congregations/csaints/documents/rc_con_csaints_doc_20070517_sanctorum-mater_en.html (accessed on 25 December 2025).
14. Schmeling, A.; Geserick, G.; Reisinger, W.; Olze, A. Age estimation. *Forensic Sci. Int.* **2007**, *165*, 178–181. [CrossRef]
15. Schmeling, A.; Grundmann, C.; Fuhrmann, A.; Kaatsch, H.J.; Knell, B.; Ramsthaler, F.; Reisinger, W.; Riepert, T.; Ritz-Timme, S.; Rösing, F.W.; et al. Criteria for age estimation in living individuals. *Int. J. Leg. Med.* **2008**, *122*, 457–460. [CrossRef]
16. Ubelaker, D.H. Estimating age at death from immature human skeletons: An overview. *J. Forensic Sci.* **1987**, *32*, 1254–1263. [CrossRef] [PubMed]
17. Cattaneo, C. Forensic anthropology: Developments of a classical discipline in the new millennium. *Forensic Sci. Int.* **2007**, *165*, 185–193. [CrossRef] [PubMed]
18. Buikstra, J.E.; Ubelaker, D.H. Standards for Data Collection from Human Skeletal Remains. *Ark. Archaeol. Surv. Res. Ser.* **1994**, *44*, 44.
19. Rösing, F.W.; Graw, M.; Marré, B.; Ritz-Timme, S.; Rothschild, M.A.; Rötzscher, K.; Schmeling, A.; Schröder, I.; Geserick, G. Recommendations for the forensic diagnosis of sex and age from skeletons. *Homo* **2007**, *58*, 75–89. [CrossRef]
20. Brickley, M.; Ferllini, R. Forensic anthropology: Methodology and practice. In *Handbook of Forensic Anthropology and Archaeology*; Left Coast Press: Walnut Creek, CA, USA, 2007; pp. 25–38.
21. Walker, P.L. Sexing skulls using discriminant function analysis of visually assessed traits. *Am. J. Phys. Anthropol.* **2008**, *136*, 39–50. [CrossRef] [PubMed]
22. Adams, B.J. *Forensic Anthropology*; Infobase Publishing: New York, NY, USA, 2007.
23. Hefner, J.T. Cranial nonmetric variation and estimating ancestry. *J. Forensic Sci.* **2009**, *54*, 985–995. [CrossRef]
24. Hefner, J.T.; Ousley, S.D. Statistical classification methods for estimating ancestry using morphoscopic traits. *J. Forensic Sci.* **2014**, *59*, 883–890. [CrossRef]

25. White, T.D.; Folkens, P.A. *The Human Bone Manual*; Elsevier Academic Press: Amsterdam, The Netherlands, 2005.
26. Ubelaker, D.H.; Wu, Y. Fragment analysis in forensic anthropology. *Forensic Sci. Res.* **2020**, *5*, 260–265. [CrossRef]
27. Decker, S.J.; Braileanu, M.; Dey, C.; Lenchik, L.; Pickup, M.; Powell, J.; Tucker, M.; Probyn, L. Forensic Radiology: A Primer. *Acad. Radiol.* **2019**, *26*, 820–830. [CrossRef]
28. Dedouit, F.; Saint-Martin, P.; Mokrane, F.Z.; Savall, F.; Rousseau, H.; Crubézy, E.; Rougé, D.; Telmon, N. Virtual anthropology: Useful radiological tools for age assessment in clinical forensic medicine and thanatology. *La Radiol. Medica* **2015**, *120*, 874–886. [CrossRef]
29. Rösing, F.W.; Graw, M.; Marré, B.; Ritz-Timme, S.; Rothschild, M.A.; Rötzscher, K.; Schmeling, A.; Schröder, I.; Geserick, G. Forensic determination of sex and age of skeletons. *Anthropol. Anz.* **2005**, *63*, 221–232. [CrossRef]
30. Ubelaker, D.H. Radiocarbon analysis of human remains: A review of forensic applications. *J. Forensic Sci.* **2014**, *59*, 1466–1472. [CrossRef]
31. Libby, W.F. *Radiocarbon Dating*; University of Chicago Press: Chicago, IL, USA, 1952.
32. Johnstone-Belford, E.C.; Blau, S. A Review of Bomb Pulse Dating and its Use in the Investigation of Unidentified Human Remains. *J. Forensic Sci.* **2020**, *65*, 676–685. [CrossRef]
33. Fahrni, S.M.; Southon, J.R.; Santos, G.M.; Palstra, S.; Meijer, H.; Xu, X. Reassessment of the 13C/12C and 14C/12C isotopic fractionation ratio and its impact on high-precision radiocarbon dating. *Geochim. Et Cosmochim. Acta* **2017**, *213*, 330–345. [CrossRef]
34. Bronk, R.C. Radiocarbon dating: Revolutions in understanding. *Archaeometry* **2008**, *50*, 249–275. [CrossRef]
35. Cardoso, H.F.; Puentes, K.; Soares, A.M.; Santos, A.; Magalhães, T. The value of radiocarbon analysis in determining the forensic interest of human skeletal remains found in unusual circumstances. *J. Forensic Leg. Med.* **2012**, *19*, 97–100. [CrossRef] [PubMed]
36. Johnstone-Belford, E.; Fallon, S.J.; Dipnall, J.F.; Blau, S. The importance of bone sample selection when using radiocarbon analysis in cases of unidentified human remains. *Forensic Sci. Int.* **2022**, *341*, 111480. [CrossRef] [PubMed]
37. Terrasi, F.; De Cesare, N.; D'Onofrio, A.; Lubritto, C.; Marzaioli, F.; Passariello, I.; Rogalla, D.; Sabbarese, C.; Borriello, G.; Casa, G.; et al. High precision 14C AMS at CIRCE. *Nucl. Instrum. Methods Phys. Res. Sect. B Beam Interact. Mater. At.* **2008**, *266*, 2221–2224. [CrossRef]
38. Ortner, D.J. *Identification of Pathological Conditions in Human Skeletal Remains*, 3rd ed.; Academic Press: New York, NY, USA, 2003.
39. Waldron, T. *Palaeopathology*; Cambridge University Press: Cambridge, UK, 2009.
40. Biehler-Gomez, L.; Cattaneo, C. *Interpreting Bone Lesions and Pathology for Forensic Practice*; Elsevier Academic Press: Amsterdam, The Netherlands, 2021.
41. Leccia, C.; Alunni, V.; Quatrehomme, G. Modern (forensic) mummies: A study of twenty cases. *Forensic Sci. Int.* **2018**, *288*, 330.e1–330.e9. [CrossRef]
42. Hughes, C.; Yim, A.D.; Juarez, C.; Servello, J.; Thomas, R.; Passalacqua, N.; Soler, A. Investigating identification disparities in forensic anthropology casework. *PLoS ONE* **2023**, *18*, e0290302. [CrossRef]
43. de Boer, H.H.; Obertová, Z.; Cunha, E.; Adalian, P.; Baccino, E.; Fracasso, T.; Kranioti, E.; Lefévre, P.; Lynnerup, N.; Petaros, A.; et al. Strengthening the role of forensic anthropology in personal identification: Position statement by the Board of the Forensic Anthropology Society of Europe (FASE). *Forensic Sci. Int.* **2020**, *315*, 110456. [CrossRef] [PubMed]
44. Lewis, M.E.; Rutty, G.N. The endangered child: The personal identification of children in forensic anthropology. *Sci. Justice* **2003**, *43*, 201–209. [CrossRef] [PubMed]
45. Guleria, A.; Krishan, K.; Sharma, V.; Kanchan, T. Methods of forensic facial reconstruction and human identification: Historical background, significance, and limitations. *Naturwissenschaften* **2023**, *110*, 8. [CrossRef] [PubMed]
46. Baliso, A.; Heathfield, L.J.; Gibbon, V.E. Forensic human identification: Retrospective investigation of anthropological assessments in the Western Cape, South Africa. *Int. J. Leg. Med.* **2023**, *137*, 793–807. [CrossRef]
47. Caple, J.; Byrd, J.; Stephan, C.N. Elliptical Fourier analysis: Fundamentals, applications, and value for forensic anthropology. *Int. J. Leg. Med.* **2017**, *131*, 1675–1690. [CrossRef]
48. Milani, C.; Tomassini, L.; Gambelunghe, C.; Pini, N.; Calcagnile, L.; Quarta, G.; D'elia, M.; Scendoni, R.; Fedeli, P.; Lancia, M. Radiocarbon and bomb pulse dating in the forensic context: A systematic review. *Forensic Sci. Int.* **2025**, *367*, 112367. [CrossRef]
49. Ubelaker, D.H.; Thomas, C.; Olson, J.E. The impact of age at death on the lag time of radiocarbon values in human bone. *Forensic Sci. Int.* **2015**, *251*, 56–60. [CrossRef]
50. Teglind, R.; Dawidson, I.; Balkefors, J.; Alkass, K. Analysis of 14C, 13C and Aspartic Acid Racemization in Teeth and Bones to Facilitate Identification of Unknown Human Remains: Outcomes of Practical Casework. *Biomolecules* **2021**, *11*, 1655. [CrossRef]
51. Wang, X.; Liu, G.; Wu, Q.; Zheng, Y.; Song, F.; Li, Y. Sex estimation techniques based on skulls in forensic anthropology: A scoping review. *PLoS ONE* **2024**, *19*, e0311762. [CrossRef]
52. Marconi, V.; Iommi, M.; Monachesi, C.; Faragalli, A.; Skrami, E.; Gesuita, R.; Ferrante, L.; Carle, F. Validity of age estimation methods and reproducibility of bone/dental maturity indices for chronological age estimation: A systematic review and meta-analysis of validation studies. *Sci. Rep.* **2022**, *12*, 15607. [CrossRef]

53. Ubelaker, D.H.; Khosrowshahi, H. Estimation of age in forensic anthropology: Historical perspective and recent methodological advances. *Forensic Sci. Res.* **2019**, *4*, 1–9. [CrossRef] [PubMed]
54. Rojas-Torres, J.; Martínez-Durán, L.; de Anta, J.M.; Bucchi, C.; Fonseca, G.M.; Salazar, L.A. Accuracy and challenges in age estimation in adults: A scoping review of anthropological, dental, biochemical, and molecular methods. *Forensic Sci. Med. Pathol.* **2025**, *21*, 1899–1927. [CrossRef] [PubMed]
55. Dirkmaat, D.C.; Cabo, L.L.; Ousley, S.D.; Symes, S.A. New perspectives in forensic anthropology. *Am. J. Phys. Anthropol.* **2008**, *137*, 33–52. [CrossRef]
56. Taylor, R.E.; Bar-Yosef, O. *Radiocarbon Dating: An Archaeological Perspective*, 2nd ed.; Routledge: New York, NY, USA, 2014.
57. Bertrand, B.; Clauzel, T.; Richardin, P.; Bécart, A.; Morbidelli, P.; Hédouin, V.; Marques, C. Application and implications of radiocarbon dating in forensic case work: When medico-legal significance meets archaeological relevance. *Forensic Sci. Res.* **2024**, *9*, owae046. [CrossRef]
58. Miles, K.L.; Finaughty, D.A.; Gibbon, V.E. A review of experimental design in forensic taphonomy: Moving towards forensic realism. *Forensic Sci. Res.* **2020**, *5*, 249–259. [CrossRef]
59. Becerra-Valdivia, L.; Leal-Cervantes, R.; Wood, R.; Higham, T. Challenges in sample processing within radiocarbon dating and their impact in 14C-dates-as-data studies. *J. Archaeol. Sci.* **2020**, *113*, 105043. [CrossRef]
60. Herrando-Pérez, S. Bone need not remain an elephant in the room for radiocarbon dating. *R. Soc. Open Sci.* **2021**, *8*, 201351. [CrossRef]
61. Pilli, E.; Palamenghi, A.; Cattaneo, C. Forensic skeletal and molecular anthropology face to face: Combining expertise for identification of human remains. *Ann. N. Y. Acad. Sci.* **2025**, *1550*, 77–107. [CrossRef]
62. Decorte, R.; Polet, C.; Boudin, M.; Tilquin, F.; Matroule, J.Y.; Dieu, M.; Charles, C.; Carlier, A.; Lebecque, F.; Deparis, O. An interdisciplinary study around the reliquary of the late Cardinal Jacques de Vitry. *PLoS ONE* **2019**, *14*, e0201424. [CrossRef] [PubMed]
63. Arponen, A.; Maijanen, H.; Immonen, V. From Bones to Sacred Artefact: The Late Medieval Skull Relic of Turku Cathedral, Finland. *Temenos-Nord. J. Study Relig.* **2018**, *54*, 149–183. [CrossRef]
64. Blau, S.; Rowbotham, S.K. Not so simple: Understanding the complexities of establishing identity for cases of unidentified human remains in an Australian medico-legal system. *Forensic Sci. Int.* **2022**, *330*, 111107. [CrossRef]
65. Blau, S.; Johnstone-Belford, E.; Rowbotham, S.K. Radiocarbon dating as tool to assist in triaging cases of unidentified human remains in Victoria, Australia: A case series. *J. Forensic Sci.* **2023**, *68*, 1372–1378. [CrossRef]
66. Cartocci, G.; Santurro, A.; Neri, M.; Zaccagna, F.; Catalano, C.; La Russa, R.; Turillazzi, E.; Panebianco, V.; Frati, P.; Fineschi, V. Post-mortem computed tomography (PMCT) radiological findings and assessment in advanced decomposed bodies. *La Radiol. Medica* **2019**, *124*, 1018–1027. [CrossRef] [PubMed]
67. Maiese, A.; Scopetti, M.; Santurro, A.; La Russa, R.; Manetti, F.; D'Errico, S.; De Matteis, A.; Cingolani, M.; Neri, M.; Pinchi, E.; et al. Corpse dismemberment: A case series. Solving the puzzle through an integrated multidisciplinary approach. *J. Forensic Leg. Med.* **2020**, *74*, 102005. [CrossRef]
68. Santurro, A.; Vullo, A.M.; Borro, M.; Gentile, G.; La Russa, R.; Simmaco, M.; Frati, P.; Fineschi, V. Personalized Medicine Applied to Forensic Sciences: New Advances and Perspectives for a Tailored Forensic Approach. *Curr. Pharm. Biotechnol.* **2017**, *18*, 263–273. [CrossRef]
69. Marcante, B.; Marino, L.; Cattaneo, N.E.; Delicati, A.; Tozzo, P.; Caenazzo, L. Advancing Forensic Human Chronological Age Estimation: Biochemical, Genetic, and Epigenetic Approaches from the Last 15 Years: A Systematic Review. *Int. J. Mol. Sci.* **2025**, *26*, 3158. [CrossRef]

Disclaimer/Publisher's Note: The statements, opinions and data contained in all publications are solely those of the individual author(s) and contributor(s) and not of MDPI and/or the editor(s). MDPI and/or the editor(s) disclaim responsibility for any injury to people or property resulting from any ideas, methods, instructions or products referred to in the content.