

Case Report

# An Amputated Tongue—The Consequences of a Human Bite

Constance Hardwick <sup>1</sup>, Alice Cameron <sup>1</sup>  and James Puryer <sup>2,\*</sup> 

<sup>1</sup> Royal United Hospital, Combe Park, Bath BA1 3NG, UK; constance.hardwick@nhs.net (C.H.); a.cameron6@nhs.net (A.C.)

<sup>2</sup> Bristol Dental School, Lower Maudlin Street, Bristol BS1 2LY, UK

\* Correspondence: james.puryer@bristol.ac.uk; Tel.: +44-0117-342-4425

Received: 3 June 2020; Accepted: 19 June 2020; Published: 28 June 2020



**Abstract:** Drug-related hospital admissions are common, and up to 25% of patients presenting to emergency departments with injuries test positive for alcohol and drug use. This case reports on a 55-year-old male who attended the emergency department (ED) at the Royal United Hospital, Bath, UK. He presented after sustaining significant soft tissue trauma to his tongue, following recreational drug use of an unknown substance. His injuries included the amputation and loss of the anterior third of his tongue, having suffered a bite from another individual. This unusual case describes the patient's injuries and subsequent management, both in the emergency department and during follow-up. This case will be of benefit to clinicians from many disciplines including dentists, oral and maxillofacial surgeons, ENT surgeons and speech and language therapists.

**Keywords:** trauma; tongue; drug

## 1. Introduction

Nine percent of adults in England reported having taken illicit drugs in 2018 [1], although the prevalence of drug use has fallen since 2011, according to the Crime Survey [2]. Drug use in 2019 was proportioned at 12% cannabis use, 4.7% cocaine, 1% amphetamines and 3.3% MDMA. Opioids remain the greatest cause of health and social harm resulting from illicit drug use, with 371 reported deaths in 2017 being related to cocaine and 63 related to ecstasy [1]. Drug-related hospital attendances resulted in 7358 hospital admissions and alcohol related admissions were 37,000 in 2018 across England; 2503 drug-related deaths were recorded [1].

Up to 25% of patients presenting to emergency departments with injuries tested positive for alcohol and drug use [3]. There is a documented link between alcohol and drug use and subsequent facial injury, such as mandible fractures [4]. Interpersonal violence is the main causative factor in 79% of alcohol and drug-related oral and maxillofacial trauma [5]. The majority of studies regarding facial and oral injuries occur with males [4].

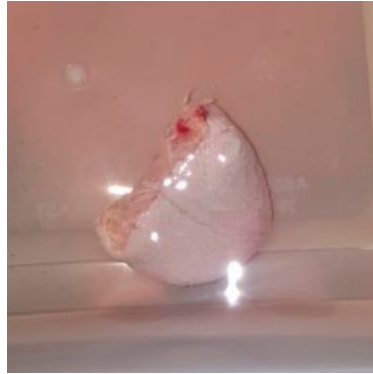The face and mouth are common targets for assault and are markers for interpersonal violence due to the face and mouth defining a person's identity and image [6,7].

This case describes the injuries and subsequent management of soft tissue trauma to the tongue of a 55-year-old male who attended a hospital emergency department (ED) following a bite from a female individual. The authors are not aware of previous reports of this amount of tongue being removed by trauma or the mechanism of injury. The case highlights the role of illicit drug use in the aetiology of trauma and the impact that it can have on quality of life. This case will be of benefit to clinicians from many disciplines including dentists, oral and maxillofacial surgeons, Ear, Nose & Throat (ENT) surgeons and speech and language therapists.

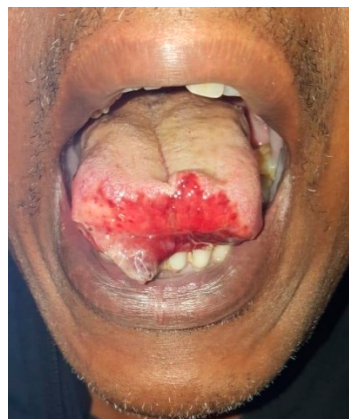## 2. Case Report

Patient informed consent was obtained.

A 55-year-old male attended the ED at the Royal United Hospital, Bath, UK after sustaining trauma to his tongue. His presenting complaint was that a person known to him was alleged to have bitten off a large piece of his tongue. This significantly sized, amputated portion of tongue was brought to the ED with him in a plastic container containing tap water (Figures 1 and 2).



**Figure 1.** The amputated anterior third of tongue was brought to the emergency department (ED) in a plastic box containing tap water.



**Figure 2.** The patient following presentation to the ED after an alleged human bite to the tongue.

A primary survey revealed that he did not present an airway risk, he was able to talk in full-sentences and there was no major haemorrhage present; his national early warning score was 0. Therefore, a thorough history of the presenting complaint and medical and social histories were taken. These revealed that the injury had occurred 14 hours prior to ED attendance and subsequent to the voluntary ingestion of a “third of a pink pill” outside of a night club, in the early hours of the morning.

The patient did not know the type of tablet he had taken but reports being aware that this was a form of recreational drug. Later that morning, a female person who was known to him had bitten off a sizeable portion of his anterior tongue, but he reported delayed ED attendance due to the lack of bleeding and significant pain. His main concern was with regards to difficulty with speech and he reported a lisp.

The patient was medically fit and well, with no regular prescribed medications and no known drug allergies. The social history showed approximately eight units of alcohol intake per week and five cigarettes per day. Recreational drug use occurred on rare occasions at social settings, such as music festivals or night clubs. The patient stated that he was never aware of the exact type of drugs that he was taking as they were provided to him by friends.

An extra-oral examination was broadly unremarkable. There were no facial lacerations present and no extra-oral swellings. Intra-oral examination revealed a dentate patient with poor oral hygiene and general calculus deposits. The anterior third of the tongue had been entirely removed from the remaining tongue. The amputation appeared to be concave in nature, the margins were ragged and haemostasis was observed. The remaining tongue did appear swollen, but the floor of the mouth was soft and non-raised; he was able to swallow. There were no other intra-oral signs of trauma, either to the teeth or to the other soft tissues.

### 2.1. Diagnoses

1. Amputated anterior third of tongue
2. Speech impediment

### 2.2. Treatment

The on-call dental core trainee discussed the case management with the off-site on-call oral and maxillo-facial speciality registrar, who also discussed it with the third on-call consultant. A decision was made that the anterior third of the tongue was non-viable for re-suturing as it had been without blood supply for over 14 h. A plan was agreed to admit the patient for the administration of 3.3 mg of IV dexamethasone and observations overnight to ensure the airway was neither comprised nor at risk due to oedema or haemorrhage.

Serum bloods were taken for hepatitis B and human immunodeficiency virus with the patient's consent. Unfortunately, the patient was unaware of the whereabouts of the assailant so comparison blood samples were not possible.

Unfortunately, the patient absconded from the ED and so the above plan was not actioned. An outpatient appointment was made for a review and an urgent referral to speech and language therapy for speech rehabilitation was also arranged.

The patient did attend the review appointment one week later, where it was noted that speech was becoming difficult with a noted lisp. The patient was systemically well; however, there was evidence of fetor oris and oral hygiene was extremely poor, with evidence of degrading clot, slough, food debris and plaque (Figure 3). Mouth care instructions were given, a prescription of 0.2% chlorhexidine gluconate mouthwash to be used and the speech and language therapy referral confirmed.

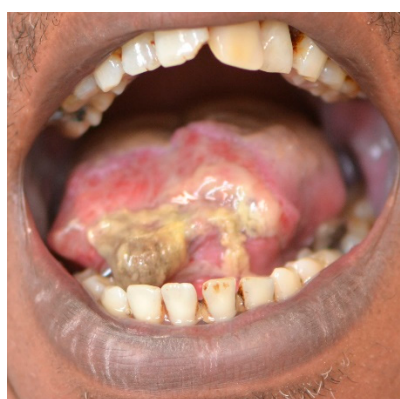


Figure 3. The injury site one week post-trauma.

## 3. Discussion

Human bite wounds present a challenge to an ED due to the complexity of the aetiology and possible life-limiting sequelae. From a review of the existing literature, we found that there is no evidence currently of a case where there has been either this amount of a tongue removed from biting or by this mechanism by another person. This may demonstrate the uniqueness of drug-related

oral trauma and the potential difficulties this poses to oral and maxillo-facial teams. A retrospective study discussing human bite injuries in 2007 showed that a majority (92%) of patients were male, 86% involved alcohol and 12% involved recreational drug use [8]. The ear was the most common facial feature to be involved in a human bite and no reported cases in the study involved the tongue.

If this case had presented with active bleeding, this would have needed acute management to achieve prompt haemostasis with tranexamic soaked gauze and firm pressure, followed by the suture ligation of vessels or diathermy. A low threshold for anaesthetic team input would have been required with regards to the loss of airway from tongue swelling and bleeding.

Fortunately, for this patient, emergency airway management was not required. However, life limiting consequences have occurred from the extent of the injuries with regard to his speech and aesthetics. The tongue is the most important articulator for vowel sound production. A previous study observing speech ineligibility before and after speech therapy found that severe speech intelligibility was noted in all patients who had a planned tongue resection involving more than a third of the tongue, and there was a statistically significant improvement in speech after six months of speech therapy [9].

A previous study described normal speech after eight months of speech and language therapy in patients who had a glossectomy involving more than two-thirds of the tongue [10].

Due to the history of recreational drug use, it was feasible that the trauma was self-induced. However, the size of the amputated portion of tongue and the concave nature of the amputation would support the patient's report that the trauma was caused by another human individual. The patient gave no history of epilepsy. The patient claimed to know his female assailant, having met her through online apps. However, she had given him a false name and was not able to be traced. We speculate that the degree and severity of the trauma would only have been tolerated due to the patient's (and possibly the assailant's) alcohol and drug intake at the time of the assault. No toxicological investigations were undertaken at the time of presentation. These may have supported the patient's history and provided further information as to the type of illicit drug that the patient had taken.

#### 4. Conclusions

This case highlights the extreme soft tissue damage that can occur post-illicit drug use with life-changing consequences not only to function and communication but also to facial aesthetics, which will have a psychological impact on the patient. With the ever-changing demographics and profile of drug use today, it is important that clinicians are aware of the possible presenting complaints and the risks that they pose so that appropriate management can be instigated.

**Author Contributions:** C.H. and A.C. wrote the initial draft manuscript. J.P. reviewed and edited the manuscript and revised the manuscript for resubmission. All authors have approved the final manuscript.

**Funding:** This research received no external funding.

**Conflicts of Interest:** The authors declare no conflict of interest.

#### References

1. Cresswell, M. Rise in the use of section 136 of the Mental Health Act 1983 in England and Wales: A viewpoint on Loughran (2018). *Med. Sci. Law* **2019**, *60*, 140–146. [[CrossRef](#)] [[PubMed](#)]
2. European Monitoring Centre for Drugs and Drug Addiction. *United Kingdom Country Drug Report*; European Monitoring Centre for Drugs and Drug Addiction: Lisbon, Portugal, 2019.
3. Sobderstrom, C.A.; Dischinger, P.C.; Kerns, T.J.; Kufera, J.A.; Mitchell, K.A.; Scalea, T.M. Epidemic increases in cocaine and opiate use by trauma centre patients: Documentalisation with a large clinical toxicology database. *J. Trauma*. **2001**, *51*, 557–564.
4. Murphy, D.A. Substance use and facial injury. *Oral Maxillofac. Surg. Clin.* **2010**, *22*, 231–238. [[CrossRef](#)] [[PubMed](#)]
5. Ogundare, B.O.; Bonnick, A.; Bayley, N. Pattern of mandibular fractures in an urban major trauma centre. *J. Oral Maxillofac. Surg.* **2003**, *61*, 713–718. [[CrossRef](#)] [[PubMed](#)]

6. Telfer, M.R.; Jones, G.M.; Shepherd, J.P. Trends in the aetiology of maxillofacial fractures in the United Kingdom (1977–1987). *Br. J. Oral Maxillofac. Surg.* **1991**, *29*, 250–255. [[CrossRef](#)]
7. Bronheim, H.; Strain, J.J.; Biller, H.F. Psychiatric aspects of head and neck surgery: Part II: Body image and psychiatric intervention. *Gen. Hosp. Psychiatry* **1991**, *13*, 225–232. [[CrossRef](#)]
8. Henry, F.P.; Purcell, E.M.; Eadie, P.A. The human bite injury: A clinical audit and discussion regarding the management of this alcohol fuelled phenomenon. *Emerg. Med. J.* **2007**, *24*, 455–458. [[CrossRef](#)] [[PubMed](#)]
9. Furia, C.L.; Kowalski, L.P.; Latorre, M.R.; Angelis, E.C.; Martins, N.M.; Barros, A.P.; Ribeiro, K.C. Speech intelligibility after glossectomy and speech rehabilitation. *Arch. Otolaryngol. Head Neck Surg.* **2001**, *127*, 877–883. [[PubMed](#)]
10. Heller, K.S.; Levy, J.; Sciubba, J.J. Speech patterns following partial glossectomy for small tumors of the tongue. *Head Neck* **1991**, *13*, 340–343. [[CrossRef](#)] [[PubMed](#)]



© 2020 by the authors. Licensee MDPI, Basel, Switzerland. This article is an open access article distributed under the terms and conditions of the Creative Commons Attribution (CC BY) license (<http://creativecommons.org/licenses/by/4.0/>).