

## Supplement

### Neuroglia Activation in Long COVID/**Post-Acute Sequela of SARS-CoV-2 (LC/PASC)**

#### **Repurposing of Methylprednisolone, Vitamin B12 and Folic Acid (vitamin B9) in the Treatment of Long COVID and **Post-Acute Sequela of SARS-CoV-2 (LC/PASC)****

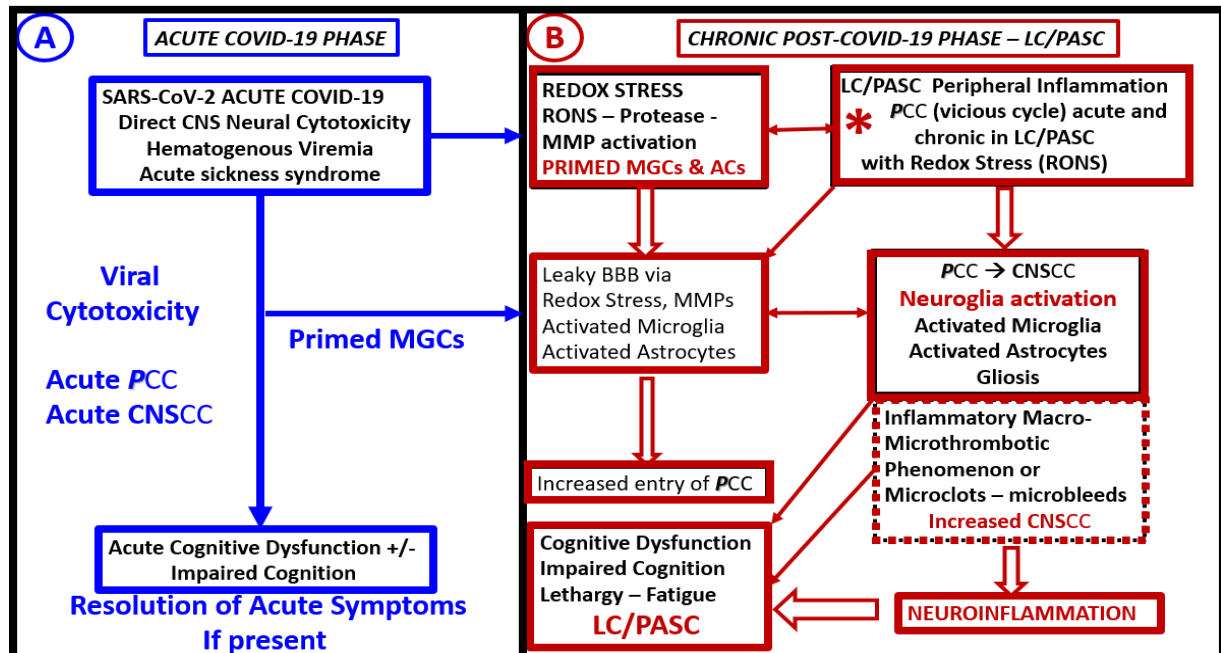
The concept for repurposing methylprednisolone, vitamin B12 and folic acid began with two personal experiences by author (M.R.H.). The first experience was my own rapid recovery with symptoms of post viral chronic fatigue syndrome similar to Long Covid/Post-acute sequela of SARS-CoV-2 (LC/PASC) syndrome upon surviving my own experience with herpes simplex type I encephalitis (HSE) in 1997. This 53-year-old physician had a three-day history of severe dull frontal headaches that was followed by disorientation and visual hallucinations. Following the release from the hospital after nine days and a full seven-day course of acyclovir he was weakened as expected following a long-term malicious illness. Unfortunately, the symptom of fatigue was disabling and the marked impaired cognition was interfering with his return to an active family medicine and critical care clinic for two weeks. This patient was desperate to return to his medical practice and decided on his own to begin therapy with 80 mg of methylprednisolone acetate intramuscularly (Depo-Medrol ®) and 2cc of injectable vitamin B12 (Cyanocobalamin Injection, USP ® 1,000 mcg/mL totaling 2,000 mcg). He also began supplementing his diet with 1 mg of folic acid (vitamin B9) daily. Within 24 hours there was a marked improvement of his sense of well-being with marked improvement of energy, appetite and importantly cognition. Three days post treatment he returned to see his neurologist and was cleared to return to his clinical medical practice without restrictions. Patient continued vitamin B12 intramuscularly weekly and folic acid (vitamin B9) for a total of 3 weeks after returning to his medical practice and suffered no further residual symptoms of his post viral syndrome.

The second experience by author (M.R.H.) involved a small isolated community outbreak of human cytomegalic virus. In 1999 author experienced a small community outbreak of human cytomegalic virus (hCMV). The first two patients were a husband and wife who developed upper respiratory infection (URI) symptoms of what they thought was “the flu” a week apart. Upon recovery from the URI the husband felt extremely run down and fatigued and when trying to do anything physical his fatigue became so pronounced that he had to discontinue whatever it was he was doing. Additionally, he was very confused during this time with loss of recent and even long-term memories such that his wife had to think and do physical things for him. One week later; however, the wife came down with nearly identical symptoms of URI and also had the persistence of severe fatigue and cognitive disabilities similar to her husband. It was these impaired cognitive issues experienced by this couple that had persisted now for three weeks that brought them to the doctor by a neighbor as neither husband or wife felt capable of safe driving. In each patient there were no physical signs of URI or cervical lymph node enlargement and their ear-nose-and throat examination as well as the rest of their physical exams were normal. Complete blood count (CBC) was basically normal with each patient showing a slight lymphocytosis suggestive of a recent viral infection and without atypical lymphocytes on their blood smear; however, they each had elevated sedimentation rates (husband 100 mm/hour and wife 88 mm/hour). They each had a negative mono-spot test as adult infectious mononucleosis

was definitely a suspect. Therefore, a viral serology panel was ordered to evaluate for recent viral infections. Surprisingly, the hCMV titers were each 3-4-fold elevated while the rest of viral patterns were within the normal range. They were asked to return to the office and each received 80 mg methylprednisolone acetate intramuscularly and 2000 mcg of cyanocobalamin and started on 1 mg of folic acid in a similar fashion as to how the physician had treated his own symptoms in 1997 following his HSE. They were asked to return to clinic in one week for follow-up. At this time both of their sedimentation rates were decreased and husbands sed rate was down to 50 and the wife's sed rate was down to 40 mm/hour. They were each excited as their impaired cognition has seemed to disappear and their strength was markedly improved and they each felt they had a "new lease on life" and were beginning to feel near normal. The injection of 2000 mcg of vitamin B12 was repeated and they were asked to return for weekly evaluations and repeat 2000mcg of vitamin B12 on a weekly basis. By the 2<sup>nd</sup> week each of their sed rates had returned to normal. The husband had one rebound of symptoms during the 3<sup>rd</sup> week and his sed rate had gone back from 15 mm/hour to 36 mm/hour so physician repeated a 2<sup>nd</sup> dose of methylprednisolone. After the 6<sup>th</sup> week neither the husband or wife required supplemental cyanocobalamin but they wished to continue the oral folic acid tablets. They were subsequently seen for routine examinations without reoccurrence of their respective symptoms of fatigue and impaired cognition.

Also, during this same time period, a female patient in her mid-thirties and three teenage males had nearly an identical set of clinical symptoms to the initial husband and wife presentations. They all had 2 to 4-fold elevations in their hCMV titers on viral serology testing and each had a more moderate elevation of their sedimentation rates with negative mono spot tests and no atypical lymphocytes on WBC blood smear examination. The female in her late thirties and was a vocal entertainer and requested to continue her cyanocobalamin injections once per month for a total of six months. All four of these patients had a full recovery from their devastating post viral fatigue syndrome and impaired cognition that allowed them to return to normal fulfilling quality of life without any residual symptoms. It should be noted here that methylprednisolone acetate should be carefully administered via a deep intramuscular injection so as to prevent dermal scarring by dimpling at the site of injection and that symptoms of adrenal fatigue - hypoadrenalism should be monitored carefully in addition to following the warnings in the package insert.

This small community outbreak of six patients with hCMV and post viral syndrome in addition to their similar history and physical findings suggest to the author that these similar treatment modalities might be successful in the treatment of LC/PASC and at the very least should be given serious consideration. These cases that were shared should provide somewhat of a proof of concept at the very least in addition to the case series by Regland et al [71]. Especially, since we now know that methylprednisolone was so helpful in saving lives during the acute COVID-19 pandemic and also now appreciating and better understanding the SARS-CoV-2 induced or related impaired folate-mediated one-carbon metabolism hypothesis as set forth in the text. The sequence of possible events of LC/PASC from this text is outlined ([Fig. S1](#)).



**Figure S1.** Possible sequence of events in acute-COVID-19 neurological sequela compared with Chronic Long Covid – Post-Acute Sequela of SARS-CoV-2 (LC/PASC). **Panel A** illustrates the acute phase of COVID-19 effects on the CNS (blue boxes). **Panel B** depicts the chronic post-COVID-19 phase of LC/PASC (red boxes). The sequence of events in chronic post-COVID-19 phase – LC/PASC begins in right-hand upper corner box (asterisk) of this figure. *AC(s)* = astrocytes; *CNSCC* = central nervous system cytokines/chemokines; *LC* = long COVID-19; *MGC(s)* = microglial cells; *PASC* = post-acute sequela of COVID-19; *PCC* = peripheral cytokines/chemokines;

Of course, time heals all wounds; however, the *LC/PASC* certainly seems to have a slow 'long and winding road' to recovery.

#### Addendum:

Probably one of best known of all viral infections that has a prolonged post viral syndrome of fatigue and myalgias is Epstein-Barr virus (EBV) infection (more commonly known as infectious mononucleosis). In these cases, author has repeatedly witnessed the positive effects of anti-inflammatory methylprednisolone acetate and vitamin B12 injections as described previously except for not using folic acid. This is especially true in EBV infections when there is or has been concurrent marked lymphadenopathy, hepatic and splenic enlargement with elevated hepatic enzymes associated with a definite active fatiguing and post viral syndrome. It is important to note that the use of corticosteroids have not been confirmed by any randomized clinical trials to date in regards to the prolonged nature of the post viral fatigue and in regards to their usage one should weigh the benefits verses the risk in each individual case presentation and it is suggested for those who wish to know more about EBV to read the following reference [101]. The use of vitamin B12 and folic acid (vitamin B9) can be more strongly supported now that we are beginning to better understand the implications of an impaired folate-mediated one-carbon metabolism mechanism that is presented in the text.

The burden of LC/PASC patients post-covid health care, especially in the more rural regions of this country, will largely be managed by the patients' family physicians and their supportive nurse practitioners and primary care providers in their outlying clinics [102]. Already, post covid multispecialty clinics have emerged that are associated with large hospital systems in larger cities, which are able to provide multiple specialists that will be required to address each possible dysfunction in multiple different organ systems since SARS-CoV-2 affects nearly all systems in the body and importantly the brain. Importantly, many of these patients will require a program of progressive physical therapy to help regain their pre-COVID physical activity and endurance. Professional health care teams who particularly have an older senior citizen clientele should consider reading a paper by a noted gerontologist [103]. The fact that the newer delta variant is now rampant in the United States and affecting a much younger population is very concerning since this age group of patients are the necessary working group that makes nations "hum".