SIUJ Société Internationale d'Urologie Journal

Article

Robotic-Assisted Simple Prostatectomy—Short Term Functional and Surgical Outcomes

Peter Stapleton [1,2,3,*], Niranjan Sathianathen [3], Rajinder Singh-Rai [1,4], Richard Wells [1,4], Emily Bak [4] and Andrew Fuller [1,2,4]

[1] Department of Surgery, Royal Adelaide Hospital, Adelaide 5000, Australia
[2] Department of Medicine, University of Adelaide, Adelaide 5000, Australia
[3] Department of Medicine, University of Melbourne, Melbourne 3010, Australia
[4] Department of Urology, South Terrace Urology, Adelaide 5000, Australia
* Correspondence: peter.stapleton@sa.gov.au; Tel.: +61-412170767

Abstract

Background/Objectives: To evaluate the surgical and functional outcomes of robot-assisted simple prostatectomy (RASP) for men with bothersome lower urinary tract symptoms (LUTS) secondary to benign prostatic hyperplasia (BPH), aiding informed clinical decision-making. **Methods:** We conducted a prospective study of 69 patients undergoing RASP for BPH-related LUTS or acute urinary retention (AUR). Three high-volume robotic urologists from a single center, utilising a modified Millins technique, performed the RASP procedures. Pre-operative data included demographics (age, prostate-specific antigen (PSA), prostate volume), LUTS measures (International Prostate Symptom Score (IPSS), quality-of-life (QOL), flow rates, pad use), and intraoperative parameters (operative time, blood loss, histology, hospital stay). Postoperative outcomes were collected at 6–8 weeks and included symptom scores, flow rates, pad use, and patient satisfaction. Data were analysed using descriptive statistics and multivariate linear logistic regression; significance was set at 95% confidence. **Results:** Median patient age was 74 years (interquartile range (IQR) 72–77) with a median prostate volume of 143 cc (IQR 123–195) and preoperative IPSS of 19 (IQR 15.0–23.0). Median console time was 60 min (IQR 50.0–65.0), estimated blood loss was 350.0 mL (IQR 200–500), and specimen weight was 105.5 g (IQR 67.25–132.5). Median hospital stay was 1.0 day; all patients passed their trial of void (TOV) postoperatively, with an IPSS improvement of 78.9% (12 points), QOL improvement of 75% (3 points), maximum flow rate (Qmax) increase of 16.3 mL/s and an overall patient satisfaction of 10 out of 10 (extremely satisfied), independent of specimen size, operative duration, or pad usage. **Conclusions:** RASP appears to be a safe and effective surgical option for men with high-volume BPH and bothersome LUTS, offering substantial symptom improvement and excellent patient satisfaction. Its advantages may extend to patients with very large prostates or concurrent bladder pathology. However, findings are limited by our modest sample size and short follow-up. Larger prospective and comparative trials are warranted to better define the role of RASP in the treatment algorithm for BPH.

Keywords: robotic-assisted simple prostatectomy (RASP); benign prostatic hyperplasia (BPH); lower urinary tract symptoms (LUTS)

Check for updates

Academic Editors: Henry Woo and Steffi Kar-Kei Yuen

Received: 20 April 2026
Revised: 25 June 2026
Accepted: 29 June 2026
Published: 12 August 2026

Copyright: © 2026 by the authors. Published by MDPI on behalf of the Société Internationale d'Urologie. Licensee MDPI, Basel, Switzerland. This article is an open access article distributed under the terms and conditions of the Creative Commons Attribution (CC BY) license.

1. Introduction

Benign prostatic hyperplasia (BPH) is a well-known and common condition affecting men's quality of life and places a significant burden on the healthcare system. Surgical

management options to improve lower urinary tract symptoms (LUTS) are predominantly endoscopic, with the 'gold standard' being a transurethral resection of the prostate (TURP) first described a century ago, in 1926 by Dr Stern [1]. TURP provides excellent functional and operative results [2]. However, when managing large and very large glands, the risk of complications such as transurethral resection (TUR) syndrome, incomplete resection, increased blood loss, and poorer functional outcomes increases [3]. For larger prostates typically > 80 cc, depending on the surgeon's expertise, TURP may no longer be a practical option due to the increased risks associated with prolonged resection time and bleeding [4]. In the setting of large and very large glands, simple prostatectomy and holmium laser enucleation of the prostate (HoLEP) have become the recommended procedures as they are not limited by prostate volume. The fundamental principle for these procedures is enucleation of the prostate gland with complete removal of the adenoma to relieve bladder outlet obstruction and improve LUTS.

As with most procedures, simple prostatectomy was initially performed as an open procedure; however, several randomized controlled trials (RCTs) have reported improved length of stay (LOS), complication rates and indwelling urinary catheter (IDC) duration with a minimally invasive laparoscopic approach [5–7]. Moreover, with the introduction of robotics into urological surgical practice in the early 2000s, it was not long after that the first robotic-assisted simple prostatectomy (RASP) was performed [8]. As with most pure laparoscopic procedures in urology, it has gradually been replaced by a robotic approach due to the improved ergonomics and comparable functional and operative outcomes [9].

After the introduction of RASP, there have been numerous advances in technology, surgical technique and understanding of the operative factors impacting recovery and functional outcomes. While there has been significant progress in robotic surgery, its use in BPH and functional urology is still 'under review' with European Association of Urology (EAU) and American Urological Association (AUA) considering it a treatment under investigation; however, it may be considered for patients with large (80–100 cc) and very large (>150 cc) prostates [10].

RASP, as with other enucleation procedures, has become more prominent in functional urology, as unlike other endoscopic procedures, it is not limited by gland size. Moreover, as robotic systems and robotic training become more common across healthcare networks, RASP is likely to become more readily available.

The aim of our study was to provide an updated and accurate assessment of the functional and surgical outcomes of RASP for men with BPH and bothersome LUTS or acute urinary retention (AUR).

2. Methods

We performed a prospective study of 69 patients who underwent a RASP for the treatment of BPH causing lower urinary tract symptoms or acute urinary retention. The study began enrolment in January 2024 and the last patient in this cohort was recruited in January 2026. RASP procedures were performed by three high-volume robotic oncological and functional urologists with over 4000 robotic cases collectively in a single centre. All patients were appropriately counselled regarding alternative treatment options and study requirements with their respective surgeons prior to RASP and study participation. As RASP is a relatively uncommon procedure, we did not include explicit inclusion or exclusion criteria but captured all patients who underwent the procedure. Discussion of suitability, alternatives including HoLEP, TURP and minimally invasive surgical therapies (MIST) interventions were discussed with all patients by the operating surgeon, prior to reaching a shared decision to proceed with RASP.

All RASP procedures were performed using a Da Vinci Xi surgical robot (Intuitive Surgical—Sunnyvale, California) utilising a standard 4-arm technique with identical port placement for robot-assisted radical prostatectomy (RARP). Instruments utilised included a monopolar scissors, Maryland bipolar forceps, tenaculum device and two needle drivers. The surgical technique adopted was a 'modified' Millin's (Figure 1); after port placement, the bladder was mobilised, and the prostatic-vesical junction was defined similarly to a RARP. The endopelvic fascia, puboprostatic ligaments and dorsal vein are all left intact. A small cystotomy is made and after defining the extent of the adenoma, a mucosal incision is made at the posterior bladder neck. The adenoma can then be either removed en bloc or in pieces, depending on the prostate size. Once the remaining prostatic adenoma is removed, the capsule is plicated with 2/0 v-lock 5/8 needle sutures to improve haemostasis and minimise the potential space for haematoma. Similar to a RARP anastomosis, a complete vesico-urethral anastomosis (VUA) is performed using 2/0 v-lock sutures on 5/8 needles. The prostatic capsule is then closed. The full procedure and figures are summarised in Appendix A.

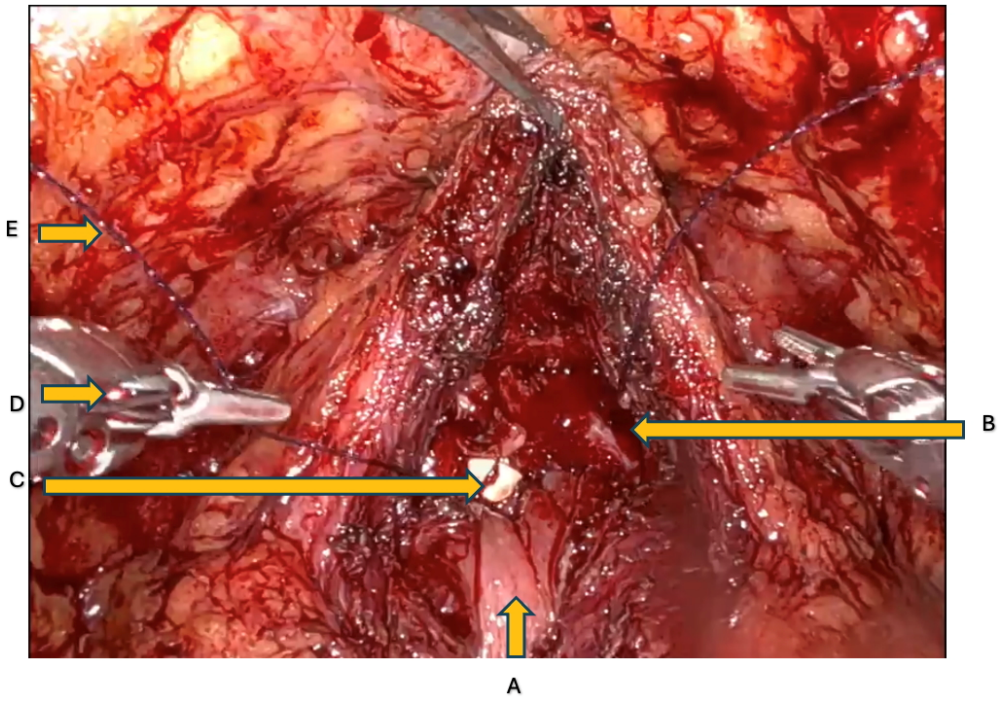

Figure 1. Demonstration of the vesicourethral anastomosis: the trigone has been pulled into the urethra prior to complete circumferential anastomosis, similar to that performed in robot-assisted radical prostatectomy (RARP). (A) Trigone, (B) Internal prostatic capsule, (C) Foley Catheter in the urethra, (D) Suture grasper, (E) V-lock suture on 5/8 needle.

The surgical approach utilised in our series differs from a standard Millins simple prostatectomy in several ways, including the port placement, bladder neck incision rather than vesicostomy, complete vesicourethral anastomosis and plication and closure of the prostatic capsule. We believe these adaptations to the procedural steps improved the surgical learning curve by adopting similar steps to those already used in RARP, reduced post-operative LUTS by using a complete VUA and minimised the potential space for haematomas and post-operative bleeding by plicating and closing the prostatic capsule. Because of this adaptive approach, no patient required postoperative irrigation and was able to be discharged from the hospital on day 1.

Pre-operative data were collected during initial consultation and included age, prostate-specific antigen (PSA), prostate size (based on best available imaging) and pre-

operative hemoglobin (Hb). Pre-operative data relating to patients' LUTS, International Prostate Symptom Score (IPSS), flow study, quality-of-life (QOL), number of pads, and prior LUTS operations, were collected by the urology practice nurse. Operative data, including duration defined as console time, histology, estimated blood loss, hospital length of stay were collated from hospital records. Postoperative data included duration of indwelling catheter, trial of void outcome, complications and postoperative PSA. Postoperative functional outcomes were then assessed again at 6–8 weeks to compare flow rate, IPSS, QOL, number of pads and patient overall satisfaction to evaluate the efficacy of RASP both operatively and functionally for the management of BPH with LUTS. Data collection was performed by a study member independent of the operations.

All patients were appropriately consented and reviewed by their respective operating surgeons, including alternative procedures and associated risks and complications. Once they had chosen to proceed with a RASP procedure, they consented to the prospective trial. Ethics was approved through our local Human Research Ethics Committee (HREC), approval number 18743, 21 November 2023.

Data were analysed using standard descriptive measures and multivariate linear regression for comparison of continuous variables; significance was set to a a confidence interval (CI) of 95%.

3. Results

Our final sample size was 69 patients with a 100% completion of pre- and post-operative follow-up for study participants. The median age of our cohort was 74 yo (interquartile range (IQR) 72–77) with a median prostate volume of 143.0 cc (IQR 123.0–195.0). The median pre-operative IPSS was 19 (severe) (IQR 15.0–23.0), Qmax was 9.90 mL/s (IQR 5.80–13.70) and a QOL of 4 (mostly unhappy) (IQR 4–5), as summarised in Table 1.

Table 1. Patient demographics and pre-operative functional results.

n		**69**
Age (years) (median (IQR))		74 *(72, 77)*
Prostate size (mL) (median (IQR))		143 *(123, 195)*
Max flow rate (mL/s) (median (IQR))		9.9 *(5.8, 13.7)*
Average flow rate (mL/s) (median (IQR))		5.0 *(3.3, 7.0)*
Voided volume (mL) (median (IQR))		186 *(136, 241)*
Voiding time (s) (median (IQR))		47.0 *(30.9, 58.6)*
Pre-op IPSS (median (IQR))		19 *(11, 12)*
Nocturia (median (IQR))		3 *(2, 4)*
QOL (median (IQR))		4 *(4, 5)*
Pre-op PVR (mL) (median (IQR))		111 *(51, 236)*
Pre-op pads (median (IQR))		0 *(0)*
Pre-op PSA (median (IQR))		7.0 *(4.3, 11.6)*
IDC (%)	No	57 (82.6)
	Yes	12 (17.4)
Indication (%)	AUR	11 (15.9)
	LUTS	58 (84.1)

Table 1. *Cont.*

n		**69**
Haematuria (%)	No	51 (73.9)
	Yes	18 (26.1)
Prior LUTS operations (%)	No	66 (95.7)
	Yes	3 (4.3)
Bladder stone (%)	No	62 (89.9)
	Yes	7 (10.1)

QOL—Quality of life, IPSS—International prostate symptom score, IDC—Indwelling catheter, LUTS—Lower urinary tract symptoms, AUR—Acute urinary retention, IQR—Interquartile range, PVR—Post void residual, PSA—Prostate specific antigen.

The median console time was 60 min (IQR 50–65) with an estimated blood loss of 350 mL (IQR 200–500) and Hb change of −15.5 g/100 mL (−9.3–−21.8). Only two patients required a transfusion; one was planned pre-operatively due to an initially low pre-operative Hb of 92 due to other chronic conditions and the other for the largest gland in the series of 500 cc on multiparametric magnetic resonance imaging (mpMRI) and 291 g resected weight.

The median resected weight was 105 g (IQR 67–132). There were four incidental diagnoses of prostate cancer, all International Society of Urological Pathology (ISUP) 1, despite not being an oncological surgery, all cases reported as clear margins. The median post-operative PSA at 6–8 weeks was 0.44 (IQR 0.22–1.28). All patients were standardised to an overnight stay in hospital, unless prolonged admission was required to resolve a complication. IDC duration was also standardised to 7 days.

All patients completed post-operative flow studies, IPSS and overall satisfaction scores as summarised in Table 2.

Table 2. Summary of surgical and functional outcomes at 6–8-week follow-up.

n	**69**
Console time (min) (median (IQR))	60 *(50, 65)*
Blood loss (mL) (median (IQR))	350 *(200, 500)*
Hb change g/L (median (IQR))	−15.5 *(−21.8, −9.3)*
Transfusion (median (IQR))	0 *(0, 0)*
LOS (days) (median (IQR))	1 *(1, 1)*
Specimen weight (g) (median (IQR))	105.5 *(67.3, 132.5)*
IDC duration (days) (median (IQR))	7 *(7, 7)*
Time to follow up (days) (median (IQR))	48 *(43, 53)*
IPSS (median (IQR))	4 *(3, 8)*
Nocturia (median (IQR))	1 *(1, 2)*
QOL (median (IQR))	1 *(0, 2)*
Max flow (mL/min) (median (IQR))	26.6 *(18.4, 34.4)*
Average flow (mL/min) (median (IQR))	14.0 *(9.0, 16.9)*
Voided volume (mL) (median (IQR))	247.5 *(161, 310)*

Table 2. *Cont.*

n		**69**
Voiding time (s) (median (IQR))		20.0 *(14.8, 27.0)*
PVR (mL) (median (IQR))		10 *(2, 28)*
Pads (median (IQR))		0 *(0, 0)*
PSA (median (IQR))		0.44 *(0.22, 1.28)*
PROM (median (IQR))		10 *(9, 10)*
Malignancy (%)	No	65 (94.2)
	Yes	4 (5.8)
Passed TOV (%)	No	0 (0)
	Yes	69 (100)
Complication (%)	No	64 (92.8)
	Yes	5 (7.2)

LOS—Length of stay, PVR—Post void residual, PSA—Prostate specific antigen, PROM—Patient reported outcome measures, TOV—Trial of void, IQR—Interquartile range, IPSS—International prostate symptom score, IDC—Indwelling catheter, QOL—Quality of life, Hb—Hemoglobin.

Table 3 represents the median change 'Δ' between pre- and post-operative key functional scores. Demonstrating a median increase in maximum flow rate (Qmax) of 16.3 mL/s, a 12 pt median reduction in patients' IPSS scores and a 3 pt improvement in QOL scores.

Table 3. Summary of surgical and functional change from pre- and post-RASP.

n	**69**
ΔMax flow rate (mL/s) (median (IQR))	16.3 (6.7, 26.8)
ΔAverage flow (mL/s) (median (IQR))	8.7 (4.0, 12.0)
ΔVoiding time (s) (median (IQR))	−24.1 (−38.0, −10.9)
ΔPVR (mL) (median (IQR))	−99 (−201, −37)
ΔIPSS (median (IQR))	−12 (−17, −7)
ΔNocturia (median (IQR))	−1 (−2, 0)
ΔQOL (median (IQR))	−3 (−4, −2)
ΔPads (median (IQR))	0 (0, 0)
ΔPSA (median (IQR))	−6.08 (−10.12, −3.32)

IQR—Interquartile range, PVR—Post void residual, QOL—Quality of life, PSA—Prostate-specific antigen, RASP—Robot-assisted simple prostatectomy, IPSS—International prostate symptom score.

Five patients experienced complications, summarised in Table 4.

Table 4. Summarising cohort complications.

Complication Grade (Clavien-Dindo)	**Details of the Complication**	**Intervention to Resolve Complication**
2	Bilateral PEs	Started on therapeutic anti-coagulation
2	Chest pain and concern for MI	Serial troponins negative, however progressed to inpatient angiogram (no occlusion, no stents)
2	Gastric Volvulus	Managed conservative with General surgery

Table 4. *Cont.*

Complication Grade (Clavien-Dindo)	Details of the Complication	Intervention to Resolve Complication
3b	Urethral stricture with AUR	Return to theatre for urethral dilation
3b	Sub-meatal stenosis	Return to theatre 8 weeks post RASP for cystoscopy and urethral dilation

PEs—Pulmonary embolisms, MI—Myocardial infarction, AUR—Acute urinary retention, RASP—Robotic-assisted simple prostatectomy.

The patient was bilateral pulmonary embolisms (PEs) had a total knee replacement 8 weeks prior to RASP and was post operatively diagnosed with a deep vein thrombosis (DVT), likely a contributing factor to his later subsegmental PEs. He was started on full anti-coagulation 5 days post op without bleeding complications and made a complete recovery. The patient with chest pain had no cardiovascular compromise and was discharged without the need for intervention. He was booked for follow-up with a cardiologist as a precaution and further outpatient risk assessment. The patient suffering from a gastric volvulus had suffered recurrent episodes prior to his operation and was safely managed by his general surgeon during the admission with a nasogastric tube, without the need for surgical intervention. It is possible the Trendelenburg position used for the operation may have precipitated this event and intra-operative placement of an nasogastric tube (NGT) may have prevented the complication. The two patients suffering from urethral stricture disease are believed to be related to catheter placement, as both patients had easy passage of IDC during the procedure, and the site of stricture was distal to the VUA. Potentially, the use of a smaller (14–12 Fr) IDC and generous use of lubricants may have prevented these strictures. However, both patients underwent urethral dilation with cystoscopy under sedation, with improvement in symptoms and no recurrence.

On multivariate linear logistic regression, we found that patient prostate volume directly correlated with increased operative duration, suggesting that every 1 cc increase in prostate volume increased console time by 0.12 min (95% CI 0.07–0.17). Additionally, prior LUTS procedures were more likely to have increased operative duration (95% CI 2.1–40.3), although it should be noted that our sample size was three and was, therefore, likely underpowered. The prior procedures included a greenlight, urolift and TURP, with an average prostate volume (PV) of 174 cc.

Increased operative duration and prostate volume were both associated with increased estimated blood loss (p-value < 0.001, 95% CI 3.39–9.46), with an adjusted coefficient of 6.42 mL/min and 2.2 mL/cc (95% CI 1.5–2.9).

When assessing post-operative IPSS in a multivariate linear regression model against age, pre-operative Qmax, IPSS, patient-reported outcome measure (PROM) and prostate size, only PROM was statistically significant (p-value < 0.001, 95% CI −2.51−−1.26), likely representing a correlation that IPSS and PROM accurately represented the patient's satisfaction and symptoms.

We completed a subgroup analysis of prostates >150 cc compared with ≤150 cc, Table 5. There was no statistically significant difference in operative duration, estimated blood loss, or Hb change, IPSS and Qmax. Although no statistical difference was found between the two cohorts, this may have been limited by the modest sample sizes.

Table 5. Subgroup analysis of prostates >150 cc and ≤150 cc.

Prostate Size (cc)	Sample Size	Duration (min)	Blood Loss (mL)	Hb Change (g/L)	IPSS Change	Qmax Change (mL/s)
>150	33	60 (50–80)	400 (300–600)	−18 (−22–−10)	−13 (−15.5–−10)	13.5 (7.4–27.8)
≤150	36	53 (45–65)	325 (200–500)	−14 (−21–−8)	−12 (−18.5–−7)	17.5 (6.1–25.2)
p-value		0.0800	0.1011	0.2855	0.9626	0.9046

IPSS—International Prostate Symptom Score, Qmax—Maximum flow rate.

4. Discussion

Our study reviewed the functional and operative outcomes for RASP for BPH associated with LUTS and AUR. All participants underwent pre and post-operative functional assessments. We demonstrated that RASP was a safe operative approach for large and very large glands, while still maintaining at or above accepted functional outcomes for BPH operations. All patients passed their trial of void (TOV) postoperatively, with an IPSS improvement of 78.9% (12 points), QOL improvement of 75% (3 points), Qmax increase of 16.3 mL/s and an overall patient satisfaction of 10 out of 10 (extremely satisfied).

Several other studies have assessed the functional and surgical outcomes of RASP (Table 6). Notably, many of these studies have small sample sizes, with only a few containing comparative operations (HoLEP, open simple prostatectomy (OSP) and laparoscopic simple prostatectomy (LSP)). Our study compares well with the current literature and supports the available evidence on the functional and surgical outcomes for RASP as a suitable alternative for LUTS secondary to BPH.

Table 6. Comparative studies assessing RASP surgical and functional outcomes.

Study	Design	N (RASP)	Comparison	Follow Up (Months)	Specimen Weight (g)	OT Duration (min)	IPSS Change	Qmax Change (mL/s)
Mourmouris et al. (2019) [11]	Multi-center Prospective	26	OSP (15)	3	115.33 (SD ± 38.49)	134 vs. 88	17 vs. 17	9 vs. 17
Bove et al. (2023) [12]	Multi-center Prospective	43	HoLEP (54)	12	102 (89–120)	111 vs. 70	15 vs. 13	14 vs. 13
Cardi et al. (2023) [13]	Single-center Prospective	80	None	6	102 (78–176)	105	15	12
Pavan et al. (2016) [14]	Multi-center Retrospective	130	LSP (189)	10	77 (58–101)	150 vs. 120	18 vs. 15	13 vs. 15
Bove et al. (2023) [15]	Single-center Retrospective	72	None	36	90 (80–116)	128	21	14
Pokorny et al. (2015) [16]	Single-center Retrospective	67	None	6	84 (65–114)	97	22	16

OSP—open simple proctectomy, LSP—Laparoscopic simple proctectomy, RASP—Robotic-assisted simple prostatectomy, IPSS—International Prostate Symptom Score, Qmax—Maximum flow rate, HoLEP—Holmium laser enucleation of the prostate, OT—Operating theatre, SD—Standard deviation.

Additionally, our series utilised a novel operative approach (Appendix A) compared with a standard Millins and Freyers, which we believe helps to improve the learning curve for already established robotic oncological surgeons, minimise post-operative irritative LUTS, and reduce the potential space for haematoma and bleeding.

There are three different approaches to simple prostatectomy: open, laparoscopic and robotic-assisted. As with many surgical procedures, minimally invasive techniques have improved surgical outcomes and reduced morbidity for patients. A recent systematic review and meta-analysis of trials comparing minimally invasive simple prostatectomy versus OSP found that RASP had similar efficacy in terms of symptom and flow rate improvement, but shorter catheterisation time, length of stay, lower transfusion rates and lower complication rates overall [6–8]. Hence, with the rise in technology and availability, robotic-assisted has become the favored approach for simple prostatectomy.

Several RASP techniques have been described, broadly divided into transvesical approaches and techniques that more closely resemble RARP. Traditional transvesical RASP involves a wide cystotomy with direct entry into the bladder and subsequent adenoma enucleation, facilitating identification of the ureteric orifices and median lobe anatomy. However, this approach may provide less favorable visualisation of the prostatic apex and typically relies on trigonal advancement or bladder neck reconstruction rather than a formal vesicourethral anastomosis. In contrast, our modified Millin's technique incorporates several reconstructive principles adopted from RARP, including preservation of the endopelvic fascia and dorsal venous complex, enucleation through a bladder neck incision, complete circumferential vesicourethral anastomosis, and closure of the prostatic capsule. Similar RARP-like approaches have been described by Sotelo et al., Coelho et al., and other contemporary robotic series, demonstrating favorable functional outcomes and reduced IDC duration [9,10]. We believe that the addition of a complete VUA may offer several theoretical advantages, including reduction in dead space, improved haemostasis through capsule plication, minimisation of postoperative irritative symptoms, and facilitation of adoption by surgeons already familiar with robotic prostatectomy techniques. While these advantages remain difficult to quantify in a non-comparative series, they may have contributed to the low complication rate, universal successful trial of void, and short length of stay observed in our cohort.

The perioperative features of our cohort compare favourably with the wider literature. The prostate gland size was similar to other studies, with the median gland size in our cohort of 143.0 cc (IQR 123.0–195.0) compared with other reviews that reported prostate volumes ranging from 81 cc to 136 cc [16–19]. The median console time in our cohort was 60 min (IQR 50–65.00), which was shorter than other papers that reported surgical durations of 97 to 182 min [19,20]. A number of factors may influence operative duration, including patient co-morbidities, previous abdominal operations and surgeon experience. All surgeons in our study were established, high-volume robotic surgeons working in a single centre. We also had a median length of stay of one day; this was standard practice for all participating surgeons, with only 4 of the 69 patients requiring LOS >1 day. One patient stayed 7 days due to bilateral pulmonary emboli (undiagnosed post total knee replacement 6 weeks earlier), managed with therapeutic Clexane, another stayed 2 days due to post-operative pain. When compared with other studies, there is a significant difference in reported LOS post RASP 3–5 days [21,22]. We utilised a modified Millian's technique in a RARP, aiming to improve vesical-urethral anastomosis in order to minimise the potential space to decrease blood loss and post-operative haematomas, which can delay discharge. All patients passed post-operative TOV on day 7.

All patients in our prospective study attended follow-up for assessment of their functional outcomes, with a median follow-up of 49 days (IQR 43–54). Although our study lacks long-term functional outcome results, Lee [7] demonstrated in their retrospective review of 150 cases with a median follow-up of 36 months, stable functional outcomes with no incidences of bladder neck stenosis or re-intervention [20].

The functional results of our cohort were comparable to current best-practice interventions, both from patients' reported symptoms and objective functional scores. The change in median IPSS was 12 pts, with an overall post-operative IPSS median of 4 (Mild). The Qmax change was 16.3 mL/s, from 9.9 mL/s to 26.6 mL/s. These functional outcomes were again supported by the patient-reported QOL improvement from 4 (mostly unhappy) to 1 (pleased), and a median patient-reported satisfaction score of 10 (IQR 9–10) (extremely satisfied). When compared with other RASP studies, the functional results in our review were analogous to those reported in the literature [21,23,24].

When compared with HoLEP, an equivalent enucleation procedure of the prostate for BPH and bothersome LUTS, RASP has similar operative and functional outcomes. Grosso et al., in a prospective review of HoLEP and RASP, found HoLEP to have slightly improved IDC duration, operative time and LOS compared with RASP [20]. However, the operative duration for RASP patients in their review was 105 min with a LOS of 5 days, compared with 60 min and 1 day in our cohort, which may suggest that these outcomes can be improved depending on surgical practice and protocol. Nevertheless, Grosso et al. demonstrated that the IDC duration was less in the HoLEP cohort, and this reached statistical significance (3 vs. 2 days) [20], similar to our cohort with a standardised duration of 7 days. Functionally, both operations have excellent outcomes. Lim et al. demonstrated a 12 pt reduction in median IPSS and an 8.3 mL/s increase in Qmax at 3 months post HoLEP in their prospective study [25], which is comparable to our cohort with a 12 pt decrease in IPSS and a 16.3 mL/s increase in Qmax at 49 days.

This study represents one of the largest prospective RASP trials in the literature, measuring both functional and surgical outcomes; however, it is still somewhat limited by its small sample size of 69 patients. Additionally, our median follow-up was only 49 days, which limits our assessment of long-term outcomes and complications such as bladder neck stenosis and recurrent LUTS requiring re-intervention. Our cohort was also from a single centre with high-volume robotic urologists, which may not be representative of other healthcare networks. Unfortunately, sexual function scores and including erectile dysfunction (ED) and retrograde ejaculation, were not included in our pre and post-operative assessments. Moreover, we were unable to include a comparative intervention such as HoLEP or TURP in the study, which limits our ability to conclude how RASP may have compared with other types of surgical management in our cohort.

5. Conclusions

Patients with bothersome LUTS or AUR secondary to BPH with large and very large prostate volumes can be safely and effectively treated with RASP. Our series, although limited by its modest sample size, has demonstrated the comparable operative and functional outcomes associated with RASP in the short term and how it may be practically utilised in a healthcare setting. However, further multicentre and larger prospective and randomised studies with extended duration are required to better understand the outcomes associated with RASP when compared with the alternative standards of care such as HoLEP and TURP.

Author Contributions: P.S.—Principal investigator, data analysis, manuscript drafting and editing; N.S.—Statistical analysis and interpretation; R.S.-R.—Supervisor; R.W.—Supervisor; E.B.—Data collection; A.F.—Supervisor, data collection, manuscript editing. All authors have read and agreed to the published version of the manuscript.

Funding: The authors declare that no funds, grants, or other support were received during the preparation of this manuscript.

Institutional Review Board Statement: This study was performed in line with the principles of the Declaration of Helsinki. Ethics approval by SA Health Central Adelaide Local Health Network HREC, approval number 18842 on 21 November 2023.

Informed Consent Statement: Informed consent for participation was obtained from all subjects involved in the study.

Data Availability Statement: The data presented in this study are available on request from the corresponding author. The data are not publicly available due to privacy and ethical reasons.

Acknowledgments: Emily Bak and the support staff at South Terrace Urology for their assistance with data collection and participant support.

Conflicts of Interest: The authors declare no conflicts of interest.

Appendix A

Instruments—Monopolar scissors (A), Maryland bipolar forceps (B), Robotic tenaculum device (C), Needle driver x2 (D).

Step 1—Port placement: Identical to the port placement in a RARP. 8 mm camera port 15cm from the pubic symphysis (A). 8 mm robotic arm ports 8 cm lateral to the camera port (B and C), Further 8mm robot port and 12 mm insufflation port 8 cm lateral to either right or left robotic arms (D and E) and a 5 mm assist port triangulated between the camera port and robot arm port (F).

Step 2—Bladder mobilisation and division of the urachus and defining the prostatic-vesical junction. [A] Prostate capsule, [B] Monopolar scissors and [C] Prostatic-vesical junction.

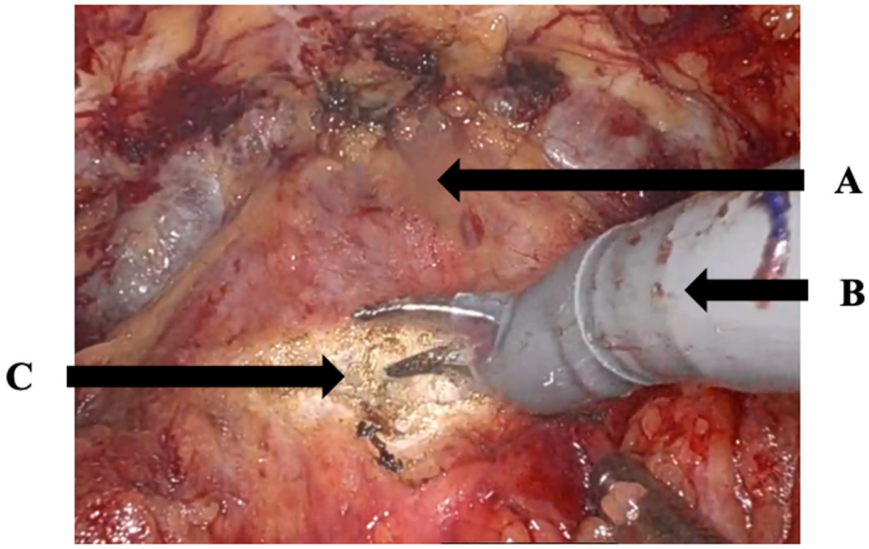

Step 3—Entering the bladder and defining the extent of the adenoma. [A] Anterior bladder neck, [B] Prostate adenoma and [C] Tenaculum device.

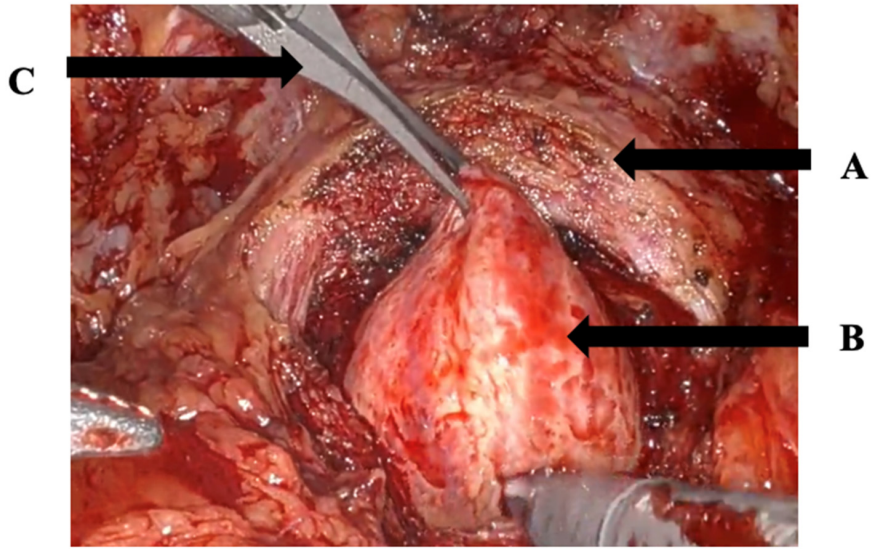

Step 4—Identification of the ureteric orifices and a mucosal incision at the posterior bladder neck.

Step 5—Removal of the adenoma, either enbloc or in pieces, depending on size. [A] Monopolar scissors and [B] Prostate adenoma being resected in pieces.

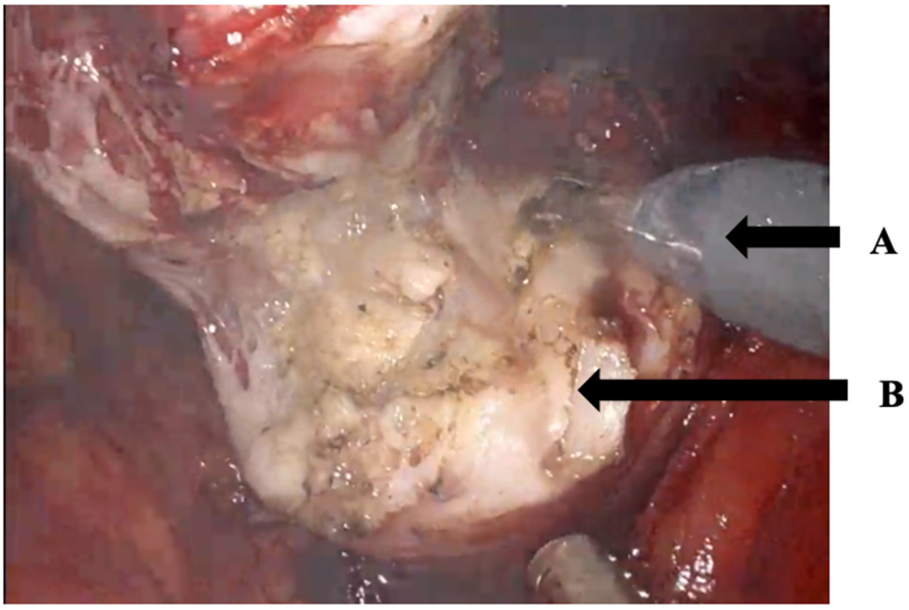

Step 6—Ligation of the feeding vessels into the prostatic capsule with 2 v-lock sutures on 5/8 needles. [A] Needle driver, [B] Prostatic capsule, [C] v-lock on 5/8 needle and [D] Prostatic capsule.

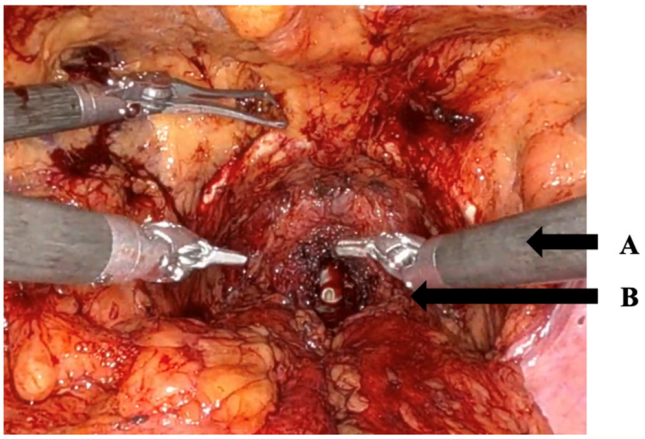

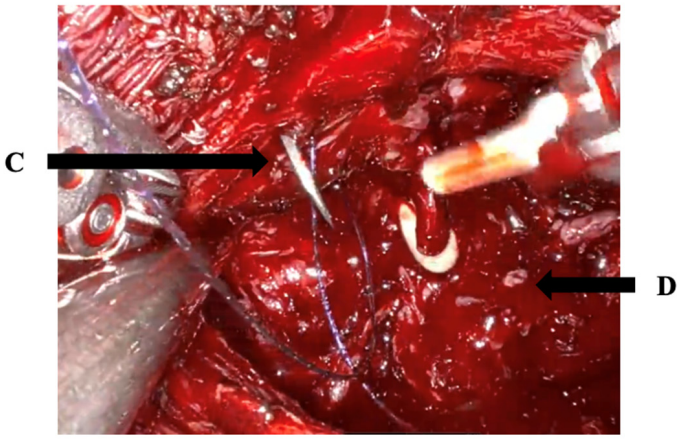

Step 7—Trigonalisation and complete vesicourethral anastomosis, identical to a RARP, using 2 v-lock sutures on 5/8 needles. [A] Foley catheter, [B] Trigone, [C] circumferential mucosal anastomosis and [D] Foley catheter.

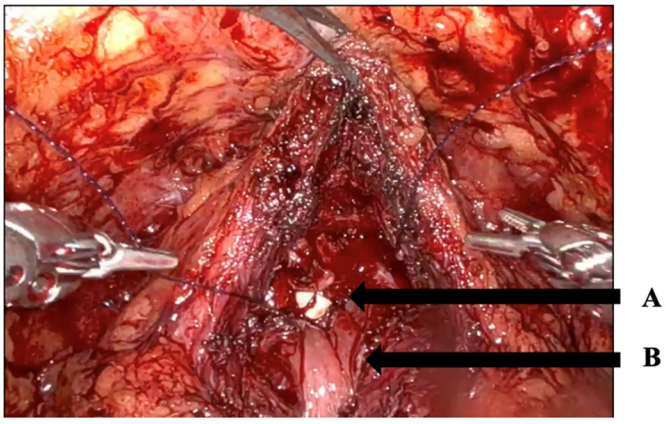

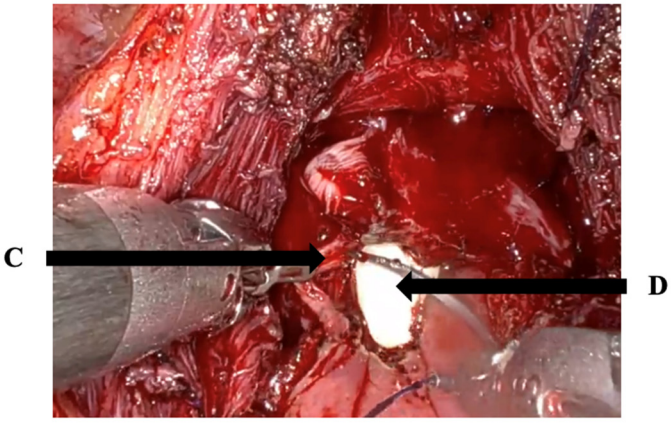

Step 8—180 mL normal saline leak test and closure of the prostatic capsule, reducing the potential space and improving haemostasis. [A] Prostatic capsule and [B] Anterior bladder.

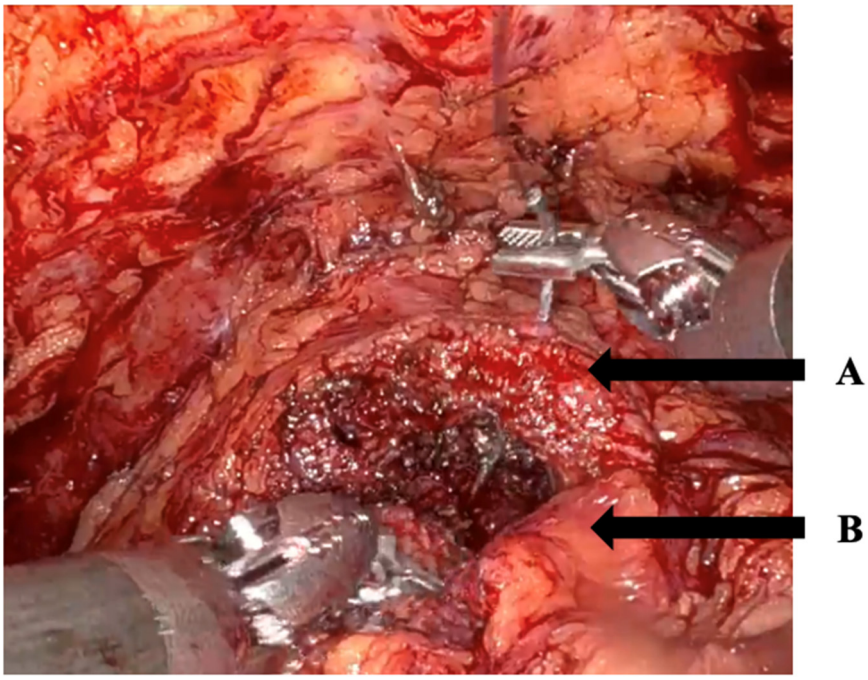

References

1. Strebel, R.T.; Kaplan, S.A. The state of TURP through a historical lens. *World J. Urol.* **2021**, *39*, 2255–2262. [CrossRef] [PubMed]
2. Cornu, J.-N.; Ahyai, S.; Bachmann, A.; de la Rosette, J.; Gilling, P.; Gratzke, C.; McVary, K.; Novara, G.; Woo, H.; Madersbacher, S. A Systematic Review and Meta-analysis of Functional Outcomes and Complications Following Transurethral Procedures for Lower Urinary Tract Symptoms Resulting from Benign Prostatic Obstruction: An Update. *Eur. Urol.* **2015**, *67*, 1066–1096. [CrossRef] [PubMed]
3. Elkoushy, M.A.; Elhilali, M.M. Management of Benign Prostatic Hyperplasia Larger than 100 ml: Simple Open Enucleation Versus Transurethral Laser Prostatectomy. *Curr. Urol. Rep.* **2016**, *17*, 44. [CrossRef] [PubMed]
4. Rassweiler, J.; Teber, D.; Kuntz, R.; Hofmann, R. Complications of Transurethral Resection of the Prostate (TURP)—Incidence, Management, and Prevention. *Eur. Urol.* **2006**, *50*, 969–980. [CrossRef] [PubMed]
5. Garcia-Segui, A.; Angulo, J.C. Prospective study comparing laparoscopic and open adenomectomy: Surgical and functional results. *Actas Urol. Esp.* **2017**, *41*, 47–54. [CrossRef] [PubMed]
6. Porpiglia, F.; Terrone, C.; Renard, J.; Grande, S.; Musso, F.; Cossu, M.; Vacca, F.; Scarpa, R.M. Transcapsular adenomectomy(Millin): A comparative study, extraperitoneal laparoscopy versus open surgery. *Eur. Urol.* **2006**, *49*, 120–126. [CrossRef] [PubMed]
7. Baumert, H.; Ballaro, A.; Dugardin, F.; Kaisary, A.V. Laparoscopic versus open simple prostatectomy: A comparative study. *J. Urol.* **2006**, *175*, 1691–1694. [CrossRef] [PubMed]
8. Dobbs, R.W.; Halgrimson, W.R.; Talamini, S.; Vigneswaran, H.T.; Wilson, J.O.; Crivellaro, S. Single-port robotic surgery: The next generation of minimally invasive urology. *World J. Urol.* **2020**, *38*, 897–905. [CrossRef] [PubMed]
9. Li, K.-P.; Chen, S.-Y.; Yang, L. Laparoscopic simple prostatectomy versus robot-assisted simple prostatectomy for large benign prostatic hyperplasia: A systematic review and meta-analysis of comparative trials. *J. Robot. Surg.* **2023**, *17*, 351–364. [CrossRef] [PubMed]
10. American Urological Association. Management of Lower Urinary Tract Symptoms Attributed to Benign Prostatic Hyperplasia: AUA Guideline 2026. Available online: https://www.auanet.org/guidelines-and-quality/guidelines/benign-prostatic-hyperplasia-(bph)-guideline (accessed on 12 April 2026).
11. Mourmouris, P.; Keskin, S.M.; Skolarikos, A.; Argun, O.B.; Karagiannis, A.A.; Tufek, I.; Obek, C.; Riza Kural, A. A prospective comparative analysis of robot-assisted vs open simple prostatectomy for benign prostatic hyperplasia. *BJU Int.* **2019**, *123*, 313–317. [CrossRef] [PubMed]
12. Bove, A.M.; Brassetti, A.; Ochoa, M.; Anceschi, U.; D'Annunzio, S.; Ferriero, M.; Tuderti, G.; Misuraca, L.; Mastroianni, R.; Cartolano, S.; et al. Robotic simple prostatectomy vs. HOLEP, a 'multi singlecenter' experiences comparison. *Cent. Eur. J. Urol.* **2023**, *76*, 128–134. [CrossRef]

13. Cardi, A.; Palleschi, G.; Patruno, G.; Tuffu, G.; D'Amico, F.E.; De Vico, A.; Carilli, M.; Pacini, P.; Pletto, S.; D'Elia, G. Robot-assisted simple prostatectomy for treatment of large prostatic adenomas: Surgical technique and outcomes from a high-volume robotic centre. *World J. Urol.* **2023**, *41*, 515–520. [CrossRef] [PubMed]
14. Pavan, N.; Zargar, H.; Sanchez-Salas, R.; Castillo, O.; Celia, A.; Gallo, G.; Sivaraman, A.; Cathelineau, X.; Autorino, R. Robot-assisted Versus Standard Laparoscopy for Simple Prostatectomy: Multicenter Comparative Outcomes. *Urology* **2016**, *91*, 104–110. [CrossRef] [PubMed]
15. Bove, A.M.; Brassetti, A.; Ochoa, M.; Anceschi, U.; Ferriero, M.; Tuderti, G.; Misuraca, L.; Mastroianni, R.; Cartolano, S.; D'Annunzio, S.; et al. Robotic-assisted simple prostatectomy: Long-term, trifecta- and pentafecta-based analysis of functional outcomes. *Ther. Adv. Urol.* **2023**, *15*. [CrossRef]
16. Pokorny, M.; Novara, G.; Geurts, N.; Dovey, Z.; De Groote, R.; Ploumidis, A.; Schatteman, P.; De Naeyer, G.; Mottrie, A. Robot-assisted simple prostatectomy for treatment of lower urinary tract symptoms secondary to benign prostatic enlargement: Surgical technique and outcomes in a high-volume robotic centre. *Eur. Urol.* **2015**, *68*, 451–457. [CrossRef] [PubMed]
17. Sorokin, I.; Sundaram, V.; Singla, N.; Walker, J.; Margulis, V.; Roehrborn, C.; Gahan, J.C. Robot-Assisted Versus Open Simple Prostatectomy for Benign Prostatic Hyperplasia in Large Glands: A Propensity Score-Matched Comparison of Perioperative and Short-Term Outcomes. *J. Endourol.* **2017**, *31*, 1164–1169. [CrossRef] [PubMed]
18. Scarcella, S.; Castellani, D.; Gauhar, V.; Teoh, J.Y.-C.; Giulioni, C.; Piazza, P.; Bravi, C.A.; De Groote, R.; De Naeyer, G.; Puliatti, S.; et al. Robotic-assisted versus open simple prostatectomy: Results from a systematic review and meta-analysis of comparative studies. *Investig. Clin. Urol.* **2021**, *62*, 631–640. [CrossRef] [PubMed]
19. Dotzauer, R.; La Torre, A.; Thomas, A.; Brandt, M.P.; Böhm, K.; Mager, R.; Borgmann, H.; Jäger, W.; Kurosch, M.; Höfner, T.; et al. Robot-assisted simple prostatectomy versus open simple prostatectomy: A single-center comparison. *World J. Urol.* **2021**, *39*, 149–156. [CrossRef] [PubMed]
20. Grosso, A.A.; Amparore, D.; Di Maida, F.; de Cillis, S.; Cocci, A.; Di Dio, M.; Russo, G.I.; Cimino, S.; Quarà, A.; Salvi, M.; et al. Comparison of perioperative and short-terms out-comes of en-bloc Holmium laser enucleation of the prostate (HoLEP) and robot-assisted simple prostatectomy: A propensity-score matching analysis. *Prostate Cancer Prostatic Dis.* **2024**, *27*, 478–484. [CrossRef] [PubMed]
21. Clavijo, R.; Carmona, O.; De Andrade, R.; Almanzor, O.; Garza, R.; Fernandez, G.; Sotelo, R. Robot-Assisted Intrafascial Simple Prostatectomy: Novel Technique. *J. Endourol.* **2013**, *27*, 328–332. [CrossRef] [PubMed]
22. Matei, D.V.; Brescia, A.; Mazzoleni, F.; Spinelli, M.; Musi, G.; Melegari, S.; Galasso, G.; Detti, S.; de Cobelli, O. Robot-assisted simple prostatectomy (RASP): Does it make sense? *BJU Int.* **2012**, *110*, E972–E979. [CrossRef] [PubMed]
23. Fareed, K.; Zaytoun, O.M.; Autorino, R.; White, W.M.; Crouzet, S.; Yakoubi, R.; Haber, G.-P.; White, M.A.; Kaouk, J.H. Robotic single port suprapubic transvesical enucleation of the prostate (R-STEP): Initial experience. *BJU Int.* **2012**, *110*, 732–737. [CrossRef] [PubMed]
24. Lee, Z.; Lee, M.; Keehn, A.Y.; Asghar, A.M.; Strauss, D.M.; Eun, D.D. Intermediate-term Urinary Function and Complication Outcomes After Robot-Assisted Simple Prostatectomy. *Urology* **2020**, *141*, 89–94. [CrossRef] [PubMed]
25. Lim, E.C.; Gu, H.M.; Yu, S.H.; Lim, D.G.; Chung, H.S.; Jung, S.I.; Kwon, D.; Kang, Y.J.; Yim, N.Y.; Hwang, E.C. Comparison of the efficacy and safety of holmium laser enucleation of the prostate and prostate artery embolization: Short-term follow-up results. *Prostate Int.* **2025**, *13*, 155–160. [CrossRef] [PubMed]

Disclaimer/Publisher's Note: The statements, opinions and data contained in all publications are solely those of the individual author(s) and contributor(s) and not of MDPI and/or the editor(s). MDPI and/or the editor(s) disclaim responsibility for any injury to people or property resulting from any ideas, methods, instructions or products referred to in the content.