

Ramin Sami¹, Mohammadali Zohal², Forozan Mohammadi³

¹Department of Internal Medicine, Isfahan University of Medical Sciences, Isfahan, Iran, Isfahan, Iran

²Pulmonary Diseases, Metabolic Diseases Research Center, Qazvin University of Medical Sciences, Qazvin, Iran, Metabolic Diseases Research Center, Velayat Hospital, 22 Bahman Blvd., Elahiyeh, Qazvin, Iran, Qazvin, Iran

³Department of Pathology, National Research Institute of Tuberculosis and Lung Disease, Shahid Beheshti University of Medical Sciences, Tehran, Iran

Adult onset still disease associated with endogenous lipid pneumonia

The authors declare no financial disclosure

Abstract

Cholesterol pneumonia or endogenous lipid pneumonia (ELP) is a rare disease that can occur in the context of a systemic disease or following a bronchial obstruction. It is characterized by a wide range of diverse symptoms and various disease course. The present report introduces a young woman diagnosed with adult onset still disease three years ago, who has been referred with macrophage activation syndrome (MAS). She underwent biopsy due to dyspnea and a crazy paving pattern in HRCT of the lungs, leading to the diagnosis of lipid pneumonia based on the interstitial lymphocytic inflammation and cholesterol granulomas. So far, there has been no report indicating MAS associated with cholesterol pneumonia. This is the second case reporting ELP in the adult onset still disease.

Key words: endogenous lipid pneumonia; cholesterol pneumonia; adult onset still disease

Adv Respir Med. 2019; 87: 50–53

Introduction

Lipoid pneumonia or cholesterol pneumonia is caused by the accumulation of cholesterol in the lungs. Fat could enter the lungs exogenously through the mouth and nose, which is also called *exogenous lipoid pneumonia*, or could be accumulated endogenously in the lungs [1]. It seems that the inability of macrophages to gather cholesterol collected in the alveoli due to the destruction of the type-II pneumocytes results in the endogenous accumulation of fat in the lungs [2]. The accumulation of fat in the lung tissue causes fibroblastic inflammation of the interstitial lung tissue, which can lead to progressive dyspnea and, in some cases, respiratory failure. Notwithstanding the common exogenous lipoid pneumonia, the endogenous type of this disease is rare, so that only a few cases have been reported thus far.

Adult onset still disease (AOSD) is characterized by the joints' involvement associated with systemic symptoms, which is commonly found in adolescence. Although pulmonary involvement is not frequent in AOSD, pulmonary hypertension and pleuritis are known as the most common pulmonary involvements associated with this disease.

In addition, a few cases of interstitial lung tissue involvement have been reported among these patients [3]. In this report, the described case is a patient with AOSD who developed cholesterol pneumonia.

Case report

The patient was a 22-year-old, non-smoking woman, who had been receiving prednisolone and methotrexate treatments as soon as being

Address for correspondence: Mohammadali Zohal, Pulmonary Diseases, Metabolic Diseases Research Center, Qazvin University of Medical Sciences, Qazvin, Iran, Metabolic Diseases Research Center, Velayat Hospital, 22 Bahman Blvd., Elahiyeh, Qazvin, Iran., Qazvin, Iran, e-mail: Zohal11@yahoo.com
DOI: 10.5603/ARM.a2019.0008

Received: 2.09.2018

Copyright © 2019 PTChP

ISSN 2451–4934

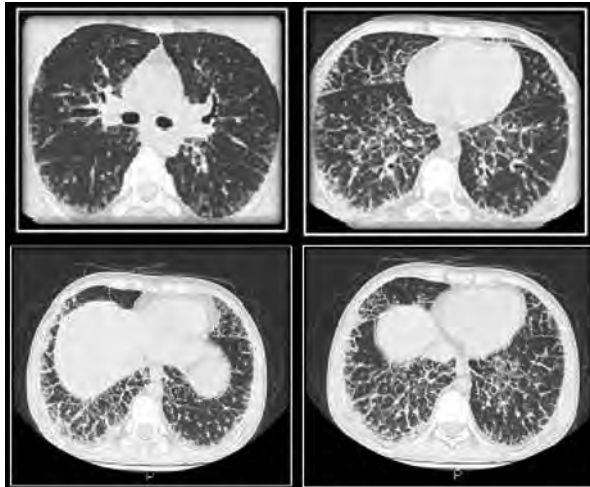


Figure 1. High-resolution computed tomography scan revealed diffuse crazy paving appearance in mid, and lower lobes of both lungs with ground glass opacity and coarse interlobular septal thickening

diagnosed with AOSD one year ago. She had been referred for a visit due to high fever, diarrhea, coughing, and dyspnea. She had fever as well as tachypnea and tachycardia during the examinations. The arterial oxygen saturation was 89%, and the scattered petechial lesions could be observed on her thorax. The lung and abdomen examinations showed the end inspiratory crackles in the lungs and mild organomegaly in the abdomen. The patient was diagnosed as pancytopenic by the laboratory tests, and also, the ESR was shown to be equal to 120. The CT scan of the lungs represented the diffuse bilateral perilymphatic nodularity view associated with interseptal thickening (crazy paving pattern) (Fig. 1). The woman underwent bronchoscopy. The bronchial washing was performed, and the specimens underwent microbial examination for microbes, tuberculosis and *Pneumocystis carinii* PCR, the results of which were all negative. Afterwards, the transbronchial lung biopsy was carried out, which showed no considerable results, except for a brief lymphocytic inflammation.

The patient initially underwent the treatment with broad-spectrum antibiotics and, then, since there was no fever break and lymphocytic hemophagocytic syndrome was diagnosed, she received the pulse corticosteroid and endoxane treatments. As no improvement was observed in the systemic symptoms, etanercept was started for the patient. Six months later, despite the improved systemic symptoms, the dyspnea still continued. The spirometry exhibited a severe non-reversible obstruction view. Also, the previous results were still observed in the new CT chest images. Considering

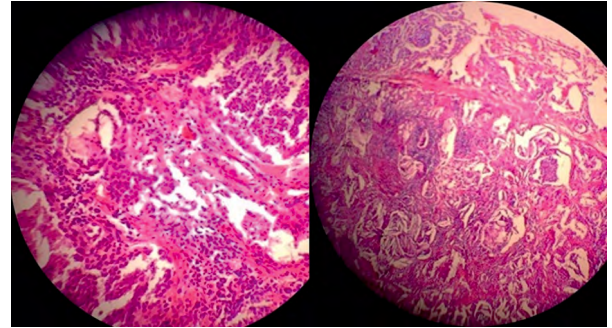


Figure 2. In the microscopic view there are lymphocytic interstitial and intra alveolar infiltration and intra alveolar, bronchiolar and scattered interstitial cholesterol clefts

such condition, the patient underwent open lung wedge biopsy from the lower right-side lobe. The macroscopic view showed the lung stiffness, and stiff nodules inside it could be touched. In the microscopic view, prepared sections revealed inflammatory cell infiltration of the interstitium, mainly lymphocytes. There are intra-alveolar aggregation of inflammatory cells, granular material and macrophage, prominent intra-alveolar, bronchiolar and scattered interstitial cholesterol clefts are noted (Fig. 2). The patient was diagnosed with lipid pneumonia. Given that there was no response to the treatments, the woman was included in the lung transplant list.

Discussion

The patient was a young woman with diagnosed AOSD, who had been receiving the treatments for three years. The lung biopsy led to the lipid pneumonia diagnosis. Notwithstanding a few reports on the pulmonary involvement in AOSD, the lipid pneumonia involvement is yet very rare in this disease [4].

Lipid pneumonia is divided into two types, namely exogenous and endogenous. In contrast to exogenous type that is quite common, the endogenous type, which is also known as cholesterol pneumonia, is rare. In the pathology of these patients, in addition to the cholesterol granules inside the alveoli and interstitial tissue, lymphocytic inflammation of the interstitial tissue is also observed [5, 6]. Therefore, the previously used term “pulmonary interstitial and intra- alveolar cholesterol granuloma” (PICG) has been replaced with the terms “endogenous lipid pneumonia” (ELP) or “cholesterol pneumonitis”, which are currently used. There are a few reports of ELP among the rheumatologic patients [3, 6, 7].

Since only a few patients have been reported with diagnosed ELP, and also, these cases have been found in different conditions, the clinical course of the disease is still unknown. In some cases, the disease emerges as a mass, and the patient expresses only complaints of coughing. On the other hand, it may occur as a progressive dyspnea caused by the development of the disease [1]. In the present case, the woman had a one-year progressive dyspnea. Given the underlying cause of the disease, the imaging results can also vary in ELP. In this study, the patient's CT scan showed crazy paving. The most important findings include nodularity, alveolar opacity, and ground glass opacity [8]. In contrast to lipid exogenous pneumonia and fatty tumors, the lesion density in ELP is not fat density [1], the reason of which is probably fibrosis caused by fat accumulation.

The best method for the diagnosis of ELP is the lung biopsy. Although the fat-containing macrophages can be observed in the bronchial lavage, yet there was no such finding for our patient. Besides, the biopsy specimen extracted from transbronchial lung biopsy in our patient was not diagnostic. Considering the advancements in the new sampling methods, cryobiopsy can probably be an appropriate method for the diagnosis of this disease. All the treatment methods in this regard have been experimental and there is no confirmed treatment for ELP. Since many of the ELP cases occur in the context of another underlying disease, the treatment should be focused on that disease. The systemic corticosteroid, TNF α antagonist, intravenous immunoglobulins [IVIg], and complete lavage of the lungs are the methods that have been used for treatment to date [9–11]. If ELP emerges as a post-obstruction case, removing the obstruction or frequent lavage of the lungs will serve as the best treatment method [1]. In the cases in which the disease emerges as a mass and is diagnosed by biopsy, it is not certainly known whether the mass removal is necessary or not. However, in the cases of extensive disease, particularly when it is associated with systemic diseases and the patient is symptomatic, prescription of the immunosuppressive drugs has been proved to be successful in some instances [9].

The pulmonary involvement among the rheumatologic patients is also a drug side effect. Although our patient was receiving the treatment with methotrexate, ELP has not been reported to date as a side effect of this drug. In addition, discontinuing medication after 6 months had no

consequence on the pulmonary lesions in our subject. Therefore, the use of methotrexate did not seem to be the cause of this complication in this case. As for our patient, the abnormal macrophage activity, which had led to MAS, could probably be associated with the incidence of ELP, but we could not perform the necessary investigations in this regard. Furthermore, the patient's systemic complications were controlled by etanercept, but the pulmonary involvement is still continued, leading to the listing the patient as a candidate for the lung transplantation.

Conclusion

In the present study, a patient with AOSD who had chronic dyspnea due to ELP, was introduced. Although many causes have been identified for dyspnea in rheumatologic diseases, ELP is not known as a common cause yet. According to this report, it is proposed to apply lung biopsy in the cases of the interstitial pulmonary involvement with no identified cause in rheumatologic patients.

Conflict of interest

The authors declare no conflict of interest.

References:

1. Betancourt SL, Martinez-Jimenez S, Rossi SE, et al. Lipoid pneumonia: spectrum of clinical and radiologic manifestations. *AJR Am J Roentgenol*. 2010; 194(1): 103–109, doi: [10.2214/AJR.09.3040](https://doi.org/10.2214/AJR.09.3040), indexed in Pubmed: [20028911](https://pubmed.ncbi.nlm.nih.gov/20028911/).
2. Kissmann G, Zamboni M, Salarini Monteiro A, et al. [Lipoid pneumonia]. *Rev Port Pneumol*. 2008; 14(4): 545–549, indexed in Pubmed: [18622532](https://pubmed.ncbi.nlm.nih.gov/18622532/).
3. Kimura Y, Weiss JE, Haroldson KL, et al. Childhood Arthritis Rheumatology Research Alliance Carra Net Investigators. Pulmonary hypertension and other potentially fatal pulmonary complications in systemic juvenile idiopathic arthritis. *Arthritis Care Res (Hoboken)*. 2013; 65(5): 745–752, doi: [10.1002/acr.21889](https://doi.org/10.1002/acr.21889), indexed in Pubmed: [23139240](https://pubmed.ncbi.nlm.nih.gov/23139240/).
4. Schultz R, Mattila J, Gappa M, et al. Development of progressive pulmonary interstitial and intra-alveolar cholesterol granulomas (PICG) associated with therapy-resistant chronic systemic juvenile arthritis (CJA). *Pediatr Pulmonol*. 2001; 32(5): 397–402, indexed in Pubmed: [11596165](https://pubmed.ncbi.nlm.nih.gov/11596165/).
5. Byerley JS, Hernandez ML, Leigh MW, et al. Clinical approach to endogenous lipid pneumonia. *Clin Respir J*. 2016; 10(2): 259–263, doi: [10.1111/crj.12203](https://doi.org/10.1111/crj.12203), indexed in Pubmed: [25123703](https://pubmed.ncbi.nlm.nih.gov/25123703/).
6. Lin J, Huang LL, Zhang JW, et al. Endogenous lipid pneumonia presenting as solitary pulmonary nodule: a case report. *Int J Clin Exp Pathol*. 2015; 8(8): 9727–9730, indexed in Pubmed: [26464746](https://pubmed.ncbi.nlm.nih.gov/26464746/).
7. Barta Z, Szabo GG, Bruckner G, et al. Endogenous lipid pneumonia associated with undifferentiated connective tissue disease (UCTD). *Med Sci Monit*. 2001; 7(1): 134–136, indexed in Pubmed: [11208509](https://pubmed.ncbi.nlm.nih.gov/11208509/).
8. Baron SE, Haramati LB, Rivera VT. Radiological and clinical findings in acute and chronic exogenous lipid pneumonia. *J Thorac Imaging*. 2003; 18(4): 217–224, indexed in Pubmed: [14561906](https://pubmed.ncbi.nlm.nih.gov/14561906/).

9. Morita H, Arai S, Kurasawa K, et al. Intensive immunosuppressive therapy for endogenous lipoid pneumonia associated with rheumatoid arthritis. *Mod Rheumatol.* 2018; 28(6): 1044–1048, doi: [10.1080/14397595.2016.1193270](https://doi.org/10.1080/14397595.2016.1193270), indexed in Pubmed: [27321430](https://pubmed.ncbi.nlm.nih.gov/27321430/).
10. Lococo F, Cesario A, Porziella V, et al. Idiopathic lipoid pneumonia successfully treated with prednisolone. *Heart Lung.* 2012; 41(2): 184–187, doi: [10.1016/j.hrtlng.2011.01.003](https://doi.org/10.1016/j.hrtlng.2011.01.003), indexed in Pubmed: [21419490](https://pubmed.ncbi.nlm.nih.gov/21419490/).
11. Amato GM, Novara V, Amato G. [Lipid pneumonia. Favorable outcome after treatment with intravenous immunoglobulins, steroids, cephalosporins]. *Minerva Pediatr.* 1997; 49(4): 163–169, indexed in Pubmed: [9244843](https://pubmed.ncbi.nlm.nih.gov/9244843/).