



Extended Abstract

Photobiostimulation Therapy in Non-Responsive Oral Ulcerative Aftosis: 3 Cases Reports [†]

Maria Giulia Nosotti ^{1,*}, Matteo Fanuli ², Luca Viganò ³ and Cinzia Casu ⁴

¹ RDH, Department of Human Sciences, Innovation and Territory, Dental Hygiene School, University of Insubria, Via Giuseppe Piatti 10, 21100 Varese, Italy

² RDH, Department of Biomedical, Surgical and Dental Sciences, University of Milan, 20122 Italy; matteo.fisher@hotmail.it

³ DDS, Department of Radiology, San Paolo Dental Bulding, University of Milan, 20142 Italy; luca.vigano1@unimi.it

⁴ DDS, Private Dental Practice, Cagliari, 09126 Italy; ginzia.85@hotmail.it

* Correspondence: mg.nosotti@gmail.com

[†] Presented at the XV National and III International Congress of the Italian Society of Oral Pathology and Medicine (SIPMO), Bari, Italy, 17–19 October 2019.

Published: 12 December 2019

1. Introduction

Ulcerative aftosis are peculiar painful lesions widely observed with common histological and pathological aspect with doubtful etiology and fewer predictable treatments [1]. These lesions are considered with primary importance in detection of some systemic issues and are often related to a wide number of pathological immune and stress-related impairments [2,3]. Elective treatment ranges from light topical anesthetics to ialuronate-based topical medications. As a bacterial thesis is proposed but never widely accepted, treatment oriented in antimicrobial way are very common, but presents few predictable results due to high heterogeneity. Here we evaluate a Photobiostimulation tissue-healing protocol [4].

2. Materials and Methods

Three patients were observed, diagnosed and treated in private practice office.

Patient history 1. Male aged 47 years, suffering from anxiety no systemic disease. He does not suffer from recurrent aphthous, referring only few episodes.

Patient history 2. Female aged 34, Hashimoto thyroiditis, recurrent aphthous stomatitis for 2 and a half years. Slow healing of mouth ulcers episodes (Figure 1).

Patient history 3. Female aged 60. Gluten intolerance, absent systemic diseases. 3 Episodes of recurrent aphthosis per year (always single and minor).

Stimulation was performed using light Laser B-cure 808 nm wavelenght, 250 mw power (Erika Carmel Ltd., Jerusalemm, Israel). It was applied directly on mouth ulcerations for 6 consecutive minutes. The device does not include projective tips, there are no probes to be applied.

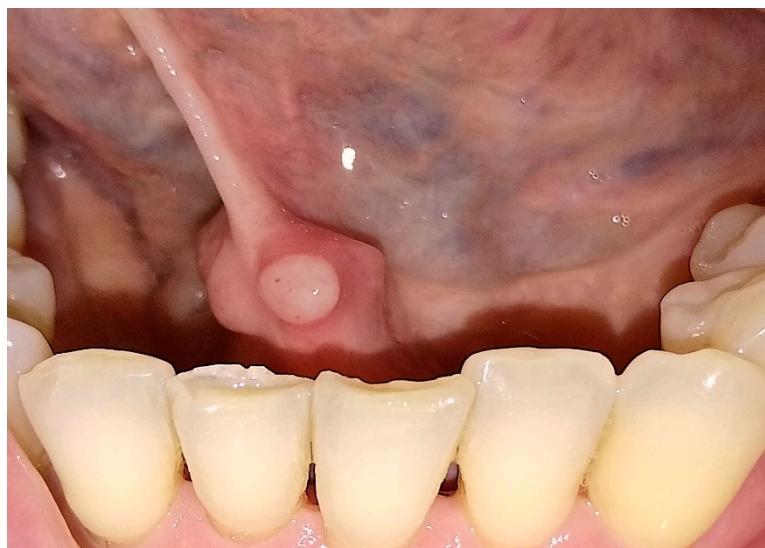

Figure 1. Patient before using the laser.

3. Results

All patients showed minor and major improvements. After 24 h, no pain symptoms were reported. After 2 days, partial or complete healing of the lesions was observed (Figure 2).

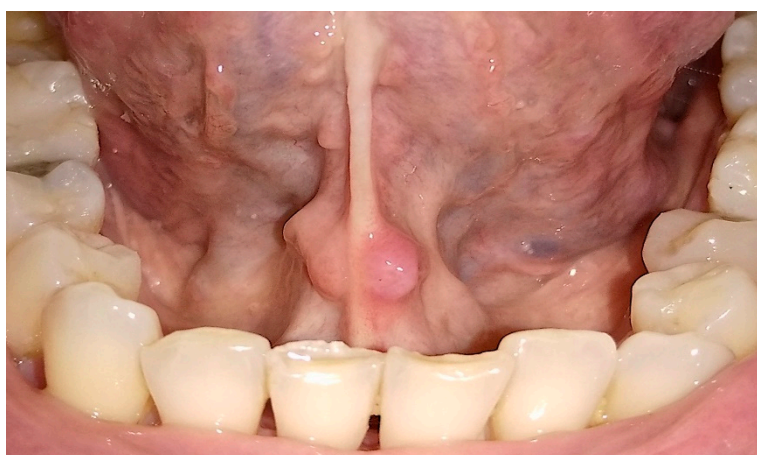


Figure 2. Patient two days after using the laser.

4. Discussion and Conclusions

Photobiostimulations protocols can be applied in the treatment of oral ulcerative lesions in recurrent cases. More reports and in vitro studies are needed to perform severe and well designed clinical protocols.

Conflicts of Interest: The authors declare no conflict of interest.

References

1. Saikaly, S.K.; Saikaly, T.S.; Saikaly, L.E. Recurrent aphthous ulceration: A review of potential causes and novel treatments. *J. Dermatol. Treat.* **2018**, *29*, 542–552.
2. Suter, V.G.A.; Sjölund, S.; Bornstein, M.M. Effect of laser on pain relief and wound healing of recurrent aphthous stomatitis: A systematic review. *Lasers Med Sci.* **2017**, *32*, 953–963.
3. Pavlić, V.; vujić-Aleksić, V.; Aoki, A.; Nežić, L. Treatment of recurrent aphthous stomatitis by laser therapy: A systematic review of the literature. *Vojnosanit. Pregl.* **2015**, *72*, 722–728.

4. Najeeb, S.; Khurshid, Z.; Zohaib, S.; Najeeb, B.; Qasim, S.B.; Zafar, M.S. Management of recurrent aphthous ulcers low-level lasers: A systematic review. *Medicina (Kaunas)* **2016**, *52*, 263–268.



© 2019 by the authors. Licensee MDPI, Basel, Switzerland. This article is an open access article distributed under the terms and conditions of the Creative Commons Attribution (CC BY) license (<http://creativecommons.org/licenses/by/4.0/>).