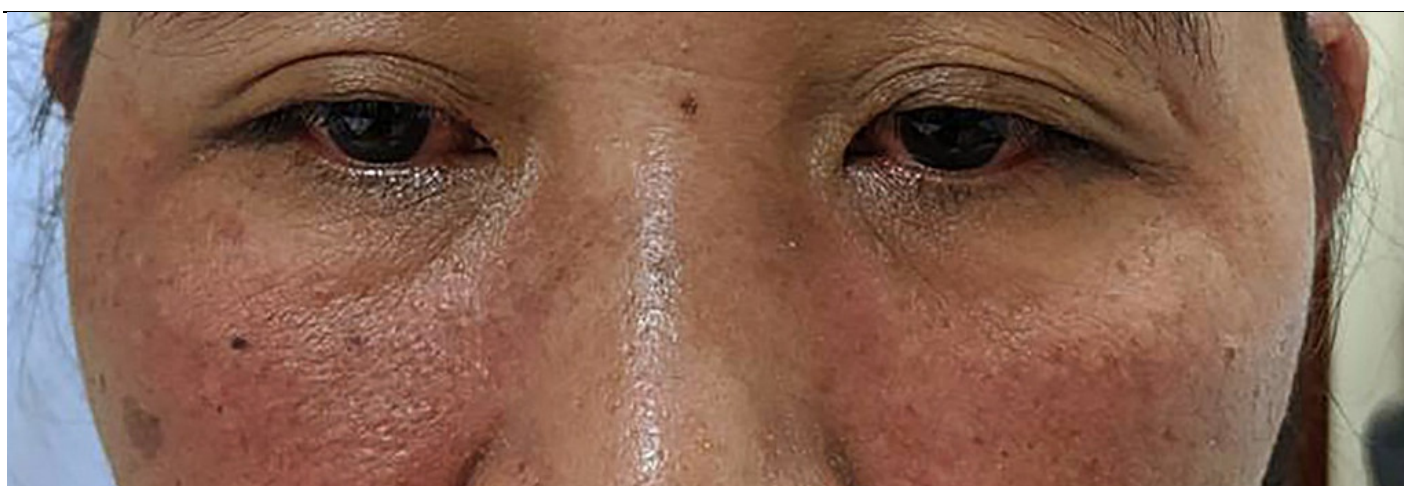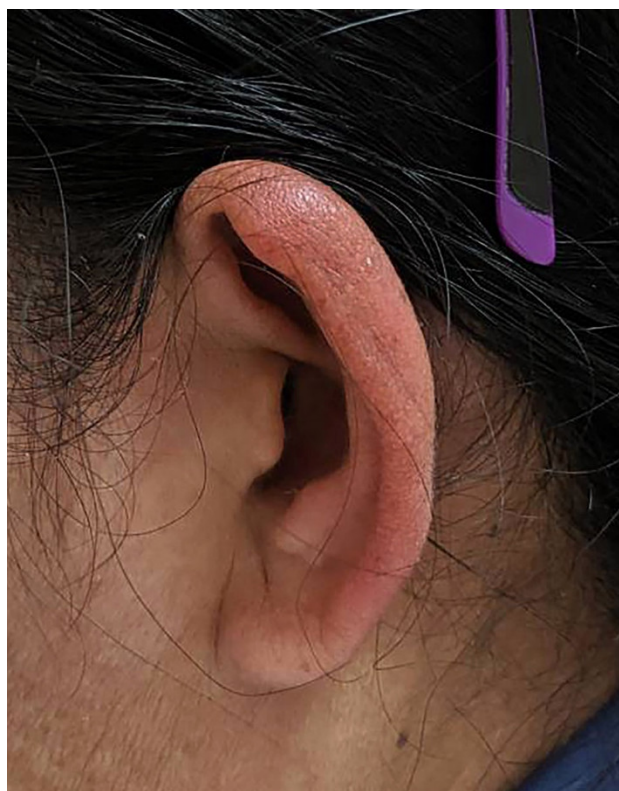

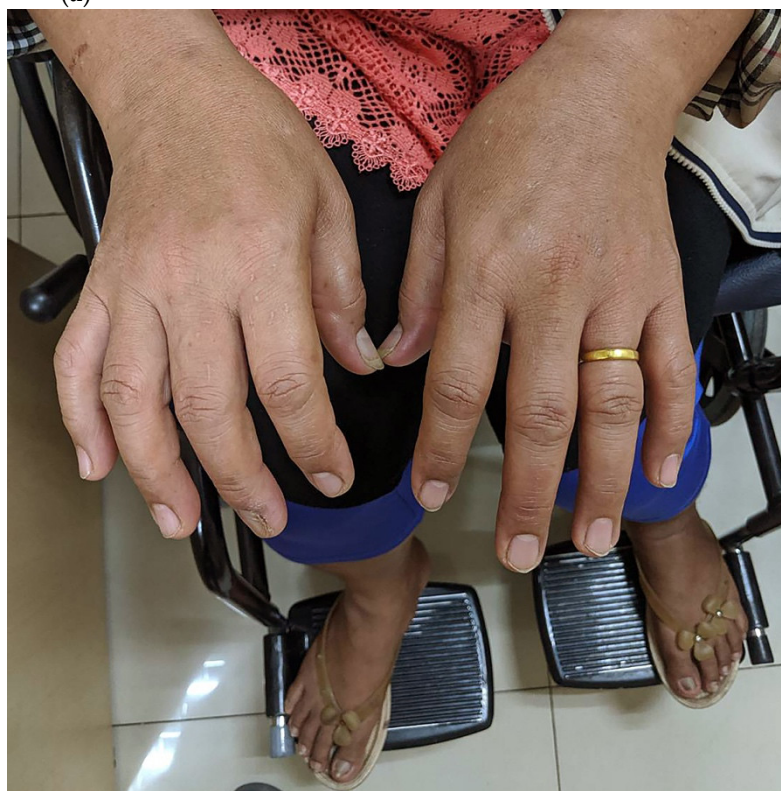
(a)



(b)



(c)

**Figure S1** Images taken at presentation to the Fever Clinic during the acute CHIKV infection (October 2019). (a) Non-purulent conjunctivitis of both eyes and erythema over the cheeks, (b) erythema of the pinna (Milians ear sign), (c) bilateral swelling of metacarpophalangeal joints and ambulation in a wheel chair due to debilitating arthralgia of the knees